SECOND EDITION



# Dermatology Essentials

Jean L. Bolognia
Julie V. Schaffer
Karynne O. Duncan
Christine J. Ko

ELSEVIER

ALGrawany

SECOND EDITION

# Dermatology Essentials

**Jean L. Bolognia** MD
Professor of Dermatology
Yale Medical School
New Haven, CT, USA

**Julie V. Schaffer** MD
Professor of Pediatrics
Hackensack Meridian School of Medicine
Hackensack, NJ, USA

**Karynne O. Duncan** MD
Private Practice
St Helena, CA, USA

**Christine J. Ko** MD
Professor of Dermatology and Pathology
Yale Medical School
New Haven, CT, USA

For additional online content visit the expertconsult website:
www.expertconsult.com



ELSEVIER London New York Oxford Philadelphia St Louis Sydney 2022

ALGrawany

© 2022, Elsevier Inc. All rights reserved.
First edition 2014

No part of this publication may be reproduced or transmitted in any form or by any means, electronic or mechanical, including photocopying, recording, or any information storage and retrieval system, without permission in writing from the publisher. Details on how to seek permission, further information about the Publisher's permissions policies and our arrangements with organizations such as the Copyright Clearance Center and the Copyright Licensing Agency, can be found at our website: www.elsevier.com/permissions

This book and the individual contributions contained in it are protected under copyright by the Publisher (other than as may be noted herein).

**Notices**

Practitioners and researchers must always rely on their own experience and knowledge in evaluating and using any information, methods, compounds or experiments described herein. Because of rapid advances in the medical sciences, in particular, independent verification of diagnoses and drug dosages should be made. To the fullest extent of the law, no responsibility is assumed by Elsevier, authors, editors or contributors for any injury and/or damage to persons or property as a matter of products liability, negligence or otherwise, or from any use or operation of any methods, products, instructions, or ideas contained in the material herein.

**ISBN: 978-0-323-62453-4**

**Cover Photograph Credits**

*Cover photographs from left to right are courtesy of: Julie V. Schaffer MD, Yale Dermatology Residents' Slide Collection, Yale Dermatology Residents' Slide Collection, and Mark D.P. Davis MD*

*Content Strategist:* Charlotta Kryhl
*Content Development Specialist:* Joanne Scott
*Project Manager:* Joanna Souch
*Design:* Margaret Reid
*Illustration Manager:* Muthukumaran Thangaraj
*Marketing Manager:* Kate Bresnahan

Printed in Canada

Last digit is the print number: 9 8 7 6 5 4 3 2 1

ELSEVIER Book Aid International Working together to grow libraries in developing countries
www.elsevier.com • www.bookaid.org

# Preface

The goal of our *Dermatology Essentials* handbook is to present the broad spectrum of cutaneous diseases in a manner that is straightforward and logical while at the same time maintaining a necessary level of sophistication. The text portion of each section is relatively brief and easy to review, with schematics and tables providing additional and more detailed information. Throughout the handbook are algorithms that present a practical approach to evaluation, differential diagnosis, and treatment of skin disorders. The clinical photographs were chosen with two key objectives in mind – to provide characteristic examples of specific diseases and to offer key teaching points. It is our hope that this handbook will improve the dermatologic care of patients and provide clinicians with greater confidence as they approach patients with cutaneous diseases.



A L G r a w a n y

# Acknowledgments

We wish to thank all the dermatologists whose clinical photographs are used in this handbook as well as the textbook *Dermatology*. In particular we thank Kalman Watsky, MD, whose photographs appear throughout the book. The team at Elsevier has provided enormous support, in particular Joanne Scott and Joanna Souch. Charlotta Kryhl also provided guidance for the project.

The following were sourced from the **Yale Dermatology Residents' Slide Collection (YDRSC)**:

1.3C, 1.3F, 1.4Aiii, 1.5B, 1.6Cii, 1.13A, 2.1B, 2.3, 4.8D, 5.7A, e5.12C, 6.4B, 6.9, 6.12A, 6.15, 6.16, 6.17A, 6.17C, e6.18, e6.20A, e6.21A, e6.22, e6.24, e6.25A, e6.35, 7.2A, 7.2B, 7.3C, 7.3D, 7.6A, 7.8, 7.9A, e7.14, e7.19, e7.20, 8.3B, 8.6, 8.8, e8.10, 9.5A, 9.5D, 9.5E, 9.5G, 9.6A, 9.6B, 9.6C, 9.7, 9.9A, 9.9B, 9.11A, e9.12, e9.13, e9.14, e9.17A, e9.17C, e9.18, 10.3A, 10.7, 10.8A (inset), 10.9A, 12.12B, 12.12E, 12.17, e12.26, 13.2B, 13.2I, 14.1B, 14.1C, 15.1A, 15.1B, 15.2A, 15.2B, 15.6, 16.1B, 16.1C, 16.1E, 16.2A, 16.4, 16.7A, 16.7B, 16.8, 16.9, 16.10A, 17.3, 17.7C, 17.8, 17.9B, 17.10A, 17.12, 17.13D, e17.18, e17.23A, e17.23B, e17.24A, e17.26, e17.27B, e17.28A, e17.35, 18.1D, 18.8, 18.9C, 18.11A, 18.12A, 18.18, 19.1C, 19.2B, 19.4A, 19.4B, 19.5B, 19.10A, 19.10B, 19.10D, e19.20, 20.2A, 21.5C, 21.6B, 21.7A, e21.12A, 22.1A, 22.1B, 22.1C, 22.1D, 22.7A, 22.7C, 23.6A, 24.2B, 24.5B, 24.10, e24.12, e24.16, e24.22, 25.2A, 25.2B, 26.3A, 26.5A, 26.6A, 26.6C, 26.8A, e26.10A, e26.11, 27.3, 27.4, 28.2A, 28.2B, 28.15, e28.17, e28.18, e28.19A, e28.19B, e28.21, e28.24, e28.25, 29.3C, 29.4B, e29.16, 30.6B, 30.12, e30.14, 31.2B, 31.3A, 31.4D, 31.5, 31.11C, 31.11D, e31.15A, e31.15B, 32.6, 32.7A, 33.3A, 33.3B, 33.3D, 33.3E, 33.3F, 33.3G, 33.4A, 33.5, 33.6, 33.7C, 33.10, 33.11, 34.2A, 34.11B, 35.4, e35.13, e35.15, e35.17C, 36.6B, e36.19, 37.1A, 38.6, 38.8B, e38.10A, e38.10B, 39.3A, 39.7A, 39.8B, e39.14A, 40.1, 41.2A, 41.5A, e41.10, 42.5C, 42.7B, 42.8B, 42.10, 43.7A, 43.8A, 43.9B, 43.9D, 43.9E, e43.15, e43.16A, e43.18A, 44.1A, e44.5B, e44.7C, 45.3B, 46.6A, 46.6B, 46.8C, 46.10C, 46.10D, e46.22, 47.3B, 47.4B, 47.9, 47.10A, e47.14B, e47.15C, e47.24A, 48.1B, 48.1D, 48.9, 48.10, 48.11A, 48.11B, e48.14, 49.4A, e50.19, e50.21, 51.2C, 51.2E, 51.3B, 51.3D, e51.11A, e51.18A, e51.18B, 52.2B, 52.8C, 53.2B, 53.15, e53.24, 54.14, 54.15A, 54.15E, 54.15F, 54.15G, 54.16, 54.17, 54.18A, 54.19, 54.23A, 54.23B, e54.28, e54.29A, e54.31, 55.3B, 55.8B, 55.17B, 56.4A, 56.4D, 56.11C, 56.11D, 56.11E, 56.11G, 56.11H, 56.11J, 56.11K, e56.17, e56.27, 57.6, e57.15B, e59.22 (inset 2), e59.31A, e59.32, Table 59.3 (insets), 60.9A, e60.21A, e60.22, 61.5, 61.9A, 61.9B, 61.12, 61.17, e61.22B, e61.30, e61.31, e61.37, e61.38, e61.40, e61.42, 62.9, 62.10, 62.11B, 62.13, 62.15, 62.16, 62.17A, 62.17B, 62.17C, e62.18, e62.19, 63.5, 63.6, 64.3D, 64.8A, 64.8C, 64.10, 64.13A, 64.13C, 64.13D, 64.13E, 64.13F, 64.15F, 64.19A, 64.25A, 64.25B, 64.25D, 64.25E, e64.26B, e64.27, e64.57, 65.7, 65.9A, 65.9B, 65.11A, 65.12, 65.14, 65.17, e65.30B, 67.4A, 67.6A, 67.6B, 67.6C, 67.9A, 67.9D, 67.9E, 67.9H, 67.11A, 67.11B, 67.13, 68.7A, 68.7C, 69.2B, 69.4A, 69.4B, 69.4C, 69.4D, 69.5A, 69.5B, 69.5C, 69.6A, 69.6B, 69.9, 69.13A, 69.13C, 70.1B, 71.1, 71.2D, 71.11, e71.18A, 72.7, e72.12, Table 72.1 (inset 1), 73.2C, 73.4C, 73.13, e73.24F, e73.27C, 74.7A, e74.26, 76.1A, 76.1C, 76.1E, 76.5, 76.8, 76.10, e76.12, e76.13, 77.2, 77.3A, 77.10, 78.1A, 78.1C, 78.1D, 78.1E, 78.2C, 78.2D, 78.3B, 78.4, 78.19, e78.22, e78.23, e78.25, e78.29, 79.2, 79.4A, 79.4B, 79.5, 80.2A, 80.2B,

81.4B, 81.7, e81.14, 82.2C, e82.11, 83.6A, e83.14, 84.6B, 85.3, 85.4C, 85.6A, 85.16A, 85.22, 85.26, e85.37B, e85.45, 86.2A, 86.2B, 86.3A, 86.4A, 86.5E, 86.10, 86.11B, 86.13B, 86.15A, 87.9, 87.12A, 87.14, 88.3A, 88.3C, 88.4, 88.6B, 88.6C, 88.7B, 88.9C, 89.2B, 89.6A, 89.8A, 90.1A, 90.2, 90.6B, 90.12, e90.15, 91.2, 91.3, 91.4A, 91.5, 91.6, 91.7A, 91.8A, 91.9A, 91.11, 91.13, 91.14, 91.15, e91.18, e91.20B, 92.1, 92.4, 92.6, 92.7, 92.10B, 93.6E, e93.21A, 94.3, 94.4, e94.17, 95.5, 95.11, 95.12, 95.17A, e95.23, e95.24, e95.25, 96.5, 96.6, e96.13C, e96.14B, 99.1, 99.3A, e99.14, 100.3B, 100.3C and e100.6.

The following were sourced from the **NYU Dermatology Slide Collection (NYUDSC)**:

e7.13B, e7.23, e7.26, 8.3A, 8.4, 8.5, e8.14, 9.5C, 9.8B, e9.16, e9.17B, e9.24, 11.2C, 12.18, e14.14, e19.17, 20.3, 23.6B, 23.6C, 24.4, 36.5C, e36.13, e36.15, 40.4A, 46.7B, 53.11C, 55.3A, 55.4A, 55.4B, 56.6B, e56.14, 57.12, 59.6, 61.10C, 61.10D, 61.13, e61.35, 63.7A, 63.7B, 65.5, 65.11B, 68.6A, 68.6B, 69.8, e69.18, e71.19, 73.4B, 73.5B, e73.24C, 78.7A, 78.7B, e81.13, 95.6, 95.9, 95.10 and 95.20.

The following were sourced from the **USC Dermatology Residents' Slide Collection (USCDRSC)**:

4.6, 36.10, 38.1, 51.7C, 54.13, e55.23B, e60.16C, e61.36, 64.16A, 64.16B, 64.18, 64.22A, 64.22B, 64.23, e64.33, e65.29, 71.2C, e71.18B, 82.2A, 85.28, 91.12, 94.11, and e99.16.

The following were sourced from the **SUNY Stony Brook Dermatology Residents' Slide Collection (SUNYSBDRSC):**

Figure 54.15C.

Chapter 58, Nail Disorders – Nail photos are courtesy of Antonella Tosti, YDRSC, Julie V. Schaffer, and Jean L. Bolognia.

# Dedication

To our families, in particular our husbands – Dennis, Andy, David and Peter – who provided the indispensable support required to complete this book, from serving as sounding boards to creating quiet time in busy households.

# List of Abbreviations

| | |
|---|---|
| Ab | Antibody |
| ABI | Ankle–brachial index |
| ACE | Angiotensin-converting enzyme |
| AI-CTD | Autoimmune connective tissue disease |
| ALK | Anaplastic lymphoma kinase |
| AK | Actinic keratosis |
| ANA | Antinuclear antibody |
| ANCA | Antineutrophil cytoplasmic antibody |
| ART | Antiretroviral therapy |
| BB | Broadband |
| BCC | Basal cell carcinoma |
| BID | Two times daily |
| BSA | Body surface area |
| BUN | Blood urea nitrogen |
| CBC | Complete blood count |
| CDC | Centers for Disease Control and Prevention |
| CMV | Cytomegalovirus |
| CNS | Central nervous system |
| CO | Carbon monoxide |
| COPD | Chronic obstructive pulmonary disease |
| Cr | Creatinine |
| CRP | C-reactive protein |
| CS | Corticosteroids |
| CSF | Cerebrospinal fluid |
| CT | Computed tomography |
| CTCL | Cutaneous T-cell lymphoma |
| CXR | Chest X-ray |
| DDT | Dichlorodiphenyltrichloro-ethane (an insecticide) |
| Dx | Diagnosis |
| DDx | Differential diagnosis |
| DEET | N, N-diethyl-meta-toluamide |
| DFA | Direct fluorescence antibody |
| DHEAS | Dehydroepiandrosterone sulfate |
| DIHS | Drug-induced hypersensitivity syndrome (also known as DRESS) |
| DM | Diabetes mellitus |
| DRESS | Drug reaction with eosinophilia and systemic symptoms (also known as DIHS) |
| DVT | Deep vein thrombosis |
| EBV | Epstein–Barr virus |
| ECG | Electrocardiogram |
| EEG | Electroencephalogram |
| EGFR | Epidermal growth factor receptor |
| ELISA | Enzyme-linked immunosorbent assay |
| EMG | Electromyography |
| ESR | Erythrocyte sedimentation rate |
| FDA | US Food and Drug Administration |
| G6PD | Glucose-6-phosphate dehydrogenase |
| GI | Gastrointestinal |
| GM-CSF | Granulocyte–macrophage colony-stimulating factor |
| GVHD | Graft-versus-host disease |
| H&E | Hematoxylin and eosin |
| HBV | Hepatitis B virus |

A L G r a w a n y

| | |
|---|---|
| HCTZ | Hydrochlorothiazide |
| HCV | Hepatitis C virus |
| HIV | Human immunodeficiency virus |
| HPV | Human papillomavirus |
| HSCT | Hematopoietic stem cell transplant |
| HSV | Herpes simplex virus |
| ICU | Intensive care unit |
| IFE | Immunofixation electrophoresis |
| IL | Interleukin |
| IM | Intramuscularly |
| IV | Intravenous |
| IVIg | Intravenous immunoglobulin |
| KA | Keratoacanthoma |
| KOH | Potassium hydroxide |
| LDH | Lactate dehydrogenase |
| LE | Lupus erythematosus |
| LFTs | Liver function tests |
| LPLK | Lichen planus-like keratosis |
| MEN | Multiple endocrine neoplasia |
| MHC | Major histocompatibility complex |
| MRA | Magnetic resonance angiography |
| MRI | Magnetic resonance imaging |
| MRSA | Methicillin-resistant *Staphylococcus aureus* |
| NB-UVB | Narrowband UVB |
| NK | Natural killer |
| NMSC | Non-melanoma skin cancer |
| NSAIDs | Nonsteroidal anti-inflammatory drugs |
| OTC | Over-the-counter |
| PAS | Periodic acid Schiff |
| PCR | Polymerase chain reaction |
| PDGF | Platelet-derived growth factor |
| PDT | Photodynamic therapy |
| PET | Positron emission tomography |
| PO | Per os (oral administration) |
| PPD | Purified protein derivative |
| PUVA | Psoralen plus ultraviolet A light |
| RBC | Red blood cell |
| RPR | Rapid plasma reagin (test for syphilis) |
| Rx | Treatment |
| SC | Subcutaneous |
| SCC | Squamous cell carcinoma |
| SLE | Systemic lupus erythematosus |
| SPEP | Serum protein electrophoresis |
| SSRIs | Selective serotonin reuptake inhibitors |
| STIs | Sexually transmitted infections |
| TB | Tuberculosis |
| TCAs | Tricyclic antidepressants |
| TGF | Transforming growth factor |
| TID | Three times daily |
| TNF | Tumor necrosis factor |
| TPMT | Thiopurine methyltransferase |
| TSH | Thyroid stimulating hormone |
| TST | Tuberculin skin test |
| URI | Upper respiratory infection |
| UVA | Ultraviolet A |
| UVB | Ultraviolet B |
| UVA1 | Ultraviolet A1 (340–400 nm) |
| UVR | Ultraviolet radiation |
| VDRL | Venereal Disease Research Laboratory (test for syphilis) |
| VEGFR | Vascular endothelial growth factor receptor |
| VZV | Varicella–zoster virus |
| WBC | White blood cell count |
| XRT | Radiation therapy |

# Basic Principles of Dermatology

# 1

- In the approach to the patient with a dermatologic disease, it is important to think initially of broad categories (Fig. 1.1); this allows for a more complete differential diagnosis and a logical approach.
- Key elements of any clinical description include distribution pattern (Table 1.1; Figs 1.2 and 1.3), type of primary lesion and its topography (Table 1.2; Fig. 1.4), secondary features (Table 1.3), and its consistency via palpation (Tables 1.4 and 1.5).
- If atrophy is present, it should be categorized as epidermal, dermal, and/or subcutaneous (Fig. 1.5).
- Color is also an important feature (Table 1.6), and this can be influenced by the skin phototype (Appendix) such that an inflammatory

| MAJOR DISTRIBUTION PATTERNS |
|---|
| • Generalized versus localized (see Fig. 1.2) versus solitary<br>• Unilateral versus bilateral<br>• If bilateral, symmetric or asymmetric pattern<br>• Random versus linear (see Fig. 1.3) or grouped (e.g. herpetiform, clustered)<br>• Special patterns – acral sites (nose, ears, distal extremities); seborrheic region (scalp, face, upper trunk); sun-exposed versus sun-protected sites; along cleavage lines; areas of occlusion; areas of pressure; areas in contact with allergens or irritants |

**Table 1.1 Major distribution patterns.** Occasionally, the pattern represents a locus minoris resistentiae.

**CLASSIFICATION SCHEME FOR DERMATOLOGIC DISORDERS**

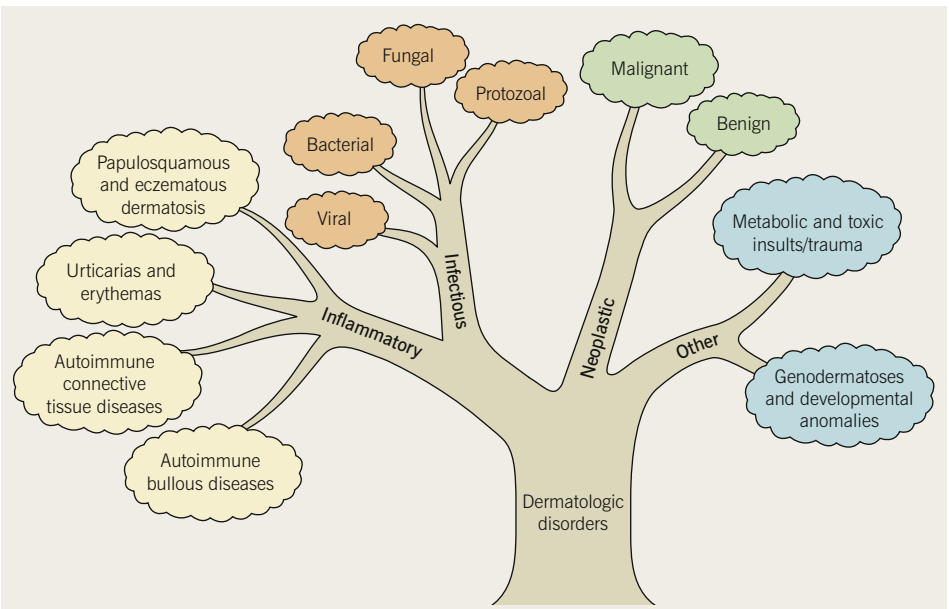


**Fig. 1.1 Classification scheme for dermatologic disorders.** This scheme is analogous to the structure of a tree with multiple branch points terminating in leaves.



A L G r a w a n y

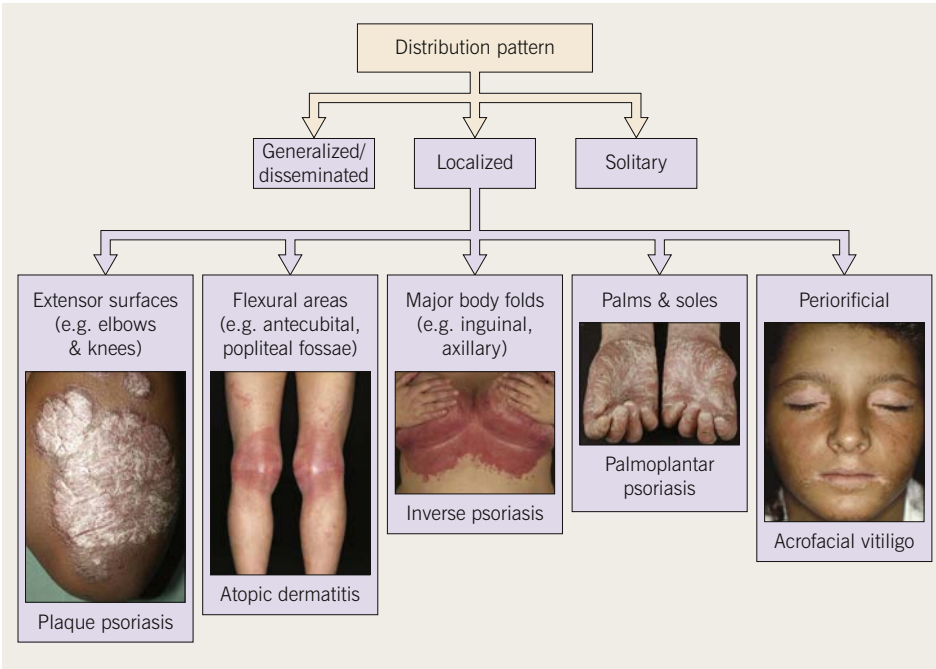


**Fig. 1.2 Examples of localized distribution patterns.** Additional patterns are outlined in Table 1.1. Generalized lesions are seen in morbilliform drug eruptions and viral exanthems. *Photographs, courtesy, Peter C. M. van de Kerkhof, MD, Thomas Bieber, MD, and Julie V. Schaffer, MD.*

lesion that appears pink in a patient with skin phototype I may appear red-brown to violet in a patient with skin phototype IV.

- The acuteness versus chronicity of the eruption provides additional information and with experience can often be determined without a history; Table 1.7 outlines major causes of acute eruptions in otherwise healthy individuals.
- Given the relative ease of obtaining skin biopsies, clinicopathologic correlation is a keystone of dermatologic diagnosis; however, it is important to choose the ideal lesion (e.g. in an inflammatory disorder, one that is fresh but well-developed), as well as the most appropriate type of biopsy (Fig. 1.6).
- For inflammatory disorders, there is a classification schema in which they are divided into major histopathologic patterns (Fig. 1.7); several side-by-side comparisons of clinical presentations with histopathologic findings illustrate the concept of clinicopathologic correlation (Figs 1.8–1.15).
- In an analogy to dermatopathology, the clinician often looks at the patient at "medium-power" (i.e. 20×), but it is also important to analyze the patient at low-power (4×), thus appreciating the overall pattern, as well as high-power (100×); the latter is aided by the use of dermoscopy (Figs 1.16 and 1.17). Additional dermoscopic images are in Chapters 88, 92, and 93.
- With experience, prompt recognition of pertinent positive and negative clinical features often leads to a narrower differential diagnosis rather rapidly, almost akin to a gestalt. However, when initially learning dermatology, it is helpful to separately address each of the key elements (see above).

For further information see Ch. 0 from *Dermatology, Fourth Edition*.

**For additional online figures and tables visit www.expertconsult.com**

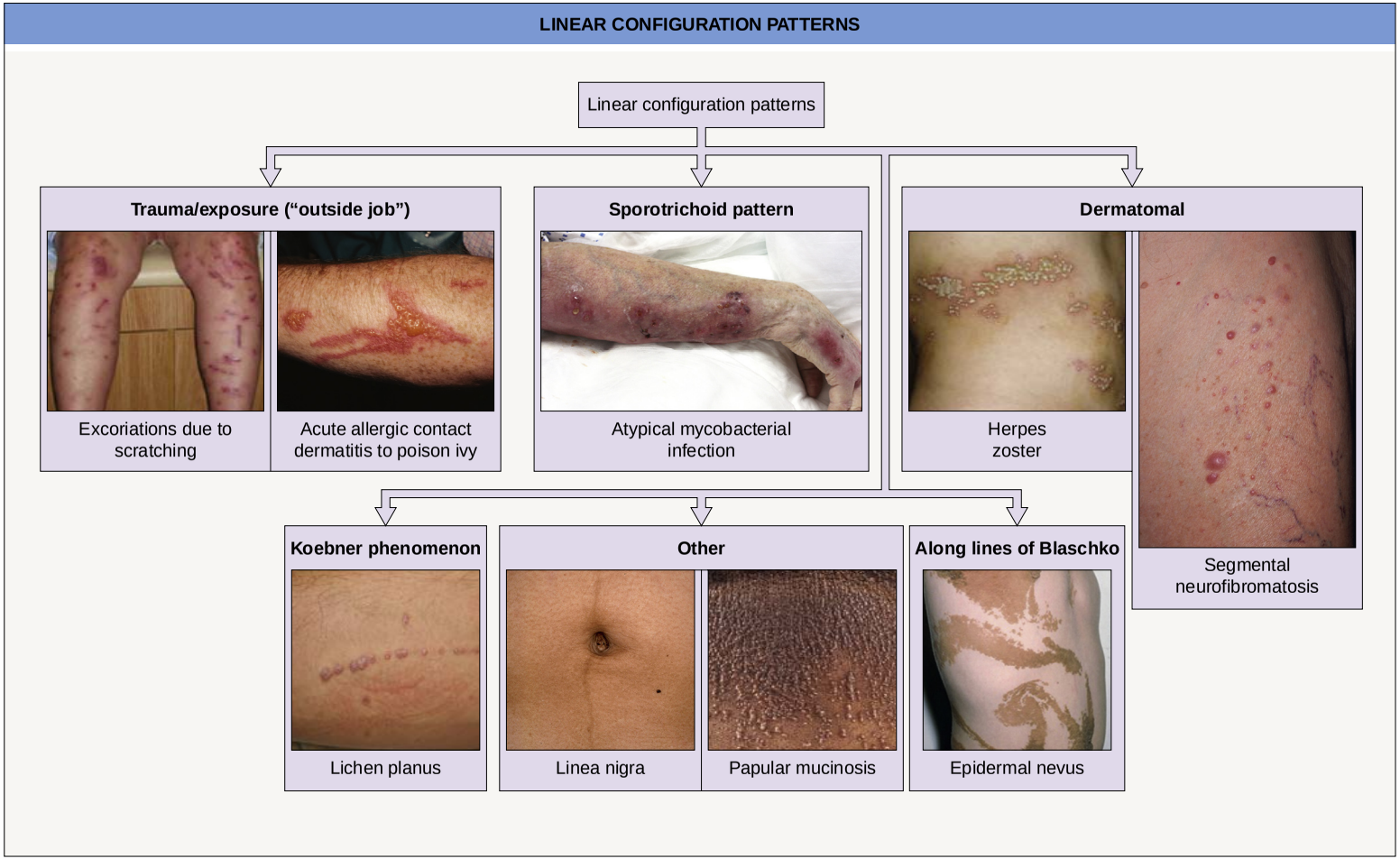


**Fig. 1.3 Linear configuration patterns.** *Photographs, courtesy, Kathryn Schwarzenberger, MD, Jean L. Bolognia, MD, Edward Cowen, MD, Whitney High, MD, Joyce Rico, MD, Louis A. Fragola, Jr., MD, and YDRSC.*

Downloaded for Novin lib (novinlibrary@yahoo.com) at United Arab Emirates University from ClinicalKey.com by Elsevier on March 26, 2022. For personal use only. No other uses without permission. Copyright ©2022. Elsevier Inc. All rights reserved.

**PRIMARY LESIONS – MORPHOLOGICAL TERMS**

| | Term | Clinical features | | Clinical example | Clinical disorders |
|---|---|---|---|---|---|
| Related by size ↕ | **Macule** | • Flat, circumscribed, non-palpable<br>• <1 cm in diameter<br>• Often hypo- or hyperpigmented<br>• Also other colors (e.g. pink, red, violet)<br>• It can be round, oval, or irregular in shape<br>• May be sharply marginated or blend into the surrounding skin | 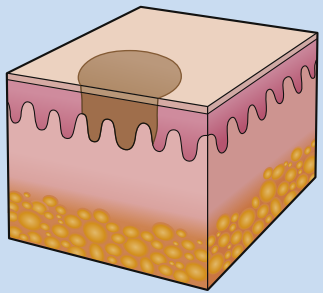 | 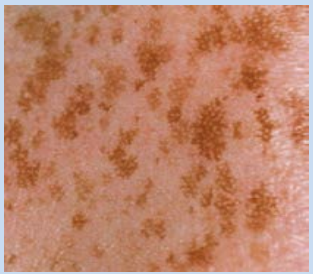<br>Solar lentigines | • Ephelid (freckle)<br>• Lentigo<br>• Idiopathic guttate hypomelanosis<br>• Petechiae<br>• Flat component of viral exanthems<br>• Junctional melanocytic nevus |
| | **Patch** | • Flat, circumscribed, non-palpable<br>• >1 cm in diameter<br>• Often hypo- or hyperpigmented<br>• Also other colors (e.g. blue, violet) | 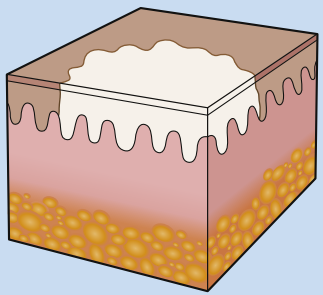 | <br>Vitiligo | • Vitiligo<br>• Melasma<br>• Dermal melanocytosis (Mongolian spot)<br>• Café-au-lait macule<br>• Nevus depigmentosus<br>• Solar purpura<br>• Port-wine stain (early) |
| Related by size ↕ | **Papule** | • Elevated, circumscribed<br>• <1 cm in diameter<br>• Elevation due to increased thickness of the epidermis and/or cells or deposits within the dermis<br>• May have secondary changes (e.g. scale, crust, erosion)<br>• Need to distinguish from vesicle or pustule | 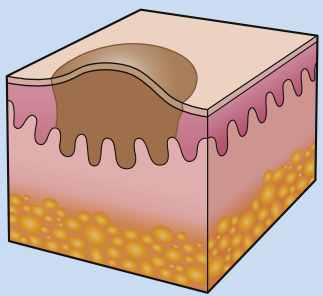 | <br>Seborrheic keratosis | • Seborrheic keratosis<br>• Cherry angioma<br>• Compound or intradermal melanocytic nevus<br>• Verruca or molluscum contagiosum<br>• Acrochordon<br>• Milium, fibrous papule (angiofibroma) |

March 26, 2022. For personal use only. No other uses without permission. Copyright ©2022. Elsevier Inc. All rights reserved.

| | | | | | |
|---|---|---|---|---|---|
| Related by size | | • When viewed in profile, it may be flat-topped, dome-shaped, filiform, pedunculated, smooth, verrucous, or umbilicated (see Fig. 1.4) | 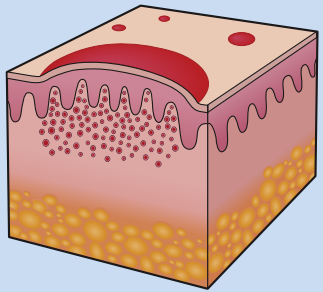 | 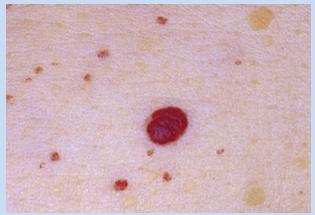 Cherry angioma | • Sebaceous hyperplasia<br>• Small vessel vasculitis |
| | **Plaque** | • Elevated, circumscribed<br>• >1 cm in diameter<br>• Elevation due to increased thickness of the epidermis and/or cells or deposits within the dermis<br>• May have secondary changes (e.g. scale, crust, erosion)<br>• May be a distinct lesion or formed by a confluence of papules | 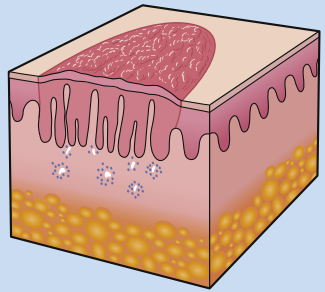 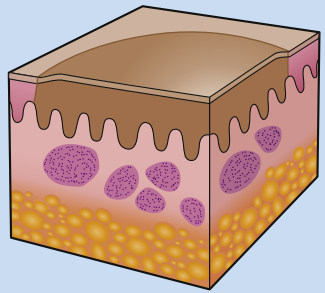 Sarcoidosis | 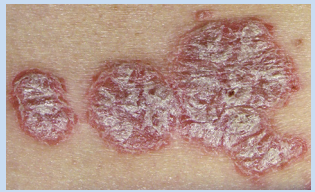 Psoriasis  Sarcoidosis | *Primarily epidermal*<br>• Psoriasis<br>• Lichen simplex chronicus<br>• Nummular dermatitis<br>*Dermal*<br>• Granuloma annulare<br>• Sarcoidosis<br>• Hypertrophic scar, keloid<br>• Morphea<br>*Both epidermal and dermal*<br>• Discoid lesions of lupus erythematosus |

**Table 1.2 Primary lesions – morphological terms.** *Continued*

Downloaded for Novin lib (novinlibrary@yahoo.com) at United Arab Emirates University from ClinicalKey.com by Elsevier on March 26, 2022. For personal use only. No other uses without permission. Copyright ©2022. Elsevier Inc. All rights reserved.

| PRIMARY LESIONS – MORPHOLOGICAL TERMS | | | | | |
|---|---|---|---|---|---|
| | **Term** | **Clinical features** | | **Clinical example** | **Clinical disorders** |
| | **Nodule** | • Elevated, circumscribed<br>• Larger volume than papule, often >1.5 cm in diameter<br>• Located primarily in the dermis and/or subcutis<br>• Greatest mass may be beneath the skin surface<br>• Can be compressible, soft, rubbery, or firm to palpation | 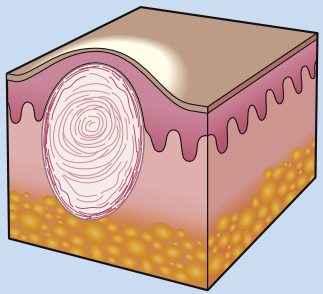 | <br>Epidermoid inclusion cysts | • Epidermoid inclusion cyst<br>• Pilar cyst<br>• Lipoma<br>• Neurofibroma<br>• Nodular melanoma<br>• Metastases<br>• Rheumatoid nodule<br>• Panniculitis, e.g. erythema nodosum |
| ⟵ Related by size ⟶ | **Vesicle** | • Elevated, circumscribed<br>• <1 cm in diameter<br>• Fluid-containing, usually clear or serous but may be hemorrhagic<br>• May become pustular, umbilicated, or an erosion | 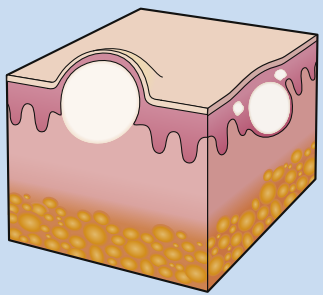 | <br>Herpes simplex | • Herpes simplex<br>• Varicella or herpes zoster<br>• Dyshidrotic eczema<br>• Acute allergic contact dermatitis<br>• Dermatitis herpetiformis |

| ⟷ Related by size ⟷ | | | | | |
|---|---|---|---|---|---|
| | **Bulla** | • Elevated, circumscribed<br>• >1 cm in diameter<br>• Fluid-containing, usually clear or serous but may be hemorrhagic<br>• May become an erosion or ulceration | 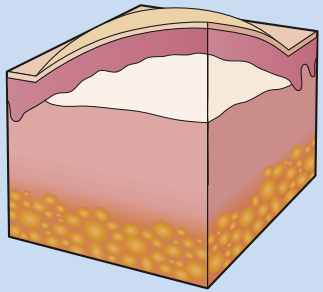 | <br>Bullous fixed drug eruption | • Friction blister<br>• Thermal burn (second-degree)<br>• Bullous pemphigoid<br>• Linear IgA bullous dermatosis<br>• Bullous fixed drug eruption<br>• Coma bullae<br>• Edema bullae |
| | **Pustule** | • Elevated, circumscribed<br>• Usually <1 cm in diameter<br>• Contains purulent material (neutrophils >> eosinophils)<br>• May be infectious or sterile | 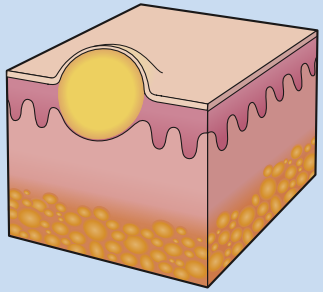 | 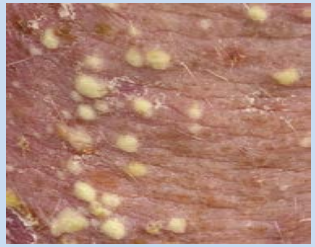<br>Folliculitis | *Follicularly centered*<br>• Folliculitis<br>• Acne vulgaris<br>• Rosacea<br>*Non-follicularly centered*<br>• Pustular psoriasis<br>• Acute generalized exanthematous pustulosis<br>• Subcorneal pustular dermatosis |
| | **Wheal** | • Transient elevation of the skin due to dermal edema | 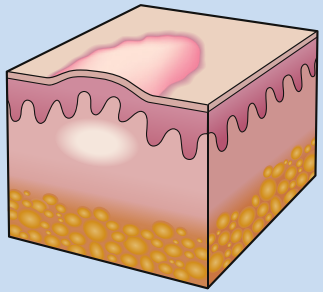 | 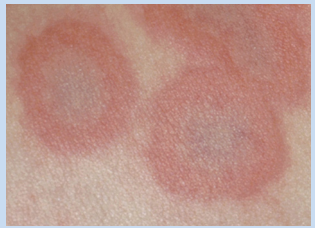<br>Acute annular urticaria | • Urticaria<br>• Urticaria multiforme |

**Table 1.2** *Continued* **Primary lesions – morphological terms.** *Photographs, courtesy, Jean L. Bolognia, MD, Lorenzo Cerroni, MD, Edward Cowen, MD, Louis A. Fragola, Jr., MD, Whitney High, MD, Joyce Rico, MD, and Kalman Watsky, MD.*

ALGrawany

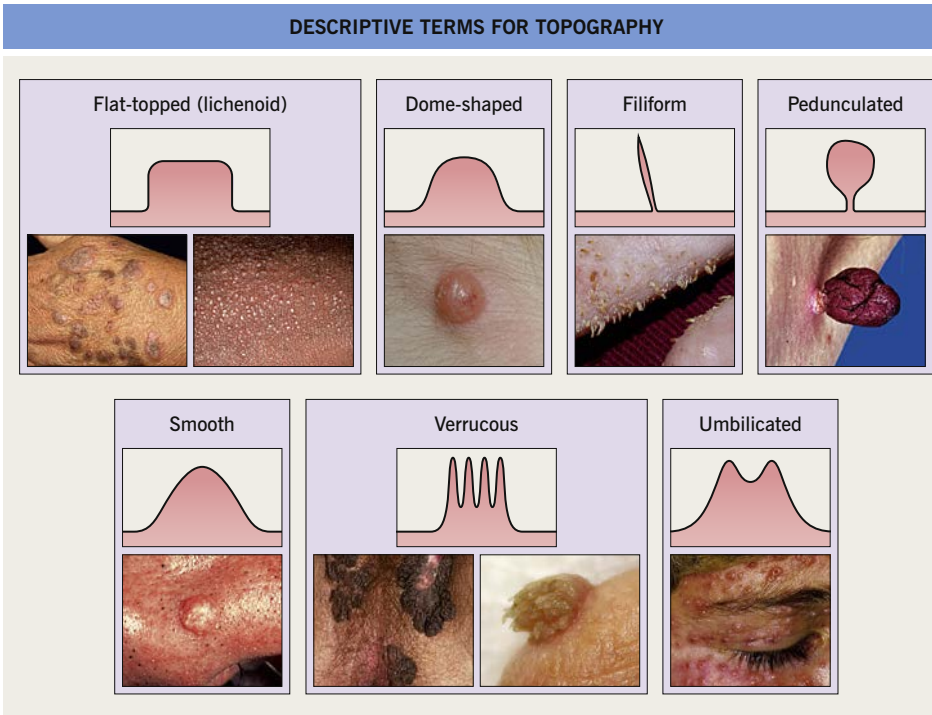


**Fig. 1.4 Descriptive terms for topography.** *Photographs, courtesy, Jennifer Choi, MD, Hideko Kamino, MD, Reinhard Kirnbauer, MD, Petra Lenz, MD, Frank Samarin, MD, Julie V. Schaffer, MD, Judit Stenn, MD, and YDRSC.*

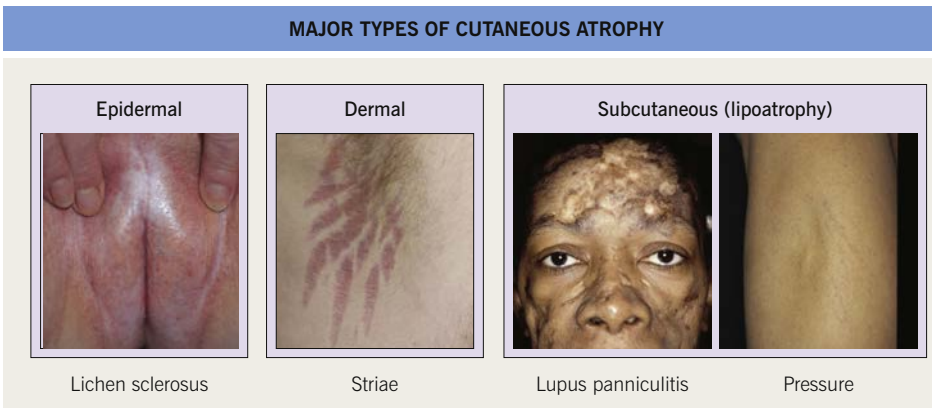


**Fig. 1.5 Major types of cutaneous atrophy.** *Photographs, courtesy, Susan M. Cooper, MD, Fenella Wojnarowska, MD, Jean L. Bolognia, MD, and YDRSC.*

| SECONDARY FEATURES – MORPHOLOGICAL TERMS | | | |
|---|---|---|---|
| **Feature** | **Description** | | **Disorders** |
| **Crust** | • Dried serum (serous), blood (hemorrhagic), or pus on the surface<br>• May include bacteria (usually *Staphylococcus*) | <br>Secondarily infected hand dermatitis | • Eczema/dermatitis (multiple types)<br>• Impetigo<br>• Later phase of herpes simplex, varicella or zoster<br>• Erythema multiforme |
| **Scale** | • Hyperkeratosis<br>• Accumulation of stratum corneum due to increased proliferation and/or delayed desquamation<br>• Represents a primary rather than a secondary feature in ichthyoses | <br>Psoriasis | • Psoriasis (micaceous [silvery] scale)<br>• Tinea (leading scale)<br>• Erythema annulare centrifugum (trailing scale)<br>• Actinic keratoses (gritty)<br>• Pityriasis rosea (peripheral collarette and/or central scale)<br>• Seborrheic (greasy)<br>• Tinea versicolor (powdery [furfuraceous])<br>• Lamellar ichthyosis (plate-like) |
| **Fissure** | • Linear cleft in skin<br>• Often painful<br>• Results from marked drying, skin thickening, and loss of elasticity | <br>Hand dermatitis | • Angular cheilitis<br>• Hand dermatitis<br>• Sebopsoriasis (intergluteal fold)<br>• Irritant cheilitis |
| **Excoriation** | • Exogenous injury to all or part of the epidermis (epithelium)<br>• Usually due to scratching | <br>Neurotic excoriations | • A secondary feature of pruritic conditions, including arthropod bites and atopic dermatitis<br>• Neurotic excoriations<br>• Acne excoriée |

**Table 1.3 Secondary features – morphological terms.** *Continued*

ALGrawany

Downloaded for Novin lib (novinlibrary@yahoo.com) at United Arab Emirates University from ClinicalKey.com by Elsevier on March 26, 2022. For personal use only. No other uses without permission. Copyright ©2022. Elsevier Inc. All rights reserved.

| SECONDARY FEATURES – MORPHOLOGICAL TERMS | | | |
|---|---|---|---|
| **Feature** | **Description** | | **Disorders** |
| **Lichenification** | • Thickening (acanthosis) of the epidermis, and accentuation of natural skin lines |  Lichen simplex chronicus | • Lichen simplex chronicus, isolated or superimposed on a pruritic condition, e.g. atopic dermatitis |
| **Erosion** | • Partial, or sometimes complete, loss of the epidermis (epithelium)<br>• A moist, oozing, and/or crusted lesion 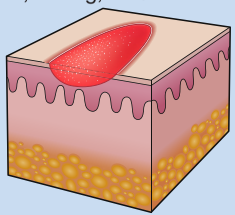 |  Pemphigus foliaceus | • Impetigo<br>• Friction<br>• Trauma<br>• Pemphigus, vulgaris and foliaceus<br>• Staphylococcal scalded skin syndrome |

| | | | |
|---|---|---|---|
| **Ulceration** | • A deeper defect (compared to an erosion), with loss of at least the entire epidermis plus superficial dermis<br>• May have loss of the entire dermis or even subcutis<br>• Size, shape, and depth of the ulcer should be noted in addition to characteristics of the border, base, and surrounding skin<br>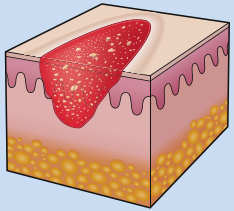 | <br>Ulcer due to small vessel vasculitis | • Venous (stasis) ulcer<br>• Neuropathic ulcer<br>• Arterial ulcer<br>• Decubitus ulcer<br>• Aphthous ulcer<br>• Ecthyma gangrenosum<br>• Ecthyma<br>• Pyoderma gangrenosum |
| **Atrophy** | • Epidermal atrophy – thinning of the epidermis, leading to wrinkling and a shiny appearance<br>• Dermal atrophy – loss of dermal collagen and/or elastin, leading to a depression (see Table 1.4) | <br>Striae secondary to potent corticosteroids | • Lichen sclerosus<br>• Poikiloderma<br>• Striae<br>• Anetoderma<br>• Focal dermal hyoplasia (Goltz syndrome) |
| **Scar** | • Increased thickness, usually of the dermis, due to enhanced production of collagen by fibroblasts<br>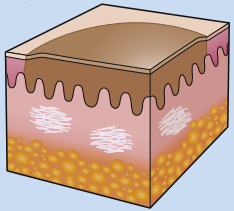 | <br>Acne scarring | • Trauma<br>• Acne<br>• Surgical excision<br>• Thermal burn |

**Table 1.3** *Continued* **Secondary features – morphological terms.** *Photographs, courtesy, Louis A. Fragola, Jr., MD, Jeffrey C. Callen, MD, Julie V. Schaffer, MD, and Whitney High, MD.*

| USE OF PALPATION IN ANALYZING CUTANEOUS LESIONS | | |
|---|---|---|
| **Types of lesion** | | **Examples** |
| Macules and patches (non-palpable) | 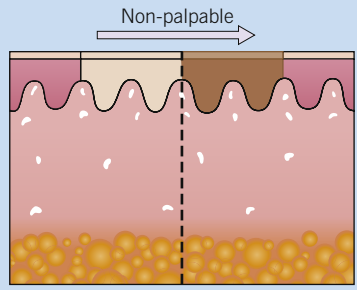 | • Solar lentigines<br>• Idiopathic guttate hypomelanosis<br>• Melasma<br>• Vitiligo<br>• Petechiae<br>• Dermal melanocytosis |
| Papules and plaques (palpable) | 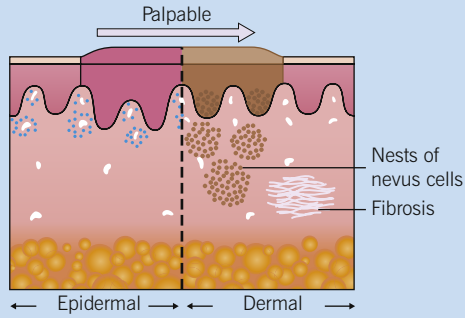 | • Psoriasis<br>• Lichen planus<br>• Dermatitis<br>• Intradermal or compound melanocytic nevus<br>• Hypertrophic scar, keloid<br>• Morphea |
| Atrophy – dermal and subcutaneous | 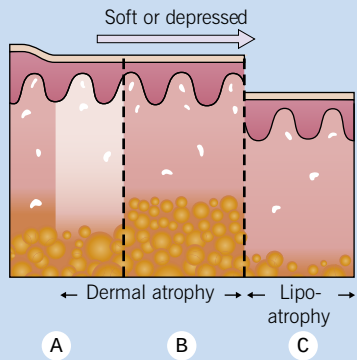 | **A** • Anetoderma<br>**B** • Focal dermal hypoplasia (Goltz syndrome)<br>**C** • Lipoatrophy due to corticosteroid injections<br>• Lipoatrophy due to panniculitis |

**Table 1.4 Use of palpation in analyzing cutaneous lesions.** *Courtesy, Whitney High, MD.*

| PALPATION OF CUTANEOUS LESIONS |
|---|
| • Soft (e.g. intradermal nevus) versus firm (e.g. dermatofibroma) versus hard (e.g. calcinosis cutis, osteoma cutis) |
| • Compressible (e.g. venous lake) versus noncompressible (e.g. fibrous papule) |
| • Tender (e.g. inflamed epidermoid inclusion cyst, angiolipoma, leiomyoma) versus nontender |
| • Blanchable (e.g. erythema due to vasodilation) versus nonblanchable (e.g. purpura) – aided by diascopy |
| • Rough versus smooth |
| • Mobile versus fixed to underlying structures |
| • Dermal versus subcutaneous |
| • Temperature – normal versus elevated |
| • Other, e.g. thrill, pulsatile |

**Table 1.5 Palpation of cutaneous lesions.**

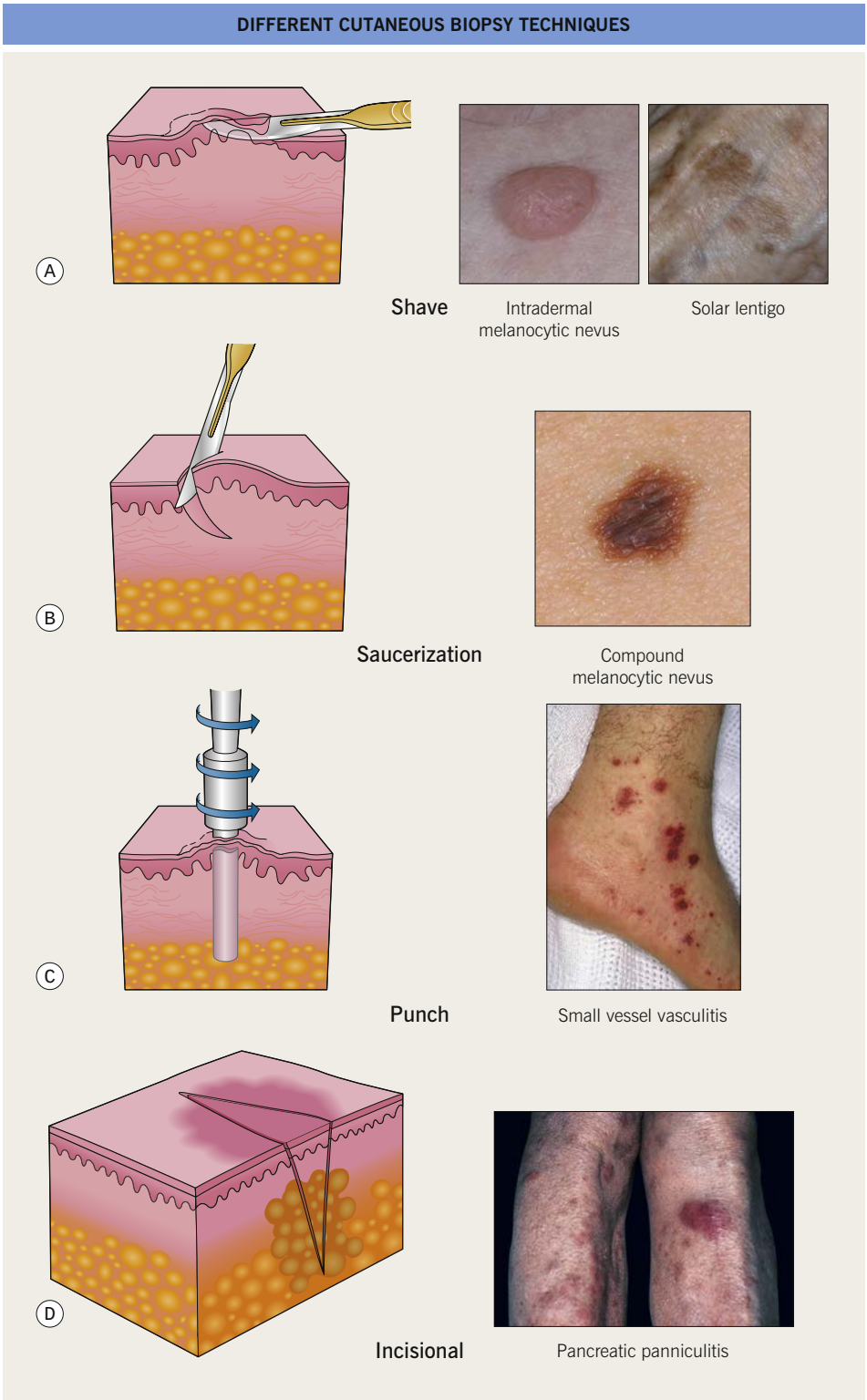


**Fig. 1.6 Different cutaneous biopsy techniques.** *See next page for figure legend.*

**Fig. 1.6 Different cutaneous biopsy techniques.** **A** Superficial shave biopsy can be performed to remove the elevated portion of an intradermal nevus or to distinguish a solar lentigo (pictured here) from lentigo maligna. **B** Deep shave biopsy (saucerization); performed to remove a compound melanocytic nevus or atypical melanocytic nevus. **C** Punch biopsy; performed to examine the dermis (as well as the epidermis) and the preferred technique for diagnosing cutaneous small vessel vasculitis. **D** Incisional biopsy; recommended for determining the specific type of panniculitis. *Courtesy, Suzanne Olbricht, MD, Raymond Barnhill, MD, Kenneth Greer, MD, Frank Samarin, MD, and YDRSC.*

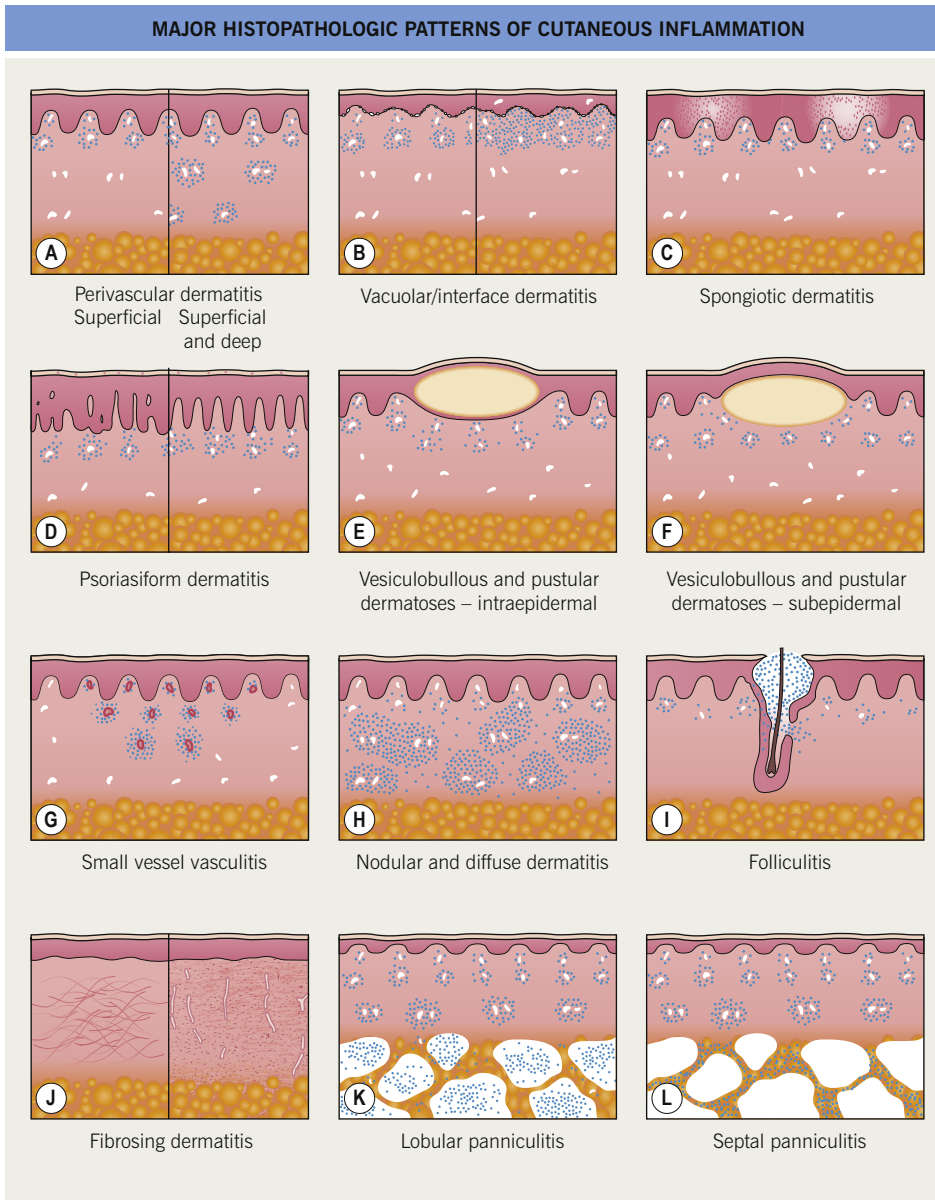


**Fig. 1.7 Major histopathologic patterns of cutaneous inflammation (based on Ackerman's classification).** Basic patterns of inflammation result primarily from the distribution of the inflammatory cell infiltrate within the dermis and/or the subcutaneous fat (e.g. nodular, perivascular). It also reflects the character of the inflammatory process itself (e.g. pustular), the presence of injury to blood vessels (e.g. vasculitis), involvement of hair follicles (e.g. folliculitis), abnormal fibrous dermal and/or subcutaneous tissue, and formation of vesicles and bullae. *Adapted from Ackerman AB. Histologic Diagnosis of Inflammatory Skin Diseases: A Method by Pattern Analysis. Philadelphia: Lea & Febiger, 1978.*

| COLORS OF CUTANEOUS LESIONS | |
|---|---|
| **Color** | **Clinical examples** |
| White | Vitiligo, idiopathic guttate hypomelanosis, calcinosis cutis |
| Tan* | Postinflammatory hypopigmentation, nevus depigmentosus |
| Yellow | Sebaceous hyperplasia, carotenoderma, xanthoma |
| Pink to red-brown (range of erythema influenced by skin phototype) | Psoriasis, dermatitis, morbilliform drug eruption, viral exanthem |
| Orange-red (salmon) | Pityriasis rubra pilaris |
| Green | *Pseudomonas* infection or colonization (e.g. of onycholysis) |
| Blue | Ecchymosis, venous lake, dermal melanocytosis, blue nevus, cyanosis |
| Gray | Postinflammatory hyperpigmentation (dermal), erythema dyschromicum perstans, argyria |
| Purple/violaceous | Solar purpura, small vessel vasculitis, lichen planus, lymphoma cutis |
| Brown | Seborrheic keratosis, compound melanocytic nevus, melasma, postinflammatory hyperpigmentation (epidermal) |
| Black | Infarct with necrosis, melanoma |

**Not to be confused with increase in pigmentation that follows exposure to ultraviolet irradiation.*

**Table 1.6 Colors of cutaneous lesions.**

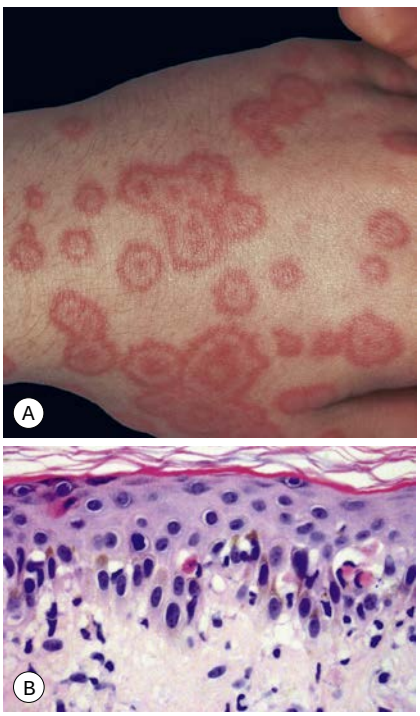


**Fig. 1.8 Interface dermatitis, vacuolar type. A** Erythema multiforme – edematous papules with central dusky erythema surrounded by an annulus of edema and then a peripheral rim of erythema, leading to a target-like appearance. **B** Vacuolar alteration along the dermal–epidermal junction in association with exocytosis of keratinocytes. *Courtesy, Carlo F. Tomasini, MD.*




**Fig. 1.9 Spongiotic dermatitis. A** Acute allergic contact dermatitis to *Toxicodendron radicans* (poison ivy). The central black discoloration is due to the plant's resin. **B** Intercellular edema (spongiosis) and vesicle formation within the epidermis. Lymphocytes are also seen in both the epidermis and dermis. *A, Courtesy, Kalman Watsky, MD; B, Courtesy, James Patterson, MD.*




**Fig. 1.10 Psoriasiform pattern. A** Psoriasis vulgaris – pink plaques with silvery scale on the shin; this clinical description utilizes the key elements of color, primary lesion, secondary changes, and distribution pattern (extensor surfaces) in order to arrive at the diagnosis. **B** Regular epidermal hyperplasia and elongated dermal papillae with thin suprapapillary plates and confluent parakeratosis. The parakeratosis represents the histopathologic correlate of the visible scale. *A, Courtesy, Julie V. Schaffer, MD; B, Courtesy, Lorenzo Cerroni, MD.*

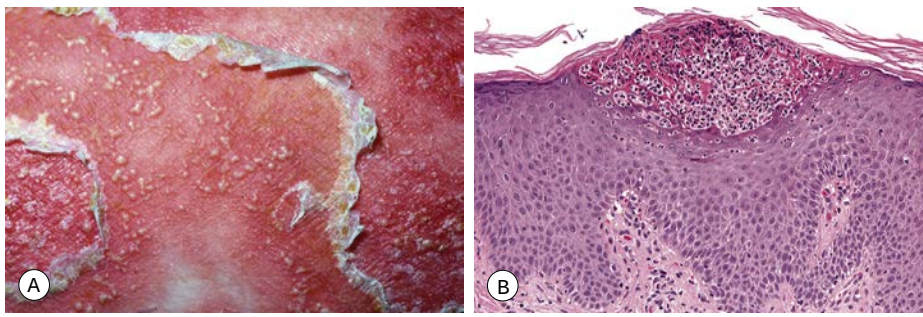


**Fig. 1.11 Intraepidermal pustular dermatosis. A** Pustular psoriasis. **B** Collection of neutrophils beneath the stratum corneum (subcorneal pustule). Scattered neutrophils are in the upper malpighian layer. *A, Courtesy, Kenneth Greer, MD; B, Courtesy, Lorenzo Cerroni, MD.*

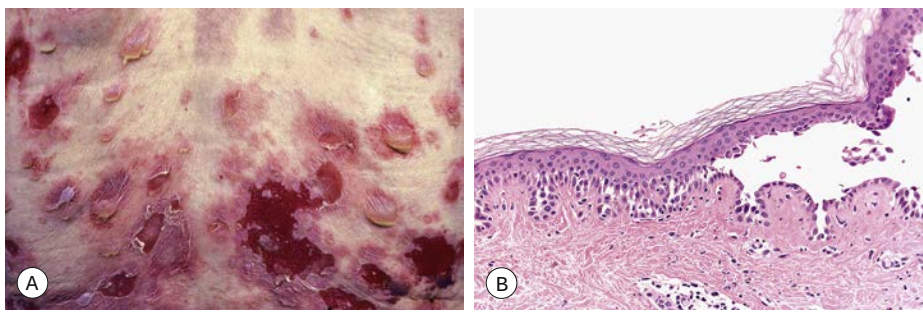


**Fig. 1.12 Intraepidermal vesiculobullous dermatosis, acantholytic type. A** Pemphigus vulgaris with flaccid bullae and erosions. Note the dependent location of the pustular contents of bullae. **B** The keratinocytes within the lower epidermis have lost their intercellular attachments and have separated from one another, resulting in an intraepidermal blister. *A, Courtesy, Carlo Francesco Tomasini, MD; B, Courtesy, Lorenzo Cerroni, MD.*

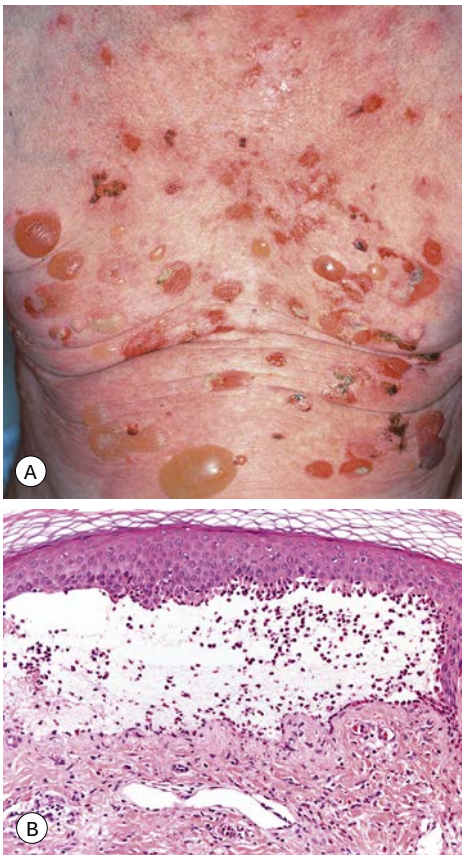


**Fig. 1.13 Subepidermal vesiculobullous dermatosis. A** Bullous pemphigoid with tense bullae. **B** Subepidermal blister with numerous eosinophils within the blister cavity. *A, Courtesy, YDRSC; B, Courtesy, Lorenzo Cerroni, MD.*




**Fig. 1.14 Small vessel vasculitis. A** Inflammatory palpable purpura of the leg. **B** Perivascular and interstitial infiltrate of neutrophils with nuclear dust (leukocytoclasia). Fibrin within the vessel wall and extravasation of erythrocytes is also seen. *A, Courtesy, Carlo F. Tomasini, MD; B, Courtesy, Christine Ko, MD.*

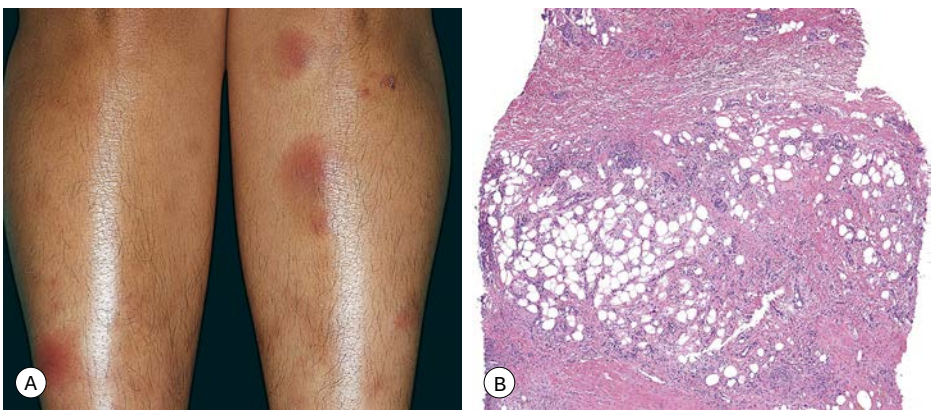


**Fig. 1.15 Septal panniculitis. A** Multiple red-brown nodules of erythema nodosum on the shins, admixed with healing bruise-like areas. **B** Predominantly septal granulomatous infiltrate with formation of characteristic Miescher's granulomas. *A, Courtesy, Kenneth Greer, MD; B, Courtesy, Christine Ko, MD.*

| ACUTE CUTANEOUS ERUPTIONS IN OTHERWISE HEALTHY INDIVIDUALS | |
|---|---|
| **Disorder** | **Characteristic findings** |
| Urticaria (see Ch. 14) | • Pathogenesis involves degranulation of mast cells with release of histamine<br>• Primary lesion: edematous wheal with erythematous flare<br>• Widespread distribution<br>• Very pruritic*<br>• Individual lesions are transient (<24 hours in duration)<br>• May become chronic (>6 weeks) |
| Acute allergic contact dermatitis (see Ch. 12) | • Immune-mediated and requires prior sensitization<br>• Primary lesion: dermatitis, with vesicles, bullae, and weeping when severe<br>• Primarily in sites of exposure; occasionally more widespread due to autosensitization<br>• Pruritus, often marked<br>• Spontaneously resolves over 2–3 weeks if no further exposure to allergen (e.g. poison ivy, nickel) |
| Acute irritant contact dermatitis (see Ch. 12) | • Direct toxic effect<br>• Primary lesion: ranges from erythema to bullae (e.g. chemical burn)<br>• At sites of exposure<br>• Burning sensation<br>• Spontaneously resolves over 2–3 weeks if no further exposure to irritant (e.g. strong acid, strong alkali) |
| Exanthematous (morbilliform) drug eruptions (see Ch. 17) | • Immune-mediated and requires prior sensitization<br>• Pink to red-brown, blanching macules and papules; may become purpuric on distal lower extremities<br>• Widespread distribution<br>• May be pruritic<br>• Spontaneously resolves over 7–10 days if no further exposure to inciting drug |
| Pityriasis rosea (see Ch. 7) | • May follow a viral illness<br>• Primary lesion: oval-shaped, pink to salmon-colored papule or plaque with fine white scale centrally and peripheral collarette; occasionally vesicular<br>• Initial lesion is often largest (herald patch)<br>• Favors trunk and proximal extremities; may have inverse pattern (axillae and groin); long axis of lesions parallel to skin cleavage lines (see Fig. 7.7)<br>• Spontaneously resolves over 6–10 weeks; exclude secondary syphilis |
| Viral exanthems (see Ch. 68) | • Due to a broad range of viruses, including rubeola, rubella, enteroviruses, parvovirus, adenovirus (see Fig. 68.1)<br>• Often associated with fever, malaise, arthralgias, myalgias, nausea, upper respiratory symptoms<br>• Primary lesions vary from blanching pink macules and papules to vesicles or petechiae<br>• Distribution varies from acral to widespread; may have an enanthem<br>• Spontaneously resolves over 3–10 days |

**May have burning rather than pruritus with urticarial vasculitis, and individual lesions of urticarial vasculitis can last longer than 24 hours.*

**Table 1.7 Acute cutaneous eruptions in otherwise healthy individuals.**

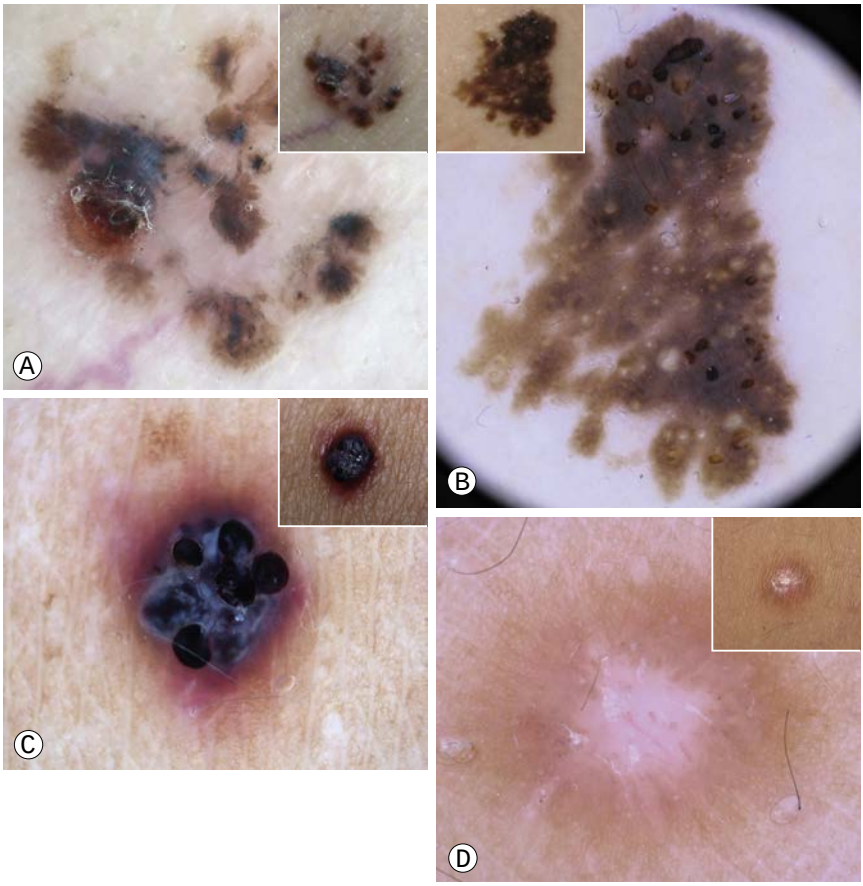


**Fig. 1.16 Use of dermoscopy to aid in the diagnosis of four common pigmented (non-melanocytic) cutaneous lesions. A** Pigmented basal cell carcinoma with leaf-like areas (islands of blue-gray color) at the periphery and a small erosion of reddish color at the left side of the lesion. **B** Seborrheic keratosis with typical milia-like cysts (white shining globules) and comedo-like openings (black targetoid globules). **C** Angiokeratoma with red-black lacunas clearly visible as well-demarcated roundish structures. **D** A dermatofibroma with characteristic central white patch and peripheral delicate pseudo-network. Dermoscopic features of melanocytic nevi and melanoma are reviewed in Chapters 92 and 93. *Courtesy, Giuseppe Argenziano, MD, and Iris Zalaudek, MD.*

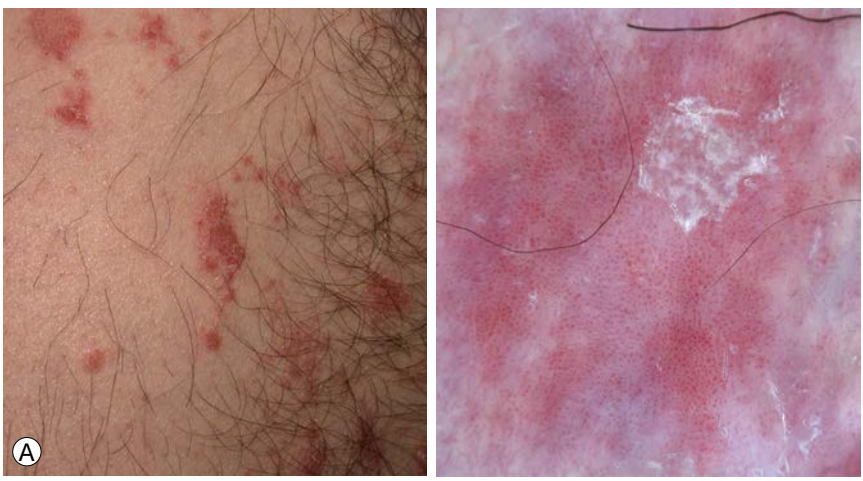


**Fig. 1.17 Use of dermoscopy to aid in the diagnosis of inflammatory disorders. A** By dermoscopy, classic psoriasis plaques exhibit regular dotted vessels. *Continued*




**Fig. 1.17** *Continued* **B** The dermoscopic pattern of lichen planus is definitely different from the previous one. Here, dotted vessels are seen at the border of typical whitish lines and clods, which closely resemble the Wickham striae found in lichen planus of the oral mucosa. *Courtesy, Giuseppe Argenziano, MD, and Iris Zalaudek, MD.*

| COLOR AS A CLUE TO THE CLINICAL DIAGNOSIS | |
|---|---|
| **Color** | **Examples of diseases with this color** |
| Erythema (pink to red-brown, depending upon the skin phototype)<br><br>Morbilliform (exanthematous) drug eruption | • Dermatitis<br>• Psoriasis<br>• Morbilliform drug eruption<br>• Viral exanthems<br>• Any insult that causes vasodilation |
| Black<br><br>Necrosis secondary to vasculopathy from levamisole-contaminated cocaine | • Necrosis of the skin due to:<br>– Vasculitis (granulomatosis with polyangiitis)<br>– Thrombosis (e.g. DIC, monoclonal cryoglobulinemia)<br>– Emboli (e.g. ecthyma gangrenosum)<br>– Vasospasm (e.g. severe Raynaud phenomenon)<br>– Vascular compromise (e.g. atherosclerosis, calciphylaxis)<br>• Eschar (e.g. anthrax)<br>• Cutaneous melanoma<br>• Traumatic tattoos (e.g. asphalt) |
| Blue (ceruloderma)<br><br>Dermal melanocytosis | • Dermal melanocytosis (e.g. Mongolian spot, nevus of Ota)<br>• Dermal melanocytomas (e.g. blue nevi)<br>• Cyanosis<br>• Ecchymoses<br>• Venous congestion (e.g. venous malformations)<br>• Drugs/deposits (e.g. minocycline, traumatic tattoos) |
| Brown<br><br>Melasma | • Pigmented lesions<br>– Lentigines<br>– Seborrheic keratoses<br>– Junctional, compound and congenital melanocytic nevi<br>– Café-au-lait macules<br>– Dermatofibromas<br>– Melanoma<br>– Pigmented AKs, Bowen disease<br>• Postinflammatory hyperpigmentation – epidermal (see Ch. 55)<br>• Melasma<br>• Phytophotodermatitis<br>• Drug-induced hyperpigmentation (e.g. cyclophosphamide)<br>• Metabolic (e.g. Addison disease, hemochromatosis) |

**eTable 1.1 Color as a clue to the clinical diagnosis.** DIC, disseminated intravascular coagulation.
*Continued*

| COLOR AS A CLUE TO THE CLINICAL DIAGNOSIS | |
|---|---|
| **Color** | **Examples of diseases with this color** |
| Gray<br><br>Argyria | • Postinflammatory hyperpigmentation – dermal (e.g. erythema dyschromicum perstans; see Ch. 55)<br>• Drugs/deposits (e.g. argyria, chrysiasis)<br>• Combined melanocytic nevus<br>• Traumatic tattoos<br>• See Blue (above) |
| Purple (violaceous)<br>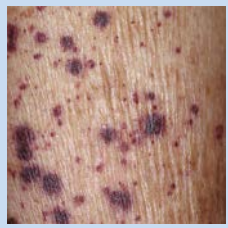<br>Palpable purpura of cutaneous small vessel vasculitis | • Purpura, non-palpable (e.g. solar purpura)<br>• Purpura, palpable (e.g. small vessel vasculitis)<br>• Vascular neoplasms (e.g. angiokeratoma, angiosarcoma)<br>• Lichen planus<br>• Lymphoma cutis<br>• Pyoderma gangrenosum – border<br>• Morphea – border (lilac) |
| White<br><br>Calcinosis cutis (systemic sclerosis) | • Absence of melanocytes or melanin production (e.g. vitiligo, piebaldism, OCA1A)<br>• Scarring (e.g. scarring in discoid lupus erythematosus)<br>• Vasospasm (e.g. Raynaud phenomenon, nevus anemicus)<br>• Deposits (e.g. calcinosis cutis, gouty tophi)<br>• Macerated stratum corneum – mucosal surfaces (e.g. leukoplakia) |
| Green<br><br>Onycholysis with secondary *Pseudomonas* infection | • Pseudomonas infection<br>• Tattoo<br>• Chloroma<br>• Green hair due to copper deposits |
| Orange-red (salmon)<br><br>Pityriasis rubra pilaris with islands of sparing | • Pityriasis rubra pilaris<br>• Mycosis fungoides (sometimes) |

**eTable 1.1** *Continued* **Color as a clue to the clinical diagnosis.** OCA1A, oculocutaneous albinism type 1A. *Continued*

| COLOR AS A CLUE TO THE CLINICAL DIAGNOSIS | |
|---|---|
| **Color** | **Examples of diseases with this color** |
| Yellow 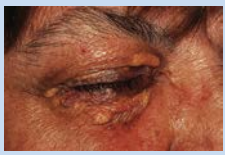 Xanthelasma | • Solar elastosis<br>• Carotenoderma<br>• Xanthomas (e.g. xanthelasma, eruptive)<br>• Xanthogranulomas<br>• Adnexal tumors and hyperplasias with sebaceous differentiation<br>• Necrobiosis lipoidica<br>• Capillaritis (yellow-brown background)<br>• Deposits/drugs (e.g. tophi, quinacrine) |

**eTable 1.1** *Continued* **Color as a clue to the clinical diagnosis.** *Some of the photos courtesy, Jean L. Bolognia, MD, Ronald Rapini, MD, Julie V. Schaffer, MD, Kalman Watsky, MD.*

# Bedside Diagnostics

# 2

- A range of bedside diagnostic procedures are performed to assist in the diagnosis of skin disorders.
- The most commonly performed procedures include microscopic examination of skin scrapings mounted in either potassium hydroxide (KOH) or mineral oil and microscopic examination of hair shafts.

## Potassium Hydroxide (KOH) Preparation of Scale

- Microscopic examination of scale (stratum corneum), obtained via scraping with a metal blade or glass slide and mounted in KOH, is commonly performed to confirm superficial cutaneous fungal infections (Fig. 2.1).
- These fungal infections include tinea (pityriasis) versicolor, tinea corporis/faciei/manuum/cruris/pedis, and cutaneous candidiasis (see Ch. 64).
- Addition of chlorazol black to the KOH can improve detection (see Fig. 2.1B).
- Neither the genus nor the species of a dermatophyte can be determined by the KOH examination of scale.
- For onychomycosis, both nail plates and subungual debris are examined; in addition, nail plates can be fixed in formalin and stained with periodic acid Schiff (PAS) or Gomori methenamine silver stain (see Ch. 64).

## Potassium Hydroxide (KOH) Preparation of Hair Shafts

- Tinea capitis is divided into two major forms: (1) endothrix – conidia occur within the hair shaft; and (2) ectothrix – while the fungus grows inside the hair shaft, conidia form on its surface (Figs 2.2 and 2.3; see Ch. 64).
- For KOH examination and fungal culture, fragile and broken hairs are preferred and can be obtained by scraping with a metal blade or glass slide or, in children, a sterile toothbrush or moistened cotton applicator (Q-tip®).

## Mineral Oil Scraping for Suspected Scabies

- Place 2–3 drops of mineral oil on a glass slide. Dip the metal blade into the oil and then scrape suspicious lesions, e.g. burrows, inflammatory papules. Next place skin scrapings on a glass slide. Several skin lesions should be scraped. Dermoscopy can be performed to better identify burrows and an adult female mite at the end of the burrow prior to scraping (see Ch. 71). Sometimes, KOH is used rather than mineral oil. Firm application of transparent adhesive tape to suspicious lesions followed by rapid removal and transfer to a glass slide is an alternative technique, providing easier transport to a laboratory.
- In addition to adult mites, eggs and feces (scybala) can be seen when scrapings are examined microscopically (Figs 2.4 and 2.5).

## Tzanck Smear

- The advent of direct fluorescent antibody (DFA) and polymerase chain reaction (PCR) assays to detect herpes simplex and varicella–zoster viral infections has led to a decline in the performance of Tzanck smears.
- Nonetheless, it can serve as an easy-to-perform bedside test with results available immediately, including during laboratory "off-hours". A Tzanck smear is most sensitive when an intact vesicle or bulla is present; in immunocompromised hosts, crusted lesions may also be positive.
- The roof is retracted and scraping of the base and angles of the vesicle should be performed in order to obtain virally infected keratinocytes, which are thinly spread onto a glass slide, allowed to dry, and then stained with Giemsa stain (Figs 2.6 and 2.7).

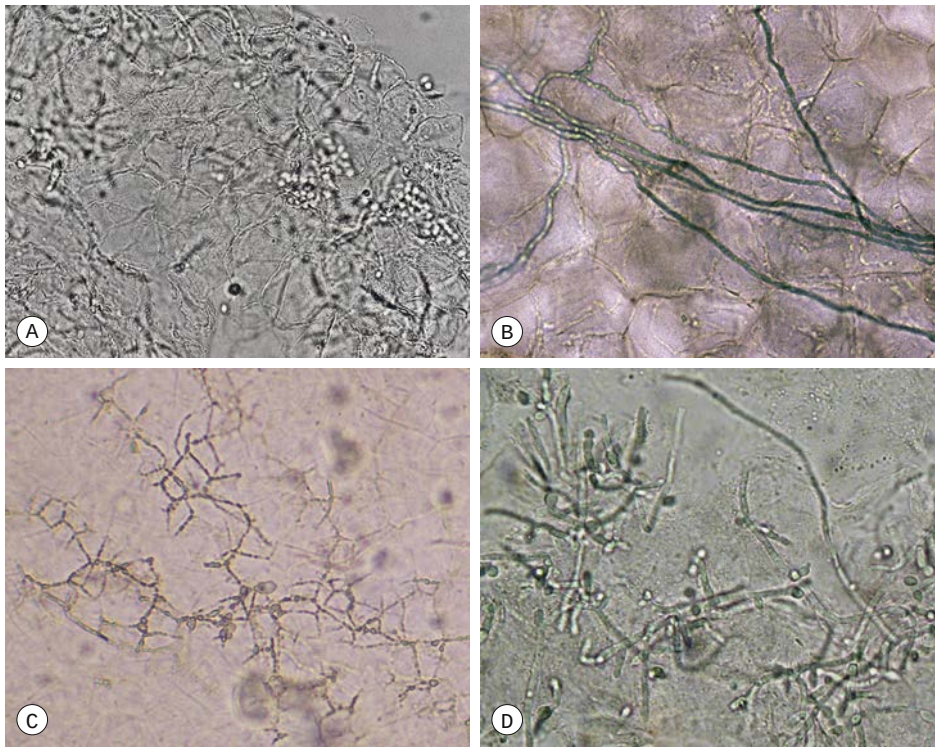


**Fig. 2.1 Microscopic examination of potassium hydroxide (KOH) preparations of scale.** **A** Tinea (pityriasis) versicolor due to *Malassezia* spp. with short mycelial forms and clusters of yeast forms. **B** Tinea corporis due to a dermatophyte with hyphae that cross over more than one cell (squame) and are branching. Chlorazol black has been added to the KOH and the stained hyphae are easier to detect. **C** Branching mosaic pattern that represents the junctures of normal epidermal cells; this is a cause of false-positive KOH exams. **D** Cutaneous candidiasis with yeast forms and pseudohyphae. Pseudohyphae can sometimes be difficult to distinguish from hyphae. *A, Courtesy, Ronald Rapini, MD; B, Courtesy, YDRSC; C, Courtesy, Louis A. Fragola, Jr., MD; D, Courtesy, Frank Samarin, MD.*

## Microscopic Examination of Molluscum Bodies

- In some patients, lesions of molluscum contagiosum may not have a classic appearance – e.g. due to inflammation, previous treatments, large size – and confirmation of the diagnosis without performing a skin biopsy can be helpful.
- The center of the papulonodule, which is often paler in color, is gently curetted to remove a core composed of the viral particles, and the contents are then thinly spread onto a glass slide; saline or KOH can be added prior to placing the coverslip (Fig. 2.8).

## Gram Stain

- Performed when pustular material is available and identifies both Gram-positive and Gram-negative bacteria (Fig. 2.9).
- In addition, fungal organisms (e.g. *Candida*) can be identified.

## Dermal Scrapings and Touch Preps

- When there is suspicion of a septic embolus or a primary infection involving the dermis and/or subcutis (bacterial, fungal, parasitic), then in addition to a sterile skin biopsy (Fig. 2.10), a touch prep or a dermal scraping can be performed. Often, the patient is immunocompromised. If there is pustular drainage, then a Gram stain and KOH preparation are performed first.
- In a touch prep, the base of a skin biopsy which includes dermis ± subcutis is tapped multiple times against a glass slide. After drying for several minutes, the glass slide

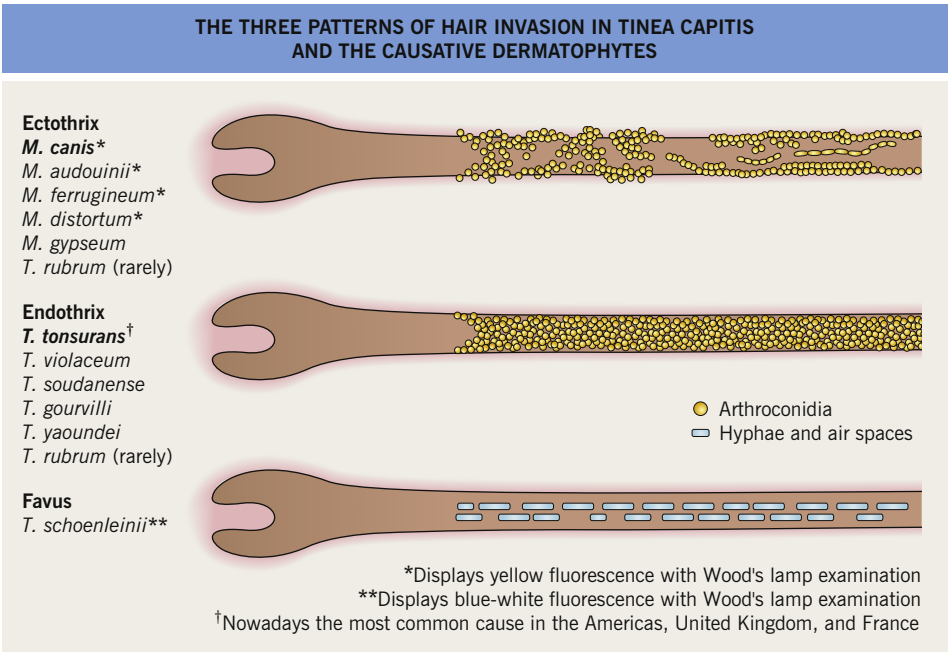


**Fig. 2.2 The three patterns of hair invasion in tinea capitis and the causative dermatophytes.** See Ch. 64 for additional details.



**Fig. 2.3 Microscopic examination of a KOH preparation of a hair shaft with an endothrix dermatophyte infection (tinea capitis).** The most common species for endothrix infections is *Trichophyton tonsurans*. Chlorazol black has been added to the KOH. *Courtesy, YDRSC.*

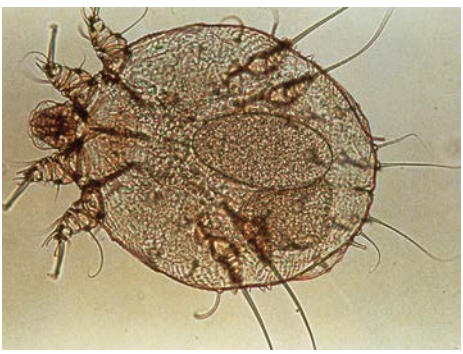

**Fig. 2.4 Microscopic examination of scrapings from a patient with scabies.** Female *Sarcoptes scabiei* var. *hominis* mite with eggs. There is a flattened, oval body with wrinkle-like corrugations and eight legs. *With permission from Taplin D, Meinking TL. Infestations. In: Schachner LA, Hansen RC (Eds.), Pediatric Dermatology, 4th edn. Edinburgh, UK: Mosby, 2011:1141–1180.*

is stained (e.g. Gram stain, Giemsa stain; Fig. 2.11).

- In a dermal scraping, the epidermis (if present) is reflected back after injection of local anesthesia, and a curette is used to scrape dermal tissue onto a slide.

## Giemsa Stain for Eosinophils or Amastigotes

- Identification of eosinophils can assist in distinguishing the pustulovesicular lesions of erythema toxicum neonatorum from neonatal pustular melanosis and congenital candidiasis.

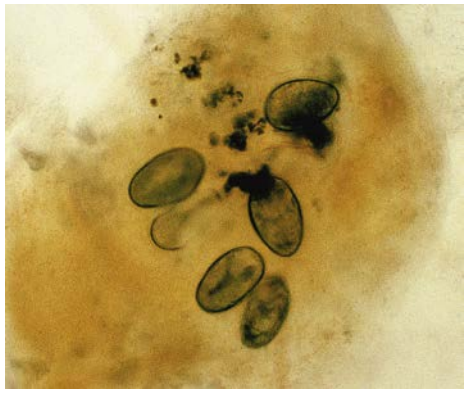

**Fig. 2.5 Microscopic examination of scrapings from a patient with scabies.** Both oval-shaped eggs and scybala (feces) are seen. *Courtesy, Craig N. Burkhart, MD, and Craig G. Burkhart, MD.*

**DEMONSTRATION OF LOCATION OF VIRALLY INFECTED KERATINOCYTES IN VESICULOBULLOUS LESIONS OF HERPES SIMPLEX, VARICELLA AND HERPES ZOSTER**

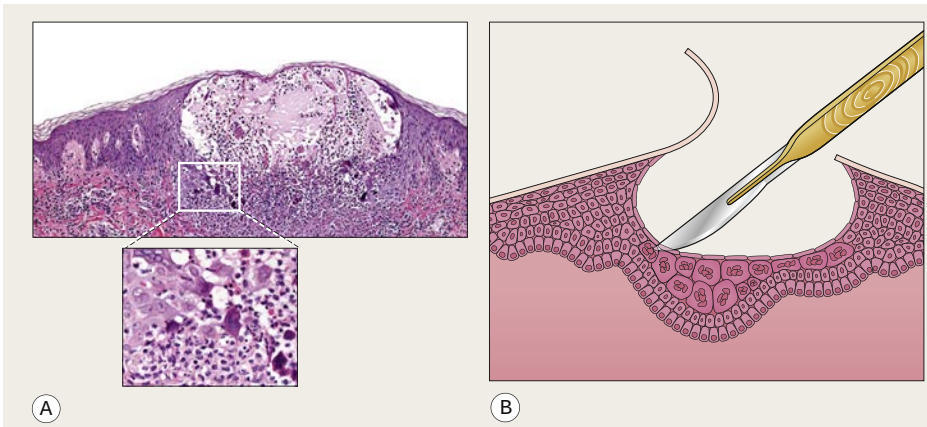


**Fig. 2.6 Demonstration of location of virally infected keratinocytes in vesiculobullous lesions of herpes simplex, varicella, and herpes zoster. A** Histologically, viral changes (e.g. multinucleated giant cells) are seen at the base of the vesicle; note their absence on the roof. **B** Scraping of the base of the vesicle is performed after the roof of the blister is reflected. *A, Courtesy, Lorenzo Cerroni, MD.*

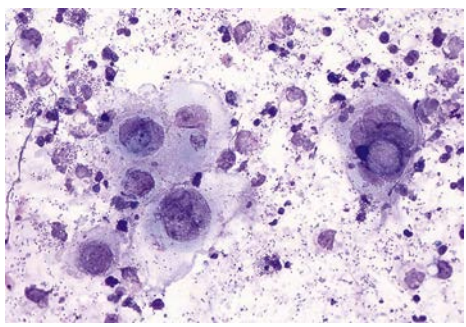

**Fig. 2.7 Tzanck smear demonstrating multinucleated giant cells.** Such cells are seen in herpes simplex, varicella, and herpes zoster viral infections (Giemsa stain). *Courtesy, Louis A. Fragola, Jr., MD.*

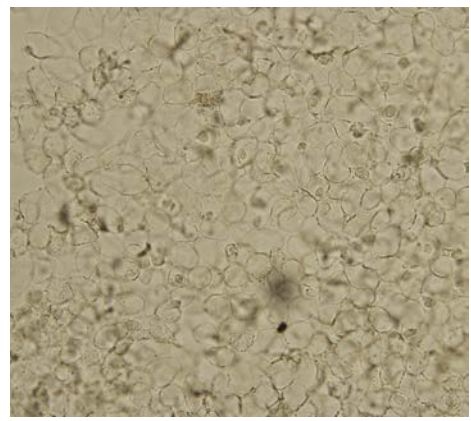

**Fig. 2.8 Large, round molluscum bodies are present in a scraping of the center of a papulonodule.** The scrapings can be mounted in saline or KOH solution. *Courtesy, Bradley Bloom, MD.*

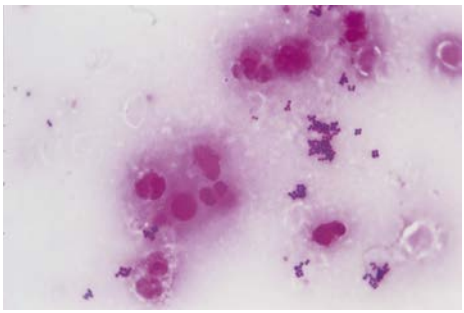

**Fig. 2.9 Gram stain of pus demonstrating polymorphonuclear leukocytes (neutrophils) and Gram-positive cocci in clusters (*Staphylococcus aureus*).** *From Ekkelenkamp, MB, Rooijakkers, SHM, Bonten, MJM. In: Cohen J, Powderly W, Opal S (Eds.), Infectious Diseases, 3rd edn. Edinburgh, UK: Mosby, 2010.*

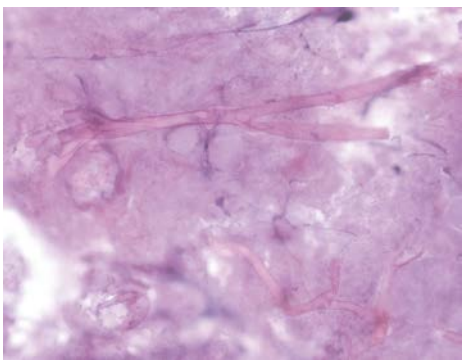

**Fig. 2.11 Microscopic examination of a "touch prep" from an incisional biopsy performed of a necrotic lesion on the chest of an immunocompromised patient.** Note the branching, ribbon-like, non-septate hyphae characteristic of *Rhizopus*. *Courtesy, Jean L. Bolognia, MD.*

**PERFORMANCE OF A STERILE SKIN BIOPSY**

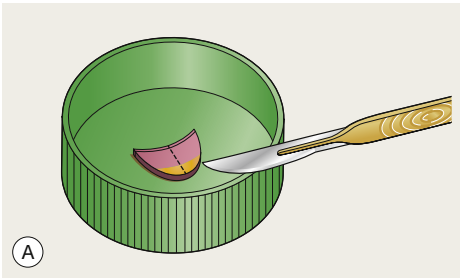





**Fig. 2.10 Performance of a sterile skin biopsy.** This is done when there is a suspicion of a septic embolus or primary skin infection of the dermis and/or subcutis. The equipment required includes a chemical antiseptic (e.g. chlorhexidine), alcohol pads, local anesthetic, punch biopsy instrument or scalpel, sterile scissors and forceps, sterile urine cup containing sterile gauze dampened with non-bacteriostatic saline, and glass slides. Following cleansing of the skin (antiseptic followed by alcohol), the skin is injected with local anesthesia, and a biopsy of dermis plus subcutaneous fat is performed (see Ch. 1). **A** The specimen is cut into two pieces on the sterile side of the urine container lid, while avoiding compression of the tissue. An alternative is to do two biopsies. **B** One piece or biopsy is placed in a sterile urine cup with moistened gauze, and the bottom of the second piece or second biopsy is tapped several times against a glass slide before being placed in formalin. The sealed sterile urine cup is hand-carried to the microbiology laboratory. Once the glass slide is dry, the touch prep can be stained to detect infectious organisms.

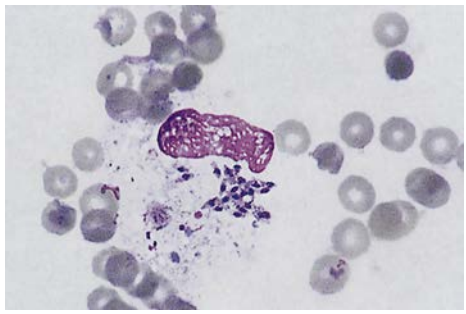

**Fig. 2.12 Dermal tissue obtained from a skin slit and scraping of a cutaneous lesion of leishmaniasis shows amastigotes within macrophages.** *From Peters W, Pasvol G. Tropical Medicine and Parasitology, 6th edn. London: Mosby, 2007.*

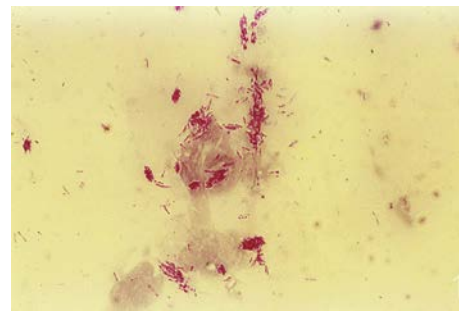

**Fig. 2.13 Smear stained with a Ziehl–Neelsen stain demonstrating acid-fast bacilli in a patient with leprosy.** *From Peters W, Pasvol G. Tropical Medicine and Parasitology, 6th edn. London: Mosby, 2007.*

• A skin slit and scraping of cutaneous lesions of leishmaniasis demonstrate amastigotes in macrophages when stained with a Giemsa stain (Fig. 2.12).

## Acid-Fast Stain for Leprosy

• When leprosy is suspected, a fold of skin is firmly squeezed and a small incision is made with a scalpel, with the liquid expressed smeared onto a slide, allowed to dry, and stained with a Fite or Ziehl–Neelsen stain (Fig. 2.13).
• For bacilloscopy, the skin sites that are examined include the earlobes, elbows, dorsal fingers, and lesions or infiltrated areas.
• While acid-fast *Mycobacterium leprae* organisms are found in ≤5% of patients with tuberculoid leprosy, they are seen in 100% of patients with lepromatous leprosy (see Ch. 62).

## Dark Field Microscopy for Treponemal Infections

• Dark field microscopy is utilized for the examination of unstained live organisms and in dermatology, primarily for the diagnosis of primary syphilis and less often secondary cutaneous syphilis (see Ch. 69).
• Expressed serous exudate with a minimal number of red blood cells is placed onto a slide and then a coverslip applied.
• The *Treponema* spirochetes have a characteristic morphology and movement pattern (Fig. 2.14).

## Evaluation of Folliculitis

• While the most common forms of folliculitis are associated with normal flora or *Staphylococcus aureus*, there are forms due to Gram-negative rods (e.g. *Pseudomonas*), *Malassezia* (*Pityrosporum*) spp., herpes simplex, and *Demodex* spp. (see Fig. 31.1).
• For bacteria, cultures are the primary means of diagnosis, but for *Pityrosporum* and *Demodex* folliculitis, bedside diagnosis is key (Fig. 2.15). In *Pityrosporum* folliculitis, only yeast forms are seen.

## Hair Shaft Examination

• Assessment of hair thinning, which may be due to miniaturization, shedding, or breakage, most commonly includes a gentle hair pull and a hair shaft examination of cut, rather than pulled, hairs; some clinicians also do a vigorous hair pluck referred to as a trichogram (20–40 scalp hairs grasped by a hemostat with rubber-covered jaws).
• In general, telogen hairs are observed with a gentle hair pull, but in disorders such as loose anagen syndrome, anagen hairs may be seen (see Ch. 56).
• In a trichogram, the ratio of anagen : telogen hairs is determined by microscopic examination of the hair bulbs (Fig. 2.16). The

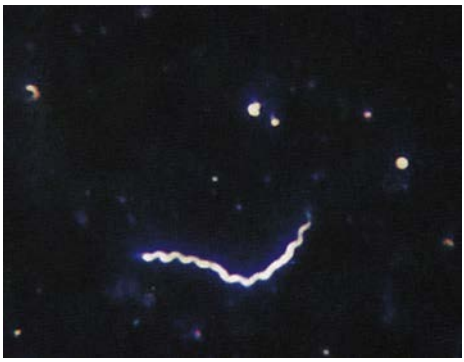

**Fig. 2.14 Dark field microscopic examination of a spirochete.** Treponemes are recognized by their characteristic corkscrew shape and deliberate forward and backward movement with rotation about the longitudinal axis. *From Morse et al. Atlas of Sexually Transmitted Diseases and AIDS, 3rd edn. London: Mosby; 2003.*



**Fig. 2.15 Microscopic examination of follicular contents in a patient with *Demodex* folliculitis.**

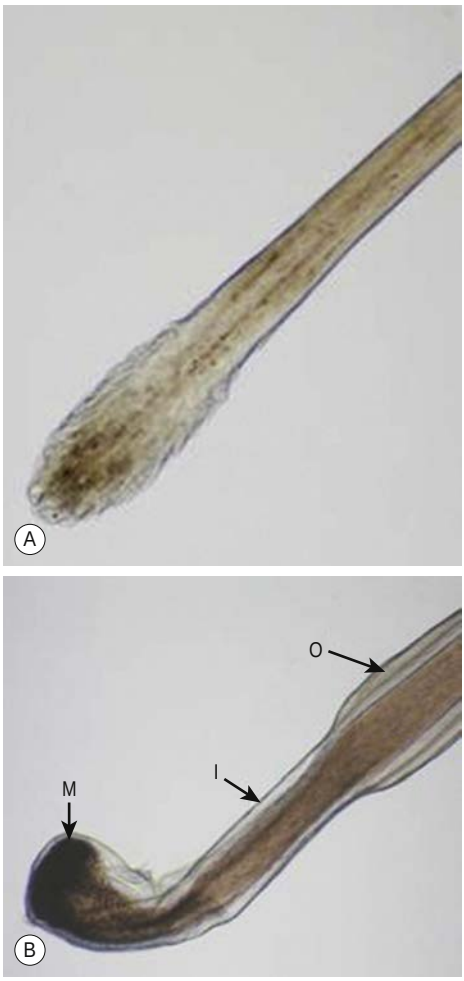


**Fig. 2.16 Comparison of a telogen versus anagen hair shaft. A** A telogen hair shaft has a club-shaped bulb. **B** An anagen hair has attached root sheaths as well as a pigmented and distorted bulb, sometimes resembling a hockey stick. M, matrix; I, inner root sheath; O, outer root sheath. *B, Courtesy, Leonard Sperling, MD.*

normal anagen-to-telogen ratio is 9:1, but in telogen effluvium, it can be 7:3 or less.

- Hair shaft examination can also detect bacterial and fungal infections (e.g. trichomycosis axillaris, white piedra, black piedra), hair casts, nits due to head lice infestation, and hair shaft abnormalities (e.g. trichorrhexis nodosa) (Fig. 2.17) (see Fig. 64.3 and Chs 56, 64, and 71).
- For optimal detection of hair shaft abnormalities, mounting in Permount™ (an adhesive composed of polymers dissolved in toluene) is performed.

## Identification of Arthropods

- Another bedside diagnostic procedure is the identification of lice, insects (e.g. bedbugs), and arachnids (e.g. ticks). Chs 71 and 72 review their identification via macroscopic and microscopic findings.

## Wood's Lamp Examination

- Table 2.1 outlines the fluorescent colors that are seen following absorption of UVA irradiation by different substances.




**Fig. 2.17 Hair shaft examination as a diagnostic tool. A** Nodule composed of numerous conidia of *Trichosporon inkin* in a patient with white piedra. **B** Two head louse egg casings (nits) are seen attached to hair shafts. **C** In trichorrhexis nodosa, the two ends of the hair shaft resemble opposing broomsticks. *B, With permission from Taplin D, Meinking TL. Infestations. In: Schachner LA, Hansen RC (Eds.), Pediatric Dermatology, 4th edn. Edinburgh, UK: Mosby, 2011:1141–1180; C, Courtesy, Christine Ko, MD.*

| WOOD'S LAMP EXAMINATION | |
|---|---|
| **Fluorescent color/change** | **Clinical example(s)** |
| Chalk-white to blue-white | Vitiligo (well-developed lesion) |
| Coral pink | Erythrasma (see Fig. 61.10B) |
| Golden to yellow-green | Tinea (pityriasis) versicolor |
| Blue-green to yellow-green | Tinea capitis due to *Microsporum* spp. |
| Enhancement of hypopigmentation | Ash leaf spot |
| Enhancement of brown color | Lentigines, epidermal form of post-inflammatory hyperpigmentation |
| Brown to brown-gray color becomes less obvious | Dermal form of postinflammatory hyperpigmentation |

**Table 2.1 Wood's lamp examination.** UVA irradiation (peak of ~365 nm) is emitted by a Wood's lamp. Colors within the visible spectrum have longer wavelengths and less energy than UVA.

# Fever and Rash

# 3

• A variety of infectious and inflammatory conditions can present with fever and a rash (Fig. 3.1). The cutaneous findings range from a morbilliform eruption or urticaria (Figs 3.2 and 3.3) to petechial, vesiculobullous, and pustular lesions (Figs 3.4–3.7).

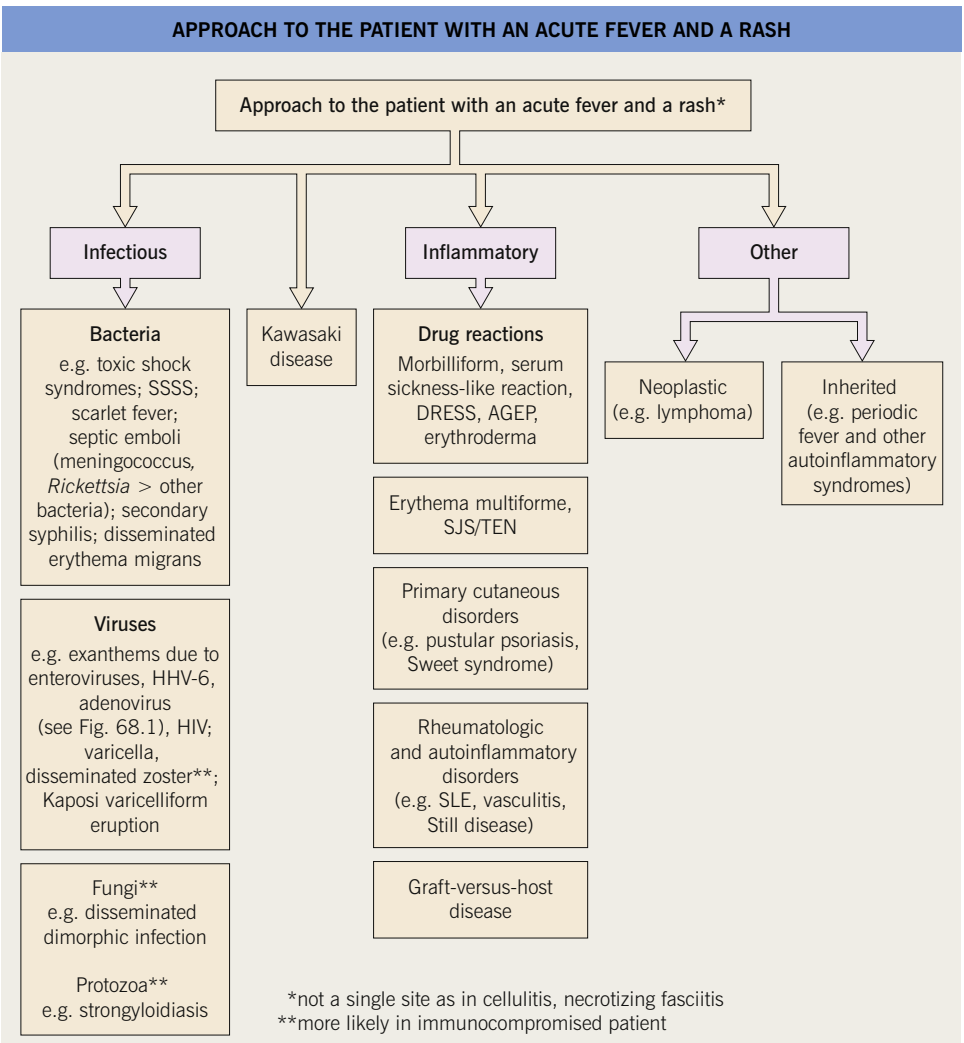


**Fig. 3.1 Approach to the patient with an acute fever and a rash.** AGEP, acute generalized exanthematous pustulosis; HHV, human herpes virus; SJS, Stevens–Johnson syndrome; SSSS, staphylococcal scalded skin syndrome; TEN, toxic epidermal necrolysis.

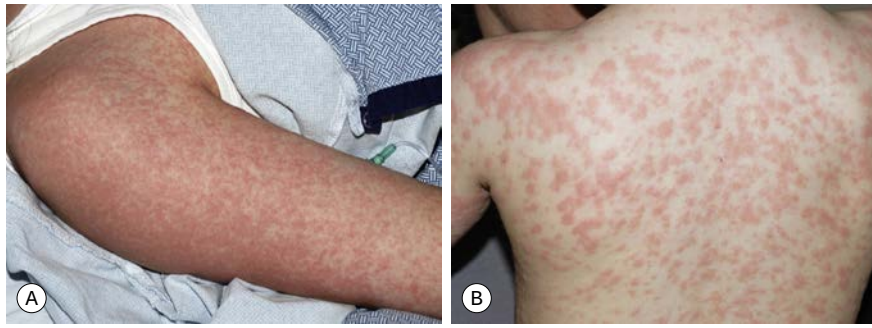

**Fig. 3.2 Morbilliform drug eruptions. A** Fine pink macules and thin papules, becoming confluent on the posterior upper arm, which is a dependent area in this hospitalized patient. **B** More edematous ("urticarial") pink papules; unlike true urticaria, these lesions are not transient. *Courtesy, Julie V. Schaffer, MD.*



**Fig. 3.3 Urticaria and serum sickness-like reaction. A** Giant annular urticaria (urticaria "multiforme") in a young child with a recent viral upper respiratory tract infection. Individual lesions last <24 hours, but they often resolve with a dusky purplish hue that can lead to misdiagnosis as erythema multiforme. **B** Serum sickness-like reaction due to amoxicillin. Some of the urticarial papules and annular plaques have a purpuric component, and the eruption was accompanied by high fevers, lymphadenopathy, arthralgias, and acral edema. *Courtesy, Julie V. Schaffer, MD.*



**Fig. 3.4 Stevens–Johnson syndrome.** The patient initially developed multiple small pink papules mimicking a morbilliform eruption, but with accentuation on the palms **(A).** A day later, confluent erythema and bullae had developed **(B),** and involvement of the vermilion lips and conjunctiva was evident. *Courtesy, Julie V. Schaffer, MD.*



**Fig. 3.5 Pustular psoriasis in a pediatric patient.** Multiple sterile papulopustules and expanding annular red plaques with pustulation at the advancing edge. This eruption was widespread and associated with fever and malaise. *Courtesy, Julie V. Schaffer, MD.*




**Fig. 3.6 Viral exanthems. A** Enteroviral exanthem presenting as widespread small pink papules, many with petechiae centrally. **B–D** Vesicular eruptions with variable crusting due to coxsackievirus A6 infection, with characteristic perioral involvement (**C**) and widespread "eczema coxsackium" in an infant with atopic dermatitis (**D**). **E** Scattered vesicles on erythematous bases in varicella, with lesions in different stages of evolution. *Courtesy, Julie V. Schaffer, MD.*




**Fig. 3.7 Staphylococcal scalded skin syndrome in a 2-year-old child. A** Diffuse, tender erythema with accentuation on the neck. Note the flaccid vesicles, skin wrinkling, and superficial erosion. **B** Later development of extensive superficial sloughing of the skin. *Courtesy, Julie V. Schaffer, MD.*

- Clinical features that distinguish entities within the differential diagnosis of an exanthematous drug eruption are summarized in Fig. 3.8.
- Although the initial skin findings of some potentially life-threatening disorders can mimic a more common benign disorder, the development of other cutaneous and extracutaneous features as the condition evolves points to the correct diagnosis (Table 3.1).

## Kawasaki Disease

- Acute febrile multisystem vasculitic syndrome that primarily affects children <5 years of age (rarely adults), with ~3-fold higher incidence in Asians than Caucasians.
- Most common cause of pediatric acquired heart disease in the United States, with greatest morbidity from coronary artery aneurysms.
- Etiology remains unknown; factors include a genetic predisposition to immune activation and possibly an infectious trigger.
- Diagnostic criteria include fever (>39°C/102°F) for ≥5 days plus the presence of ≥4 of the following five criteria.
  - Bilateral non-purulent bulbar conjunctival injection
  - Oropharyngeal changes such as "chapped"/fissured lips (Fig. 3.9), a "strawberry" tongue, and diffuse hyperemia
  - Cervical lymphadenopathy (>1.5 cm; usually unilateral)
  - Erythema, edema, and (eventually) desquamation of the hands and feet (Fig. 3.10A)
  - Polymorphous exanthem – morbilliform or urticarial > erythema multiforme-like (Fig. 3.10B), scarlatiniform, or pustular
- Initial manifestation is often erythema in the perineal area, followed by desquamation (Fig. 3.10B–3.10D); subacute manifestations can include a psoriasiform eruption and transverse orange-brown (pseudo) chromonychia.
- "Incomplete" Kawasaki disease (more common in infants) is diagnosed if fever for ≥5 days and coronary artery abnormalities (via echocardiography or angiography) but <4 other criteria.

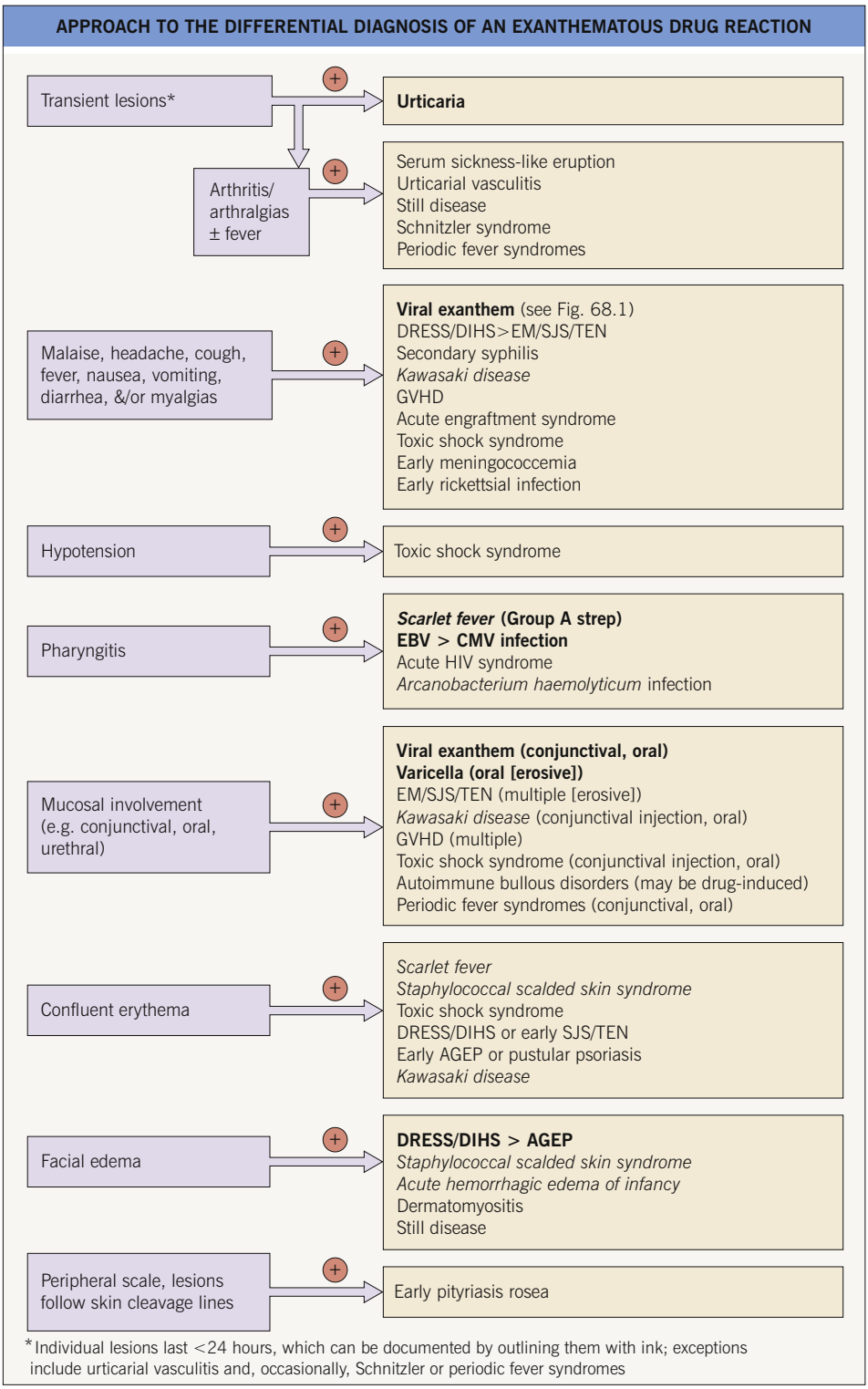


**Fig. 3.8 Approach to the differential diagnosis of an exanthematous drug reaction.** With a few exceptions (e.g., pityriasis rosea, autoimmune bullous disorders), patients with these entities may be febrile. *Entities in italics occur primarily in children*. Toxic shock syndrome can be staphylococcal or streptococcal (see Ch. 61). Acute generalized exanthematous pustulosis (AGEP) is also referred to as a pustular drug eruption. Autoimmune bullous disorders that may be drug-induced include bullous pemphigoid or linear IgA bullous dermatosis > pemphigus. *Continued*

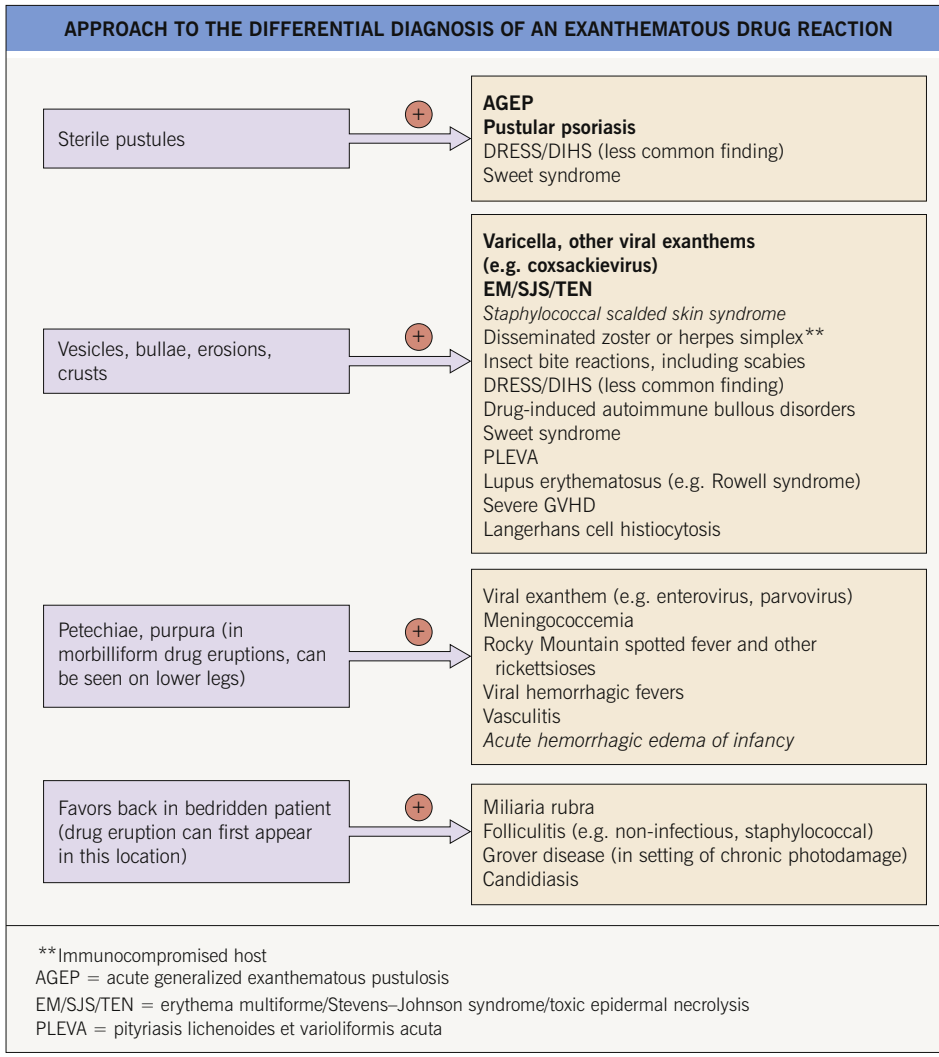


**Fig. 3.8** *Continued* **Approach to the differential diagnosis of an exanthematous drug reaction.**

| POTENTIALLY LIFE-THREATENING CONDITIONS WITH INITIAL SKIN FINDINGS THAT CAN MIMIC A MORE COMMON BENIGN DISORDER | | |
|---|---|---|
| **Potentially life-threatening condition** | **Benign disorder that is mimicked early in the course** | **Clues to the diagnosis as the condition evolves** |
| DRESS/DIHS* | Morbilliform/urticarial drug eruption > viral exanthem | • Facial swelling<br>• High fever<br>• Prominent lymphadenopathy<br>• Marked peripheral blood eosinophilia, atypical lymphocytes<br>• Elevated transaminases, other signs of internal organ involvement |
| Stevens–Johnson syndrome/ toxic epidermal necrolysis | Morbilliform/urticarial drug eruption > viral exanthem | • Early involvement of palms & soles<br>• Duskiness or blistering (often initially in the center of lesions)<br>• Painful/tender skin<br>• Mucosal erosions (oral, nasal, ocular, genital) |
| Rocky Mountain spotted fever (RMSF), other rickettsial spotted fevers | Viral exanthem (or severe viral syndromes) | • Potential exposure to ticks (e.g. season [spring–late summer for RMSF], geographic location)<br>• High fever, myalgias, headache (often for 2–5 days prior to rash)<br>• Rash begins on wrists/ankles → spreads centripetally (± palms/soles)<br>• Petechiae within erythematous macules/ papules |
| Meningo-coccemia | Viral exanthem | • Petechiae → retiform purpura<br>• Fever with chills, myalgias<br>• Headache, stiff neck |
| Kawasaki disease | Viral exanthem, morbilliform/ urticarial drug eruption, erythema multiforme, “diaper dermatitis” (for early perineal eruption) | • Early perineal erythema → desquamation<br>• Conjunctival injection<br>• “Chapped” lips, “strawberry” tongue<br>• Acral erythema and edema<br>• Continued high-spiking fever<br>• Prominent unilateral lymphadenopathy |
| Staphylococcal scalded skin syndrome (SSSS) | Seborrheic dermatitis, viral exanthem | • Painful/tender skin<br>• Periorificial (around mouth & eyes) edema and (later) radial scale-crusts<br>• Confluent erythema → superficial erosions/peeling, esp. in intertriginous sites |
| Necrotizing fasciitis | Cellulitis | • Tense, “woody” induration<br>• Extreme pain *or* (later) anesthesia<br>• Rapid evolution<br>• Erythema → dusky gray color<br>• Watery, malodorous discharge |

**In general, begins ≥2 weeks after drug is initiated and has a relatively limited set of culprit medications (see Ch. 17).*

**Table 3.1 Potentially life-threatening conditions with initial skin findings that can mimic a more common benign disorder.** The cutaneous manifestations are most likely to resemble those of milder disorder during the first 24 hours. Diffuse erythema, often beginning on the trunk, or a scarlatiniform exanthem can also be early manifestations of toxic shock syndrome.

**FACIAL FINDINGS IN KAWASAKI DISEASE, STAPHYLOCOCCAL SCALDED SKIN SYNDROME AND ERYTHEMA MULTIFORME MAJOR/STEVENS–JOHNSON SYNDROME**

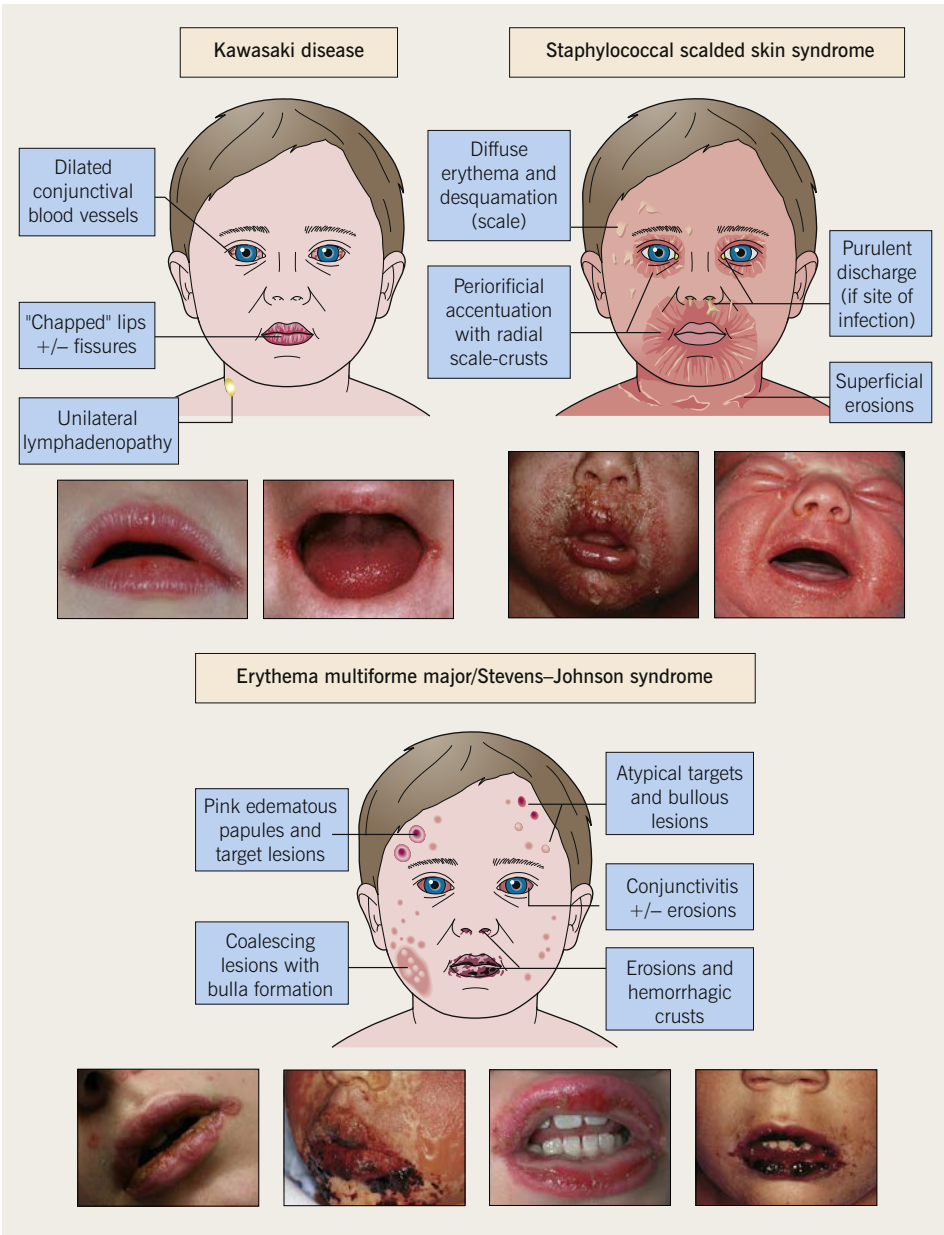


**Fig. 3.9 Facial findings in Kawasaki disease, staphylococcal scalded skin syndrome, and erythema multiforme major/Stevens–Johnson syndrome.** Hemorrhagic crusting and erosions of the vermilion portion of the lips can also be seen in primary gingivostomatitis due to herpes simplex virus, pemphigus vulgaris, and paraneoplastic pemphigus.

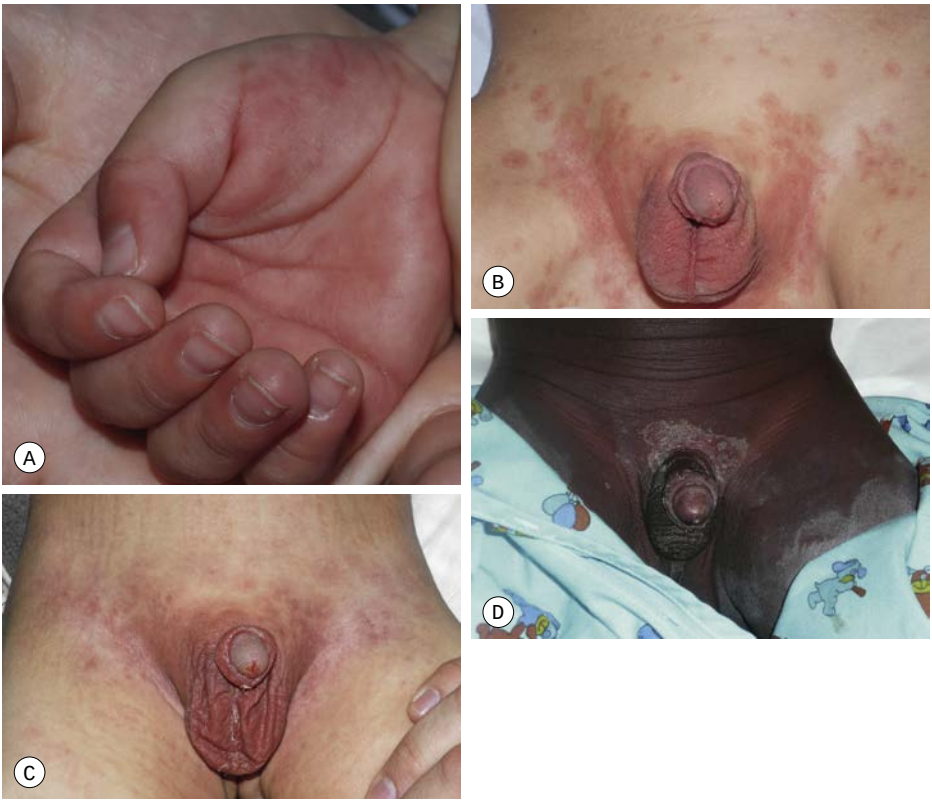


**Fig. 3.10 Kawasaki disease. A** Erythema and edema of the palm early in the disease course. **B, C** Erythema multiforme-like lesions becoming confluent in the perineal region on the second day of fever **(B)**, followed by desquamation 2 days later **(C)**. **D** Erythema (less evident due to the patient's darkly pigmented skin) and desquamation in the genital area. Involvement of the skin in this location is a characteristic early finding in Kawasaki disease. *A–C, Courtesy, Julie V. Schaffer, MD. D, Courtesy, Anthony Mancini, MD.*

- Other cardiac (e.g. myo-/pericarditis, valvular abnormalities), CNS (e.g. irritability, aseptic meningitis), musculoskeletal (e.g. arthritis), gastrointestinal, and genitourinary involvement can occur.
- Laboratory findings of acute disease include leukocytosis with neutrophilia, anemia, elevated ESR/CRP and hepatic transaminase levels, hypoalbuminemia and sterile pyuria; thrombocytosis typically develops by the 2nd or 3rd week (occasionally thrombocytopenia early).
- **DDx:** viral exanthem, multisystem inflammatory syndrome in children associated with COVID-19, scarlet fever, toxic shock syndrome, early staphylococcal scalded skin syndrome, drug reaction, erythema multiforme, Still disease, periodic fever syndrome.
- **Rx:** IVIg and aspirin are first-line; corticosteroids and infliximab are options for refractory disease.

## Periodic Fever Syndromes

- Group of hereditary autoinflammatory disorders that feature recurrent episodes of fever and rash (Table 3.2).
- Cutaneous findings, which range from erysipeloid erythema to urticarial eruptions, represent clues to the underlying diagnosis.
- Acute inflammation in other organ systems can lead to manifestations such as arthritis, serositis, and conjunctivitis; over time, secondary systemic amyloidosis may develop.

For further information see Chs 20, 21, 45 and 81 from *Dermatology, Fourth edition*.

**For additional online figures visit www.expertconsult.com**

| HEREDITARY PERIODIC FEVER SYNDROMES THAT PRESENT WITH A RASH | | | | |
|---|---|---|---|---|
| | **Familial Mediterranean fever (FMF)** | **Hyper-IgD with periodic fever syndrome (HIDS)** | **TNF receptor-associated periodic syndrome* (TRAPS)** | **Cryopyrin-associated periodic syndromes** (CAPS)** |
| Ethnic predilection | Armenians, Turks, Jews (especially Sephardic), Arabs, Italians | Dutch, northern Europeans | Variable | Variable |
| Inheritance | AR | AR | AD | AD |
| Gene | *MEFV* | *MVK* | *TNFRSF1A* | *NLRP3* > *NLRP12* |
| Protein | Pyrin | Mevalonate kinase | TNF receptor-1 | Cryopyrin > monarch-1 |
| Episode length | 1–4 days | 3–7 days | Often >7 days | <1–3 days |
| Mucocutaneous and ocular findings | Erysipeloid erythema and edema favoring leg/foot; ± palpable purpura (due to vasculitis) | Erythematous macules/papules; may become purpuric; ± oral or genital ulcers | Annular/serpiginous erythematous patches/plaques; distal migration on extremity; later ecchymotic; periorbital edema, conjunctivitis; ± oral ulcers | Urticarial papules and plaques; may be cold-induced; conjunctivitis > uveitis; ± oral ulcers |
| Musculoskeletal findings | Monoarthritis, myalgia | Arthralgia, oligoarthritis | Migratory myalgia > arthralgia > monoarthritis | Myalgia (limbs), arthralgia; arthritis and arthropathy in NOMID |
| Other clinical manifestations | Serositis (e.g., peritonitis mimicking acute abdomen, pleuritis), scrotal swelling, splenomegaly; amyloidosis | Abdominal pain, diarrhea, vomiting, cervical LAN, HSM | Serositis, scrotal pain, splenomegaly > LAN; amyloidosis | Hearing loss in MWS and NOMID; LAN, HSM, chronic aseptic meningitis & dysmorphic facies in NOMID; amyloidosis |
| Treatment | Colchicine prophylaxis; IL-1/IL-1R antag, TNF inhibitors, tocilizumab | CS for acute attacks; IL-1/IL-1R antag, TNF inhibitors, tocilizumab | CS for acute attacks; IL-1/IL-1R antag, etanercept, tocilizumab | CS for acute attacks; IL-1/IL-1R antag (rilonacept, canakinumab, anakinra) |

*Includes familial Hibernian fever.
**Cryopyrin-associated periodic syndromes (CAPS) include familial cold autoinflammatory syndrome, Muckle–Wells syndrome (MWS), and neonatal-onset multisystem inflammatory disease (NOMID; also known as chronic infantile neurologic, cutaneous and articular syndrome [CINCA]).

**Table 3.2 Hereditary periodic fever syndromes that present with a rash.** In all of these disorders, episodic "attacks" are characterized by fever and may be associated with headache. Table 37.3 outlines the cutaneous findings in other inherited autoinflammatory diseases. AD, autosomal dominant; AR, autosomal recessive; HSM, hepatosplenomegaly; IL-1/IL-1R antag, IL-1/IL-1 receptor antagnoists; LAN, lymphadenopathy.



ALGrawany







**eFig. 3.1 Sweet syndrome. A** Scattered edematous pink papules and plaques on the chest. **B** The edema can be quite marked as seen in these lesions on the upper back. *A, Courtesy, Mark D. P. Davis, MD. B, Courtesy, Kalman Watsky, MD.*



**eFig. 3.2 Acute generalized exanthematous pustulosis.** Diffuse erythema and numerous sterile pustules with superficial epidermal detachment in areas where the pustules have become confluent in a patient receiving amoxicillin. *Courtesy, Laurence Valeyrie-Allanore, MD*.



**eFig. 3.3 Bullous pemphigoid.** Multiple tense bullae and crusted erosions on a background of erythematous skin. *Courtesy, Julie V. Schaffer, MD.*



**eFig. 3.4 Vesicular eruptions due to coxsackievirus A6 infection.** *Courtesy, Julie V. Schaffer, MD.*

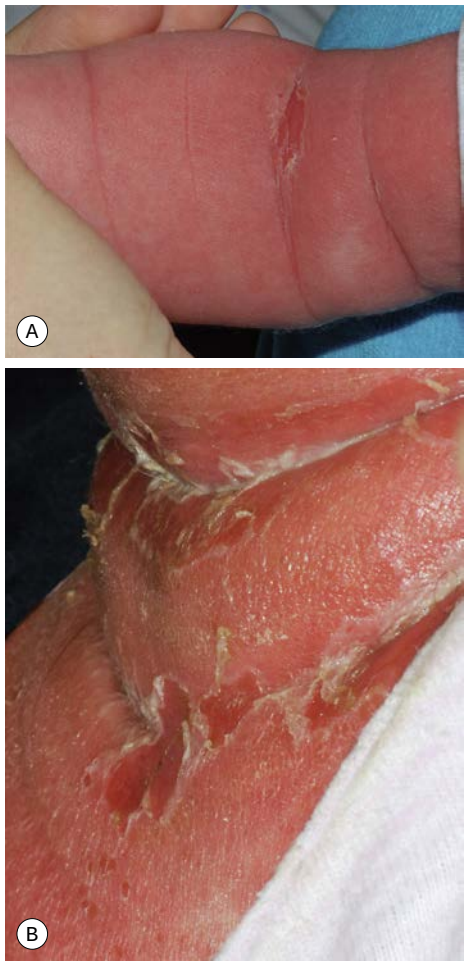


**eFig. 3.5 Staphylococcal scalded skin syndrome. A** Diffuse erythema with an early superficial erosion in the antecubital fossa. **B** More extensive involvement on the neck with a wrinkled appearance of the erythematous skin in addition to peeling and multiple erosions. *Courtesy, Julie V. Schaffer, MD.*



**eFig. 3.6 Staphylococcal folliculitis on the back of a hospitalized boy.** Other eruptions with a predilection for occluded sites such as the back of a bedridden patient include miliaria rubra (especially if febrile), non-infectious folliculitis, Grover disease (in the setting of chronic photodamage), and candidiasis. *Courtesy, Julie V. Schaffer, MD.*

# Pruritus and Dysesthesia

# 4

## Definitions

- **Pruritus:** an unpleasant sensation of the skin that elicits a desire to scratch.
- **Dysesthesia:** an unpleasant, abnormal sensation that can be either spontaneous or evoked; abnormal, unpleasant sensations may include pain, pruritus ("neuropathic itch"), tingling, burning, "pins and needles".

## Pruritus

- The most common skin-related symptom in dermatology; can have a profound negative impact on a patient's quality of life.
- Results from the activation of the sensory nervous system, involving four sequential levels: the peripheral nervous system → the dorsal root ganglia → the spinal cord → and the brain.
- There are multiple etiologies of pruritus, and it is often a major clinical challenge to diagnose the underlying etiology and to adequately treat.

### Etiologies

- May arise ***secondary*** to a number of conditions:
  - Dermatologic disorders (Table 4.1, Fig. 4.1)
  - Allergic or hypersensitivity syndromes
  - Systemic diseases (10–25%) and malignancies (Figs 4.2 and 4.3)
  - Toxins associated with kidney or liver dysfunction
  - Medications (Table 4.2)
  - Neurologic disorders (see text below)
  - Psychiatric conditions (see Ch. 5)
- May also be ***primary*** or ***idiopathic*** – that is, no readily apparent skin disease, underlying etiology, or associated condition.
- Most patients with pruritus due to an underlying dermatologic disorder present with characteristic or diagnostic skin lesions (e.g. dermatitis of the flexures in atopic dermatitis; see Table 4.1).
- In ***primary*** pruritus and ***secondary*** pruritus NOT due to an underlying dermatologic disorder, the lesions are usually nonspecific (e.g. linear excoriations [see Fig. 4.1], prurigo simplex, prurigo nodularis [Figs 4.5 and 4.6]).

### Diagnostic Pearls

- Patients with chronic, idiopathic pruritus need serial examinations because pruritus can antedate clinical manifestations of the underlying disorder (e.g. lymphoma) or with time, more specific lesions may appear (e.g. bullous pemphigoid).
- Sparing of the mid upper back, an area of patient-hand inaccessibility ('butterfly sign') (see Fig. 4.6), is suggestive of pruritus NOT associated with a dermatologic disorder; note, however, this sign is not seen in those who use back scratchers or similar devices.
- Aquagenic pruritus, provoked by cooling of the skin after emergence from a bath, is often idiopathic but may be a sign of polycythemia vera.
- Of note, some patients may have a combination of specific and nonspecific skin lesions and both may be due to an underlying systemic disorder (e.g. eosinophilic folliculitis associated with HIV infection/AIDS).

### Approach to the Patient with Pruritus

- Identifying the underlying etiology of a patient's pruritus is important in determining the appropriate management.
- A simplified approach to the patient with pruritus is presented in Fig. 4.2 and Table 4.3.

### Management of Pruritus

- General treatment measures for pruritus are outlined in Table 4.4.

| COMMON DERMATOLOGIC DISEASES WITH PRURITUS AS A MAJOR SYMPTOM |
|---|
| **Infestations/bites and stings** |
| • Scabies, pediculosis, arthropod bites |
| **Inflammation** |
| • Dermatitis: atopic, stasis, allergic > irritant, seborrheic (especially of the scalp)<br>• Psoriasis, parapsoriasis<br>• Lichen planus<br>• Urticaria, dermographism (Fig. 4.4), papular urticaria, urticarial dermatitis<br>• Drug eruptions (e.g. morbilliform)<br>• Bullous diseases (e.g. BP, DH)<br>• Mastocytosis<br>• Eosinophilic folliculitis<br>• Pruritic papular eruption of HIV<br>• LS (especially of the vulva), dermatomyositis, LE (systemic and cutaneous)<br>• GVHD |
| **Infection** |
| • Bacterial (e.g. folliculitis)<br>• Viral (e.g. varicella)<br>• Fungal (e.g. inflammatory tinea)<br>• Parasitic (e.g. schistosomal cercarial dermatitis) |
| **Neoplastic** |
| • Cutaneous T-cell lymphoma (e.g. mycosis fungoides, Sézary syndrome) |
| **Other** |
| • Xerosis/eczema craquelé<br>• Scar-associated pruritus, post-burn pruritus<br>• Fiberglass dermatitis<br>• Lichen simplex chronicus, prurigo nodularis<br>• Primary cutaneous amyloidosis (macular, lichenoid)<br>• Pregnancy dermatoses<br>• Neuropathic itch (e.g. notalgia paresthetica)<br>• PMLE, actinic prurigo, chronic actinic dermatitis<br>• Darier and Hailey–Hailey disease<br>• Porphyrias<br>• Ichthyoses |

**Table 4.1 Common dermatologic diseases with pruritus as a major symptom.** BP, bullous pemphigoid; DH, dermatitis herpetiformis; LS, lichen sclerosus; PMLE polymorphous light eruption.

## Classic Clinical Findings from Chronic Pruritus

### LICHEN SIMPLEX CHRONICUS (LSC)

- Skin-colored to pink or hyperpigmented plaques with exaggerated skin lines and a leathery appearance due to repeated, often habitual, scratching or rubbing (Fig. 4.7).
- Favors the posterior neck and occipital scalp (see Fig. 4.7B), anogenital region (see Table 1.3), and ankles (see Fig. 4.7A) as well as the extensor surface of the forearms and shins.
- LSC may be superimposed upon a specific cutaneous disorder, most commonly atopic dermatitis.
- In addition to symptomatic relief (e.g. topical anesthetics such as pramoxine), disruption of the itch–scratch cycle requires discussion of possible psychosocial issues (e.g. stress, depression, anxiety).
- **Rx:** potent topical CS, often under occlusion (e.g. hydrocolloid dressings), can be helpful.



**Fig. 4.1 Nonspecific lesions in atopic dermatitis.** Prurigo simplex, prurigo nodularis-like lesions and angulated ulcerations; the latter two are primarily on the knees. Although this patient had atopic dermatitis, similar lesions can be seen in patients with "primary" or "idiopathic" pruritus. *Courtesy, Antonio Torrelo, MD.*

• **Other Rx:** intralesional CS or use of an office-applied dressing (e.g. Unna boot) may be required.

#### PRURIGO NODULARIS

• Multiple, discrete, firm papulonodules with central scale-crust due to chronic and repetitive scratching and picking.
• Degree of pruritus can vary from moderate to intense.
• Lesions usually favor the extensor surfaces of the extremities (see Fig. 4.5), upper back, and buttocks, but they can be widespread in easily reachable areas (see Fig. 4.6).
• Disruption of the itch–scratch cycle requires symptomatic relief and discussion of psychosocial issues as in LSC (see above).
• **Rx:** depending on the number of lesions, varies from superpotent topical or intralesional CS to phototherapy (UVB [broadband or narrowband] or PUVA) and thalidomide.
• Novel agents, especially monoclonal antibodies (e.g. nemolizumab, dupilumab), may be beneficial for recalcitrant disease.
• If no underlying reversible disorder is detected (see Table 4.3), prurigo nodularis can be difficult to treat.

## Neurologic Etiologies of Pruritus and Dysesthesia

• The same neurological diseases that can cause neuropathic pain and dysesthesia can also cause neuropathic itch, with some differences (e.g. opioid pain relievers that help treat neuropathic pain may cause or worsen neuropathic itch).
• Neuropathic itch syndromes are typically due to either peripheral (PNS) or central nervous system (CNS) disorders and can be further categorized into focal or regional presentations.
• CNS-related neuropathic itch syndromes involve abnormalities of the brain.
• PNS-related neuropathic itch syndromes involve abnormalities of the spinal cord, cranial or spinal nerve roots, or peripheral nerves.
• Neuropathic itch is more likely to develop in the head and neck region than on the lower body (e.g. facial zoster is more likely to cause postherpetic itch [PHI] than zoster on the torso).
• Neuropathic itch differs in quality from other forms of pruritus and often makes afflicted individuals want to "dig at" or "gouge out" their skin; it is not responsive to antihistamines, but patients may find relief with application of ice packs.
• Patients with neuropathic itch often present first to a dermatologist.

#### TRIGEMINAL TROPHIC SYNDROME (TTS)

• A type of intractable facial neuropathic itch characterized by "painless scratching" to the point of self-harm and cutaneous ulceration.
• Classically involves the nasal ala and typically results from impingement or damage to the sensory portion of the trigeminal nerve (Figs 4.8 and 4.9).
• Common inciting factors include iatrogenesis (ablation of the Gasserian ganglion to treat intractable trigeminal neuralgia), infection (varicella zoster virus [VZV], herpes simplex virus), stroke (infarction of the posterior cerebellar artery), CNS tumors or their resultant treatment.
• Clinically may present as a small crust that develops into a crescentic ulcer that may gradually extend to involve the cheek and upper lip.
• The nasal tip is usually spared because its nerve supply is derived from the external branch of the anterior ethmoidal nerve.
• Treatment is difficult and should involve protective barriers, patient education, and surgical consultation; gabapentin, amitriptyline, and carbamazepine have been anecdotally reported as helpful.

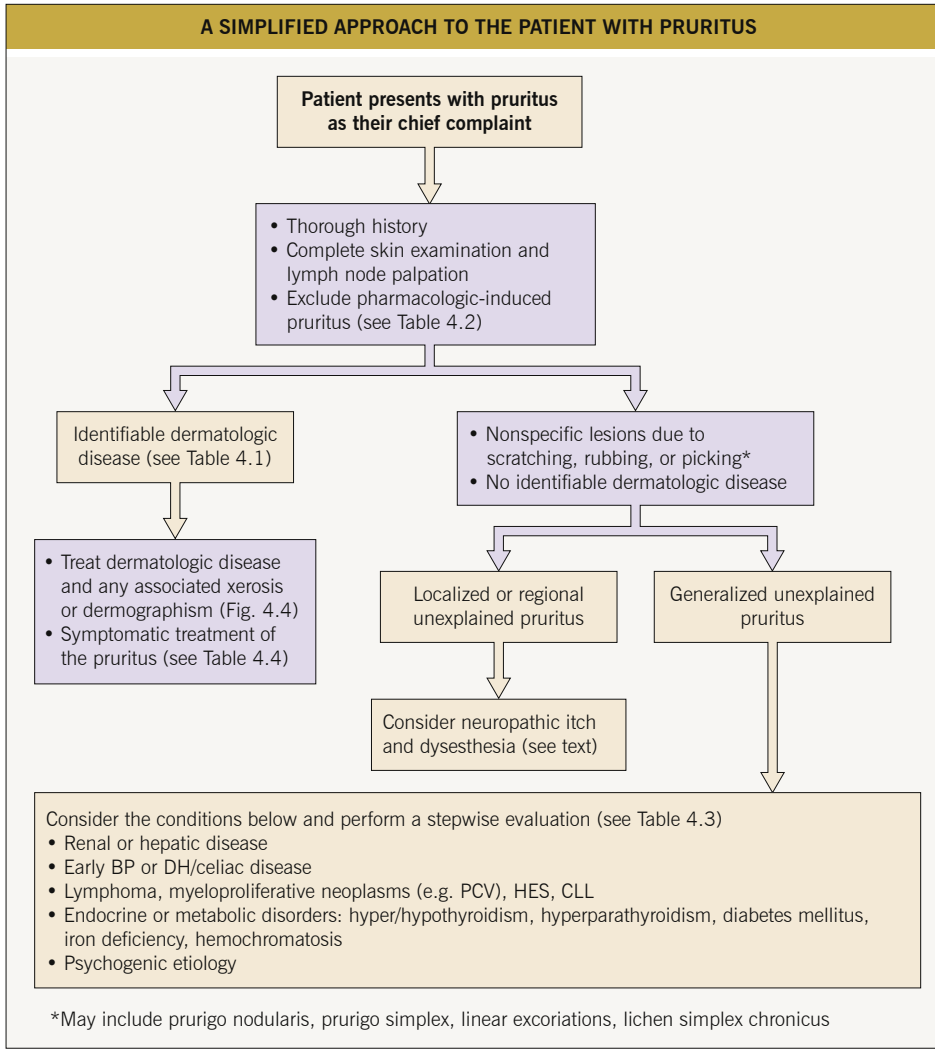


**Fig. 4.2 A simplified approach to the patient with pruritus.** BP, bullous pemphigoid; CLL, chronic lymphocytic leukemia; DH, dermatitis herpetiformis; HES, hypereosinophilic syndromes; PCV, polycythemia vera.

### SENSORY (MONO)NEUROPATHIES WITH PRURITUS AND DYSESTHESIA (RADICULOPATHIES)

- Characterized by a pattern of focal or regional neurological dysfunction that is caused by "injury" to a single sensory nerve root (SNR) or less often to a few adjacent nerve roots, resulting in pruritus or dysesthesia.
- "Injuries" that can cause damage to these SNRs may include (1) impingement from spinal osteoarthritis; (2) distal impingement or irritation by inflamed muscles or connective tissues; (3) infections (e.g. VZV, Lyme disease, leprosy); and (4) other rare causes, such as tumors (schwannomas, metastases), vascular malformations, and cysts.
- The abnormal sensation (e.g. pruritus or other dysesthesia) is perceived in the skin area that is innervated by the damaged SNR(s), and these areas are known as dermatomes (see Fig. 67.10).
- Clinical presentations are usually unilateral and on the side of the damaged SNR, but occasionally may be bilateral.
- The evaluation of an unexplained radiculopathy should include a neurologic examination.

• If the symptoms are severe, sudden in onset, or worsen significantly, then radiologic imaging (MRI is most sensitive) of the appropriate area of the spine can be performed.



**Fig. 4.3 Xerosis and pruritus in a patient with end-stage renal failure on hemodialysis.** There are a few papules of acquired perforating dermatosis admixed with the scratch marks. *Courtesy, Jean L. Bolognia, MD.*

• If radiologic imaging is negative, electromyogram and nerve conduction studies can be considered.

• In general, symptomatic treatment may include (1) topical agents (e.g. anesthetics, capsaicin); (2) various oral neuromodulators (e.g. gabapentin, pregabalin, other anticonvulsants); (3) physical therapy and acupuncture (if underlying muscle or connective tissue inflammation); and (4) botulinum toxin injections to weaken impinging muscles, if deemed safe.

• Several classic radiculopathies encountered in dermatology are (1) "shingles" or post-herpetic neuralgia (PHN) or post-herpetic itch (PHI); (2) notalgia paresthetica; (3) brachioradial pruritus, and (4) meralgia paresthetica (see Fig. 4.8).



**Fig. 4.4 Dermographism.** Linear streaks of urticaria induced by scratching the skin. Assessment for dermographism should be performed in all patients with pruritus. *Courtesy, Franz J. Legat, MD.*

| COMMON PHARMACOLOGIC ETIOLOGIES OF PRURITUS WITHOUT A RASH |
|---|
| **Most common** |
| • *Opioids:* tramadol, codeine, morphine*,**, butorphanol*, fentanyl* |
| • *Illicit drugs:* methamphetamine, cocaine |
| **Less common** |
| • *Antihypertensives:* calcium channel blockers |
| • *Antimalarials:* chloroquine (most common in individuals of African heritage) |
| • *Psychotropic drugs:* selective serotonin reuptake inhibitors |
| • *Anti-neoplastic agents*: CTLA-4 inhibitors, PD-1 inhibitors, EGFR inhibitors, selective BRAF or MEK inhibitors, tyrosine kinase inhibitors (e.g. sorafenib [especially scalp pruritus]) |
| • *Other:* statins, hydroxyethyl starch, omeprazole, paclitaxel, tamoxifen, granulocyte–macrophage colony-stimulating factor, interferon |
| **Pruritus is more likely with intrathecal/epidural than systemic administration.* <br> ***Also causes nonimmunologic release of histamine from mast cells.* |

**Table 4.2 Common pharmacologic etiologies of pruritus without a rash.** Itch may also occur as a direct effect of interleukin 2 therapy. Additional drugs may cause pruritus secondary to cholestatic injury (e.g. sulfonamides, penicillins, erythromycin estolate). CTLA-4, cytotoxic T lymphocyte-associated antigen 4; PD-1, programmed cell death protein 1.

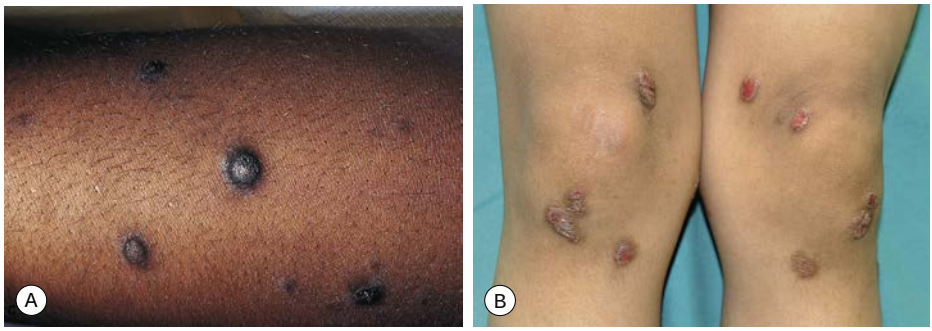

**Fig. 4.5 Prurigo nodularis. A** Firm hyperpigmented papulonodules on the extensor forearm due to repeated scratching and picking. **B** Papulonodules and plaques in various stages on the knees of a patient with atopic dermatitis. *A, Courtesy, Ronald P. Rapini, MD; B, Courtesy, Antonio Torrelo, MD.*



**Fig. 4.6 Multiple lesions of prurigo nodularis.** Note the sparing of the mid upper back ("butterfly sign"). *Courtesy, USCDRSC.*

*NOTALGIA PARESTHETICA*

- Affects roughly 10% of the adult population and thought to be related to SNR impingement at the level of the spinal cord due to osteoarthritis or more distally, due to impingement or irritation from inflamed muscles or other connective tissue.
- Presents with focal, intense pruritus of the upper back, most commonly along the medial scapular borders (see Fig. 4.8A and C); sometimes the pruritus is accompanied by other dysesthesias (e.g. pain, burning).
- Often, a hyperpigmented patch that is a result of chronic rubbing is seen in the area of pruritus (Fig. 4.8A and C).
- **DDx:** macular amyloidosis, which is also due to chronic rubbing and is probably a related entity; both disorders can be a cutaneous marker of Sipple syndrome, especially if the onset is during childhood or adolescence.
- **Rx:** topical capsaicin, a natural plant product that depletes substance P from cutaneous nerve endings, 5 times daily for 1 week followed by 3 times daily for 3–6 weeks may be effective.
- **Other Rx:** topical anesthetics, gabapentin, and acupuncture.

*BRACHIORADIAL PRURITUS*

- Chronic, intermittent pruritus or burning pain of the dorsolateral aspects of the forearms and elbows; sometimes more extensive area of involvement (e.g. shoulder region) (see Fig. 4.8A and B).
- Most patients have photodamaged skin and degenerative cervical spine disease, with UV light exposure and heat serving as triggers.
- The patient can often precisely delineate the affected area with a marking pen, and within this area are excoriations, prurigo simplex lesions, and sometimes even scarring (see Fig. 4.8B).

| LABORATORY AND RADIOGRAPHIC EVALUATION OF THE PATIENT WITH GENERALIZED PRURITUS OF UNKNOWN ETIOLOGY |
|---|
| **Basic initial evaluation** |
| CBC with differential and platelet count<br>ESR and CRP<br>Creatinine, blood urea nitrogen, electrolytes<br>Liver transaminases, alkaline phosphatase, bilirubin<br>LDH<br>Fasting glucose<br>TSH ± free thyroxine |
| **Possible additional evaluation** |
| **Skin biopsy** |
| Routine histology (if skin lesions are present)<br>Direct immunofluorescence studies* |
| **Other laboratory tests** |
| Serum total and/or allergen-specific IgE<br>Serum ferritin, iron, total iron binding capacity<br>Hemoglobin A1c<br>Parathyroid function (calcium, phosphate and parathyroid hormone levels)<br>Stool for ova/parasites and/or occult blood<br>Viral hepatitis panel (including hepatitis B and C viruses)<br>HIV testing<br>Anti-tissue transglutaminase ± epidermal transglutaminase IgA antibodies**<br>Anti-BP180 and anti-BP230 bullous pemphigoid IgG antibodies<br>Anti-mitochondrial and anti-smooth muscle antibodies<br>Serum tryptase, histamine, and/or chromogranin-A levels<br>Urinalysis with sediment evaluation<br>24-hour urine collection for 5-hydroxyindoleacetic acid (5-HIAA; a serotonin metabolite) and porphyrins<br>Serum protein electrophoresis, serum immunofixation electrophoresis |
| **Radiographic studies** |
| Chest X-ray or CT scan<br>Abdominal and pelvic ultrasonography or CT scan<br>Lymph node ultrasonography |
| **Other investigations** |
| Patch testing<br>Prick testing for major atopy and relevant occupational allergens<br>Age-appropriate cancer screening (in conjunction with primary care physician)<br>If hydroxyethyl starch (HES)-induced pruritus is suspected, electron microscopy of a biopsy sample from normal-appearing skin |
| **Biopsy perilesional skin or normal-appearing skin (in vicinity of lesions if present) to assess for bullous pemphigoid and dermatitis herpetiformis, respectively.*<br>***Often performed in conjunction with serum total IgA; in patients with IgA deficiency, anti-tissue transglutaminase IgG antibodies should be assessed.* |

**Table 4.3 Laboratory and radiographic evaluation of the patient with generalized pruritus of unknown etiology.** A general physical examination should also be performed by the patient's primary care physician. Selection of particular tests beyond the basic initial evaluation is based upon the patient's history, physical examination findings, and pruritus severity. The results of initial testing can also help to direct further evaluation.

- The "ice-pack sign" is another diagnostic clue, because application of ice is often reported as the only modality that provides relief.
- **Rx:** sun protection, cold packs, topical medications (pramoxine, capsaicin), oral neuromodulating drugs (gabapentin, amitriptyline).

*MERALGIA PARESTHETICA*

- Due to impingement of the lateral femoral cutaneous nerve as it passes through the

| GENERAL MEASURES FOR THE TREATMENT OF PRURITUS AND DYSESTHESIA |
|---|
| **Skin care** |
| • Lukewarm baths or showers with minimal use of soap (use mild soaps or non-soap cleansers)<br>• Moisturization twice a day, especially while skin still damp (ointment > cream)<br>• Avoid woolens, harsh fabrics, fabric softeners<br>• Keep nails cut short<br>• Address any superimposed dermographism |
| **Topicals** |
| • *Cooling agents/counterirritants*: e.g. menthol, camphor, capsaicin (best for localized itch, especially of neuropathic origin)<br>• *Anesthetics*: e.g. pramoxine, lidocaine, prilocaine, polidocanol, palmitoylethanolamine<br>• *Anti-inflammatory agents*: corticosteroids, calcineurin inhibitors |
| **Systemic medications** |
| • *Antihistamines*: especially if there is a component of dermographism or urticaria; otherwise limited efficacy beyond sedative effects; consider doxepin (beginning with 10–25 mg at bedtime)<br>• *Neuromodulators*: gabapentin, pregabalin (best for neuropathic pruritus, post-herpetic neuralgia, post-burn pruritus)<br>• *Antidepressants:* SSRIs (e.g. fluoxetine, paroxetine, sertraline, venlafaxine), tricyclics (e.g. amitriptyline, doxepin), mirtazapine (sedative effects)<br>• *Opioid antagonists/agonists:* e.g. naltrexone, naloxone, nalfurafine*, butorphanol nasal spray<br>• *Other:* thalidomide, monoclonal antibodies (e.g. nemolizumab, dupilumab; especially for prurigo nodularis); aprepitant (reports of benefit in atopic dermatitis, CTCL, and itch induced by EGFR- and tyrosine kinase-inhibitors) |
| **Physical modalities** |
| • *Phototherapy*: UVB (broadband or narrowband), PUVA, UVA, UVA-1<br>• Acupuncture |
| **Psychological approaches** |
| • Behavior modification therapy, biofeedback<br>• Support groups |
| **Treatment for renal pruritus** |
| • *Topical measures:* capsaicin, pramoxine, γ-linolenic acid, cromolyn sodium<br>• *Systemic measures (first-line):* gabapentin, pregabalin, UVB (broadband or narrowband)<br>• *Systemic measures (second-line):* naltrexone, nalfurafine* |
| **Treatment for hepatic pruritus** |
| • *Systemic measures (first-line):* cholestyramine, ursodeoxycholic acid<br>• *Systemic measures (second-line):* rifampin<br>• *Systemic measures (third-line):* naloxone, naltrexone, nalfurafine* |
| **Kappa-opioid receptor agonist; available in Japan.* |

**Table 4.4 General measures for the treatment of pruritus and dysesthesia.** CTCL, cutaneous T-cell lymphoma.

inguinal ligament; rarely due to trauma or ischemia.

- Presents with pruritus or dysesthesia of the anterolateral thigh, most often numbness or burning pain (see Fig. 4.8D).
- Predisposing factors include obesity, pregnancy, tight clothing, and, rarely, mass effect from tumor or hemorrhage.
- **Rx:** removal of the cause of compression, focal nerve block at the inguinal ligament, and lastly surgical decompression.
- Neuromodulating medications are not typically helpful.

### SMALL FIBER POLYNEUROPATHIES (SFPN)

- Perhaps the most common cause of chronic pruritus in the following areas: bilateral feet; feet and legs; hands and legs; or other widespread bilateral areas of the body.
- Typically presents with pruritus, dysesthesias, paresthesias, and/or neuropathic pain in a "stocking-glove" distribution; muscle function is usually intact.



A L G r a w a n y



**Fig. 4.7 Lichen simplex chronicus. A** Lichenified plaque on the ankle of a young man. **B** Note the increased skin markings in this hyperpigmented plaque on the posterior neck. *A, Courtesy, Franz Legat, MD; B, Courtesy, Ronald P. Rapini, MD.*

- If the diagnosis of SFPN is suspected based on history and neurologic examination, then potentially treatable causes should be identified, including:
  - Fasting blood glucose, HbA1c (diabetes mellitus)
  - Serum $B_{12}$, RBC folate, methylmalonic acid, homocysteine, and copper levels ($B_{12}$, folate, or copper deficiencies)
  - Serum (SPEP) and urine (UPEP) protein electrophoreses, immunofixation and serum-free light-chain analysis (monoclonal gammopathy)
  - CBC with differential and platelets (hematologic malignancies)
- For SFPN, there are two diagnostic tests:
  - Immunohistochemical staining (e.g. anti-PGP9.5) of a (non-traumatized) distal leg skin punch biopsy specimen to evaluate the small nerve fibers (requires a special fixative)
  - Autoimmune function testing (e.g. sweat functioning)

## Regional Dysesthesia Syndromes

- Typically caused by an underlying neurological disorder (either peripheral or central), but it is not always identifiable.
- Several locoregional dysesthesia syndromes are encountered in dermatology: burning mouth syndrome (orodynia), burning scalp syndrome (scalp dysesthesia), and several dysesthetic anogenital syndromes.
- **DDx:** includes psychogenic pruritus/dysesthesia (see Ch. 5).

### Burning Mouth Syndrome (Orodynia)

- Burning mucosal pain without clinically detectable oral lesions; most commonly affects middle-aged to elderly women.
- Typically bilateral, involving the anterior two-thirds of the tongue, palate, and lower lip.
- Diagnosis requires exclusion of secondary causes such as malignancy (e.g. oral SCC), vitamin deficiencies (e.g. folate, $B_{12}$), candidiasis, xerostomia (e.g. previous radiation therapy, Sjögren syndrome), contact stomatitis, and ill-fitting dentures.
- Depression and anxiety are more common in patients with burning mouth syndrome.
- **Rx:** oral tricyclic antidepressants and gabapentin in addition to topical anesthetics (e.g. lidocaine, dyclonine) and mouthwashes (various combinations of tetracycline, hydrocortisone, diphenhydramine, nystatin, and Maalox®).

### Burning Scalp Syndrome (Scalp Dysesthesia)

- Diffuse scalp burning, pain, pruritus, numbness or tingling without any specific cutaneous lesions.
- Strongly correlated with underlying depression and anxiety.
- Occasionally associated with primary neurologic disorders (e.g. multiple sclerosis).
- Diagnosis requires exclusion and treatment of secondary causes, such as seborrheic dermatitis, folliculitis, lichen planopilaris, allergic or irritant contact dermatitis, dermatomyositis, and discoid lupus erythematosus.
- **Rx:** oral tricyclic antidepressants.

### Dysesthetic Anogenital Syndromes

- Various names: pruritus ani, anodynia, pruritus vulvae, vulvodynia, pruritus scroti, scrotodynia, penile pain syndrome.

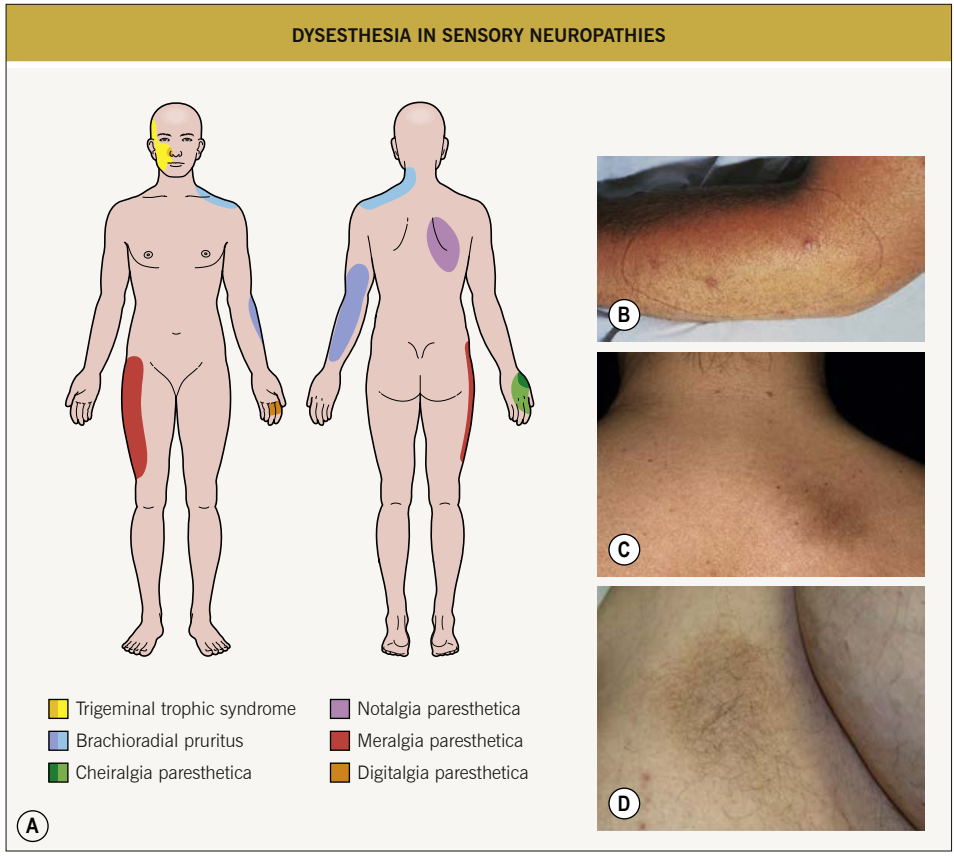


**Fig. 4.8 Dysesthesia in sensory neuropathies.** **A** Distribution of dysesthesia in selected neuropathic conditions. Darker shades indicate more common areas of involvement. **B** Brachioradial pruritus with the affected area outlined by ink. **C** Classic notalgia paresthetica with hyperpigmentation on the right upper back at the medial scapular border. **D** Meralgia paresthetica presenting as hyperpigmentation and lichenification in a discrete area of dysesthesia on the anterior thigh. *A, Courtesy, Karynne O. Duncan, MD; B, Courtesy, Elke Weisshaar, MD and Jeffrey D. Bernhard, MD; C, Courtesy Lorenzo Cerroni, MD; D, Courtesy, YDRSC.*




**Fig. 4.9 Trigeminal trophic syndrome.** Ulceration localized to the nasal ala and adjacent cheek. *Courtesy, Edward Cowen, MD.*

- Severe, intractable pruritus or dysesthesia despite either a normal clinical examination or the presence of nonspecific cutaneous findings.
- When all typical secondary causes of anogenital pruritus and dysesthesia have been investigated and treated (e.g. candidiasis, fecal incontinence; see Ch. 60), and the patient still has symptoms, consider lumbosacral radiculopathy (imaging studies), dermographism (trial of oral antihistamines), and contact dermatitis (patch testing).
- If no etiology detected, consider both psychiatric counseling and treatment with a neuromodulator medication (e.g. tricyclic antidepressant or gabapentin).

## Complex Regional Pain Syndrome (CRPS)

- Previously known as reflex sympathetic dystrophy; characterized by continuing regional pain that is out of proportion to the usual course following trauma or other insults.
- The upper extremities, particularly the hands (Fig. 4.10) are most commonly affected but lower extremities may also be involved.
- Due to regional insult to nociceptive terminals that results in a signal cascade which ultimately amplifies the pain response in the CNS.
- Characteristic findings include burning pain, hyperalgesia, allodynia, vasomotor dysfunction (e.g. erythema, edema, livedo reticularis, cyanosis), hypertrichosis, hyperhidrosis, nail dystrophy, motor dysfunction and eventually atrophy.



**Fig. 4.10 Complex regional pain syndrome with scaling and erosions of the fingertips.**
*Courtesy, Kalman Watsky, MD.*

- Patients with suspected CRPS should be referred to a neurologist for further evaluation.

For further information see Ch. 6 from *Dermatology, Fourth Edition*.

**For additional online figures and tables visit www.expertconsult.com**



**eFig. 4.1 Extreme xerosis associated with pruritus in an HIV-infected patient.** *Courtesy, Elke Weisshaar, MD and Jeffrey D. Bernhard, MD.*



**eFig. 4.2 Linear excoriations on the leg.** Although this patient had atopic dermatitis, similar lesions can be seen in patients with "primary" or "idiopathic" pruritus. *Courtesy, Elke Weisshaar, MD and Jeffrey D. Bernhard, MD.*



**eFig. 4.3 Lichen simplex chronicus of the lateral neck.** Note the increased skin markings. Use of topical corticosteroids can lead to a shiny appearance and a rim of hypopigmentation. *Courtesy, Elke Weisshaar, MD and Jeffrey D. Bernhard, MD.*



**eFig. 4.4 Lichen simplex chronicus.** Secondary pigmentary changes are seen more commonly in darkly pigmented skin. *Courtesy, Louis A. Fragola, Jr., MD.*




**eFig. 4.5 Widespread prurigo nodularis.** Numerous excoriated papules and nodules **(A–C)**. **A** This patient had underlying atopic dermatitis. **B, C** Note the sparing of the mid upper back ("butterfly sign"). **D** Numerous erosions with hemorrhagic crusts, referred to as prurigo simplex. *A, Courtesy, Elke Weisshaar, MD and Jeffrey D. Bernhard, MD; B, Courtesy, Franz J. Legat, MD; C, D, Courtesy, Luis Requena, MD.*



**eFig. 4.6 Pemphigoid nodularis.** Multiple crusted lesions and scars are evident. Bullous pemphigoid is often intensely pruritic and may not present with intact vesiculobullae. *Courtesy, Jeffrey P. Callen, MD.*




**eFig. 4.7 Trigeminal trophic syndrome.** Erosions and ulcerations with hemorrhagic crusts favor the ala nasi **(A–C)**. Obvious linear excoriations are seen in the second patient **(B)**. This patient **(C)** also has excoriations, superficial ulcers, and scars on the upper lip, cheek and chin. *A, B, Courtesy, Kalman Watsky, MD; C, Courtesy, Lorenzo Cerroni, MD.*




**eFig. 4.8 Dysesthesia in sensory neuropathies. A, B** Notalgia paresthetica. Circumscribed areas of hyperpigmentation on the **(A)** left mid back (overlying the medial aspect of the scapula) and **(B)** right lower medial scapula due to chronic rubbing and scratching. Both patients complained of significant pruritus in those areas. An incidental café-au-lait macule is on the right mid back in patient **A**. **C** Secondary skin lesions on the right neck in a patient with cervical osteoarthropathy. *A, Courtesy, Jean L. Bolognia, MD; B, C, Courtesy, Franz J. Legat, MD.*

| DIFFERENTIAL DIAGNOSIS OF PRURITUS OR PRICKLING SENSATIONS PROVOKED BY WATER CONTACT |
|---|
| **Disease-associated skin findings typically evident at time of visit** |
| • Polycythemia vera* (ruddy complexion)<br>• Mastocytosis (cutaneous lesions, positive Darier's sign)<br>• Hypereosinophilic syndrome (cutaneous lesions in >50% of patients)<br>• Hemochromatosis (diffuse hyperpigmentation) |
| **Urticaria by history and/or challenge** |
| • Dermographism<br>• Cold urticaria<br>• Cholinergic urticaria (with hot water exposure)<br>• Aquagenic urticaria |
| **Skin findings (other than those due to scratching) typically absent** |
| • Hodgkin lymphoma<br>• Myelodysplastic syndromes<br>• Essential thrombocythemia<br>• Testosterone-induced erythrocytosis<br>• Drug-related (e.g. antimalarials, bupropion, clomipramine)<br>• Aquagenic pruritus of the elderly (xerosis may be subtle)<br>• Primary (idiopathic) aquagenic pruritus |
| **Aspirin doses up to 300–500 mg 1–3 times daily may provide partial relief; improvement of aquagenic pruritus with selective serotonin reuptake inhibitors (SSRIs) has been reported.* |

**eTable 4.1 Differential diagnosis of pruritus or prickling sensations provoked by water contact.**
A possible relationship with lactose intolerance in a subset of patients has also been reported.

| THERAPEUTIC LADDER FOR RENAL PRURITUS |
|---|
| **Topical medications** |
| • Capsaicin (0.025% three to five times daily) (2)<br>• γ-linolenic acid (2.2% four times daily) (1)<br>• Pramoxine (1)<br>• Cromolyn sodium (4% cream twice daily) (1) |
| **Systemic medications and phototherapy** |
| **First-line for persistent moderate-to-severe pruritus** |
| • Gabapentin (100–300 mg PO†) (1)<br>• Pregabalin (25–75 mg PO†) (1)<br>• UVB broadband or narrowband phototherapy (1) |
| **Second-line for persistent moderate-to-severe pruritus** |
| • Naltrexone (25–100 mg PO daily) (2)<br>• Nalfurafine* (2.5–5 mcg PO or IV†) (1) |
| **Additional options** |
| • Activated charcoal (6 gm PO daily) (1)<br>• Montelukast (10 mg PO daily) (1)<br>• Cromolyn sodium (100–135 mg PO 3–4 times daily) (1)<br>• Thalidomide (100 mg PO daily) (1)<br>• Ketotifen (1–2 mg PO daily) (2)<br>• Doxepin (10–20 mg PO daily) (1)<br>• Sertraline (25–100 mg PO daily) (2)<br>• Pentoxifylline (600 mg IV†) (3)<br>• Lidocaine (200 mg IV daily) (3)<br>• Erythropoietin (36 U/kg SC three times a week) (3)<br>• Cholestyramine (4–16 gm PO daily in divided doses) (2) |
| *†Typically administered post hemodialysis; daily or every other day administration of gabapentin/pregabalin has also been reported.*<br>**Kappa-opioid receptor agonist; available in Japan.* |

**eTable 4.2 Therapeutic ladder for renal pruritus.** In addition, the quality of dialysis should be evaluated and the parathyroid hormone (PTH) level assessed, with treatment of parathyroidism if present. Ondansetron was found to have no benefit over placebo in randomized controlled trials, and antihistamines have marginal efficacy. Acupuncture, omega-3 fatty acids supplementation, and oral turmeric have been reported to have benefit. Key to evidence-based support: (1) prospective controlled trial; (2) retrospective study or large case series; (3) small case series or individual case reports.

| TREATMENT OPTIONS FOR HEPATIC OR CHOLESTATIC PRURITUS | | |
|---|---|---|
| **1st line** | Cholestyramine* | • 4–16 gm PO daily<br>• Improvement may be temporary<br>• Only FDA-approved medication for cholestatic pruritus. |
| **1st line for ICP** | Ursodeoxycholic acid (ursodiol)* | • 13–15 mg/kg or 1 gm PO daily |
| **2nd line** | Rifampin* | • 300–600 mg PO daily (depending upon serum bilirubin level)<br>• Increases hepatic metabolism of bile salts |
| **3rd line** | Naloxone* | • 0.2 mcg/kg/min IV infusion, preceded by 0.4 mg IV bolus (continue treatment with oral naltrexone)<br>• μ-opioid receptor antagonist |
| | Naltrexone* | • 25 mg PO twice daily [day 1], then 50 mg PO daily<br>• μ-opioid receptor antagonist |
| | Nalfurafine* | • 2.5–5 mcg PO daily<br>• κ-opioid receptor agonist available in Japan |
| **4th line** | Sertraline* | • 50–100 mg PO daily<br>• Selective serotonin reuptake inhibitor |
| **Additional medical options** | | |
| Phototherapy | | • Especially broadband- or narrowband-UVB<br>• Can be used in combination with other treatments for an additive effect |
| Bright light therapy | | • 10,000 lux reflected toward the eyes for up to 60 minutes twice daily |
| Nalmefene* | | • Escalating twice daily PO dose: 2 mg [day 1], 5 mg [day 2], 10 mg [day 3], then 20 mg; further increases as needed to maximum of 120 mg<br>• μ-opioid receptor antagonist |
| Butorphanol nasal spray | | • 1–2 mg (1 to 2 puffs) daily<br>• κ-opioid receptor agonist and μ-opioid receptor antagonist |
| Ondansetron | | • 4–8 mg IV or 4–24 mg PO daily (equivocal effects in controlled studies)<br>• 5-$HT_3$ receptor antagonist |
| Paroxetine | | • 10–20 mg PO daily<br>• Selective serotonin reuptake inhibitor |
| Dronabinol | | • 5 mg PO nightly<br>• Cannabinoid B1 receptor agonist |
| Phenobarbital | | • 2–5 mg/kg PO daily |
| Stanozolol | | • 5 mg PO daily |
| Propofol* | | • 10–15 mg IV (bolus), 1 mg/kg/h (infusion) |
| Lidocaine | | • 100 mg IV daily |
| Thalidomide | | • 100 mg PO daily |
| **Procedural interventions** | | |
| Nasobiliary drainage | | • Quick relief of pruritus; possible complications include cholangitis and pancreatitis |
| Other methods to removal putative circulating pruritic factors | | • Plasmapheresis, plasma separation and anion adsorption<br>• Extracorporeal albumin dialysis (e.g. MARS [molecular adsorbents recirculating system]) |

**Benefit confirmed in controlled clinical trials.*

**eTable 4.3 Treatment options for hepatic or cholestatic pruritus.** Antihistamines have limited therapeutic benefit other than their sedating properties, and gabapentin did not have a therapeutic advantage over placebo in a controlled study. Ileal bile transporter inhibition (e.g. with GSK2330672) is currently under investigation and was shown to be of benefit for primary biliary cholangitis in a randomized controlled trial. ICP, intrahepatic cholestasis of pregnancy. *Modified from Kremer et al. Dig Dis 2014;32:637–45.*



A L G r a w a n y

| COMMON PHARMACOLOGIC ETIOLOGIES OF PRURITUS | |
|---|---|
| **Pathomechanism** | **Medication(s)** |
| Cholestasis | Chlorpromazine, erythromycin estolate, estrogens (including oral contraceptives), captopril, sulfonamides |
| Hepatotoxicity | Acetaminophen, anabolic steroids (including testosterone), isoniazid, minocycline, amoxicillin-clavulanic acid, halothane, phenytoin, sulfonamides |
| Sebostasis/xerosis | β-blockers, retinoids, tamoxifen, busulfan, clofibrate |
| Phototoxicity | 8-Methoxypsoralen |
| Neurologic | Tramadol, codeine, cocaine, morphine*,**, butorphanol*, fentanyl*, methamphetamine |
| Increased serotonin signaling | Selective serotonin reuptake inhibitors (e.g. sertraline, fluoxetine) |
| Increased bradykinin levels† | Angiotensin-converting enzyme (ACE) inhibitors |
| Increased leukotriene levels | NSAIDs |
| Histamine analogue | Betahistine |
| MRGPR§ stimulation | Chloroquine (pruritus may be generalized, localized to the hands/feet, or aquagenic; most common in individuals of African heritage) |
| T-cell activation due to CTLA-4 or PD-1 inhibition | Ipilimumab, nivolumab, pembrolizumab |
| EGFR inhibition | Panitumumab, gefitinib, cetuximab, erlotinib |
| Selective BRAF or MEK inhibition | Vemurafenib, dabrafenib, trametinib, cobimetinib |
| Other tyrosine kinase inhibition | Sorafenib (especially scalp pruritus), imatinib, dasatinib, nilotinib |
| Deposition | Hydroxyethyl starch |
| Idiopathic | Clonidine, gold salts, lithium, bleomycin |

**Pruritus is more likely with intrathecal/epidural than systemic administration.*
***Also causes non-immunologic release of histamine from mast cells.*
*†Pruritus may precede development of angioedema.*
*§MAS-related G protein-coupled receptor expressed by epidermal C-nerve fibers.*

**eTable 4.4 Common pharmacologic etiologies of pruritus.** Itch may also occur as a direct effect of interleukin 2 therapy. CTLA-4, cytotoxic T lymphocyte-associated antigen 4; PD-1, programmed cell death protein 1.

| ISSVD TERMINOLOGY AND CLASSIFICATION OF VULVAR PAIN |
|---|
| **Vulvar pain related to a specific disorder** |
| • Infectious (e.g. candidiasis, HSV infection, herpes zoster)<br>• Inflammatory (e.g. lichen planus, immunobullous disorders)<br>• Neoplastic (e.g. Paget disease, squamous cell carcinoma)<br>• Neurologic (e.g. herpes neuralgia, spinal nerve compression) |
| **Vulvodynia** |
| **Localized (vestibulodynia, clitorodynia, hemivulvodynia, etc.)** |
| • Provoked (sexual, non-sexual, or both)<br>• Unprovoked<br>• Mixed (provoked and unprovoked) |
| **Generalized (dysesthetic vulvodynia)** |
| • Provoked (sexual, non-sexual, or both)<br>• Unprovoked<br>• Mixed (provoked and unprovoked) |

**eTable 4.5 International Society for the Study of Vulvovaginal Disease (ISSVD) terminology and classification of vulvar pain (2003).**

# 5 Psychocutaneous Disorders

## Introduction

- Psychodermatology refers to any aspect of dermatology in which psychological factors play a significant role.
- Psychodermatologic disorders can be classified in two ways: (1) by the specific psychodermatologic condition or (2) by the underlying psychopathology (Fig. 5.1).
- Treatment is simplified by basing the choice of psychotropic medication or therapy on the underlying psychopathology (Table 5.1).
- The more commonly encountered primary psychiatric disorders in dermatology include body dysmorphic disorder, excoriation (skin-picking) disorder, acne excoriée, trichotillomania, other body-focused repetitive behavior disorders (BFRBD), delusions of parasitosis, dermatitis artefacta, and nonsuicidal self-injury.
- Because many of these patients with primary psychiatric disorders present to the dermatologist and not the psychiatrist, it is important to establish the correct diagnosis and to offer appropriate treatment options.

## The More Common Primary Psychiatric Disorders Seen in Dermatology

### Obsessive–Compulsive and Related Disorders: General Features

- *Obsessions* are recurrent and persistent thoughts, images, or urges that are intrusive and unwanted.
- *Compulsions* are repetitive behaviors or mental acts that are performed in order to reduce anxiety or distress, especially that arising from obsessions.
- In all of these disorders, the preoccupations and/or behaviors lead to significant distress or impairment in social, occupational, or other areas of functioning.
- Some of these conditions feature *body-focused repetitive behaviors (BFRB;* e.g. hair-pulling, skin-picking; Table 5.2, Fig. 5.2).
- BFRB become *disorders* (BFRBD) when the following criteria are met: (1) the repetitive behavior causes skin lesions; (2) there are repeated attempts to decrease or stop the behavior; (3) the behavior causes significant distress or impaired functioning; (4) there is no other underlying medical condition or mental disorder to explain the behavior.

#### BODY DYSMORPHIC DISORDER

- Characterized by a distressing or impairing preoccupation with a nonexistent or slight defect in appearance.
- On a psychiatric spectrum from obsessional to delusional.
- Mean age of onset is 30–35 years; females = males; present in up to 10–15% of dermatologic patients.
- Patients usually concerned with nose, mouth, hair, breasts, or genitalia.
- Often adopt compulsive (e.g. numerous visits to physician for reassurance), ritualistic (e.g. excessive grooming routines), or delusional (e.g. multiple unnecessary surgeries) behaviors.
- Consider and assess for this diagnosis in patients seeking multiple cosmetic procedures.
- **Rx:** selective serotonin reuptake inhibitors (SSRIs) for obsessive–compulsive disorder (OCD) variant or antipsychotics for delusional variant.

#### EXCORIATION (SKIN-PICKING) DISORDER

- Previously known as "*neurotic excoriations*;" categorized in DSM-5™ as a BFRBD characterized by a conscious, repetitive, and uncontrollable desire to pick, scratch or rub the skin, resulting in skin lesions.

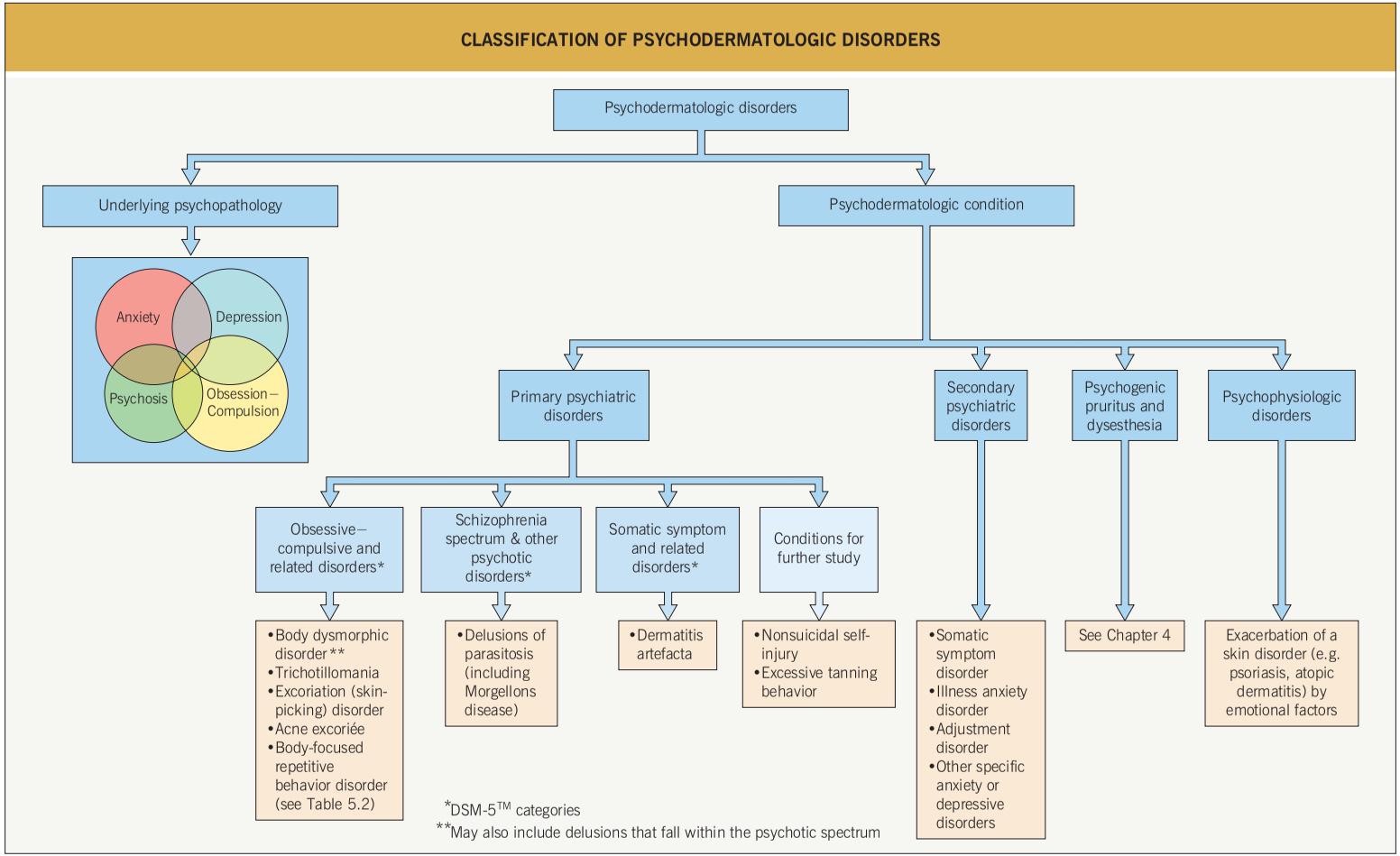


**Fig. 5.1 Classification of psychodermatologic disorders.**

**PSYCHOTROPIC MEDICATIONS MOST COMMONLY USED IN DERMATOLOGY**

**Treatment of procedural anxiety in adults (prior to procedure)**

**Benzodiazepines**
Diazepam: 10 mg orally 30 minutes prior
Alprazolam: 0.5 mg orally 30–60 minutes prior
Lorazepam: 2 mg orally 30–60 minutes prior

- An approximate 50% dose reduction necessary for older (age >60) or debilitated adults, patients with low cardiac output or hepatic insufficiency
- Repeated dose, 50–100% of initial dose, may be repeated in 30–60 minutes if initial dose has no effect
- Patients must have a driver to take them home

**Treatment of obsessive compulsive disorder (OCD)**

**Selective serotonin reuptake inhibitors (SSRIs) (in addition to cognitive behavioral therapy)**

| SSRI | Initial dose | Maximum dose (via weekly dose escalation**) |
|---|---|---|
| Fluoxetine | 10–20 mg/day | 60 mg/day* |
| Citalopram | 10–20 mg/day | 40 mg/day** |
| Paroxetine | 10–20 mg/day | 50 mg/day |
| Sertraline | 25–50 mg/day | 200 mg/day |
| Escitalopram | 10 mg/day | 20 mg/day** |

- Clinical response may take 6–10 weeks to become apparent
- Children, adolescents and young adults should be closely monitored for any suicidal ideation
- N-acetylcysteine (up to 2400 mg/day) alone, or in combination with SSRIs has shown promise in treating OCD

**Treatment of delusions of parasitosis**

**Antipsychotics**
Pimozide: initiate at 0.5–1 mg/day and gradually (every 2–4 weeks) titrate up to 2–6 mg/day, if needed
Risperidone: initiate at 0.5 mg/day and titrate up to 1–4 mg/day, if needed
Olanzapine: initiate at 2.5 mg/day and gradually titrate up to 5–15 mg/day, if needed

- Response is often seen after ~2 weeks and treatment should be continued for several months, followed by gradual tapering
- Side effects include extrapyramidal symptoms, QTc prolongation (significant risk, pimozide; moderate risk, risperidone); tardive dyskinesia (pimozide, if prolonged use); metabolic syndrome (risperidone, olanzapine), weight gain (olanzapine), and hyperprolactinemia (risperidone). Baseline ECG recommended (pimozide) if history of arrythmia or cardiac conduction abnormalities.

**Make dose adjustments after several weeks of therapy*
***Higher doses associated with QTc prolongation*

**Table 5.1 Psychotropic medications most commonly used in dermatology.**

- On a psychiatric spectrum most closely related to OCD but may also be an expression of generalized anxiety disorder or depression.
- Most common in middle-age; females > males.
- Favors scalp, face, upper back, extensor forearms, shins, buttocks.
- Lesions usually in all stages of evolution: erosions (prurigo simplex) (Fig. 5.3A), deep circular or linear ulcerations with hypertrophic borders, hypo- or hyperpigmented scars (Fig. 5.3B); admixed well-healed scars point to chronicity.
- **DDx:** (1) underlying causes of pruritus (see Ch. 4); (2) underlying primary cutaneous disorder (e.g. folliculitis); (3) stereotypic movement disorders.
- **Rx:** symptomatic treatment of pruritus (topicals, oral antihistamines); tricyclic antidepressants (TCAs) or SSRIs (if underlying depression); SSRIs (if underlying OCD); consultation with a psychiatrist.

### ACNE EXCORIÉE

- Considered a subset of excoriation (skin-picking) disorder, characterized by ritualistic picking of acne lesions (Fig. 5.4).

| BODY-FOCUSED REPETITIVE BEHAVIORS (BFRBs) AND ASSOCIATED MUCOCUTANEOUS FINDINGS | |
|---|---|
| **Body-focused repetitive behavior** | **Associated mucocutaneous findings** |
| Lip licking | Irritant contact dermatitis, secondary bacterial or yeast infections |
| Lip picking or biting | Multiple erosions or ulcerations, recurrent HSV |
| Cheek chewing or biting | Bite fibroma, morsicatio buccarum |
| Cuticle pulling, picking, or biting (see Fig. 5.2) | Paronychia, nail surface irregularities |
| Nail biting (onychophagia) (see Fig. 5.2) | Paronychia, nail dystrophy, subungual hemorrhages |
| Nail picking or pulling (onychotillomania) | |
| Habit-tic deformity of the thumbnail | Multiple midline Beau's lines with prominent longitudinal central depression |
| Thumb or finger sucking | Skin maceration, dermatitis, secondary bacterial or yeast infections |
| Nose picking (rhinotillexomania) | Erosions, secondary bacterial infections |
| Trichotillomania | See text |
| Excoriation (skin-picking) disorder | See text |

**Table 5.2 Body-focused repetitive behaviors (BFRBs) and associated mucocutaneous findings.** BFRBs occur on a chronic basis and present with characteristic mucocutaneous findings, depending on the body site and behavior type. These behaviors exist along a spectrum, with habits at one end and body-focused repetitive behavioral disorders (BFRBD) at the other end. The latter disorders continue despite repeated attempts to stop, and lead to impaired functioning (e.g. social, occupational) or to distress manifesting as feelings of loss of control, embarrassment, or shame.



**Fig. 5.2 Body-focused repetitive behaviors.** Sequelae of nail biting (onychophagia) and cuticle picking. *Courtesy, Karynne O. Duncan, MD.*

- Often associated with OCD; most common in young females.
- **Rx:** aggressively treat underlying acne; TCAs or SSRIs (if underlying depression); SSRIs (if underlying OCD); consultation with a psychiatrist.

### TRICHOTILLOMANIA

- Categorized in DSM-5™ as a BFRBD characterized by the recurrent pulling out of one's hair, resulting in hair loss.
- In dermatologic practice, often see cases of hair pulling that are on a spectrum from inattentive habitual hair pulling to obvious OCD psychopathology (BFRBD).
- Most helpful to approach the patient by age of onset, in terms of discussing prognosis and treatment.
  - ***Preschool onset:*** typically benign course; most children outgrow the habit; **Rx** involves bringing awareness to parents and patient
  - ***Pre-adolescent to young adult onset:*** more chronic, relapsing course; on a spectrum from habit/unawareness to underlying psychopathology; **Rx** includes bringing awareness, behavioral modification therapy, psychotropic medications as necessary
  - ***Adult onset:*** more protracted course; often due to underlying psychopathology; **Rx** most often entails referral to psychiatrist/psychologist and treatment of underlying psychiatric disorder
- Peak onset ages 8–12 years; females > males.
- Most commonly scalp hair, but also eyebrows, eyelashes, or pubic hair.

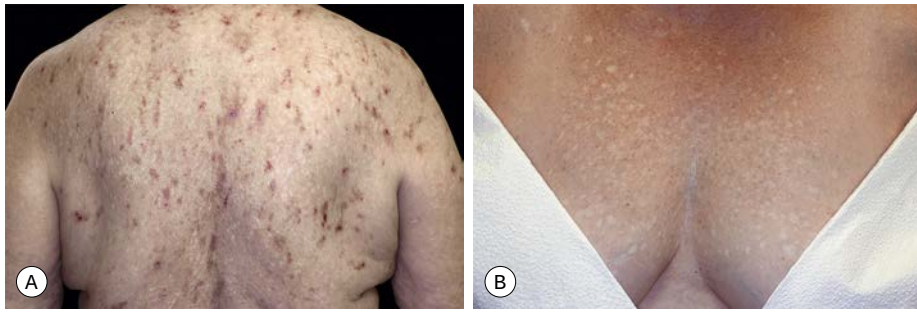

**Fig. 5.3 Excoriation (skin-picking) disorder. A** Multiple linear excoriations and prurigo simplex lesions on the back of this woman who picked at her skin for several hours each day, often using a kitchen table knife on her back. **B** Numerous hypopigmented scars on the chest of this woman from years of extensive skin picking. *Courtesy, Karynne O. Duncan, MD.*



**Fig. 5.4 Acne excoriée.** This patient compulsively picked at his acne lesions. *Courtesy, Richard Odom, MD.*



**Fig. 5.5 Trichotillomania.** Classic findings with small areas of sparing. *Courtesy, John Koo, MD.*

- Classically see hairs of varying lengths distributed within the area of alopecia; uninvolved areas are normal (Fig. 5.5).
- Sometimes associated ritualistic behavior or trichophagy.
- **DDx:** other causes of non-scarring alopecia (e.g. alopecia areata, tinea capitis).
- A helpful diagnostic test is the "clipped hair square," in which a small section of hair is clipped close to the scalp with scissors; in trichotillomania the hairs (being too short to pull out) display uniform hair regrowth.
- **Rx:** behavioral modification is primary treatment; psychosocial support; SSRIs; case reports of olanzapine, N-acetylcysteine (1200–2400 mg/day for adults) or inositol being helpful.

## Schizophrenia Spectrum and Other Psychotic Disorders

### DELUSIONS OF PARASITOSIS

- A *somatic type of delusional disorder* (within the broad group of *schizophrenia spectrum and other psychotic disorders*) in which patients have the isolated, fixed, false belief (delusion) that their skin is infested with parasites, despite any objective evidence of an infestation.
- DSM-5™ criteria for diagnosis include the following: (1) delusion has been present for ≥1 month; (2) patient has no other impaired functioning or bizarre behavior apart from the impact of the delusion; (3) the delusion cannot be attributed to the effects of a substance, medication, medical condition or other psychiatric disorder.



**Fig. 5.6 Delusions of parasitosis.** Samples of alleged "parasites" brought in by a patient ("matchbox sign"). *Courtesy, Kalman Watsky, MD.*

- Typical onset is in the mid 50s–60s.
- Patients often bring in bits of skin, lint, and other specimens to prove the existence of the supposed parasites (Fig. 5.6).
- Often experience cutaneous sensations of crawling, biting, and/or stinging.
- Skin findings, which are self-induced, range from none to excoriations, lichenification, prurigo nodularis, and ulcerations.
- **DDx:** true formication (tactile hallucination involving the sensation of bugs crawling or biting the skin) related to alcohol withdrawal or other drugs (e.g. amphetamines, cocaine), a medical condition (e.g. neurologic disorder), or other psychiatric disorder (e.g. schizophrenia).
- A recent investigation by the Centers for Disease Control and Prevention supported the categorization of Morgellons disease as a form of delusions of parasitosis; hallmark of Morgellons is that patients claim to observe "fibers" exuding from their skin.
- **Rx:** establish rapport with patient first; do not challenge their delusional belief; antipsychotics (see Table 5.1).

## Somatic Symptom and Related Disorders

### DERMATITIS ARTEFACTA

- A type of factitious disorder within the broad DSM-5™ category of somatic symptom and related disorders.
- Characterized by self-inflicted lesions as a means to satisfy a psychological need that is not consciously understood; self-denial.
- Rare disorder; many patients suffer from borderline personality disorder; may have underlying depression and/or anxiety.
- Onset typically in adolescence or young adulthood; females >> males.
- Lesions often appear in easy-to-reach areas and appear in bizarre shapes and configurations; may employ outside instruments (Fig. 5.7).
- **DDx:** (1) primary dermatologic disorder; (2) delusions of parasitosis; (3) malingering (conscious gain); (4) nonsuicidal self-injury (patients acknowledge they injured themselves); (5) factitious disorder imposed on another (previously called Munchausen syndrome by proxy).
- **Rx:** symptomatic treatment of wounds; psychosocial support; psychotropic medications tailored to underlying psychopathology.

## Other/Conditions for Further Study

### NONSUICIDAL SELF-INJURY (CUTTING)

- Repeated infliction of shallow injuries to the surface of the body, typically via cutting, stabbing or burning; often a sharp object (e.g. knife or razor), cigarette, or eraser is employed.
- No suicidal intent; purpose is usually to reduce negative emotions or to resolve an interpersonal difficulty; patients will admit to this behavior but often will not seek help.
- Often associated with depression, anxiety and sometimes with borderline personality disorder.
- Onset is typically in early adolescence; female : male ratio is about 1.5 : 1.
- Most common sites of involvement are the dorsal hands/arms and anterior thighs; lesions present as an admixture of linear erosions or well-healed scars (Fig. 5.8), often in an array of parallel lines (likened to "railroad ties"); some individuals will cut words into their skin; with time, the cutting will typically escalate to more frequent and numerous lesions.
- Unexplained, recurrent "cuts and scratches" on the forearms and legs of adolescents should arouse suspicion for this behavior.
- **DDx**: in contrast to dermatitis artefacta, patients acknowledge that they inflicted the lesions upon themselves.
- **Rx:** familial and psychological support; treatment of underlying psychopathology.

For further information see Ch. 7 from *Dermatology, Fourth Edition*.

**For additional online figures visit www.expertconsult.com**




**Fig. 5.7 Dermatitis artefacta. A** Lesions in multiple stages of evolution, from circular, crusted erosions to "bizarre-shaped" erosions on the mid-shin to hyperpigmented scars. This teenage girl denied knowing how the lesions developed or having any role in the process. **B** Scars from cigarette burns. **C** Erosions in different stages of healing. *A, Courtesy, YDRSC; B, Courtesy, Ronald P. Rapini, MD; C, Courtesy, Antonio Torrelo, MD.*



**Fig. 5.8 Nonsuicidal self-injury.** Repeated episodes of self-cutting with a razor blade caused these hypopigmented scars on the dorsal hand and forearm of this young woman. *Courtesy, Karynne O. Duncan MD.*

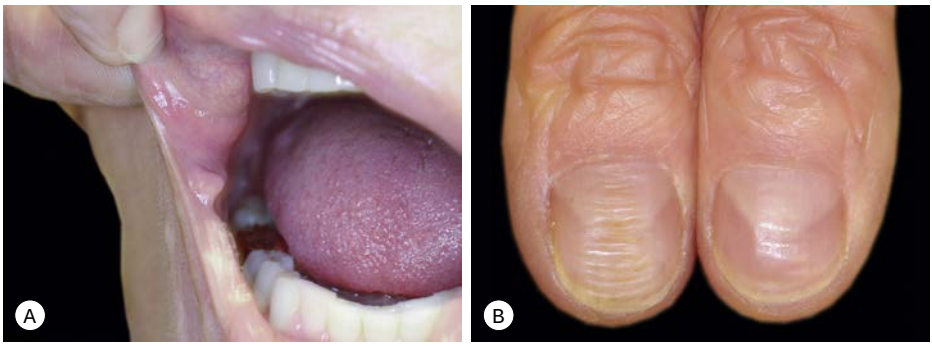


**eFig. 5.1 Body-focused repetitive behaviors. A** Bite fibroma from years of cheek chewing. **B** Habit-tic deformity of the thumbnail. *Courtesy, Karynne O. Duncan, MD.*

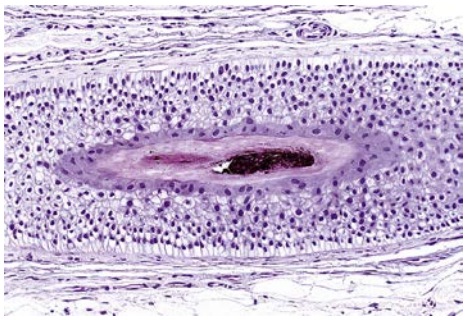

**eFig. 5.2 Histopathology of trichotillomania.** Pigmented follicular cast. *Courtesy, Ronald P. Rapini, MD.*

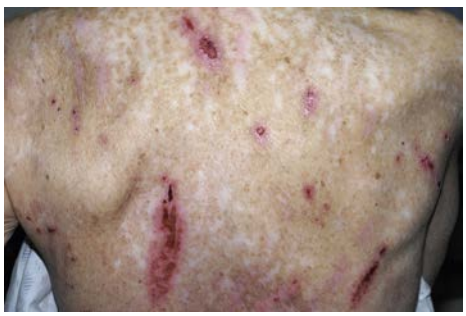

**eFig. 5.3 Delusions of parasitosis.** Multiple excoriations and hypopigmented scars resulting from the patient's attempts to "dig out" parasites. *Courtesy, Kalman Watsky, MD.*



A L G r a w a n y

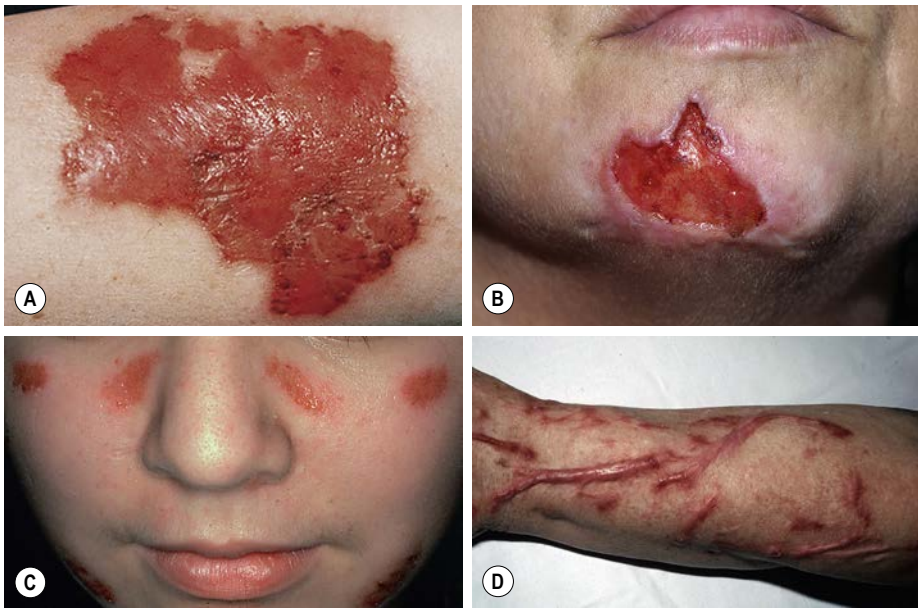


**eFig. 5.4 Dermatitis artefacta. A, B** Erosions and ulcer with "bizarre" shapes and angulated borders, possibly created with sharp instruments. **C** Symmetric erosions on the cheeks of an adolescent girl. **D** Unusual, linear, hypertrophic scars resulting from self-carving with a sharp instrument. These patients all denied knowing how the lesions had developed or having any role in the process. *A, Courtesy, John Koo, MD; B, Courtesy, Kalman Watsky, MD; C, Courtesy, YDRSC; D, Courtesy, M. Joyce Rico, MD.*

# Psoriasis 6

## Key Points

- Affects up to 2% of the population.
- Chronic disorder in those with a polygenic predisposition combined with triggering factors such as infections (especially streptococcal infection, but also HIV infection) or medications (e.g. interferon, β-blockers, lithium, or oral CS taper).
- Koebner phenomenon – elicitation of psoriatic lesions by traumatizing the skin.
- Common sites (Fig. 6.1)
  - Scalp
  - Elbows and knees
  - Nails, hands, feet, trunk (intergluteal fold)
- Skin lesions
  - Most commonly – well-demarcated, erythematous plaques with silvery scale (Fig. 6.2)
  - Other lesions include sterile pustules, glistening plaques in intertriginous zones
- Histopathologic findings
  - Regular acanthosis, confluent parakeratosis with neutrophils, hypogranulosis, dilated blood vessels (see Ch. 1)
- Major systemic association is psoriatic arthritis (Table 6.1), most commonly presenting as asymmetric oligoarthritis of hands/feet; the metabolic syndrome is also common.
- Pathogenesis
  - Regarded as a T-cell-driven disease involving cytokines, including TNF-α and IL-23 (stimulates Th17 cells)
  - Genes that have been associated with psoriasis include those encoding IL-12, IL-23, caspase recruitment domain family member 14 (CARD14, a regulator of NF-κB signaling) and, for generalized pustular psoriasis, the IL-36 receptor antagonist (a regulator of IL-8 production and IL-1β responses)

## Variants

### Chronic Plaque Psoriasis

- Typical lesion – well-demarcated, erythematous plaque with silvery scale.
- Often symmetrical lesions on the elbows and knees; additional sites include the scalp, presacrum, hands, feet, intergluteal fold, and umbilicus (Fig. 6.3, Fig. 6.4, Fig. 6.5).
- May be generalized (Fig. 6.6).
- Lesions may be surrounded by a peripheral, blanching ring (Woronoff's ring), especially when patient is receiving phototherapy.
- **DDx:** *for lesions on the elbows/knees* – dermatomyositis, pityriasis rubra pilaris (in children); *for truncal lesions* – various forms of dermatitis including nummular, parapsoriasis, mycosis fungoides, subacute cutaneous lupus erythematosus, drug-induced psoriasiform eruptions; *for palmoplantar lesions* (see Fig. 13.1 and Table 13.1) – tinea, keratotic eczema.

### Guttate Psoriasis

- Typical lesion – small papule or plaque (3 mm to 1.5 cm) with adherent scale (Fig. 6.7).
- Generalized distribution.
- Affects children > adults.
- Often preceded by an upper respiratory tract infection.
- In children, may have spontaneous remission but often responds well to UVB phototherapy.
- **DDx:** pityriasis rosea, syphilis, id reaction to tinea pedis, and small plaque parapsoriasis.

### Linear Psoriasis

- Linear, erythematous, scaly lesions that often follow the lines of Blaschko.
- **DDx:** inflammatory linear verrucous epidermal nevus (ILVEN; follows the lines of Blaschko; resistant to therapy), epidermal nevus with superimposed psoriasis.

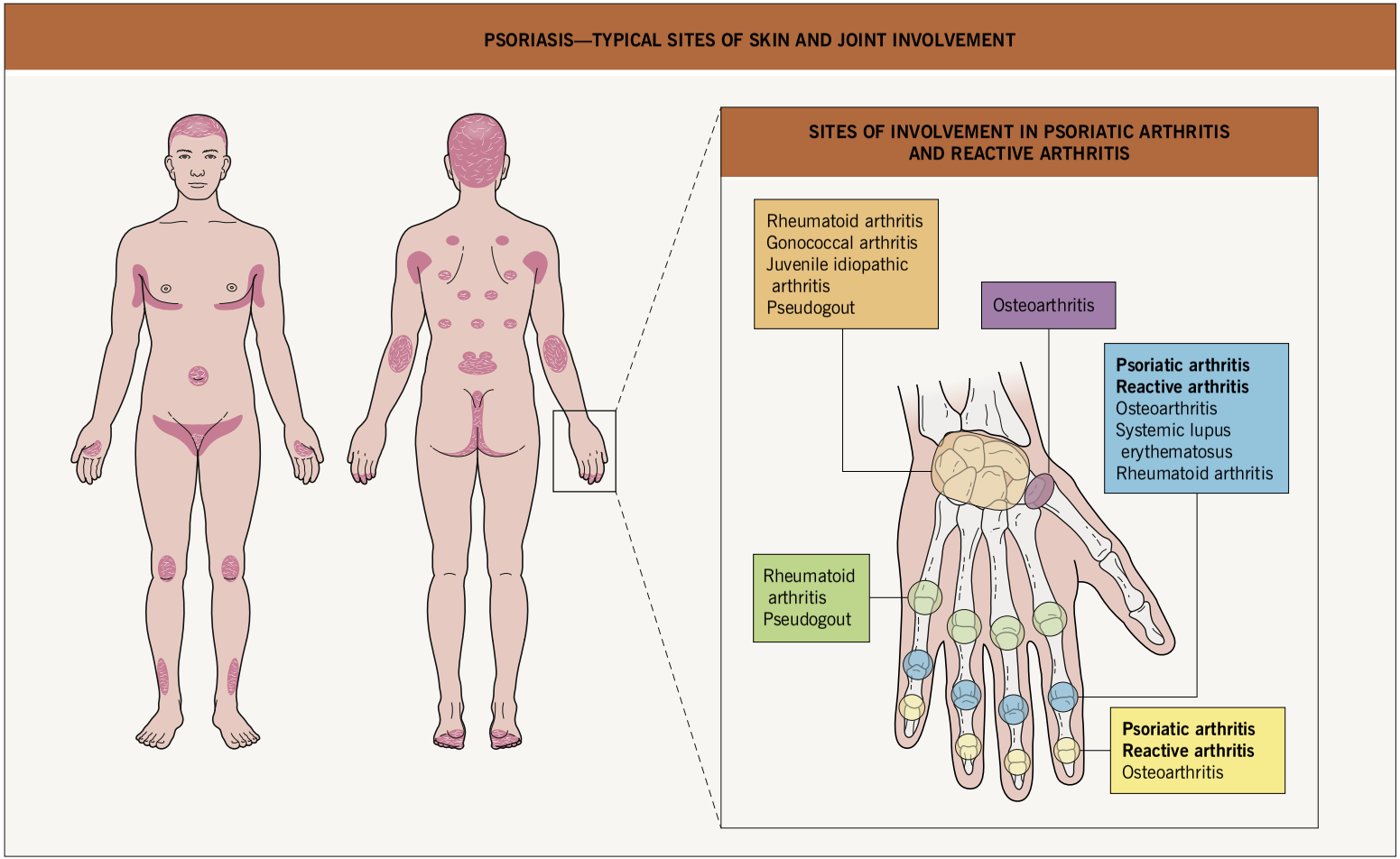


**Fig. 6.1 Psoriasis – typical sites of skin and joint involvement.**

| FIVE TYPES OF PSORIATIC ARTHRITIS |
|---|
| • Mono- and asymmetric oligoarthritis |
| • Arthritis of distal interphalangeal joints |
| • Rheumatoid arthritis-like presentation |
| • Arthritis mutilans |
| • Spondylitis and sacroiliitis |

**Table 6.1 Five types of psoriatic arthritis.**



**Fig. 6.2 Psoriatic plaques.** Note the sharp demarcation and silvery scale. *Courtesy, Julie V. Schaffer, MD.*

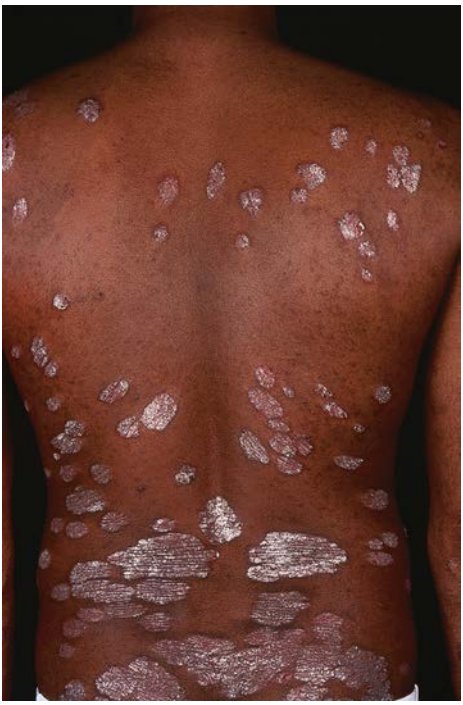

**Fig. 6.3 Symmetric distribution of psoriatic plaques.** *Courtesy, Peter C. M. van de Kerkhof, MD.*

## Erythrodermic Psoriasis

- Generalized erythema of the skin, with areas of scaling.
- Gradual or acute onset.
- Nail changes, facial sparing, and a history of typical plaque-type psoriasis may be helpful clues.
- May be seen after abrupt tapering of medications, especially CS.
- **DDx:** other causes of erythroderma, e.g. pityriasis rubra pilaris, generalized atopic dermatitis, Sézary syndrome (see Table 8.2).

## Pustular Psoriasis

- Generalized pustular psoriasis (von Zumbusch pattern)
  - Erythema and sterile pustules arising within erythematous, painful skin; lakes of pus characteristic (Fig. 6.8)
  - Often associated fever
  - Triggering factors – pregnancy (termed impetigo herpetiformis), rapid tapering of CS, hypocalcemia, infections
  - **DDx:** acute generalized exanthematous pustulosis (AGEP; pustular drug reaction) (see Ch. 17)
- Palmoplantar (pustulosis)
  - Sterile pustules on palms/soles (Fig. 6.9)
  - May have no evidence of psoriasis elsewhere
  - Triggering factors – infections, stress
  - May be aggravated by smoking
  - Associated with inflammatory bone lesions (see Ch. 21)
- Annular pattern (Fig. 6.10)
  - **DDx:** includes Sneddon–Wilkinson disease (see below)
- Exanthematic type
  - Significant overlap with AGEP
- Localized pattern – within plaques, often due to irritants (Fig. 6.11).
- Acrodermatitis continua (of Hallopeau)
  - Erythema and scale of distal digit with pustules (Fig. 6.12)
  - Often associated fever




**Fig. 6.4 Palmoplantar psoriasis.** Erythematous scaling plaques of the palmar **(A)** and plantar surfaces **(B)**. Occasionally, there is well-demarcated hyperkeratosis with minimal erythema **(C)**. *A, Courtesy, Peter C. M. van de Kerkhof, MD; B, Courtesy, YDRSC.*

## Special Sites

### Scalp

- Well-demarcated, erythematous plaques with silvery scale.
- Scale may be attached for some distance onto scalp hairs, giving an asbestos-like appearance (pityriasis amiantacea).
- Occasionally alopecia may be seen within lesions.
- **DDx:** seborrheic dermatitis (more diffuse pattern), tinea capitis, dermatomyositis.

### Flexural (Inverse Psoriasis)

- Shiny, pink, well-demarcated thin plaques with minimal scale (Fig. 6.13).
- Common sites include the axilla, inguinal crease, intergluteal cleft, inframammary area, and retroauricular fold.
- Sebopsoriasis – seborrheic dermatitis and psoriasis are at either ends of a spectrum, with intermediate forms termed sebopsoriasis.
- Additional **DDx:** seborrheic dermatitis, candidiasis, tinea cruris, erythrasma, granular parakeratosis (see Fig. 13.4).

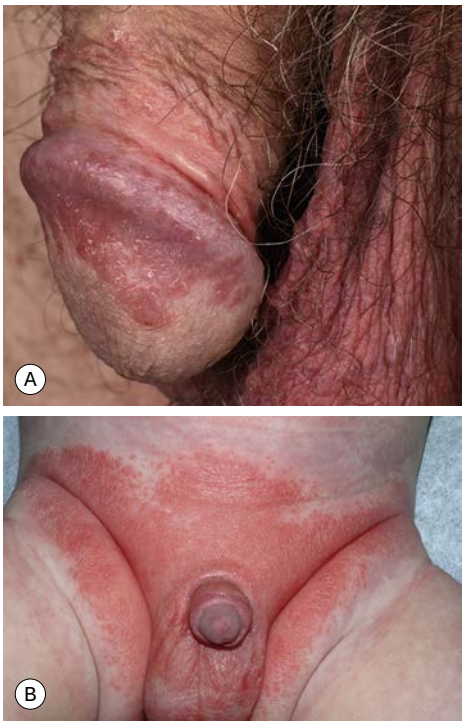


**Fig. 6.5 Psoriasis of the genitalia. A** Well-demarcated erythematous plaques with scale on the glans and shaft of the penis in an adult. **B** Infantile psoriasis with a well-demarcated erythematous plaque of the diaper area, along with involvement of the penis and scrotum. This is in contrast to atopic dermatitis where there is often sparing of the diaper area. *A, Courtesy, Lorenzo Cerroni, MD; B, Courtesy, Julie V. Schaffer, MD.*

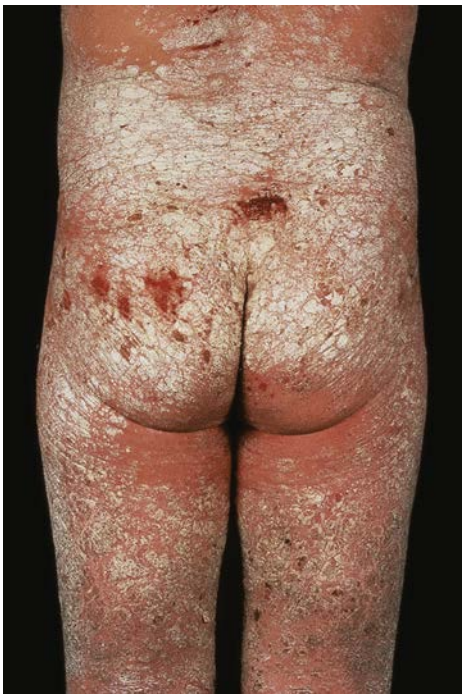

**Fig. 6.6 Widespread chronic plaque psoriasis.** *Courtesy, Peter C. M. van de Kerkhof, MD.*



**Fig. 6.7 Guttate psoriasis.** Small discrete papules and plaques of guttate psoriasis. *Courtesy, Christine J. Ko, MD.*

### Oral

- Migratory, annular lesions with central denuded areas and white borders.
- Similar to geographic tongue clinically and histopathologically.

### Nail (see Ch. 58)

- Fingernails > toenails (Fig. 6.14).
- Associated with psoriatic arthritis.
- Findings include nail pitting, oil spots (salmon patch), onycholysis with proximal red rim, splinter hemorrhages, subungual debris.

## Sneddon–Wilkinson Disease (Subcorneal Pustular Dermatosis)

- Often begins in body folds or major intertriginous zones.
- Lesions are annular with superficial pustules on the border.
- Classic sign is a half and half pustule with clear fluid superiorly and pus inferiorly (dependent portion).
- Two schools of thought – this disease is (1) a variant of psoriasis vs (2) a separate entity (Fig. 6.15).



**Fig. 6.8 Pustular psoriasis.** Large areas of erythema with numerous pustules. Confluence of pustules creates lakes of pus. *Courtesy, Julie V. Schaffer, MD.*

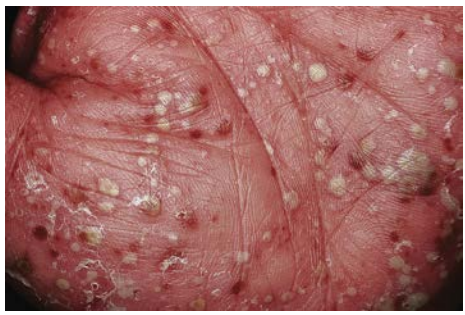

**Fig. 6.9 Pustulosis of the palms and soles.** Multiple sterile pustules are admixed with yellow-brown macules on the palm. *Courtesy, YDRSC.*



**Fig. 6.10 Annular pustular psoriasis.** Multiple annular inflammatory plaques studded with pustules. *Courtesy, Julie V. Schaffer, MD.*



**Fig. 6.11 Scalp psoriasis with extension onto the neck.** Note the involvement of the external auditory canal. *Courtesy, Peter C. M. van de Kerkhof, MD.*

## Psoriatic Arthritis

- Seen in 5–30% of patients with cutaneous psoriasis.
- Most commonly is an asymmetric oligoarthritis affecting the distal, or both proximal and distal ("sausage"), interphalangeal joints (Fig. 6.16).
- More rarely, but classically, is arthritis of all the distal interphalangeal joints of the fingers.
- Occasionally, presentation is rheumatoid arthritis-like, affecting small- and medium-sized joints symmetrically.
- Arthritis mutilans – rare form with acute, rapidly progressive joint inflammation and destruction; softening and telescoping of the digits.
- Spondylitis and sacroiliitis – axial arthritis as well as arthritis of the knees and sacroiliac joints; may be HLA-B27-positive and may have associated inflammatory bowel disease or uveitis.
- **DDx:** reactive arthritis (previously referred to as Reiter disease)
  - Urethritis, arthritis, ocular findings (e.g., conjunctivitis), and oral ulcers in addition to psoriasiform lesions, especially on the soles (keratoderma blennorrhagicum) or genitalia (balanitis circinata) (Fig. 6.17)
  - More common in men
  - Strongly associated with HLA-B27
  - Course is often self-limited
  - May be severe in HIV-positive individuals (see Table 6.1)

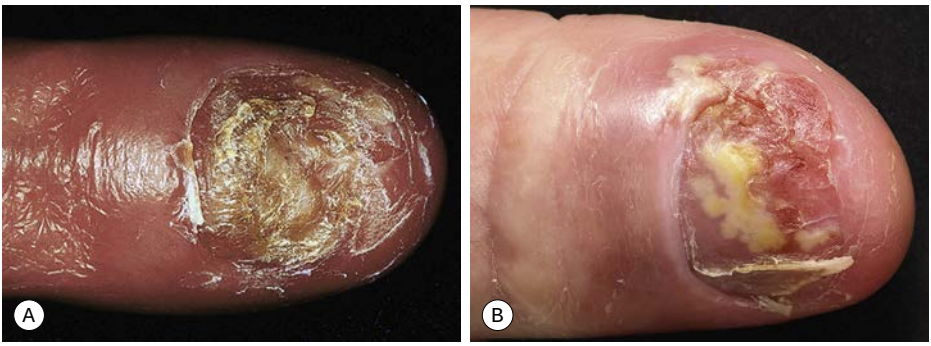


**Fig. 6.12 Acrodermatitis continua (of Hallopeau). A, B** Erythema and scale of the distal digit, pustules within the nail bed, and partial shedding of the nail plate. *A, Courtesy, YDRSC; B, Courtesy, Peter C. M. van de Kerkhof, MD.*



**Fig. 6.13 Inverse psoriasis.** Shiny erythematous plaques of the inframammary folds that lack scale. *Courtesy, Luis Requena, MD.*



**Fig. 6.14 Nail psoriasis.** Changes include distal onycholysis, pitting, and "oil spot" (salmon patch) phenomenon.




**Fig. 6.15 Sneddon–Wilkinson disease.**
**A** Annular and polycyclic plaques in the axilla.
**B** Numerous, fragile, subcorneal pustules arising within a background of erythema. There is dependent pooling of the pustular contents in some of the larger lesions. There is significant overlap with pustular psoriasis. *A, Courtesy, YDRSC; B, Courtesy, Department of Dermatology, Medical University of Graz.*

## Treatment

- Topical agents
  - First-line
    - CS (Table 6.2)
    - Vitamin $D_3$ analogues (calcipotriene [calcipotriol], calcitriol) (Table 6.3)
  - Second-line
    - Calcineurin inhibitors (may be first-line for sensitive areas such as the face or flexures)
    - Tars (e.g. liquor carbonis detergens [LCD] 5%)
    - Anthralin
    - Tazarotene
- Phototherapy and systemic agents
  - First-line
    - Phototherapy – UVB (narrowband or broadband > PUVA) (Table 6.4); if thick keratotic plaques, can combine with oral retinoids. Oral PUVA – 0.6–0.8 mg/kg of 8-methoxypsoralen (MOP) orally 1–3 hours before light exposure; bath PUVA – 0.5–5 mg of 8-MOP/liter of bath water with immediate irradiation after soaking for 15–20 minutes; topical PUVA (e.g. for palms/soles) – 8-MOP 0.1–0.01% cream/ointment/lotion followed by UVA irradiation
    - Methotrexate (oral or intramuscular, occasionally subcutaneous) (Table 6.5)



**Fig. 6.16 Psoriatic arthritis.** Asymmetric involvement of the distal interphalangeal (DIP) and proximal interphalangeal (PIP) joints. A "sausage" digit (third digit bilaterally) results from involvement of both the DIP and PIP joints. *Courtesy, YDRSC.*




**Fig. 6.17 Reactive arthritis (formerly Reiter disease). A, B** Plantar lesions of keratoderma blennorrhagicum. **C** Papulosquamous lesions of balanitis circinata on the penis. *A, C, Courtesy, YDRSC; B, Courtesy, Eugene Mirrer, MD.*

| INDICATIONS AND CONTRAINDICATIONS FOR TOPICAL CORTICOSTEROIDS |
|---|
| **Indications** |
| • Mild to moderate psoriasis: first-line treatment as monotherapy or in combination<br>• Severe psoriasis: often in combination with a vitamin $D_3$ analogue, a topical retinoid, anthralin, or tar<br>• Monotherapy for flexural and facial psoriasis (usually mild strength)<br>• Recalcitrant plaques often require occlusion (plastic, hydrocolloid) |
| **Contraindications** |
| • Bacterial, viral, and mycotic infections<br>• Atrophy of the skin<br>• Allergic contact dermatitis due to corticosteroids or constituents of the formulation<br>• Pregnancy or lactation* |
| **Relative; can consider limited use of mild- to moderate-strength corticosteroids.* |

**Table 6.2 Indications and contraindications for topical corticosteroids.** Maximal quantities: 50 gm/week of a superpotent corticosteroid; 100 gm/week of a potent corticosteroid. *Courtesy, Peter C. M. van de Kerkhof, MD.*

| INDICATIONS AND CONTRAINDICATIONS FOR VITAMIN $D_3$ ANALOGUES |
|---|
| **Indications** |
| • Mild to moderate psoriasis: first-line treatment as monotherapy or in combination<br>• Severe psoriasis: combination treatment |
| **Contraindications** |
| • Involvement requiring more than the maximally recommended quantity, e.g. 100 gm/week of calcipotriene<br>• Abnormality in bone or calcium metabolism*<br>• Renal insufficiency<br>• Allergy to the vitamin $D_3$ analogue or constituents of the preparation<br>• Pregnancy or lactation |
| **For example, sarcoidosis and bone metastases.* |

**Table 6.3 Indications and contraindications for vitamin $D_3$ analogues.** If used in conjunction with phototherapy, vitamin $D_3$ preparations need to be applied after UV irradiation or at least several hours prior, because they may reduce UV penetration into the skin. *Courtesy, Peter C. M. van de Kerkhof, MD.*

  - Oral retinoids (e.g. acitretin, isotretinoin)
- Second-line systemic
  - Targeted immunomodulators ("biologic" agents) (Tables 6.6 and 6.7)
  - Cyclosporine

- See Table 6.8 for treatment options for special sites.
- See Table 6.9 for treatment options in patients with comorbidities or special situations.
- See Appendix for the recommended laboratory evaluation for patients receiving targeted immunomodulators.

For further information see Ch. 8 from *Dermatology, Fourth Edition*.

**For additional online figures visit www.expertconsult.com**



A L G r a w a n y

| INDICATIONS AND CONTRAINDICATIONS FOR PHOTOTHERAPY |
|---|
| **Indications** |
| • Moderate to severe psoriasis: first-line treatment as monotherapy or in combination |
| **Contraindications (absolute or relative)** |
| • Genetic disorders characterized by increased photosensitivity or an increased risk of skin cancer (UVB and PUVA)* |
| • Skin type I (UVB and PUVA)† |
| • Photosensitive dermatoses (UVB and PUVA)† |
| • Unavoidable phototoxic systemic or topical medications (UVB and PUVA)† |
| • Vitiligo (UVB and PUVA)† |
| • Previous history of arsenic exposure, ionizing irradiation, or excessive phototherapy (UVB and PUVA) |
| • High cumulative number of PUVA treatments, i.e. >150–200 individual treatments (PUVA)* |
| • Treatment with cyclosporine (UVB and PUVA)* |
| • Immunosuppressive medication (UVB and PUVA) |
| • Previous history of skin cancers (PUVA > UVB) |
| • Atypical melanocytic nevi (UVB and PUVA) |
| • Seizure disorder (risk of fall/injury; UVB and PUVA) |
| • Poor compliance (UVB and PUVA) |
| • Men and women in reproductive years without contraception (PUVA) |
| • Pregnancy or lactation (PUVA)* |
| • Impaired liver function or hepatotoxic medication (PUVA) |
| • Cataracts (PUVA) |
| **Absolute contraindication.* |
| *†Need to adjust the dose and monitor closely.* |

**Table 6.4 Indications and contraindications for phototherapy.** *Courtesy, Peter C. M. van de Kerkhof, MD.*

## Supplementary Figures

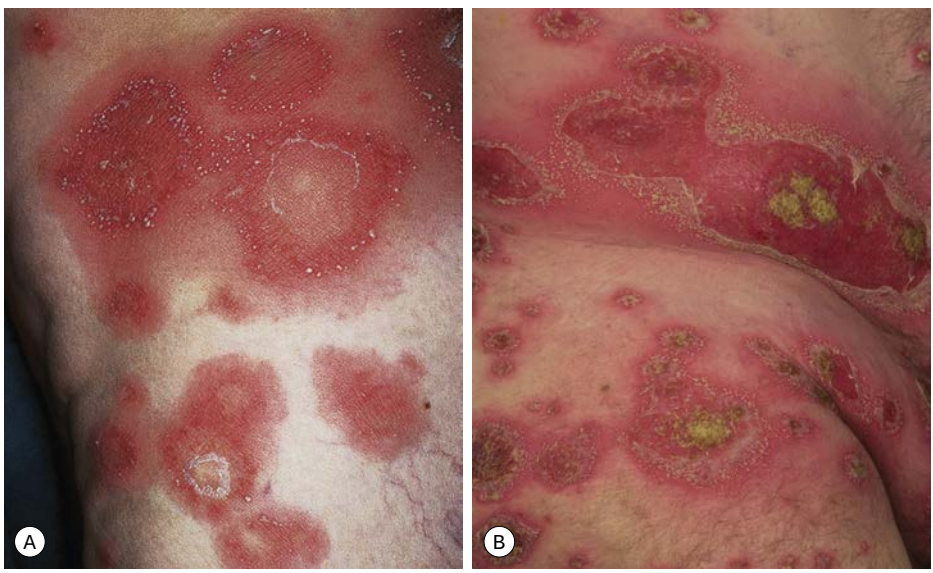


**sFig. 6.1 Annular pustular psoriasis.** Multiple annular inflammatory plaques studded with pustules. As the lesions enlarge, there can be central clearing, dry desquamation **(A)**, and/or moist desquamation that resembles wet cigarette paper **(B)**. *A, Courtesy, YDRSC; B, Courtesy, Peter C. M. van de Kerkhof, MD.*

| INDICATIONS AND CONTRAINDICATIONS FOR METHOTREXATE (MTX) |
|---|
| **Indications** |
| • Severe psoriasis<br>• Chronic plaque psoriasis (>10–15% BSA or interference with employment or social functioning)<br>• Pustular psoriasis (generalized or localized)<br>• Erythrodermic psoriasis<br>• Psoriatic arthritis (moderate to severe)<br>• Severe nail psoriasis<br>• Psoriasis not responding to topical treatments, phototherapy, and/or systemic retinoids |
| **Contraindications (absolute or relative)** |
| • Impaired kidney function (creatinine clearance <60 ml/min)‡<br>• Severe anemia, leukopenia, and/or thrombocytopenia*<br>• Significant liver function abnormalities, hepatitis (active and/or recent), severe fibrosis, cirrhosis, excessive alcohol intake*<br>• Concomitant hepatotoxic medications<br>• Concomitant medications that increase MTX levels, e.g. trimethoprim–sulfamethoxazole*<br>• Significantly reduced pulmonary function*<br>• Pregnancy or lactation*<br>• Currently planning to have children (male and female patients)‡<br>• Immunodeficiency syndromes<br>• Severe infections*<br>• Active infections<br>• Peptic ulcer (active)*<br>• Gastritis<br>• Concomitant radiation therapy<br>• Pleural effusion or ascites‡<br>• Hypersensitivity to MTX*<br>• Unreliable patient* |
| **Absolute contraindication.*<br>*†Requires significant reduction in dosage.*<br>*‡Because of possible mutagenic risk and teratogenicity, discontinue MTX 3 months prior to attempts to conceive; continue contraception during these 3 months.* |

**Table 6.5 Indications and contraindications for methotrexate (MTX).** *Courtesy, Peter C. M. van de Kerkhof, MD.*

| COMMERCIALLY AVAILABLE BIOLOGIC AGENTS FOR THE TREATMENT OF PSORIASIS | | |
|---|---|---|
| **Target** | | **Biologic agents (estimated % of patients who achieve PASI75)** |
| TNF | | Etanercept (30–60), adalimumab (50–80), infliximab (75–85) |
| IL-12/IL-23 | p40 subunit of IL-12/IL-23 | Ustekinumab (65–80) |
| | IL-23 | Guselkumab (80–90) |
| IL-17 | | Secukinumab (65–85), ixekizumab (85–90), risankizumab (63–98), tildrakizumab (61–66), brodalumab (60–85) |

**Table 6.6 Commercially available biologic agents for the treatment of psoriasis.** Biosimilar products, e.g. adalimumab-atto, etanercept-szzs, infliximab-dyyb, are also commercially available. PASI, psoriasis area severity index.

| FDA WARNINGS AND PRECAUTIONS FOR TARGETED IMMUNE MODULATORS USED FOR PSORIASIS |
|---|
| **TNF inhibitors** |
| • Increased risk of serious infections, including tuberculosis, bacterial sepsis, systemic fungal infections (e.g. histoplasmosis), and infections due to opportunistic pathogens |
| • Risk of hepatitis B virus reactivation |
| • Malignancies (especially lymphomas) have been reported in patients receiving these agents, including children and adolescents<br>– For infliximab, lymphomas are seen more often than in the general population and fatal hepatosplenic T-cell lymphomas have developed in patients with inflammatory bowel disease who were also receiving azathioprine or 6-mercaptopurine<br>– An increased risk of non-melanoma skin cancer and melanoma has been observed in patients with rheumatoid arthritis treated with TNF inhibitors |
| • Congestive heart failure (exacerbation or new onset) has been observed |
| • Demyelinating disease (exacerbation or new onset) has been observed |
| • Anaphylaxis or severe allergic reactions can occur, including serum sickness-like reactions to infliximab |
| • Other potential adverse events include autoimmune hepatitis, cytopenias, and a lupus-like syndrome |
| **IL-12/IL-23 inhibitors** |
| • Serious infections have been observed; may increase the risk of infection and reactivation of latent infections |
| • Patients genetically deficient in IL-12/IL-23 have an increased risk of severe infections with mycobacteria and *Salmonella* |
| • BCG vaccination should not be given in the year prior to initiation or the year following completion of ustekinumab therapy |
| • Could potentially increase the risk of malignancies |
| • Hypersensitivity reactions (e.g. angioedema, anaphylaxis) can occur |
| • Reversible posterior leukoencephalopathy syndrome has been reported |
| **IL-17 inhibitors** |
| • Serious infections have been observed; may increase the risk of infection and reactivation of latent infections<br>– Patients genetically deficient in IL-17 are prone to chronic mucocutaneous candidiasis |
| • New onset and exacerbation of inflammatory bowel disease have occurred |
| • Hypersensitivity reactions (e.g. angioedema, anaphylaxis) can develop |
| • For brodalumab: suicidal ideation and behavior, including complete suicides, have occurred |

**Table 6.7 US Food and Drug Administration (FDA) warnings and precautions for targeted immune modulators used for psoriasis.** Live vaccines should not be given to patients receiving these medications. BCG, bacillus Calmette-Guérin.



**sFig. 6.2 Psoriasis of the genitalia.** Erythematous plaques with scale on the penis and scrotum. Courtesy Peter Gary, MD.



**sFig. 6.3 Inverse psoriasis.** Shiny erythematous plaques in the axilla that lack scale.



Downloaded for Noor Ibrahim (noorbibrahim@yahoo.com) at United Arab Emirates University from ClinicalKey.com by Elsevier on

| MANAGEMENT OF PSORIASIS AT SPECIFIC SITES | |
|---|---|
| **Specific sites** | **Special considerations and practical treatments** |
| Scalp | • Remove scale with topical 5–10% salicylic acid |
| | • Apply potent or ultrapotent corticosteroids in a lotion, gel foam or shampoo formulation, either alone or in combination with calcipotriene |
| Face; groin, axilla, and other body folds | • First-line: mild topical corticosteroids |
| | • Second-line: topical calcineurin inhibitors or tacalcitol/calcitriol in combination with a mild topical corticosteroid |
| Nail | • Differentiate proximal versus distal nail unit pathology due to nail matrix versus nail bed pathology, respectively; consider coexisting onychomycosis |
| | • For distal nail unit pathology: vitamin $D_3$ analogues topically (limited evidence) |
| | • For proximal pathology: intralesional corticosteroids and/or systemic antipsoriatic therapies |

**Table 6.8 Management of psoriasis at specific sites.** These sites do improve with systemic therapies, but involvement of these sites alone is usually not a sufficient indication for a systemic therapy. *Courtesy, Peter C. M. van de Kerkhof.*



**sFig. 6.4 "Localized" pattern of pustular psoriasis.** The pustules are limited to pre-existing plaques of psoriasis. *Courtesy, YDRSC.*



**sFig. 6.5 Guttate psoriasis.** Numerous papules due to the Koebner phenomenon after a sunburn. *Courtesy Ronald P. Rapini, MD.*

| PREFERRED TREATMENTS FOR PSORIASIS IN THE SETTING OF COMORBIDITIES | | | | | | | | |
|---|---|---|---|---|---|---|---|---|
| **Comorbidity or special situation** | **Topical therapies** | | **Phototherapy** | **Systemic therapies** | | | | |
| | Corticosteroids | Other topical agents | | Apremilast† | Retinoids | MTX†,^ | CSA* | Immunomodulators ("biologics")** |
| Liver disease | ✓ | ✓ | ✓ (UVB) | ✓ | | | | ✓ |
| Hepatitis B viral infection | ✓ | ✓ | ✓ (UVB) | ✓ | | | | ✓ (IL-17 inhibitors considered safer)<br>Test for anti-HBc Ab, HBsAg; if latter +, measure HBV DNA<br>Consult gastroenterologist re HBV pretreatment |
| Hepatitis C viral infection | ✓ | ✓ | ✓ (UVB) | ✓ | | | | ✓ (TNF inhibitors > IL-17 or IL-23 inhibitors)<br>Test for anti-HCV Ab, HCV RNA to assess need for HCV treatment |
| Metabolic syndrome | ✓ | ✓ | ✓ | ✓ | ✓^ | ✓^ | ✓ | ✓ (infliximab and ustekinumab are dosed by weight) |
| Latent tuberculosis infection | ✓ | ✓ | ✓ | ✓ | ✓ | | | ✓ (IL-17 inhibitors considered safer)<br>Consult for pretreatment with INH |
| HIV/AIDS, well-controlled | ✓ | ✓ | ✓ (UVB) | ✓ | ✓ | | | ✓Co-management with infectious disease specialist |
| Pregnancy | ✓ (mild to moderate strength) | ✓ can use certain topicals with caution (e.g. anthralin, calcipotriene) | ✓ (UVB) | | | | ✓ (pregnancy category C) | ✓ (consider TNF inhibitors*** [especially certolizumab given minimal placental transfer], ustekinumab***, IL-17 inhibitors [e.g. secukinumab***], IL-23 inhibitors)<br>Co-management with gynecologist |

| | | | | | | | | |
|---|---|---|---|---|---|---|---|---|
| History of internal malignancy (e.g. lymphoma, lung cancer) | ✓ | ✓ | ✓ (UVB) | ✓ | ✓ | | | Consult with oncologist |
| History of frequent skin cancers | ✓ | ✓ (vitamin $D_3$ analogues, retinoids) | | ✓ | ✓ | | | |

*†Renal dysfunction requires a dose adjustment.*
**Contraindicated for patients with renal dysfunction.*
***TNF inhibitors are relatively contraindicated in lupus erythematosus patients; IL-17 inhibitors should be avoided in patients with inflammatory bowel disease (Crohn disease and ulcerative colitis).*
*^Used with caution in patients with non-alcoholic steatohepatitis.*
****Pregnancy category B.*

**Table 6.9 Preferred treatments for psoriasis in the setting of comorbidities.** INH, isoniazid.



**sFig. 6.6 Nail psoriasis.** Changes include distal onycholysis, pitting, and "oil spot" (salmon patch) phenomenon. *Courtesy, YDRSC.*



**sFig. 6.7 Nail psoriasis.** Nail plate pitting, distal onycholysis, oil drop changes, and subungual and proximal hyperkeratosis are seen. There is also proximal nail-fold inflammation with loss of the cuticle, especially of the forefingers. *Courtesy, Marcel C. Pasch, MD.*



**sFig. 6.8 Childhood psoriasis.** The scalp is a common site of involvement and psoriasis is distinguished by its sharp demarcation. *Courtesy, Julie V. Schaffer, MD.*



**eFig. 6.1 Guttate psoriasis.** Small discrete papules and plaques of guttate psoriasis in an adolescent; note the Koebner phenomenon. *Courtesy, YDRSC.*

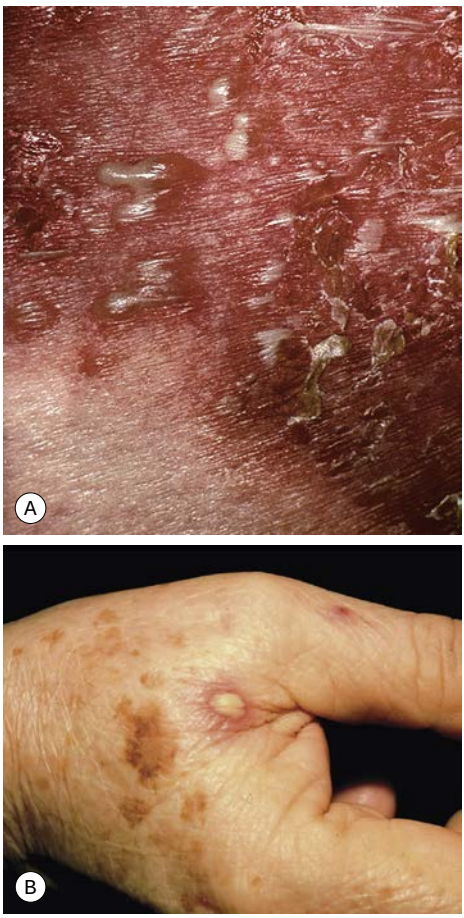


**eFig. 6.2 Sneddon–Wilkinson disease.** **A** Subcorneal pustules with scale and crusts as well as background erythema. **B** Discrete pustule with an erythematous rim. *A, Courtesy, YDRSC; B, Courtesy, Joyce Rico, MD.*



**eFig. 6.3 Annular plaques of psoriasis due to central clearing.** *Courtesy, Julie V. Schaffer, MD.*







**eFig. 6.4 Psoriatic plaques. A, B** Note the sharp demarcation and silvery scale. These plaques are in commonly involved sites. *B, Courtesy, Lorenzo Cerroni, MD.*



**eFig. 6.5 Multiple large plaques of psoriasis.** There is obvious symmetry of the plaques on the upper extremities. Some patients have associated pruritus and hemorrhagic crusts due to scratching. *Courtesy, Luis Requena, MD.*



**eFig. 6.6 Guttate psoriasis.** Numerous, small, discrete papules with scale on the thighs. *Courtesy, Kalman Watsky, MD.*



**eFig. 6.7 Annular pustular psoriasis.** Multiple annular inflammatory plaques whose active borders are studded with pustules followed by desquamation. As these lesions enlarge, there is central clearing. The intensity of erythema can vary and the color is influenced by the skin phototype. *A, Courtesy, Marieke M. B. Seyger, MD, PhD.*

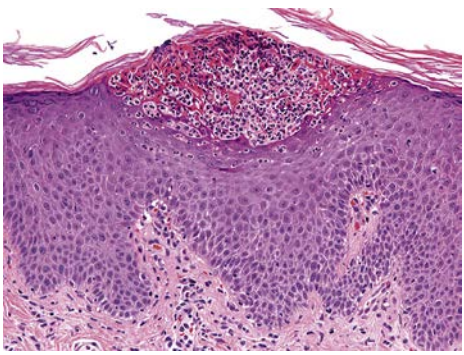

**eFig. 6.8 Spongiform pustule of Kogoj.** A collection of neutrophils is seen within the upper stratum spinosum. *Courtesy, Lorenzo Cerroni, MD.*

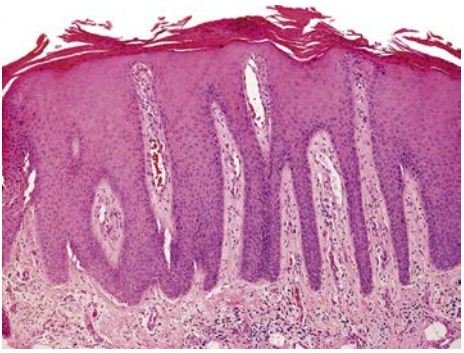

**eFig. 6.9 Stable plaque psoriasis.** Hyperplasia of the epidermis with "squared-off" rete ridges, elongation of the dermal papillae, dilated superficial blood vessels, hypogranulosis, and parakeratosis plus remnants of neutrophils (microabscess of Munro). *Courtesy, Lorenzo Cerroni, MD.*



**eFig. 6.10 Psoriatic plaque.** Note the sharp demarcation and silvery scale. *Courtesy, YDRSC.*

# 7 Other Papulosquamous Disorders

## Parapsoriasis

- Chronic, usually asymptomatic patches or thin plaques with fine scale whose color varies from pink to red-brown; may have associated epidermal atrophy and occasionally poikiloderma (large plaque parapsoriasis).
- Two major forms of parapsoriasis are small plaque (lesions usually <5 cm in diameter) and large plaque (usually >5 cm); digitate dermatosis is a form of the former, whereas retiform parapsoriasis is a variant of the latter (Figs 7.1 and 7.2).
- While the distribution may be limited or more generalized, there is a tendency for an increase in extent over time; large plaque parapsoriasis can favor the sun-protected "girdle" area; both forms usually occur in adults.
- Controversy exists regarding the percentage of cases of large plaque parapsoriasis that eventually evolve into mycosis fungoides.
- Histologically, parakeratosis and nonspecific spongiotic dermatitis is seen in small and large plaque; large plaque may have a more lichenoid infiltrate.
- An infiltrate of $CD4^+$ T lymphocytes, often clonal, in large plaque > small plaque parapsoriasis, leading to the term "clonal dermatitis".
- **DDx:** small plaque – pityriasis rosea (PR), PR-like drug eruption, pityriasis lichenoides chronica, guttate psoriasis, secondary syphilis; large plaque parapsoriasis – patch stage mycosis fungoides (MF), MF-like drug eruption; if a few lesions, consider tinea corporis.
- **Rx:** topical CS, sunlight, phototherapy (e.g. NB-UVB).

## Pityriasis Lichenoides et Varioliformis Acuta (PLEVA) and Pityriasis Lichenoides Chronica (PLC)

- PLEVA, also known as Mucha–Habermann disease, and PLC exist along a clinicopathologic spectrum such that patients can have characteristic lesions of both disorders, either concurrently or in tandem.
- In both forms, there are recurrent crops of papules with individual lesions spontaneously resolving over weeks (PLEVA) to months (PLC); only occasionally is there an obvious trigger (e.g. viral infection, medication); the entire course of the disorder can last for years.
- PLEVA occurs more commonly in younger age groups; it is characterized by widespread erythematous papules that are often crusted but may be vesicular or pustular (Fig. 7.3A–C).
- The onset of PLEVA can be abrupt, and recurrences typically occur for months to years; there is an unusual ulcerative form that is accompanied by fever, lymphadenopathy, arthritis, and mucosal involvement.
- PLC is characterized by pink to red-brown papules with scale and can resolve with postinflammatory guttate hypopigmentation (Fig. 7.3D, E).
- Histologically, parakeratosis, an interface dermatitis with necrotic keratinocytes, and extravasation of red blood cells are seen; the infiltrate is composed of T cells that are often monoclonal; in PLEVA, the infiltrate may be wedge-shaped and neutrophils may be seen.
- **DDx:** PLEVA – varicella or other viral exanthem, e.g. coxsackievirus, disseminated zoster without a dermatome (more limited duration), lymphomatoid papulosis (often fewer larger lesions), arthropod reactions, small vessel vasculitis; PLC – small plaque parapsoriasis, pityriasis rosea, secondary syphilis, guttate psoriasis, lichen planus.
- **Rx:** topical CS, prolonged courses of antibiotics (e.g. erythromycin, tetracyclines), phototherapy (e.g. NB-UVB); severe cases may require methotrexate in consultation with a dermatologist.




**Fig. 7.1 Small plaque parapsoriasis.** **A** Small (<5 cm), dull pink, slight scaly patches on the trunk. **B** Digitate dermatosis with elongated finger-like lesions on the flank that are pink-brown to yellow-brown in color. Digitate dermatosis is the exception to the 5-cm rule as the lesions may measure 10 cm or more along their long axes. *A, Courtesy, Lorenzo Cerroni, MD; B, Courtesy, Gary Wood, MD, and George Reizner, MD.*

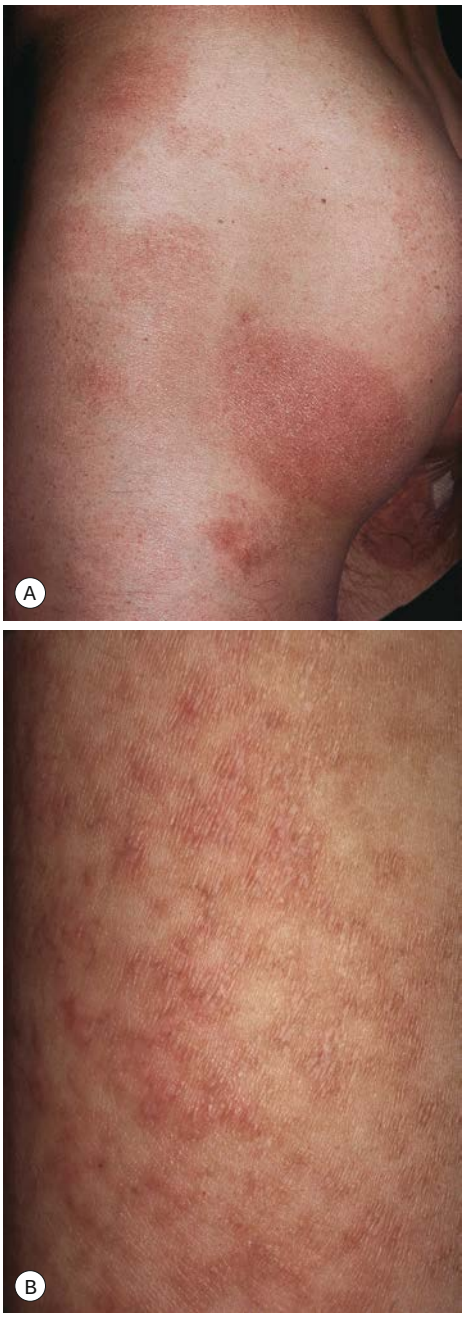


**Fig. 7.2 Large plaque parapsoriasis.** **A** Large, variably erythematous patches in the bathing trunk region – a classic clinical presentation. **B** Retiform parapsoriasis with pink-brown lesions forming a net-like pattern, hence the term retiform; note the associated wrinkling due to epidermal atrophy. *A, B, Courtesy, YDRSC.*




**Fig. 7.3 Clinical spectrum of pityriasis lichenoides.** In the acute form (PLEVA), widespread erythematous papules and papulovesicles are admixed with crusted lesions **(A, B)**; sometimes there can be an ulcerative component **(C)**. Lesions can heal with varioliform scars. Individuals with the chronic form (PLC) develop multiple red-brown papules, some of which have scale **(D)**; these lesions often heal with hypopigmentation, especially in patients with darkly pigmented skin **(E). F** A number of patients will have lesions characteristic of both PLEVA and PLC. *A, Courtesy, Julie V. Schaffer, MD; B, Courtesy, Thomas Schwarz, MD; C, D, Courtesy, YDRSC; E, Courtesy, Antonio Torrelo, MD; F, Courtesy, Kalman Watsky, MD.*




**Fig. 7.4 Pityriasis rosea – herald patches in two patients with different skin phototypes.** **A, B** A herald patch typically precedes the development of a more widespread eruption. Either central or peripheral white scale can be seen. *A, Courtesy, Kalman Watsky, MD; B, Used with permission of the Mayo Foundation for Medical Education and Research.*

## Pityriasis Rosea

- Occurs more commonly in adolescents and young adults; in general, individuals are healthy and have no systemic complaints/symptoms (see Table 1.7).
- The etiology is unknown, but viral infections may serve as a trigger.
- Lesions increase in number and extent over a few weeks but then spontaneously resolve; classically, the initial lesion, known as the "herald patch," is often the largest (Fig. 7.4).
- The distribution is that of a 1920s bathing suit – proximal extremities and trunk; occasionally, an inverse pattern is seen in which the majority of lesions are in the axillae and/or groin (Fig. 7.5).
- Pink to salmon-colored papules or plaques are round or oval in shape (Fig. 7.6), with their long axes following Langer's lines of cleavage (Fig. 7.7), creating a "Christmas tree" pattern on the trunk; scale, both fine white centrally and as a collarette at the edge of the lesion, is the most common secondary change, but occasionally crusting, vesicles, purpura, or even pustules may be seen.
- The average duration is 6–8 weeks, with some cases lasting for months.
- Histologically, mounds of parakeratosis are seen, accompanied by spongiosis and a mild perivascular and interstitial lymphocytic infiltrate; extravasation of red blood cells may occur.
- **DDx:** guttate psoriasis, secondary syphilis (preceding chancre, usually genital; accompanied by malaise, lymphadenopathy, other mucocutaneous signs such as condylomata lata, palmoplantar lesions; and positive Venereal Disease Research Laboratory [VDRL] or rapid plasma reagin [RPR] test), pityriasis lichenoides chronica (especially if persistent), nummular dermatitis (if vesicular), pityriasis rosea-like drug eruptions (e.g. ACE inhibitors, metronidazole).
- **Rx:** topical anti-pruritic lotions or CS (for the minority of patients with associated pruritus), natural sunlight, 14-day course of erythromycin, 10-day course of azithromycin, NB-UVB.



**Fig. 7.5 Inverse pityriasis rosea.** In this variant, the lesions are limited to the pelvic region and/or axillae. The long axes of the lesions follow the lines of cleavage. *Courtesy, Julie V. Schaffer, MD.*

## Pityriasis Rubra Pilaris (PRP)

- One of the dermatologic disorders that can lead to an erythroderma (Fig. 7.8), often with an onset in the head and neck region; peaks of incidence – first to second decade of life and sixth decade of life.




**Fig. 7.6 Pityriasis rosea. A, B** Both round and oval-shaped plaques can be seen as well as fine white scale and collarettes of scale. **C** In patients with more darkly pigmented skin, central hyperpigmentation can develop and there may be a more follicular pattern. *A, Courtesy, YDRSC; B, Courtesy, Julie V. Schaffer, MD; C, Courtesy, Aisha Sethi, MD.*

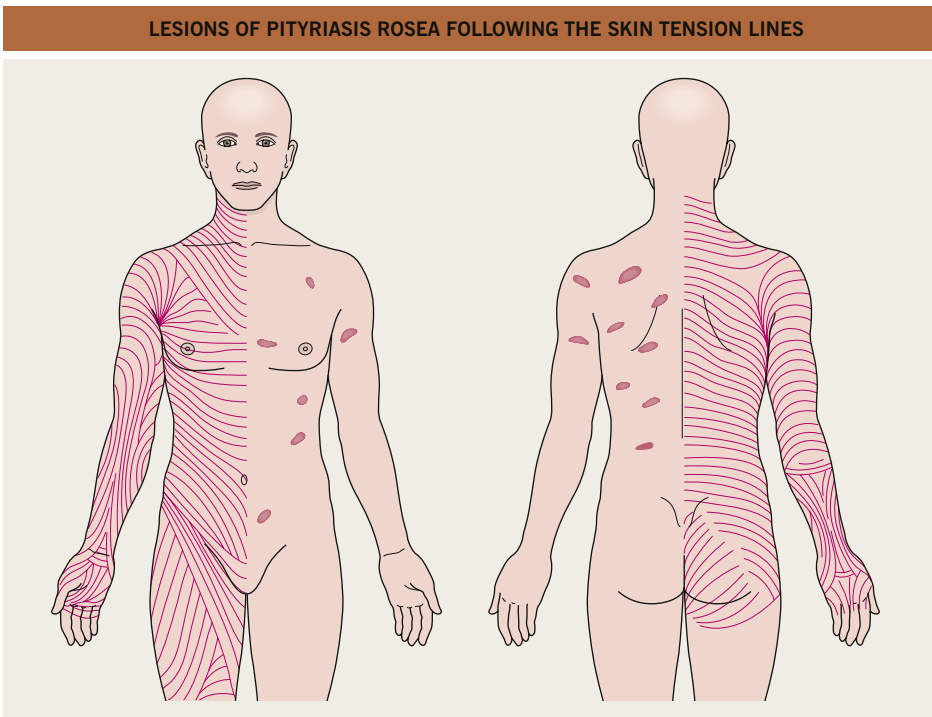


**Fig. 7.7 Lesions of pityriasis rosea following the skin tension lines.** These lines are often referred to Langer's lines of cleavage. The long axis of the individual lesions aligns with these lines.

- It is characterized by a salmon or orange-red color, islands of sparing, follicular papules (including within the relatively spared areas and on the dorsal fingers), and a waxy keratoderma (Fig. 7.9).
- May be exacerbated by exposure to UV irradiation and rarely triggered by medications (e.g. tyrosine kinase inhibitors); classic forms spontaneously resolve within 3–5 years.
- Five major forms plus an HIV-associated type have been described, with distinctions based on age of onset and distribution, with the adult classic form being the most common (Figs 7.10 and 7.11); occasionally PRP is familial and can be due to *CARD14* mutations.
- Histologically, there is alternating ortho- and parakeratosis, both vertically and horizontally, within the stratum corneum (checkerboard pattern); additional findings are follicular plugging with a shoulder of parakeratosis, acantholysis within the epidermis, and variable inflammation.
- **DDx:** other causes of erythroderma, in particular psoriasis and Sézary syndrome (see Table 8.2), and an unusual form of dermatomyositis seen more often in Asians (Wong type); in children, also progressive symmetric erythrokeratoderma; early on, seborrheic dermatitis.
- **Rx:** oral isotretinion, acetretin, methotrexate, TNF inhibitors (mixed results); response should be seen within 6 months.

## Pityriasis Rotunda

- Seen primarily in the Far East, Mediterranean basin, and Africa; favors individuals with darker skin phototypes.
- Large, asymptomatic, circular and polycyclic patches with scale that are often hyperpigmented; the lesions are also well demarcated and lack inflammation clinically, occurring on the trunk and extremities.
- Associated with malnutrition and secondarily with internal malignancies or systemic infections; occasionally, familial, especially in Caucasians.
- Histologically, resembles ichthyosis vulgaris with hyperkeratosis and a reduced granular layer.
- **DDx:** leprosy, large plaque parapsoriasis, tinea corporis, tinea versicolor.



**Fig. 7.8 Erythroderma due to pityriasis rubra pilaris.** Within areas of erythema, follicular hyperkeratosis (knee) may be more difficult to appreciate than in areas of relative sparing (compare to Fig. 7.9A). *Courtesy, YDRSC.*

## Granular Parakeratosis

- Originally described in the axillae of adults (primarily women), but can involve other intertriginous zones and in infants, the diaper area.
- Red-brown plaques with scale, often thick, that may be related to chronic irritation (Fig. 7.12); there may be secondary maceration and pruritus.
- Diagnostic histopathologic findings of marked compact parakeratosis with retained keratohyaline granules within the stratum corneum.
- **DDx:** other causes of intertrigo (e.g. seborrheic dermatitis, inverse psoriasis, candidiasis), irritant or allergic contact dermatitis, erythrasma, Hailey–Hailey disease.
- **Rx:** discontinuation of topical irritants (e.g. mineral salt-containing crystals used as "natural" deodorants, biodegradable diapers), mild topical CS.

For further information see Ch. 9 from *Dermatology, Fourth Edition*.




**Fig. 7.9 Pityriasis rubra pilaris. A** Orange-red follicular papules with coalescence into large scaly plaques, in addition to islands of sparing; follicular hyperkeratosis is often easier to appreciate within the relatively spared islands. **B** On the dorsal aspects of the digits, clustered keratotic follicular papules can resemble a "nutmeg grater". **C, D** The islands of sparing may be rather sharply demarcated; note the salmon color of the plaques. **E** Waxy keratoderma, again with an orange hue. **F** Orange-red keratotic follicular papules. *A, Courtesy, YDRSC; B, Courtesy, Antonio Torrelo, MD; C, Courtesy, NYUDSC; D, Used with permission of the Mayo Foundation for Medical Education and Research; E, F, Courtesy, Luis Requena, MD.*

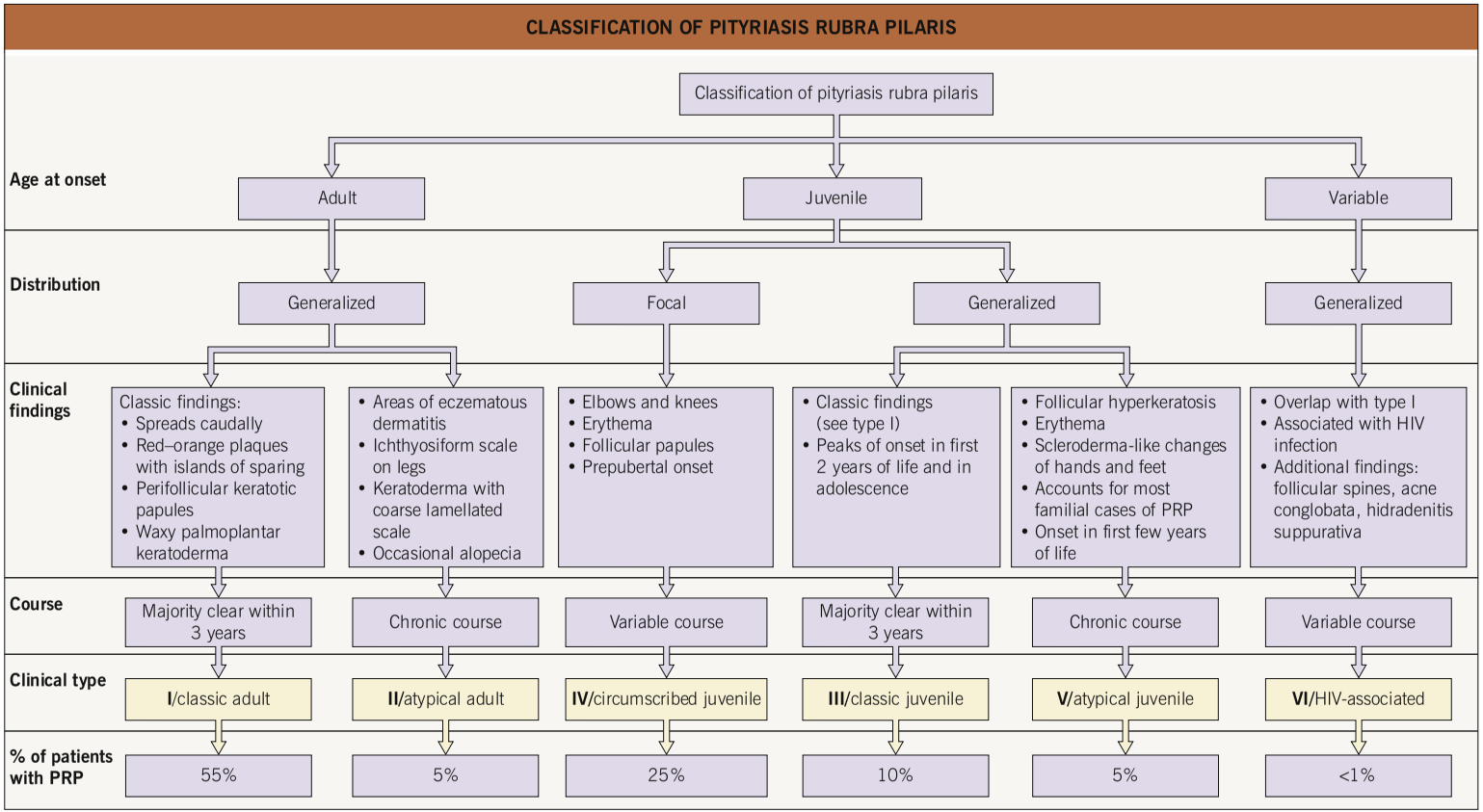


**Fig. 7.10 Classification of pityriasis rubra pilaris (PRP).** Type VI PRP is also referred to as HIV-associated follicular syndrome. *CARD14* mutations have been detected in patients with familial PRP.



**Fig. 7.11 Circumscribed juvenile pityriasis rubra pilaris (type IV).** Symmetric pink plaques with scale are present on the dorsal aspect of the fingers, metacarpophalangeal joints, and knees. There are follicular keratotic papules on the knees. *Courtesy, Antonio Torrelo, MD.*



**Fig. 7.12 Granular parakeratosis involving the axilla.** Coalescing brown papules with hyperkeratosis and slight maceration. *Courtesy, Kalman Watsky, MD.*







**eFig. 7.1 Small plaque parapsoriasis. A** Small (<5 cm), pink, slightly scaly patches. **B** Digitate dermatosis with elongated finger-like lesions on the flank. Digitate dermatosis is the exception to the 5-cm rule as the lesions may measure 10 cm or more along their long axes. *A, Courtesy, Gary Wood, MD, and George Reizner, MD; B, Courtesy, NYUDSC.*



**eFig. 7.2 Pityriasis lichenoides chronica presenting as macules of hypopigmentation.** This is more common in darker skin phototypes. *Courtesy, YDRSC.*



**eFig. 7.3 Pityriasis lichenoides.** An admixture of crusted and scaly papules characteristic of PLEVA and PLC, respectively, are seen. *Courtesy, Antonio Torrelo, MD.*



**eFig. 7.4 Pityriasis lichenoides.** A variety of lesions are seen – light pink thin papules with scale, red-brown papules with white scale and scattered red-brown papules with scale-crust. *Courtesy, Julie V. Schaffer, MD.*



**eFig. 7.5 Pityriasis rosea – herald patch.** It typically precedes the development of a more widespread eruption and is usually larger in size. *Courtesy, Kalman Watsky, MD.*



**eFig. 7.6 Pityriasis rosea.** Two herald patches are seen. *Courtesy, Kalman Watsky, MD.*



**eFig. 7.7 Pityriasis rosea in darkly pigmented skin.** It tends to be more papular than in lightly pigmented skin. Note the associated hyperpigmentation. *Courtesy, YDRSC.*



**eFig. 7.8 Inverse pityriasis rosea.** In this variant, the lesions are limited to the pelvic region and/or axillae. The long axes of the lesions follow the lines of cleavage. *Courtesy, YDRSC.*



**eFig. 7.9 Inverse pityriasis rosea.** Oval plaques with peripheral scale on the central buttocks. *Used with permission of the Mayo Foundation for Medical Education and Research.*

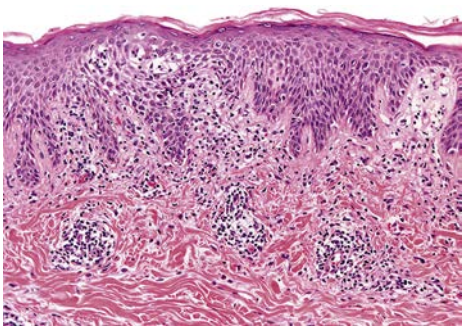

**eFig. 7.10 Pityriasis rosea – histopathologic features.** Parakeratosis, mild spongiosis associated with exocytosis of lymphocytes into the epidermis, perivascular dermal lymphocytic infiltrates, and extravasated red blood cells are seen. *Courtesy, Lorenzo Cerroni, MD.*



**eFig. 7.11 Pityriasis rubra pilaris.** Striking symmetric islands of sparing on the flanks. Follicular papules are present at the periphery of the diffuse erythema. *Used with permission of the Mayo Foundation for Medical Education and Research.*

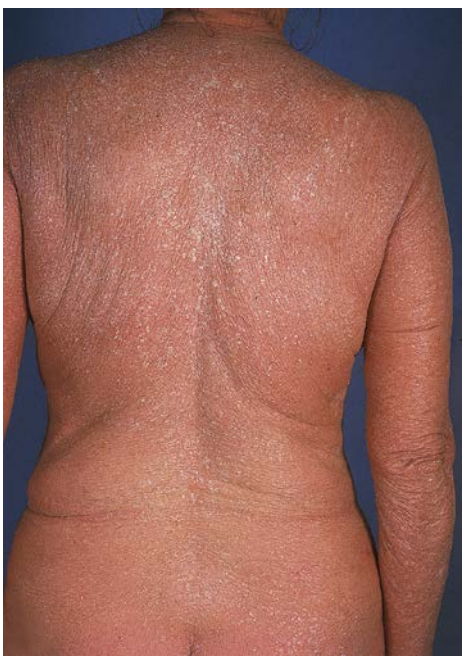

**eFig. 7.12 Pityriasis rubra pilaris.** Although this patient is erythrodermic, the small islands of sparing provide a clue to the diagnosis. *Courtesy, NYUDSC.*

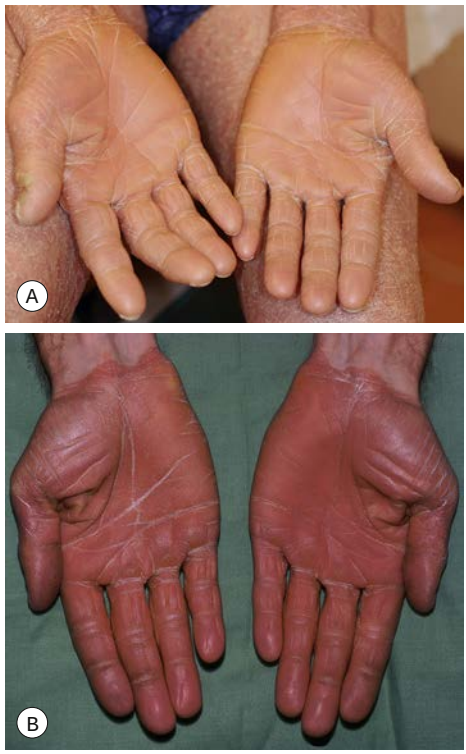


**eFig. 7.13 Pityriasis rubra pilaris – palmar involvement. A** Waxy keratoderma with an orange hue. **B** Orange-pink keratoderma. *A, Courtesy, Irwin Braverman, MD; B, Courtesy, Larry Lantis, MD.*



**eFig. 7.14 Pityriasis rubra pilaris-like presentation in Wong variant of juvenile dermatomyositis.** *Courtesy, Antonio Torrelo, MD.*

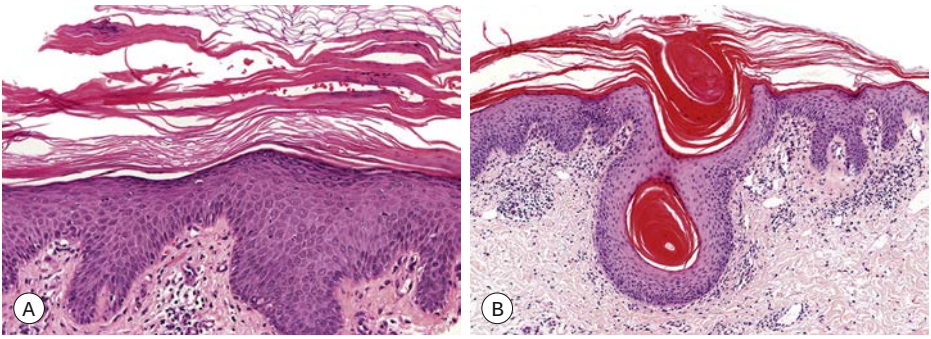


**eFig. 7.15 Pityriasis rubra pilaris – histopathologic features.** Psoriasiform dermatitis with alternating vertical and horizontal ortho- and parakeratosis ("checkerboard pattern") (**A**), as well as follicular hyperkeratosis with parakeratosis in the shoulders of the follicular plug (**B**). *Courtesy, Lorenzo Cerroni, MD.*



**eFig. 7.16 Granular parakeratosis.** Brownish-red papules that have coalesced into a keratotic plaque in the axilla. *Courtesy, David Mehregan, MD.*

# Erythroderma

# 8

- Defined as generalized redness and scaling involving >80–90% of the body surface area (BSA).
- A clinical presentation that can arise from a variety of diseases, often divided into three major categories: (1) primary skin disorders; (2) drug-related (Table 8.1); and (3) malignancies, particularly Sézary syndrome and erythrodermic mycosis fungoides.
- In adults (Table 8.2), the most common primary skin disorders are psoriasis (Fig. 8.1) and atopic dermatitis (Fig. 8.2), with allergic contact dermatitis or pityriasis rubra pilaris (Fig. 8.3) less common.
- In addition to atopic dermatitis, causes in infants and neonates (Table 8.3) include inherited ichthyoses, immunodeficiencies, staphylococcal scalded skin syndrome (SSSS), and seborrheic dermatitis.
- Despite varied etiologies, patients have a number of clinical features in common: generalized erythema and desquamation (scaling) (Fig. 8.6), pruritus with secondary changes (e.g. lichenification), dyspigmentation, eruptive seborrheic keratoses (Fig. 8.7), secondary cutaneous infections, ectropion (Fig. 8.8) and purulent conjunctivitis; additional findings include palmoplantar keratoderma, nail dystrophy and alopecia.

| DRUGS ASSOCIATED WITH ERYTHRODERMA | |
|---|---|
| **Common** | **Less common*** |
| • Allopurinol<br>• Beta-lactam antibiotics<br>• Carbamazepine/oxcarbazepine<br>• Gold<br>• Phenobarbital<br>• Phenytoins<br>• Sulfasalazine<br>• Sulfonamides**<br>• Zalcitabine | • Captopril/lisinopril<br>• Carboplatin/cisplatin<br>• Checkpoint inhibitors***<br>• Cytarabine<br>• Cytokines (IL-2/GM-CSF)<br>• Dapsone<br>• Diflunisal<br>• Fluindione<br>• Hydroxychloroquine/chloroquine<br>• Isoniazid<br>• Isotretinoin/acitretin<br>• Lithium<br>• Mercury compounds<br>• Minocycline<br>• Omeprazole/lansoprazole<br>• Ribavirin<br>• Telaprevir<br>• Thalidomide<br>• Tocilizumab<br>• Vancomycin† |

*Reference for additional drugs: Litt JZ, Shear NH. Drug Eruption & Reaction Manual, 23rd ed. Boca Raton: CRC Press; 2017.*
**Includes furosemide.*
***Ipilimumab, nivolumab, pembrolizumab.*
†Not to be confused with the infusion reaction due to rapid infusion of vancomycin.*

**Table 8.1 Drugs associated with erythroderma.**

| CAUSES OF ERYTHRODERMA IN ADULTS | |
|---|---|
| **Underlying disease** | **Major features** |
| **Common** | |
| Psoriasis (Ch. 6) (see Fig. 8.1) | • Pre-existing psoriatic plaques<br>• Often spares face<br>• Nail changes (pits, oil drop, onycholysis)<br>• Subcorneal pustules (pustular psoriasis)<br>• Inflammatory arthritis<br>• Personal or family history of psoriasis<br>• Onset after withdrawal of CS or methotrexate<br>• On a medication that can exacerbate psoriasis (e.g. lithium) |
| Atopic dermatitis (Ch. 10) (see Fig. 8.2) | • Pre-existing lesions (e.g. in flexures)<br>• Severe pruritus<br>• Lichenification, including eyelids<br>• Prurigo nodularis<br>• Elevated serum IgE, eosinophilia<br>• Personal or family history of atopy<br>• Cataracts, keratoconus |
| Drug reactions (Ch. 17) (see Table 8.1) | • Often preceded by morbilliform or scarlatiniform exanthem<br>• Typically more abrupt onset<br>• Facial edema<br>• In dependent areas, may become purpuric<br>• No history of skin diseases<br>• Usually resolves within 2–6 weeks after withdrawal of culprit drug; with the possible exception of DRESS/DIHS (see Ch. 17) |
| Idiopathic erythroderma (see Fig. 8.4) | • Elderly men<br>• Chronic, relapsing<br>• Severe pruritus<br>• Palmoplantar keratoderma<br>• Dermatopathic lymphadenopathy<br>• Consider less commonly associated drugs (Table 8.1)<br>• Continue to re-evaluate for cutaneous T-cell lymphoma |
| **Less common** | |
| Cutaneous T-cell lymphoma (CTCL) (Ch. 98) | • Sézary syndrome more common than erythrodermic mycosis fungoides or other forms of CTCL<br>• Intense pruritus<br>• Deep purple-red hue<br>• Painful fissured keratoderma<br>• Alopecia<br>• Leonine facies<br>• Lymphadenopathy<br>• Elevated $CD4^+$:$CD8^+$ ratio (blood)<br>• Detection of clonal T-cell population in skin and blood (flow cytometry) |
| Pityriasis rubra pilaris (Ch. 7) (see Fig. 8.3) | • Cephalocaudal progression<br>• Salmon-colored erythema<br>• Islands of sparing (*nappes claires*)<br>• Waxy keratoderma<br>• Perifollicular keratotic papules<br>• Flare after sun exposure |

**Table 8.2 Causes of erythroderma in adults.** *Continued*

| CAUSES OF ERYTHRODERMA IN ADULTS | |
|---|---|
| **Underlying disease** | **Major features** |
| Dermatitis (non-atopic)<br>• Contact (Ch. 12)<br>• Seborrheic (Ch. 11)<br>• Stasis with autosensitization (Ch. 11) | • Pre-existing localized disease<br>• Distribution of initial lesions<br>• Occupation and hobbies<br>• Patch testing<br>• Review oral medications (systemic contact dermatitis) |
| **Rare** | |
| Crusted (Norwegian) scabies (Ch. 71) | • Elderly, infants, immunocompromised<br>• Crusted keratoderma |
| Chronic actinic dermatitis (Ch. 73) | • Initial lesions in photodistribution<br>• Drug history<br>• UVA, UVB, and visible light phototesting<br>• Photopatch testing |
| Papuloerythroderma of Ofuji | • Widespread, pruritic, red-brown, flat-topped papules; may become confluent<br>• Sparing of skin folds ("deck chair" sign)<br>• Favors elderly men<br>• May be associated with lymphoma or HIV infection |
| Paraneoplastic erythroderma | • Fine scaling, melanoerythroderma<br>• Cachexia<br>• Lymphoproliferative disorders (other than Sézary syndrome), including lymphomas and rarely thymomas<br>• In the case of solid-organ malignancies, usually late-stage |
| **Other** | |
| • Hypereosinophilic syndrome (Ch. 20)<br>• Lichen planus<br>• Autoimmune connective tissue disease (dermatomyositis, lupus)<br>• Autoimmune bullous dermatoses (e.g. pemphigus foliaceus [Fig. 8.5])<br>• Dermatophyte infection<br>• Mastocytosis<br>• GVHD | |

**Table 8.2** *Continued* **Causes of erythroderma in adults.**







**Fig. 8.1 Psoriatic erythroderma. A** The disease flare correlated with the administration of lithium. **B** Nail findings (subungual hyperkeratosis, nail plate thickening, and oil-drop changes) point to the diagnosis of psoriasis. There is also soft tissue swelling of the forefinger due to psoriatic arthritis. *A, Courtesy, Jean L. Bolognia, MD; B, Courtesy, Wolfram Sterry, MD.*



**Fig. 8.2 Erythroderma due to atopic dermatitis.** Widespread erythema, fine white scaling and obvious pruritus in addition to circumoral pallor in this infant. *Courtesy, Antonio Torrelo, MD.*







**Fig. 8.3 Erythroderma secondary to pityriasis rubra pilaris.** A few islands of sparing are noted on the flank and breast **(A)**. **B** Large thin scales are seen as well as the distinctive salmon to orange-red color. *A, Courtesy, NYUDSC; B, Courtesy, YDRSC.*



**Fig. 8.4 Idiopathic erythroderma.** This is the type of patient who requires longitudinal evaluation to exclude the development of cutaneous T-cell lymphoma. *Courtesy, NYUDSC.*



**Fig. 8.5 Erythroderma due to pemphigus foliaceus.** Generalized erythema with widespread scale-crusts and large areas of erosion. *Courtesy, NYUDSC.*



**Fig. 8.6 Erythroderma with desquamation.** Obvious exfoliation of scale with underlying erythema. *Courtesy, YDRSC.*



**Fig. 8.7 Eruptive seborrheic keratoses in a patient with idiopathic erythroderma.** *Courtesy, Jean L. Bolognia, MD.*

| CAUSES OF ERYTHRODERMA IN NEONATES AND INFANTS |
|---|
| **Inherited ichthyoses (Ch. 46)** |
| • Epidermolytic ichthyosis (bullous congenital ichthyosiform erythroderma)<br>• Congenital ichthyosiform erythroderma (CIE) (non-bullous form)<br>• Netherton syndrome<br>• Conradi–Hünermann–Happle syndrome (X-linked dominant chondrodysplasia punctata) |
| **Immunodeficiencies (Ch. 49)** |
| • Omenn syndrome<br>• Other forms of SCID, agammaglobulinemia, complement deficiencies (e.g. C3, C5), IPEX syndrome<br>• Wiskott–Aldrich syndrome, hyper-IgE syndrome |
| **Primary dermatoses** |
| • Atopic dermatitis<br>• Seborrheic dermatitis<br>• Psoriasis |
| **Drug reactions (see Table 8.1)** |
| **Infections** |
| • Staphylococcal scalded skin syndrome (Ch. 61)<br>• Neonatal toxic shock-like exanthematous disease<br>• Congenital cutaneous candidiasis |
| **Other** |
| • Diffuse cutaneous mastocytosis<br>• Pityriasis rubra pilaris (Ch. 7)<br>• GVHD<br>• Rare ichthyoses<br>• Ankyloblepharon, ectodermal dysplasia, and cleft lip/palate (AEC) syndrome (Ch. 52)<br>• Nutritional dermatitis, including kwashiorkor |

**Table 8.3 Causes of erythroderma in neonates and infants.** SCID, severe combined immunodeficiency; IPEX, immune dysregulation, polyendocrinopathy, enteropathy, X-linked.

- In addition to these shared features, more specific clinical findings and initial sites of involvement may suggest the underlying etiology (see Table 8.2).
- Potential systemic complications: generalized lymphadenopathy, edema, tachycardia, high-output cardiac failure, hepatomegaly, thermoregulatory disturbances, compensatory hypermetabolism, cachexia, hypoalbuminemia, and anemia.
- Dx is often challenging because both clinical and histologic features may be nonspecific; repeat clinical examinations, laboratory evaluations, and skin biopsies are often necessary (Fig. 8.9).
- Despite a thorough evaluation, the cause can remain unknown (idiopathic) in up to a third of patients (see Fig. 8.4).
- Some patients with idiopathic erythroderma eventually develop a cutaneous T-cell lymphoma (CTCL).



**Fig. 8.8 Ectropion in the setting of erythroderma.** *Courtesy, YDRSC.*

- Treatment strategies should address the dermatological symptoms, the underlying etiology, and the associated systemic complications (Table 8.4).
- May represent a serious medical threat to the patient and require hospitalization.

| GENERAL TREATMENT STRATEGIES FOR ADULT ERYTHRODERMA |
|---|
| **General measures** |
| • Consider hospitalization<br>• Nutritional assessment<br>• Correct fluid/electrolyte imbalances<br>• Prevent hypothermia<br>• Treat secondary infections (e.g. *Staphylococcus aureus*)<br>• Oral antihistamines to suppress pruritus (via sedation) |
| **Topical measures** |
| • Open wet dressings (see Appendix)<br>• Bland emollients<br>• Low- to mid-potency topical CS (ointments > creams)<br>• Reserve high-potency topical CS for lichenified areas<br>• Avoid coal tar ointments and anthralin, may aggravate condition |
| **Additional measures** |
| • Treat specific underlying disease, if known<br>• Idiopathic and/or refractory to topical medications and general measures, consider:<br>– Systemic CS (start dose of prednisone: 1 mg/kg/day with maintenance dose of ≤0.5 mg/kg/day with slow taper)<br>– Methotrexate (7.5–10 mg/week)<br>– Cyclosporine (initial dose of 4–5 mg/kg/day with reduction to 1–3 mg/kg/day)<br>– Azathioprine (as dosed for atopic dermatitis; see Ch. 10)<br>– Mycophenolate mofetil<br>• Psoriasis<br>– Avoid systemic CS<br>– Consider methotrexate*, acitretin, cyclosporine, targeted immune modulators (“biologics”)<br>• Drug eruptions<br>– Stop offending drug<br>– In severe cases (e.g. DRESS/DIHS), may need to use systemic CS |
| **May take 4–6 weeks to see any significant improvement.* |

**Table 8.4 General treatment strategies for adult erythroderma.**

For further information see Ch. 10 from *Dermatology, Fourth Edition*.

**For additional online figures visit www.expertconsult.com**

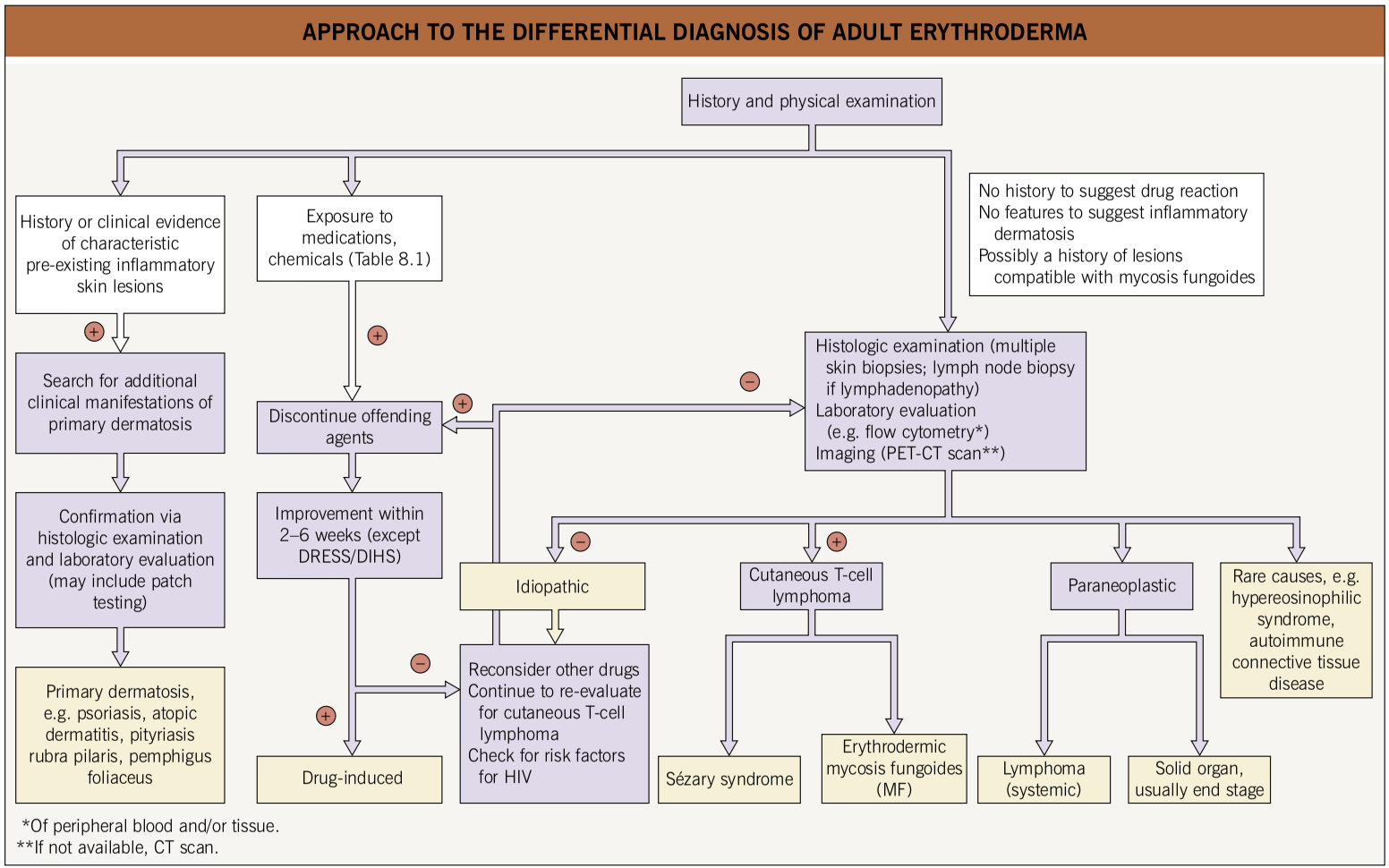


**Fig. 8.9 Approach to the differential diagnosis of adult erythroderma.** PET, positron emission tomography.



**eFig. 8.1 Erythroderma with desquamation.** Obvious exfoliation of scale with underlying erythema. *Courtesy, YDRSC.*



**eFig. 8.2 Psoriatic erythroderma.** There is diffuse involvement of the trunk but a clue to the diagnosis is the individual lesions on the arm. *Courtesy, Luis Requena, MD.*

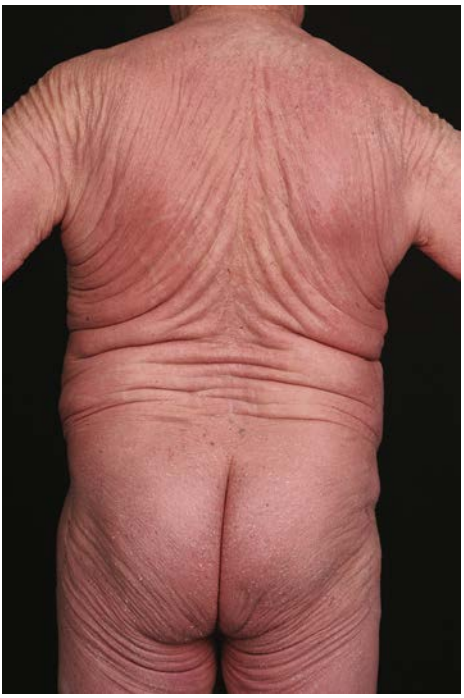

**eFig. 8.3 Erythroderma due to atopic dermatitis.** Widespread erythema with fine white scaling and excoriations. *Courtesy, Lorenzo Cerroni, MD.*

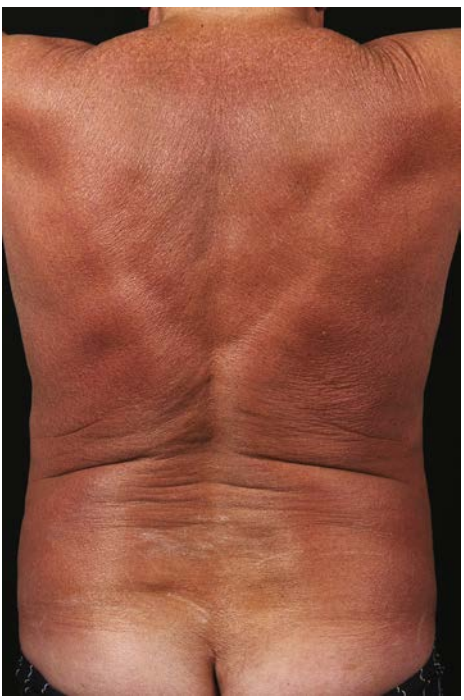

**eFig. 8.4 Sézary syndrome.** Diffuse erythroderma with a red-brown color. Note the evidence of scratching on the lower back. *Courtesy, Lorenzo Cerroni, MD.*

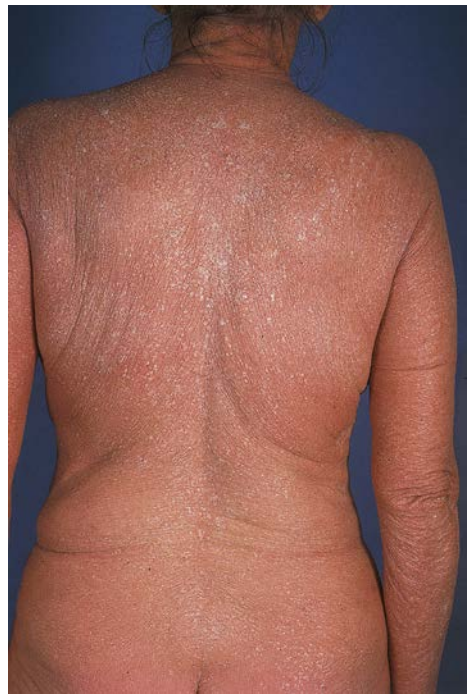

**eFig. 8.5 Erythroderma secondary to pityriasis rubra pilaris.** A few islands of sparing are noted on the upper back. *Courtesy, NYUDSC.*



**eFig. 8.6 Nail dystrophy in a patient with idiopathic erythroderma.** In addition to yellowing and thickening of the nail plate as well as subungual debris, splinter hemorrhages, and onycholysis, there is impending onychomadesis of at least one fingernail. *Courtesy, Karynne O. Duncan, MD.*

# Lichen Planus and Lichenoid Dermatoses

9

## Lichen Planus

- Idiopathic disorder that can affect the skin, hair, nails, and/or mucosae (oral, vulvovaginal) and most commonly affects adults.
- May represent a T-cell-mediated autoreactive disorder against keratinocytes whose self-antigens have been altered by trauma or infection (e.g. HCV).
- Flat-topped (lichenoid) papules that are often polygonal in shape and purple in color may coalesce into plaques (Fig. 9.1); lesions usually resolve with hyperpigmentation (Fig. 9.2).
- A characteristic finding is Wickham striae, a network of fine white lines on the surface of papules and plaques (Fig. 9.3).
- The most common cutaneous sites of involvement are the scalp, flexor wrists (Fig. 9.4), forearms, genitalia, distal lower extremities, in particular the shins, and presacral areas.
- There are multiple variants of lichen planus, from exanthematous to hypertrophic (Table 9.1; Figs 9.5 and 9.6).
- Histologically, a band-like infiltrate of lymphocytes is seen in the upper dermis abutting the epidermis, with apoptosis of keratinocytes (Civatte or colloid bodies) and hypergranulosis; the outline of the lower aspect of the epidermis may be sawtooth-like and melanophages are present in the upper dermis.
- **DDx:** lichenoid drug eruption, lupus erythematosus, pityriasis lichenoides chronica, lichen nitidus, GVHD, and a lichenoid "id" reaction due to acute contact dermatitis to nickel (children), as well as the entities in the comments section of Table 9.1.
- **Rx:** topical or intralesional CS, topical calcineurin inhibitors, phototherapy (NB-UVB), and if severe, consider systemic therapy, e.g. oral CS, hydroxychloroquine [scalp disease], acitretin, JAK inhibitors, apremilast. Topical options for oral lichen planus are outlined in Table 59.2.

## Lichenoid Drug Eruption

- A drug-induced eruption that has an appearance similar to lichen planus; frequently more generalized or in a photodistribution (e.g. HCTZ-induced [Fig. 9.7]).
- Often a latent period of months after instituting drug.
- Lesions tend to be more eczematous, psoriasiform, or pityriasis rosea-like.

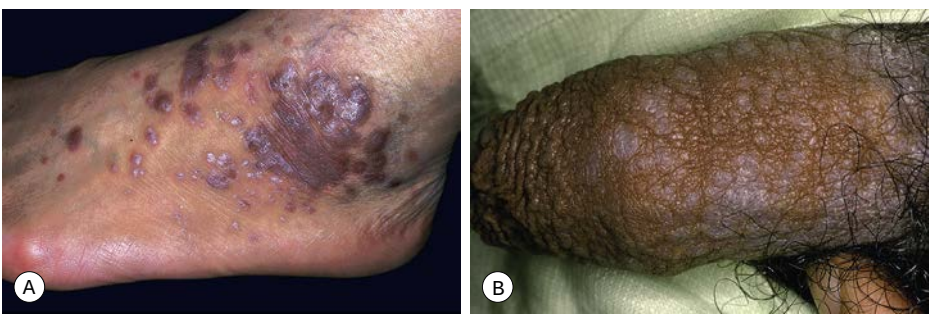


**Fig. 9.1 Lichen planus. A** Violaceous papules and plaques with white scale and Wickham striae on the dorsal foot. **B** Note the flat-topped (lichenoid) nature of the violaceous papules on the penis.
*A, Courtesy, Tetsuo Shiohara, MD. B, Courtesy, Louis A. Fragola, Jr, MD.*



**Fig. 9.2 Lichen planus of the dorsal hand.** Note the flat-topped nature of the lesions and the postinflammatory hyperpigmentation. *Courtesy, Frank Samarin, MD.*



**Fig. 9.3 Wickham striae in lichen planus.** This patient has a hypertrophic lesion in addition to classic lesions. *Courtesy, Julie V. Schaffer, MD.*

- Most commonly incriminated drugs are angiotensin-converting enzyme (ACE) inhibitors, thiazide diuretics, antimalarials, β-blockers, TNF inhibitors, quinidine and immune checkpoint inhibitors (e.g. nivolumab).
- Despite discontinuation of the offending drug, the eruption may be persistent, requiring treatments employed for lichen planus (e.g. topical corticosteroids).

## Lichen Striatus

- Linear array of small, 2–4 mm, flat-topped (lichenoid) papules whose color ranges from skin-colored to pink to tan (i.e. hypopigmented, especially in darkly pigmented patients) (Fig. 9.8).



**Fig. 9.4 Koebnerization of lichen planus into the site of the excision of the saphenous vein.** Lesions also appeared where Steri-Strips™ had been applied. Note the pink to light violet color of the flexor wrist lesions in this lightly pigmented patient. *Courtesy, Robert M. Hartman, MD.*

- Lesions appear over several days to weeks along the lines of Blaschko (see Ch. 51) and are usually asymptomatic.
- Favors children (median age = 2–3 years), with a single streak along one extremity; spontaneously resolves over months to a few years.
- Acral streaks can be associated with nail dystrophy (e.g. onycholysis, splitting).
- No consistently identified trigger and mosaicism for a particular gene not detected to date.
- **DDx:** linear lichen planus, Blaschkitis (multiple streaks; adults; relapsing course; trunk > extremities), subtle or inflamed epidermal nevus > linear GVHD (specific setting), linear porokeratosis, linear psoriasis.
- **Rx:** no specific effective therapy; observation given spontaneous resolution; can try topical corticosteroids or topical calcineurin inhibitors.

## Lichen Nitidus

- Multiple, tiny, discrete, flat-topped papules that are uniform in size and usually

| VARIANTS OF LICHEN PLANUS | | |
|---|---|---|
| **Type** | **Clinical aspects** | **Comments** |
| Actinic LP | Sun-exposed sites, especially face, neck, dorsal aspect of arms<br>Red-brown annular plaques or melasma-like appearance | Middle East<br>Young adults, children |
| Acute (exanthematous; eruptive) LP (Fig. 9.5A) | Abrupt onset<br>Widespread distribution | Usually self-limited (3–9 months)<br>Exclude lichenoid drug eruption, pityriasis rosea, secondary syphilis |
| Annular LP (Fig. 9.5B) | Thin raised border, with hyperpigmented or skin-colored center | Favors axillae, groin/penis, extremities |
| Atrophic LP (Fig. 9.5C) | Large plaques with epidermal atrophy<br>Later stage of disease | **DDx:** lichen sclerosus<br>Annular variant with loss of elastic fibers centrally |
| Bullous LP (Fig. 9.5D) | Bullae within pre-existing lesions | Separation of epidermis from dermis with underlying lichenoid lymphocytic infiltrate |
| Hypertrophic LP (Figs 9.3 & 9.5E) | Favors shins and dorsal feet<br>Thick pruritic plaques with scale<br>Can develop SCC | Average duration – 6 years<br>**DDx:** lichen amyloidosis, LSC, rupioid psoriasis |
| Inverse LP (Fig. 9.5F) | Violaceous plaques<br>Axillae > inguinal or other major body folds | Overlap with LP pigmentosus as lesions resolve with hyperpigmentation |
| LP pemphigoides | Variable distribution of vesicobullae, including previously uninvolved skin | Routine histopathology and DIF of bullous lesions – similar to BP; IIF: autoAb to BPAG2 |
| LP pigmentosus (Fig. 9.5G) | Brown to gray-brown macules and patches in sun-exposed areas of the face and neck *or* intertriginous zones<br>Inflammatory phase usually absent | Skin phototypes III and IV<br>Coexisting LP lesions in 20% of patients<br>**DDx:** erythema dyschromicum perstans, resolved inverse LP |
| Lichen planopilaris (see Ch. 56) | Keratotic plugs within hair follicles with narrow surrounding red to violet-colored rim<br>Hair-bearing sites, especially the scalp | A form of scarring alopecia<br>Variant – frontal fibrosing alopecia (see Ch. 56)<br>**DDx** for scalp: discoid LE |
| Linear LP (Fig. 9.5H) | Need to distinguish Koebner phenomenon from lesions following lines of Blaschko | See Chs 1 and 51<br>**DDx:** lichen striatus if along lines of Blaschko |
| LP/LE overlap | Lesions favor acral sites<br>Overlapping features | Spectrum – from only cutaneous LE to systemic LE |
| Nail LP (Fig. 9.6A,B); (see Ch. 58) | Lateral thinning, longitudinal ridging, fissuring<br>Dorsal pterygium | Variant – twenty-nail dystrophy (more common in children) |
| Oral LP (Fig. 9.6C,D) | Reticular form – white lacy lines or circle with short radiating spikes (buccal mucosa)<br>Erosive form* – includes chronic desquamative gingivitis | Patients can have both gingival and vulvovaginal involvement<br>May be associated with HCV infection |
| Ulcerative LP | Plantar surface > palms | |
| Vulvovaginal LP (see Ch. 60) | Inner aspects of labia minora<br>Glazed erythema that easily bleeds | **DDx:** lichen sclerosus |

**If erosive variant plus lichenoid cutaneous lesions, DDx includes paraneoplastic pemphigus.*

**Table 9.1 Variants of lichen planus (LP).** AutoAb, autoantibody; BP, bullous pemphigoid; BPAG2, bullous pemphigoid antigen 2 (type XVII collagen); DIF, direct immunofluorescence; HCV, hepatitis C virus; IIF, indirect immunofluorescence; LSC, lichen simplex chronicus.




**Fig. 9.5 Variants of lichen planus.**
**A** Exanthematous variant with multiple papulosquamous lesions. **B** Annular variant with thin elevated rim and central hyperpigmentation. **C** Atrophic variant with large, long-standing lesions. **D** Bullous variant with vesicobullae arising in pre-existing plaque. **E** Hypertrophic variant with thick plaques on the shins, a common location for this variant. **F** Inverse variant of the axillae; note the purple color. *Continued*







**Fig. 9.5, cont'd G** Pigmentosus variant with only hyperpigmented lesions in an intertriginous zone. **H** Linear variant with coalescence of violaceous lesions with Wickham striae along the lines of Blaschko on an extremity. Note the postinflammatory hyperpigmentation proximally. *A, D, E, G, Courtesy, YDRSC; B, Courtesy, Frank Samarin, MD; C, Courtesy, NYUDSC; F, Courtesy, Jeffrey Callen, MD; H, Courtesy, Joyce Rico, MD.*













**Fig. 9.6 Lichen planus of the nails and oral mucosa. A** Thinning of the nail plate with lateral loss. **B** Violaceous discoloration of the periungual area with pterygium formation. **C** Reticular oral form characterized by a white lacy pattern composed of rings with short radiating spikes; there is also an erosion of the buccal mucosa. **D** Erosions, lacy pattern, and scarring of the tongue. *A–C, Courtesy, YDRSC; D, Courtesy, Louis A. Fragola, Jr., MD.*



**Fig. 9.7 Lichenoid drug eruption in a photodistribution.** The patient was taking HCTZ. Note the sparing under the watchband. *Courtesy, YDRSC.*

skin-colored (Fig. 9.9); may occasionally be pink to brown in color or hypopigmented (darkly pigmented individuals).

- Lesions favor the anterior trunk, genitalia, and upper extremities and tend to cluster; variants include vesicular, hemorrhagic, linear, and spiny.
- A linear arrangement of papules may be seen, due to the Koebner phenomenon (Table 9.2).
- No consistently identified trigger and persists for months to years.
- Histologically, characteristic finding of a "ball" consisting of a superficial circumscribed infiltrate of lymphocytes and epithelioid cells (2–3 dermal papillae in width) surrounded by a "claw" of epidermis.
- **DDx:** papular eczema, flat warts, lichen planus, frictional lichenoid dermatitis of the elbows and knees, lichen striatus (when linear), secondary syphilis, lichen spinulosus, lichen scrofulosorum, actinic lichen nitidus (see below).
- **Rx:** no specific effective therapy; can try topical CS or topical calcineurin inhibitors and for extensive disease, phototherapy (e.g. NB-UVB).

## Erythema Dyschromicum Perstans (EDP; Ashy Dermatosis)

- Symmetric distribution of multiple oval-shaped gray to gray-brown macules and patches (0.5–2.5 cm; Fig. 9.10); occasionally, a transient thin peripheral rim of erythema is present.




**Fig. 9.8 Lichen striatus. A** Linear streak on the leg that follows the lines of Blaschko. It is composed of numerous small, tan (hypopigmented), flat-topped papules. **B** Single streak on the posterior lower extremity composed of multiple pink flat-topped papules. The differential diagnosis would include Blaschkitis and linear lichen planus. *A, Courtesy, Antonio Torrelo, MD; B, Courtesy, NYUDSC.*

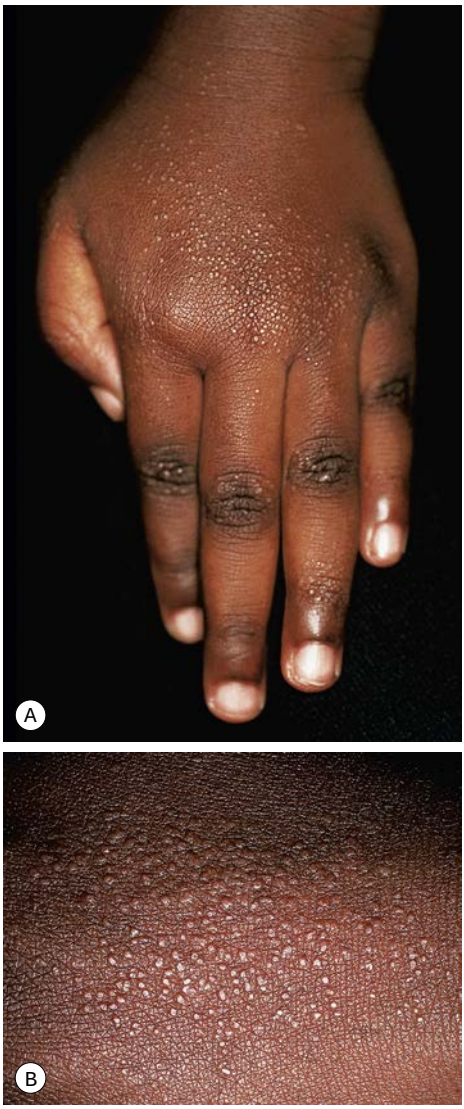


**Fig. 9.9 Lichen nitidus. A** Numerous tiny flat-topped papules on the hand. **B** A close-up view shows the shiny surface. *Courtesy, YDRSC.*

- Favors neck, trunk, and proximal upper extremities; as in pityriasis rosea, the long axis of lesions often follows skin cleavage lines, i.e. Langer's lines (see Fig. 7.7).
- Slowly progressive, asymptomatic disorder that favors children and young adults, in particular individuals from Latin America with skin phototypes III and IV.
- No consistently identified trigger.
- In children, may resolve after a few years (~70% of patients by 2 or 3 years), but often more chronic in adults.

| CLINICAL ENTITIES THAT COMMONLY DISPLAY KOEBNER (ISOMORPHIC) PHENOMENON |
|---|
| • Psoriasis |
| • Vitiligo |
| • Lichen planus |
| • Lichen niditus |
| • Cutaneous small vessel vasculitis |
| • Still disease |
| • Inoculation* – verrucae, mollusca contagiosa |
| **Sometimes referred to as pseudo-Koebner phenomenon.* |

**Table 9.2 Clinical entities that commonly display Koebner (isomorphic) phenomenon.** This is to be distinguished from Wolf isotopic response in which a second skin disease appears at the site of an initial unrelated and often healed skin disease (e.g. granuloma annulare at site of healed herpes zoster).

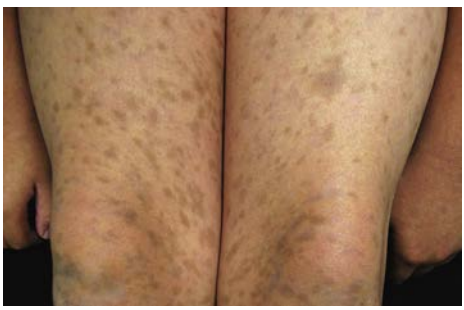

**Fig. 9.10 Erythema dyschromicum perstans.** Numerous oval to polygonal, gray-brown (ashy-colored) macules on the lower extremities. *Courtesy, Graham Dermatopathology Library Collection, Wake Forest University.*

- Histologically, melanin-containing dermal macrophages (melanophages; incontinent pigment) is predominant finding.
- **DDx:** multiple fixed drug eruption (lesions more circular and browner color), postinflammatory hyperpigmentation (e.g. previous lichenoid drug eruption, pityriasis rosea), lichen planus pigmentosus.
- Idiopathic eruptive macular pigmentation is often considered to be a variant of EDP.
- **Rx:** no specific effective therapy; can try sunscreens and mild topical CS.

## Lichen Spinulosus

- Clusters of multiple follicular papules, each containing a keratotic spine.




**Fig. 9.11 Keratosis lichenoides chronica. A** Linear and stellate keratotic plaques. **B** Symmetrical distribution of linear and reticulated keratotic plaques admixed with small violaceous lichenoid papules. *A, Courtesy, YDRSC; B, Courtesy, Kathy Schwarzenberger, MD.*

- Appears abruptly and usually no associated symptoms.
- Favors the neck, extensor arms, abdomen and buttocks of children and adolescents.

## Keratosis Lichenoides Chronica

- Violaceous keratotic lichenoid papules are arranged in a linear or reticulated pattern (Fig. 9.11); can resemble Chinese characters.
- Involvement of the limbs and trunk in a symmetric fashion, in addition to facial plaques that may be psoriasiform.
- Tends to be chronic, progressive, and difficult to treat; occasionally responds to phototherapy (NB-UVB or PUVA) ± systemic retinoids.

## Actinic Lichen Nitidus (Summertime Actinic Lichenoid Eruption)

- Pinhead-sized papules in sun-exposed sites in young adults with darker skin phototypes (IV, V); histopathologic features similar to lichen nitidus.
- Some clinicians have expanded the clinical spectrum such that it overlaps with actinic lichen planus.

## Annular Lichenoid Dermatitis (of Youth)

- Limited number of annular red-brown lesions with central hypopigmentation; they are often 5–15 cm in diameter and favor the groin and flanks.
- More commonly seen in children and young adults.
- **DDx:** inflammatory morphea, mycosis fungoides, inflammatory vitiligo, figurate erythemas.

For further information see Ch. 11 from *Dermatology, Fourth Edition*.

**For additional online figures visit www.expertconsult.com**



**eFig. 9.1 Lichen planus with postinflammatory hyperpigmentation.** The most notable finding is postinflammatory hyperpigmentation, but the distribution on the flexor wrists and the presence of Wickham striae in the upper lesion point to the diagnosis. *Courtesy, YDRSC.*



**eFig. 9.2 Annular lichen planus.** The lesions on the trunk have a thin hyperpigmented rim. *Courtesy, YDRSC.*



**eFig. 9.3 Lichen planus pemphigoides.** The blisters are not limited to plaques of lichen planus as in bullous lichen planus. This patient had anti-BP180 autoantibodies. *Courtesy, YDRSC.*



**eFig. 9.4 Hypertrophic lichen planus.** On the dorsal digits, thin violaceous plaques are present in addition to thick keratotic plaques that favor the knuckles. *Courtesy, Joyce Rico, MD.*



**eFig. 9.5 Linear lichen planus.** Discrete lesions along the lines of Blaschko on the lower extremity of an adult. *Courtesy, NYUDSC.*

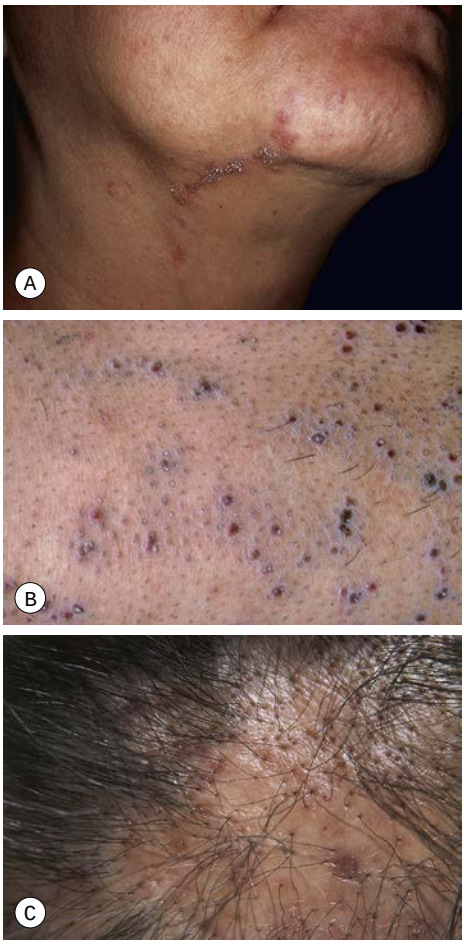


**eFig. 9.6 Lichen planopilaris. A** Keratotic spines surrounded by a violaceous rim in the linear variant. **B** Multiple clusters of follicular keratotic plugs on the leg admixed with small violaceous papules, some of which are folliculocentric. **C** Cicatricial alopecia with "end-stage" changes centrally, but perifollicular inflammation at the margins. *A, C, Courtesy, YDRSC; B, Courtesy, NYUDSC.*

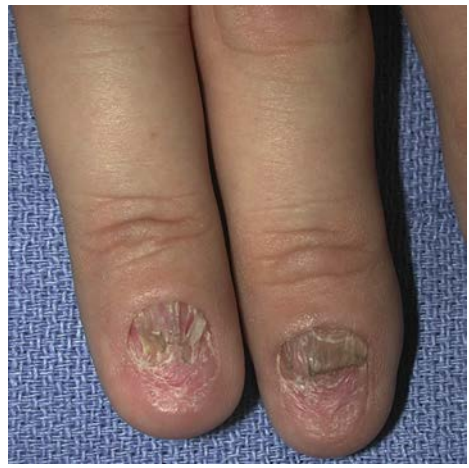

**eFig. 9.7 Nail lichen planus.** Longitudinal fissuring of shortened nail plates. *Courtesy, YDRSC.*



**eFig. 9.8 Lichenoid drug eruption.** Thick violaceous plaques on the shin of a patient receiving nivolumab. *Courtesy, Jeffrey P. Callen, MD.*

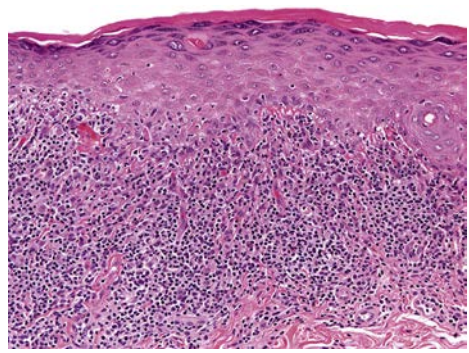

**eFig. 9.9 Lichen planus – histopathologic features.** Hyperkeratosis, focal increase in the granular layer, sawtoothing of the epidermis with keratinization of the basal layer, and a lichenoid infiltrate. Apoptosis of keratinocytes is also present. *Courtesy, Lorenzo Cerroni, MD.*



**eFig. 9.10 Lichen striatus.** Three linear streaks on the lower extremity composed of multiple pink papules, some of which are flat-topped with scale. The primary differential diagnosis would be Blaschkitis. *Courtesy, Tetsuo Shiohara, MD, and Yoshiko Mizukawa, MD.*

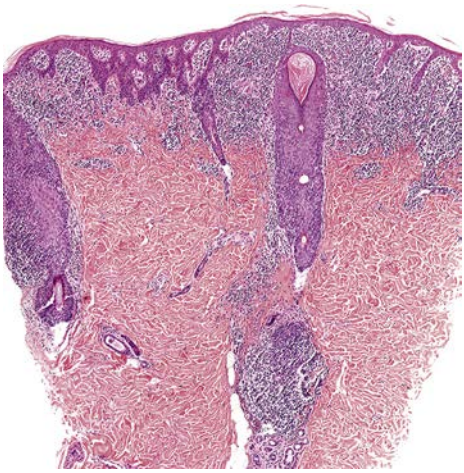

**eFig. 9.11 Lichen striatus – histopathologic features.** In addition to hyperkeratosis with focal parakeratosis, both a lichenoid and a perivascular and periadnexal lymphocytic infiltrate extending into the deeper dermis is seen. *Courtesy, Lorenzo Cerroni, MD.*

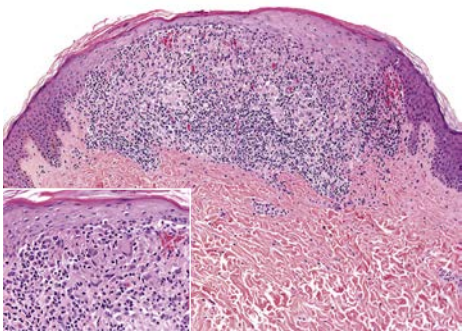

**eFig. 9.12 Lichen nitidus – histopathologic features.** Note the typical "ball and claw" configuration for the infiltrate and epidermis, respectively. There is thinning of the epidermis that overlies the infiltrate. Several Langhans giant cells are within the infiltrate (inset). *Courtesy, Lorenzo Cerroni, MD.*



**eFig. 9.13 Lichen spinulosus.** Grouped, skin-colored follicular papules on the extensor surface of the arm. Central keratotic plugs can be seen. *Courtesy, NYUDSC.*



**eFig. 9.14 Keratosis lichenoides chronica.** Crusted psoriasiform scaling plaques on the face. *Courtesy, Jiro Arata, MD.*



**eFig. 9.15 Annular lichenoid dermatitis (of youth).** Pink-brown annular plaque with central hypopigmentation. *Courtesy, Julie V. Schaffer, MD.*

# Atopic Dermatitis 10

## Introduction

- Common inflammatory skin disease that affects 10–25% of children and 2–10% of adults in most high-income and some low-income countries.
- Eczematous dermatitis characterized by intense pruritus and a chronic or chronically relapsing course.
- Sequelae often include sleep disturbances, psychological distress, disrupted family dynamics, and impaired functioning at school or work.
- Onset usually in infancy or early childhood, with development in the first year of life in >50% and before 5 years of age in >85% of affected individuals.
- Often accompanied by other atopic disorders such as asthma and allergic rhinoconjunctivitis (hay fever), which develop in an age-dependent sequence referred to as the atopic march (Fig. 10.1).
- Atopy is linked to the presence of allergen-specific serum IgE antibodies, which exist in ~70% of individuals who meet diagnostic criteria for atopic dermatitis (AD) (Table 10.1).
- The "hygiene hypothesis" postulates that decreased exposure to infectious agents in early childhood increases susceptibility to atopic diseases.
- Both a genetic predisposition and environmental triggers (e.g. irritation, epicutaneous sensitization, microbial colonization) have pathogenic roles in AD.
- Loss-of-function variants in the filaggrin gene (*FLG*), which encodes a protein important to epidermal barrier function, represent a major predisposing factor for AD that is present in 20–50% of AD patients of European or Asian descent; these *FLG* variants are also implicated in ichthyosis vulgaris.

## Clinical Features and Disease Stages of AD

- Pruritic eczematous lesions are often excoriated and exist on a spectrum of acuity:
  - *Acute lesions*: edematous, erythematous papules and plaques that may have vesiculation, oozing, and crusting (Figs 10.2B and 10.3B, C)
  - *Subacute lesions:* erythematous patches or plaques with scaling and variable crusting (Fig. 10.4A)
  - *Chronic lesions:* thickened plaques with lichenification (increased skin markings) as well as scaling (Figs 10.3A and 10.4B–E)
- Regional variants of AD are depicted in Fig. 10.5.
- Small perifollicular papules (papular eczema) are especially common in patients with darkly pigmented skin (Fig. 10.6).
- Postinflammatory hyper-, hypo-, or (in severe cases) depigmentation may be seen upon resolution of AD lesions (see Fig. 10.8).
- **DDx:** outlined in Table 10.2.
- AD is divided into infantile, childhood, and adolescent/adult stages with characteristic morphologies and distributions (see Figs 10.2 and 10.5).

### Infantile AD (Age <2 Years)

- Usually develops after 6 weeks of age and often features acute lesions.
- Frequently begins on the cheeks, forehead, and scalp (see Fig. 10.2); also favors the extensor aspects of the extremities and trunk (see Fig. 10.3A, B).
- The diaper area and central face tend to be spared.

### Childhood AD (Age 2–12 Years)

- Lesions are less acute and typically become lichenified.

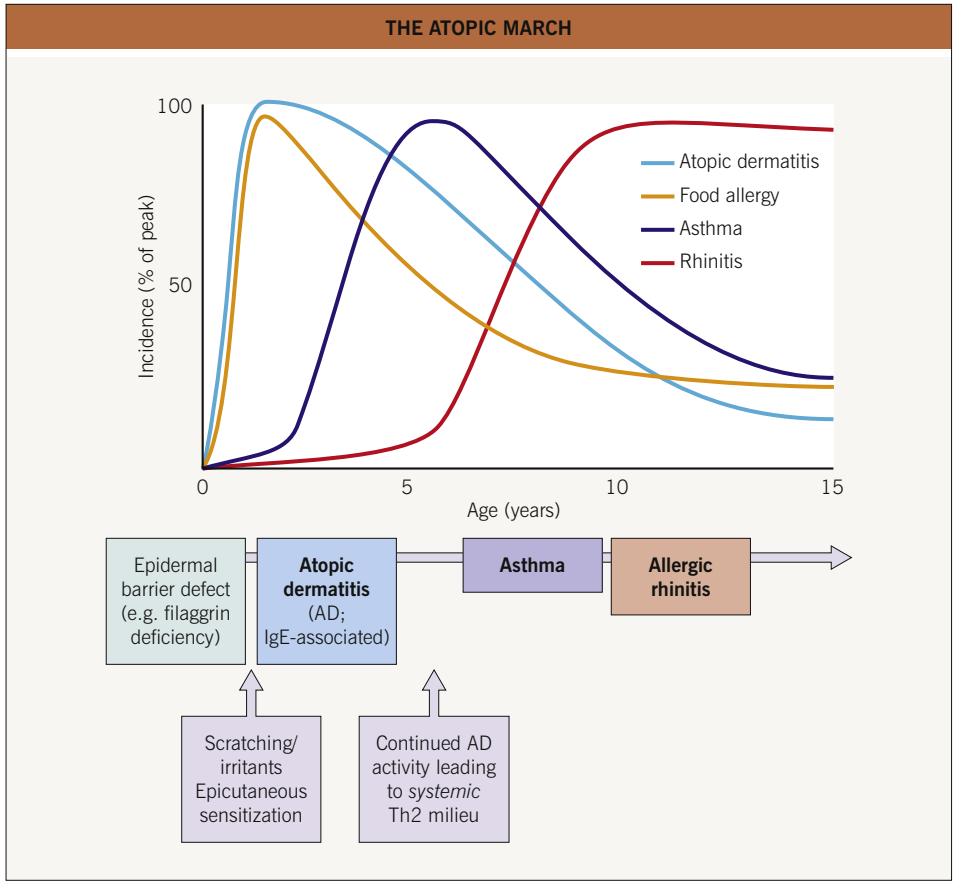


**Fig. 10.1 The atopic march.**

| DIAGNOSTIC FEATURES AND TRIGGERS OF ATOPIC DERMATITIS |
|---|
| **Essential features** *(must be present and are sufficient for diagnosis)* |
| • Pruritus<br>– Rubbing or scratching can initiate or exacerbate flares ("the itch that rashes")<br>– Often worse in evening and triggered by exogenous factors (e.g. sweating, rough clothing)<br>• Typical eczematous morphology and age-specific distribution patterns (see text and Figs 10.2 and 10.5)<br>• Chronic or relapsing course |
| **Important features** *(seen in most cases, support the diagnosis)* |
| • Onset during infancy or early childhood<br>• Personal and/or family history of atopy (IgE reactivity)<br>• Xerosis<br>– Dry skin with fine scale in areas *without* clinically apparent inflammation<br>– Often leads to pruritus |

**Table 10.1 Diagnostic features and triggers of atopic dermatitis (AD).** *Continued*

| DIAGNOSTIC FEATURES AND TRIGGERS OF ATOPIC DERMATITIS |
|---|
| **Associated features** *(suggest the diagnosis, but less specific)* (see Figs 10.5 and 10.8) |
| • Other filaggrin deficiency-associated conditions: keratosis pilaris, hyperlinear palms, and ichthyosis vulgaris (IV; see Ch. 46; ~15% of patients with AD have moderate–severe IV, and >50% of patients with IV have AD)<br>• Follicular prominence, lichenification, and prurigo lesions<br>• Ocular conditions: recurrent conjunctivitis, anterior subcapsular cataract; periorbital changes: pleats, darkening<br>• Other regional findings, e.g. perioral or periauricular dermatitis, pityriasis alba<br>• Atypical vascular responses, e.g. mid facial pallor, white dermographism*, delayed blanch |
| **Triggers** |
| • *Climate:* extremes of temperature (winter or summer), low humidity<br>• *Irritants:* wool/rough fabrics, perspiration, detergents, solvents<br>• *Infections:* cutaneous (e.g. *Staphylococcus aureus*, molluscum contagiosum) or systemic (e.g. URI)<br>• *Environmental allergies:* e.g. to dust mites, pollen, contact allergens; consider patch testing if recalcitrant AD, especially if in an atypical distribution<br>• *Food allergies:*<br>– Trigger in small minority of AD patients, e.g. 10–30% of those with moderate to severe, refractory AD<br>– Common allergens: egg (most often linked to AD exacerbation), milk, peanuts/tree nuts, (shell)fish, soy, wheat<br>– Limited food allergy testing is recommended in children <5 years of age who have moderate to severe AD with: (1) persistent activity despite optimized management; or (2) a history of an immediate allergic reaction after ingesting a particular food<br>– Introduction of peanut-containing foods as early as 4–6 months of age is recommended to reduce risk of peanut allergy in infants with AD; prior peanut-specific IgE and/or skin prick testing should be performed in those with severe AD or egg allergy<br>– Detection of allergen-specific IgE (via blood and skin-prick tests) does *not* necessarily mean that allergy is triggering the patient's AD; when relevant food allergens are identified and avoided, skin-directed AD therapy is still important |
| **Stroking the skin leads to a white streak that reflects excessive vasoconstriction.* |

**Table 10.1** *Continued* **Diagnostic features and triggers of atopic dermatitis (AD).**

| DIFFERENTIAL DIAGNOSIS OF ATOPIC DERMATITIS | | |
|---|---|---|
| **Chronic dermatoses** | | |
| C | Seborrheic dermatitis | Common (especially in infants) |
| B | Contact dermatitis (allergic* or irritant) | Common |
| B | Psoriasis (especially palmoplantar) | Common |
| A>C | Nummular eczema | Uncommon (although nummular lesions can be seen in AD, true nummular eczema is uncommon) |
| A | Asteatotic eczema | Common |
| B | Lichen simplex chronicus | Common |
| **Infections and infestations** | | |
| B | Scabies | Common |
| B | Dermatophytosis* | Common |
| B | Impetigo | Especially for nummular lesions |
| **Primary immunodeficiencies** e.g. hyper-IgE and Wiskott–Aldrich syndromes (C) | | |
| **Malignancies** e.g. mycosis fungoides, Sézary syndrome (A > C) | | |
| **Genetic/metabolic disorders** e.g. Netherton syndrome, ectodermal dysplasias | | |
| **Autoimmune disorders** e.g. dermatitis herpetiformis, pemphigus foliaceus, dermatomyositis | | |
| **Other** e.g. keratosis pilaris, photoallergic drug eruptions, eczematous drug eruptions** | | |

**Common causes of autosensitization dermatitis (id reaction).*
***Although drug eruptions are common, those resembling AD are uncommon.*

**Table 10.2 Differential diagnosis of atopic dermatitis (AD).** A, adults; B, both; C, children/infants.

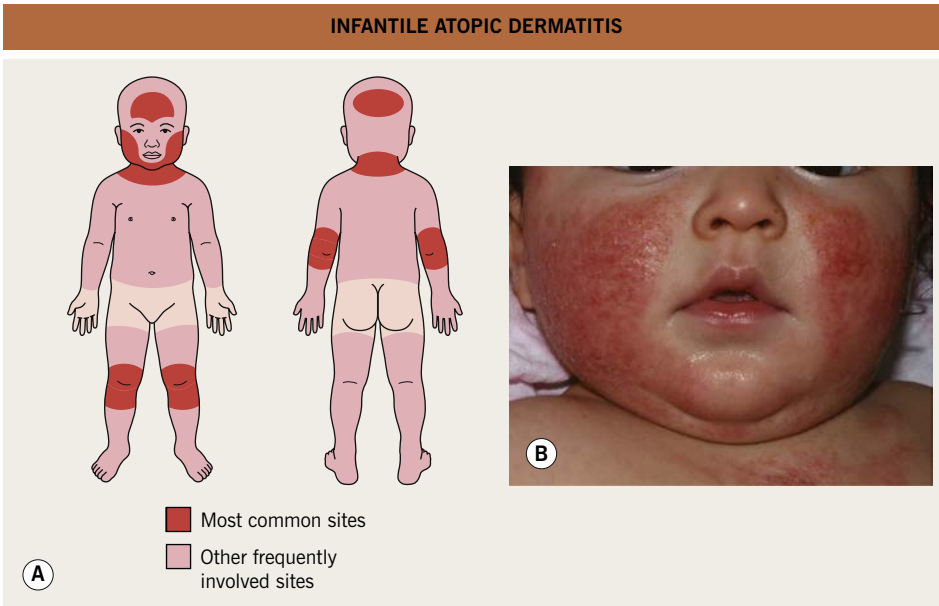


**Fig. 10.2 Infantile atopic dermatitis. A** Distribution pattern of infantile atopic dermatitis. **B** Erythema and scale-crust on the cheeks, with sparing of the central face.

- Favors the antecubital and popliteal fossae (flexural eczema), wrists/ankles, hands/feet, neck, and periorificial regions of the face (see Figs 10.4 and 10.5).
- Often associated with widespread xerosis.
- ≥50% of children with AD go into remission by 12 years of age.

### Adolescent/Adult AD (Age >12 Years)

- Subacute to chronic, lichenified lesions with distribution similar to childhood AD.
- Some patients have chronic involvement limited to a particular site, e.g. the hands or face (especially the eyelids) (Fig. 10.7; see Fig. 10.5).
- Chronic papular lesions may develop due to habitual scratching or rubbing (see Fig. 10.6).
- More often extensive or even erythrodermic if continuous since childhood.

## Associated Features of AD

- Figs 10.8 and 10.9 present findings that are frequently associated with AD.

### Keratosis Pilaris

- Affects >40% of patients with AD and ~15% of the general population.
- Onset typically in childhood; may improve after puberty (especially facial involvement).
- Affects the lateral aspect of the upper arms, thighs, and lateral cheeks (especially in children); the trunk and distal extremities are much less common sites.
- Keratotic follicular papules, often with a rim of erythema (see Fig. 10.9A) or (especially on the cheeks) a background of patchy erythema.
- *Keratosis pilaris rubra* (KPR) has prominent, confluent background erythema (see Fig. 10.9B).
- *Keratosis pilaris atrophicans* is a rare atrophic variant that favors the lateral eyebrows.
- Keratolytic agents (e.g. lactic, glycolic, or salicylic acid) and topical retinoids are sometimes used to decrease the hyperkeratotic component, but the benefit is limited and irritation can occur, especially in AD patients.

### Pityriasis Alba

- Common in children/adolescents, especially those with AD and tan or darkly pigmented skin.
- Ill-defined hypopigmented macules and patches (usually 0.5–3 cm) with subtle fine scaling.
- Located on face (especially cheeks) (see Fig. 10.9C) > shoulders and arms.




**Fig. 10.3 Extensive atopic dermatitis (AD).** **A** AD on the extensor surface of an infant's arm, which is a common site in this age group. Note the follicular prominence on the trunk. **B** Nummular lesions on the extensor aspect of the arm in an infant with widespread AD. Note the nipple eczema. **C** Widespread AD in a young child with excoriations, crusting, and lichenification. *A, Courtesy, YDRSC; B, Courtesy, Julie V. Schaffer, MD; C, Courtesy, Maeve McAleer, MD, Grainne O'Regan, MD, and Alan Irvine, MD.*

- Represents a low-grade eczematous dermatitis with postinflammatory hypopigmentation as the primary clinical manifestation.
- **DDx:** postinflammatory hypopigmentation (e.g. from AD, psoriasis, or pityriasis lichenoides chronica; usually also extrafacial lesions), tinea versicolor (individual lesions more sharply demarcated and smaller), vitiligo (depigmented).
- **Rx:** regular use of sunscreens may make pityriasis alba less noticeable.

## Complications of AD

- An impaired skin barrier and modified immune milieu predispose AD patients to cutaneous infections.




**Fig. 10.4 Childhood atopic dermatitis.** **A** Flexural eczema in the popliteal fossa with excoriations and hemorrhagic crusting. **B** Lichenification, scale, and punctate excoriations in the antecubital fossae. **C** Coalescing papules and lichenification on the ankle due to chronic scratching and rubbing. **D, E** Thick eczematous plaques with excoriations (**D**) and marked lichenification (**E**) on the dorsal hand and wrist. *A, B, D, E, Courtesy, Julie V Schaffer, MD; C, Courtesy, Antonio Torrelo, MD.*

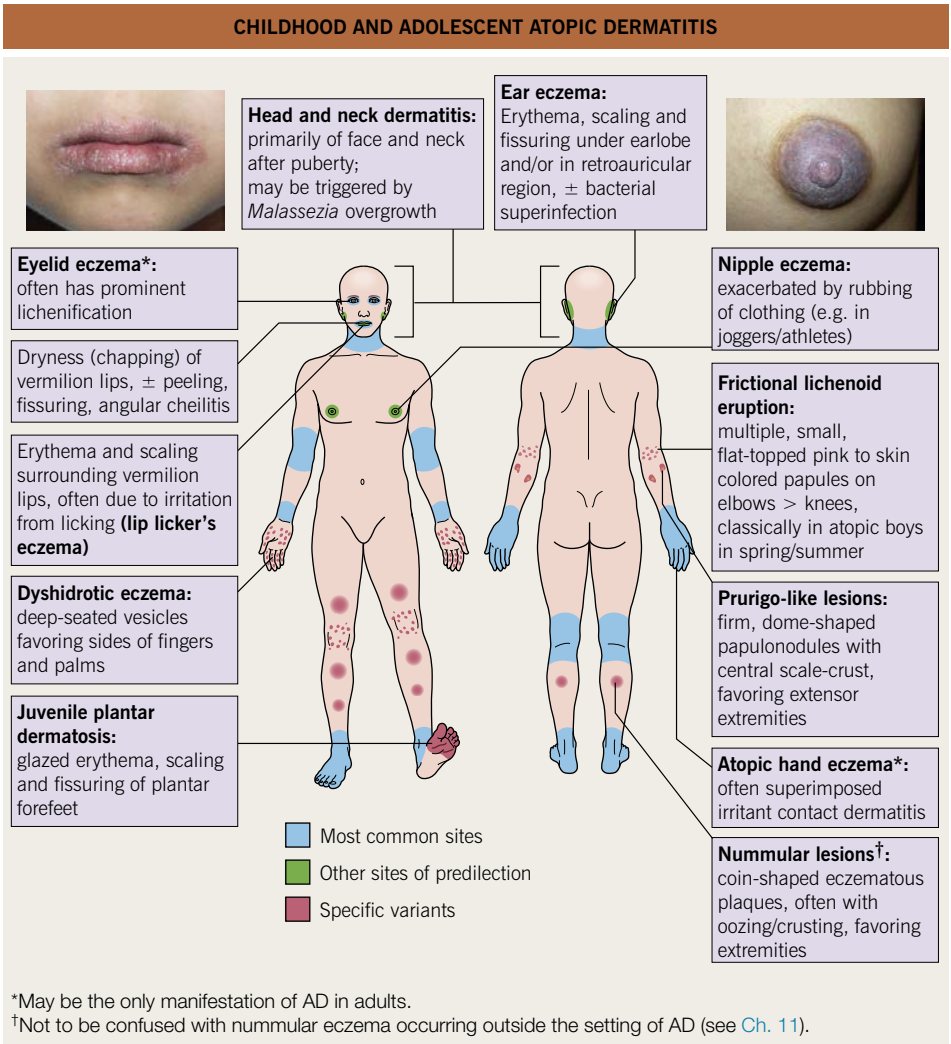


**Fig. 10.5 Childhood and adolescent atopic dermatitis (AD): distribution patterns and regional variants.**

- Affected skin is usually colonized by *Staphylococcus aureus*, and impetiginization (which can also result from *Streptococcus pyogenes*) (Fig. 10.10), folliculitis, and furunculosis frequently occur.
- Eczema herpeticum typically presents with rapid development of numerous monomorphic, punched-out erosions with hemorrhagic crusting (Fig. 10.11); vesicles may or may not be evident.
- Molluscum contagiosum infections result in an increased number of lesions, usually with associated dermatitis (see Ch. 68).
- Potential ocular complications of AD are listed in Table 10.1.

## Triggers and Prevention of AD

- Multiple environmental and psychological factors can trigger or exacerbate AD (see Table 10.1).
- Avoidance of relevant triggers represents an important consideration in AD management.
- Administration of probiotics/prebiotics to pregnant mothers and infants may potentially help to prevent AD onset in high-risk individuals.

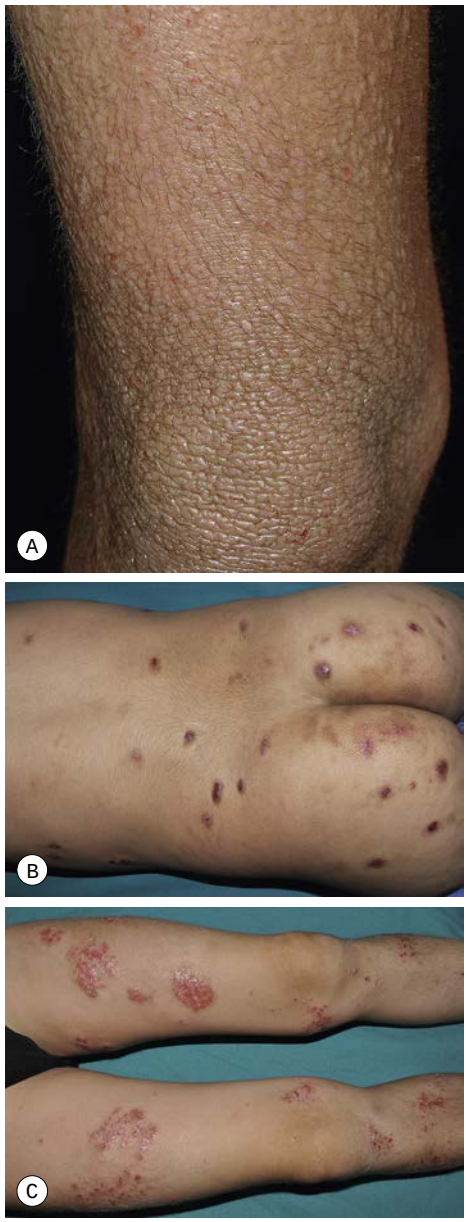


**Fig. 10.6 Atopic dermatitis variants.** **A** Chronic papular lesions resulting from habitual rubbing and scratching in the setting of longstanding disease. **B** Prurigo lesions presenting as firm, dome-shaped papules and nodules with central hemorrhagic crust. **C** Nummular plaques with oozing and crusting on the legs. *A, Courtesy, Thomas Bieber, MD, and Caroline Bussman, MD; B, C, Courtesy, Antonio Torrelo, MD.*



**Fig. 10.7 Severe facial atopic dermatitis in an adult.** *Courtesy, YDRSC.*

## Treatment of AD

- There are two major components to management of AD (Fig. 10.12).
  - Treatment of active dermatitis with anti-inflammatory agent(s)
  - Maintenance designed to improve skin barrier function, control subclinical inflammation, and avoid trigger factors
- Proactive treatment of AD provides better long-term disease control and could potentially interrupt the atopic march.
- Basics of skin care.
  - Daily lukewarm bath (preferred for infants/children) or shower with limited use of a mild cleanser
  - Within 3 minutes of exit from bath/shower, application of (1) a topical CS (or calcineurin inhibitor/other anti-inflammatory agent) when/where indicated; and then (2) liberal use of an emollient to the entire skin surface
  - Ointments (minimize stinging) and creams (less greasy) are preferred to lotions as emollients and should be applied twice daily; products containing lactic or glycolic acid can lead to stinging and should be avoided
- Topical anti-inflammatory agents.
  - First-line: topical CS of appropriate strength used once or twice daily until eczema is clear (see Fig. 10.12)

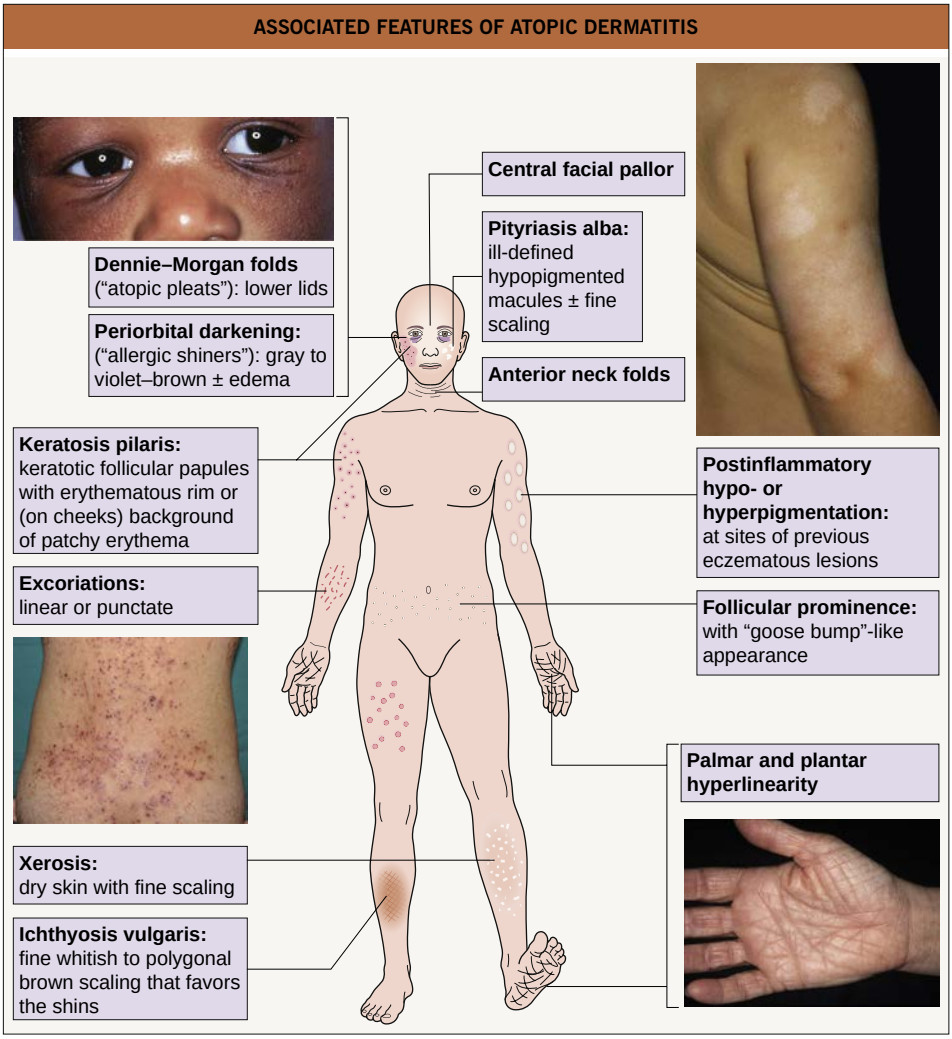


**Fig. 10.8 Associated features of atopic dermatitis.** *Inset of eyes: Courtesy, YDRSC. Inset of hand: Courtesy, Jean L. Bolognia, MD. Insets of excoriations and hypopigmentation: Courtesy, Antonio Torrelo, MD.*

- CS ointments (minimize stinging) and creams are generally preferred, but CS solutions, foams, and oils are useful for AD on the scalp
- Addressing patients'/parents' specific concerns about CS use helps to maximize adherence to the treatment plan
- Tap water compresses followed by CS application or wet wraps after CS application can speed improvement of acute flares

– Second-line: topical calcineurin inhibitors (TCIs; e.g. tacrolimus, pimecrolimus) or crisaborole are helpful primarily for thinner lesions, especially on the face and in intertriginous areas
– High-level maintenance with intermittent use of a topical CS and/or TCI to usual sites of eczema once clear can help to control subclinical inflammation and prevent flares (see Fig. 10.12)

• Phototherapy and systemic anti-inflammatory agents.
– Narrowband UVB (often induces remission) > UVA1 (for acute flares) > UVA-broadband UVB combination
– Dupilumab, a monoclonal antibody that targets IL-4 and IL-13 signaling

involved in Th2 inflammation, is FDA-approved for the treatment of recalcitrant moderate-to-severe AD in patients ≥6 years of age (with studies in younger children in progress); it can be used with concurrent topical CS treatment and has a favorable side-effect profile, with injection site reactions and conjunctivitis each occurring in 5–10% of patients
  - Among other systemic anti-inflammatory agents traditionally utilized for severe, recalcitrant AD, oral cyclosporine has the most evidence for efficacy, but its use is limited by potential side effects such as nephrotoxicity; azathioprine, mycophenolate mofetil, and methotrexate have less dramatic benefit but better long-term safety profiles
  - Systemic CS therapy should be avoided due to the high likelihood of significant rebound flares (see Fig. 10.12) and the unacceptable side effects of long-term use; uncommon exception: severe acute flare (e.g. with a specific trigger) resistant to aggressive topical management – this short course of systemic CS must be transitioned to a topical regimen, phototherapy, or another systemic agent
- Emerging AD treatments include topical and oral JAK inhibitors and biologic agents targeting IL-13 or IL-31.
- Adjunctive pharmacologic therapy.
  - Sedating antihistamines (e.g. hydroxyzine, diphenhydramine, doxepin) given at bedtime may help to break the itch–scratch cycle, especially if pruritus disrupts sleep
  - Controlled trials of non-sedating antihistamines, leukotriene antagonists, antibiotics (oral or topical) aimed at reducing colonization, and probiotics have not consistently demonstrated efficacy as treatments of AD; dilute sodium hypochlorite (bleach) baths (¼–½ cup of household bleach in ~full standard bathtub 1–2 times weekly) may be of benefit, especially in patients with recent staphylococcal superinfections




**Fig. 10.9 Associated findings in patients with atopic dermatitis. A** Keratosis pilaris. Note the discrete perifollicular papules with central keratotic cores on the extensor surface of the upper arm. Each papule has a rim of erythema. **B** Keratosis pilaris rubra on the lateral face. This variant is characterized by tiny, grain-like follicular papules superimposed on confluent erythema. **C** Pityriasis alba. Note the slight scale associated with the hypopigmented macules and patches on the cheek. *A, Courtesy, YDRSC. B, Courtesy, Angela Hernández-Martín, MD; C, Courtesy, Julie V. Schaffer, MD.*

For further information see Ch. 12 from *Dermatology, Fourth Edition*.



For additional online figures visit www.expertconsult.com



**Fig. 10.10 Infected hand dermatitis in a patient with atopic dermatitis.** There is impetigo-like crusting as well as pustules. *Courtesy, Julie V. Schaffer, MD.*




**Fig. 10.11 Eczema herpeticum.** Note the monomorphic erosions and hemorrhagic crusts on the arm (**A**) and posterior neck (**B**). Vesicles are rarely evident. *A, Courtesy, Maeve McAleer, MD, Grainne O'Regan, MD, and Alan Irvine, MD; B, Courtesy, Julie V. Schaffer, MD.*

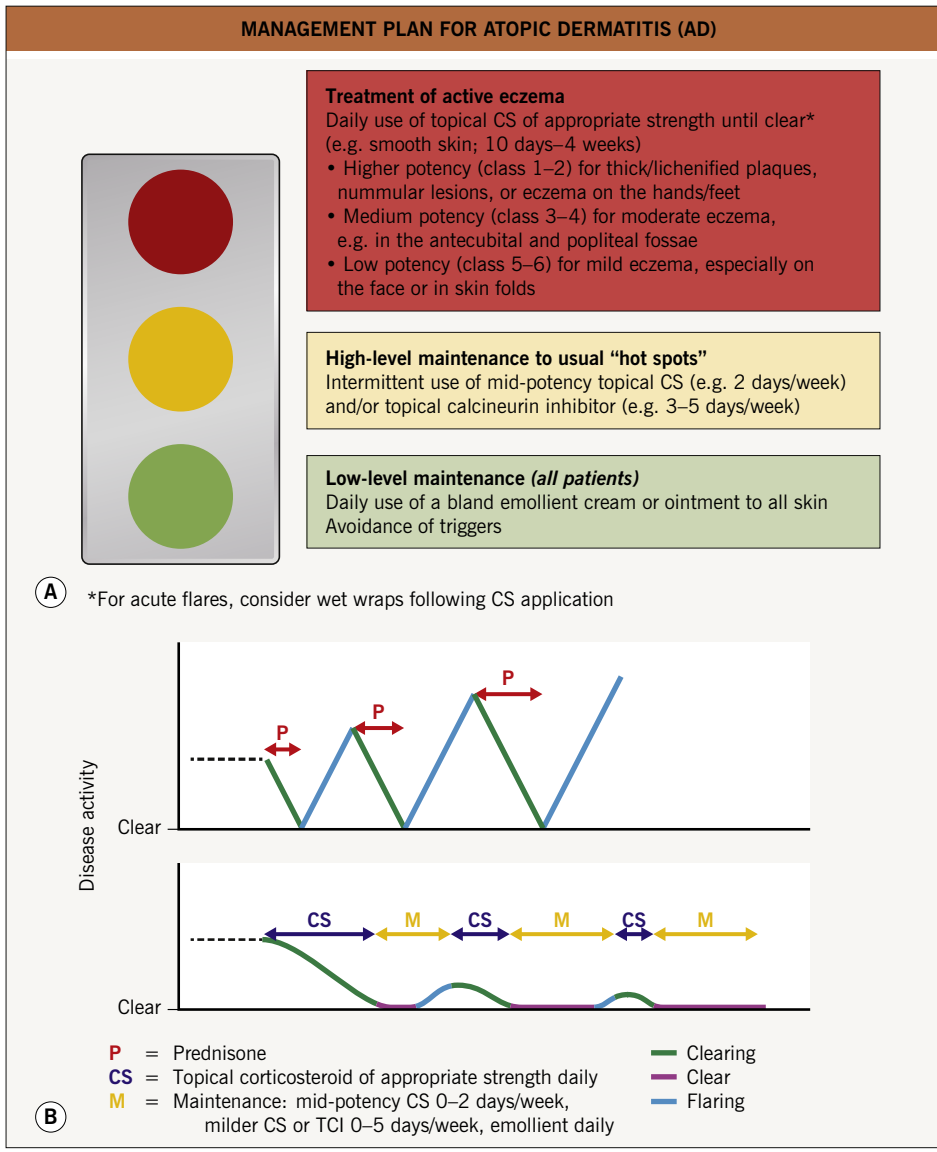


**Fig. 10.12 Management plan for atopic dermatitis. A** The therapeutic regimen should include both treatment of active eczema and maintenance (low-level in all and high-level in some patients). **B** Intermittent courses of a systemic CS result in rebound flares and worsening of disease over time. In contrast, a proactive regimen utilizing topical CS leads to longer clear periods and milder disease over time.



**eFig. 10.1 Atopic dermatitis on the face of an infant.** Acute lesions with oozing and serous crusting are common in this age group. *Courtesy, Julie V. Schaffer, MD.*



**eFig. 10.2 Infantile atopic dermatitis on the face.** More severe, widespread facial dermatitis with accentuation of scale-crust around the mouth. *Courtesy, Maeve McAleer, MD, Grainne O'Regan, MD, and Alan Irvine, MD.*




**eFig. 10.3 Childhood atopic dermatitis. A** Extension from the antecubital fossae to the wrists and hands. Note the excoriations and lichenification. **B** Pink lichenified plaques with excoriation and hemorrhagic crusting as well as lichenification. **C** Thick lichenified plaques. **D** Widespread eczematous dermatitis. *A, Courtesy, Thomas Bieber, MD, and Caroline Bussmann, MD; B, C Courtesy, Julie V. Schaffer, MD; D, Courtesy, Luis Requena, MD.*



**eFig. 10.4 Atopic dermatitis in childhood exacerbated by *Malassezia*.** The patient has scaling of the scalp and confluent erythema of the upper face. *Courtesy, Maeve McAleer, MD, Grainne*



**eFig. 10.5 Postinflammatory depigmentation in atopic dermatitis.** This patient has widespread, severe disease and multiple lesions of prurigo nodularis. *Courtesy, Jean L. Bolognia, MD.*

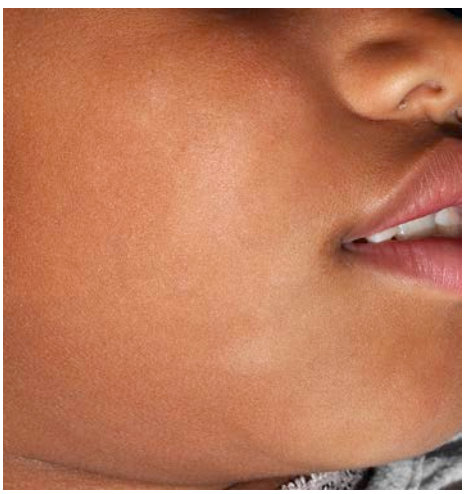

**eFig. 10.6 Pityriasis alba.** Note the slight scale associated with the hypopigmented macules and patches on the cheek. *Courtesy, Antonio Torrelo, MD.*







**eFig. 10.7 Eczema herpeticum. A** Monomorphic, punched-out erosions with a scalloped border in this infant with a history of facial atopic dermatitis. **B** Monomorphic, small hemorrhagic crusts and erosions coalescing in the popliteal fossae, an area of pre-existing atopic dermatitis. *A, Courtesy, Julie V. Schaffer, MD; B, Courtesy, Kalman Watsky, MD.*



**eFig. 10.8 Infected hand dermatitis in a patient with atopic dermatitis.** There is impetigo-like crusting as well as pustules. *Courtesy, Louis A. Fragola, Jr., MD.*



A L G r a w a n y

# Other Eczematous Eruptions 11

The major forms of dermatitis include atopic (see Ch. 10), contact (see Ch. 12), seborrheic, asteatotic (xerotic), stasis, and nummular. Dermatitis of special sites – i.e. hands, feet, lips, eyelids, diaper area, and major body folds – is reviewed in Chapter 13, and pityriasis alba is reviewed in Chapters 10 and 54.

## Seborrheic Dermatitis

- Common disorder with both an infantile and an adult form (Figs 11.1 and 11.2); unusual in children.
- Possibly related to components of sebum and *Malassezia* spp.
- Severe or recalcitrant seborrheic dermatitis can be a sign of underlying HIV infection or neurologic disorder.
- In adults, tends to be a chronic relapsing disorder; stress or tapering of systemic CS can lead to a flare.
- Symmetric distribution pattern that includes regions with greater sebum production – scalp, ears (external canal, retroauricular fold), medial eyebrows, upper eyelids, nasolabial folds, central chest – and major body folds.
- Lesions are pink-yellow to red-brown in color, depending on the underlying skin phototype, and they often have greasy scale, especially in the head and neck region; occasionally annular in configuration.
- On the scalp, involvement tends to be more diffuse, compared to the well-circumscribed plaques with thicker silvery scale that are more characteristic of scalp psoriasis.
- In some patients, the lesions of the scalp, ears, and major body folds have features of both seborrheic dermatitis and psoriasis, leading to the term "sebopsoriasis".
- **DDx:** psoriasis, contact dermatitis, other causes of diaper dermatitis (see Fig. 13.4), intertrigo (see Fig. 13.2) or blepharitis (see Fig. 13.6), tinea (pityriasis) versicolor (when presternal), tinea capitis (especially in children), atopic dermatitis, pityriasis amiantacea, and dermatomyositis (scalp); may coexist with rosacea.
- **Rx:** topical antifungal creams and daily shampooing (e.g. ketoconazole, ciclopirox, selenium sulfide or zinc-containing shampoo alternating with a gentle shampoo), mild topical CS on the face and in body folds and moderate-strength topical CS for the scalp and ears; topical calcineurin inhibitors (e.g. tacrolimus ointment).

## Asteatotic Eczema (Xerotic Eczema, Eczema Craquelé)

- Arises in areas of dry skin, especially during winter months, in dry climates, and in older adults.
- The areas of dermatitis resemble a "dried riverbed" or "crazy-paving" with superficial cracking of the skin (Fig. 11.3).
- May be associated with pruritus; stinging can occur with application of water-based topical agents, including those that contain lactic or glycolic acid.
- Favors the shins, thighs, lower flanks, and posterior axillary line; may become more widespread but with sparing of the face, palms, and soles.
- Involvement of the posterior axillary line seen in chronic GVHD; when widespread, consider the possibility of an underlying systemic lymphoma.
- **DDx:** stasis dermatitis ± autosensitization, ichthyosis vulgaris, adult atopic dermatitis, allergic or irritant contact dermatitis.
- **Rx:** decrease frequency of bathing and use of soaps, liberal use of water-in-oil emollients, mild topical CS ointments.




**Fig. 11.1 Infantile seborrheic dermatitis.** **A** Involvement of the scalp with thick adherent yellow scale overlying mild inflammation is often referred to as "cradle cap". **B** Glistening red plaques of the neck, axillary and inguinal folds as well as the penis and umbilicus. Note disseminated lesions on the trunk and extremities. *A, Courtesy, Antonio Torrelo, MD; B, Courtesy, Robert Hartman, MD.*

## Stasis Dermatitis

- Pruritic dermatitis with scale-crust and sometimes oozing that favors the shins and calves (see Fig. 86.5D); historically often begins near the medial malleolus.
- Patients often have a history of chronic lower extremity edema and may have a history of deep vein thromboses and/or recurrent cellulitis.
- Often accompanied by other signs of chronic venous hypertension (Table 11.1).
- One of the more common causes of autosensitization (Fig. 11.4).
- **DDx:** allergic contact dermatitis, irritant contact dermatitis, asteatotic eczema, nummular dermatitis; may accompany other causes of the red leg, especially cellulitis and acute or chronic lipodermatosclerosis (Fig. 11.5), but the latter lack the clinical and histopathologic findings of dermatitis.
- **Rx:** exclude superimposed allergic contact dermatitis (e.g. neomycin, preservatives in topical creams) or component of infectious eczematous dermatitis if draining ulcer; open wet dressings for a few days, mild topical CS ointments, leg elevation, pressure stockings (after excluding arterial insufficiency via ankle–brachial index), endovascular ablation of large varicosities, water-in-oil emollients for maintenance therapy.

## Autosensitization Dermatitis (Id Reaction)

- More widespread distribution of dermatitis that follows by days to weeks the development of localized areas of dermatitis, e.g. allergic contact dermatitis, stasis dermatitis, inflammatory tinea infections.
- Can also represent a rebound phenomenon when there has been too rapid a taper of systemic CS, as in 6-day taper of prednisone or methylprednisolone (Medrol® dose pack) for poison ivy dermatitis.
- Favored sites of involvement (in addition to primary site): extensor aspects of extremities (see Fig. 11.4), palms and soles, usually in a symmetric pattern.
- In children with tinea capitis, the id reaction often involves the head and neck region.
- Areas of dermatitis, often ill-defined, can be accompanied by excoriated papules (Fig. 11.6).
- **DDx:** atopic dermatitis, widespread contact dermatitis (e.g. textiles), Gianotti–Crosti syndrome (children), drug eruption to systemic antifungal medication (tinea capitis id),




**Fig. 11.2 Adult seborrheic dermatitis of the scalp, ear, and face.** **A** Diffuse scaling of the scalp in addition to erythema of the forehead. **B** Fairly sharply demarcated pink plaque with white and greasy scale. Note the fissure in the retroauricular fold. **C** Thin pink-orange plaques with yellow, greasy scale, especially of the melolabial fold and eyebrows. When this degree of severity is seen, the possibility of underlying HIV infection needs to be considered. **D** Symmetric red-brown to violet plaques of the central forehead, nasal bridge, and medial cheeks with an associated hypopigmented figurate rim. *A, Courtesy, Jean L. Bolognia, MD; B, Courtesy, Norbert Reider, MD, and Peter O. Fritsch, MD; C, Courtesy, NYUDSC; D, Courtesy, Jeffrey Callen, MD.*

eczematous drug eruptions (e.g. calcium channel blockers [unusual]). When palmoplantar, dyshidrotic eczema, inflammatory tinea.

- **Rx:** in addition to aggressively treating the primary dermatitis, topical CS and oral antihistamines usually suffice; occasionally, when severe, systemic CS.

## Infectious Eczematous (Eczematoid) Dermatitis

- Dermatitis that initially involves the skin surrounding a site of infection, usually bacterial, which is weeping or has drainage (e.g. otitis externa, infected leg ulcer, toe web infection) (Fig. 11.7).



**Fig. 11.3 Asteatotic eczema (eczema craquelé).** The distal lower extremity has obvious inflammation and xerosis with adherent white scale (pseudo-ichthyosis) as well as a criss-cross pattern of superficial cracks and fissures said to resemble a dried riverbed. *Courtesy, Louis A. Fragola, Jr., MD.*

| CUTANEOUS SIGNS OF CHRONIC VENOUS HYPERTENSION |
|---|
| • Edema, often tender |
| • Varicosities |
| • Stasis dermatitis |
| • Petechiae superimposed on a yellow-brown discoloration due to hemosiderin deposits (stasis purpura) |
| • Lipodermatosclerosis, acute and chronic |
| • Stasis ulcerations, in particular above the medial malleolus |
| • Acroangiodermatitis (pseudo-Kaposi sarcoma) |
| • Livedoid vasculopathy (porcelain-white scars surrounded by punctate telangiectasias, small irregularly shaped purpuric macules due to infarcts, and painful ulcerations)* |
| **Need to exclude causes of hypercoagulability/thrombophilia.* |

**Table 11.1 Cutaneous signs of chronic venous hypertension.**

- An id reaction can develop and treatment of both the infection and the dermatitis is recommended.

## Nummular Dermatitis (Nummular Eczema)

- Markedly pruritic, coin-shaped lesions of dermatitis, usually measuring 2 or 3 cm in diameter (Fig. 11.8).



**Fig. 11.4 Autosensitization dermatitis.** There is dermatitis of the extensor surfaces of the upper extremities in this patient with allergic contact dermatitis to neomycin as well as stasis dermatitis and venous ulceration. *Courtesy, Jean L. Bolognia, MD.*

- Occurs primarily on the extremities, classically the legs in men and the arms in women.
- Favors adults and can develop in the absence of an atopic diathesis; a chronic relapsing course is common.
- **DDx:** coin-shaped lesions of atopic dermatitis, autosensitization dermatitis, impetigo, stasis dermatitis, allergic contact dermatitis, tinea corporis, vesicular pityriasis rosea, mycosis fungoides.
- **Rx:** in addition to topical CS and calcineurin inhibitors, often requires phototherapy to clear.

## Dyshidrotic Eczema (Acute and Recurrent Vesicular Hand Dermatitis)

- Firm, pruritic vesicles of the palms > soles as well as the lateral and medial aspects of the digits (Fig. 11.9); tends to be recurrent.

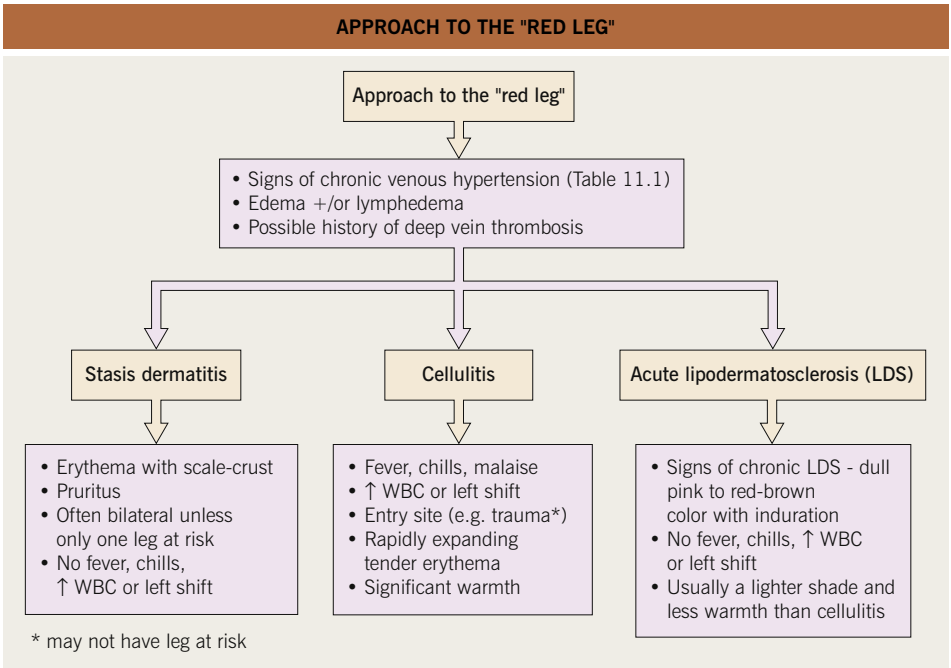


**Fig. 11.5 Approach to the "red leg."** Patients with lower extremity edema can have baseline tenderness with palpation.



**Fig. 11.6 Id reaction in a child due to allergic contact dermatitis (ACD) to nickel.** Square-shaped area of ACD due to nickel in a buckle surrounded by multiple crusted edematous papules. *Courtesy, Julie V. Schaffer, MD.*



**Fig. 11.7 Infectious eczematous dermatitis.** Crusting and scaling at the periphery of otitis externa due to *Staphylococcus aureus*. *Courtesy, Norbert Reider, MD, and Peter O. Fritsch, MD.*

- Intact vesicles due to edema within the epidermis are more long-lived because of the thick stratum corneum in acral sites.
- When the vesicles are small and grouped, they are said to have an appearance similar to tapioca pudding.
- When larger vesicles develop, the term pompholyx is sometimes used.
- Can flare with stress, allergic or irritant contact dermatitis, and administration of IVIg; seen in patients with atopic dermatitis and hyperhidrosis.
- **DDx:** id reaction (can have overlap), inflammatory tinea pedis or manuum, allergic contact dermatitis, scabies,



**Fig. 11.8 Nummular dermatitis (nummular eczema).** Multiple coin-shaped lesions of acute and subacute dermatitis on the leg that are fairly well demarcated. There is often marked pruritus. *Courtesy, Norbert Reider, MD, and Peter O. Fritsch, MD.*



**Fig. 11.9 Dyshidrotic eczema (pompholyx).** Clusters of firm vesicles along the lateral aspect of the thumb and hypothenar eminence. *Courtesy Louis A. Fragola, Jr., MD.*

dyshidrosiform bullous pemphigoid; if secondarily infected, palmoplantar pustulosis; when localized to a single digit, whitlow (herpes simplex infection) or blistering digital dactylitis (staphylococcal or group A streptococcal infection).

- **Rx:** exclude allergic or irritant contact dermatitis; topical CS, topical calcineurin inhibitors, bath PUVA; occasionally, when severe, systemic CS.



**Fig. 11.10 Juvenile plantar dermatosis in a child.** Erythema and scaling of the plantar surface of the forefoot, especially the ball of the foot and the great and fifth toes. Note the glazed appearance of the skin of the left foot. *Courtesy, Kalman Watsky, MD.*

## Juvenile Plantar Dermatosis

- Favors the plantar surface of the forefeet in prepubertal children, usually with an atopic diathesis.
- The skin is dry and scaly with mild inflammation and a characteristic glazed appearance (Fig. 11.10).
- Thought to be related to hydration of the stratum corneum from wearing shoes made of impermeable materials and subsequent shearing of skin due to friction.
- **DDx:** other causes of foot dermatitis (see Table 13.1), especially psoriasis, allergic contact dermatitis (e.g. rubber, chromates in leather), tinea pedis (interdigital toe webs involved), atopic dermatitis.
- **Rx:** permeable socks and shoes, emollients, CS ointments, keep feet dry including removal of wet socks and wet shoes.

## Infective Dermatitis

- Rare disorder of childhood or adolescence associated with human T-cell lymphotropic virus type 1 (HTLV-1) infection.
- Dermatitis of the scalp, ears, eyelid margins, paranasal skin, axillae, and groin that clears with oral antibiotics.

For further information see Ch. 13 from *Dermatology, Fourth Edition*.

**For additional online figures visit www.expertconsult.com**

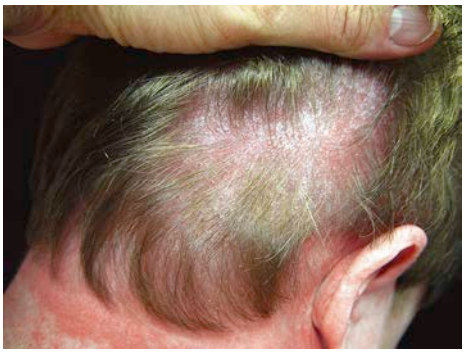

**eFig. 11.1 Seborrheic dermatitis-like eruption due to dermatomyositis.** This patient presented with severe pruritus of the scalp. In addition to the scalp involvement, she had Gottron's papules and a photodistributed poikiloderma. *Courtesy, Jeffrey P. Callen, MD.*



**eFig. 11.2 Asteatotic eczema (eczema craquelé).** When widespread, there can be involvement of the trunk and proximal extremities. Along with the shins, the area that surrounds the posterior axillary fold is a common site for asteatotic eczema. *Courtesy, Thomas Schwarz, MD.*




**eFig. 11.3 Asteatotic eczema (eczema craquelé). A** The distal lower extremity has areas of dull erythema that contain a criss-cross pattern of superficial cracks and fissures said to resemble a dried riverbed. **B** A close-up of the pattern.



**eFig. 11.4 Id reactions in children due to allergic contact dermatitis to nickel.** Multiple flat-topped papules, several of which have been excoriated, in addition to patches of eczema. *Courtesy, Julie V. Schaffer, MD.*




**eFig. 11.5 Nummular dermatitis. A, B** Coin-shaped lesions of acute and subacute dermatitis that are fairly well demarcated. There is often marked pruritus. *A, Luis Requena, MD; B, Courtesy, Kalman Watsky, MD.*



**eFig. 11.6 Nummular dermatitis in a child.** Multiple circular lesions on the back with obvious vesiculation. *Courtesy, Julie V. Schaffer, MD.*

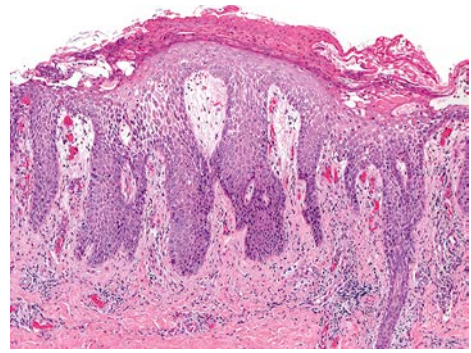

**eFig. 11.7 Nummular dermatitis – histopathologic features.** Irregular acanthosis of the epidermis is accompanied by marked spongiosis as well as parakeratotic scale and crust. A lymphohistiocytic infiltrate is present in the dermis with a few lymphocytes within the epidermis. Edema is present in the papillary dermis. *Courtesy, Lorenzo Cerroni, MD.*



**eFig. 11.8 Dyshidrotic eczema.** Firm papules and pseudovesicles on the palms and volar sides of the fingers. *Courtesy, Norbert Reider, MD, and Peter O. Fritsch, MD.*

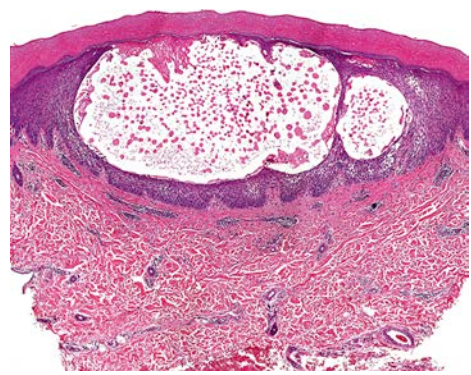

**eFig. 11.9 Dyshidrotic eczema – histopathologic features.** Spongiosis within the epidermis is accompanied by macrovesicles; the thickened stratum corneum points to an acral location. *Courtesy, Lorenzo Cerroni, MD.*

# Irritant and Allergic Contact Dermatitis, Occupational Dermatoses, and Dermatoses Due to Plants

# 12

## Key Points

- Irritant contact dermatitis (ICD)
  - Accounts for 80% of all causes of contact dermatitis
  - Secondary to a local toxic effect caused by a topical substance or physical insult
- Allergic contact dermatitis (ACD)
  - Accounts for 20% of all causes of contact dermatitis
  - A delayed-type hypersensitivity reaction to a substance to which the individual has been previously sensitized
  - Compared to ICD, more commonly presents with pruritus during the acute phase
- One of the most common occupational dermatoses is ICD.
- Plants can cause a variety of skin reactions, the most common in North America being ACD to poison ivy.

## Irritant Contact Dermatitis

- Localized, non-immunologically mediated cutaneous inflammatory reaction (Figs 12.1–12.5).
- Secondary to a direct toxic effect
  - Chronic – erythema, fissures, and scale which is oftentimes thick
  - Acute – erythema, edema, and vesiculation followed by erosions and scaling; in severe cases may lead to epidermal necrosis (a "chemical burn")
- Commonly affects the hands (see Fig. 13.1); Table 12.1 reviews pertinent questions for when environmental exposures are suspected.
- A common cause of cheilitis (lip-licking; see Fig. 13.5).
- May be secondary to an occupational exposure (Table 12.2)
  - Common causes are soaps and wet work, and less often petroleum products, cutting oils, and coolants



**Fig. 12.1 Bilateral irritant contact dermatitis of the feet and ankles due to chronic occlusive footwear.** *Courtesy, David Cohen, MD.*



**Fig. 12.2 Bilateral irritant contact dermatitis of the palms secondary to repeated contact with paint solvents.** Extensive patch testing excluded allergic contact dermatitis in this professional paint and crayon illustrator. *Courtesy, Kalman Watsky, MD.*



**Fig. 12.3 Moderately severe irritant contact dermatitis of the hands due to chronic exposure to disinfecting solutions and antiseptics.** The results of patch testing, latex challenge testing, and RAST testing were negative in this practicing dentist. *Courtesy, David Cohen, MD.*

- **DDx:** when severe, thermal burn; ACD and other dermatitides; there may be a combination of causes, e.g. ICD and ACD, ICD and atopic dermatitis.
- **Rx:** primarily avoidance of the irritant.

## Allergic Contact Dermatitis

- In contrast to ICD, more commonly presents with pruritus during the acute phase; the chronic phase has significant overlap with ICD (Fig. 12.6).
- Initially, well demarcated and localized to site of contact with the allergen (Figs 12.7–12.12).
  - Acute – in addition to erythema and edema, vesicobullae and weeping may develop (Fig. 12.7)
  - Chronic – often lichenified with scale (Figs 12.6B and 12.9)
- Can have autosensitization with extension beyond original site (see Ch. 11); airborne allergens primarily contact exposed skin and can mimic (or overlap) photoallergic or phototoxic reactions (Fig. 12.11).



**Fig. 12.4 Chemical burn from topical application of apple cider vinegar mimicking child abuse in an infant.** Note the sharply demarcated erythema with angular borders and sparing of the skin folds, as well as the superficial blistering and desquamation. *Courtesy, Julie V. Schaffer, MD.*

- Occasionally, there is a diffuse, patchy distribution, depending on the allergen (e.g. body wash or shampoo) and/or concomitant atopic dermatitis.
- Common allergens are metals, fragrances, preservatives, and topical antibiotics, as well as plants, in particular poison ivy/oak (see below) (Fig. 12.12).
- Common causes of occupational ACD are rubber, nickel, epoxy resin, and aromatic amines.
- Suspected allergens should be avoided; a repeat open application test can be tried first but patch testing is required for accurate diagnosis; detailed lists of allergen-containing products are available.
- In patch testing, specific concentrations of allergens are dissolved in petrolatum or water and placed in wells that are then applied to the patient's back for 48 hours (Figs 12.13 and 12.14); grading of reactions is performed at two time points (Table 12.3).
- **DDx:** other forms of dermatitis (ICD, atopic dermatitis, stasis dermatitis, seborrheic dermatitis), erythematotelangiectatic rosacea, dermatophyte infection.
- **Rx:** short term: topical and systemic CS depending on severity; long term: avoidance of allergen(s).

## Common Allergens

### Metals

- Cross-reactivity not uncommon within each broad category.
- Nickel – found in costume jewelry, snaps on jeans, backs of watches, belt buckles

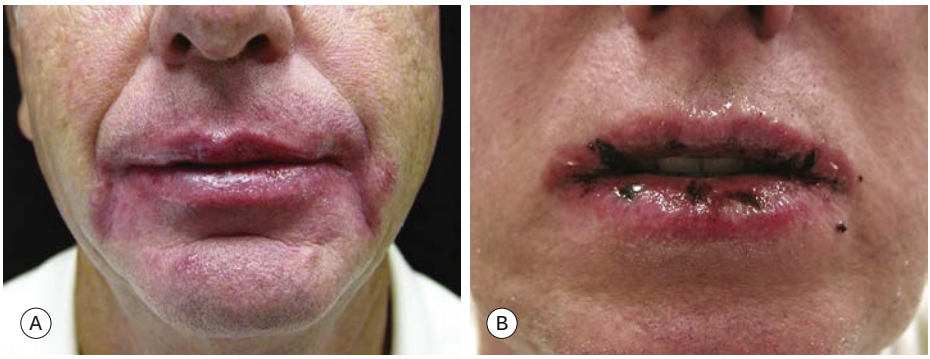


**Fig. 12.5 Cheilitis due to irritant versus allergic contact dermatitis. A** Irritant contact dermatitis – this patient had the habit of licking his lips and there is involvement of the vermilion and cutaneous lips as well as the perioral region. **B** Allergic contact dermatitis to oxybenzone with involvement of the upper and lower lips. *A, Courtesy, Jeffrey P. Callen; B, Courtesy, Kalman Watsky, MD.*

| POINTS TO CONSIDER WHEN EVALUATING HAND DERMATITIS AND ENVIRONMENTAL EXPOSURES ARE SUSPECTED | |
|---|---|
| Occupation | Are findings consistent with work exposure as a cause? |
| | Does time off result in improvement? |
| Materials handled | Do labels and material safety data sheets (MSDS) list potential irritants or allergens? |
| | Is there a relationship to handling food? |
| | Other persons in workplace affected? |
| | Protective equipment (e.g. gloves) used? |
| Previous skin disease or history of atopy | Is there a history of eczema as a child? |
| Known allergies | Is there unrecognized exposure? |
| Treatment | May cause allergic contact dermatitis |
| Hobbies | Including exposure to plants |

**Table 12.1 Points to consider when evaluating hand dermatitis and environmental exposures are suspected.** *Courtesy, Peter S. Friedmann, MD.*

(Figs 12.15 and 12.16); dimethylglyoxime test (Fig. 12.15 inset) identifies objects that release nickel (can purchase dimethylglyoxime at nonickel.com).

- Chromate – found in metals, leather, cement.
- Cobalt – used to harden metals; cosmetics, enamel, ceramics, hair dyes, and joint replacements; the cobalt spot test can be used.
- Gold – found in jewelry, dental fillings, and some electronics.

## Topical Antibiotics

- Neomycin sulfate – found in many over-the-counter preparations (e.g. hemorrhoid creams).
- Bacitracin – in many products.

## Fragrances

- Balsam of Peru (*Myroxylon pereirae*) – one of the naturally occurring fragrances; also found in spices (cloves, Jamaican pepper, cinnamon); fragrance can be used to mask odors in products, including some that are labeled "unscented". Allergic individuals should look for "fragrance-free" products, being aware that unfortunately even those products may be labeled as such despite containing some fragrance that is being used as a preservative.

## Preservatives

- Formaldehyde – cosmetics and textiles (permanent press), medications, paints.

| COMMON IRRITANTS AND EXAMPLES OF MAJOR EXPOSURE(S) | |
|---|---|
| **Irritant** | **Examples of major exposure(s)** |
| **Inorganic acids** | |
| Hydrofluoric acid | Etching of glass/metal/stone; rust/stain/limescale removers |
| Sulfuric acid | Manufacturing of fertilizers, textile fibers, explosives, paper |
| Hydrochloric acid | Production of fertilizers, dyes, paints; used in food processing |
| Chromic acid | Used in metal treatments |
| Nitric acid | Production of fertilizers and explosives; in cleaning products |
| Phosphoric acid | Used in fertilizer, pharmaceuticals, water treatment |
| **Organic acids** | |
| Formic acid | Used as a neutralizer in leather manufacturing |
| **Alkalis** | |
| Sodium hydroxide | Used in the manufacture of bleaches, dyes, vitamins, pulp, paper, plastics, soaps and detergents |
| Calcium oxide | |
| **Metal salts** | |
| Arsenic trioxide | Aerosolized in the smelting of metals |
| Beryllium compounds | Used in the production of hard, corrosion-resistant alloys |
| **Solvents** | |
| Stoddard solvent | Used in dry cleaning |
| Water | Ubiquitous |
| **Alcohols** | |
| Glycols | Commonly used in cosmetic products |
| **Detergents and cleansers** | |
| Sodium lauryl sulfate | Detergents and cleansers |
| Cocamidopropyl betaine | Detergents, therapeutic formulations, personal care products |
| **Disinfectants** | |
| Ethylene oxide | Medical sterilization |
| Chloroxylenol | Baby powders and shampoos |
| Iodines | Surgical scrub, shampoo, skin cleansers |
| Benzalkonium chloride | Used for instrument cleansing; in ophthalmic solutions |
| **Food** | Pineapples, garlic, mustard |
| **Plants** | Thistles, prickly pears, grasses |
| **Plastics** | |
| **Bodily fluids** | |
| **Fabric/man-made vitreous fibers (e.g. fiberglass)** | |

**Table 12.2 Common irritants and examples of major exposure(s).** *Courtesy, David Cohen, MD.*

- Thimerosal – found as a preservative in vaccines, contact lens solution, antiseptics, and cosmetics.
- Quaternium-15 – formaldehyde-releasing preservative; found in shampoos, moisturizers, cosmetics, and soaps.
- Methylisothiazolinone (MI)/methylchloroisothiazolinone (MCI) – MI is sometimes present in combination with MCI or alone in sanitary wet wipes, make-up removal wipes (see Fig. 12.8), liquid soaps, as well as paints.




**Fig. 12.6 Allergic contact dermatitis to shoes – acute versus chronic. A** Extremely pruritic erythematous papules and papulovesicles appeared within days of wearing new sneakers; note the distribution pattern. **B** Pebbled and lichenified plaques with both hypo- and hyperpigmentation. The patient had a positive patch test to potassium dichromate. *Courtesy, Louis A. Fragola, Jr., MD.*



**Fig. 12.7 Acute vesiculobullous allergic contact dermatitis.** The allergen was neomycin from a topical antibiotic ointment. *Courtesy, Jonathan Chan, MD.*

## Other Important Allergens

### Topical Corticosteroids

- Can cause ACD in up to 6% of patients.
- Consider CS allergy if an existing dermatitis worsens with CS use or fails to clear; testing with topical tixocortol pivalate (group 1) and budesonide (group 1) will detect ~75% of CS allergy.
- If CS allergy is suspected/confirmed, use of a CS from a different class can be considered (see Appendix).

### Other

Additional allergens include paraphenylenediamine in temporary tattoos (see Fig. 12.10) and hair dyes, propolis in lip balms, acrylates in artificial nails, thiuram in rubber and makeup applicators, formaldehyde resin in nail polish, components of adhesives, and blue dyes in textiles.

## Systemic Contact Dermatitis

- Systemic exposure to a chemical/allergen to which the patient has had prior sensitization (Table 12.4; Fig. 12.17); e.g. administration of oral diphenhydramine to a patient previously sensitized to the topical formulation.

## Occupational Dermatoses

- Most commonly an irritant (e.g. to soaps) > allergic contact dermatitis (e.g. to rubber).
- Other occupational dermatoses include contact urticaria (see Ch. 14), skin cancer, folliculitis (see Ch. 31), contact leukoderma (see Ch. 54), foreign body reactions, and infections (Table 12.5).

## Plant Dermatoses

- Plants can cause a variety of skin reactions, including ACD (Fig. 12.12), ICD, urticaria, and phytophotodermatitis (Table 12.6).
- ACD to plants that contain urushiol.
  - Commonly secondary to poison ivy, genus *Toxicodendron* (Fig. 12.20) – compound leaves with three leaflets and flowers/fruits arising from the



**Fig. 12.8 Acute allergic contact dermatitis with a prominent component of edema.** The allergen was methylisothiazolinone in a wet wipe used to remove make-up. *Courtesy, Rosemary L. Nixon, MD.*



**Fig. 12.10 Allergic contact dermatitis to *p*-phenylenediamine in a temporary tattoo.** *Courtesy, Rosemary L. Nixon, MD.*



**Fig. 12.9 Chronic allergic contact dermatitis due to glutaraldehyde.** The patient was an optometrist. This presentation can also be seen in irritant contact dermatitis and distinction can be difficult without patch testing. *Courtesy, Kalman Watsky, MD.*



**Fig. 12.11 Airborne contact dermatitis.** The allergen was an epoxy resin. *Courtesy, Rosemary L. Nixon, MD.*

axillary position; black dots of urushiol often present on leaves
- Chemicals that cross-react with urushiol are found in the cashew nut tree (nutshell oil and bark), mango tree (leaves, bark, stems, fruit skin), Brazilian pepper tree (sap and crushed berries), Japanese lacquer tree (bark sap), Indian marking tree nut (black juice), and Ginkgo tree (seed coat)
- Allergen-containing smoke can cause respiratory tract inflammation, systemic contact dermatitis, and temporary blindness
- After contact with urushiol, a sensitized person develops erythema, vesicles/bullae, and edema within 2 days; the reaction can last 2 or 3 weeks (see Fig. 12.12)
- **Rx:** topical, or if severe, systemic CS; treatment should be for at least 2 weeks, otherwise rebound phenomenon common (i.e. avoid the use of a 6-day Medrol® dose pack)




**Fig. 12.12 Clinical manifestations of Anacardiaceae dermatitis.** *Acute poison ivy dermatitis:* **A** Periorbital edema, in addition to crusted and weeping linear streaks and plaques. **B** This distribution pattern is seen in patients who wear gloves. **C** Erythematous streaks with linear vesicles. **D** "Black-spot" dermatitis: Note the black discoloration in the central portion of the edematous plaques due to plant resin. *Other:* **E** Allergic contact dermatitis due to cashew nut shell oil. This represented an occupational exposure. **F** Weed-whacker dermatitis with widespread spotted pattern. *A, F, Courtesy Louis A. Fragola, Jr., MD; B, E, Courtesy, YDRSC; C, Courtesy, Joyce Rico, MD; D, Courtesy, Kalman Watsky, MD.*

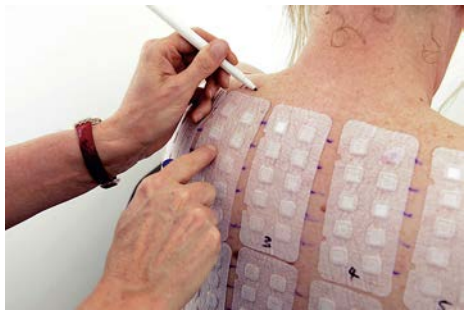

**Fig. 12.13 Placement of allergens to the patient's back utilizing AllergEAZE™ chambers.** *Courtesy, Rosemary L. Nixon, MD.*



**Fig. 12.14 Sites of specific patch tests labelled for future reference following removal of the chambers.** *Courtesy, Rosemary L. Nixon, MD.*

| INTERNATIONAL GRADING SYSTEM FOR PATCH TESTS | | |
|---|---|---|
| +/– | 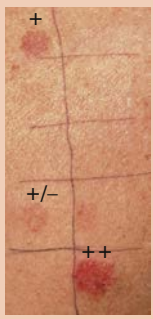 | Doubtful reaction, faint macular erythema |
| + | | Weak, non-vesicular reaction with erythema, infiltration, and papules |
| ++ | | Strong, vesicular reaction with infiltration and papules |
| +++ | | Spreading bullous reaction |
| – | | Negative reaction |
| IR | | Irritant reaction |

*Grading is performed at two time points after the patch tests have been in place for 48 hours (then removed; see Fig. 12.14): initially after removal and then 1–7 days later.*

**Table 12.3 International grading system for patch tests.**



**Fig. 12.15 Allergic contact dermatitis to nickel.** Excoriated pink plaques due to nickel within the belt buckle. Inset: A positive dimethylglyoxime test in which the pink color indicates the presence of nickel. *Courtesy, Julie V. Schaffer, MD; Inset: Courtesy, Rosemary L. Nixon, MD.*

- Phytophotodermatitis
  - Non-immunologic reaction to topical contact with a photosensitizer and subsequent exposure to ultraviolet A light
  - Erythema, vesicles/bullae, and subsequent hyperpigmentation; often in linear streaks or bizarre configurations; however, hyperpigmentation may be the only clinical finding (Figs 12.21 and 12.22)
  - Commonly secondary to furocoumarins (psoralens and angelicins) in plants, e.g. limes, celery, false Bishop's weed, and rue

For further information see Chs 14–17 from *Dermatology, Fourth Edition*.

**For additional online figures and tables visit www.expertconsult.com**

Downloaded for Novin lib (novinlibrary@yahoo.com) at United Arab Emirates University from ClinicalKey.com by Elsevier on March 26, 2022. For personal use only. No other uses without permission. Copyright ©2022. Elsevier Inc. All rights reserved.

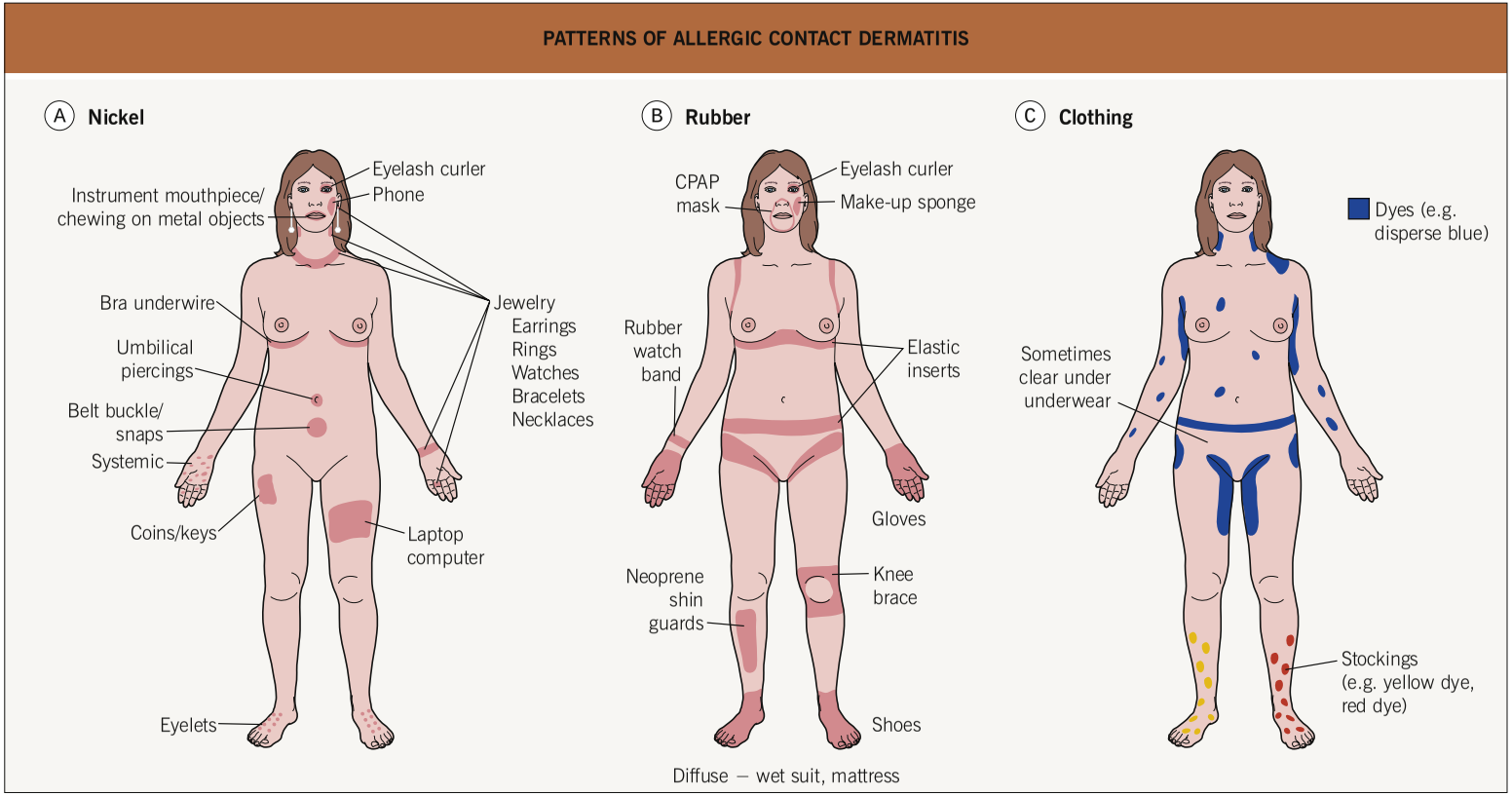


**Fig. 12.16 Patterns of allergic contact dermatitis.** **A** Due to nickel; lesions can also arise from metal braces and on the back at the site of bra clasps. **B** Due to rubber. **C** Due to dyes and resins in clothing. CPAP, continuous positive airway pressure. *Courtesy, Jean L. Bolognia, MD.*

| EXAMPLES OF TOPICAL ALLERGENS THAT MAY RESULT IN SYSTEMIC CONTACT DERMATITIS AFTER SYSTEMIC EXPOSURE | |
|---|---|
| **Cutaneous allergen** | **Systemic exposure** |
| Ethylenediamine hydrochloride | Aminophylline, hydroxyzine/cetirizine |
| Poison ivy | Cashews, mango peel |
| Fragrance (balsam of Peru) | Foods, sodas, mouthwashes, spices |
| Sorbic acid | Preservative in food |
| Nickel and other metal salts | Nickel (and other metal salts) in food |
| Quinolones | Oral antibiotics |
| Neomycin | Streptomycin, kanamycin |
| Thiuram | Disulfiram |

**Table 12.4 Examples of topical allergens that may result in systemic contact dermatitis after systemic exposure.**



**Fig. 12.17 Systemic contact dermatitis.** This patient, who was previously sensitized to ethylenediamine, received intravenous aminophylline. *Courtesy, YDRSC.*



**Fig. 12.18 Fiberglass dermatitis.** Multiple pruritic pink papules at the site of exposure. *Courtesy, NYUDSC.*



**Fig. 12.19 Chloracne.** Note involvement of retroauricular skin with numerous comedones (primarily closed) and cysts. The clinical differential diagnosis includes folliculotropic mycosis fungoides.

| SELECTED OCCUPATIONAL DERMATOSES | |
|---|---|
| **Dermatosis** | **Key features** |
| Fiberglass dermatitis (Fig. 12.18) | Pruritus, tingling |
| | Erythematous papules (sometimes with follicular accentuation) |
| | Paronychia |
| Skin cancer | Major hazards are ultraviolet radiation, ionizing radiation, and carcinogenic chemicals |
| | Most common tumor is squamous cell carcinoma |
| Acne | Clinical features similar to non-occupationally related acne |
| | In addition, unusual sites may be affected (arms, abdomen) |
| | Inciting factors – exposures to oils, halogenated polycyclic hydrocarbons (chloracne), and repeated frictional trauma |
| | Chloracne – open comedones predominate; concentration of lesions on malar cheeks and behind ears (Fig. 12.19) |
| White finger(s) | Workers at risk include operators of chainsaws and pneumatic tools with exposures to vibrations from 30 to 300 Hz and cold |
| | Transient loss of sensation with possible permanent neuropathy |
| Orf | Seen in farmers, slaughterhouse workers, veterinarians |
| | Secondary to a parapoxvirus from exposure to sheep, goats, or reindeer |
| Herpetic whitlow | Exposure to herpes simplex virus, e.g. health care workers |
| Erysipeloid | Seen in farmers, fishermen, butchers |
| | Exposure to *Erysipelothrix rhusiopathiae* in shellfish, fish, birds, and mammals, especially pigs |

**Table 12.5 Selected occupational dermatoses.**

| MOST COMMON SKIN REACTIONS TO PLANTS | | |
|---|---|---|
| **Reaction type** | **Plants/fruit** | **Inciting agent** |
| Allergic contact dermatitis | Poison ivy | Alkyl-catechols and resorcinols in urushiol |
| | Peruvian lily | Tulipalin A > B |
| | Chrysanthemum | Sesquiterpene lactones* |
| Irritant contact dermatitis | Dumb cane | Calcium oxalate |
| | Daffodils | Calcium oxalate |
| | Prickly pear | Glochids |
| Urticaria | Stinging nettle | Histamine |
| Phytophotodermatitis | Persian lime | Furocoumarins (psoralens and angelicins) |
| | Celery | Same |
| | Rue | Same |
| Other – burning/edema | Hot peppers | Capsaicin |

**Can cause airborne contact dermatitis and positive in chronic actinic dermatitis.*

**Table 12.6 Most common skin reactions to plants.** Some plants can cause more than one reaction; e.g. garlic can cause ACD (diallyldisulfide), ICD, and urticaria.

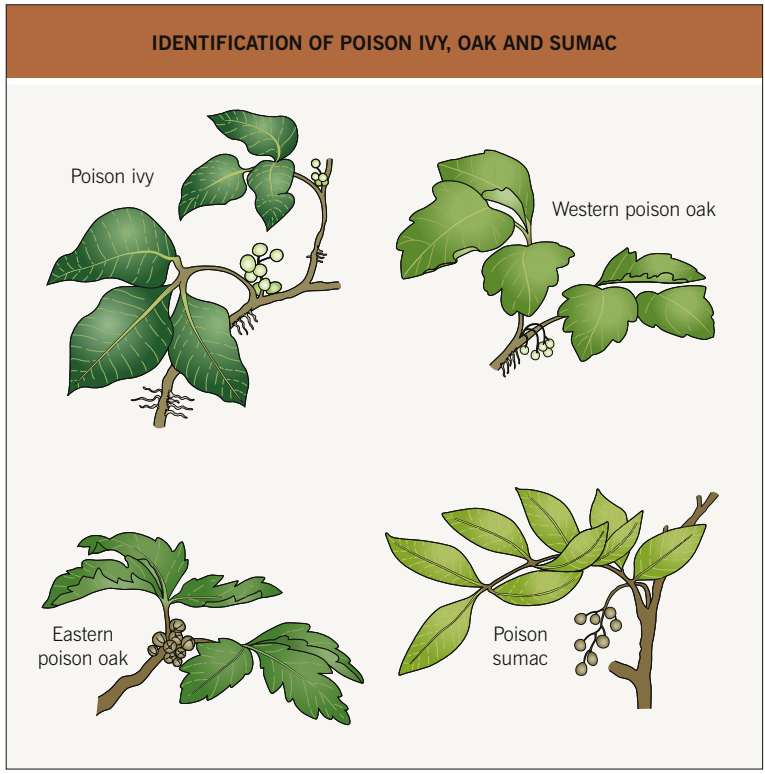


**Fig. 12.20 Characteristic features useful for identifying poison ivy, poison oak, and poison sumac.** *With permission from the American Journal of Contact Dermatitis.*



**Fig. 12.21 Bullous phase of phytophotodermatitis.** There was associated burning but no pruritus, and the linear bullae were replaced by hyperpigmentation. *Courtesy, Jean L. Bolognia, MD.*



**Fig. 12.22 Phytophotodermatitis.** Streaky hyperpigmentation due to contact with a psoralen-containing plant followed by exposure to sunlight. *Courtesy, Lorenzo Cerroni, MD.*



**eFig. 12.1 Chronic allergic contact dermatitis (ACD).** Chronic foot dermatitis due to ACD to rubber (mercaptobenzothiazole). *Courtesy, Louis A. Fragola, Jr., MD.*



**eFig. 12.2 Persistent hand dermatitis due to chronic allergic contact dermatitis.** The allergen was epoxy resin.



**eFig. 12.3 Acute allergic contact dermatitis with a prominent component of edema.** Periorbital edema, in addition to crusted and weeping plaques, due to poison ivy. *Courtesy, Jean L. Bolognia, MD.*



**eFig. 12.4 Allergic contact dermatitis due to aloe-containing cream.** The degree of involvement on the upper and lower lips is similar, as opposed to actinic cheilitis. *Courtesy, YDRSC.*

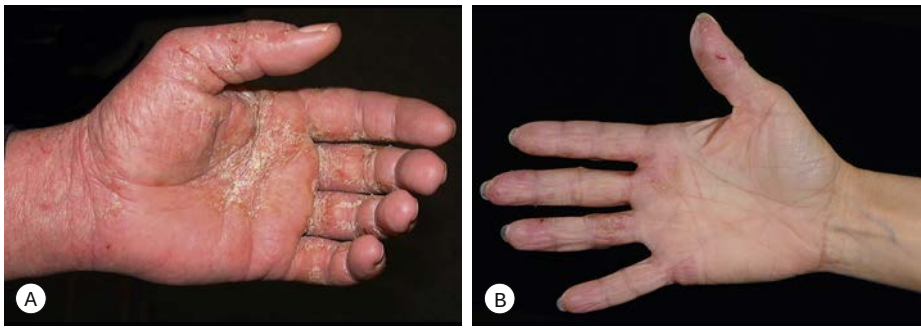


**eFig. 12.5 Persistent hand dermatitis due to chronic allergic contact dermatitis. A** In this machine operator, the allergen was black rubber. **B** The allergen was methylisothiazolinone in sanitary wet wipes.

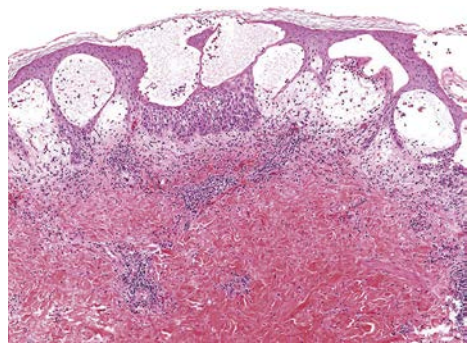

**eFig. 12.6 Allergic contact dermatitis (ACD) – histologic features.** Acute ACD with marked spongiosis leading to intraepidermal vesiculation. There is a perivascular infiltrate of lymphocytes and eosinophils as well as exocytosis of these cells into the epidermis. *Courtesy, Lorenzo Cerroni, MD.*




**eFig. 12.7 Patch test reactions.** **A** +/– to + reaction. **B, C** + reaction. **D** ++ reaction. **E** +++ reaction. **F** Erythematous papules at the edge of the Finn chamber application site (rim or edge effect). **G** Pustular irritant reaction at the site of the application of a metalworking fluid. The adjacent skin impression of a chamber reflects good adherence. **H** Three different patch test reactions: +/– to quaternium-15, + to formaldehyde, and ++ to nickel. *C, F, H, Courtesy, Kalman Watsky, MD.*




**eFig. 12.8 Allergic contact dermatitis to fragrance found in cologne. A** Patient at the time of diagnosis. **B** Patient after avoidance of fragrances and his cologne.



**eFig. 12.9 Airborne contact dermatitis.** The allergen was an epoxy resin. Note the involvement of the eyelids.



**eFig. 12.11 Cement burns.** Ulcerations on the fingertips of a construction worker exposed to wet cement. *Courtesy, P.J. Coenraads, MD.*



**eFig. 12.10 Hand of a builder who presented with a dyshidrotic (pompholyx) pattern of eczema.** Investigation demonstrated allergic contact dermatitis to chromate found in cement and contact urticaria to latex in the gloves he was using for hand protection.



**eFig. 12.12 Airborne contact dermatitis.** This farmer from Gujarat, India was allergic to the sesquiterpene lactones in *Parthenium hysterophorus*. *Courtesy, Shyam Verma, MBBS, DVD, FRCP.*




**eFig. 12.13 Allergic contact dermatitis in a florist.** **A** Florist with fingertip *Alstroemeria* allergic contact dermatitis showing how he holds a Peruvian lily while cutting off the leaves. **B** Index finger of the same florist, showing the chronic, lichenified, hyperkeratotic dermatitis caused by allergy to Peruvian lily and tulipalin A. *Photos with permission from the American Journal of Contact Dermatitis. 1999;10(3):172–6.*




**eFig. 12.14 Chronic allergic contact dermatitis leading to hand dermatitis.** This golfer wore one leather glove and had positive patch tests to potassium dichromate and a piece of his glove. *Courtesy, Kalman Watsky, MD.*




**eFig. 12.15 Allergic contact dermatitis to leather shoes.** Note the correspondence to sites of exposure.



**eFig. 12.16 Hand dermatitis in a florist who handled *Alstroemeria* and had a positive patch test to tuliposidase A.** Erythema, scaling, and fissures of the fingers are seen.



**eFig. 12.17 Contact urticaria of the fingers after wearing latex rubber gloves.** Although signs can be subtle, the implications of making the diagnosis are significant.



**eFig. 12.18 Airborne contact dermatitis.** Example of the airborne contact dermatitis pattern seen in a patient allergic to sesquiterpene lactones. Note involvement of the submental region and upper anterior neck, which would not be expected if this were a photodermatitis. *Courtesy, Dirk Elston, MD.*



**eFig. 12.19 Acute vesiculobullous allergic contact dermatitis (ACD).** The allergen was urushiol in poison ivy; this distribution pattern is seen in patients who wear gloves.



**eFig. 12.20 Allergic contact dermatitis to neomycin.** Note the erythema and edema of the upper eyelids.



**eFig. 12.21 Treatment of tinea with topical corticosteroid resulted in an appearance resembling dermatitis.** Note nail dystrophy in one hand.



**eFig. 12.22 Erythematous, burning, edematous scrotum from irritant reaction after applying garlic (*Allium sativum*) to treat a "rash."** *Courtesy of Dr Martin Giandoni.*

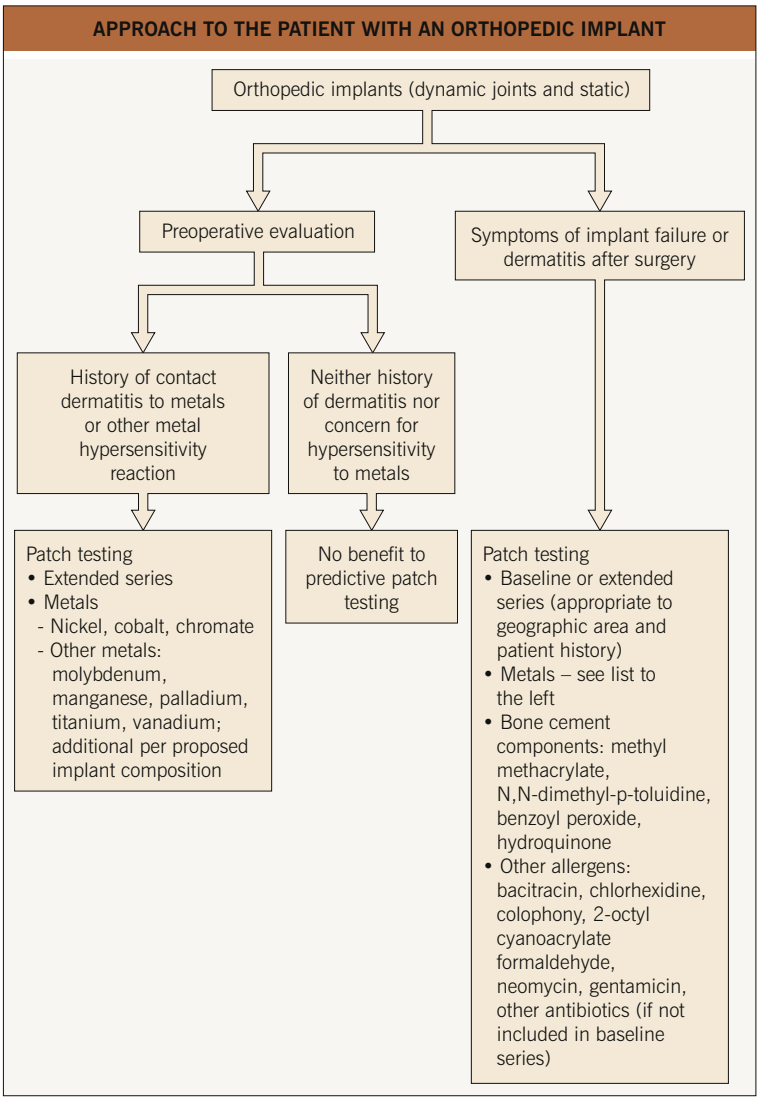


**eFig. 12.23 Approach to the patient with an orthopedic implant.** *Adapted from Schalock PC, Menné T, Johansen JD, et al. Contact Derm. 2011;66:4–19.*

| GUIDELINES AIMED AT PREVENTING CONTACT DERMATITIS | | |
|---|---|---|
| **Advice** | | **Explanation** |
| Do not wear rings | | • Chemicals/water accumulate underneath |
| Hand washing | • Use lukewarm water and dry thoroughly | • Skin damage from detergent is reduced at a low temperature<br>• Dermatitis often begins at sites that are missed, e.g. fingerwebs |
| Wear gloves | • For wet work | • Wet work is the major risk factor for contact dermatitis |
| | • For as short a time period as possible | • Glove occlusion also damages the skin |
| | • With a cotton inner liner if prolonged exposure | • Liners absorb moisture and reduce irritation |
| | • That are dry, clean and intact | • Occlusion of chemicals inside gloves increases irritancy |
| Use moisturizer | • Frequently throughout the day | • Encourages barrier repair |
| | • To the whole hand | • Need to include web spaces |
| | • That is fragrance-free and preservative-free | • Prevents sensitization and development of ACD to common allergens |
| For antisepsis | • Use alcohol gel | • Less irritating than soaps or antiseptic detergents |
| Follow the same advice at home | | • Domestic exposures are additive |

**eTable 12.1 Guidelines aimed at preventing contact dermatitis.** ACD, allergic contact dermatitis.

# Clinical Approach to Regional Dermatoses

# 13

- Some inflammatory, infectious, metabolic, neoplastic, and genetic skin conditions have a predilection for particular areas of the body.
- This chapter addresses the diagnosis and treatment of regional dermatoses affecting the hands, feet, intertriginous regions, diaper area, lips, and eyelids.

## Dermatitis of the Hands and Feet

- An approach to the classification of hand dermatitis is presented in Fig. 13.1, and the differential diagnosis of foot dermatitis is summarized in Table 13.1.
- Because the hands and feet have a thicker stratum corneum than other areas of the body, percutaneous absorption of topical medications is decreased.
- High-potency topical CS or the use of occlusion may be needed to effectively treat inflammatory dermatoses in these sites.

## Intertriginous Dermatitis

- Intertriginous areas include the inguinal creases, gluteal cleft, axillae, inframammary folds, and beneath pannus in obese patients.
- The differential diagnosis of dermatitis in the major skin folds is presented in Fig. 13.2.
- Other conditions with a predilection for intertriginous regions include skin tags, acanthosis nigricans, hidradenitis suppurativa, Fox–Fordyce disease, scabies, erythema migrans, variants of lichen planus (e.g. inverse, pigmentosus), inverse pityriasis rosea, vitiligo, lentigines in the setting of neurofibromatosis type 1, Dowling–Degos disease, and pseudoxanthoma elasticum.
- Occlusion and a high level of cutaneous hydration in intertriginous sites increase the absorption of topical medications.
- Low-potency topical CS are often effective for dermatoses in these areas, and prolonged use of more potent agents (including antifungal combination products; see below) has increased potential to result in side effects such as cutaneous atrophy (Fig. 13.3).

## Diaper Dermatitis

- Develops in >50% of infants and has a variety of causes (Fig. 13.4).
- Dampness and exposure to urine and feces represent factors in the etiology of irritant and infectious forms of diaper dermatitis.
- Frequent changing of highly absorbent disposable diapers decreases the incidence and severity of diaper dermatitis.
- Seborrheic dermatitis and psoriasis in the diaper area predispose infants and toddlers to other forms of diaper dermatitis.
- An exuberant, multifactorial diaper dermatitis (e.g. sebopsoriasis with *Candida* or bacterial superinfection) can trigger the rapid development of numerous small, scaly erythematous papules in a widespread distribution on the trunk and extremities (psoriasiform "id" reaction).
- Mild topical CS are helpful for the inflammatory component of irritant dermatitis and primary dermatoses in the diaper area, while topical imidazole creams treat candidiasis and have additional anti-inflammatory effects; these agents can be used together for seborrheic dermatitis or psoriasis.
- Combination products containing a potent CS (e.g. Lotrisone® [clotrimazole + betamethasone dipropionate], Mycolog® [nystatin + triamcinolone]) and long-term daily use of any CS in the diaper area should be avoided (see above).
- Barrier ointments containing zinc oxide provide protective and soothing effects; a thick layer should be used (following application of anti-inflammatory/antimicrobial agents if needed) with each diaper change in patients with diaper dermatitis.

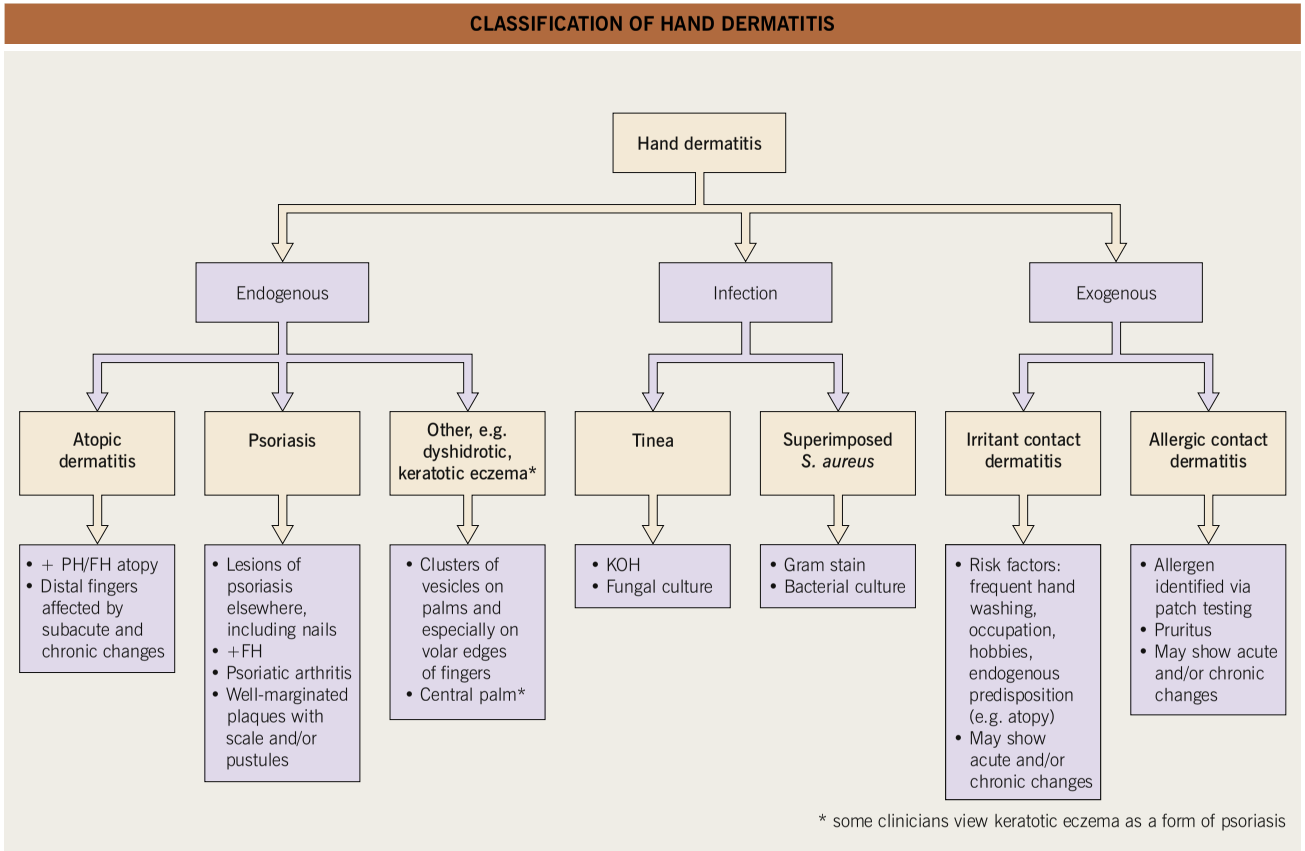


**Fig. 13.1 Classification of hand dermatitis.** More than one etiology may be present, e.g. atopic dermatitis plus irritant contact dermatitis. FH, family history; PH, personal history. *Courtesy, David E. Cohen, MD.*

| DIFFERENTIAL DIAGNOSIS OF FOOT DERMATITIS |
|---|
| **Allergic contact dermatitis** |
| • Location of the dermatitis on the dorsal surface versus plantar surface (especially weight-bearing areas) of the feet can reflect an allergen in the top portion or sole of the shoe, respectively<br>• Common shoe allergens include dichromate (used to tan leather), adhesive components (e.g. formaldehyde resins, colophony), rubber accelerators, and dyes; allergens implicated in foot dermatitis also include topical antibiotics (e.g. bacitracin)<br>• Often associated with atopy and/or hyperhidrosis<br>• Lesions extend more proximally in sock/stocking dermatitis, where the most common allergen is azo dyes |
| **Dyshidrotic eczema** |
| • Pruritic, deep-seated vesicles (often pinhead-sized) on the palms/soles and sides of the fingers/toes<br>• Referred to as "pompholyx" when larger vesicles/bullae are present<br>• Frequently associated with atopy or contact dermatitis (allergic and irritant) |
| **Juvenile plantar dermatosis** |
| • "Glazed" erythema, scale and fissuring on the balls of the feet and plantar aspect of the toes<br>• Usually occurs in prepubertal children<br>• Associated with atopic dermatitis, sweaty feet, and occlusive footwear |
| **Tinea pedis (athlete's foot)** |
| • Dermatophyte infections of the plantar skin are usually accompanied by involvement of the interdigital spaces (e.g. maceration)<br>• A "moccasin" distribution of diffuse scaling/erythema and a vesicular inflammatory variant favoring the medial foot can also occur<br>• Lesions on the lateral and dorsal aspects of the feet tend to have an annular configuration<br>• Often associated with tinea unguium |
| **Psoriasis** |
| • Usually well-demarcated areas of erythema, adherent scale, and often fissuring<br>• Psoriasiform plaques elsewhere (e.g. dorsal hands/feet, elbows/knees, scalp) and nail involvement (e.g. pitting, oil spots) |
| **Pustulosis of the palms and soles** |
| • "Sterile" pustules admixed with yellow-brown macules favoring the instep<br>• Often *not* associated with plaque psoriasis elsewhere<br>• Keratoderma blennorrhagicum occurs in the setting or reactive arthritis |
| **Keratolysis exfoliativa (recurrent focal palmar and plantar peeling)** |
| • Circinate pattern of superficial desquamation (collarettes) on the palms and/or soles<br>• Worsens in warm weather and is associated with low-grade irritation/friction |
| **Keratoderma climactericum** |
| • Mechanically induced hyperkeratosis and fissuring on the heels and weight-bearing areas of the soles<br>• Typically occurs in women >45 years of age<br>• Predisposing factors include obesity and a cold, dry climate |
| **Other** |
| • Atopic dermatitis<br>• Irritant contact dermatitis (e.g. related to occlusive footwear)<br>• Crusted scabies<br>• Pityriasis rubra pilaris<br>• Inherited palmoplantar keratoderma (diffuse or focal)<br>• Acquired keratoderma, e.g. associated with hypothyroidism |

**Table 13.1 Differential diagnosis of foot dermatitis.**

## DIFFERENTIAL DIAGNOSIS OF INTERTRIGINOUS DERMATOSES IN ADULTS

**Common** → **Less common** → **Uncommon**

**Irritant/frictional intertrigo***
- Ill-defined erythema/maceration
- Predisposing factors: obesity, heat & humidity, hyperhidrosis, diabetes mellitus, poor hygiene
- Secondary infections common

**Seborrheic dermatitis****
- Well-demarcated, pink to red, moist patches/plaques
- Centered along inguinal creases
- Involvement of scalp, face, ears

**Inverse psoriasis****
- Well-demarcated, pink to red plaques
- Shiny with little scale in folds
- Centered along inguinal creases
- Psoriasiform plaques elsewhere (e.g. genitals, intergluteal cleft, scalp, elbows/knees, hands/feet)
- Nail psoriasis (pitting, oil spots)



**Dermatophytosis (tinea cruris)**
- Less often centered along inguinal creases
- Expanding annular lesions with scaly erythematous border that may contain pustules or vesicles
- Extension to inner thigh, buttock; usually spares scrotum
- Coexisting tinea pedis/unguium very common



**Candidiasis**
- Intense erythema with desquamation and satellite papules/pustules
- Often involves scrotum as well as skin folds
- Predisposing factors: occlusion, hyperhidrosis, diabetes mellitus, antibiotic or corticosteroid use, immunosuppression



**Erythrasma**
- Pink–red to brown patches with fine scale
- Coral-red fluorescence with Wood's lamp illumination

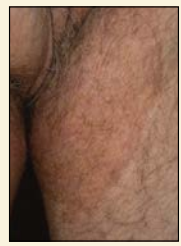

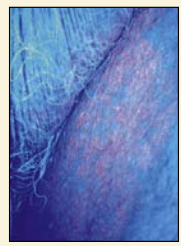

**Allergic contact dermatitis**
- Consider if fails to respond to usual therapy

**Granular parakeratosis**



**Systemic contact dermatitis, symmetrical drug-related intertriginous and flexural exanthema (Table 13.2), toxic erythema of chemotherapy**

**Hailey–Hailey disease, Darier disease** (depicted)**, pemphigus vegetans**



**Zinc deficiency, necrolytic migratory erythema, other "nutritional dermatitis"**

**Cutaneous Crohn disease**



**Langerhans cell histiocytosis**



**Extramammary Paget disease**



*Also referred to more nonspecifically as intertriginous dermatitis or intertrigo.
**The term "sebopsoriasis" may be used when features of both seborrheic dermatitis and psoriasis are present.

**Fig. 13.2 Differential diagnosis of intertriginous dermatitis in adults.** Individual patients often have multiple disorders superimposed upon one another. Bullous impetigo and streptococcal intertrigo are considerably more common in children than adults (see Fig. 13.4). *Insets: Courtesy, Luis Requena, MD; YDRSC; Eugene Mirrer, MD; Louis A. Fragola, Jr., MD; David Mehregan, MD and Robert Hartman, MD.*



**Fig. 13.3 Cutaneous atrophy in the inguinal fold from chronic use of a topical CS.** This 10-year-old girl's seborrheic dermatitis had been treated with a mid-potency topical CS on a daily basis for several years, resulting in the development of striae. *Courtesy, Julie V. Schaffer, MD.*

## Cheilitis

- The differential diagnosis of cheilitis and clues to determining the etiology are outlined in Fig. 13.5.

## Eyelid Dermatitis

- An approach to the classification of eyelid dermatitis is presented in Fig. 13.6.

**SYMMETRICAL DRUG-RELATED INTERTRIGINOUS AND FLEXURAL EXANTHEMA (SDRIFE): CLINICAL CRITERIA**

- Exposure to a systemically administered drug*, occurring with either the initial or a repeated dose (excluding contact allergens)
- Sharply demarcated erythema of the gluteal/perianal area and/or V-shaped erythema of the inguinal/genital area
- Involvement of at least one other intertriginous site/flexural fold
- Symmetric involvement in affected areas
- Absence of systemic symptoms and signs

**Not a chemotherapeutic agent, so distinct from toxic erythema of chemotherapy.*

**Table 13.2 Symmetrical drug-related intertriginous and flexural exanthema (SDRIFE): clinical criteria.** This entity is also referred to as drug-induced intertrigo, flexural drug eruption, and baboon syndrome. The latter term is also used for a form of systemic contact dermatitis. *Adapted from Häusermann P, Harr TH, Bircher AJ. Baboon syndrome resulting from systemic drugs: Is there strife between SDRIFE and allergic contact dermatitis syndrome? Contact Dermatitis 2004;51:297–310.*

- Low-potency topical CS are often effective for dermatitis on the eyelids because of the delicate skin in this site, and prolonged CS use (especially of more potent agents) may potentially lead to ocular side effects.

For further information see Chs 13 and 15 from *Dermatology, Fourth Edition*.

**For additional online figures and tables visit www.expertconsult.com**

## DIFFERENTIAL DIAGNOSIS OF DIAPER DERMATITIS

Common → Less common → Rare

### Irritant contact dermatitis
- Glazed erythema ± scale → "punched out" erosions
- Favors convex surfaces, often spares folds
- Prolonged contact with urine/feces (esp. if diarrhea), friction
- Over time pseudoverrucous papules can develop




### Candidiasis
- Intense erythema with desquamation/ superficial erosions & peripheral scale/collarettes
- Satellite pustules
- Favors folds, genitalia
- Yeast/pseudohyphae on KOH preparation
- ± Recent antibiotic use, thrush



### Seborrheic dermatitis
- Well-demarcated, salmon-colored to red, moist or scaly patches and plaques
- Favors folds
- Involvement of other flexural sites, scalp



### Bacterial infections

***Bullous impetigo***
- Flaccid bullae, vesiculopustules, superficial shiny red erosions with a collarette of scale
- Gram stain +



***Streptococcal intertrigo & perianal/ vulvovaginal infection***
- Sharply demarcated, bright red erythema
- Usually no satellite lesions
- Perianal and vulvovaginal area, skin folds
- Pain, itch, foul odor
- ± Pharyngitis in patient or family members



### Psoriasis
- Well-demarcated erythematous plaques
- Shiny in folds, scaly on convex surfaces
- Psoriasiform lesions elsewhere, ± family history



### Allergic contact dermatitis*
- Consider if fails to respond to usual therapy
- "Holster" distribution if reaction to rubber additives in diaper elastics
- May affect folds if reaction to components of baby wipes or topical preparations

### Atopic dermatitis (AD)
- Excoriations, lichenification
- Favors skin at diaper margins and convex surfaces
- Often relative sparing of the diaper area
- Marked pruritus
- Other pruritic eczematous lesions in usual sites of AD

### Acrodermatitis enteropathica, other forms of "nutritional dermatitis"



### Langerhans cell histiocytosis



### Other infections (e.g. congenital syphilis, dermatophytosis)

### Granular parakeratosis

### Early Kawasaki disease (see Fig. 3.10)

*Potential allergens include sorbitan sesquioleate (an emulsifier in diaper balms), fragrances, disperse dyes, rubber additives (e.g. mercaptobenzothiazole), preservatives in baby wipes, and diaper components.

**Fig. 13.4 Differential diagnosis of diaper dermatitis.** Patients often have a combination of disorders, one superimposed upon another. The spectrum of "erosive papulonodular dermatosis" due to chronic irritation in the diaper area includes granuloma gluteale infantum, perianal pseudoverrucous papules, and Jacquet erosive dermatitis. Discrete papules or nodules can also be seen in scabies. Coxsackievirus infection and congenital syphilis may present with erosions in this location. *Insets: Courtesy, Robert Hartman, MD; and Julie V. Schaffer, MD.*

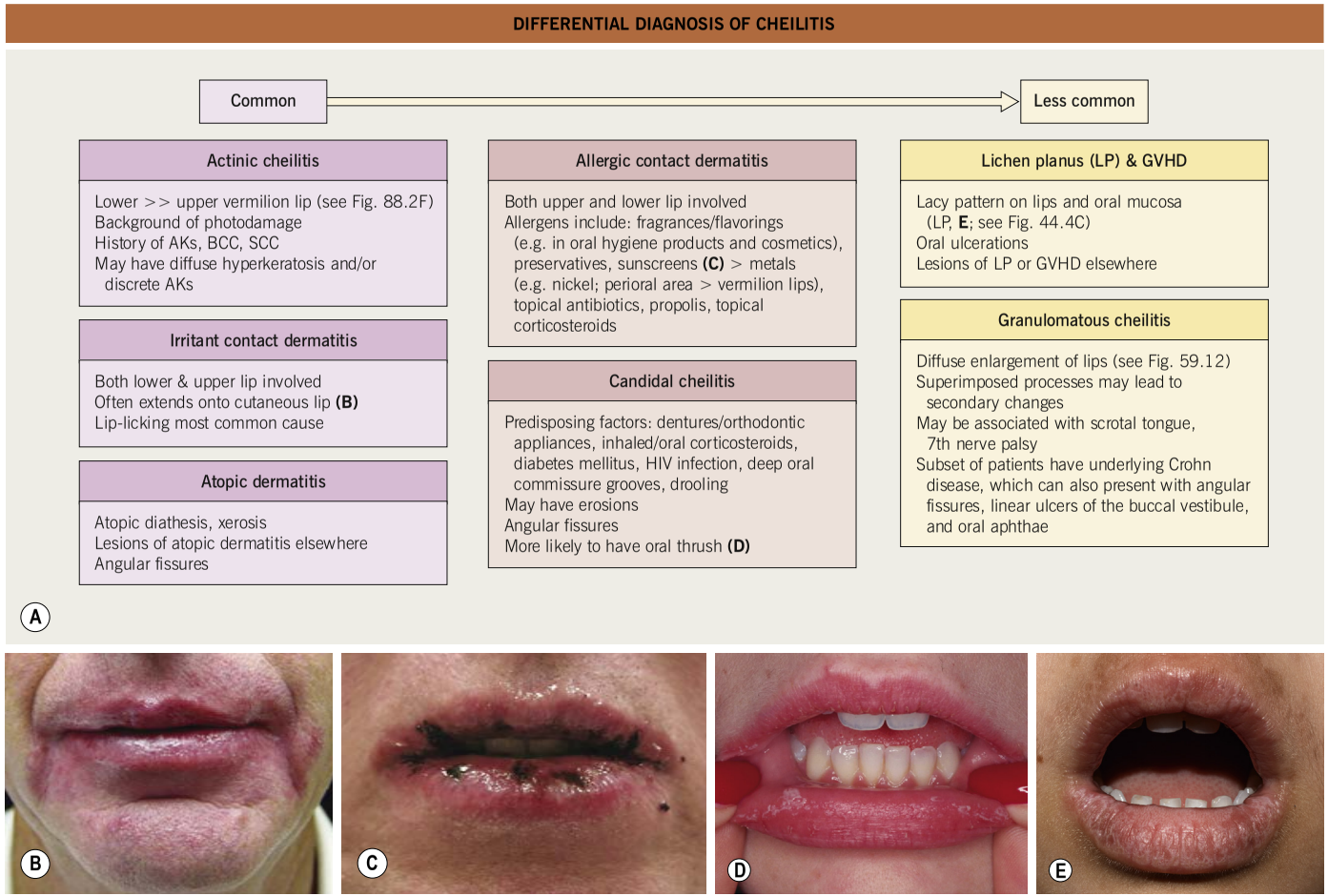


**Fig. 13.5 Differential diagnosis of cheilitis.** **A** Multiple etiologies are often present, e.g. atopic dermatitis plus irritant contact dermatitis. Other uncommon causes include cheilitis glandularis, actinic prurigo, lichen sclerosus, and nutritional deficiencies. **B** Irritant contact dermatitis – this patient had the habit of licking his lips and there is involvement of the vermilion and cutaneous lips as well as the perioral region. **C** Allergic contact dermatitis to oxybenzone with involvement of the upper and lower lips. **D** Thrush and candidal cheilitis. **E** Lichen planus presenting with a lacy pattern on the lips in a young boy. *A, Courtesy, Jean L. Bolognia, MD; B, Courtesy Jeffrey Callen, MD; C, Courtesy, Kalman Watsky, MD; D, Courtesy, Louis A. Fragola, Jr., MD; E, Courtesy, Julie V. Schaffer, MD.*

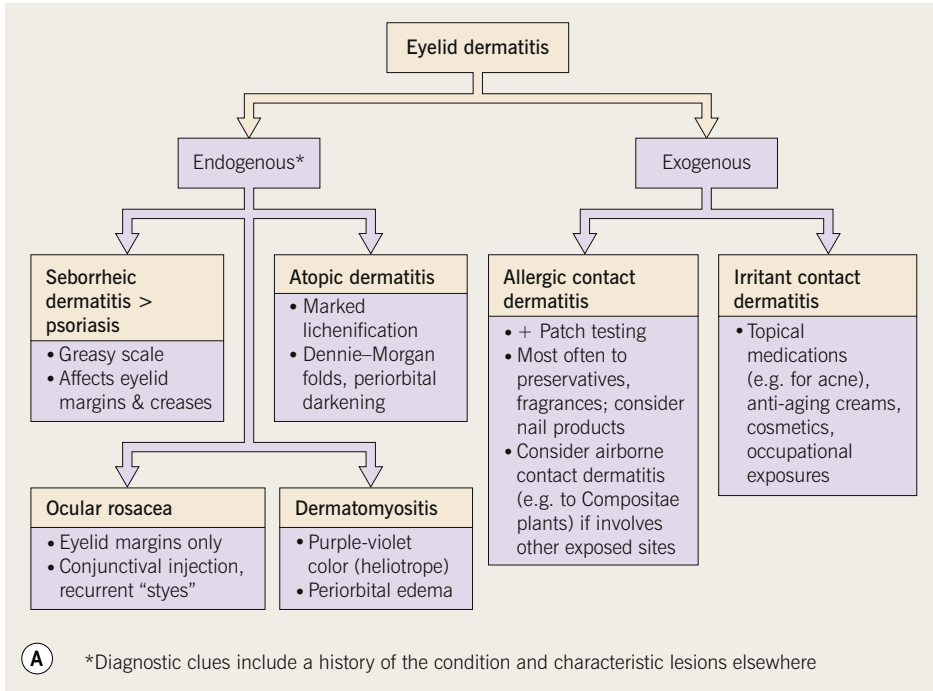


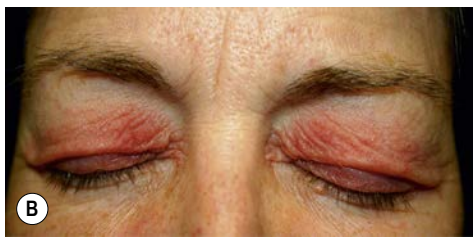





**Fig. 13.6 Classification of eyelid dermatitis.** **A** More than one etiology may be present, e.g. atopic dermatitis plus irritant contact dermatitis. **B** Allergic contact dermatitis to neomycin. **C** Airborne contact dermatitis to an epoxy resin.

# Urticaria and Angioedema

# 14

- Urticaria and angioedema can occur at any age and are estimated to have an overall lifetime prevalence of 10–25%.
- Urticaria (hives) is characterized by *wheals*: evanescent, pale to pink-red, edematous papules or plaques (Fig. 14.1); lesions often have central clearing, a peripheral erythematous flare, and associated pruritus.
- Individual wheals last <24 hours, which can be documented by outlining them with ink.
- Angioedema represents deeper dermal and subcutaneous or submucosal swelling (Fig. 14.2); affected areas are ill-defined, have minimal or no overlying erythema, and may be painful as well as pruritic.
- In addition to the skin/subcutis, angioedema can affect the mouth and respiratory or gastrointestinal tract; an area of swelling may persist for several days.
- A classification scheme and **DDx** for urticaria and angioedema are presented in Table 14.1; patients with angioedema may have associated urticaria, including physical urticaria.
- Urticaria and urticaria-associated angioedema result from the release of histamine and other proinflammatory and vasoactive




**Fig. 14.1 Wheals.** Wheals can be small **(A)** or large and annular **(B),** but they still retain the classic central pallor and erythematous flare. **C** Occasionally, more uniform edematous plaques are seen. *A, Courtesy, Jean L. Bolognia, MD; B, C, Courtesy, YDRSC.*



**Fig. 14.2 Angioedema.** The swelling is deeper than in wheals and may affect mucosal surfaces. Note the swelling of the lips and periorbital region and the lack of erythema. *Courtesy, Clive E. H. Grattan, MD.*

substances from mast cells; this leads to extravasation of plasma, vasodilatation, and pruritus.

- Stimuli for mast cell degranulation are shown in Fig. 14.3.

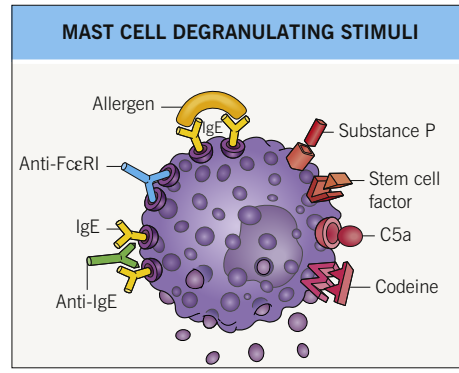


**Fig. 14.3 Mast cell degranulating stimuli.** Both immunologic and non-immunologic stimuli can lead to release of mediators. Stem cell factor is also known as KIT ligand. Autoantibodies against the high-affinity IgE receptor (FcεRI) and the Fc portion of IgE are implicated in chronic autoimmune urticaria.

**CLASSIFICATION AND DIFFERENTIAL DIAGNOSIS OF URTICARIA AND ANGIOEDEMA**

- **Spontaneous ("ordinary") urticaria**
  - Acute (duration <6 weeks)
  - Chronic (occurring at least twice weekly for ≥6 weeks*): median duration of ~2–5 years; includes an autoimmune form
- **Inducible urticaria (including physical urticaria)**
  - *Due to mechanical stimuli*: dermographism, delayed pressure urticaria†
  - *Due to temperature changes*: cold > heat-induced urticaria
  - *Due to sweating/physical exertion:* cholinergic > adrenergic urticaria, exercise-induced anaphylaxis
  - *Due to sun or water exposure:* solar and aquagenic urticaria
  - Contact urticaria (immunologic or non-immunologic)
- **Angioedema without wheals** (including hereditary angioedema; see Fig. 14.10)
- Related conditions in **DDx****: Schnitzler syndrome, serum sickness-like reaction (see Ch. 17), urticarial vasculitis† (see Ch. 19), hereditary autoinflammatory (e.g. periodic fever) syndromes (see Table 3.2)
- Additional **DDx:**
  - *For transient urticarial lesions*: Still disease, scombroid poisoning, erythema marginatum, cutaneous mastocytosis (also persistent red-brown papules/plaques)
  - *For urticarial lesions lasting >24 hours*: urticarial drug eruption, viral exanthem, erythema multiforme (central duskiness/vesiculation rather than clearing), insect bite reactions, Sweet syndrome, urticarial bullous pemphigoid, acute hemorrhagic edema of infancy, Kawasaki disease
  - *For angioedema*: early airborne or allergic contact dermatitis, insect bite reaction

**Urticaria occurring less frequently than this over a long period is referred to as episodic or recurrent.*
*†Individual lesions tend to last >24 hours; urticarial vasculitis features burning/pain, purpura upon resolution, and a subgroup associated with hypocomplementemia and autoimmune connective tissue disease (e.g. SLE).*
***Consider for chronic urticaria with associated symptoms such as fevers, pain, and arthralgias.*

**Table 14.1 Classification and differential diagnosis of urticaria and angioedema.**

| CAUSES OF ACUTE AND CHRONIC SPONTANEOUS URTICARIA | |
|---|---|
| **Acute urticaria** | **Chronic urticaria** |
| • Infection (e.g. URI) (~40%)<br>• Drug (~10%)<br>• Food (≤1%)<br>• Idiopathic (~50%) | • Autoimmune (histamine-releasing autoantibodies against FcεRI or the Fc portion of IgE; see Fig. 14.3) (40–50%)<br>• Chronic infection (e.g. parasitic) (≤5%)<br>• Pseudoallergic (≤5%)<br>• Idiopathic (~50%) |

**Table 14.2 Causes of acute and chronic spontaneous urticaria.** Acute urticaria data is for patients presenting to a dermatologist or emergency department. FcεRI, high-affinity IgE receptor (present on mast cells); IgE, immunoglobulin E.



**Fig. 14.4 Urticaria in a young child.** This clinical presentation of urticaria, which is referred to as "urticaria multiforme", is sometimes misdiagnosed as erythema multiforme because of the dusky centers. As lesions expand, central clearing can occur, which is not seen in erythema multiforme. *Courtesy, Luis Requena, MD.*

## Spontaneous ("Ordinary") Urticaria: Acute and Chronic

- Although both can occur at any age, acute urticaria is most common in children, whereas chronic urticaria has a peak in the fourth decade of life and a female : male ratio of ~2 : 1.
- The most frequent causes of acute and chronic urticaria are listed in Table 14.2.
- Acute urticaria in young children often presents with large annular or polycyclic lesions (urticaria "multiforme"; Fig. 14.4; see Fig. 3.3A) that tend to resolve with a transient dusky purplish hue, which can lead to misdiagnosis as erythema multiforme.
- Urticaria can result in sleep disturbances and anxiety.
- Chronic autoimmune urticaria is associated with an increased risk of other autoimmune conditions, such as thyroid disorders and celiac disease.
- An approach to the diagnosis of chronic urticaria is outlined in Fig. 14.5; extensive laboratory evaluations (e.g. for food allergies) are extremely low-yield and are not recommended.
- **Rx:** a stepwise therapeutic approach is presented in Fig. 14.6; long-acting antihistamines are the mainstay of treatment, and systemic corticosteroids should be avoided.

## Inducible Urticaria

- Different forms of physical urticaria and other inducible urticaria variants may coexist with one another and/or chronic spontaneous urticaria.
- **Rx:** see Fig. 14.6.

### Dermographism ("Skin Writing")

- Affects at least 10% of the general population; may lead to symptoms such as pruritus.
- Linear or irregularly shaped wheals develop at sites of scratching or friction (Fig. 14.7); lesions typically resolve within an hour.
- Can elicit via stroking the skin, e.g. with a thin wooden stick or tongue depressor.

### Delayed Pressure Urticaria

- Pruritic and/or painful erythema and swelling (Fig. 14.8) develop 0.5–12 hours after sustained pressure to the skin (e.g. due to tight clothing or shoes); may last several days, sometimes with associated arthralgias and malaise.

### Cold Urticaria

- Wheals ± angioedema develop within minutes of cold exposure, with maximal hiving upon rewarming; systemic reactions (e.g. anaphylaxis) may occur with aquatic activities.

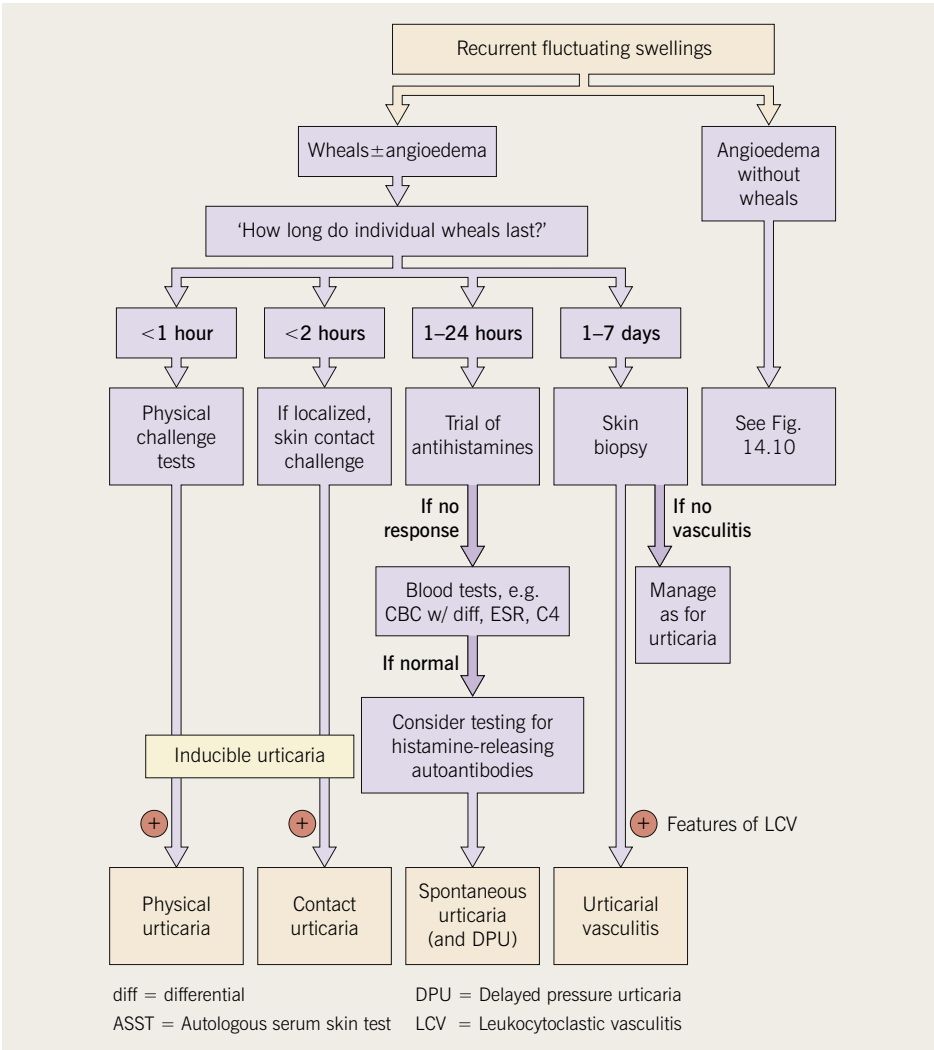


**Fig. 14.5 Approach to the diagnosis of chronic urticaria.** In a positive ASST, a localized wheal and flare response occurs upon intradermal injection of autologous serum, providing evidence of functional histamine-releasing factors in the blood. Regulations regarding blood products limit the availability of this test. *Courtesy, Clive E. H. Grattan, MD.*

- Can elicit via ice cube test (Fig. 14.9; 1- to 10-minute application within glove, then rewarming).
- Usually primary; <5% of cases are associated with cryoglobulins or cryofibrinogen.
- Rare early-onset variants with autosomal dominant inheritance and a negative ice cube test: cryopyrin-associated periodic syndrome (see Table 3.2), familial atypical cold urticaria (wheals upon evaporative cooling; *PLCG2* mutations).

## Cholinergic Urticaria

- Multiple small (2–3 mm), monomorphic, pruritic wheals with an erythematous flare develop within 15 minutes of sweat-inducing stimulus (e.g. physical exertion, emotional stress, hot bath); favors the upper body but may be widespread.
- **DDx:** adrenergic urticaria (blanched halo rather than flare), heat urticaria (can occur without sweating), exercise-induced urticaria/anaphylaxis (only with exercise, not a hot

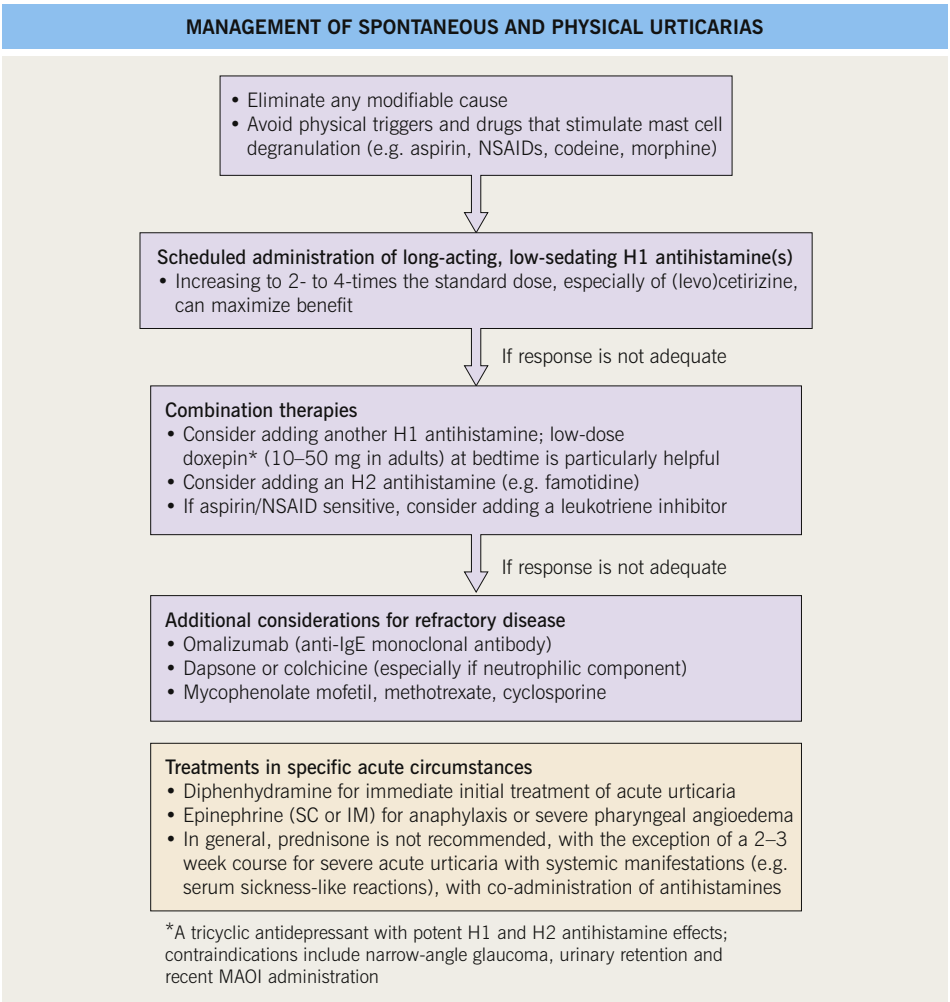


**Fig. 14.6 Management of spontaneous and physical urticarias.** MAOI, monoamine oxidase inhibitor.



**Fig. 14.7 Symptomatic dermographism within minutes of scratching.** Dermographism can be a contributing factor in a number of dermatoses. *Courtesy, Jean L. Bolognia, MD.*



**Fig. 14.8 Delayed pressure urticaria.** *Courtesy, Clive E. H. Grattan, MD.*

bath), aquagenic urticaria (upon contact with water of any temperature).

### Solar Urticaria

- Pruritus and wheals within 5–10 minutes of exposure to UVA and/or visible light > UVB (see Ch. 73).

### Contact Urticaria

- *Immunologic contact urticaria* presents with localized pruritus and hives within 30 minutes of handling fresh vegetables/fruits or contact with latex in sensitized individuals; occasionally generalizes, and "protein contact dermatitis" may occur with repeated exposure (especially in atopic patients).
- Evaluation of suspected type 1 latex allergy initially involves a blood test for specific IgE; if negative, a prick test with latex extract can be performed in a controlled setting and, if there is no reaction, confirmed with a usage test (e.g. wearing the suspect glove).
- "*Oral allergy syndrome*" presents with intraoral itching and swelling in individuals with a pollen allergy upon ingestion of cross-reacting fresh fruits or vegetables.
- *Non-immunologic contact urticaria* results from exposure to plants containing toxins (e.g. histamine) within sharp "hairs" on their leaves (e.g. stinging nettles).

## Schnitzler Syndrome

- Chronic urticaria ± pruritus associated with a monoclonal gammopathy (IgM >> IgG).
- Other features include fevers, arthralgias, bone pain, lymphadenopathy, leukocytosis, and an increased ESR; patients may develop a lymphoproliferative malignancy.
- **Rx:** prednisone, anakinra, and rituximab, as well as treatment of the underlying disorder.

## Hereditary Angioedema (HAE)

- HAE due to deficiency (type I) or dysfunction (type II) of the complement C1 esterase inhibitor (C1 inh) is an uncommon autosomal dominant disorder that presents with episodic nonpruritic angioedema lasting 2–3 days, often beginning in early childhood and triggered by trauma; although not associated with true urticaria, attacks are occasionally preceded or accompanied by transient, nonpruritic, serpiginous erythematous patches.
- Type I/II HAE favors the extremities and gastrointestinal tract (may mimic an acute abdomen), and airway compromise due to laryngeal edema can occur.
- HAE with normal C1 inh (previously known as type III HAE) is a later-onset form with more frequent facial involvement that develops primarily in teenage girls and young women.
- Pathogenesis of HAE is related to excessive generation of bradykinin, which leads to increased vascular permeability.
- Evaluation and **DDx:** outlined in Fig. 14.10.
- **Rx:** *acute attacks* – IV C1 inhibitor concentrate, SC ecallantide (kallikrein inhibitor) or SC icatibant (bradykinin $B_2$ receptor antagonist); *short-term* (e.g. for surgical or dental procedures) or *long-term prophylaxis* – IV or SC C1 inhibitor concentrate, SQ lanadelumab (kallikrein inhibitor; long-term) > androgens (e.g. oral danazol), antifibrinolytic agents (long-term); antihistamines, epinephrine, and corticosteroids are *not* effective.

For further information see Ch. 18 from *Dermatology, Fourth Edition*.

**For additional online figures and a table on antihistamines visit www.expertconsult.com**



**Fig. 14.9 Cold urticaria.** Wheals developed on the forearm after placement of an ice cube for 10 minutes, followed by rewarming. *Courtesy, Thomas Schwarz, MD.*

**ALGORITHM FOR THE DIAGNOSIS OF ANGIOEDEMA**

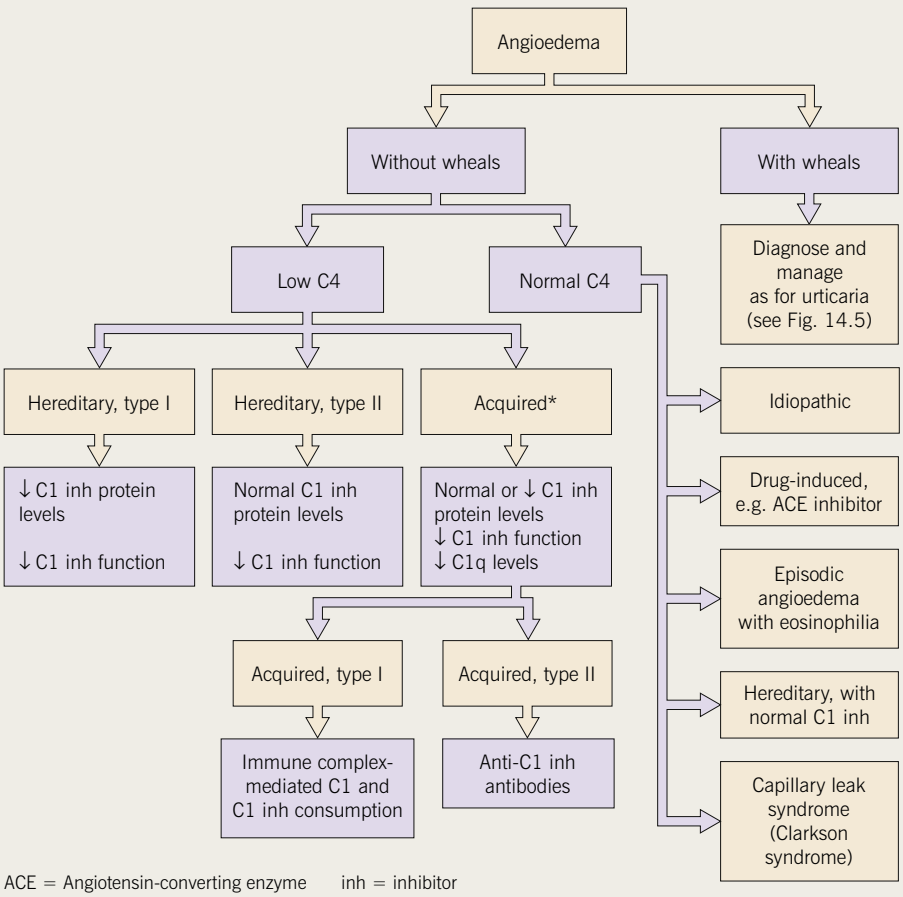


ACE = Angiotensin-converting enzyme inh = inhibitor

* Associated with B-cell lymphoproliferative disorders (e.g. lymphomas, monoclonal gammopathy of undetermined significance)

**Fig. 14.10 Algorithm for the diagnosis of angioedema.** Genetic testing may help to confirm the diagnosis of hereditary angioedema with normal C1 inhibitor, with implicated genes including *F12* (factor XII) > *PLG* (plasminogen), *KNG1* (kininogen 1), and *ANGPT1* (angiopoietin-1). Episodic angioedema with eosinophilia as well as weight gain and fever is known as Gleich syndrome. Systemic capillary leak syndrome can lead to life-threatening hypotension and is associated with an IgG monoclonal gammopathy.



**eFig. 14.1 Acute urticaria.** Wheals may be annular or arcuate. *Courtesy, YDRSC.*



**eFig. 14.4 Urticarial vasculitis.** Lesions look like spontaneous urticaria but last longer and may bruise. An incidental finding is a skin graft donor site. *Courtesy, NYUDSC.*



**eFig. 14.2 Acute urticaria with polycyclic wheals in an infant.** *Courtesy, Julie V. Schaffer, MD.*

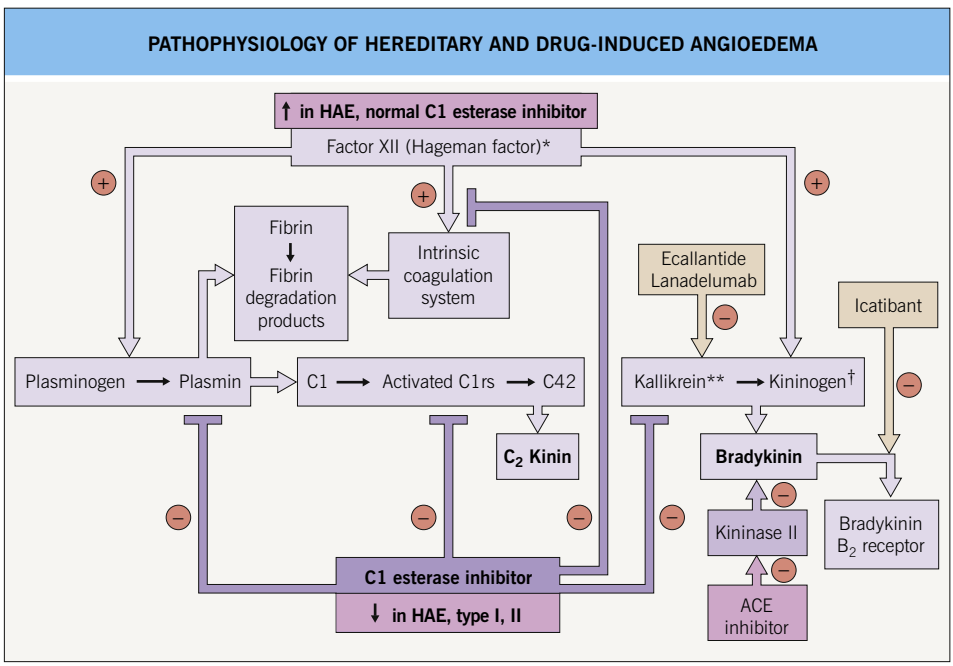


**eFig. 14.3 Pathophysiology of hereditary and drug-induced angioedema.** *The active form of factor XII is XIIa. **Kallikrein is formed from prekallikrein. †High-molecular weight.

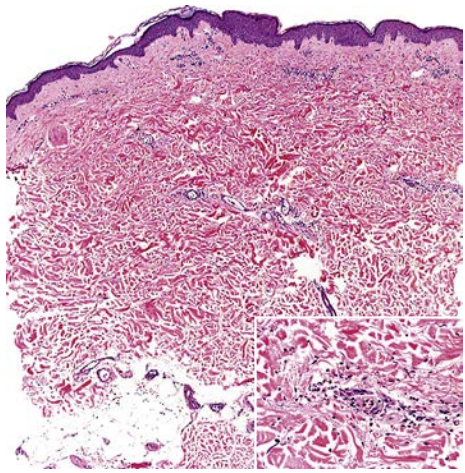

**eFig. 14.5 Histopathology of spontaneous urticaria.** A sparse, mainly perivascular inflammatory infiltrate and scant edema within the superficial and mid dermis. Note several neutrophils and a few eosinophils (inset). *Courtesy, Lorenzo Cerroni, MD.*

**ANTIHISTAMINES FOR URTICARIA**

| Class | Examples | Plasma half-life (hours) | Typical daily adult dose* |
|---|---|---|---|
| Classic (sedating) H1 antihistamines | Chlorpheniramine (1) | 12–15 | 4 mg three times daily (up to 12 mg at night) |
| | Hydroxyzine (1) | 20 | 10–25 mg three times daily (up to 75 mg at night) |
| | Diphenhydramine (2) | 4 | 10–25 mg at night |
| | Doxepin† (1) | 17 | 10–50 mg at night |
| Second-generation H1 antihistamines | Acrivastine‡ (1) | 2–4 | 8 mg three times daily |
| | Cetirizine§ (1) | 7–11 | 10 mg once daily |
| | Loratadine (1) | 8–11 | 10 mg once daily |
| | Mizolastine** (1) | 13 | 10 mg once daily |
| Newer second-generation H1 antihistamines | Desloratadine (1) | 19–35 | 5 mg once daily |
| | Fexofenadine (1) | 17 | 180 mg once daily |
| | Levocetirizine (1) | 7–10 | 5 mg once daily |
| | Rupatadine** (1) | 6 | 10 mg once daily |
| H2 antagonists¶ | Cimetidine (1) | 2 | 400 mg twice daily |
| | Famotidine (2) | 2–4 | 20 mg twice daily |

**For second-generation H1 antihistamines such as (levo)cetirizine, increasing to 2-4-fold the standard dose may increase benefit. Current prescribing manuals should be consulted for details on doses in children.*
*†Possesses potent H1 and H2 antihistamine properties.*
*‡Only available in the US as a combination product with pseudoephedrine for seasonal allergic rhinitis.*
*§The active metabolite of hydroxyzine.*
***Not available in the US.*
*¶Used in combination with $H_1$ antagonists.*

**eTable 14.1 Antihistamines for urticaria.** Key to evidence-based support: (1) prospective controlled trial; (2) retrospective study or large case series; (3) small case series or individual case reports.

# 15 Figurate Erythemas

A number of cutaneous diseases can have an annular, arciform, or polycyclic configuration, from urticaria to granuloma annulare and tinea corporis (Table 15.1). Sites of involvement, rate of expansion, and characteristics of the border assist in narrowing the differential diagnosis, along with histopathologic examination of the active edge. This chapter discusses in more detail the classic figurate erythemas.

## Erythema Annulare Centrifugum (EAC)

- Annular, arciform, and polycyclic plaques due to infiltrates of lymphocytes within the dermis; lesions usually last for a few weeks to months and as they migrate centrifugally, there is central clearing; recurrences are common.
- This gyrate erythema is sometimes divided into superficial and deep forms, based on clinicopathologic findings, with the superficial form being minimally elevated with "trailing" white scale (Fig. 15.1A) and the deep form having a more infiltrated border (Fig. 15.1B); some authors reserve the designation EAC for the superficial form.
- Color varies from pink to darker red-violet, with the superficial form favoring the thighs and the deeper form the trunk; peak incidence is during the fifth decade.
- Often idiopathic, but some cases appear to be a reactive process triggered by fungal infections, in particular tinea pedis, or less often, viral infections or medications.
- **DDx:** Tinea corporis (especially if scale is present); if no surface changes, annular urticaria (Fig. 15.2), benign lymphocytic infiltrate (of Jessner), cutaneous lymphoid hyperplasia, cutaneous lupus erythematosus (tumidus), and lymphoma cutis as well as the other entities covered in this chapter and Table 15.1; in some patients, the diagnosis of EAC is rendered after exclusion of other disorders.
- **Rx:** if trigger identified, it should be treated; if no trigger is identified, topical CS may be of some benefit.

## Erythema Marginatum

- Cutaneous manifestation of rheumatic fever (due to a preceding group A β-hemolytic streptococcal infection) and therefore seen more commonly in children.
- Migratory annular and polycyclic erythematous eruption that represents a major Jones criterion; subcutaneous nodules can also develop, but during a later phase of the disease; both findings are seen in the minority of patients.
- This asymptomatic figurate erythema favors the trunk and proximal extremities, with individual lesions lasting a few hours to days and recurrences occurring over a several-week period.
- Associated systemic manifestations: carditis, migratory polyarthritis, chorea, fever.
- **DDx:** annular urticaria (including urticaria multiforme), annular erythema of infancy, Still disease and other autoinflammatory diseases, Kawasaki disease.
- **Rx:** address the underlying rheumatic fever.

## Erythema Gyratum Repens

- Migratory figurate erythema composed of multiple concentric rings that is said to resemble the grain of wood (Fig. 15.3); the lesions can migrate up to 1 cm per day and may have associated scale or pruritus.
- Paraneoplastic dermatosis in the vast majority of patients, with lung cancer and breast cancer representing the most common

| ADDITIONAL ENTITIES THAT CAN HAVE AN ANNULAR, ARCIFORM, OR POLYCYCLIC CONFIGURATION | |
|---|---|
| **No epidermal (surface) changes** | |
| Annular urticaria | Individual lesions are transient, lasting <24 hrs |
| Urticaria multiforme | Migratory edematous plaques that may have dusky centers; edema of the face, hands and feet can develop; primarily in infants and young children, often following a viral or bacterial infection |
| Serum sickness-like eruption | Urticarial (or morbilliform) eruption due to a systemic medication; may be accompanied by arthralgias, arthritis, and fever |
| Urticarial vasculitis | Individual lesions usually last >24 hrs and may resolve with petechiae |
| Granuloma annulare | Skin-colored to dull pink elevated border, often composed of coalescing papules; favors acral sites, elbows |
| Annular elastolytic giant cell granuloma | Chronically sun-exposed sites with significant photodamage; hypopigmented centrally as expands |
| Interstitial granulomatous dermatitis | Associated with autoimmune connective tissues diseases, e.g. rheumatoid arthritis, and systemic medications, e.g. TNF inhibitors |
| Sarcoidosis | Skin-colored to red-brown; with pressure (diascopy), has a yellow-brown color; face > trunk, extremities; sometimes has scale |
| Leprosy | Primarily tuberculoid and borderline forms, with the former often having central hypopigmentation |
| Syphilis | Secondary stage, in particular on the face, and tertiary stage (gummas); facial lesions may have central hyperpigmentation |
| Annular erythema of infancy | Slowly expanding with an urticarial border; individual lesions spontaneously resolve over a few days |
| Benign lymphocytic infiltrate (of Jessner) | Favors the head, neck, and upper trunk; erythematous papules and plaques last weeks to months |
| LE tumidus | Firm erythematous plaques that favor the face and upper trunk |
| Lymphoma cutis, both B- and T-cell | Pink to violet papules and plaques; may be primary cutaneous or related to a systemic lymphoma; some subtypes of CTCL, e.g. mycosis fungoides, can have scale |
| **Scale and/or crust** | |
| Tinea corporis | Scale and pustules in the advancing border; KOH examination is positive for hyphae |
| Seborrheic dermatitis | Lesions on the face and central chest; associated scale |
| Annular psoriasis | Scale is silvery; associated scalp, intergluteal, and nail involvement |
| Subacute cutaneous LE | Primarily sun-exposed sites, especially upper trunk and upper outer arms; hypopigmented centrally |
| Elastosis perforans serpiginosa | Border contains keratotic papules and lesions favor flexural sites |

**Table 15.1 Additional entities that can have an annular, arciform, or polycyclic configuration.** *Continued*

| ADDITIONAL ENTITIES THAT CAN HAVE AN ANNULAR, ARCIFORM, OR POLYCYCLIC CONFIGURATION | |
|---|---|
| **Wickham striae within border** | |
| Annular lichen planus | The elevated border is string-like |
| **Petechiae within border** | |
| Annular capillaritis | Both petechiae and yellow-brown hue due to hemosiderin |
| **Vesicobullae within border** | |
| Linear IgA bullous dermatosis | Border may resemble "string of pearls"; DIF required |
| **More serpiginous border** | |
| Cutaneous larva migrans | Favors feet, buttocks, and areas in contact with sandy ground |

**Table 15.1** *Continued* **Additional entities that can have an annular, arciform, or polycyclic configuration.** These disorders are covered in other chapters. See text for discussion of the classic figurate erythemas. Both erythema multiforme and erythema migrans can have a bull's-eye appearance. CTCL, cutaneous T-cell lymphoma; DIF, direct immunofluorescence.

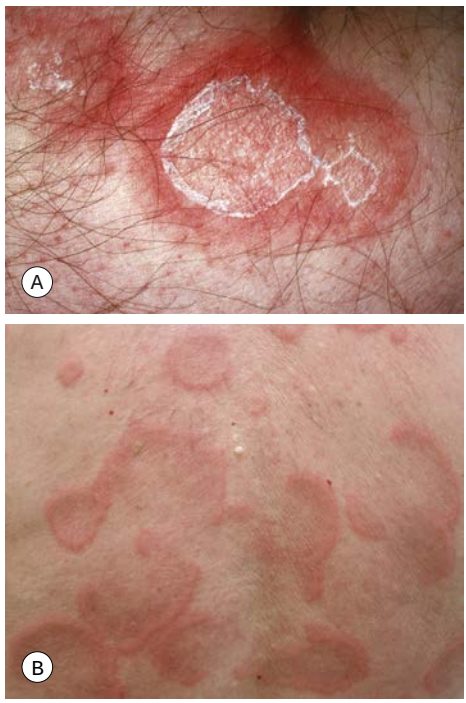


**Fig. 15.1 Erythema annulare centrifugum.** **A** Superficial form, with polycyclic plaques and delicate scale on the inner margin of the advancing edge (trailing scale). The scale is detached centrally. **B** Deep form, with obvious elevation of advancing edges and without trailing scale. *Courtesy, YDRSC.*

underlying malignancies; patients may have other paraneoplastic phenomena, e.g. acquired ichthyosis, palmoplantar keratoderma.

- Occasionally, patients have no underlying disease or an underlying infection, e.g. pulmonary tuberculosis.
- **DDx:** EAC (slower migration and usually not concentric), tinea imbricata, the resolving phase of pityriasis rubra pilaris, erythrokeratodermia variabilis, mycosis fungoides.
- **Rx:** address the underlying malignancy; if antineoplastic treatment is successful, the eruption will resolve.

## Erythema Migrans (EM; Erythema Chronicum Migrans [ECM])

- Cutaneous manifestation of the earlier stages of infection with *Borrelia burgdorferi* spirochetes; seen in 60–80% of patients diagnosed with Lyme borreliosis.
- Occurs most commonly in the United States (northeast, upper Midwest, west coast), Scandinavia, and central Europe; natural hosts are white-footed mice and white-tailed deer.
- Can be localized to the site of the bite of an infected *Ixodes* tick (Figs 15.4 & 15.5) or as the disease progresses, becomes disseminated with multiple secondary lesions (Fig. 15.6); several species of *Ixodes* can transmit disease, including *I. scapularis*, *I. pacificus*, *I. ricinus*.
- At the site of the tick bite, usually after a period of 1 or 2 weeks (range 2–28 days),

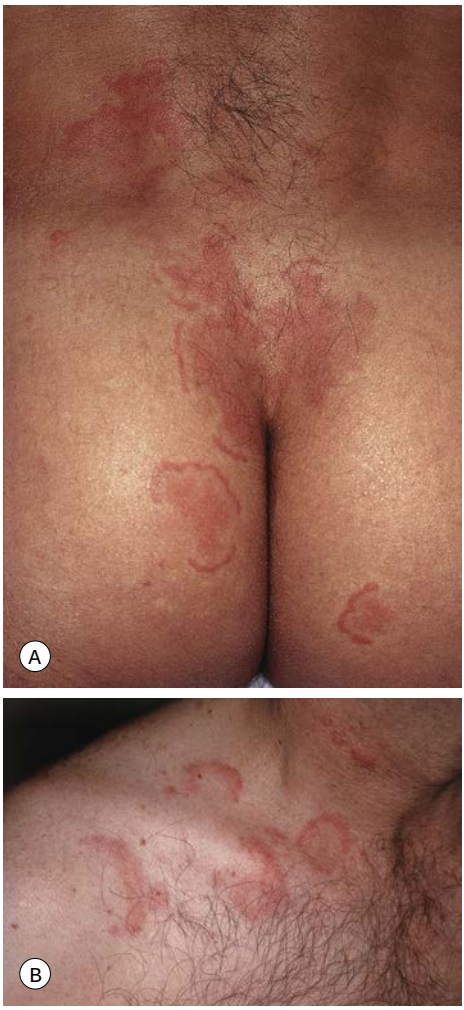


**Fig. 15.2 A comparison of erythema annulare centrifugum and urticaria.** The lesions in **A** have no scaling and may be confused with annular urticaria **(B)**. However, *individual* lesions of urticaria are evanescent, lasting <24 hours. Placement of an ink circle around a lesion, followed by longitudinal observation, allows this distinction. *Courtesy, YDRSC.*



**Fig. 15.3 Erythema gyratum repens.** Multiple concentric annular plaques, with a wood-grain appearance. *Courtesy, Agustin Alomar, MD.*



**Fig. 15.4 Erythema migrans.** Expanding annular plaque that has a bull's-eye appearance. *Courtesy, YDRSC.*

an erythematous patch or plaque appears that expands over days to weeks to reach a diameter of at least 5 cm; central clearing can result in an annular lesion and sometimes the lesion has a bull's-eye appearance; occasionally, vesicles are seen.

- Primary lesions often favor body folds, are frequently asymptomatic and spontaneously resolve (without treatment) within 6 weeks; primary, and especially disseminated, lesions can be accompanied by flu-like symptoms – headache, malaise, arthralgia, myalgia, and fever.
- Transmission usually requires attachment of the infected *Ixodes* tick for over 24 hours; if untreated, sequelae include arthritis, Bell palsy, and atrioventricular heart block (Table 15.2); *Ixodes* ticks may also transmit babesiosis, anaplasmosis, *Borrelia miyamotoi*, or Powassan virus.
- Development of additional cutaneous findings (e.g. pseudolymphoma, acrodermatitis chronica atrophicans; Fig. 15.7) is seen in individuals infected outside the United States and reflects the geographic distribution of different genospecies of *Borrelia*, e.g. *B. afzelii* is found in Europe but not the United States.
- **DDx:** exaggerated local reaction to an arthropod bite, cellulitis, allergic contact dermatitis, southern tick-associated rash illness (STARI or Masters disease), nonpigmented fixed drug eruption, and other causes of pseudocellulitis (see Table 61.2); of note,

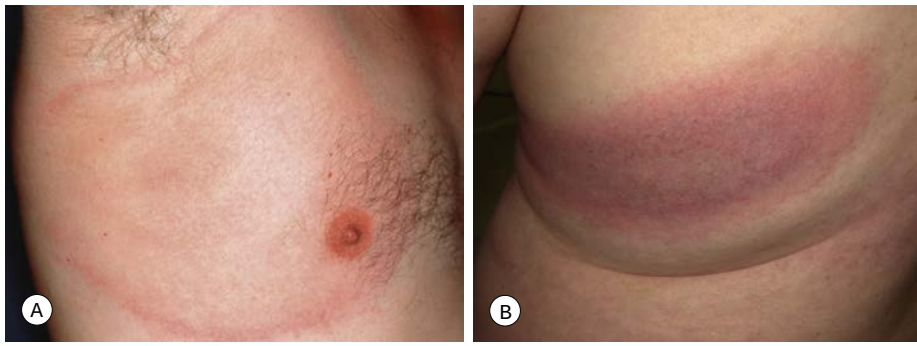


**Fig. 15.5 Erythema migrans. A**,**B** The lesions spread centrifugally, sometimes becoming >10 cm in diameter and may develop a violaceous color centrally. *A, Courtesy, Lorenzo Cerroni, MD; B, Courtesy, Dennis Cooper, MD.*



**Fig. 15.6 Disseminated erythema migrans.** Multiple circular pink plaques are scattered on the thigh and knee. Patients often have flu-like constitutional symptoms. *Courtesy, YDRSC.*

**STAGES AND MAJOR ORGAN MANIFESTATIONS OF LYME BORRELIOSIS**

| Organ | Early localized disease | Early disseminated disease | Chronic disease |
|---|---|---|---|
| Skin | Erythema migrans | | Acrodermatitis chronica atrophicans (Europe) |
| | Disseminated erythema migrans<br>Borrelial lymphocytoma (Europe) | | |
| Nervous system | | Meningo-polyradiculoneuritis<br>Cranial neuritis<br>Bell palsy | Encephalopathy<br>Encephalomyelitis<br>Neuropathy |
| Musculoskeletal system | | Arthralgias, arthritis<br>Myositis | Chronic arthritis |
| Heart | | Atrioventricular block<br>Myopericarditis, pancarditis<br>Tachycardia | |
| Lymphatic | Regional lymphadenopathy | Regional or generalized lymphadenopathy | |
| Other | | Conjunctivitis, iritis<br>Hepatitis<br>Nonproductive cough<br>Microscopic hematuria or proteinuria | |

**Table 15.2 Stages and major organ manifestations of Lyme borreliosis.** *Adapted from Müllegger RR. Dermatological manifestations of Lyme borreliosis. Eur J Dermatol. 2004;14:296–309.*

peak specific IgM antibodies usually appear at 3–6 weeks into infection so they may not be detected in patients with early EM (false-negative rate as high as 60%).

- **Rx** is outlined in Table 15.3; for patients who: (1) live in an endemic area; (2) had a tick attached for >36 hours; (3) removed the tick within the past 72 hours; and (4) if possible, had the tick identified as *I. scapularis*, a single dose of oral doxycycline (200 mg) may reduce the risk of developing Lyme borreliosis from 3.2% to 0.4%.



**Fig. 15.7 Acrodermatitis chronica atrophicans is another manifestation of Lyme borreliosis.** Note the shiny and wrinkled skin plus more visible superficial veins – signs of atrophy. *Courtesy, YDRSC.*

**TREATMENT OPTIONS FOR BORRELIOSIS**

| Manifestation | Drug | Dose (pediatric dose*) | Duration (days) | Comments |
|---|---|---|---|---|
| **Erythema migrans** | Doxycycline | 100 mg (2 mg/kg) po BID | 14 (range, 10–21) | • Not preferred in children <8 yrs of age**, or pregnant or lactating women<br>• Good CNS penetration<br>• Also treats human granulocytic anaplasmosis |
| | Amoxicillin | 500 mg (16 mg/kg) po TID | 14 (range, 14–21)§ | |
| | Cefuroxime axetil | 500 mg (15 mg/kg) po BID | 14 (range, 14–21) | |

**The maximum pediatric dose is the adult dose.*
***The American Academy of Pediatrics considers use of doxycycline for ≤21 days to be acceptable in children <8 years of age.*
*§Recommended for 21 days for pregnant women.*

**Table 15.3 Treatment options for borreliosis.** *Continued*

For further information see Ch. 19 from *Dermatology, Fourth Edition*.

**For additional online figures and CDC Lyme disease surveillance case definition table visit www.expertconsult.com**

| TREATMENT OPTIONS FOR BORRELIOSIS | | | |
|---|---|---|---|
| **Manifestation** | **Drugs** | **Duration (days)** | **Comments** |
| **Meningitis** | Ceftriaxone (iv), cefotaxime (iv) | 14 (range, 10–28) | |
| **Cranial nerve palsy (without meningitis)** | Same drugs and dosages as for erythema migrans | 14 (range, 14–21) | • May not affect outcome of facial palsy |
| **Carditis** | If symptomatic, initiate treatment with parenteral antibiotic (e.g. ceftriaxone) then based upon clinical response, finish course with oral agents | 14 (range, 14–21) | • Advanced heart block may require a pacemaker |
| **Arthritis** | Same parenteral agents as for meningitis and same oral agents as for erythema migrans | 28 | • If persists or recurs, a second course of antibiotics |

**Table 15.3** *Continued* **Treatment options for borreliosis.** A Jarisch–Herxheimer-like reaction with an increase in systemic symptoms and in the size or intensity of the inflammation of the erythema migrans lesion occurs in ~15% of patients within 24 hours after the initiation of antimicrobial therapy. If all three antibiotics for erythema migrans are contraindicated, then macrolides (e.g. clarithromycin, azithromycin, erythromycin) can be prescribed but the cure rates are ~80% yrs, years.



**eFig. 15.1 Annular urticaria.** Individual lesions are evanescent, lasting <24 hours. Placement of an ink circle around a lesion, followed by longitudinal observation, allows for confirmation and distinction from erythema annulare centrifugum. *Courtesy, Agustín España, MD.*



**eFig. 15.2 Erythema marginatum (rheumaticum).** Polycyclic and evanescent annular lesions are seen on the trunk of this young patient. *Courtesy, Agustín España, MD.*



**eFig. 15.3 Resolving pityriasis rubra pilaris.** The lesions can resemble erythema gyratum repens. *Courtesy, Irwin Braverman, MD.*



**eFig. 15.4 Annular erythema of infancy.** Expanding annular urticarial plaques in a 6-month-old boy. Lesions are typically asymptomatic, expand slowly, and then resolve over a few days. New plaques may continue to appear for several months. *Courtesy, Julie V. Schaffer, MD.*



**eFig. 15.5 Erythema migrans.** Concentric rings as well as multiple vesicles in the central portion are seen. *Courtesy, YDRSC.*



**eFig. 15.6 Disseminated erythema migrans.** Multiple circular and a few annular plaques are scattered on the lower extremities as well as the trunk (not shown). *Courtesy, Thomas Schwarz, MD.*

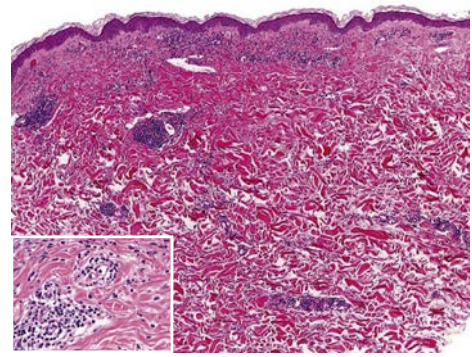

**eFig. 15.7 Erythema migrans – histopathologic features.** A superficial and deep perivascular infiltrate is present within the dermis. The infiltrate is composed of lymphocytes and plasma cells (inset). *Courtesy, Lorenzo Cerroni, MD.*

| 2017 CDC LYME DISEASE SURVEILLANCE CASE DEFINITION |
|---|
| **Definition of erythema migrans (EM)** |
| A skin lesion that typically begins as a red macule or papule and expands over a period of days to weeks to form a large round lesion, often with partial central clearing. A single primary lesion must reach ≥5 cm in diameter. Secondary lesions also may occur. Annular erythematous lesions occurring within several hours of a tick bite represent hypersensitivity reactions and do not qualify as EM. For most patients, the expanding EM lesion is accompanied by other acute symptoms, particularly fatigue, fever, headache, mildly stiff neck, arthralgia, or myalgia. These symptoms are typically intermittent. The diagnosis of EM must be made by a physician. Laboratory confirmation is recommended for persons with no known exposure. |
| **Confirmed** |
| • A case of EM with exposure in a high-incidence state* - ***or*** -<br>• A case of EM with laboratory evidence of infection† and a known exposure in a low-incidence state - ***or*** -<br>• Any with at least one late manifestation‡ that has laboratory evidence of infection |
| **Probable** |
| • Any other case of physician-diagnosed Lyme disease that has laboratory evidence of infection† |
| **Suspected** |
| • A case of EM where there is no known exposure* and no laboratory evidence of infection† - ***or*** -<br>• A case with evidence of infection but no clinical information available (e.g. a laboratory report) |
| **Exposure is defined as having been (≤30 days before onset of EM) in wooded, brushy, or grassy areas (i.e. potential tick habitats) of Lyme disease vectors. Since infected ticks are not uniformly distributed, a detailed travel history to verify whether exposure occurred in a high- or low-incidence state is needed. An exposure in a high-incidence state is defined as exposure in a state with an average Lyme disease incidence of at least 10 confirmed cases/100,000 for the previous three reporting years. A low-incidence state is defined as a state with a disease incidence of <10 confirmed cases/100,000 (see CDC website for state-based statistics).* ***A history of a tick bite is not required.***<br>*†A positive culture for* B. burgdorferi *- or - a positive two-tier test defined as a positive or equivocal enzyme immunoassay or immunofluorescent assay followed by a positive IgM (≥2 of 3 bands for OspC, BmpA, Fla) or IgG (≥5 of 10 bands) in a western immunoblot (WB) for Lyme disease - or - a positive single-tier IgG WB for Lyme disease (but two-tiered favored for patient diagnosis).*<br>*‡Recurrent, brief attacks (weeks or months) of objective joint swelling in one or a few joints, sometimes followed by chronic arthritis in one or a few joints; lymphocytic meningitis, cranial neuritis, particularly facial palsy, radiculoneuropathy, or rarely, encephalomyelitis; acute onset of high-grade (2nd-degree or 3rd-degree) atrioventricular conduction defects that resolve in days to weeks and are sometimes associated with myocarditis.*<br>*From wwwn.cdc.gov/nndss/conditions/lyme-disease/case-definition/2017/* |

**eTable 15.1 2017 CDC Lyme disease surveillance case definition.** CDC, Centers for Disease Control and Prevention.

# Erythema Multiforme, Stevens–Johnson Syndrome, and Toxic Epidermal Necrolysis

16

## Erythema Multiforme

- Self-limited, but potentially recurrent, disease.
- Two forms: erythema multiforme (EM) major and EM minor (Table 16.1).
- Both forms have an abrupt onset of papular 'target' lesions that favor acrofacial sites.
- Two types of target lesions: (1) typical targets, with at least three different zones; (2) atypical papular targets, with only two different zones and/or a poorly defined border (Fig. 16.1).
- EM minor: typical > atypical *papular* target lesions, little or no mucosal involvement, and no systemic symptoms.
- EM major: typical > atypical *papular* target lesions, moderate to severe mucosal involvement (Fig. 16.2), and some systemic symptoms (fever, asthenia, arthralgia).
- Preceding HSV infection is the most common precipitating factor; less often other infections, in particular *Mycoplasma pneumoniae* (Table 16.2 and see Fig. 16.2B); rarely drug exposure.
- The term *Mycoplasma*-induced rash and mucositis (MIRM) has been proposed to describe a clinical presentation with significant mucositis (oral, ocular and anogenital) ± more limited cutaneous involvement; some authors consider this entity to simply be a variant of EM.
- Diagnosis is based on clinicopathologic correlation and not solely histopathologic findings.
- EM is a distinct disorder from Stevens–Johnson syndrome (SJS) and toxic epidermal necrolysis (TEN) (see Table 16.1).
- EM does not progress to TEN.
- **DDx:** annular urticaria/urticaria multiforme (Fig. 16.3; Table 16.3), morbilliform drug reaction (Fig. 16.4), multiple fixed drug eruption (FDE), acute hemorrhagic edema of infancy, Kawasaki disease, small vessel vasculitis (classic and urticarial), Rowell syndrome, acute GVHD, drug reaction with eosinophilia and systemic symptoms (DRESS) (for EM major).
- **Rx** *mild* disease: symptomatic and supportive care, treat underlying infection if detected, ophthalmology consultation if ocular involvement.
- **Rx** *recurrent* disease: oral antiviral drug as prophylaxis for HSV infections, administered for at least 6 months (acyclovir 10 mg/kg/day, valacyclovir 500–1000 mg/day, or famciclovir 250 mg BID).
- **Rx** *severe recurrent* disease or *failure to respond* to prophylactic (anti-HSV) treatment: double the antiviral dose and if this fails, then consider referral to a dermatologist for possible immunosuppressive treatment.

## Stevens–Johnson Syndrome (SJS) and Toxic Epidermal Necrolysis (TEN)

- SJS and TEN are considered the same disease, but along a clinical spectrum of severity and distinct from EM (see Table 16.1).
- Most likely etiology for both is an adverse reaction to a medication.
- Most common culprit drugs (Table 16.4): NSAIDs, antibiotics (in particular, sulfonamides and penicillins), aromatic anticonvulsants, and allopurinol.
- Increased risk in certain patient groups: immunocompromised (e.g. HIV infection), patients undergoing radiotherapy while concomitantly receiving anticonvulsants, patients with slow acetylator genotypes, and in patients who have specific HLA alleles (see Table 17.1); HLA genotyping is now recommended for all Asians prior to administering carbamazepine (*HLA-B*15:02*) and for Asians and African Americans prior to receiving allopurinol (*HLA-B*58:01*).
- Mucocutaneous tenderness, erythema, and varying degrees of epidermal detachment are characteristic features.

Downloaded for Novin lib (novinlibrary@yahoo.com) at United Arab Emirates University from ClinicalKey.com by Elsevier on March 26, 2022. For personal use only. No other uses without permission. Copyright ©2022. Elsevier Inc. All rights reserved.

| COMPARISON OF ERYTHEMA MULTIFORME (EM) MINOR, EM MAJOR, STEVENS–JOHNSON SYNDROME (SJS), SJS/TOXIC EPIDERMAL NECROLYSIS (TEN) OVERLAP, AND TEN | | | | | | |
|---|---|---|---|---|---|---|
| **Clinical entity** | **Type of skin lesions** | **Distribution** | **Mucosal involvement** | **Systemic symptoms** | **Progression to TEN** | **Precipitating factors** |
| **EM minor** (Figs 16.1 & 16.4) | • Typical targets<br>• ± *Papular* atypical targets | Extremities (especially elbows, knees, wrists, hands), face | Absent or mild | Absent | No | • Herpes simplex virus<br>• Other infectious agents |
| **EM major** (Fig. 16.2) | • Typical targets<br>• ± *Papular* atypical targets<br>• Occasionally bullous lesions | Extremities, face | Severe | Usually present<br>• Fever<br>• Arthralgias | No | • Herpes simplex virus<br>• *Mycoplasma pneumoniae*<br>• Other infectious agents<br>• Rarely, drugs |
| **SJS** (Figs 16.6 & 16.7) | • Dusky and/or dusky-red *macules* with epidermal detachment and erosions<br>• *Macular* atypical targets<br>• Bullous lesions<br>• <10% BSA detachment | Isolated lesions<br>Confluence (+)<br>Trunk, face | Severe | Usually present<br>• Fever<br>• Lymphadenopathy<br>• Hepatitis<br>• Cytopenias | Possible | • Drugs<br>• Occasionally, *Mycoplasma pneumoniae**<br>• Rarely, immunizations |
| **SJS/TEN** overlap (Fig. 16.9) | • Similar to SJS<br>• 10–30% BSA detachment | Isolated lesions<br>Confluence (++)<br>Trunk, face, neck | Severe | • Same as SJS | Likely | • Drugs |
| **TEN** (Figs 16.8, 16.10 & 16.11) | • Similar to SJS<br>• >30% BSA detachment | Confluence (+++)<br>Isolated lesions rare<br>Trunk, face, neck, elsewhere | Severe, with involvement of respiratory and gastrointestinal mucosa | • Same as SJS plus nephritis | | • Drugs |

**Occasionally, also subcorneal pustules.*

**Table 16.1 Comparison of erythema multiforme (EM) minor, EM major, Stevens–Johnson syndrome (SJS), SJS/toxic epidermal necrolysis (TEN) overlap, and TEN.**

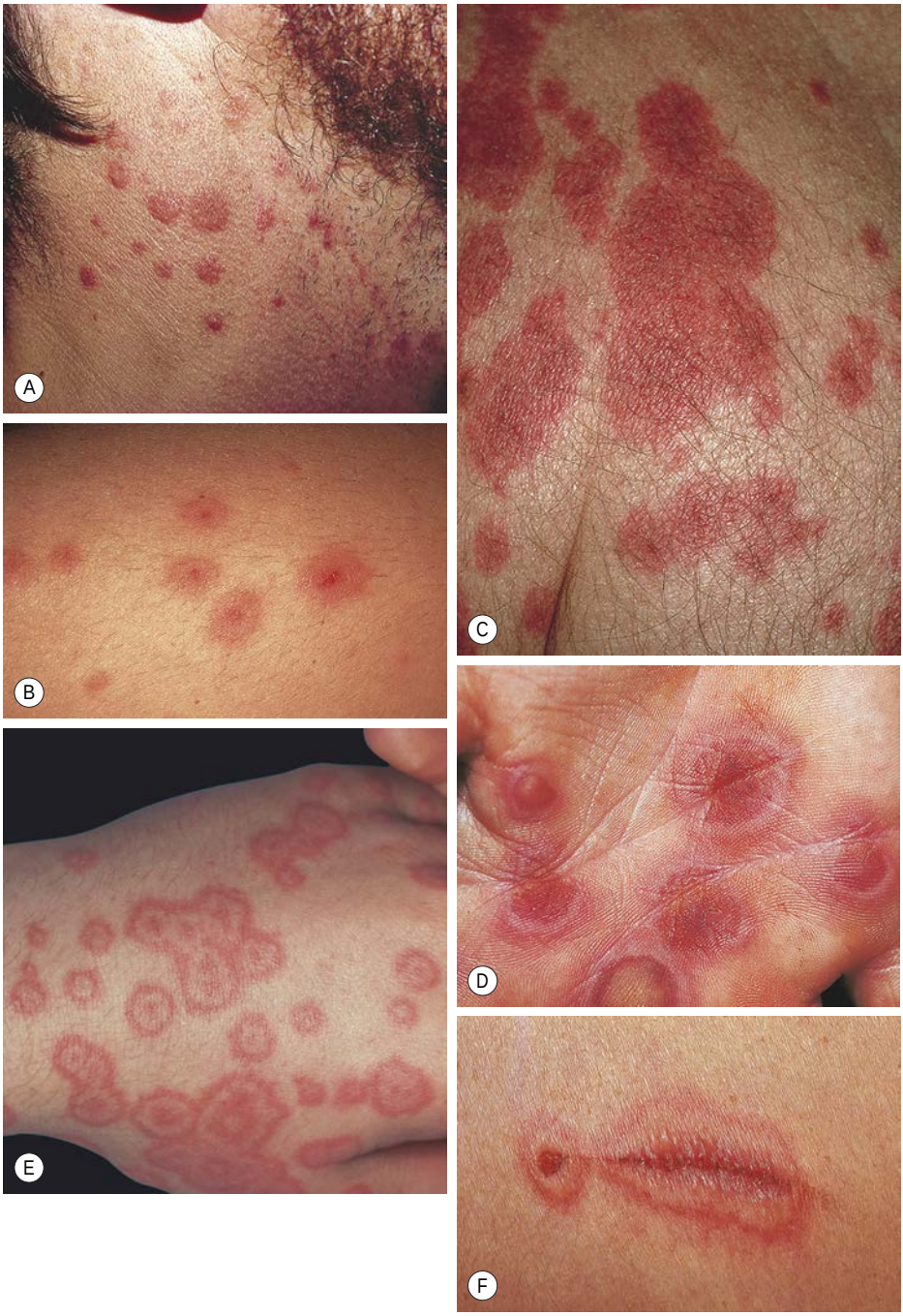


**Fig. 16.1 Phenotypic variety in lesions of erythema multiforme (EM). A** Edematous/urticarial. **B** Urticarial with central crusting. **C** Erythematous plaques with dusky centers; coalescence of the lesions leads to a well-defined polycyclic outline. **D, E** Typical (classic) target lesions on the palms and dorsal hand, with three zones of color change ("bull's eye"); note the central vesicles in **(D)**. **F** Isomorphic response with crust formation. *A, D, F Courtesy, William Weston, MD; B, C, E, Courtesy, YDRSC.*

| PRECIPITATING FACTORS IN ERYTHEMA MULTIFORME | | |
|---|---|---|
| **Infections** (~90% of cases) | Viral | • Herpes simplex virus (HSV-1, HSV-2)<br>• Parapoxvirus (orf)<br>• Vaccinia (smallpox vaccine)<br>• Varicella zoster virus (chickenpox)<br>• Adenovirus<br>• Cytomegalovirus<br>• Epstein–Barr virus<br>• Hepatitis virus<br>• Coxsackievirus<br>• Parvovirus B19<br>• Human immunodeficiency virus |
| | **Bacterial** | • ***Mycoplasma pneumoniae*** (see Fig. 16.2B)<br>• *Chlamydophila* (formerly *Chlamydia*) *psittaci* (ornithosis)<br>• *Salmonella*<br>• *Mycobacterium tuberculosis* |
| | **Fungal** | • *Histoplasma capsulatum*<br>• Dermatophytes |

**Table 16.2 Precipitating factors in erythema multiforme.** This is a *non-exhaustive* list based primarily on case reports and small series of cases. The most common causes are in bold.

| COMPARISON OF URTICARIA AND ERYTHEMA MULTIFORME | |
|---|---|
| **Urticaria** | **Erythema multiforme** |
| Central zone is normal skin or transient duskiness | Central zone is damaged skin (dusky, bullous, or crusted) |
| Lesions are transient, lasting less than 24 hours* | Individual lesions "fixed" for at least 7 days |
| New lesions appear daily | All lesions appear within first 72 hours |
| May be associated with swelling of face, hands, or feet (angioedema) | No edema |

**Confirmed with "circle test" – circle a given urticarial lesion with pen/marker and re-check to see if still there in 24 hours.*

**Table 16.3 Comparison of urticaria and erythema multiforme.**

| MEDICATIONS MOST FREQUENTLY ASSOCIATED WITH STEVENS–JOHNSON SYNDROME (SJS) AND TOXIC EPIDERMAL NECROLYSIS (TEN) | |
|---|---|
| Allopurinol | Chlormezanone*,‡ |
| Aminopenicillins | Lamotrigine (risk may be increased when co-administered with valproic acid) |
| Amithiozone (thioacetazone)*,† | Phenylbutazone*,§ |
| Antiretroviral drugs, especially NNRTIs (e.g. nevirapine, efavirenz, etravirine) | Piroxicam |
| Aromatic anticonvulsants (e.g. phenobarbital, phenytoin, carbamazepine) | Quinolones |
| Cephalosporins | Sulfasalazine |
| Checkpoint inhibitors (e.g. ipilimumab, nivolumab) | Sulfonamide antibiotics (e.g. sulfamethoxazole**, sulfadiazine*,†, sulfadoxine†) |

**Not available in the United States.*
*†Antibacterial.*
*‡Sedative/hypnotic.*
*§Nonsteroidal anti-inflammatory drug.*
***Usually in combination with trimethoprim.*

**Table 16.4 Medications most frequently associated with Stevens–Johnson syndrome (SJS) and toxic epidermal necrolysis (TEN).** For a complete updated list of drugs associated with SJS and TEN, refer to Litt JZ, Shear N. Litt's Drug Eruption and Reaction Manual, 26th ed. London: CRC Press, 2019. NRTIs, non-nucleoside reverse transcriptase inhibitors.




**Fig. 16.2 Mucosal involvement in erythema multiforme (EM) major. A** Typical target lesions are seen as well as serous crusting of the vermilion lips and eyelid margin. At the margin of the serous crusting of the lip, there are two zones of color with a polycyclic outline. **B** Erosions and hemorrhagic crusting of the lips in a child with the acro-mucosal variant associated with *Mycoplasma pneumoniae* infection. *A, Courtesy, YDRSC; B, Courtesy, Julie V. Schaffer, MD.*

- SJS is characterized by <10% body surface area (BSA) epidermal detachment, SJS–TEN overlap by 10–30% BSA epidermal detachment, and TEN by >30% BSA epidermal detachment (Fig. 16.5).
- Onset is usually 7–21 days after starting culprit medication.
- Symptoms that typically precede skin findings by 1–3 days: prodromal flu-like syndrome, sore throat, fever, painful skin.
- Tender cutaneous lesions are most prominent on the trunk (see Fig. 17.3), followed by extension to the face (Fig. 16.6A), neck and proximal extremities.



**Fig. 16.3 Acute annular urticaria (urticaria multiforme) in an infant misdiagnosed as erythema multiforme.** These migratory, annular plaques are markedly edematous. Some of the lesions have an erythematous or dusky center while others have central clearing with two shades of peripheral rings. There are no crusts or blisters. The term "urticaria multiforme" has been used to describe these skin findings, which are often preceded by a viral or bacterial infection and accompanied by angioedema of the face, hands, and/or feet. *Courtesy, Julie V. Schaffer, MD.*



**Fig. 16.4 Multiple lesions of erythema multiforme (EM) on the trunk.** The dusky or crusted centers within the papules help to differentiate EM from a morbilliform drug eruption. *Courtesy, YDRSC.*

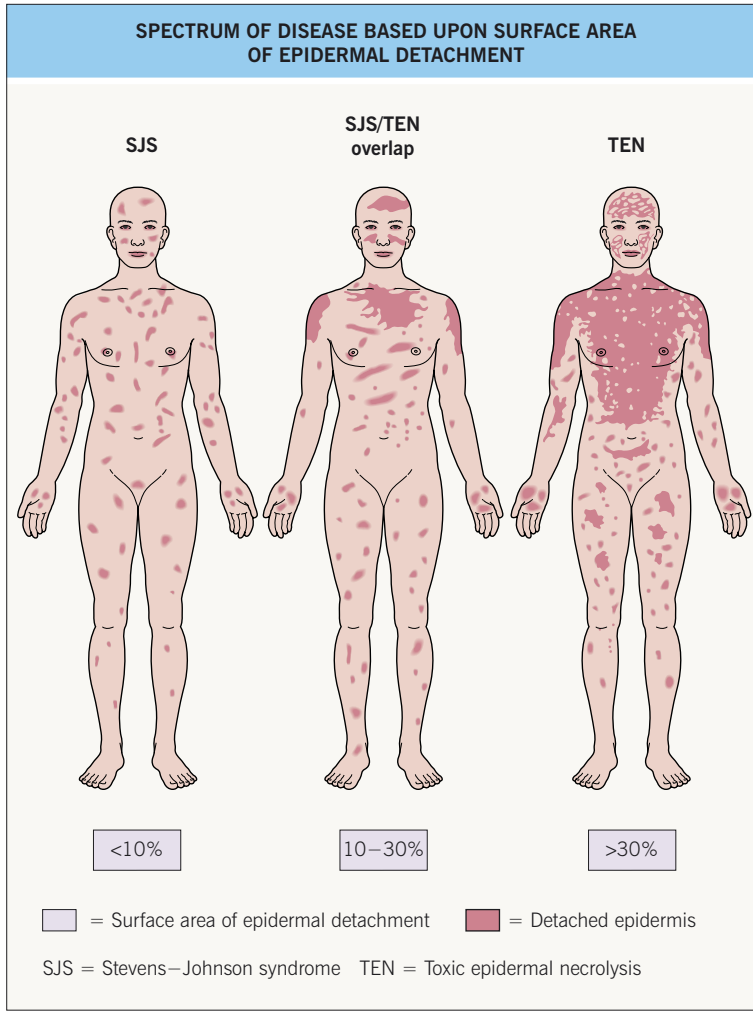


**Fig. 16.5 Spectrum of disease based upon surface area of epidermal detachment.**

- Painful erythema and erosions of buccal, ocular, and genital mucosa are seen in >90% of patients (Fig. 16.7 and see Fig. 16.6B).
- Morphologic progression of skin lesions: dusky red or purpuric *macules* (macular atypical targets) of various sizes and shapes that begin to coalesce (Fig. 16.8); the gray-colored centers become wrinkled and begin to slough due to the development of flaccid bullae and poor attachment of the necrotic epidermis (likened to wet cigarette paper) (Fig. 16.9); the result is raw, denuded, bright red dermis (scalding) (Fig. 16.10).
- Additional systemic findings: fever, lymphadenopathy, hepatitis, cytopenias, erosions of epithelium in the gastrointestinal and respiratory tracts.
- Unpredictable course; worse prognosis in the elderly and with increasing BSA involvement (Table 16.5).
- Mortality rate in SJS is 1–5% and in TEN, 25–35%; survivors may have both ocular (e.g. symblepharon, conjunctival synechiae, entropion, ingrowth of eyelashes) and cutaneous (e.g. scarring, dyspigmentation, eruptive melanocytic nevi) sequelae, as well as persistent erosions of the mucous membranes, urethral stenosis, phimosis, nail dystrophy, and diffuse hair loss (Fig. 16.11).
- Most important factor in improving outcome is withdrawal of the culprit medication.
- Epidermal detachment is due to extensive keratinocyte death via apoptosis, which is




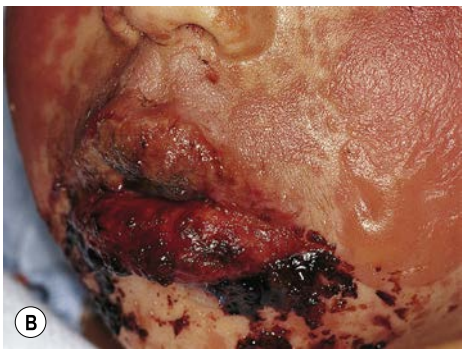


**Fig. 16.6 Stevens–Johnson syndrome (SJS) in childhood. A** In this child with early SJS, there are individual erythematous lesions on the lower face, but coalescence on the cheeks. The two fresh bullae on the cheek are still intact. **B** Hemorrhagic crusts and denudation of the lips in a child with SJS secondary to trimethoprim-sulfamethoxazole therapy; note the bullous cutaneous lesions. *A, Courtesy, Julie V. Schaffer, MD; B, Courtesy, William Weston, MD.*







**Fig. 16.7 Mucosal involvement in Stevens–Johnson syndrome (SJS). A** Erythema and conjunctival erosions. **B** Erosions of the genital mucosa. *A, B, Courtesy, YDRSC.*

mediated by interaction of the death receptor-ligand pair Fas–Fas ligand; perforin, granzyme B, and granulysin also play a role.

- **DDx:** EM major, drug-induced linear IgA bullous dermatosis (LABD), acute generalized exanthematous pustulosis (AGEP), generalized fixed drug eruption (FDE), severe acute GVHD, Rowell syndrome, paraneoplastic pemphigus, toxic erythema of chemotherapy (TEC), disseminated intravascular coagulation/purpura fulminans; in children can consider staphylococcal scalded skin syndrome (SSSS) and Kawasaki disease.
- **Rx:** stop the culprit medication, rapid initiation of supportive care, consider specific therapy (no evidence-based treatment) (Fig. 16.12).



**Fig. 16.8 Cutaneous features of toxic epidermal necrolysis (TEN).** Characteristic dusky red color of the early macular eruption in TEN. Lesions with this color often progress to full-blown necrolytic lesions with dermal–epidermal detachment. *Courtesy, YDRSC.*

For further information see Ch. 20 from *Dermatology, Fourth Edition*.

**For additional online figures visit www.expertconsult.com**



**Fig. 16.9 Stevens–Johnson syndrome (SJS) versus SJS–TEN overlap.** In addition to mucosal involvement and numerous dusky lesions with flaccid bullae, there are areas of coalescence and multiple sites of epidermal detachment. Because the latter involved >10% body surface area, the patient was classified as having SJS–TEN overlap. Note the epidermal detachment (inset), whose appearance has been likened to wet cigarette paper. *Courtesy, YDRSC.*




**Fig. 16.10 Clinical features of toxic epidermal necrolysis (TEN). A** Detachment of large sheets of necrolytic epidermis (>30% body surface area), leading to extensive areas of denuded skin. A few intact bullae are still present. **B** Extensive symmetric hemorrhagic crusting of the face with areas of denudation. **C** Epidermal detachment of palmar skin. **D** Note the rolled and folded sheets of detached epidermis at the edge of denuded skin in addition to widespread erythema and intact bullae. *A, Courtesy, YDRSC; B, Courtesy, Wolfram Hötzenecker, MD, Christina Prins, MD, Lars E. French, MD; C, Courtesy, Lars E. French, MD; D, Courtesy, Luis Requena, MD.*

| SCORTEN SCALE | |
|---|---|
| **Prognostic factors** | **Points** |
| Age >40 years | 1 |
| Heart rate >120 bpm | 1 |
| Cancer or hematologic malignancy | 1 |
| BSA involved on day 1 above 10% | 1 |
| Serum urea level (>10 mmol/l) | 1 |
| Serum bicarbonate level (<20 mmol/l) | 1 |
| Serum glucose level (>14 mmol/l) | 1 |
| **SCORTEN** | **Mortality rate (%)** |
| 0–1 | 3.2 |
| 2 | 12.1 |
| 3 | 35.8 |
| 4 | 58.3 |
| ≥5 | 90 |

**Table 16.5 SCORTEN scale.**




**Fig. 16.11 Sequelae of toxic epidermal necrolysis. A** Symblepharon, erosion of lower lateral eyelid margin and sparse eyelashes; the patient also had entropion with an ingrowth of eyelashes and pebble-like scarring of facial skin. **B** Nail dystrophy consisting of longitudinal ridging and fissuring, fragility and distal notching. *A,B, Courtesy, Wolfram Hötzenecker, MD, Christina Prins, MD, Lars E. French, MD.*

Downloaded for Novin lib (novinlibrary@yahoo.com) at United Arab Emirates University from ClinicalKey.com by Elsevier on March 26, 2022. For personal use only. No other uses without permission. Copyright ©2022. Elsevier Inc. All rights reserved.

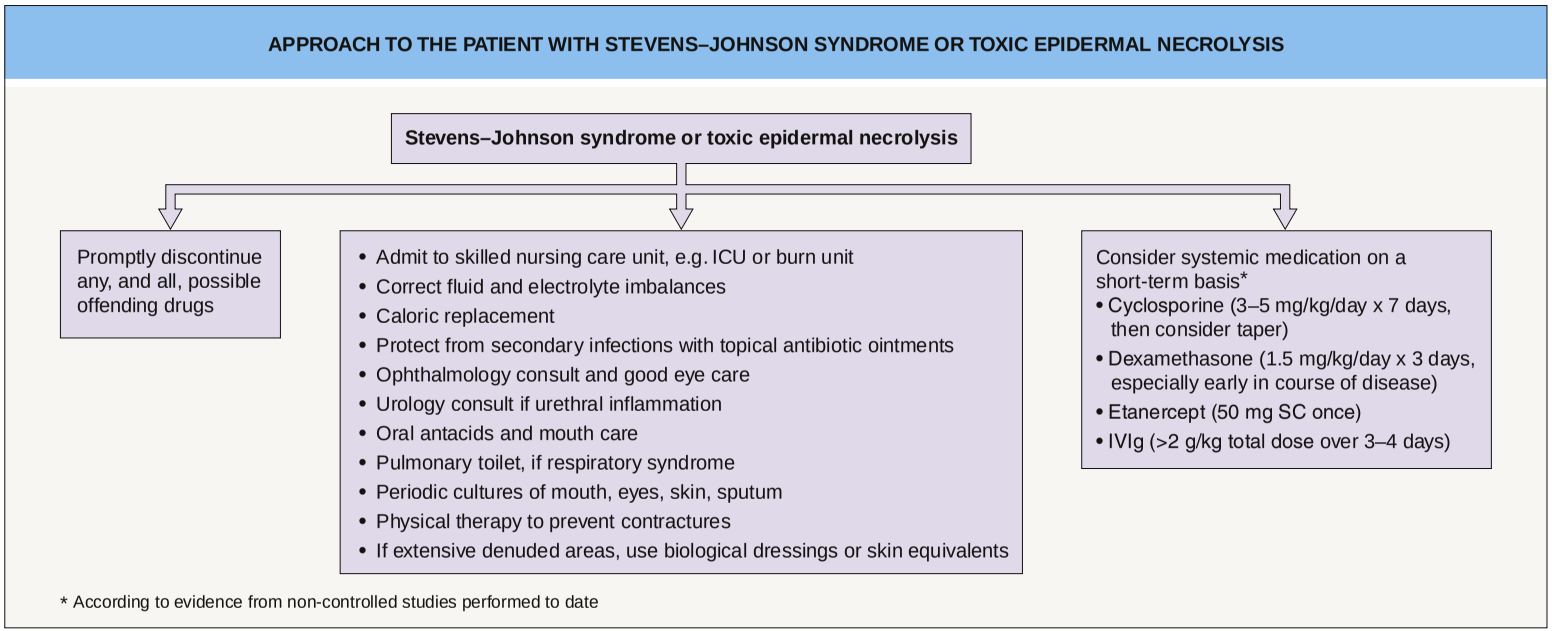


**Fig. 16.12 Management of the patient with Stevens–Johnson syndrome or toxic epidermal necrolysis.** ICU, intensive care unit.

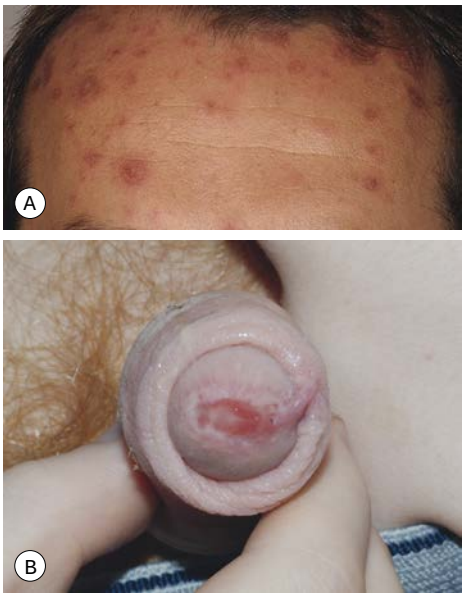


**eFig. 16.1 Erythema multiforme (EM).** **A** Atypical papular target lesions on the upper forehead mixed with more typical target lesions on the lower forehead. **B** Erosions of the genitalia in a child with the acro-mucosal variant of EM associated with *Mycoplasma pneumoniae* infection. *A, Courtesy, Wolfram Hötzenecker, MD, Christina Prins, MD, and Lars E. French, MD; B, Courtesy, Julie V. Schaffer, MD.*



**eFig. 16.3 Mucosal involvement in Stevens–Johnson syndrome.** Conjunctival erosions and exudate. *Courtesy William Weston, MD.*

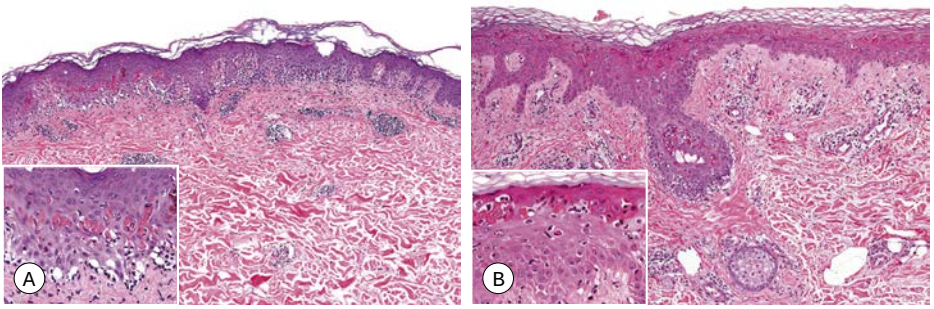


**eFig. 16.2 Erythema multiforme – histopathologic features.** **A** Early lesion – focal sites of apoptosis of keratinocytes with an interface dermatitis and vacuolar degeneration of the basal layer (inset). A perivascular lymphocytic infiltrate is also present. **B** Late lesion – more confluent necrosis of keratinocytes within the upper layers of the stratum spinosum (inset). The hair follicle still has evidence of an interface dermatitis. *Courtesy, Lorenzo Cerroni, MD.*

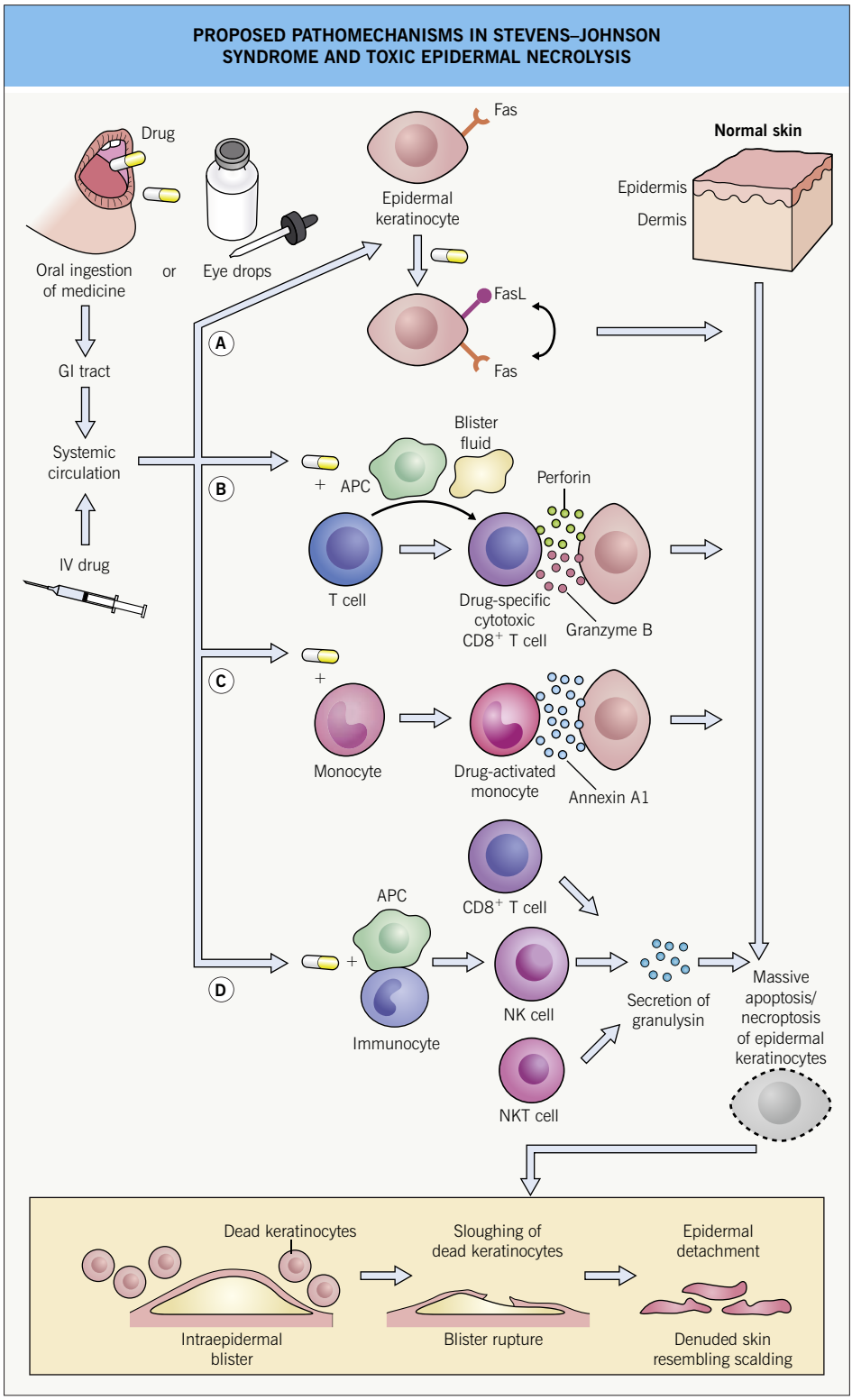


**eFig. 16.4 Proposed pathomechanisms in Stevens–Johnson syndrome (SJS) and toxic epidermal necrolysis (TEN).**



**eFig. 16.5 Stevens–Johnson syndrome (SJS)/toxic epidermal necrolysis (TEN) overlap and early TEN.** A child with early TEN due to diclofenac. There is coalescence of the dusky lesions as well as detached epidermis and denudation. *Courtesy, Lisa Weibel, MD.*



**eFig. 16.6 Clinical features of toxic epidermal necrolysis (TEN).** Hemorrhagic crusts with mucosal involvement. *Courtesy, Lars E. French, MD.*




**eFig. 16.7 Sequelae of toxic epidermal necrolysis (TEN). A, B** Facial involvement of a patient with TEN (50% body surface area involvement) before **(A)** and 3 weeks after **(B)** treatment with IVIg (0.75 g/kg/day for 4 days). Note the hypopigmented scarring on the cheeks **(B)**. **C** Larger irregular areas of hypopigmented scarring on the arm. *A, B, Courtesy, Lars E. French, MD; C, Courtesy, Wolfram Hötzenecker, MD, Christina Prins, MD, and Lars E. French, MD.*

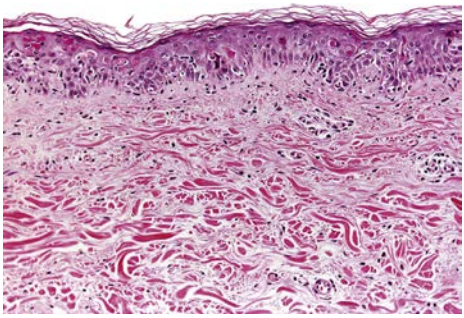

**eFig. 16.8 Toxic epidermal necrolysis – histopathologic features.** Apoptotic keratinocytes are present individually and in clusters within the epidermis. Subtle vacuolar changes along the basal layer are accompanied by minimal inflammation, with scattered lymphocytes within the epidermis. *Courtesy, Lorenzo Cerroni, MD.*

# 17 Drug Reactions

AGEP, acute generalized exanthematous pustulosis;
DRESS, drug reaction with eosinophilia and systemic symptoms;
SJS, Stevens–Johnson syndrome;
TEN, toxic epidermal necrolysis

- The skin is one of the most common targets for adverse drug reactions.
- Risk factors for developing an adverse cutaneous drug reaction (ACDR) include: female gender, immunosuppression (e.g. HIV infection), specific HLA alleles (Table 17.1); the risk increases as the number of drugs taken increases.
- Pathogenesis of ACDRs is not totally understood but can involve immunologic, nonimmunologic, and idiosyncratic mechanisms (Table 17.2).

| SPECIFIC HLA ALLELES THAT INCREASE THE RISK OF SEVERE CUTANEOUS DRUG REACTIONS | | | |
|---|---|---|---|
| **Drug** | **Higher risk population(s)** | **HLA allele** | **Type of drug reaction** |
| Abacavir** | All patients | **B*5701** | DRESS |
| Allopurinol** | Asians, US Blacks > Europeans | **B*5801** | SJS/TEN, DRESS |
| Carbamazepine**, lamotrigine, phenytoin | Han Chinese and other Asians | **B*1502** | SJS/TEN |
| Carbamazepine | Europeans, Japanese, Han Chinese | **A*3101** | DRESS |
| Dapsone | Chinese | B*1301 | DRESS |
| Nevirapine | French | DRB1*01:01 | DRESS |

***It is recommended that patients in at-risk populations be screened for the presence of these HLA alleles prior to initiating treatment with these medications.*

**Table 17.1 Specific HLA alleles that increase the risk of severe cutaneous drug reactions.** Highest relative risks are in bold.

| MECHANISMS OF CUTANEOUS DRUG-INDUCED REACTIONS | |
|---|---|
| Immunologic mechanism (unpredictable) | • IgE-dependent drug reactions<br>• Cytotoxic drug-induced reactions<br>• Immune complex-dependent drug reactions<br>• Cell-mediated reactions |
| Nonimmunologic mechanism (sometimes predictable) | • Overdose<br>• Pharmacologic side effects<br>• Cumulative toxicity<br>• Delayed toxicity<br>• Drug–drug interactions<br>• Alterations in metabolism<br>• Exacerbation of disease |
| Idiosyncratic with a possible immunologic mechanism (unpredictable) | • DRESS<br>• SJS/TEN<br>• Drug reactions in the setting of HIV infection<br>• Drug-induced lupus erythematosus |

**Table 17.2 Mechanisms of cutaneous drug-induced reactions.**

| SELECTED MOST AND LEAST LIKELY DRUGS TO CAUSE ADVERSE CUTANEOUS REACTIONS | |
|---|---|
| **Most likely culprit drugs** | **Least likely culprit drugs*** |
| **Antibiotics** (e.g. penicillins, aminopenicillins, sulfonamides, cephalosporins, tetracyclines, fluoroquinolones) | Acetaminophen<br>Aspirin*<br>Diphenhydramine<br>Opioids* (e.g. meperidine, codeine, morphine)<br>Vitamins (e.g. multivitamins, thiamine, folic acid, ferrous sulfate)<br>Potassium<br>Magnesium<br>Digoxin<br>Aminophylline<br>Spironolactone<br>Nitroglycerin<br>Lidocaine<br>Insulin, regular<br>Prednisone |
| **Aromatic anticonvulsants** (e.g. carbamazepine, phenytoin, phenobarbital, lamotrigine) | |
| **Targeted therapies** (e.g. EGFR inhibitors, BRAF inhibitors [when used alone]) | |
| **Checkpoint inhibitors** (e.g. anti-CTLA-4 antibodies, anti-PD-1 antibodies, anti-PD-L1 antibodies) | |
| **Other**<br>Packed red blood cells<br>NSAIDs<br>Allopurinol | |

*With the exception of urticaria with opioids and aspirin.

**Table 17.3 Selected most and least likely drugs to cause adverse cutaneous reactions.**

- Some of the most and least likely culprit drugs are listed in Table 17.3.
- Most common types of ACDRs: morbilliform > urticaria > vasculitis or fixed drug eruption (FDE) (Table 17.4).
- Severe cutaneous adverse drug reactions (SCARs) cause significant morbidity and potential mortality, but fortunately only constitute ~2% of ACDRs.
- SCARs that require immediate attention: SJS/TEN, DRESS (also referred to as drug-induced hypersensitivity syndrome [DIHS]), vasculitis, serum sickness, serum sickness-like reaction, angioedema/anaphylaxis, warfarin-induced skin necrosis, and heparin-induced thrombocytopenia and thrombosis syndrome (HIT) (see Table 17.4 and Fig. 17.1).
- Features that should alert one to the presence of a SCAR are outlined in Table 17.5.
- A practical approach in determining the cause of an ACDR is outlined in Table 17.6.
- Organizing pertinent information into a drug chart (see Fig. 17.2 and Appendix) can be helpful in synthesizing the available information.
- The most important step in the treatment of SCARs is early identification and withdrawal of the culprit drug.
- In non-life-threatening morbilliform drug eruptions, the culprit drug is ideally stopped, but if vitally important to the patient's health and no alternative drug is available, one can consider "treating through" the eruption with supportive care (e.g. topical CS and oral antihistamines).
- An approach to the management of a suspected ACDR is presented in Fig. 17.1.
- Additional reviews of specific types of drug reactions can be found in other chapters (Table 17.7).
- The use of both targeted therapies and immune checkpoint inhibitors to treat various malignancies has expanded rapidly. The more common mucocutaneous side effects of these agents are listed in Tables 17.8 and 17.9, respectively.
- Selected drug-induced eruptions due to chemotherapeutic agents are listed in Table 17.10.
- Localized injection site reactions to selected medications are outlined in Table 17.11.

For further information see Ch. 21 from *Dermatology, Fourth Edition*.

**For additional online figures and tables visit www.expertconsult.com**

| CHARACTERISTICS OF SELECTED ADVERSE CUTANEOUS DRUG REACTIONS (ACDR) | | | | | | | |
|---|---|---|---|---|---|---|---|
| **Diagnosis/ *% drug-induced*** | **Selected responsible drugs** | **Time interval to onset** | **Mucocutaneous features** | **Systemic features** | **Other helpful hints** | **Differential diagnosis** | **Treatment (in addition to withdrawal of culprit drug)** |
| Severe cutaneous adverse reactions to drugs (SCARs) (Fig. 17.1) | | | | | | | |
| **SJS**<br>*80–90+%*<br>**TEN**<br>*80–90+%*<br>(Fig. 17.3)<br>(see Ch. 16) | • Antibiotics (e.g. sulfonamides, aminopenicillins, cephalosporins, quinolones)<br>• Aromatic anticonvulsants*<br>• NSAIDs<br>• Allopurinol<br>• Antiretroviral drugs (especially NNRTIs [nevirapine])<br>• Checkpoint inhibitors (e.g. ipilimumab, nivolumab) | • 7–21 days | • Mucosal erosions<br>• Dusky macular atypical targets<br>• Necrosis and epidermal detachment<br>• SJS <10% BSA<br>• SJS/TEN overlap 10–30% BSA<br>• TEN >30% BSA | • Prodromal URI symptoms<br>• Fever<br>• Skin pain | • Leukopenia<br>• Skin biopsy<br>• Frozen section to differentiate from SSSS | • EM major<br>• LABD<br>• SSSS<br>• AGEP<br>• Severe acute GVHD<br>• Rowell syndrome<br>• Kawasaki disease<br>• Generalized FDE<br>• Paraneoplastic pemphigus | Mild disease<br>• Hospitalization<br>• Wound care<br>• Ophthalmology consult<br>Severe disease<br>• ICU/burn care<br>• Consider other systemic therapy (see Fig. 16.12) |

**Table 17.4A Characteristics of selected adverse cutaneous drug reactions (ACDR).** *Continued*

| CHARACTERISTICS OF SELECTED ADVERSE CUTANEOUS DRUG REACTIONS (ACDR) | | | | | | | |
|---|---|---|---|---|---|---|---|
| **Diagnosis/ *% drug-induced*** | **Selected responsible drugs** | **Time interval to onset** | **Mucocutaneous features** | **Systemic features** | **Other helpful hints** | **Differential diagnosis** | **Treatment (in addition to withdrawal of culprit drug)** |
| **DRESS** *80–90+%* (Fig. 17.4) | • Aromatic anticonvulsants* • Antimicrobials (e.g. dapsone, sulfonamides) • Allopurinol • Antiretrovirals (e.g. abacavir, nevirapine) | • 15–40 days | • Facial edema • Edematous morbilliform eruption with follicular accentuation • Face, upper trunk, and extremities favored initially • Occasionally other skin findings: vesicles,bullae, pustules, erythroderma, purpura | (Always present to some degree) • Fever • Lymphadenopathy • Arthralgias/arthritis • Hepatitis • Myocarditis • Pneumonitis • Nephritis • Thyroiditis • Gastrointestinal bleeding (allopurinol) | • Marked eosinophilia • Lymphocytosis with increased atypical lymphocytes • Increased liver enzymes • Consider skin biopsy • Consider laboratory testing for reactivation of HHV6 in immunocompromised host • Cutaneous and visceral involvement may persist for weeks to months after withdrawal of culprit drug • With rapid taper of CS may see rebound | • Viral exanthem • Other ACDR • Cutaneous lymphoma • Pseudolymphoma • Idiopathic hypereosinophilic syndrome | • Oral CS with a long course (often several months for more severe disease) and slow taper • Topical CS may relieve symptoms • Longitudinal evaluation for up to a year, given delayed manifestations, e.g. thyroiditis, myocarditis |

**Table 17.4A** *Continued* **Characteristics of selected adverse cutaneous drug reactions (ACDR).** *Continued*

| CHARACTERISTICS OF SELECTED ADVERSE CUTANEOUS DRUG REACTIONS (ACDR) | | | | | | | |
|---|---|---|---|---|---|---|---|
| **Diagnosis/ *% drug-induced*** | **Selected responsible drugs** | **Time interval to onset** | **Mucocutaneous features** | **Systemic features** | **Other helpful hints** | **Differential diagnosis** | **Treatment (in addition to withdrawal of culprit drug)** |
| **Cutaneous small vessel vasculitis (CSVV)** *~10%* | • Penicillins<br>• NSAIDs<br>• Antibiotics (e.g. sulfonamides, cephalosporins, quinolones)<br>• Diuretics (e.g. furosemide, hydrochlorothiazide)<br>• Allopurinol<br>• Phenytoin<br>• Levamisole<br>• Bortezomib<br>• Systemic immunomodulators (e.g. G-CSF, GM-CSF, interferons, TNF inhibitors) | • 7–21 days (initial)<br>• <3 days (rechallenge) | • Purpuric papules, most often on lower extremities<br>• Hemorrhagic blisters<br>• Urticaria-like lesions<br>• Pustules | (Not always present)<br>• Fever<br>• Myalgias<br>• Arthralgias/arthritis<br>• Headache<br>• Peripheral edema<br>• Peripheral neuropathy<br>• Glomerulonephritis | • Urinalysis and BUN/Cr to exclude active urine sediment/kidney involvement<br>• Check stools for evidence of GI bleeding<br>• Skin biopsy of early lesion for H&E and DIF | • CSVV that is idiopathic or due to infection, autoimmune connective tissue or disease, malignancy | Mild disease<br>• Observation<br>• High-potency topical CS<br>Severe or systemic disease<br>• Oral CS<br>• Steroid-sparing immunosuppressive agents |

**Table 17.4A** *Continued* **Characteristics of selected adverse cutaneous drug reactions (ACDR).** *Continued*

| CHARACTERISTICS OF SELECTED ADVERSE CUTANEOUS DRUG REACTIONS (ACDR) | | | | | | | |
|---|---|---|---|---|---|---|---|
| **Diagnosis/ *% drug-induced*** | **Selected responsible drugs** | **Time interval to onset** | **Mucocutaneous features** | **Systemic features** | **Other helpful hints** | **Differential diagnosis** | **Treatment (in addition to withdrawal of culprit drug)** |
| **Cutaneous medium vessel vasculitis (CMVV)** | • Hydralazine<br>• Propylthiouracil<br>• Methimazole<br>• Minocycline<br>• Penicillamine<br>• Allopurinol<br>• Sulfasalazine<br>• Levamisole | • Hours to years | • Purpuric plaques and nodules (favors face, ears, breasts, and extremities)<br>• Ulcers<br>• Livedo reticularis<br>• Digital necrosis<br>• Occasionally palpable purpura, mimicking a CSSV | (Often present)<br>• Fever<br>• Arthralgias/arthritis<br>• Necrotizing glomerulonephritis<br>• Pulmonary hemorrhage<br>• Peripheral neuropathy | • Skin biopsy may reveal leukocytoclastic vasculitis of superficial and deep vessels<br>• ANCA (+) with propylthiouracil, hydralazine, minocycline, levamisole | • Polyarteritis nodosa (classic or cutaneous)<br>• Granulomatosis with polyangiitis<br>• Microscopic polyangiitis<br>• Eosinophilic granulomatosis with polyangiitis | Mild, early disease<br>• Drug withdrawal is often adequate<br>Severe disease with systemic involvement or late withdrawal of culprit drug<br>• May require immunosuppressive therapy |
| **"True" serum sickness** (due to nonhuman proteins)<br>*>90%* | • Anti-thymocyte globulin<br>• Tositumomab<br>• Infliximab | • 7–21 days | • Morbilliform eruption<br>• Urticaria<br>• Purpuric papules/ plaques | • Fever<br>• Arthralgias/ arthritis<br>• Lymphadenopathy<br>• Renal disease | • Hypocomplementemia<br>• Circulating immune complexes<br>• Vasculitis seen in skin biopsy | • Viral exanthem<br>• Other ACDR | Mild disease<br>• Supportive care<br>Severe disease<br>• Oral CS<br>• Steroid-sparing immunosuppressive agents |
| **Serum sickness-like reaction**<br>*>90%*<br>(see Fig. 3.3B) | • Cefaclor<br>• Minocycline<br>• Penicillins<br>• Sulfonamides<br>• Bupropion<br>• Propranolol<br>• Phenytoin<br>• NSAIDs | • 7–21 days | • Morbilliform eruption<br>• Urticaria, acral edema<br>• Urticarial papules and plaques with a purpuric component | • Fever<br>• Arthralgia/arthritis<br>• Lymphadenopathy | • *No* hypocomplementemia, circulating immune complexes, vasculitis or renal disease | • Urticaria multiforme<br>• Viral exanthem<br>• DRESS<br>• Acute hemorrhagic edema of infancy<br>• EM or early SJS<br>• Kawasaki disease | • Long-acting oral antihistamines, especially if urticaria<br>• Oral CS if significant symptoms |

**Table 17.4A** *Continued* **Characteristics of selected adverse cutaneous drug reactions (ACDR).** *Continued*

| CHARACTERISTICS OF SELECTED ADVERSE CUTANEOUS DRUG REACTIONS (ACDR) | | | | | | | |
|---|---|---|---|---|---|---|---|
| **Diagnosis/ *% drug-induced*** | **Selected responsible drugs** | **Time interval to onset** | **Mucocutaneous features** | **Systemic features** | **Other helpful hints** | **Differential diagnosis** | **Treatment (in addition to withdrawal of culprit drug)** |
| **Angioedema/ anaphylaxis** *30%* | • Penicillins<br>• Radiocontrast media<br>• Monoclonal antibodies | • Minutes to hours | • Acute pale or pink subcutaneous swelling<br>• Favors face (eyelids, ears, lips, nose)<br>• Less often extremities and genitalia<br>• Associated with urticaria 50% of the time | • Involvement of oropharynx, larynx, epiglottis, and surrounding tissues may impair breathing and swallowing<br>• Intestinal wall edema can cause nausea, vomiting, diarrhea, pain<br>• Hypotension and circulatory collapse with anaphylaxis | | • Severe insect bite reaction<br>• Food allergies<br>• Hereditary angioedema<br>• Acquired angioedema<br>• Estrogen-dependent angioedema | Mild disease<br>• Oral antihistamine<br>Severe disease<br>• Hospitalization<br>• SC epinephrine (adrenaline)<br>• IV/oral antihistamines<br>• IV/oral CS |
| | • NSAIDs | • 1–7 days | | | | | |
| | • ACE inhibitors<br>• Angiotensin II receptor blockers | • 1 day to several years | | | | | |
| **Warfarin (Coumadin®)-induced skin necrosis** *100%* (Fig. 17.5) | • Warfarin | • 2–5 days | • Red to violaceous painful plaques evolving into hemorrhagic blisters and necrotic ulcers<br>• Favors areas of greatest subcutaneous fat, e.g. breasts, thighs, buttocks | • Extreme pain at affected site | • Protein C deficiency | • DIC<br>• Septicemia | • Vitamin K<br>• IV heparin<br>• IV protein C concentrate |

**Table 17.4A** *Continued* **Characteristics of selected adverse cutaneous drug reactions (ACDR).** *Continued*

| CHARACTERISTICS OF SELECTED ADVERSE CUTANEOUS DRUG REACTIONS (ACDR) | | | | | | | |
|---|---|---|---|---|---|---|---|
| **Diagnosis/ *% drug-induced*** | **Selected responsible drugs** | **Time interval to onset** | **Mucocutaneous features** | **Systemic features** | **Other helpful hints** | **Differential diagnosis** | **Treatment (in addition to withdrawal of culprit drug)** |
| **Heparin-induced thrombocytopenia with thrombosis (HIT)** *100%* (Fig. 17.6) (see Fig. 18.2) | • Heparin – all forms (IV, SC, LMWH; and in heparin flushes used for dialysis and IV catheters) | • 5–10 days (initial)<br>• Early-onset, occurs within 24 hours (re-challenge within ~100 days of last exposure)<br>• Delayed-onset, occurs ~9 days after stopping heparin<br>• Anaphylactoid reaction, occurs within 30 minutes of IV bolus | • Skin necrosis at sites of injection and at distant sites (e.g. distal extremities, nose)<br>• Digital ischemia<br>• Petechiae | • Venous and arterial systemic thrombosis<br>• In anaphylactoid reaction, see acute inflammatory (fever, chills) and cardiorespiratory (hypertension, shortness of breath) symptoms | • Thrombocytopenia or decrease in platelets by >50%<br>• Positive functional assay (serotonin release assay or heparin-induced platelet aggregation assay)<br>• Positive ELISA immunoassay for antiplatelet factor 4/heparin antibodies | • DIC<br>• Septicemia<br>• Anti-phospholipid antibody syndrome | • Change to another, non-heparin anticoagulant, e.g.<br>• Argatroban<br>• Danaparoid<br>• Fondaparinux<br>• Bivalirudin<br>• Direct acting oral anticoagulants<br>• Once the thrombocytopenia is resolved, most patients are then transitioned to warfarin or other outpatient anticoagulant |

**Aromatic anticonvulsants (e.g. carbamazepine, phenytoin, phenobarbital, lamotrigine [especially in combination with valproic acid] are most often implicated).*

**Table 17.4A** *Continued* **Characteristics of selected adverse cutaneous drug reactions (ACDR).** 5-FU, 5-fluorouracil; ACE, angiotensin-converting enzyme; DIC, disseminated intravascular coagulation; DIF, direct immunofluorescence; G-CSF and GM-CSF, granulocyte and granulocyte–macrophage colony-stimulating factors; LABD, linear IgA bullous dermatosis; LMWH, low-molecular-weight heparin; NNRTIs, non-nucleoside reverse transcriptase inhibitors; SSSS, staphylococcal scalded skin syndrome.

| CHARACTERISTICS OF SELECTED ADVERSE CUTANEOUS DRUG REACTIONS (ACDR) | | | | | | | |
|---|---|---|---|---|---|---|---|
| **Diagnosis/ *% drug-induced*** | **Selected responsible drugs** | **Time interval to onset** | **Mucocutaneous features** | **Systemic features** | **Other helpful hints** | **Differential diagnosis** | **Treatment (in addition to withdrawal of culprit drug)** |
| Less severe cutaneous adverse reactions to drugs | | | | | | | |
| **Morbilliform/ exanthematous/ maculopapular drug eruption**<br>*Child: 10–20%*<br>*Adult: 50–70%*<br>(Fig. 17.7)<br>(see Fig. 3.2) | • Aminopenicillins<br>• Sulfonamides<br>• Cephalosporins<br>• Aromatic anticonvulsants*<br>• Allopurinol<br>• Abacavir<br>• Nevirapine | • 4–14 days (occasionally sooner with rechallenge) | • Erythematous macules and subtle papules that often become confluent<br>• Symmetric distribution favoring trunk, upper extremities<br>• Dependent areas in bed-ridden patients<br>• Purpuric lesions on lower legs and feet<br>• Sometimes annular or targetoid plaques<br>• Typically no mucosal involvement | • Pruritus<br>• Low-grade fever | • Mild eosinophilia<br>• May get a bit worse before getting better upon withdrawal of culprit drug<br>• Eruption resolves in 1–2 weeks after withdrawal of culprit drug | • Viral exanthem | • Supportive care with oral antihistamines and mild topical CS<br>• Can treat through eruption if culprit drug is crucially important to patient and no adequate alternative |

**Table 17.4B Characteristics of selected adverse cutaneous drug reactions (ACDR).** Less severe adverse cutaneous reactions to drugs. *Continued*

| CHARACTERISTICS OF SELECTED ADVERSE CUTANEOUS DRUG REACTIONS (ACDR) | | | | | | | |
|---|---|---|---|---|---|---|---|
| **Diagnosis/ *% drug-induced*** | **Selected responsible drugs** | **Time interval to onset** | **Mucocutaneous features** | **Systemic features** | **Other helpful hints** | **Differential diagnosis** | **Treatment (in addition to withdrawal of culprit drug)** |
| **Urticaria** *<10%* (Fig. 17.8) (see Fig. 3.3A) | • Penicillins<br>• Cephalosporins<br>• NSAIDs<br>• Monoclonal antibodies<br>• Radiocontrast media** | • Minutes to hours | • Transient erythematous, edematous papules and plaques with central pallor<br>• Varied sizes and configurations, including annular; sometimes transient central duskiness in children (urticaria "multiforme") | • Pruritus | • Individual lesions last <24 hours<br>• Normal skin left behind when lesions resolve | • Other causes of urticaria (e.g. virus, food allergy, idiopathic)<br>• Urticarial vasculitis<br>• Serum sickness-like reaction<br>• EM | • Oral antihistamines with a longer half-life, e.g. cetirizine |
| **AGEP** *70–90%* (Fig. 17.9) | • Antibiotics (e.g. aminopenicillins, penicillins, cephalosporins, clindamycin, macrolides, sulfonamides)<br>• Calcium channel blockers (especially diltiazem) | • <4 days | • Numerous, small, mostly nonfollicular, sterile pustules that arise within large areas of edematous erythema<br>• Often begins on face and in intertriginous areas, and then becomes widespread<br>• In 50% of patients, additional skin lesions: petechiae, purpura, atypical target-like lesions, vesicles | • Fever<br>• Pruritus or burning | • Leukocytosis with neutrophilia<br>• Transient renal dysfunction<br>• Hypocalcemia<br>• Skin biopsy helpful<br>• Resolves with superficial desquamation | • Acute pustular psoriasis<br>• DRESS<br>• Morbilliform drug eruption<br>• TEN | • Supportive care<br>• Mild topical CS<br>• Antipyretics |

**Table 17.4B** *Continued* **Characteristics of selected adverse cutaneous drug reactions (ACDR).** Less severe adverse cutaneous reactions to drugs. *Continued*

| CHARACTERISTICS OF SELECTED ADVERSE CUTANEOUS DRUG REACTIONS (ACDR) | | | | | | | |
|---|---|---|---|---|---|---|---|
| **Diagnosis/ *% drug-induced*** | **Selected responsible drugs** | **Time interval to onset** | **Mucocutaneous features** | **Systemic features** | **Other helpful hints** | **Differential diagnosis** | **Treatment (in addition to withdrawal of culprit drug)** |
| **Fixed drug eruption (FDE)** *99%* (Fig. 17.10) | • Sulfonamides<br>• NSAIDs<br>• Tetracyclines<br>• Pseudoephedrine (non-pigmenting FDE) | • 7–14 days (first exposure)<br>• Within 24–48 hours (rechallenge) | • One or a few round, sharply demarcated erythematous and edematous plaques<br>• Sometimes with a dusky violaceous hue, central blister, or detached epidermis<br>• Favors lips, face, hands, feet, genitalia<br>• Fades over several days; residual postinflammatory brown pigmentation<br>Variants<br>• Generalized FDE (numerous lesions)<br>• Non-pigmenting FDE<br>• Linear FDE | | • Upon rechallenge lesions recur at exact same sites ± new lesions<br>• Skin biopsy helpful | • Arthropod or spider bite (single lesion)<br>• EM (generalized FDE)<br>• SJS (generalized FDE plus mucosal involvement)<br>• TEN (generalized FDE with blisters/ epidermal detachment)<br>• Cellulitis (non-pigmenting FDE)<br>• Lichen planus (linear FDE) | • Supportive care |

**Aromatic anticonvulsants (e.g. carbamazepine, phenytoin, phenobarbital, lamotrigine).*
***Often anaphylactoid reaction.*

**Table 17.4B** *Continued* **Characteristics of selected adverse cutaneous drug reactions (ACDR).** Less severe adverse cutaneous reactions to drugs. 5-FU, 5-fluorouracil, EM, erythema multiforme.

## APPROACH TO A SUSPECTED ADVERSE CUTANEOUS DRUG REACTION (ACDR)

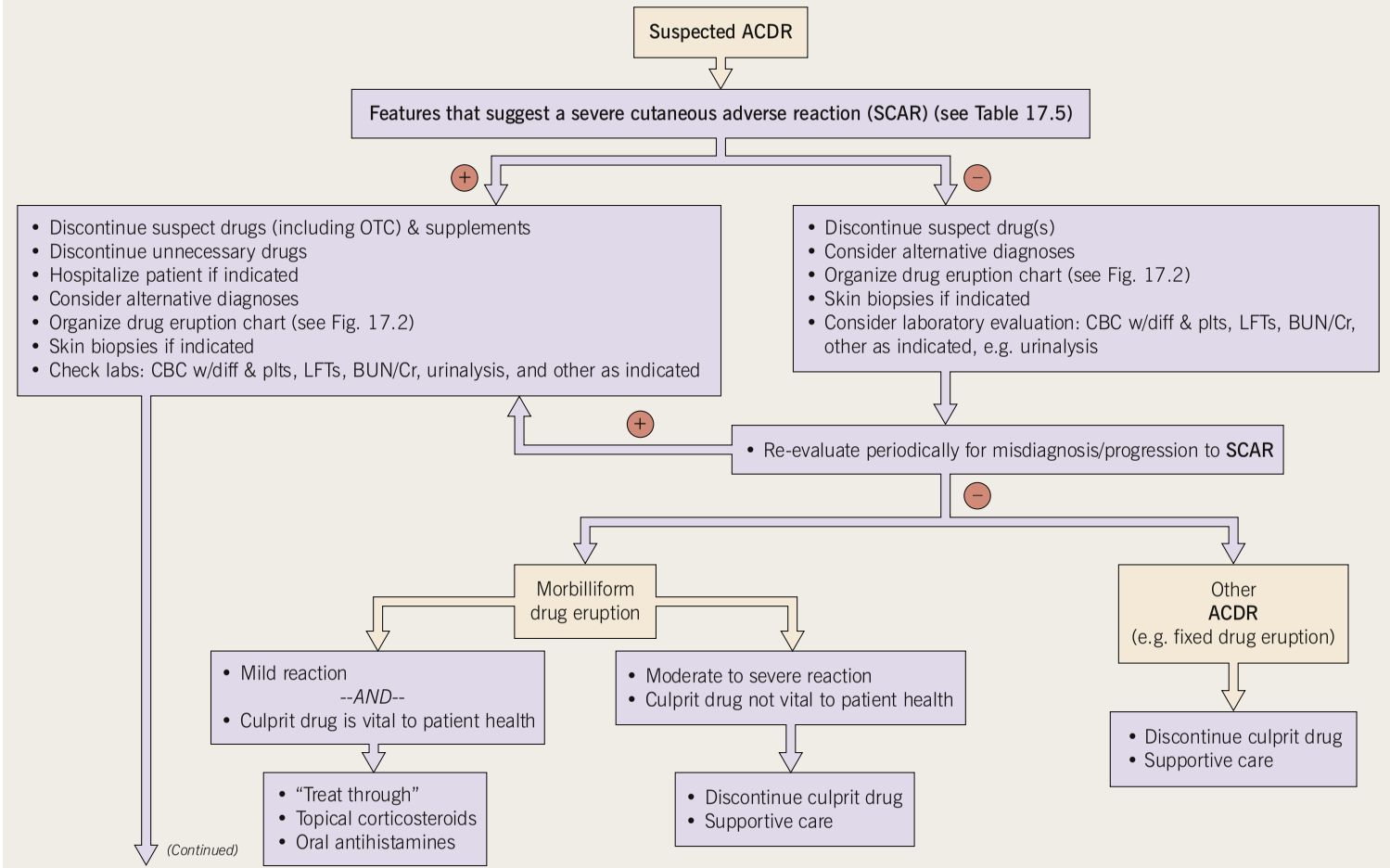

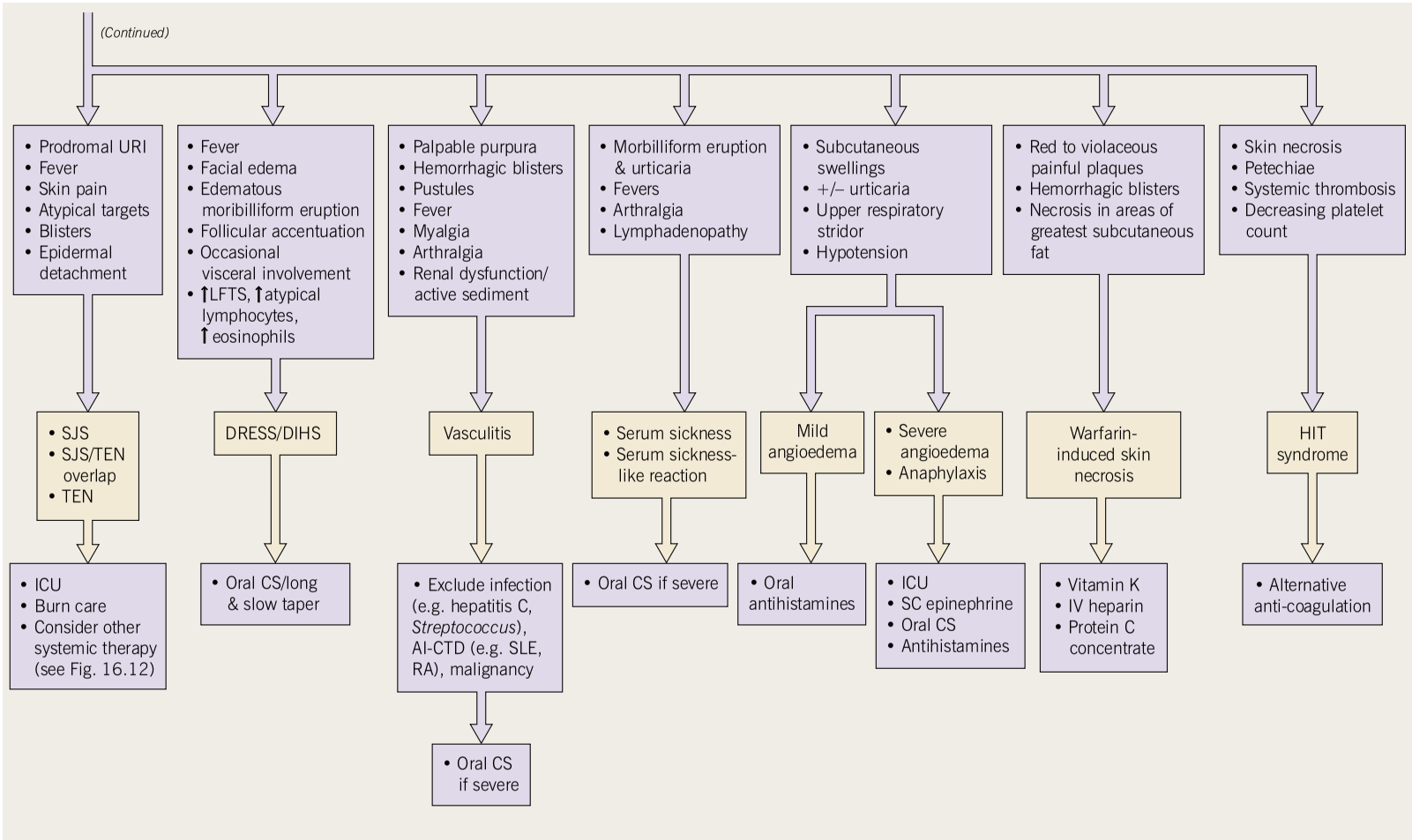


**Fig. 17.1 Approach to a suspected adverse cutaneous drug reaction (ACDR).** diff, differential; HIT, heparin-induced thrombocytopenia and thrombosis syndrome; plts, platelets; RA, rheumatoid arthritis; SCAR, severe cutaneous adverse reaction to a drug.

**DRUG ERUPTION CHART - SAMPLE**

| Drugs | Pre-hospital Duration (years) | Dates drug(s) administered | | | | | | Rash onset ↓ | Derm consult ↓ | | Rash worse ↓ | | | Rash better ↓ | | |
|---|---|---|---|---|---|---|---|---|---|---|---|---|---|---|---|---|
| | | 6/15 | 6/16 | 6/17 | 6/18 | 6/19 | 6/20 | 6/21 | 6/22 | 6/23 | 6/24 | 6/25 | 6/26 | 6/27 | 6/28 | 6/29 |
| Aspirin | x 10 | × | × | × | × | × | × | × | × | × | × | × | × | × | × | × |
| Heparin SC | | | × | × | × | × | × | × | × | × | × | × | × | × | × | × |
| Famotidine | | × | × | × | × | × | × | × | × | | | | | | | |
| Insulin | x 5 | × | × | × | × | × | × | × | × | × | × | × | × | × | × | × |
| Digoxin | x 8 | × | × | × | × | × | × | × | × | × | × | × | × | × | × | × |
| Diltiazem | x 6 | × | × | × | × | × | × | × | × | × | × | × | × | × | × | × |
| Multivitamin | x 5 | × | × | × | × | × | × | × | × | | | | | | | |
| Thiamine | | × | × | × | | | | | | | | | | | | |
| Folate | | × | × | × | × | × | × | × | × | | | | | | | |
| Lorazepam | | × | × | × | × | × | × | × | × | × | × | × | | | | |
| Zolpidem | | × | × | | × | × | | × | | | | | | | | |
| Acetaminophen | | × | × | | | | | | | | | | | | | |
| Ibuprofen | | | | × | × | | | | | | | | | | | |
| Tramadol HC | | | | | | × | × | × | | | | | | | | |
| Maalox® | | | × | × | × | | | | | | | | | | | |
| Lactulose | | | | | | × | × | × | | | | | | | | |
| Diphenhydramine | | | | | | | | × | × | × | × | × | × | | | |
| Ampicillin/sulbactam | | × | × | | | | | | | | | | | | | |
| Vancomycin | | | | × | × | × | × | × | × | | | | | | | |
| Ceftazidime | | | | × | × | × | × | × | × | | | | | | | |
| Levofloxacin | | | | | | | | | | × | × | | | | | |
| Linezolid | | | | | | | | | | | | × | × | × | × | × |
| | | | | | | | | | | | | | | | | |
| | | | | | | | | | | | | | | | | |
| | | | | | | | | | | | | | | | | |
| **Laboratory** | | | | | | | | | | | | | | | | |
| WBC | | 20.2 | 16.5 | 7.0 | 7.6 | 8.1 | 10.2 | 11.3 | 11.5 | 11.2 | 11.5 | 10.5 | 9.2 | 7.0 | 7.0 | 6.5 |
| % Eosinophils | | 0% | 0% | <1% | <1% | 3% | 5% | 7% | 9% | 9% | 8% | 7% | 5% | 3% | 1% | 1% |
| % Atypical lymphocytes | | 0% | → | | | | | | | | | | | | | |
| Platelets | | nl | → | | | | | | | | | | | | | |
| AST | | nl | → | | | | | | | | | | | | | |
| ALT | | nl | → | | | | | | | | | | | | | |
| BUN/Cr | | nl | → | | | | | | | | | | | | | |
| Temperature (ºC) | | 40 | | | 38 | | | 38.3 | | 38.5 | | | 37.5 | | | |
| Physical exam* | | nl | → | | | | | | | | | | | | | |
| Type of rash | | | | | | | | Morbilliform → Confluence | | | | | | | | |

*Checking for the presence of lymphadenopathy, arthritis, wheezing, hypotension

**Fig. 17.2 Drug eruption chart.** This is a helpful working template for organizing all of the available patient information into one document for a patient with a suspected adverse cutaneous drug reaction (ACDR). **Step 1:** Compile all of the recently consumed or administered drugs (including prescription, OTC, and supplements) into the chart. **Step 2:** Review and list the pertinent laboratory information and physical findings at the bottom of the chart. **Step 3:** Referring to Fig. 17.1, exclude a SCAR and categorize the type of ACDR. **Step 4:** Based on time intervals (see Table 17.4) and the most and least likely drugs to cause ACDR (see Table 17.3), begin to formulate the most likely culprit drugs and recommend their discontinuation. In addition, discontinue unnecessary drugs. **Step 5:** Longitudinal evaluation of the patient is necessary to (1) exclude progression to a SCAR, (2) determine the response upon discontinuation of the culprit drug (noting that it might "get worse before it gets better"), and (3) provide supportive care to the patient. In this sample patient, the most likely culprit drugs are ceftazidime > ampicillin/sulbactam > vancomycin; however, the multivitamin, folate, famotidine, zolpidem, acetaminophen, ibuprofen, tramadol, Maalox®, and lorazepam (must taper off and not abruptly stop) were also discontinued. Note that the discontinuation of levofloxacin by the primary physicians was not necessary. Refer to www.expertconsult.com for a blank template of the drug eruption chart. ALT, alanine aminotransferase; AST, aspartate aminotransferase.



**Fig. 17.3 Early Stevens–Johnson syndrome.** This patient was originally diagnosed with a severe morbilliform drug eruption from penicillin, but then areas of epidermal detachment due to friction developed. *Courtesy, YDRSC.*

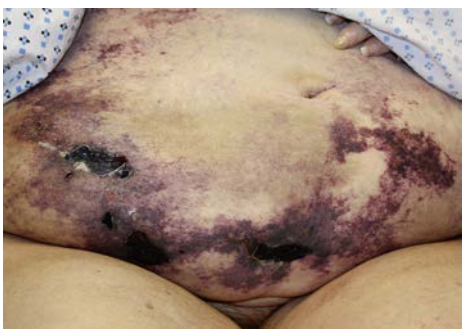

**Fig. 17.5 Warfarin (Coumadin®)-induced skin necrosis.** Retiform purpuric plaques with large hemorrhagic crusts and underlying ulcers on the abdominal pannus of a woman who recently initiated warfarin treatment. *Courtesy, Jean L. Bolognia, MD.*




**Fig. 17.4 Drug reaction with eosinophilia and systemic symptoms (DRESS).** Also known as drug-induced hypersensitivity syndrome (DIHS). **A** Facial edema and multiple edematous papules are present. **B** Exanthematous eruption with confluence, edema and vesiculation on the forearm. *A, Courtesy, Kenneth Greer, MD; B, Courtesy Alicia Little, MD.*

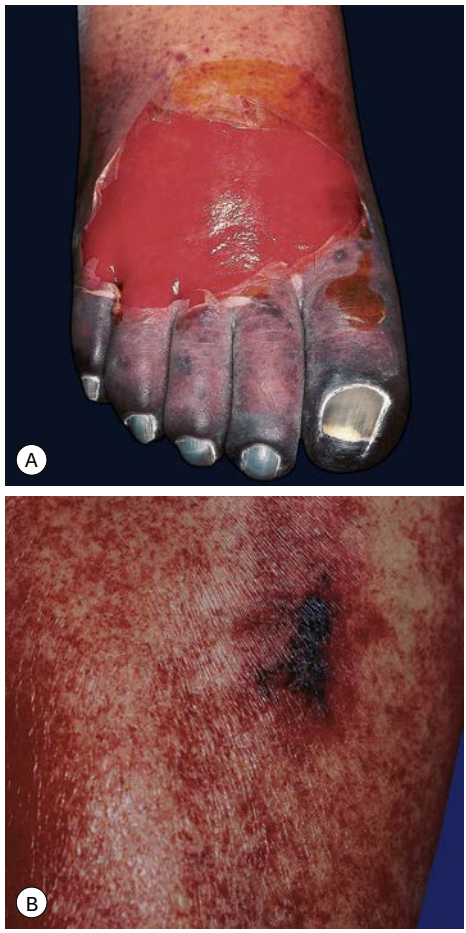


**Fig. 17.6 Heparin-induced thrombocytopenia with thrombosis syndrome (HIT). A** Ischemia and necrosis of the foot. **B** Petechiae due to thrombocytopenia and an irregular area of cutaneous necrosis. *A, Courtesy, Kalman Watsky, MD; B, Courtesy, Jean L. Bolognia, MD.*



**Fig. 17.8 Urticaria secondary to penicillin.** Several of the lesions have a figurate appearance. *Courtesy, YDRSC.*

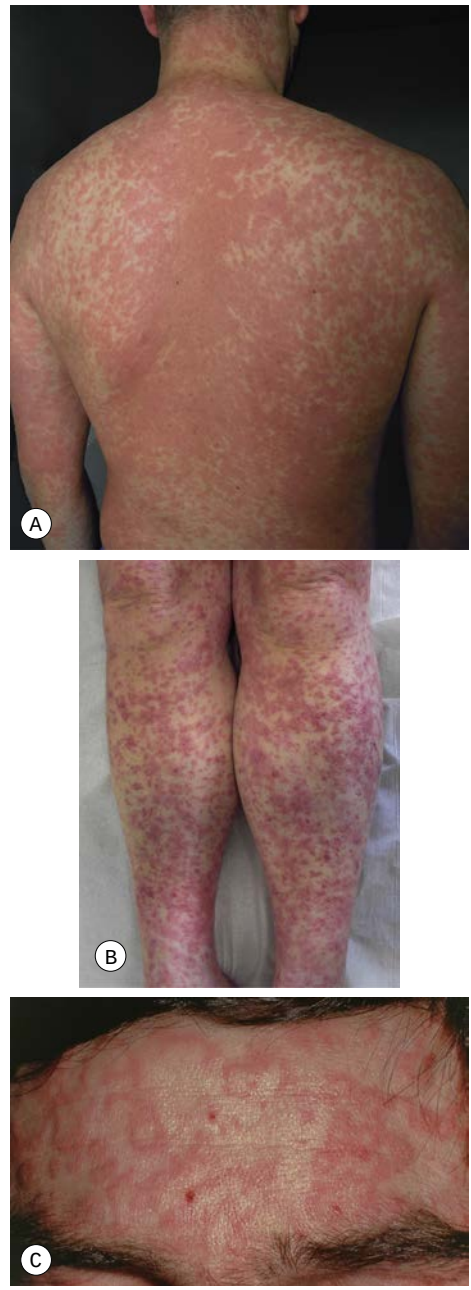


**Fig. 17.7 Morbilliform (exanthematous) drug eruptions. A** Erythematous papules and urticarial lesions with confluence on the mid back induced by amoxicillin. **B** Due to dependency, lesions on the distal lower extremities can become petechial or purpuric. **C** Pink papules and annular lesions on the forehead due to phenobarbital. *A, B, Courtesy, Laurence Valeyrie-Allanore, MD; C, Courtesy, YDRSC.*

| FEATURES THAT SUGGEST A SEVERE CUTANEOUS ADVERSE REACTION TO A DRUG | | |
|---|---|---|
| **Cutaneous features** | **Systemic features** | **Laboratory findings** |
| • Skin pain<br>• Confluent erythema<br>• Facial edema<br>• Blisters or epidermal detachment<br>• Mucosal erosions<br>• Necrosis<br>• Palpable purpura<br>• Urticaria<br>• Swelling of lips/tongue | • High fever<br>• Lymphadenopathy<br>• Arthralgia/arthritis<br>• Shortness of breath, wheezing, stridor, hypotension<br>• Other visceral involvement | • Marked eosinophilia<br>• Lymphocytosis with atypical lymphocytes<br>• Leukopenia<br>• Abnormal liver or renal function tests<br>• Thrombocytopenia |

**Table 17.5 Features that suggest a severe cutaneous adverse reaction (SCAR) to a drug.**




**Fig. 17.9 Acute generalized exanthematous pustulosis (AGEP). A** Numerous sterile pustules with superficial epidermal detachment in areas where the pustules have become confluent in a patient receiving amoxicillin. **B** Diffuse erythema of the buttock with multiple small sterile pustules due to a cephalosporin, and face (**C**) due to metronidazole. **D** Positive patch test result 4 days following the application of 0.75% metronidazole in a patient with a previous pustular drug eruption to that medication. *A, Courtesy, Laurence Valeyrie-Allanore, MD; B, Courtesy, YDRSC; C, D, Courtesy, Kalman Watsky, MD.*

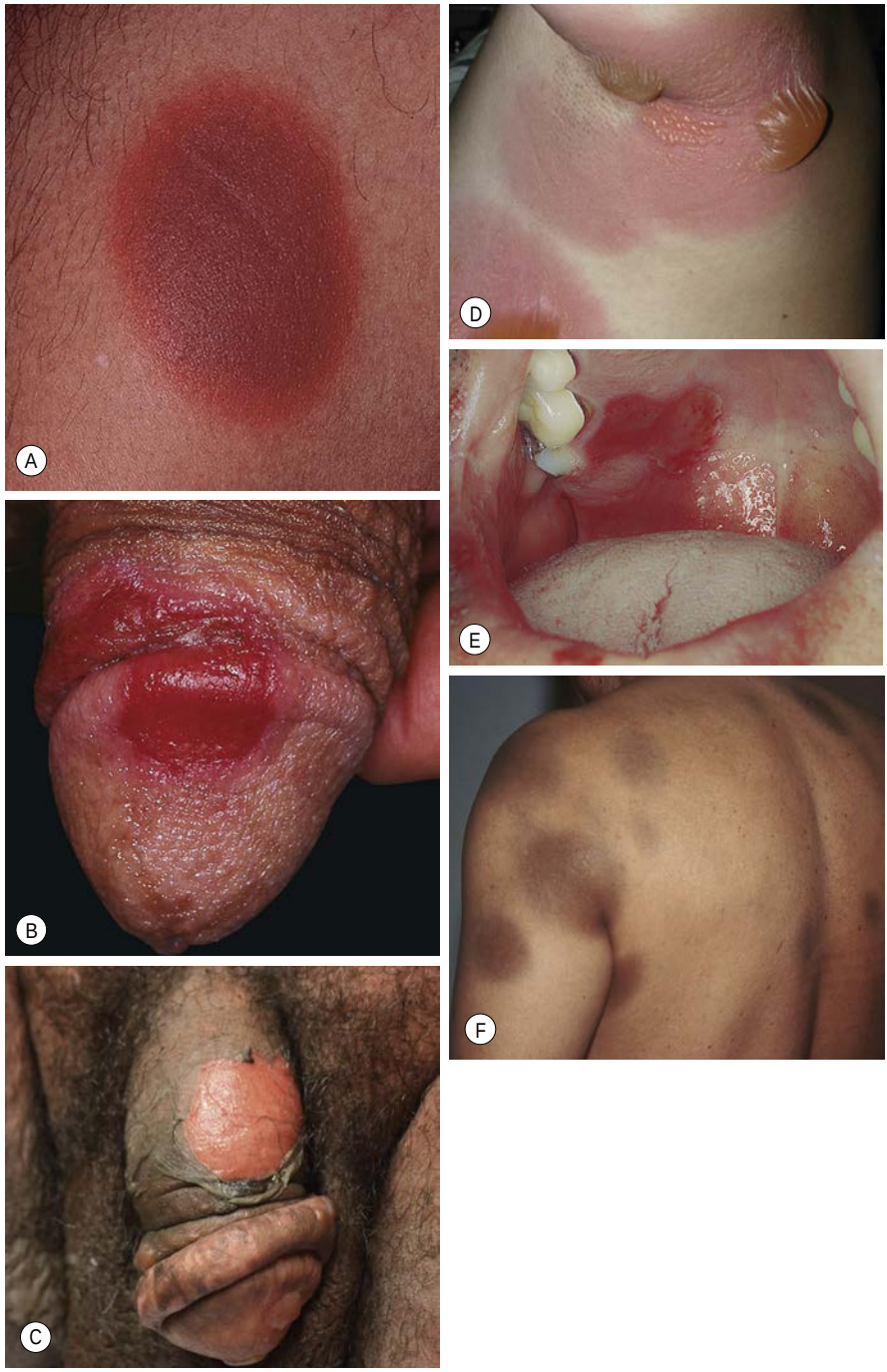


**Fig. 17.10 Fixed drug eruptions (FDE).** **A** An oval, well-demarcated red-brown plaque with a more erythematous border. **B** Erosive lesion of the penis due to epidermal detachment; this clinical presentation is sometimes misdiagnosed as recurrent HSV infection. **C, D** Generalized bullous FDE with involvement of the genitalia and intertriginous zones; erosions are seen following rupture of the bullae. Because of its more widespread distribution, this variant can be confused with SJS/TEN. **E** In the mouth, mucosal detachment leads to erosions. **F** Once inflammation is completely resolved, circular or oval areas of hyperpigmentation are commonly seen. Responsible drugs were phenolphthalein (**A**), ciprofloxacin (**B**), naproxen (**C**), pseudoephedrine (**D**), allopurinol (**E**), trimethoprim-sulfamethoxazole (**F**). *A, Courtesy, YDRSC; B, E, Courtesy, Kalman Watsky, MD; C, Courtesy, Sara Perkins, MD; D, Courtesy, Edward W Cowen, MD; F, Courtesy, Mary Stone, MD.*

| DRUG RESPONSIBILITY ASSESSMENT | |
|---|---|
| Clinical characteristics | • Type of primary lesion (e.g. urticaria, erythematous papule, pustule, purpuric papule, vesicle or bulla)<br>• Distribution and number of lesions<br>• Mucous membrane involvement, facial edema<br>• Associated signs and symptoms: fever, pruritus, lymph node enlargement, visceral involvement |
| Chronological factors | • Document all drugs to which the patient has been exposed (including OTC and complementary) and the dates of administration<br>• Date of eruption<br>• Time interval between drug introduction (or reintroduction) and skin eruption<br>• Response to removal of the suspected agent<br>• Consider excipients (e.g. soybean oil)<br>• Response to rechallenge* |
| Literature search | • Bibliographic research (e.g. PubMed, Micromedex, Litt's Drug Eruption and Reaction Database)<br>• Drug Alert Registry or MedWatch<br>• Data collected by pharmaceutical companies<br>• In the case of more recently released medications, extrapolation based on the class of drug and in particular the first drug released in the class |

*Often inadvertent.*

**Table 17.6 Logical approach to determine the cause of a drug eruption.**

| ADDITIONAL REVIEWS OF SPECIFIC TYPES OF DRUG REACTIONS | |
|---|---|
| Psoriasiform (Fig. 17.11) | Ch. 6 |
| Erythroderma | Ch. 8, Table 8.1 |
| Lichenoid (Fig. 17.12) | Ch. 9 |
| Urticaria | Ch. 14 |
| Stevens–Johnson syndrome and toxic epidermal necrolysis | Ch. 16 |
| Warfarin- and heparin-induced necrosis | Ch. 18 |
| Vasculitis | Ch. 19 |
| Sweet syndrome | Ch. 21 |
| Pemphigus and bullous pemphigoid | Chs 23 and 24 |
| Linear IgA bullous dermatosis (LABD) | Ch. 25, Table 25.1 |
| Acneiform/folliculitis | Chs 29 and 31 |
| Hyper- and hypohidrosis | Ch. 32 |
| Lupus erythematosus (systemic and cutaneous) | Ch. 33, Tables 33.4 and 33.5 |
| Granulomatous (interstitial) | Ch. 37 |
| Pseudoporphyria | Ch. 41, Table 41.2 |
| Hypopigmentation (skin and hair) | Ch. 54 |
| Hyperpigmentation and dyschromatosis | Ch. 55 |
| Hypertrichosis and hirsutism | Ch. 57 |
| Nail abnormalities | Ch. 58, Table 58.4 |
| Gingival enlargement | Ch. 59, Table 59.3 |
| Phototoxic and photoallergic | Ch. 73, Table 73.4 |
| Cutaneous lymphoid hyperplasia (pseudolymphoma) | Ch. 99 |

**Table 17.7 Additional reviews of specific types of drug reactions.**

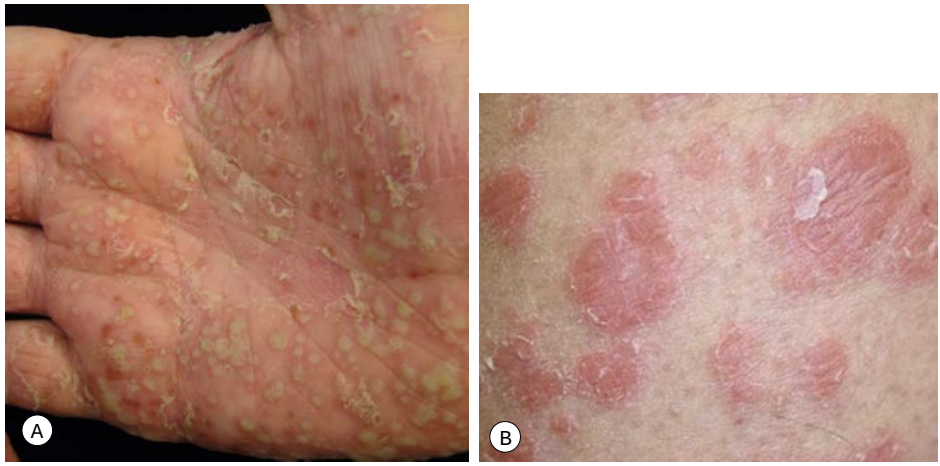


**Fig. 17.11 Psoriasiform eruptions due to TNF inhibitors. A** Palmoplantar pustulosis that developed as a complication of infliximab. **B** Eruption of plaque-type psoriasis in a patient receiving infliximab for GVHD of the gastrointestinal tract. *A, Courtesy, J. Mark Jackson, MD and Jeffrey P. Callen, MD; B, Courtesy, Dennis Cooper, MD.*

**THE MORE COMMON MUCOCUTANEOUS SIDE EFFECTS OF TARGETED THERAPIES**

| Mucocutaneous side effect | General management recommendations |
|---|---|
| Xerosis | • *EGFR inhibitor-induced papulopustular reaction prophylaxis (P) and treatment (T):*<br>– Gentle cleansers, moisturization, sun avoidance/ protection (P)<br>– Topical antibiotics (e.g. clindamycin, erythromycin) twice daily (P, T)<br>– Oral antibiotics (e.g. doxycycline [100 mg twice daily] or minocycline [50–100 mg twice daily]) (P, typically for 6–8 weeks; T)<br>– Topical low to mid-potency CS twice daily (T)<br>– Oral CS (e.g. prednisone 0.5 mg/kg/day × 7 days) if more severe or unresponsive to above measures (T)<br>• *Management of hand-foot eruptions:*<br>– Limit exposure to heat, hot water, tight clothing/ shoes, chemical irritants<br>– Topical high-potency CS ointments to inflamed areas twice daily<br>– Topical keratolytic agents or humectants (e.g. 10–20% urea cream, ammonium lactate) to hyperkeratotic areas twice daily<br>• *Management of stomatitis:*<br>– See Table 59.2<br>– Morbilliform eruptions, such as those from selected BRAF inhibitors, may require a drug holiday or reduced dose |
| Pruritus | |
| Papulopustular eruption (Fig. 17.12) | |
| Morbilliform eruption | |
| Photosensitivity | |
| Palmoplantar hyperkeratosis | |
| Acral erythema (may be bullous) | |
| Paronychia | |
| Stomatitis | |
| Alopecia | |
| Curly, brittle hair | |
| Eyelash trichomegaly &/or facial hair growth | |
| Skin growths: squamous papillomas, KAs, SCCs* | |

**Most often seen when BRAF inhibitors are given alone; incidence can be significantly reduced when BRAF inhibitors are combined with MEK inhibitors.*

**Table 17.8 The more common mucocutaneous side effects of targeted therapies.** Targeted therapies include: (1) various inhibitors of VEGFR (e.g. sorafenib, sunitinib, vandetanib, pazopanib, bevacizumab, ranibizumab) and EGFR (e.g. erlotinib, gefitinib, cetuximab, panitumumab, canertinib, lapatinib); (2) multi-kinase inhibitors that target the KIT receptor (e.g. imatinib, dasatinib, nilotinib) and MAP kinase pathway (vemurafenib, dabrafenib, cobimetinib); and (3) mTOR (e.g. sirolimus, everolimus, temsirolimus) and proteasome inhibitors (e.g. bortezomib, carfilzomib).




**Fig. 17.12 Papulopustular (acneiform) reactions to epidermal growth factor receptor (EGFR) inhibitors. A** Numerous pustules on an erythematous base with coalescence on the central upper back. **B** Multiple follicular papulopustules, hyperpigmented scars, and a large multiloculated inflamed cyst on the cheek. *A, Courtesy, Lauren Levy, MD and Jonathan Leventhal, MD; B, Courtesy, Kalman Watsky, MD.*

**THE MORE COMMON MUCOCUTANEOUS SIDE EFFECTS OF IMMUNE CHECKPOINT INHIBITORS***

| Mucocutaneous side effect | General management recommendations |
|---|---|
| Xerosis | • General measures: gentle cleansers and daily moisturization; sun avoidance/protection<br>• For pruritus, try long-acting, non-sedating antihistamines in the daytime (e.g. cetirizine) and more sedating antihistamines at bedtime (e.g. hydroxyzine, doxepin)<br>• Morbilliform, eczematous, lichenoid and psoriasiform eruptions (grade 1 or grade 2***) can be treated with mid- to high-potency topical CS creams and ointments, respectively<br>• More severe (grade 3 or 4***) or recalcitrant to topical treatment eruptions may require oral CS<br>• Suspicion of SCAR requires biopsy, discontinuation of checkpoint inhibitor and possible hospitalization |
| Pruritus | |
| Morbilliform eruption** | |
| Dermatitis, eczematous or psoriasiform** | |
| Lichenoid eruption** | |
| Bullous pemphigoid, lichen planus pemphigoides | |
| Photosensitivity | |
| Vitiligo-like leukoderma, poliosis | |
| Alopecia areata, alopecia universalis | |
| Dermatomyositis, SCLE | |
| SCARs (e.g. SJS–TEN, DRESS, vasculitis, AGEP) | |
| Psoriasis flare | |
| Eruptive KAs | |
| Uveitis, episcleritis | |
| Sarcoid-like reaction | |

**In addition to these mucocutaneous side effects, autoimmune-like inflammation of internal organs may often occur (e.g. enteritis/colitis, hepatitis, thyroiditis, myocarditis, pneumonitis, etc).*
***May be accentuated in sun-exposed sites; for lichenoid, may be intraoral.*
****Refer to https://www.asco.org/management-immune-related-adverse-events-patients-treated-immune-checkpoint-inhibitor-therapy.*

**Table 17.9 The more common mucocutaneous side effects of immune checkpoint inhibitors.** Dermatologic toxicity is the most common immune-related adverse event with checkpoint inhibitors, including anti-CTLA-4 (e.g. ipilimumab, tremelimumab), anti-PD-1 (e.g. nivolumab, pembrolizumab), and anti-PD-L-1 (e.g. atezolizumab, avelumab, durvalumab) antibodies. SCARs, severe cutaneous adverse reactions to medications; SCLE, subacute cutaneous lupus erythematosus.

| MUCOCUTANEOUS SIDE EFFECTS OF CHEMOTHERAPEUTIC AGENTS | |
|---|---|
| **Reactions** | **Responsible drugs** |
| Alopecia, reversible | Alkylating agents: cyclophosphamide, ifosfamide, mechlorethamine (nitrogen mustard)<br>Anthracyclines: daunorubicin, doxorubicin, idarubicin, mitoxantrone<br>Taxanes: paclitaxel, docetaxel<br>Topoisomerase 1 inhibitors: topotecan, irinotecan<br>Etoposide, vincristine, vinblastine, actinomycin D, busulfan, MTX, gemcitabine |
| Alopecia, irreversible | Busulfan, thiotepa, cyclophosphamide (conditioning regimens); docetaxel, paclitaxel |
| Mucositis | Daunorubicin, doxorubicin, high-dose MTX, high-dose melphalan, topotecan, cyclophosphamide, taxanes, hydroxyurea, continuous infusions of 5-FU and prodrugs of 5-FU |
| Extravasation reactions (e.g. chemical cellulitis, ulceration) | Anthracyclines, carmustine, 5-FU, vinblastine, vincristine, mitomycin C |
| Chemotherapy recall (tender sterile inflammatory nodules at sites of previous chemotherapy extravasation or administration) | 5-FU, mitomycin C, paclitaxel, doxorubicin, epirubicin |
| Hyperpigmentation (see Ch. 55) (Fig. 17.13E) | Alkylating agents: busulfan, cyclophosphamide, cisplatin, mechlorethamine, melphalan, bendamustine<br>Antimetabolites: 5-FU, 5-FU prodrugs (e.g. capecitabine, tegafur), MTX, hydroxyurea<br>Antibiotics: bleomycin, doxorubicin |
| Mucosal hyperpigmentation | Busulfan, 5-FU, hydroxyurea, cyclophosphamide |
| Nail hyperpigmentation (Fig. 17.13A) | 5-FU, cyclophosphamide, daunorubicin, doxorubicin, hydroxyurea, MTX, bleomycin |
| Onycholysis | Paclitaxel, docetaxel (along with photosensitivity) |
| Radiation recall | MTX, doxorubicin, daunorubicin, taxanes, etoposide, dacarbazine, melphalan, capecitabine, gemcitabine, 5-FU, pemetrexed, actinomycin D, hydroxyurea |
| Radiation enhancement | Doxorubicin, hydroxyurea, taxanes, 5-FU, etoposide, gemcitabine, MTX |
| Photosensitivity | 5-FU and 5-FU prodrugs, MTX, hydroxyurea, dacarbazine, mitomycin C, docetaxel |
| Inflammation of "keratoses" (Fig. 17.13B) | Actinic keratoses: 5-FU and 5-FU prodrugs, pentostatin, interleukin-2<br>Seborrheic keratoses: cytarabine, taxanes<br>Disseminated superficial actinic porokeratosis: 5-FU and 5-FU prodrugs, taxanes |
| Toxic erythema of chemotherapy (Figs 17.14 and 17.15)<br>• Acral erythema (erythrodysesthesia) | Cytarabine, anthracyclines, 5-FU and 5-FU prodrugs, taxanes, MTX, busulfan, cysplatin |
| • Eccrine squamous syringometaplasia | Cytarabine, busulfan, cyclophosphamide, carmustine, taxanes |
| Neutrophilic eccrine hidradenitis (Fig. 17.13C) | Cytarabine, bleomycin, anthracyclines, cyclophosphamide, cisplatin, topotecan |
| Ulcerations | Hydroxyurea (lower extremities) |
| Squamous cell carcinoma | Fludarabine, hydroxyurea, topical BCNU |

**Table 17.10 Mucocutaneous side effects of chemotherapeutic agents.** 5-FU, 5-fluorouracil; BCNU, carmustine; MTX, methotrexate.




**Fig. 17.13 Mucocutaneous side effects of chemotherapeutic agents.** **A** Horizontal melanonychia due to 5-fluorouracil. **B** Inflammation surrounding a seborrheic keratosis in a patient receiving paclitaxel. **C** Neutrophilic eccrine hidradenitis; erythematous plaques on the leg, which may be confused with Sweet syndrome. **D** Raynaud phenomenon and digital necrosis due to systemic bleomycin. **E** Multiple linear (flagellate) erythematous, urticarial plaques in a patient receiving systemic bleomycin. *A, B, Courtesy, Jean L. Bolognia, MD; C, Courtesy, Jean Revuz, MD; D, Courtesy, YDRSC; E, Courtesy, Kalman Watsky, MD.*

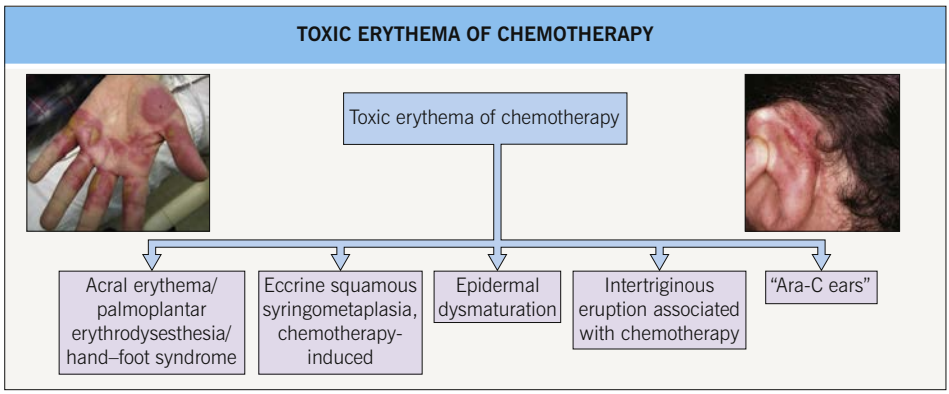


**Fig. 17.14 Toxic erythema of chemotherapy (TEC).** Use of a number of terms (especially those based on histopathologic findings), including palmoplantar erythrodysesthesia, eccrine squamous syringometaplasia, and epidermal dysmaturation, has created some confusion for clinicians. There is considerable overlap in the appearance of the symmetric erythematous to dusky patches, which can develop edema, erosions, desquamation, or purpura, whether they favor acral sites, intertriginous zones, or the elbows and knees. "Toxic erythema of chemotherapy" has been suggested as an encompassing term that allows simplification. In addition, there is no need to implicate additional diagnoses when lesions are not limited to the hands and feet. Insets: Erythema of the ears due to cytarabine (cytosine arabinoside), sometimes referred to as "Ara-C ears"; the petechiae are due to thrombocytopenia. Dusky edematous plaques of the palm, some of which have developed sterile bullae. *Courtesy, Jean L. Bolognia, MD and Boni Elewski, MD.*




**Fig. 17.15 Toxic erythema of chemotherapy. A** Symmetric involvement of intertriginous zones and the scrotum. There is central desquamation and some of the lesions have a dusky color. The patient was receiving fludarabine plus intravenous busulfan. **B** Toxic erythema of chemotherapy due to cytarabine, with obvious erythema of the plantar surface. *A, Courtesy, Leonard Kristal, MD; B, Courtesy, Jean L. Bolognia, MD.*

| REACTIONS LOCALIZED TO SITES OF INJECTIONS OF MEDICATIONS | |
|---|---|
| Etanercept | Erythematous plaques, vasculitis, eosinophilic cellulitis |
| Adalimumab | Erythematous or urticarial plaques |
| GM-CSF, G-CSF | Pustular reaction, urticarial plaque |
| Interferon | Vasculopathy with necrosis, development of plaque of psoriasis, lupus-like reaction |
| Interleukin-2 | Lobular panniculitis, granulomas |
| Anakinra | Erythematous or urticarial plaques |
| Corticosteroids | Dermal atrophy, lipoatrophy, telangiectasias, deposits, hypopigmentation |
| Vitamin K | Erythematous plaque, often annular; morpheaform plaque (Texier disease) |
| Heparin | Necrosis, ecchymosis, erythematous plaques, urticaria |
| Low-molecular-weight, calcium-containing heparin | Calcinosis cutis |
| Glatiramer acetate | Fibrosis, panniculitis, lipoatrophy, vasospasm, Nicolau syndrome |
| Iron | Brown discoloration, hyperpigmentation |
| Vitamin $B_{12}$ | Pruritus, morpheaform plaque |
| Enfuvirtide | Erythematous or morpheaform plaque |
| Bortezomib | Erythematous or urticarial plaque, necrosis |
| Insulin | Erythema, pruritus, urticaria, induration, lipoatrophy, lipohypertrophy |
| Desensitization antigens | Subcutaneous sarcoidosis |
| Hyaluronic acid, silicone | Swelling, granulomatous reaction |
| | Dermal atrophy, lipoatrophy, telangiectasias, deposits, hypopigmentation |
| **Vaccines*** | |
| Aluminum-containing vaccine | Nodules, foreign body reaction |
| Thimerosal-containing vaccine | Allergic contact dermatitis |
| Lipid nanoparticle-encapsulated COVID-19 mRNA-1273 vaccine | Delayed, pruritic erythematous plaque, usually large in diameter, that may or may not recur with second dose |

**Localized reactions can also occur, (e.g. pseudocellulitis/excessive limb swelling) as well as generalized reactions, (e.g. anaphylaxis, Sweet syndrome, AGEP, bullous pemphigoid, linear IgA bullous dermatosis, lichenoid eruptions, and erythema multiforme).*

**Table 17.11 Reactions localized to sites of injections of medications (in addition to extravasation of those administered intravenously).** G-CSF, granulocyte colony-stimulating factor; GM-CSF, granulocyte–macrophage colony-stimulating factor.

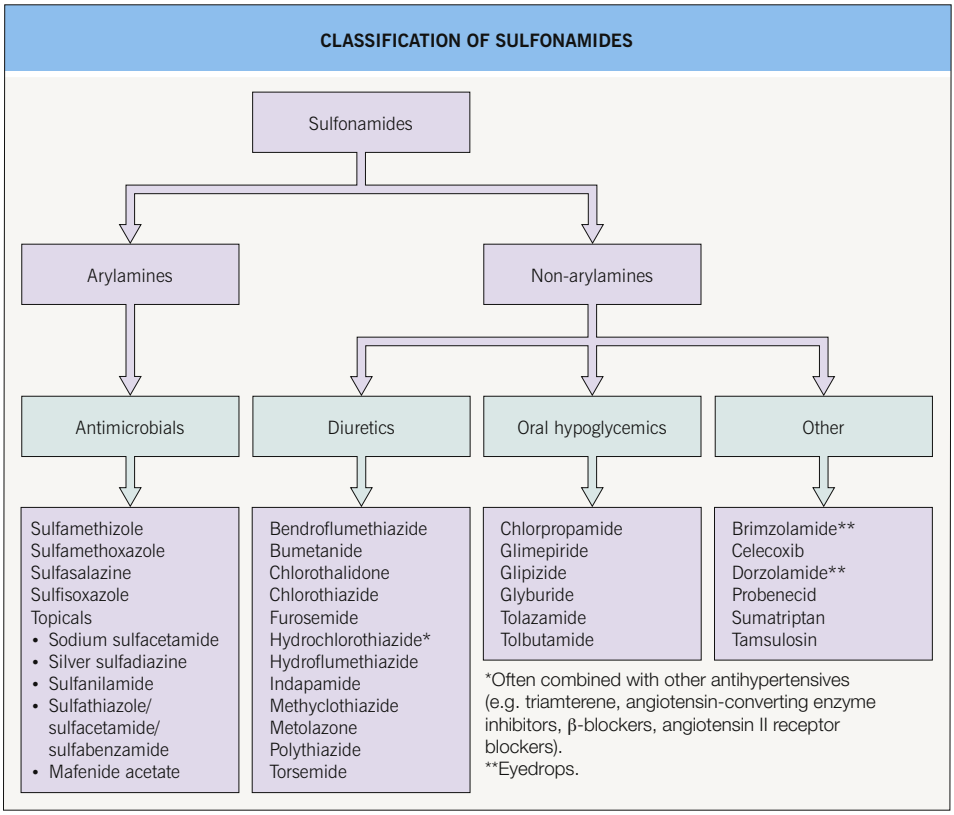


**eFig. 17.1 Classification of sulfonamides.** Approximately 10% of the patients with a history of a drug reaction to antimicrobial sulfonamides will also react to the non-arylamine sulfonamides. However, this is thought to be a reflection of a predisposition to allergic reactions rather than cross-reactivity.



**eFig. 17.2 Stevens–Johnson syndrome.** Flaccid bullae leading to epidermal detachment (<10% body surface area). *Courtesy, YDRSC.*



**eFig. 17.3 Drug reaction with eosinophilia and systemic symptoms (DRESS) due to carbamazepine.** Exanthematous eruption with confluence on the thighs. *Courtesy, Alicia Little, MD.*



**eFig. 17.4 Serum sickness due to antithymocyte globulin.** The purpuric lesions are due to small vessel vasculitis in this patient with aplastic anemia. *Courtesy, Jean L. Bolognia, MD.*



**eFig. 17.5 Warfarin (Coumadin®) necrosis.** Striking areas of purpura and ischemia on the scrotum. *Courtesy, Kenneth Greer, MD.*

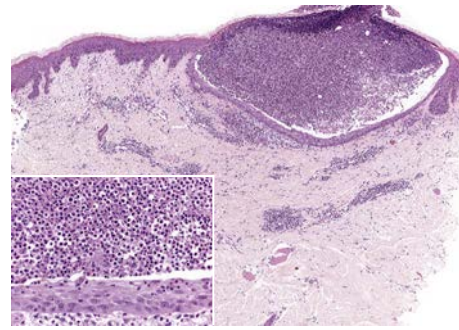

**eFig. 17.6 Histopathology of acute generalized exanthematous pustulosis (AGEP).** Subcorneal pustule composed of neutrophils as well as scattered neutrophils within the epidermis (inset). *Courtesy, Lorenzo Cerroni, MD.*




**eFig. 17.7 Exanthematous drug eruptions. A** Numerous pink papules on the trunk due to a cephalosporin. **B** Confluence of the lesions on the trunk secondary to phenobarbital. *A, B, Courtesy, YDRSC.*




**eFig. 17.8 Fixed drug eruptions.** **A** Coalescing red-brown plaques with a central dusky violaceous hue. **B** As lesions start to resolve, a brown hue can begin to appear within the areas of inflammation. **C** Bullous fixed drug eruption. *A, Courtesy, YDRSC; B, Courtesy, Laurence Valeyrie-Allanore, MD; C, Courtesy, Jean Revuz, MD.*



**eFig. 17.9 Cutaneous discoloration due to amiodarone.** Gray-violet discoloration of the face. Note sparing of the lower eyelid. *Courtesy, Jean L. Bolognia, MD.*



**eFig. 17.10 Iododerma.** Edematous erythematous vesiculopustules on the buttocks with central crusts. *Courtesy, YDRSC.*




**eFig. 17.11 Methotrexate toxicity.** Increased serum levels of methotrexate secondary to decreased renal excretion can lead to epidermal necrosis. **A** Large erosions and areas of epidermal necrosis with a shellac-like appearance in a patient with rheumatoid arthritis. **B** Epidermal necrosis limited to psoriatic plaques. *A, Courtesy, Kalman Watsky, MD; B, Courtesy, YDRSC.*




**eFig. 17.12 Cutaneous side effects of chemotherapeutic agents. A** Ulceration due to extravasation of doxorubicin. **B** Hydroxyurea-induced lower extremity ulcerations. *A, Courtesy, YDRSC; B, Courtesy, Brian Horvath, MD.*



A L G r a w a n y




**eFig. 17.13 Toxic erythema of chemotherapy. A** Acral erythema due to sorafenib. **B** Axillary erythema and desquamation in a patient receiving busulfan plus fludarabine. *A, Courtesy, Peter W. Heald, MD; B, Courtesy, Jean L. Bolognia, MD.*



**eFig. 17.14 Exanthematous (morbilliform) drug reaction to lenalidomide with accentuation at sites of bortezomib injections.** *Courtesy, Dennis Cooper, MD.*



**eFig. 17.15 Papulopustular (acneiform) reaction to an EGFR inhibitor.** Pustules and numerous crusted papules on the face. *Courtesy, Diane Thiboutot, MD.*




**eFig. 17.16 Cutaneous reactions to immunotherapies. A** SJS/TEN overlap due to ipilimumab. **B** Inflammation of actinic keratoses in a patient receiving intravenous interleukin-2. *A, Courtesy, Marianna Freudzon, MD; B, Courtesy, Jean L. Bolognia, MD.*



**eFig. 17.17 Psoriasiform eruption due to TNF inhibitor.** Sterile pustulosis of the plantar surface developed in this patient with rheumatoid arthritis who had received infliximab for the previous 5 years. There was no reduction in immunosuppression prior to the onset of the psoriasiform eruption. *Courtesy, Chris Bunick, MD.*



**eFig. 17.19 Erythematous edematous plaque at the site of GM-CSF injection.** *Courtesy, YDRSC.*



**eFig. 17.18 Postinflammatory hyperpigmentation and ulceration at sites of interferon-β-1b injection in a woman with multiple sclerosis.** *Courtesy, Jean L. Bolognia, MD.*



**eFig. 17.20 Etanercept injection site reaction.** Similar reactions occur with nearly all subcutaneously injected biologic therapies. *Courtesy, J. Mark Jackson, MD and Jeffrey P. Callen, MD.*



**eFig. 17.21 Photolichenoid drug eruption due to hydrochlorothiazide.** The lesions favored the extensor surfaces of the forearms. *Courtesy, YDRSC.*

| REGISCAR SCORING SYSTEM FOR DRESS | | | |
|---|---|---|---|
| **Criteria** | **No** | **Yes** | **Unknown/ unclassifiable** |
| Fever (≥38.5°C) | –1 | 0 | –1 |
| Lymphadenopathy (≥2 sites; >1 cm) | 0 | 1 | 0 |
| Circulating atypical lymphocytes | 0 | 1 | 0 |
| Peripheral hypereosinophilia | 0 | | 0 |
| • 0.7–1.499 × $10^9$/L - *or* - 10–19.9%* | | 1 | |
| • ≥1.5 × $10^9$/L - *or* - ≥20%* | | 2 | |
| Skin involvement | | | |
| • Extent of cutaneous eruption > 50% BSA | 0 | 1 | 0 |
| • Cutaneous eruption suggestive of DRESS** | –1 | 1 | 0 |
| • Biopsy suggests DRESS | –1 | 0 | 0 |
| Internal organs involved† | 0 | | 0 |
| • One | | 1 | |
| • Two or more | | 2 | |
| Resolution in ≥15 days | –1 | 0 | –1 |
| Laboratory results negative for at least three of the following (and none positive): (1) ANA; (2) blood cultures; (3) HAV/HBV/HCV serology; and (4) *Chlamydia* and *Mycoplasma* serology | 0 | 1 | 0 |
| Final score: <2, no case; 2–3, possible case; 4–5, probable case; >5, definite case | | | |

**If leukocytes <4.0 × $10^9$/L.*
***At least two of the following: edema, infiltration, purpura, scaling.*
*†Liver, kidney, lung, muscle/heart, pancreas, or other organ and after exclusion of other explanations.*

**eTable 17.1 European Registry of Severe Cutaneous Adverse (Drug) Reactions (RegiSCAR) scoring system for DRESS (drug reaction with eosinophilia and systemic symptoms).**
This scoring system has been validated. HAV, hepatitis A virus; HBV, hepatitis B virus; HCV, hepatitis C virus.

| ASSESSMENT AND LONGITUDINAL EVALUATION OF PATIENTS WITH DRESS |
|---|
| **Basic laboratory screening during the acute phase with recommended repetitive tests *in italics*^** |
| • *CBC with differential, platelet count,* peripheral smear for atypical lymphocytes<br>• *BUN, creatinine, urinalysis,* spot urine for protein:creatinine ratio*<br>• *LFTs, creatine kinase (CK),* lipase, CRP<br>• *TSH, free T4* (repeat at 3 months, 1 year, and 2 years)<br>• Fasting glucose (in anticipation of systemic corticosteroids) |
| **Additional testing** |
| • ECG, troponin T, baseline echocardiogram<br>• Quantitative PCR for HHV-6, HHV-7, EBV, CMV<br>• Wright stain of urine for eosinophilia (prior to instituting corticosteroids)<br>• ANA, blood cultures (exclusion criteria in RegiSCAR scoring system)<br>• If hemophagocytic lymphohistiocytosis suspected**, ferritin, triglycerides, LDH, BM examination |
| **Further testing based upon laboratory abnormalities or signs and symptoms**** |
| • Liver – PT, PTT, albumin<br>• Renal – albumin, renal ultrasound (if laboratory abnormalities)<br>• Cardiac – ECG, troponin T, echocardiogram<br>• Neurologic – brain MRI<br>• Pulmonary – CXR, PFTs<br>• Gastrointestinal – endoscopy |
| *^Testing is more frequent during the acute phase (e.g. twice weekly) with frequency also a reflection of disease severity. Longitudinal evaluation is recommended for at least one year.*<br>**Allows for immediate assessment for proteinuria.*<br>***Including during longitudinal evaluation.* |

**eTable 17.2 Assessment and longitudinal evaluation of patients with DRESS (drug reaction with eosinophilia and systemic symptoms).** BM, bone marrow; CK, creatine kinase; PFT, pulmonary function test; PT, prothrombin time; PTT, partial thromboplastin time.

| DRUGS ASSOCIATED WITH DRESS | |
|---|---|
| **Drug category** | **Specific drugs** |
| Anticonvulsants | **Carbamazepine, lamotrigine*, phenobarbital, phenytoin**, oxcarbazepine, zonisamide > valproic acid |
| Antimicrobials | Ampicillin, cefotaxime, **dapsone**, ethambutol, isoniazid, linezolid, metronidazole, **minocycline**, pyrazinamide, quinine, rifampin, sulfasalazine (salazosulfapyridine), streptomycin, **trimethoprim–sulfamethoxazole**, teicoplanin, **vancomycin** |
| Antiretrovirals | **Abacavir**, **nevirapine**, zalcitabine |
| Antidepressants | Bupropion, fluoxetine |
| Antihypertensives | Amlodipine, captopril |
| NSAIDs | Celecoxib, ibuprofen |
| Miscellaneous | **Allopurinol****, azathioprine**,** imatinib, mexiletine, ranitidine, ziprasidone |
| *Especially when coadministered with valproic acid.<br>**Full doses in the setting of renal dysfunction a risk factor.* | |

**eTable 17.3 Drugs associated with DRESS (drug reaction with eosinophilia and systemic symptoms).** Most commonly associated drugs are in bold.

| AGEP – MOST COMMONLY ASSOCIATED MEDICATIONS | |
|---|---|
| • Acetaminophen<br>• Antibiotics<br>– *Penicillins, aminopenicillins*<br>– *Cephalosporins*<br>– *Clindamycin*<br>– *Pristinamycin*<br>– Sulfonamides<br>– Metronidazole<br>– Carbapenems<br>– Quinolones<br>– Macrolides | • Calcium channel blockers, especially *diltiazem*<br>• Carbamazepine<br>• Cetirizine<br>• Herbal medicines<br>• Antimalarials, especially hydroxychloroquine<br>• NSAIDs, including oxicam derivatives and COX-2 inhibitors<br>• Proton pump inhibitors<br>• Terbinafine |

**eTable 17.4 Acute generalized exanthematous pustulosis (AGEP) – most commonly associated medications.** Common culprits are in *italics*.

| DRUG-INDUCED ALOPECIA | |
|---|---|
| Telogen phase | • Amphetamines<br>• **Anticoagulants:** heparin > warfarin<br>• Anticonvulsants: carbamazepine, valproic acid, phenytoin, lamotrigine<br>• Antidepressants: imipramine, desipramine, maprotiline, fluoxetine<br>• Antihypertensive agents:<br>– **β-blockers:** timolol, acebutolol, propanolol<br>– ACE inhibitors: captopril, enalapril, ramipril<br>– Diuretics: spironolactone<br>• Antimicrobials: terbinafine, gentamicin, thiamphenicol, fluconazole, isoniazid<br>• Antithyroid drugs: carbimazole, thiouracils<br>• Colchicine<br>• **Interferons**<br>• Lipid-lowering agents: clofibrate, cholestyramine<br>• **Lithium**<br>• NSAIDs: piroxicam, naproxen, indomethacin, ibuprofen<br>• Oral contraceptives (discontinuation)<br>• **Retinoids**<br>• Others: allopurinol, cimetidine, L-dopa, pyridostigmine, bromocriptine, buspirone |
| Anagen phase | • Antineoplastic agents (see Table 17.9 and 17.10)<br>• Others: arsenic, bismuth, gold, thallium |

**eTable 17.5 Drug-induced alopecia.** The more commonly incriminated medications are in bold. ACE, angiotensin-converting enzyme.

| ADVERSE REACTIONS TO RADIOCONTRAST MEDIA |
|---|
| **Iodinated** |
| **Immediate (<1 hour)**<br>Urticaria (usually non-immunologic), angioedema<br>Anaphylactoid reaction<br>**Delayed (1 hour to 1 week)**<br>Morbilliform eruption<br>Acute generalized exanthematous pustulosis (AGEP)<br>Symmetrical drug-related intertriginous and flexural exanthema (SDRIFE)<br>Iododerma (also >1 week) |
| **Gadolinium** |
| Urticaria, erythema (rare)<br>Anaphylactoid reactions, anaphylaxis (rare)<br>Nephrogenic systemic fibrosis (in the setting of renal insufficiency; see Ch. 35) |

**eTable 17.6 Adverse reactions to radiocontrast media.**

| MUCOCUTANEOUS AND EXTRACUTANEOUS SIDE EFFECTS OF IMMUNE CHECKPOINT INHIBITORS |
|---|
| **Mucocutaneous** |
| • Morbilliform eruption* |
| • Eczematous eruption* |
| • Pruritus |
| • Vitiligo-like leukoderma, poliosis |
| • Vogt–Koyanagi–Harada-like syndrome |
| • Alopecia areata, alopecia universalis |
| • Lichenoid eruption* |
| • Lichen planus pemphigoid |
| • Bullous pemphigoid |
| • Dermatomyositis |
| • Subacute cutaneous lupus erythematosus |
| • Vasculitis |
| • Repigmentation of gray hair |
| • Sarcoidosis and sarcoidosis-like lesions, including subcutaneous |
| • Panniculitis |
| • DRESS, including with radiation |
| • Radiation sensitivity |
| • Neutrophilic dermatoses, in particular Sweet syndrome |
| • Acute generalized exanthematous pustulosis |
| • Stevens–Johnson syndrome, toxic epidermal necrolysis |
| • Psoriasis flare |
| • Eruptive keratoacanthomas |
| • Oral ulcers |
| **Extracutaneous** |
| • Enteritis/colitis (diarrhea, nausea, vomiting) |
| • Hepatitis |
| • Autoimmune thyroiditis, hypothyroidism ≫ hyperthyroidism |
| • Hypophysitis, hypopituitarism |
| • Adrenal insufficiency |
| • Pneumonitis |
| • Sarcoidosis (pulmonary, lymph nodes) |
| • Type 1 diabetes, acute onset with severe hyperglycemia, ketoacidosis |
| • Pancreatitis |
| • Nephritis, hyperkalemia |
| • Neurotoxicity, including Guillain–Barré syndrome, PRES |
| • Myocarditis |
| • Uveitis, episcleritis |
| • Vasculitis |
| **May be intraoral or accentuated in sun-exposed sites* |

**eTable 17.7 Mucocutaneous and extracutaneous side effects of immune checkpoint inhibitors.** These include anti-CTLA-4 (e.g. ipilimumab, tremelimumab), anti-PD-1 (e.g. nivolumab, pembrolizumab), and anti-PD-L-1 (e.g. atezolizumab, avelumab, durvalumab) antibodies. PRES, posterior reversible encephalopathy syndrome.

# 18 Purpura and Disorders of Microvascular Occlusion

- Purpura represents visible hemorrhage into the skin or mucous membranes; in contrast to erythema due to vasodilation, it is nonblanching upon application of external pressure.
- Purpura can be *primary*, where hemorrhage is an integral part of lesion formation, or *secondary*, where there is hemorrhage into established lesions due to factors such as venous hypertension, gravity, or thrombocytopenia.
- As purpuric lesions fade, their color evolves from red-purple or blue to brown or yellow-green.
- Primary purpura has a broad differential diagnosis, and it is helpful to categorize purpuric lesions based on their size and morphology.
  - *Petechiae*: ≤3 mm and macular (Table 18.1; Fig. 18.1A)
  - *Ecchymoses*: usually >1 cm and macular with round/oval to slightly irregular borders, and typically have an element of trauma in their pathogenesis (see Table 18.1; Fig. 18.1B); a greater volume of hemorrhage leads to a *hematoma*, which is palpable
  - *Retiform purpura*: reticulated, branching or stellate morphology, which reflects occlusion of the vessels that produce the livedo reticularis pattern (see Ch. 87; Tables 18.2 and 18.3; Figs 18.1C and 18.2–18.9)
  - *Classic "palpable purpura"*: round red-purple papules that are occasionally targetoid, with a component of blanching erythema in early lesions; represents the most common presentation of cutaneous small vessel vasculitis (see Ch. 19; Fig. 18.1D)

| CAUSES OF PETECHIAE AND ECCHYMOSIS WITH MINOR TRAUMA |
|---|
| **Petechiae (≤3 mm in diameter)** |
| **Significant thrombocytopenia (e.g. <20,000/mm$^3$)**<br>• Etiologies include ITP, TTP, DIC, drugs, and bone marrow infiltration/failure<br>**Platelet dysfunction**<br>• Hereditary or acquired (e.g. due to aspirin or NSAIDs)<br>**Etiologies unrelated to platelets**<br>• Increased intravenous pressure, e.g. due to the Valsalva maneuver (coughing, childbirth) or use of a blood pressure cuff (Rumpel–Leede sign)<br>• Trauma (often linear configuration)<br>• Scurvy (perifollicular distribution)<br>• Inflammatory conditions, especially in dependent sites (e.g. pigmented purpuric dermatoses, hypergammaglobulinemic purpura of Waldenström) |
| **Ecchymosis with minor trauma (lesions usually >1 cm in diameter)** |
| **Defective coagulation**<br>• Etiologies include anticoagulant use, hepatic insufficiency, and vitamin K deficiency<br>**Poor dermal support of blood vessels**<br>• Etiologies include actinic purpura (Fig. 18.1B), corticosteroid use, scurvy, primary systemic amyloidosis, and Ehlers–Danlos syndrome<br>**Thrombocytopenia or platelet dysfunction** (see above) |

**Table 18.1 Causes of petechiae and ecchymosis with minor trauma.** DIC, disseminated intravascular coagulation; ITP, idiopathic thrombocytopenia purpura; TTP, thrombotic thrombocytopenic purpura. *Courtesy, Warren W. Piette, MD.*




**Fig. 18.1 Clinical examples of petechiae and purpura. A** Round to oval petechiae, ≤3 mm in diameter. **B** Actinic (solar) purpura in sites of chronic sun exposure plus trauma. **C** Non-inflammatory (bland) retiform purpura as well as hemorrhagic bullae in a patient with disseminated intravascular coagulation (DIC). **D** Palpable purpura due to cutaneous small vessel vasculitis (inflammation plus hemorrhage). *A, Courtesy, Warren Piette, MD; B, Courtesy, Kalman Watsky, MD; C, Courtesy, Judit Stenn, MD; D, Courtesy, YDRSC.*

- A biopsy specimen can be helpful in determining the etiology of a purpuric eruption, e.g. whether there is vascular occlusion with minimal inflammation or vasculitis (inflammation and fibrinoid necrosis of vessel walls). Because secondary changes of vasculitis may be seen when an older lesion of microvascular occlusion is sampled, and likewise a late lesion of vasculitis may have minimal residual inflammation, it is preferable to choose a well-developed but relatively early lesion (e.g. 24–48 hours old).

## Selected Microvascular Occlusion Syndromes (See Table 18.2)

### Antiphospholipid Syndrome (APS)

- Acquired systemic autoimmune disorder characterized by vascular thrombosis and/or pregnancy complications in the presence of elevated levels of antiphospholipid antibodies (Table 18.4).
- Predilection for young to middle-aged women (5:1 female:male ratio in adults) and often associated with systemic lupus erythematosus.

| CAUSES OF RETIFORM PURPURA | |
|---|---|
| **Disorder** | **Major features** |
| **Microvascular platelet plugs** | |
| Heparin-induced thrombocytopenia (HIT) | • ~1–5% of patients receiving heparin* (IV or SC) develop an Ab that binds to heparin–platelet factor 4 complexes and leads to ↓ platelets ± thrombosis, typically with onset on day 5–10 of therapy*<br>• Retiform purpura can be distant from or at sites of heparin injection (Fig. 18.2) |
| Thrombocytosis due to myeloproliferative disorders | • Occurs in essential thrombocythemia > polycythemia vera; may be associated with secondary erythromelalgia (see Ch. 87) |
| Paroxysmal nocturnal hemoglobinuria | • Acquired somatic *PIGA* mutation leads to complement-mediated injury of blood cells, resulting in hemolysis, thrombosis (especially venous), and cytopenias<br>• Other skin findings can include petechiae, hemorrhagic bullae, and leg ulcers<br>• **Rx:** eculizumab to inhibit terminal complement cascade (↑ meningococcemia risk) |
| Thrombotic thrombocytopenic purpura (TTP) ± hemolytic uremic syndrome (HUS) | • May be *primary* (Ab against or genetic defect in ADAMTS13 protease → reduced cleavage of vWF) or *secondary* (often with HUS, e.g. due to hemorrhagic colitis or drugs)<br>• Petechiae > retiform purpura; also fever, thrombocytopenia, microangiopathic hemolytic anemia, renal dysfunction, and CNS involvement |
| **Cold-related agglutination** | |
| Cryoglobulinemia type I > cryofibrinogenemia† | • Retiform purpura that favors acral sites (Fig. 18.3); see Table 18.3 |
| **Altered coagulation** | |
| Antiphospholipid syndrome | • See text and Table 18.4 (Figs 18.4 and 18.5) |
| Protein C or S deficiency/dysfunction | • *Warfarin necrosis* (protein C – short half-life, so function decreases faster than for procoagulant factors Fig. 18.6): 2–5 days after starting warfarin without heparin, especially if large loading dose; favors sites of abundant fat in women (see Fig. 17.5)<br>• *Sepsis-associated purpura fulminans* (protein C; see Fig. 18.1C)<br>• *Post-infectious purpura fulminans* (Ab blocks protein S): ~2 weeks after streptococcal infection or varicella<br>• *Neonatal purpura fulminans* (homozygous/compound heterozygous protein C > S defect; Fig. 18.7) |

**Table 18.2 Causes of retiform purpura.** *PIGA*, phosphatidylinositol glycan anchor class A; vWF, von Willebrand factor. *Continued*

| CAUSES OF RETIFORM PURPURA | |
|---|---|
| **Disorder** | **Major features** |
| **"Vascular coagulopathy"** | |
| Livedoid vasculopathy | • Often associated with thrombophilia (Table 18.5); see text (Fig. 18.8) |
| Degos disease (malignant atrophic papulosis) | • Vaso-occlusive disorder of skin, GI tract, and CNS; favors young adults<br>• Small erythematous papules on trunk and extremities evolve over 2–4 weeks to porcelain white scars with rim of telangiectasias; similar lesions can be seen in antiphospholipid syndrome |
| Sneddon syndrome – often in setting of antiphospholipid syndrome or adenosine deaminase 2 deficiency (± associated polyarteritis nodosa) | • Triad of widespread livedo reticularis/racemosa ("broken" livedo), labile hypertension, and cerebrovascular disease; favors young women |
| **Embolization and/or crystal deposition** | |
| Cholesterol emboli ("warfarin blue toe syndrome") | • Atherosclerosis (especially in older men) leads to emboli, often triggered by:<br>(1) Arterial/coronary catheterization or thrombolytic therapy (hours–days later)<br>(2) Prolonged anticoagulation (after 1–2 months of treatment)<br>• Retiform purpura of distal leg(s) + more extensive livedo reticularis (Fig. 18.9)<br>• Fever, myalgias, multisystem involvement (e.g. renal, GI, CNS); often peripheral eosinophilia |
| Other sources of emboli and/or crystal deposition | • Infective endocarditis (acute > subacute**), marantic endocarditis, atrial myxomas, hypereosinophilic syndrome (with intracardiac thrombus‡), systemic oxalosis (e.g. in primary hyperoxaluria), crystalglobulin vasculopathy (associated with monoclonal gammopathy) |
| **Reticulocyte/red blood cell occlusion (e.g. in sickle cell disease or severe malaria)** | |
| **Organisms within vessels (usually in immunocompromised patients)** | |
| Ecthyma gangrenosum | • See Ch. 61 |
| Vessel-invasive fungi | • e.g. *Aspergillus*, *Mucor* (see Ch. 64) |
| Disseminated strongyloidiasis | • "Thumbprint" purpura in periumbilical region |
| Lucio phenomenon | • Reactional state in lepromatous leprosy, primarily in Mexico and Central America (see Ch. 62) |
| **Other causes** | |
| Vasculitis (usually involving small and medium-sized vessels) | • e.g. ANCA-associated vasculitides, polyarteritis nodosa (see Ch. 19); early lesions often exhibit prominent erythema and induration |
| Calciphylaxis | • See Ch. 42 |
| Necrotic spider bite reaction | • See Ch. 72 |
| Intravascular lymphoma | • Most often B cell (Fig. 18.10); see Table 97.3 |

**Less common with low-molecular-weight heparin (≤1%) than unfractionated heparin; a transient decrease in the platelet count can also occur within the first 2 days of heparin therapy due to its direct effects on platelet activation.*
*†May be an incidental finding in hospitalized patients; cold agglutinins rarely lead to acrocyanosis or purpura.*
***Skin lesions on the hands and feet associated with subacute endocarditis are more likely to be tender red-purple papules due to immune complex deposition ("Osler nodes"),than purpuric macules representing septic emboli ("Janeway lesions"; more common in acute endocarditis).*
*‡Cutaneous microthrombi and superficial thrombophlebitis have also been described.*

**Table 18.2** *Continued* **Causes of retiform purpura.** *Courtesy, Warren W. Piette, MD.*

| CLASSIFICATION OF CRYOGLOBULINS | | | | |
|---|---|---|---|---|
| **Type** | **Composition** | **Associations** | **Pathophysiology** | **Clinical manifestations** |
| I | Monoclonal IgM or IgG >> IgA | Plasma cell dyscrasias, lymphoproliferative disorders | Vascular occlusion | Retiform purpura (often acral; Fig. 18.3), gangrene, acrocyanosis, Raynaud phenomenon |
| II** | Monoclonal IgM* (>IgG*) against polyclonal IgG | HCV, HIV, autoimmune connective tissue diseases, lymphoproliferative disorders | Vasculitis | Palpable purpura, arthralgias, peripheral neuropathy, glomerulonephritis |
| III** | Polyclonal IgM* against polyclonal IgG | | | |

*Typically have rheumatoid factor activity (i.e. are directed against the Fc portion of IgG).
**Referred to as "mixed" cryoglobulins.

**Table 18.3 Classification of cryoglobulins.** HCV, hepatitis C virus.



**Fig. 18.2 Heparin necrosis at site of subcutaneous heparin injection.** Note the branching or retiform pattern of intense hemorrhage and the necrosis in the center of the lesion. *From Robson K, Piette W. Adv Dermatol. 1999;15:153–182, used with permission.*




**Fig. 18.3 Type I cryoglobulinemia in a patient with multiple myeloma (IgG type). A** Note the retiform purpura and the areas of necrosis within the purpuric areas (inset). **B** Lesions favor the helices of the ears as well as the distal extremities and nose. *A, Courtesy, Jean L. Bolognia, MD. B, Courtesy, Jonathan Leventhal, MD.*



**Fig. 18.4 Retiform purpura in antiphospholipid syndrome.** Purpura and ischemia of the distal portion of the foot. The purpuric lesions have irregular borders (marked with ink). *Courtesy, Jean L. Bolognia, MD.*



**Fig. 18.6 Warfarin (Coumadin®) necrosis.** Striking area of retiform purpura and ischemia on the scrotum. *Courtesy, Kenneth Greer, MD.*

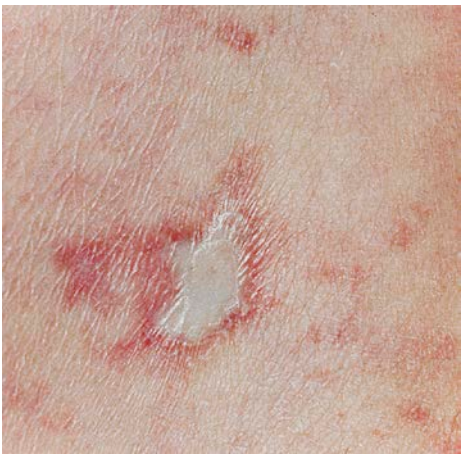

**Fig. 18.5 Atrophie blanche-like scarring in antiphospholipid syndrome.** This patient had lupus erythematosus. *Courtesy, Warren Piette, MD.*



**Fig. 18.7 Protein C deficiency in an infant.** Large purpuric plaques, with development of bullae and necrotic ulcerations within those on the lower extremities. Note the retiform purpura surrounding the heel ulcer. *Courtesy, Luis Requena, MD.*

- Cutaneous findings can include livedo reticularis, retiform purpura progressing to cutaneous necrosis, leg ulcers, livedoid vasculopathy, Degos-like lesions, nail bed infarcts, superficial thrombophlebitis, and anetoderma (see Figs 18.4 and 18.5).
- Deep venous thrombosis and CNS disease are the most common extracutaneous manifestations; catastrophic APS affecting multiple organ systems together with widespread retiform purpura occasionally occurs.
- **Rx:** anticoagulant and antiplatelet agents; also immunomodulatory agents (e.g. systemic CS, rituximab) for catastrophic APS.

## Livedoid Vasculopathy

- Chronic condition that occurs primarily in young to middle-aged women, often with underlying thrombophilia (Table 18.5).



**Fig. 18.8 Livedoid vasculopathy.** Punched-out ulcers on the ankle as well as multiple stellate purpuric macules. *Courtesy, YDRSC.*

- Recurrent development of hemorrhagic crusts resembling ground pepper and extremely painful, punched-out ulcers on the legs (especially the ankles); frequently arises within a background of retiform purpura ± livedo reticularis (see Fig. 18.8).
- The ulcers heal slowly, forming stellate, ivory-white, atrophic scars bordered by papular telangiectasias and hemosiderin pigmentation; such lesions, referred to as *atrophie blanche*, also occur in other settings such as venous hypertension, antiphospholipid syndrome (see Fig. 18.5), and cutaneous vasculitis.
- **Rx:** anticoagulant, antiplatelet, and fibrinolytic agents (especially if thrombophilia).

## Other Purpuric Disorders

### Pigmented Purpuric Dermatoses (Capillaritis)

- Group of disorders characterized by clustered petechial hemorrhage due to inflammation affecting capillaries.




**Fig. 18.9 Cholesterol emboli. A** Livedo reticularis proximally on the thigh. **B** Both livedo reticularis and retiform purpura distally. **C** Purpura of the digits in "warfarin blue toe syndrome". **D** Several irregularly shaped ulcers with eschars surrounded by retiform purpura. *A, B, Courtesy, Norbert Sepp, MD; C, Courtesy, YDRSC; D, Courtesy, Kalman Watsky, MD.*

| ANTIPHOSPHOLIPID ANTIBODY SYNDROME: SAPPORO–SYDNEY CRITERIA |
|---|
| **At least one clinical criterion and one laboratory criterion required*** |
| **Clinical criteria** |
| 1. Vascular thrombosis<br>– One or more objectively confirmed episodes of arterial, venous, or small vessel thrombosis occurring in any tissue or organ<br>2. Pregnancy morbidity<br>– One or more unexplained deaths of morphologically normal fetuses at or after the 10th week of gestation – *or* –<br>– One or more premature births of morphologically normal neonates at or before the 34th week of gestation because of eclampsia, pre-eclampsia, or placental insufficiency – *or* –<br>– Three or more unexplained consecutive spontaneous abortions before the 10th week of gestation |
| **Laboratory criteria – present on two or more occasions at least 12 weeks apart*** |
| 1. Anti-cardiolipin antibodies, IgG or IgM [>40 GPL/MPL *or* >99th percentile as measured by a standardized ELISA]<br>2. Lupus anticoagulant [detected according to the guidelines of the International Society on Thrombosis and Haemostasis]<br>3. Anti-$\beta_2$-glycoprotein I antibodies, IgG or IgM [>99th percentile as measured by a standardized ELISA] |
| **Patients who do not meet these criteria may still have antiphospholipid antibody syndrome.* |

**Table 18.4 Antiphospholipid syndrome: Sapporo–Sydney criteria.** GPL, IgG phospholipid units; MPL, IgM phospholipid units. *Adapted from Lim W. Thrombotic risk in the antiphospholipid syndrome Semin Thromb Hemost 2014;40:741–6.*



**Fig. 18.10 Intravascular B-cell lymphoma.** The clinical presentation in this patient was retiform purpura and necrosis with livedo. *Courtesy, Lucinda Buescher, MD.*

• *Schamberg disease:* most common form, occurring in both children and adults; recurrent crops of discrete yellow-brown patches containing pinpoint petechiae ("cayenne pepper") on the lower legs > thighs, buttocks, trunk, and arms (Fig. 18.11A); the yellow-brown color reflects deposits of hemosiderin, derived from extravasated RBCs, within the dermis.

• *Purpura annularis telangiectodes* (*of Majocchi*): favors adolescent girls and young women; expanding annular plaques with punctate telangiectasias and petechiae in their borders (Fig. 18.12A).

• *Lichen aureus*: solitary golden to rust-colored or purple-brown patch or thin plaque, typically on the leg overlying a perforator vein.

• Other forms include *pigmented purpuric lichenoid dermatitis* presenting as red-brown papules and *eczematid-like purpura* with scaling and pruritus (Fig. 18.12B); these variants favor the lower legs of men.

• **DDx:** "stasis purpura" presenting as petechiae superimposed on diffuse hemosiderin deposition on the legs (see Fig. 18.11B); purpuric forms of allergic contact dermatitis, drug eruptions or mycosis fungoides; suction-induced purpura (e.g. with cupping), hypergammaglobulinemic purpura of Waldenström, angioma serpiginosum; *for lichenoid variant:* primarily small vessel vasculitis.

| EVALUATION FOR THROMBOPHILIA (HYPERCOAGULABILITY) | | |
|---|---|---|
| **Disorder** | **~% of population** | **Potential confounding conditions** |
| **Hereditary** | | |
| Factor V Leiden (can screen with activated protein C resistance) | 5 | Warfarin, OCP, pregnancy, ↑ factor VIII levels, lupus anticoagulant |
| Prothrombin G20210A mutation | 3 | — |
| Hyperhomocysteinemia (↑ homocysteine level*) | >5 | Deficient folate, $B_{12}$, or $B_6$; older age, smoking |
| Protein C deficiency (↓ activity) | 0.3 | Warfarin, OCP, pregnancy, liver disease |
| Protein S deficiency (↓ free antigen level) | ≤0.3 | Warfarin, OCP, pregnancy, liver disease |
| Antithrombin III deficiency | 0.05 | Heparin, liver disease |
| Excess factor VIII activity | 10 | Acute-phase response, OCP, pregnancy, old age |
| Dysfibrinogenemia (↓ fibrinogen activity relative to antigen level; ↑ reptilase time) | — | Liver or renal disease, amyloidosis, malignancy |
| Excess plasminogen activator inhibitor-1 (PAI-1) activity* | 10+ | Wide range of normal values |
| **Acquired** | | |
| Lupus anticoagulant† | — | Warfarin, heparin |
| Anticardiolipin antibodies (IgG or IgM)† | — | Various infectious diseases |
| Anti-$\beta_2$-glycoprotein I antibodies (IgG or IgM)† | — | — |
| Cryoglobulinemia, type I | — | — |
| Cryofibrinogens | — | Acute-phase response |

**May subsequently test for a homozygous* MTHFR *mutation (although hyperhomocysteinemia can also be due to other genes or acquired) or* PAI-1 *4G/5G polymorphism.*
*†Antiphospholipid antibodies (see Table 18.4); additional studies may include anti-phosphatidylserine and/or prothrombin antibodies.*

**Table 18.5 Evaluation for thrombophilia (hypercoagulability).** Evaluation for entities in the rows shaded gray is often considered as second tier. The initial laboratory evaluation should also include a CBC with differential and platelet count, examination of a peripheral blood smear, ESR, activated partial thromboplastin time (PTT), and hepatic and renal function panels. Testing for ANCA can be considered for patients with retiform purpura, as ANCA-positive vasculitides occasionally present with minimally inflammatory lesions.

- **Rx:** difficult; topical CS if pruritic, phototherapy.

## Hypergammaglobulinemic Purpura of Waldenström

- Recurrent crops of petechiae, purpuric macules, and/or palpable purpura (Fig. 18.13) on the lower extremities, often in young women with an autoimmune connective tissue disease (especially Sjögren syndrome).
- Associated with polyclonal hypergammaglobulinemia, an elevated ESR, rheumatoid factor (IgG or IgA), and anti-SSA/Ro and anti-SSB/La antibodies.

For further information see Chs 22 and 23 from *Dermatology, Fourth Edition*.

**For additional online figures visit www.expertconsult.com**

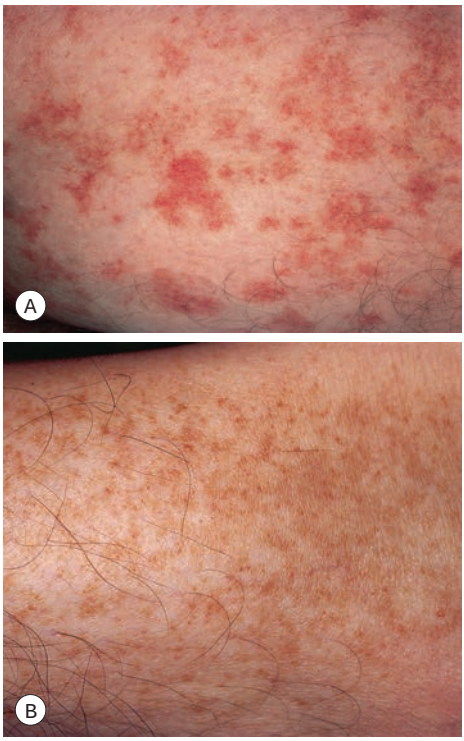


**Fig. 18.11 Schamberg disease versus petechiae and hemosiderin secondary to venous hypertension. A** Discrete yellow-pink patches with superimposed petechiae in Schamberg disease. **B** Petechiae within a background of more diffuse hemosiderin deposition in the setting of venous hypertension, referred to as "stasis purpura." *A, Courtesy, YDRSC; B, Courtesy, Jean L. Bolognia, MD.*




**Fig. 18.12 Less common forms of pigmented purpuric eruptions. A** Purpura annularis telangiectodes of Majocchi characterized by annular plaques with "cayenne pepper" petechiae in the border. **B** Eczematid-like purpura that typically presents with pruritus. *A, Courtesy, YDRSC; B, Courtesy, Kalman Watsky, MD.*



**Fig. 18.13 Hypergammaglobulinemic purpura of Waldenström.** This young woman with Sjögren syndrome had recurrent crops of petechiae on her lower legs. Note the hemosiderin deposition at sites of older lesions. *Courtesy, Julie V. Schaffer, MD.*



**eFig. 18.1 Actinic (solar) purpura in sites of chronic sun exposure plus trauma.** *Courtesy, Jean L. Bolognia, MD.*

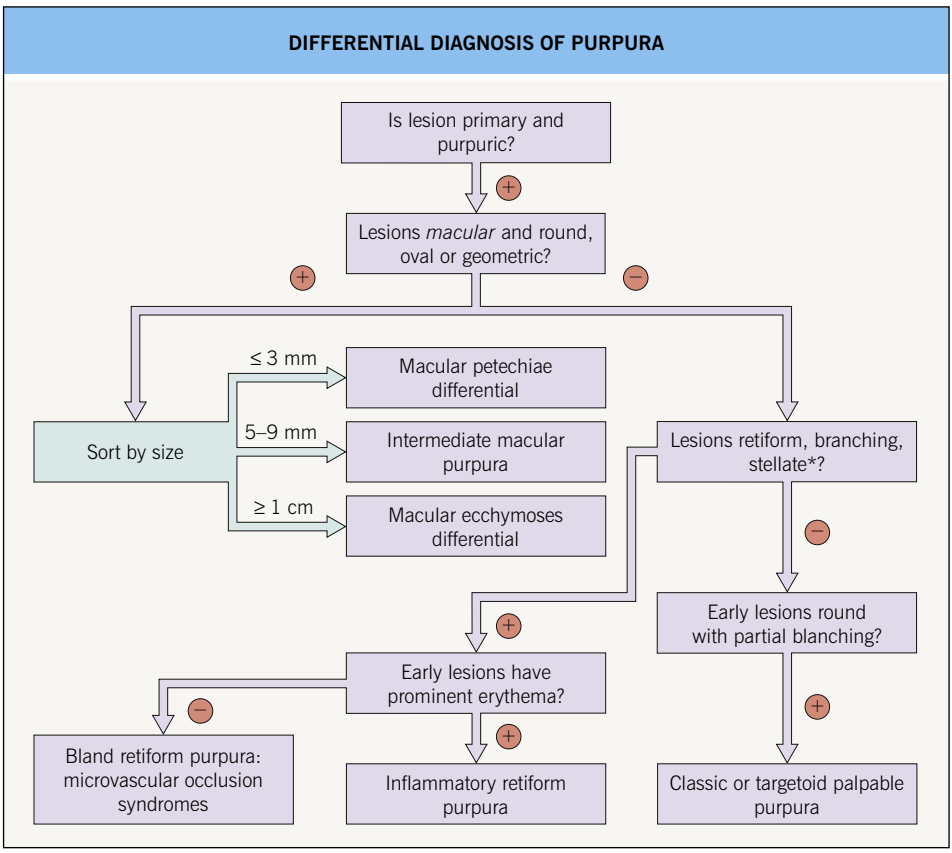


**eFig. 18.2 Differential diagnosis of purpura.** *While very few lesions are truly stellate, i.e. characterized by a central area of necrosis or hemorrhage with radiating extensions, some authors continue to use this term to describe these lesions.

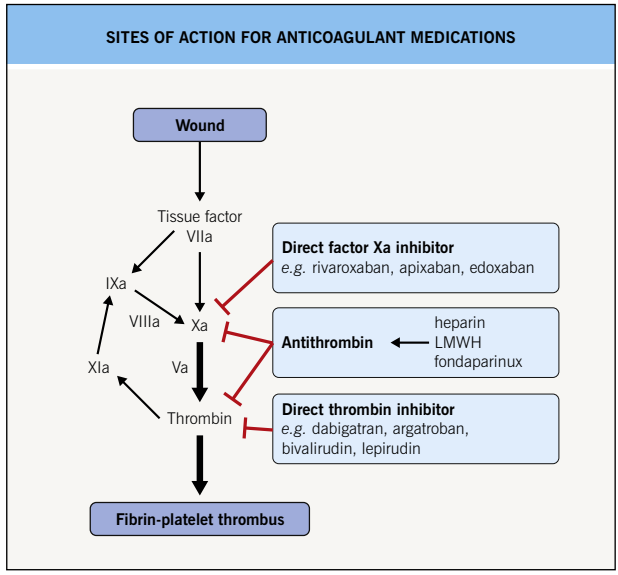


**eFig.18.3 Sites of action for anticoagulant medications.**
LMWH, low-molecular-weight heparin.



**eFig. 18.4 Warfarin (Coumadin®) necrosis.**
Striking areas of purpura and ischemia on the pannus. Note the branching outline of the purpura and central necrosis in the lesions. *Courtesy, Jean L. Bolognia, MD.*



**eFig. 18.5 Antiphospholipid antibody syndrome.** Purpura and ischemia of the distal fingers. *Courtesy, YDRSC.*



**eFig. 18.6 Livedo racemosa due to adenosine deaminase 2 deficiency.** *Courtesy, Edward Cowen, MD.*

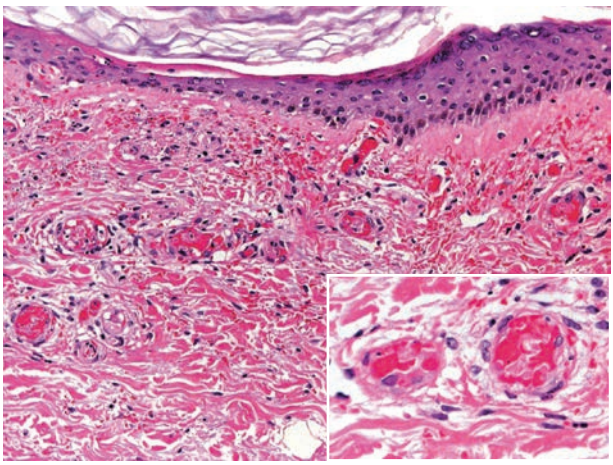

**eFig. 18.7 Histopathology of occlusive vasculopathy due to type I cryoglobulinemia.** In the dermis, there is eosinophilic material within several blood vessels (inset) with hemorrhage and a minimal inflammatory infiltrate. *Courtesy, Lorenzo Cerroni, MD.*

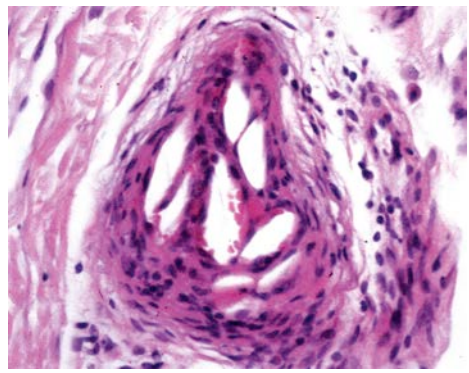

**eFig. 18.8 Histopathology of cholesterol emboli.** Intravascular clefts, which result from dissolution of cholesterol crystals during fixation, are seen. *Courtesy, Norbert Sepp, MD.*



**eFig. 18.9 Linear pigmented purpuric dermatosis.** There is a linear array of yellow-brown macules and patches with superimposed petechiae and small, red-brown purpuric papules on the arm of a child. The eruption had been present for several months and was limited to this segment of skin. *Courtesy, Julie V. Schaffer, MD.*

# 19 Vasculitis

- Vasculitis is characterized by an inflammatory infiltrate that targets blood vessels and leads to destruction of their walls.
- Cutaneous vasculitis can occur in isolation or together with involvement of other organs; in the latter scenario, skin findings may represent important signs of systemic disease.
- Cutaneous vasculitides are classified based on the size of the vessels affected, which determines the morphology of the skin lesions (Table 19.1).
- Other features that assist in categorization include direct immunofluorescence findings (e.g. IgA deposits in Henoch–Schönlein purpura [HSP]), the presence or absence of antineutrophil cytoplasmic antibodies (ANCA), and systemic manifestations (e.g. hematuria, abdominal pain, paresthesias).
- Constitutional symptoms (e.g. fevers, malaise) and arthralgias or arthritis can develop in most forms of vasculitis.
- Favors adults but can occur at any age; HSP accounts for the majority of cases in children.
- The pathogenesis of cutaneous small vessel vasculitis (CSVV) and several other vasculitides (e.g. cryoglobulinemic vasculitis, polyarteritis nodosa) is related to immune complex deposition, which results in complement activation and recruitment of neutrophils; in contrast, neutrophils directly mediate vessel damage in ANCA-associated "pauci-immune" vasculitis.

## Cutaneous Small Vessel Vasculitis (CSVV)

- The clinical hallmark of CSVV is palpable purpura – nonblanching red-purple papules that favor dependent sites and areas of trauma (Koebner phenomenon) or pressure (e.g. from tight clothing); however, lesions often begin as partially blanching urticarial papules or purpuric macules, and occasionally other morphologies may be observed (e.g. vesicles or pustules; see Table 19.1, Figs 19.1 and 19.2); frequently asymptomatic but can have associated pruritus, burning, or pain.
- Possible underlying conditions are presented in Figs 19.3 and 19.4.
- Characterized by the histologic finding of *leukocytoclastic vasculitis (LCV)* – transmural infiltration of postcapillary venules by neutrophils that undergo fragmentation (leukocytoclasia), leading to fibrinoid necrosis of the vessel walls (see Fig. 1.14).
- **DDx:** specific CSVV subtypes or systemic vasculitides (see Table 19.1 and below), morbilliform drug eruptions or arthropod bites (with hemorrhage in dependent sites), petechial viral exanthems (see Fig. 68.1), pigmented purpura, erythema multiforme, pityriasis lichenoides, septic emboli.
- Usually resolves within several weeks to months, typically with postinflammatory hyperpigmentation; chronic or recurrent in ~10% of patients, especially if an underlying AI-CTD or cryoglobulinemia.
- **Rx:** eliminate possible triggers, evaluate for systemic involvement (see Fig. 19.15), and provide supportive care (e.g. leg elevation, NSAIDs); for more severe or persistent (e.g. >4 weeks) skin disease, oral dapsone ± colchicine; if rapidly progressive or ulcerating, a 4- to 6-week course of prednisone may be considered.

### Henoch–Schönlein Purpura (HSP)

- Form of CSVV characterized by prominent vascular IgA deposition, which is evident via direct immunofluorescence (DIF) of a skin biopsy specimen (see Fig. 23.2); favors children <10 years of age, often presenting 1–2 weeks after an upper respiratory tract infection (URI).
- Urticarial papules evolve into palpable purpura, occasionally progressing to bullous or necrotic lesions (Fig. 19.5); typically involves the buttocks and lower extremities, but may be more widespread.

| CLASSIFICATION OF CUTANEOUS VASCULITIS | | | |
|---|---|---|---|
| **Size of predominantly affected vessels** | **Types of vessels affected in the skin** | **Forms of cutaneous vasculitis** | **Cutaneous morphologies** |
| Small | Arterioles, capillaries and venules in *superficial to mid dermis* | **Idiopathic**<br>**Secondary causes** (e.g. drugs, infections, inflammatory disorders; Fig. 19.3)<br>**Henoch–Schönlein purpura**<br>**Urticarial vasculitis**<br>**Acute hemorrhagic edema of infancy**<br>**Erythema elevatum diutinum** | • Palpable purpura (Fig. 19.1) > macular purpura or petechiae<br>• Urticarial, annular or targetoid papules/plaques (Fig. 19.2A,B)<br>• Vesicles, bullae (Fig. 19.2C), pustules |
| Small ± medium-sized | | **Cryoglobulinemic vasculitis**<br>**ANCA-associated vasculitis**<br>• Granulomatosis with polyangiitis<br>• Eosinophilic granulomatosis with polyangiitis<br>• Microscopic polyangiitis<br>**Secondary causes** (e.g. drugs, rheumatoid arthritis; Fig. 19.3) | |
| Medium-sized | Small arteries and veins in *deep dermis to subcutis* | **Polyarteritis nodosa (PAN)**<br>• Classic (systemic) PAN<br>• Cutaneous PAN | • Livedo racemosa ("broken" livedo reticularis)<br>• Retiform purpura<br>• Subcutaneous nodules<br>• Ulcers, digital necrosis |
| Large | (*Extracutaneous* named arteries*) | **Temporal arteritis**<br>**Takayasu arteritis** | • Temporal arteritis*: erythema, alopecia, purpura, tender nodules → ulcers on frontotemporal scalp; ulcers on tongue<br>• Takayasu arteritis*: nodules, ulcers |

*Cutaneous involvement is uncommon.*

**Table 19.1 Classification of cutaneous vasculitis.**

Downloaded for Novin lib (novinlibrary@yahoo.com) at United Arab Emirates University from ClinicalKey.com by Elsevier on March 26, 2022. For personal use only. No other uses without permission. Copyright ©2022. Elsevier Inc. All rights reserved.




**Fig. 19.1 Cutaneous small vessel vasculitis.** **A** Classic presentation of purpuric macules and papules on the distal lower extremities. **B** Early lesions may be erythematous rather than purpuric. **C** Eventually inflammatory lesions can no longer be blanched due to hemorrhage within the dermis. **D** Hemorrhagic vesicles in addition to palpable purpura. **E** Central necrosis with formation of hemorrhagic crusts. *A, C, Courtesy, Kalman Watsky, MD; B, Courtesy, NYU Slide Collection; D, Courtesy, YDRSC; E, Courtesy, Frank Samarin, MD.*




**Fig. 19.2 Clinical variants of cutaneous small vessel vasculitis.** **A** Targetoid appearance that can resemble erythema multiforme. **B** Hemorrhagic crusts in annular configuration. **C** Predominantly vesicular lesions on the foot. **D** Lesions limited to the upper extremities. **E** Purpuric macules and papules with areas of confluence resembling a purpuric morbilliform drug eruption. *A, Courtesy, Kalman Watsky, MD; B, Courtesy, YDRSC; C, Courtesy, Karynne O. Duncan, MD; D, Courtesy, Lindy Fox, MD; E, Courtesy, David Wetter, MD, and Jan Dutz, MD.*

**ETIOLOGIES OF CUTANEOUS SMALL VESSEL VASCULITIS**

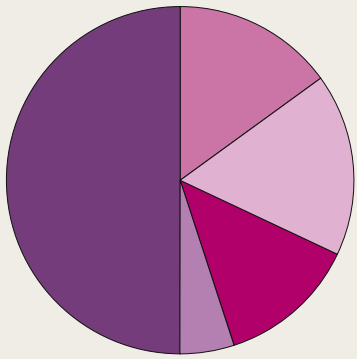

- **Infection (15–20%)**
  e.g. streptococcal or upper respiratory tract infections, hepatitis C>B, leprosy, subacute infective endocarditis
- **Autoimmune connective tissue disease (15–20%)**
  e.g. rheumatoid arthritis, SLE, Sjögren syndrome
- **Drug (10–15%)**
  e.g. penicillins, quinolones, NSAIDs, propylthiouracil*
- **Neoplasm (5%)**
  e.g. plasma cell dyscrasias, myelo- and lymphoproliferative disorders
- **Idiopathic (45–55%)**

*Often associated with antineutrophil cytoplasmic antibodies (ANCA).

**Fig. 19.3 Etiologies of cutaneous small vessel vasculitis.**










**Fig. 19.4 Cutaneous small vessel vasculitis associated with systemic disorders.** The underlying diseases were Sjögren syndrome **(A),** rheumatoid arthritis **(B)**, and endocarditis due to *Streptococcus mitis* **(C).** Note the Koebner phenomenon in **(A)** and the rheumatoid nodules in **(B).** *A, B, Courtesy, YDRSC; C, Courtesy, David Wetter, MD, and Jan Dutz, MD.*




**Fig. 19.5 Henoch–Schönlein purpura. A, B** Multiple pink, partially blanching papules on the lower extremities. These early lesions are beginning to develop a hemorrhagic component, while sites of previous involvement on the shin are now dull pink patches. **C** Less common vesiculobullous variant. **D** More developed purpuric macules and papules on the buttocks with coalescence into a retiform configuration on the upper left. Inflammatory retiform purpura can be seen in IgA vasculitis. *A, C, D, Courtesy, David Wetter, MD, and Jan Dutz, MD; B, Courtesy, YDRSC.*

- Other manifestations include acral or scrotal edema, arthralgias/arthritis (especially of the knees and ankles; ~75% of children), colicky abdominal pain (~65%; occasionally intussusception), bloody stools (~30%), and microscopic hematuria ± proteinuria (~30–40%; can be delayed up to 3 months).
- Resolves over several weeks to months, with recurrent purpuric eruptions in ~20% and long-term renal impairment in ~2% of children with HSP.
- Adults with HSP are more likely to have necrotic skin lesions, renal involvement, and chronic kidney disease; in adults with unexplained persistent or widespread IgA vasculitis, especially if involving medium-sized vessels, an underlying IgA monoclonal gammopathy or malignancy should be considered.
- **Rx:** as for CSVV above, with monitoring for renal disease and systemic CS therapy as needed for arthritis, abdominal pain, and severe nephritis; however, CS administration does not appear to prevent renal disease or its sequelae.

## Acute Hemorrhagic Edema of Infancy

- Uncommon CSVV variant that affects children ≤2 years of age, often following a URI.
- Presents with annular or targetoid purpuric plaques and edema favoring the face, ears, and extremities (Fig. 19.6); patients may be febrile, but extracutaneous involvement is rare and spontaneous resolution occurs within 1–3 weeks.
- **DDx:** urticaria "multiforme" (giant annular urticaria; see Fig. 3.3), serum sickness-like




**Fig. 19.6 Acute hemorrhagic edema of infancy.** Multiple edematous, erythematous plaques on the face and extremities of a toddler. Some of the lesions have begun to become dusky. *Courtesy, Ilona J. Frieden, MD.*



**Fig. 19.7 Urticarial vasculitis.** Arcuate, dull violet urticarial plaques on the lower extremities. *Courtesy, David Wetter, MD, and Jan Dutz, MD.*

reaction, urticarial vasculitis, Kawasaki disease, erythema multiforme, Sweet syndrome; findings sometimes overlap with HSP.

### Urticarial Vasculitis

- Presents with urticarial plaques that have histologic features of LCV (Fig. 19.7); favors middle-aged women, and a hypocomplementemic subset is associated with AI-CTD (especially SLE and Sjögren syndrome).
- In contrast to urticaria, individual lesions last >24 hours, resolve with purpura or hyperpigmentation, and produce burning or pain > pruritus.
- Patients with hypocomplementemic urticarial vasculitis may have arthralgias/arthritis, chronic obstructive pulmonary disease, and involvement of the GI tract, kidneys, or eyes.
- **DDx:** see Table 14.1.

### Erythema Elevatum Diutinum

- Chronic form of vasculitis that favors middle-aged to older adults; associated disorders include HIV and other infections (e.g. streptococcal), AI-CTD, and IgA monoclonal gammopathy.
- Presents with persistent violaceous to red-brown plaques on extensor surfaces (e.g. elbows, knees) (Fig. 19.8); patients occasionally have arthralgias or ocular disease, and dapsone therapy is usually effective.

## Small and Medium-Sized Vessel Vasculitis

### Cryoglobulinemic Vasculitis (see Table 18.3)

- "Mixed" cryoglobulinemia (types II and III) can lead to vasculitis of small ± medium-sized vessels; associated with hepatitis C infection > other infections (e.g. HIV), AI-CTD, and lymphoproliferative disorders.
- Palpable purpura is the most common cutaneous manifestation (Fig. 19.9); other findings can include arthritis/arthralgias, peripheral neuropathy, glomerulonephritis, and hepatitis.
- **Rx:** treatment of associated hepatitis C with direct-acting antivirals (now first-line; e.g. sofosbuvir + ledipasvir or daclatasvir) or interferon + ribavirin; CS or rituximab for severe or refractory systemic disease.



**Fig. 19.8 Erythema elevatum diutinum.** Erythematous papulonodules on the knee (acute lesions) admixed with resolving lesions. *Courtesy, Kenneth Greer, MD.*




**Fig. 19.9 Cutaneous small vessel vasculitis due to mixed cryoglobulinemia. A** Palpable purpura represents the most common presentation. **B** Purpuric papules and plaques with central necrosis and ulceration as well as a few vesicles in a patient with type II cryoglobulinemia in the setting of hepatitis C viral infection. The patient also had an elevated rheumatoid factor, decreased C4, and an IgM monoclonal gammopathy. *B, Courtesy, David Wetter, MD, and Jan Dutz, MD.*

## ANCA-Associated Vasculitis

- The features of specific ANCA-associated vasculitides are presented in Table 19.2 and Figs 19.10–19.12.
- Favors middle-aged to older adults, but can occur at any age.
- Requires evaluation for extracutaneous disease (see Fig. 19.15).
- ANCA against various antigens also occur in other diseases (e.g. ulcerative colitis, autoimmune hepatitis); cocaine use can lead to ANCA (typically against myeloperoxidase, proteinase-3, and neutrophil elastase) together with nasal destruction (Table 19.3) or (with levamisole adulteration) more widespread vasculitis or vasculopathy plus neutropenia (see Fig. 75.3).
- **Rx:** induction of remission with systemic CS ± cyclophosphamide or rituximab; maintenance with CS-sparing agents (e.g. methotrexate, azathioprine), trimethoprim–sulfamethoxazole.

## Predominantly Medium-Sized Vessel Vasculitis

### Polyarteritis Nodosa (PAN): Classic (Systemic) and Cutaneous Variants

- Segmental vasculitis affecting primarily medium-sized vessels, including small arteries in the deep dermis and subcutis.
- Favors middle-aged adults (men > women), but can occur at any age.
- **DDx:** other types of vasculitis; livedoid vasculopathy, antiphospholipid syndrome, and other microvascular occlusion syndromes (see Ch. 18); superficial thrombophlebitis, panniculitis.

#### CLASSIC (SYSTEMIC) PAN

- Associated with hepatitis B infection in ~10% of patients.
- Approximately 25% of patients have cutaneous manifestations, including livedo racemosa, retiform purpura, palpable purpura (when small vessels are affected), and "punched out" ulcers > subcutaneous nodules and digital infarcts (Fig. 19.13A).

Downloaded for Novin lib (novinlibrary@yahoo.com) at United Arab Emirates University from ClinicalKey.com by Elsevier on March 26, 2022. For personal use only. No other uses without permission. Copyright ©2022. Elsevier Inc. All rights reserved.

| ANCA-ASSOCIATED VASCULITIDES | | | | |
|---|---|---|---|---|
| **Disorder [No. of diagnostic criteria required]** | **Predominant ANCA type/antigen** | **Cutaneous and oral findings** | **Extracutaneous manifestations** | **Histologic findings¶** |
| Granulomatosis with polyangiitis (GPA; Wegener granulomatosis) [2] | C-/PR3 (80–90%*)<br>P-/MPO (~10%) | • Palpable purpura (Fig. 19.10A)<br>• Friable, micropapular gingivae ("strawberry gums"; see Fig. 59.17), oral ulcers (Fig. 19.10B)<br>• PNGD**<br>• Subcutaneous nodules<br>• Pyoderma gangrenosum-like ulcers (Fig. 19.10C) | • **Upper respiratory**: *oral ulcers or purulent/bloody nasal discharge;* septal perforation/saddle nose (Table 19.3); acute hearing loss; chronic sinusitis/otitis/mastoiditis<br>• **Pulmonary**: *nodules, fixed infiltrates or cavities*†<br>• **Renal:** glomerulonephritis, *with hematuria or RBC casts in urine sediment*<br>• **Ocular**: proptosis, scleritis<br>• Less often neurologic, GI, and cardiac involvement | • *Granulomatous inflammation*<br>• Vasculitis of small ± medium-sized vessels |
| Eosinophilic granulomatosis with polyangiitis (EGPA; Churg–Strauss syndrome)‡ [4] | P-/MPO (~40%)<br>C-/PR3 (~10%) | • Palpable purpura (Fig. 19.11A)<br>• PNGD** (Fig. 19.11B)<br>• Subcutaneous nodules<br>• Urticarial plaques<br>• Livedo racemosa, retiform purpura (Fig. 19.11C), ulcers | • **Upper respiratory**: allergic rhinitis§, nasal polyps§, *sinusitis*†<br>• **Pulmonary**: *asthma*§, *eosinophilic pneumonia*†<br>• **Hematologic**: *peripheral eosinophilia (>10%)*, elevated IgE<br>• **Neurologic**: *mononeuritis multiplex*<br>• **Cardiac**: myo- or pericarditis<br>• Less often renal, GI, and ocular involvement | • *Extravascular eosinophils*<br>• Granulomatous inflammation<br>• Vasculitis of small ± medium-sized vessels |
| Microscopic polyangiitis [4] | P-/MPO (~60%)<br>C-/PR3 (~30%) | • Palpable purpura (Fig. 19.12)<br>• Erythematous macules, urticarial or purpuric plaques<br>• Livedo racemosa, ulcers, splinter hemorrhages | • **Renal**: glomerulonephritis, *with hematuria or RBC casts in urine sediment*<br>• **Pulmonary**: capillaritis/hemorrhage, *no asthma*<br>• **Neurologic**: mononeuritis multiplex<br>• Less often upper respiratory tract, cardiac, GI, and ocular involvement | • *Vasculitis of small* (± medium-sized) *vessels*<br>• *No granulomas* |

**Approximately 60% in patients with limited/localized disease.*
***Palisaded neutrophilic and granulomatous dermatitis, which typically presents with umbilicated, crusted papulonodules on extensor surfaces (e.g. elbows) or the face (especially in granulomatosis with polyangiitis) (see Ch. 78).*
*†Radiographic evidence represents a diagnostic criterion.*
*‡Occasionally triggered by leukotriene inhibitors and/or rapid discontinuation of CS therapy.*
*§Usually the initial manifestations.*
*¶May be observed in biopsies of the skin, mucosa, respiratory tract, kidney, or nerve.*

**Table 19.2 Antineutrophil cytoplasmic antibody (ANCA)-associated vasculitides.** As in other forms of vasculitis, patients often have constitutional symptoms (e.g. fevers, malaise, weight loss), arthralgias, and arthritis. *Classic diagnostic criteria for each disorder (1990 American College of Rheumatology Classification for GPA and EGPA) are in italics*. Alternative criteria that do not specify a lack of granulomatous inflammation have also been proposed for microscopic polyangiitis. C-, cytoplasmic ANCA; MPO, myeloperoxidase; PR3, proteinase-3; P-, perinuclear ANCA.




**Fig. 19.10 Granulomatosis with polyangiitis (Wegener granulomatosis).** **A** Palpable purpura of the legs due to small vessel vasculitis (leukocytoclastic vasculitis). **B** Ulceration of the tongue**. C** Ulceration on the leg, which may be misdiagnosed as pyoderma gangrenosum. **D** Subungual digital infarcts. *A, B, D, Courtesy, YDRSC; C, Courtesy, David Wetter, MD, and Jan Dutz, MD.*




**Fig. 19.11 Eosinophilic granulomatosis with polyangiitis (Churg–Strauss syndrome).** **A** Palpable purpura on the buttocks due to small vessel (leukocytoclastic) vasculitis. **B** Palisaded neutrophilic and granulomatous dermatitis presenting with crusted, firm papules on the elbow. **C** Purpuric dermal plaques on the palm due to vasculitis involving a small artery (representing medium-sized vessel). *A, C, Courtesy, Kanade Shinkai, MD, and Lindy P. Fox, MD; B, Courtesy, Kalman Watsky, MD.*




**Fig. 19.12 Microscopic polyangiitis. A** Petechiae and purpuric macules on the lower extremity; some of the lesions have central hemorrhagic crusts. Histologically, leukocytoclastic vasculitis was seen. **B** Petechiae and multiple purpuric papules with central necrosis on the plantar surface. *A, Courtesy, David Wetter, MD, and Jan Dutz, MD; B, Courtesy, Cora Whitney Hannon, MD, and Robert Swerlick, MD.*




**Fig. 19.13 Polyarteritis nodosa (PAN). A** Retiform purpura of the dorsal foot in a patient with *systemic* PAN. **B** Livedo racemosa and subcutaneous nodules of the lower extremities in a patient with *cutaneous* PAN. *A, Courtesy, Kanade Shinkai, MD, and Lindy P. Fox, MD; B, Courtesy, David Wetter, MD, and Jan Dutz, MD.*

| DIFFERENTIAL DIAGNOSIS OF NASAL DESTRUCTION OR DEFORMITY |
|---|
| **Inflammatory disorders** |
| • Granulomatosis with polyangiitis<br>• Relapsing polychondritis<br>• Sarcoidosis |
| **Neoplastic disorders** |
| • Nasal natural killer/T-cell lymphoma (lethal midline granuloma)<br>• Squamous cell and basal cell carcinomas<br>• Neuroblastoma, salivary gland tumors, sarcomas (e.g. rhabdomyosarcoma) |
| **Infectious disorders** |
| • *Bacterial*: rhinoscleroma, glanders, noma, syphilis (late congenital or tertiary), yaws<br>• *Mycobacterial*: leprosy, tuberculosis (lupus vulgaris)<br>• *Fungal*: paracoccidioidomycosis, zygomycosis, aspergillosis<br>• *Parasitic*: mucocutaneous leishmaniasis, acanthamoebiasis, rhinosporidiosis |
| **Other** |
| • Cocaine use (cocaine-induced midline destructive lesion)<br>• Nasal myiasis<br>• Factitious or traumatic |

**Table 19.3 Differential diagnosis of nasal destruction or deformity.**

• Extracutanous manifestations include fevers, weight loss, arthralgias, myalgias, and involvement of arteries supplying the GI tract, kidneys (e.g. renovascular hypertension, *not* glomerulonephritis), nervous system (peripheral > central), heart, and testes.

• **Rx:** systemic CS, treatment of associated hepatitis B; cyclophosphamide for severe or refractory systemic disease.

### CUTANEOUS PAN

• Accounts for >30% of childhood PAN and ≤5% of adult PAN.

• May be associated with infections (e.g. streptococcal) or medications (e.g. minocycline – may be P-ANCA$^+$, unlike most forms of PAN); childhood PAN may occur in the setting of adenosine deaminase 2 (ADA2) deficiency, which can also result in early-onset strokes (see Table 37.3).

• Tender subcutaneous nodules favoring the lower extremities, often in a background of livedo racemosa and sometimes following the course of an artery (see Fig. 19.13B); retiform purpura, ulcers, and annular plaques may also be seen.

• Arthralgias, myalgias, and peripheral neuropathy may occur in areas of skin disease; chronic course without systemic progression.

• **Rx:** intralesional or systemic CS, dapsone, methotrexate; TNF inhibitors for ADA2 deficiency.

## Diagnostic Approach to Patients with Suspected Cutaneous Vasculitis

• An approach to the evaluation of patients suspected to have vasculitis, including assessment of underlying conditions and systemic manifestations, is presented in Fig. 19.14.

For further information see Ch. 24 from *Dermatology, Fourth Edition*.

**For additional online figures and tables visit www.expertconsult.com**

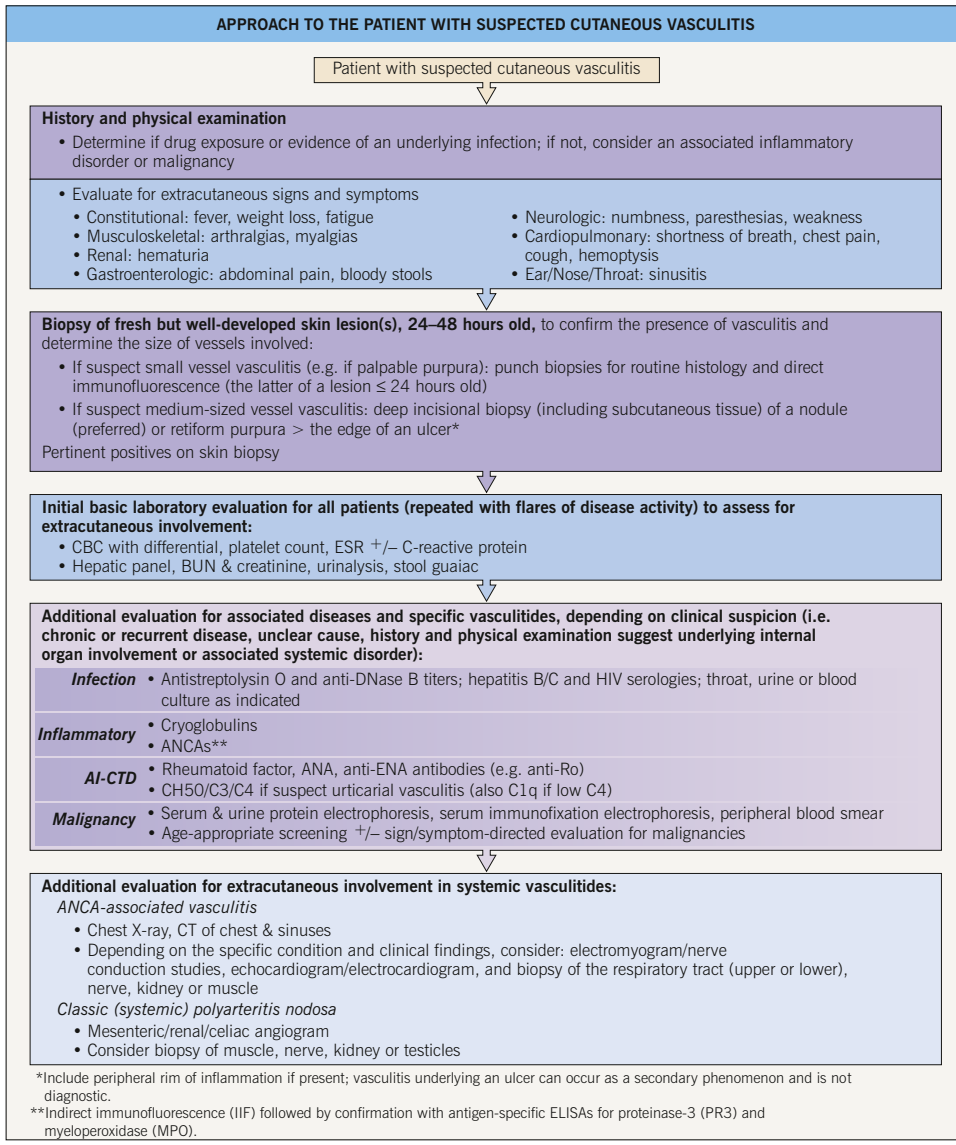


**Fig. 19.14 Approach to the patient with suspected cutaneous vasculitis.** ENA, extractable nuclear antigen; ENT, ear, nose, and throat; GU, genitourinary.

| LYMPHOCYTIC VASCULITIS |
|---|
| • Defined histologically as a perivascular lymphocytic dermal infiltrate with associated damage to the walls of small blood vessels; findings may range from extravasated RBCs and swelling or hyperplasia of endothelial cells to fibrin deposition and fibrinoid necrosis of the vessel wall<br>• Most commonly seen in:<br>**Pernio**<br>**Pityriasis lichenoides et varioliformis acuta (PLEVA)**<br>Resolving leukocytoclastic vasculitis<br>Rickettsial, viral infections<br>Autoimmune connective tissue diseases, e.g. lupus erythematosus, relapsing polychondritis<br>Behçet disease<br>Hypercoagulable disorders, e.g. Sneddon syndrome<br>Lymphocytic thrombophilic arteritis (macular arteritis)<br>Panniculitis, including lupus |

**eTable 19.1 Lymphocytic vasculitis.** This topic is one where there is ongoing debate. The most common entities are in bold.

| CLINICAL DIFFERENTIAL DIAGNOSIS OF CUTANEOUS VASCULITIS | |
|---|---|
| **Clinical presentation** | **Differential diagnosis** |
| Palpable purpuric papules/plaques | Arthropod bites<br>Morbilliform drug eruptions with hemorrhage in dependent sites<br>Erythema multiforme<br>Pityriasis lichenoides et varioliformis acuta<br>Infectious emboli (septic vasculitis) due to bacteria (e.g. *Neisseria meningococcus* [acute meningococcemia]), rickettsiae, fungi (e.g. *Rhizopus*)<br>Lichenoid capillaritis (pigmented purpura)<br>Cellulitis |
| Purpuric macules/patches | **Hemorrhage**<br>• Trauma<br>• Solar (actinic) purpura*<br>• Medication-related (i.e. aspirin, topical or systemic corticosteroids)*<br>• Thrombocytopenia and platelet dysfunction<br>• Coagulopathies*<br>• Viral exanthems (e.g. enterovirus, parvovirus B19)<br>• Scurvy<br>• Primary systemic amyloidosis<br>**Thromboses**<br>• Hypercoagulable state (e.g. antiphospholipid antibody; see (Table 18.5)<br>• Livedoid vasculopathy<br>• Purpura fulminans (e.g. due to sepsis/DIC)<br>• Heparin necrosis<br>• Warfarin (Coumadin®) necrosis<br>• Thrombotic thrombocytopenic purpura<br>• Hemolytic uremic syndrome<br>• Paroxysmal nocturnal hemoglobinuria<br>**Emboli**<br>• Cholesterol<br>• Cardiac (infective endocarditis ≫ myxomatous or marantic)<br>• Fat<br>• Air<br>**Cold-related gelling**<br>• Cryoglobulins (primarily type I)<br>**Inflammation**<br>• Pigmented purpura (capillaritis)<br>• Hypergammaglobulinemic purpura of Waldenström<br>**Infection**<br>• Lucio phenomenon (leprosy)<br>• Strongyloidiasis |

**eTable 19.2 Clinical differential diagnosis of cutaneous vasculitis.** *Continued*

| CLINICAL DIFFERENTIAL DIAGNOSIS OF CUTANEOUS VASCULITIS | |
|---|---|
| **Clinical presentation** | **Differential diagnosis** |
| Urticarial lesions | Urticaria (including neutrophilic urticaria)<br>Arthropod bites and papular urticaria<br>Urticaria multiforme<br>Serum sickness-like reaction<br>Autoinflammatory diseases (e.g. periodic fevers; see Tables 3.2 and 37.3)<br>Still disease, including adult-onset<br>Schnitzler syndrome<br>Viral exanthems<br>Kawasaki disease<br>Sweet syndrome<br>Urticarial phase of bullous pemphigoid |
| Ulcers ± atrophie blanche | Venous hypertension or peripheral arterial disease<br>Pyoderma gangrenosum<br>Livedoid vasculopathy<br>Hypercoagulable state (e.g. antiphospholipid antibodies; see Table 105.9)<br>Calciphylaxis<br>Infections (e.g. bacterial, mycobacterial, dimorphic or opportunistic fungal, protozoal)<br>Hemoglobinopathies<br>Factitial<br>Halogenodermas<br>Degos disease<br>(See Fig. 86.1 for additional entities) |
| Nodules | Panniculitis<br>Superficial migratory thrombophlebitis<br>Dermal neoplasms<br>Infections (e.g. bacterial, mycobacterial, dimorphic or opportunistic fungal) |
| Livedo reticularis | See Ch. 87 |
| Digital gangrene | Arterial occlusive disease, including atherosclerosis<br>Diabetes mellitus<br>Thromboangiitis obliterans (Buerger disease)<br>Systemic sclerosis<br>Emboli (e.g. cholesterol, septic)<br>Cryoglobulinemia (type I) > cryofibrinogenemia or cold agglutinin disease<br>Thrombosis (e.g. antiphospholipid syndrome, purpura fulminans, myeloproliferative thrombocytosis)<br>Calciphylaxis<br>Hypereosinophilic syndrome<br>Paraneoplastic acral vascular syndrome (e.g. with lung or ovarian carcinoma) |
| **Element of trauma.* | |

**eTable 19.2** *Continued* **Clinical differential diagnosis of cutaneous vasculitis.** DIC, disseminated intravascular coagulation.

| UNDERLYING CAUSES OF SECONDARY CUTANEOUS VASCULITIS | | | | |
|---|---|---|---|---|
| **Association** | **Incidence** | **Agent/disease** | | |
| | | *Common* | *Uncommon* | *Rare* |
| Idiopathic | 50% | | | |
| Infection | 15–20% | **Bacterial** | | |
| | | Beta-hemolytic streptococci, especially group A<br>*Mycobacterium leprae* | *Neisseria meningitidis* (in chronic meningococcemia)<br>*Mycobacterium tuberculosis*<br>Atypical mycobacteria | *Mycoplasma pneumoniae*<br>*Chlamydophila pneumoniae, Chlamydia trachomatis*<br>*Brucella*<br>*Bartonella henselae*<br>*Salmonella*<br>*Campylobacter*<br>*Yersinia enterocolitica*<br>*Treponema pallidum* |
| | | **Septic vasculitis*** | | |
| | | Infective endocarditis | *Neisseria meningitidis* (acute)<br>*Neisseria gonorrhoeae*<br>*Staphylococcus aureus*<br>Rickettsiae<br>Gram-negative rods<br>*Escherichia coli*<br>*Klebsiella*<br>*Pseudomonas*<br>Disseminated fungal infections (immunocompromised hosts)<br>*Candida*<br>*Aspergillus*<br>*Fusarium*<br>*Mucor* | *Francisella tularensis* |
| | | **Viral** | | |
| | | Upper respiratory tract infection<br>Hepatitis C > B >> A, including vaccines | HIV<br>Parvovirus B19 | Cytomegalovirus<br>Varicella zoster virus<br>Influenza virus, including vaccine |
| Inflammatory disorders | 15–20% | Autoimmune connective tissue diseases<br>• Rheumatoid arthritis**<br>• SLE<br>• Sjögren syndrome | Inflammatory bowel disease<br>Behçet disease<br>Hypergammaglobulinemic purpura of Waldenström<br>Seronegative spondyloarthropathies | Sarcoidosis<br>Cystic fibrosis‡<br>Primary biliary cholangitis<br>Bowel-associated dermatosis–arthritis syndrome<br>Gluten enteropathy |

**eTable 19.3 Underlying causes of secondary cutaneous vasculitis.** *Continued*

| UNDERLYING CAUSES OF SECONDARY CUTANEOUS VASCULITIS | | | | |
|---|---|---|---|---|
| Drug exposure† | 10–15% | ***Antibiotics, esp. β-lactams***<br>Penicillins<br>Cephalosporins, esp. cefaclor<br>Sulfonamides<br>Minocycline‡<br>Quinolones<br>Macrolides<br>***Cardiovascular***<br>Thiazides<br>Hydralazine‡<br>Quinidine<br>***Other***<br>Allopurinol<br>Bortezomib<br>D-penicillamine<br>G-CSF<br>NSAIDs<br>Propylthiouracil/other antithyroid agents‡<br>Serum (e.g. ATG)<br>Streptokinase | ***Antimicrobials***<br>Quinine<br>Vancomycin<br>***Cardiovascular***<br>ACE inhibitors<br>β-blockers<br>Furosemide<br>***Other***<br>Cocaine adulterated with levamisole‡<br>COX-2 inhibitors<br>Interferons<br>Leukotriene inhibitors‡,§<br>Methotrexate<br>Oral contraceptives<br>Phenytoin<br>Retinoids<br>Sirolimus<br>Sulfonylureas<br>TNF-α inhibitors<br>Warfarin | ***Antimicrobials***<br>Mefloquine<br>***Cardiovascular***<br>Amiodarone<br>***Neuropsychiatric***<br>Atypical antipsychotics<br>Gabapentin<br>Phenothiazines<br>SSRIs<br>***Other***<br>Insulin<br>Leflunomide<br>Metformin<br>Methamphetamine<br>3,4- methylenedioxymethamphetamine<br>Rituximab<br>SSKI<br>Tocolytics (e.g. ritodrine, terbutaline)<br>***Miscellaneous***<br>Radiographic contrast media<br>Food/drug additives<br>Vitamins |
| Neoplasms | 2–5% | Plasma cell dyscrasias<br>• Monoclonal gammopathies<br>• Multiple myeloma<br>Myelodysplasia<br>Myeloproliferative disorders<br>Lymphoproliferative disorders<br>Hairy cell leukemia | Solid organ carcinomas (IgA vasculitis in adults >> other forms of CSVV) | |
| Genetic disorder | Rare | Alpha-1 antitrypsin deficiency | | Immunodeficiency syndrome (see Table 49.1)<br>Familial Mediterranean fever and other periodic fever syndromes |

**Histopathology varies and includes leukocytoclastic vasculitis, organisms within the vessel wall and non-inflammatory thrombotic purpura.*
***Rheumatoid vasculitis typically occurs in seropositive patients with elevated inflammatory markers; cutaneous vasculitis is the most common presentation, followed by vasculitic neuropathy.*
*†Peripheral blood eosinophilia may be present in up to 80% and 20% of patients with systemic and skin-limited diseases, respectively.*
*‡May be associated with antineutrophil cytoplasmic antibodies (ANCAs).*
*§Associated with eosinophilic granulomatosis with polyangiitis (Churg–Stauss syndrome).*

**eTable 19.3** *Continued* **Underlying causes of secondary cutaneous vasculitis.** ACE, angiotensin-converting enzyme; ATG, antithymocyte globulin; COX, cyclooxygenase; CSVV, cutaneous small vessel vasculitis; G-CSF, granulocyte colony-stimulating factor; HSP, Henoch–Schönlein purpura; SSRI, selective serotonin reuptake inhibitor. *List of associated drugs adapted from Lotti T, et al. J Am Acad Dermatol 1998;39:667 -87; ten Holder SM, et al. Ann Pharmacother 2002;36:130 -47; and Ortiz-Saniuan F, et al. J Rheumatol 2014;41:2201–7.*

| POSSIBLE ADDITIONAL DIAGNOSTIC TESTING FOR PATIENTS WITH SUSPECTED ANCA-ASSOCIATED VASCULITIDES | | | | | | | | |
|---|---|---|---|---|---|---|---|---|
| | **Chest X-ray and/or chest CT scan** | **Electromyogram/ nerve conduction studies** | **Lung, nerve or kidney biopsy** | **Upper respiratory tract or muscle biopsy** | **ECG, echocardiogram** | **CT scan of sinuses** | **Serum IgE level** | **Consider GI and ophthalmologic examination** |
| Microscopic polyangiitis | √ | √ | √ | | | | | |
| Granulomatosis with polyangiitis | √ | √ | √* | √* | √ | √ | | √ |
| Eosinophilic granulomatosis with polyangiitis | √ | √ | √ | | √ | √ | √ | √ |

**Depends upon signs and symptoms.*

**eTable 19.4 Possible additional diagnostic testing for patients with suspected ANCA-associated vasculitides.**

Downloaded for Novin lib (novinlibrary@yahoo.com) at United Arab Emirates University from ClinicalKey.com by Elsevier on March 26, 2022. For personal use only. No other uses without permission. Copyright ©2022. Elsevier Inc. All rights reserved.

| KEY DISORDERS IN THE DIFFERENTIAL DIAGNOSIS OF ANCA-ASSOCIATED VASCULITIDES AND THEIR DISTINGUISHING FEATURES | | |
|---|---|---|
| **ANCA-positive vasculitic syndrome** | **Disorder in differential diagnosis** | **Distinguishing features of the disorder in the differential diagnosis** |
| Microscopic polyangiitis | Eosinophilic granulomatosis with polyangiitis (Churg–Strauss syndrome) | • Eosinophilia<br>• Asthma and sinus disease<br>• Increased incidence of cardiac involvement |
| | Granulomatosis with polyangiitis (Wegener granulomatosis) | • Granulomatous inflammation<br>• Increased incidence of ocular and severe upper respiratory tract involvement |
| | Polyarteritis nodosa | • Absence of glomerulonephritis<br>• Lower incidence of pulmonary involvement<br>• Vasculitis of renal arteries rather than small vessel vasculitis<br>• Renovascular hypertension<br>• ANCA-negative |
| | Goodpasture syndrome | • Kidney-bound or circulating anti-glomerular basement membrane antibodies |
| | SLE or rheumatoid vasculitis | • Distinct rheumatologic serologies<br>• In SLE, develops in individuals with longstanding disease |
| Granulomatosis with polyangiitis (Wegener granulomatosis) | Eosinophilic granulomatosis with polyangiitis (Churg–Strauss syndrome) | • Eosinophilia<br>• Asthma<br>• Lower incidence of severe renal disease |
| | Microscopic polyangiitis | • Absence of granulomatous inflammation |
| | NK/T-cell lymphoma | • Destructive nasal midline lesion<br>• Characteristic histology |
| | Tuberculosis (lupus vulgaris), leprosy | • Destructive nasal midline lesion<br>• Characteristic histologic features and laboratory findings |
| | Cocaine-induced destructive nasal midline lesion | • By ELISA, ANCAs are positive for both human neutrophil elastase and proteinase 3<br>• Neutropenia |
| | Goodpasture syndrome, SLE, rheumatoid arthritis | • See above |
| Eosinophilic granulomatosis with polyangiitis (Churg–Strauss syndrome) | Microscopic polyangiitis | • No granulomatous inflammation<br>• No history of asthma<br>• No hypereosinophilia |
| | Granulomatosis with polyangiitis (Wegener granulomatosis) | • Increased incidence of glomerulonephritis<br>• Lower incidence of cardiac or peripheral nerve involvement |
| | Hypereosinophilia, secondary | • Due to medications, parasitic infections, allergic disease, malignancy |
| | Hypereosinophilic syndrome | • Pruritus, eczematous or urticarial eruptions, oral ulcerations, and angioedema |

**eTable 19.5 Key disorders in the differential diagnosis of ANCA-associated vasculitides and their distinguishing features.**

| THERAPEUTIC LADDER FOR PATIENTS WITH VASCULITIS | | | | | | |
|---|---|---|---|---|---|---|
| **Disorder** | **First-line treatment** | **Evidence levels** | **Second-line treatment** | **Evidence levels** | **Third-line treatment** | **Evidence levels** |
| Cutaneous small vessel vasculitis | Discontinue incriminated drugs<br>Supportive care<br>Treat underlying infections, neoplasms<br>NSAIDs<br>Antihistamines | 3<br>3 | Colchicine (0.6 mg BID–TID)<br>Dapsone (50–200 mg/day)<br>CS | 2<br>3<br>2<br>3 | AZA (2 mg/kg/day)<br>MYC<br>MTX<br>IVIg<br>CSA<br>CYC<br>Rituximab<br>PEX | 3<br>3<br>3<br>3<br>3<br>3<br>3<br>3 |
| Henoch–Schönlein purpura (including IgA vasculitis in adults) | Supportive care | | Dapsone<br>Colchicine<br>CS<br>AZA ± CS<br>CYC ± CS<br>CSA ± CS<br>Antihistamines | 2<br>3<br>1, 2<br>2<br>2<br>3 | IVIg<br>Rituximab<br>MYC<br>CS + tacrolimus<br>ACA<br>PEX<br>Factor XIII | 3<br>3<br>3<br>1, 2<br>3<br>2<br>2, 3<br>2 |
| Acute hemorrhagic edema of infancy | Supportive care | 3 | | | CS | 3 |
| Urticarial vasculitis | Antihistamines<br>Indomethacin<br>Dapsone (100–200 mg/day) ± pentoxifylline<br>CS | 3<br>3<br>2<br>2 | Colchicine (0.6 mg BID–TID)<br>Hydroxychloroquine (200–400 mg/day)<br>AZA<br>MTX | 2<br>2<br>2<br>2 | MYC<br>IVIg<br>Rituximab<br>CSA<br>PEX<br>Canakinumab<br>Tocilizumab<br>CYC | 2<br>3<br>2<br>3<br>3<br>1<br>3<br>2 |

**eTable 19.6 Therapeutic ladder for patients with vasculitis.** *Continued*

Downloaded for Novin lib (novinlibrary@yahoo.com) at United Arab Emirates University from ClinicalKey.com by Elsevier on March 26, 2022. For personal use only. No other uses without permission. Copyright ©2022. Elsevier Inc. All rights reserved.

Downloaded for Novin lib (novinlibrary@yahoo.com) at United Arab Emirates University from ClinicalKey.com by Elsevier on March 26, 2022. For personal use only. No other uses without permission. Copyright ©2022. Elsevier Inc. All rights reserved.

| THERAPEUTIC LADDER FOR PATIENTS WITH VASCULITIS | | | | | | |
|---|---|---|---|---|---|---|
| **Disorder** | **First-line treatment** | **Evidence levels** | **Second-line treatment** | **Evidence levels** | **Third-line treatment** | **Evidence levels** |
| Erythema elevatum diutinum | NSAIDs<br>Intralesional CS<br>Dapsone | 3<br>3<br>3 | Colchicine<br>Chloroquine<br>Tetracyclines | 3<br>3<br>3 | Niacinamide<br>PEX | 3<br>3 |
| Cryoglobulinemic vasculitis (+ HCV) | Peginterferon–ribavirin ± telaprevir or boceprevir; sofosbuvir/ledipasvir*<br>CS | 1, 2<br>3 | CS + CYC | 3 | IVIg<br>Rituximab (± ribavirin, IFN)<br>PEX | 3<br>2<br>3 |
| Cutaneous polyarteritis nodosa | Treat underlying infections<br>Discontinue incriminated drugs<br>NSAIDs<br>CS (topical, intralesional or oral) | 3<br>2 | MTX (7.5–15 mg/wk)<br>Dapsone/sulfapyridine<br>IVIg<br>HCQ | 3<br>3<br>3<br>3 | Pentoxifylline<br>Colchicine<br>AZA or MYC<br>TNF-α inhibitors<br>Warfarin | 3<br>3<br>3<br>3<br>3 |
| Classic polyarteritis nodosa (+ HBV) | CS<br>CS + PEX + IFN/lamivudine** | 2<br>2 | CS + CYC | 2 | IVIg | 3 |
| Microscopic polyangiitis | CS<br>CS + rituximab ± CYC | 3<br>1 | CS + CYC<br>MTX | 3<br>3 | AZA<br>MYC<br>IVIg<br>Rituximab<br>Infliximab | 2<br>3<br>3<br>3<br>3 |
| Granulomatosis with polyangiitis (Wegener granulomatosis) (to induce remission in limited disease) | CS + MTX | 1 | TMP–SMX (± CS) | 2 | | |

**eTable 19.6** *Continued* **Therapeutic ladder for patients with vasculitis.** *Continued*

| THERAPEUTIC LADDER FOR PATIENTS WITH VASCULITIS | | | | | | |
|---|---|---|---|---|---|---|
| **Disorder** | **First-line treatment** | **Evidence levels** | **Second-line treatment** | **Evidence levels** | **Third-line treatment** | **Evidence levels** |
| Granulomatosis with polyangiitis (Wegener granulomatosis) (to induce remission in generalized disease) | CS + CYC (pulse)<br>CS + rituximab ± CYC<br>CS + rituximab | 1<br>1, 2<br>1, 2 | CS + CYC + PEX (if severe renal disease, may be first line) | 1 | MYC | 3 |
| | | | | | IVIg | 3 |
| | | | | | PEX | 3 |
| | | | | | Infliximab | 2 |
| | | | | | T-cell depletion | 3 |
| | | | | | Alemtuzumab | 3 |
| Granulomatosis with polyangiitis (Wegener granulomatosis) (to maintain remission) | CS + AZA<br>CS + MTX<br>CS + rituximab | 1<br>1<br>1, 2 | CS + CYC<br>TMP-SMX | 2<br>1 | MYC | 2 |
| | | | | | AZA or MTX | 3 |
| | | | | | Leflunomide | 3 |
| Eosinophilic granulomatosis with polyangiitis (Churg–Strauss syndrome) | CS | 2 | CS + CYC (first line in severe disease) | 3 | Mepolizumab | 1 |
| | | | | | IVIg ± PEX | 2 |
| | | | | | Rituximab | 3 |
| | | | | | AZA | 2 |
| | | | | | MYC | 3 |
| | | | | | MTX | 3 |
| | | | | | IFN-α | 3 |

**Long-term control of HCV-associated mixed cryoglobulinemia can only be achieved via a treatment regimen that incorporates anti-hepatitis C viral therapy. Additional regimens for HCV infection include ritonavir-enhanced paritaprevir + ombitasvir and dasabuvir or sofosbuvir/velpatasvir + ribavirin.*
***Newer antiviral agents such as tenofovir, entecavir, and telbivudine are currently under investigation.*

**eTable 19.6** *Continued* **Therapeutic ladder for patients with vasculitis.** Key to evidence-based support: (1) prospective controlled trial; (2) retrospective study or large case series; (3) small case series or individual case reports. ACA, aminocaproic acid; AZA, azathioprine; CSA, cyclosporine; CYC, cyclophosphamide; HBV, hepatitis B virus; HCV, hepatitis C virus; IFN, interferon; MTX, methotrexate; MYC, mycophenolate mofetil; PEX, plasmapheresis; TMP-SMX, trimethoprim–sulfamethoxazole.

Downloaded for Novin lib (novinlibrary@yahoo.com) at United Arab Emirates University from ClinicalKey.com by Elsevier on March 26, 2022. For personal use only. No other uses without permission. Copyright ©2022. Elsevier Inc. All rights reserved.

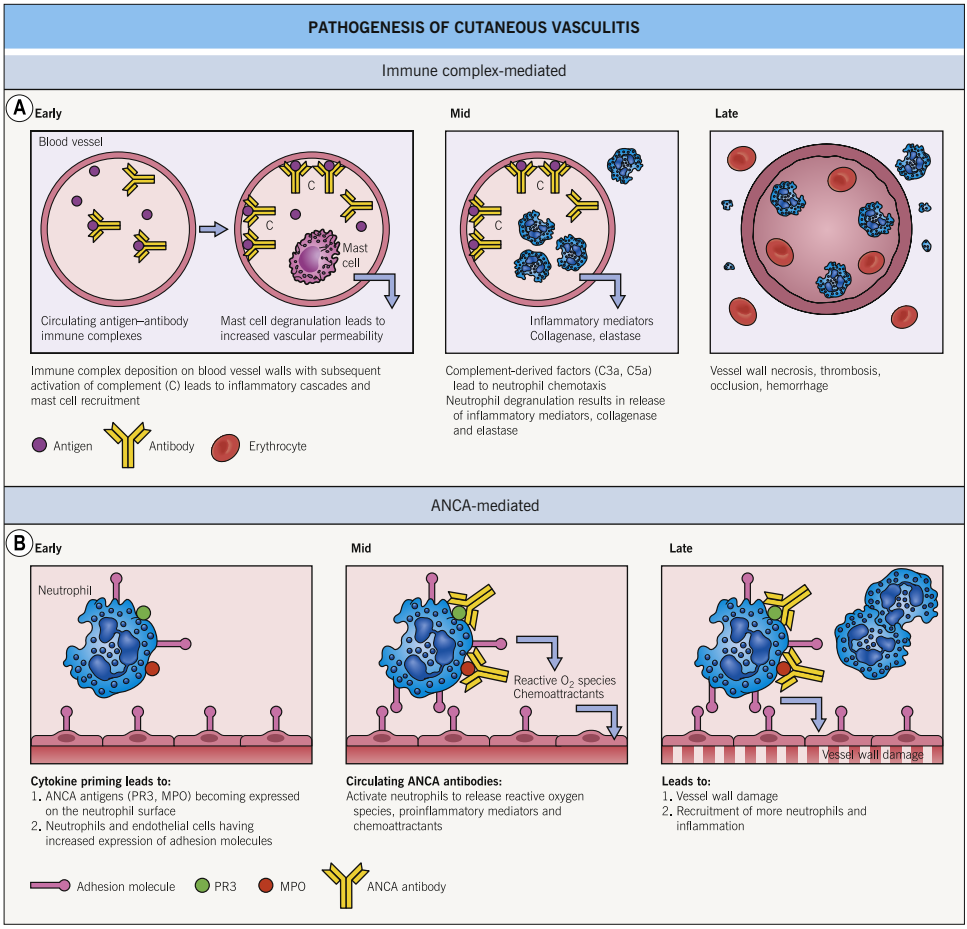


**eFig. 19.1 Pathogenesis of cutaneous vasculitis – immune complex- versus ANCA-mediated.** **A** In immune complex-mediated vasculitis, circulating antigens (e.g. infectious agents, medications, neoplasms) induce antibody formation. Binding of antibodies to circulating antigens creates immune complexes. Immune complex deposition within postcapillary venules activates complement and subsequently leads to an increase in adhesion molecule expression on the endothelium. Complement split products (C3a and C5a) induce mast cell degranulation and neutrophil chemotaxis. Mast cell degranulation leads to increased vascular dilation and permeability, enhancing immune complex deposition and leukocyte tethering to endothelium. Increased adhesion between inflammatory cells (especially neutrophils) and the endothelium is mediated by elevated expression of selectins (E-selectin, P-selectin) and members of the immunoglobulin superfamily (ICAM-1, VCAM-1, PECAM-1) on endothelial cells in concert with the upregulation of their corresponding ligands and receptors/adhesion molecules on leukocytes (e.g. P-selectin glycoprotein ligand-1, LFA-1, Mac-1). Neutrophils release proteolytic enzymes (such as collagenases and elastases) and free oxygen radicals that damage the vessel wall. In addition, formation of the membrane attack complex (C5–C9) on the endothelium leads to the activation of the clotting cascade and the release of cytokines and growth factors with ensuing thrombosis, inflammation and angiogenesis. **B** In ANCA-mediated vasculitis, following primary activation by cytokines such as TNF, intracellular proteins from neutrophils (e.g. proteinase 3 [PR3], myeloperoxidase [MPO]) become expressed on the cell surface. After formation of ANCA that recognize these antigens, binding of the autoantibodies to neutrophils leads to increased neutrophil adhesion to vessel walls and subsequent cellular activation. Neutrophils then release reactive oxygen species and other toxic mediators that result in vessel wall damage (see **A**). Because the vessel damage in ANCA-positive vasculitides is directly mediated by neutrophils rather than by immune complexes, they are referred to as “pauci-immune” vasculitides. Formation of ANCA may be related to an impairment in neutrophil apoptosis which results in a prolonged opportunity for autoantibody development.



**eFig. 19.2 Cutaneous small vessel vasculitis.** Early lesions may be erythematous rather than purpuric. *Courtesy, NYUDSC.*



**eFig. 19.3 Cutaneous small vessel vasculitis associated in a patient with relapsing polychondritis and myelodysplasia.** *Courtesy, Jean L. Bolognia, MD.*

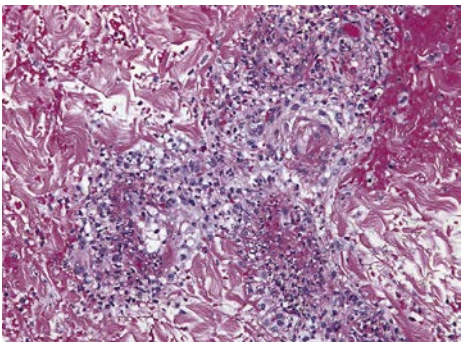

**eFig. 19.4 Cutaneous small vessel vasculitis – histopathologic features.** Angiocentric segmental inflammation with endothelial swelling, a neutrophilic infiltrate with leukocytoclasia, red blood cell extravasation, and fibrinoid necrosis of blood vessel walls. The neutrophils are present around and within the walls of the small dermal blood vessels. *Courtesy, David F. Fiorentino, MD.*



**eFig. 19.5 Henoch–Schönlein purpura.** More developed lesions with central necrosis. *Courtesy, YDRSC.*

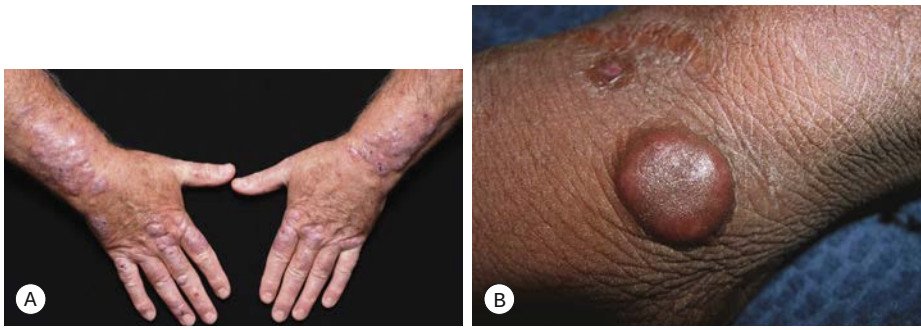


**eFig. 19.6 Erythema elevatum diutinum. A** Symmetrically distributed, dull pink to violet-brown nodules and plaques on the extensor forearms and dorsal hands. **B** Firm nodule on the dorsum of the hand in a patient with HIV infection, representing a late-stage lesion. *B, Courtesy, David Wetter, MD, and Jan Dutz, MD; C, Courtesy, Rachel Moore, MD.*

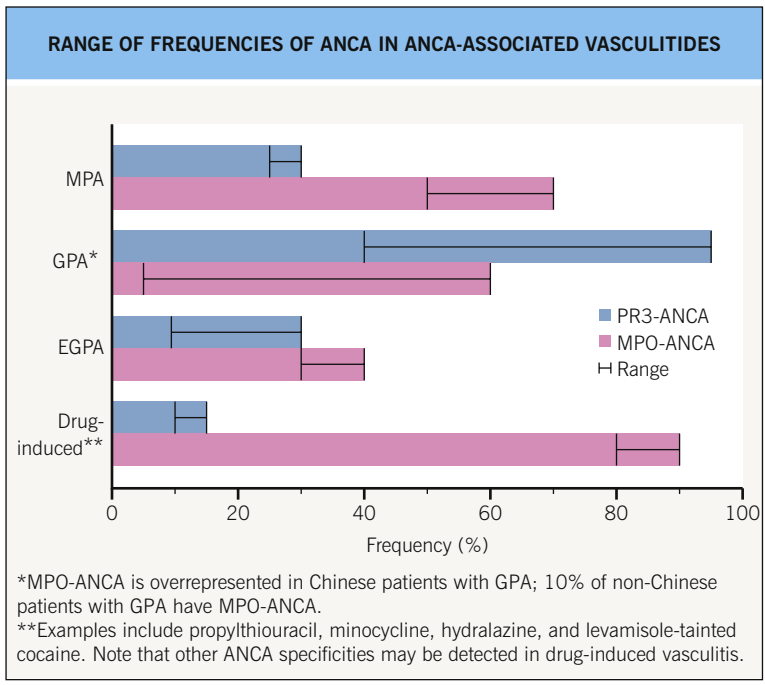


**eFig. 19.7 Range of frequencies of ANCA in ANCA-associated vasculitides.** Variability reflects differences in cohorts studied, disease extent and severity at time of assays, diagnostic criteria, and cutoff values of various ANCA assays. Negative ANCA testing does not exclude the presence of an ANCA-associated vasculitis, as overall frequencies for ANCA positivity are 90% (generalized GPA), 60% (limited GPA), 70% (MPA), and 50% (EGPA), respectively. EGPA, eosinophilic granulomatosis with polyangiitis; GPA, granulomatosis with polyangiitis; MPA, microscopic polyangiitis; MPO, myeloperoxidase; PR3, proteinase 3. *Adapted from Wiik AS. Rheum Dis Clin NA 2010;36:479–89.*

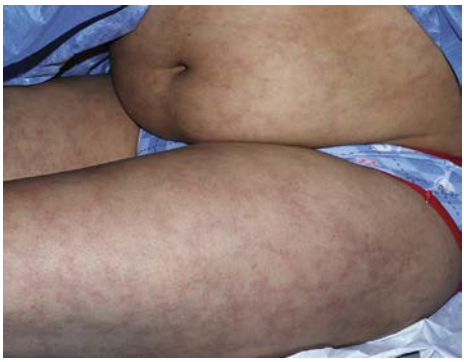

**eFig. 19.8 Cutaneous polyarteritis nodosa (PAN).** Livedo reticularis of the lower extremities and abdomen in an adolescent. *Courtesy, Julie V. Schaffer, MD.*

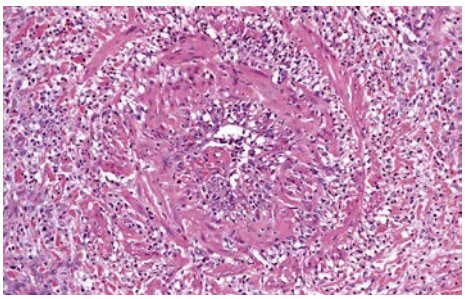

**eFig. 19.9 Cutaneous polyarteritis nodosa – histologic features.** Vasculitis of a medium-sized vessel situated deep in the dermis. Neutrophils, neutrophilic debris, and fibrin within the arteriolar wall are seen. *Courtesy, Lorenzo Cerroni, MD.*



**eFig. 19.10 Temporal arteritis.** Two ulcerations of the scalp in association with alopecia and scarring in an elderly patient. *Courtesy, Steve Feldman, MD.*

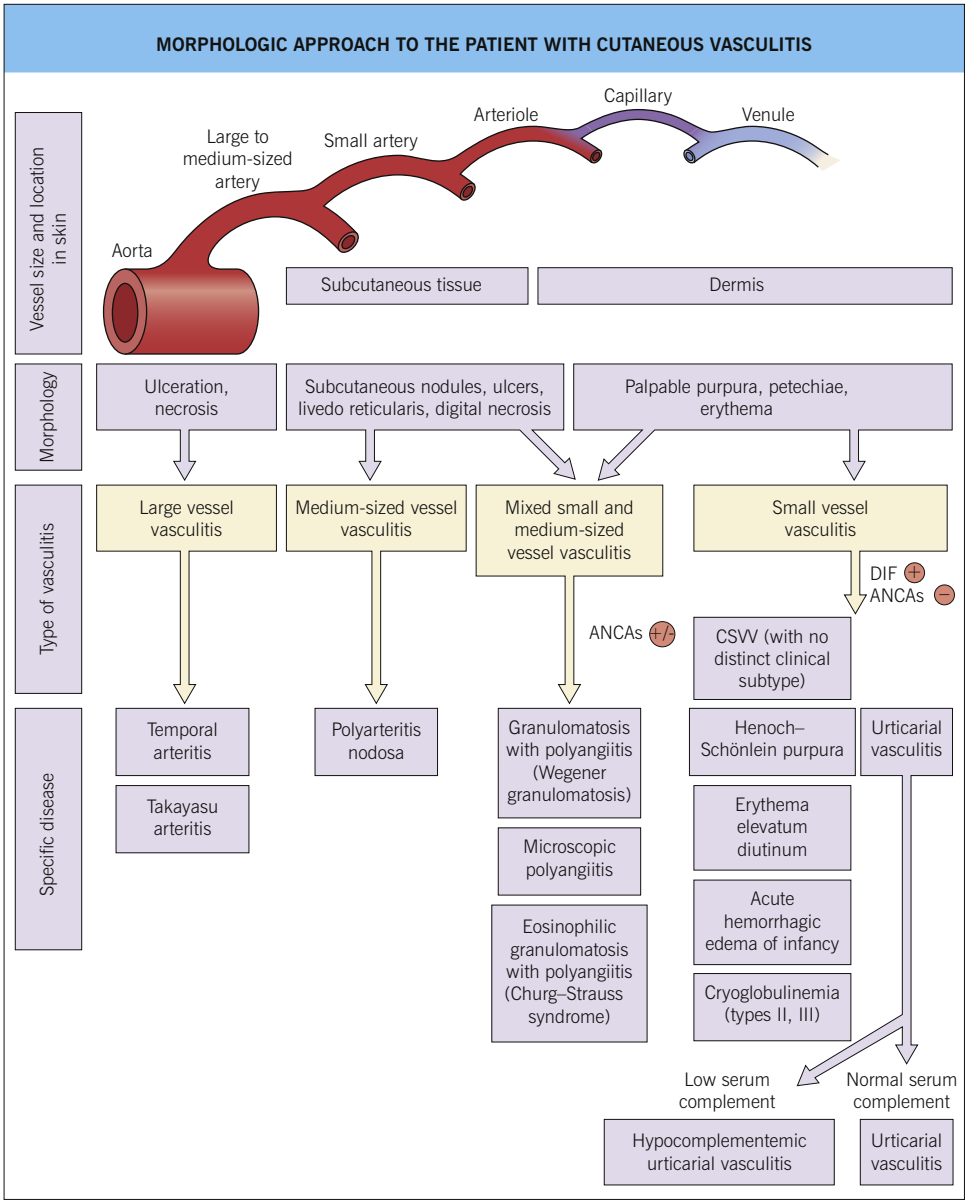


**eFig. 19.11 Morphologic approach to the patient with suspected cutaneous vasculitis.** DIF, direct immunofluorescence.

# Eosinophilic Dermatoses

# 20

As with the group of disorders known as neutrophilic dermatoses, there is significant overlap in the cutaneous findings of entities where eosinophils play a role – from papular urticaria triggered by arthropod bites to Wells syndrome and hypereosinophilic syndrome (Fig. 20.1; Table 20.1). The exception is granuloma faciale, which has a more specific presentation.

## Granuloma Faciale

- Idiopathic disorder characterized by one or more persistent red-brown to violet-brown plaques on the face (Fig. 20.2); prominent follicular openings are often noted and a third of patients have multiple plaques.
- Most commonly occurs in middle-aged adults, and extrafacial involvement is unusual (<10% of patients).
- The clinical diagnosis is confirmed via histopathology where eosinophils, neutrophils, and lymphocytes are seen in the dermis.
- **DDx:** sarcoidosis, foreign body granuloma, granulomatous rosacea, and other entities that lead to persistent red to red-brown plaques of the face (see Fig. 99.2).
- **Rx:** often difficult; intralesional CS, topical calcineurin inhibitors, cryosurgery, vascular lasers.

## Exaggerated Insect Bite and Insect Bite-Like Reactions (Eosinophilic Dermatosis Associated with Hematologic Disorders/ Malignancies)

- Lesions may occur at sites of known insect bites but a history of bites may be lacking, hence the term insect bite-like reaction; presents as pruritic, erythematous, edematous papulonodules and vesiculobullae.
- The most common associated systemic disorder is chronic lymphocytic leukemia, but these reactions can also be seen in patients with other lymphoproliferative as well as myeloproliferative disorders (see Table 99.2) and at sites of mosquito bites in those with EBV-associated NK/T-cell lymphoproliferative disorders.

## Papuloerythroderma of Ofuji

- Widespread red-brown papules that coalesce into an erythroderma with sparing of skin folds ("deck-chair" sign), often with peripheral eosinophilia; primarily elderly men, frequently Japanese.
- Usually idiopathic, but occasionally there is an underlying lymphoma (especially T-cell) or carcinoma (most commonly gastric).
- **DDx:** other causes of erythroderma (see Ch. 8).

## Wells Syndrome (Eosinophilic Cellulitis)

- Recurrent burning, pruritic or painful pink to red plaques that are often edematous, thus resembling infectious cellulitis; over time the lesions may become more infiltrative (Fig. 20.3).
- As the plaques and nodules spontaneously fade over a period of 1–2 months, a residual brown to gray or even green color may be seen.
- Associated symptoms include malaise and occasionally fever; peripheral eosinophilia is common.
- Unknown etiology; the possibility of triggers such as arthropod bites, parasitic infections (e.g. toxocariasis), or an underlying myeloproliferative disorder is a matter of debate.
- Within the dermis, there is a discharge of the granular contents of eosinophils, which then coat collagen fibers and lead to the formation of "flame figures"; the latter can also be seen in other disorders in which there are numerous eosinophils in the skin.

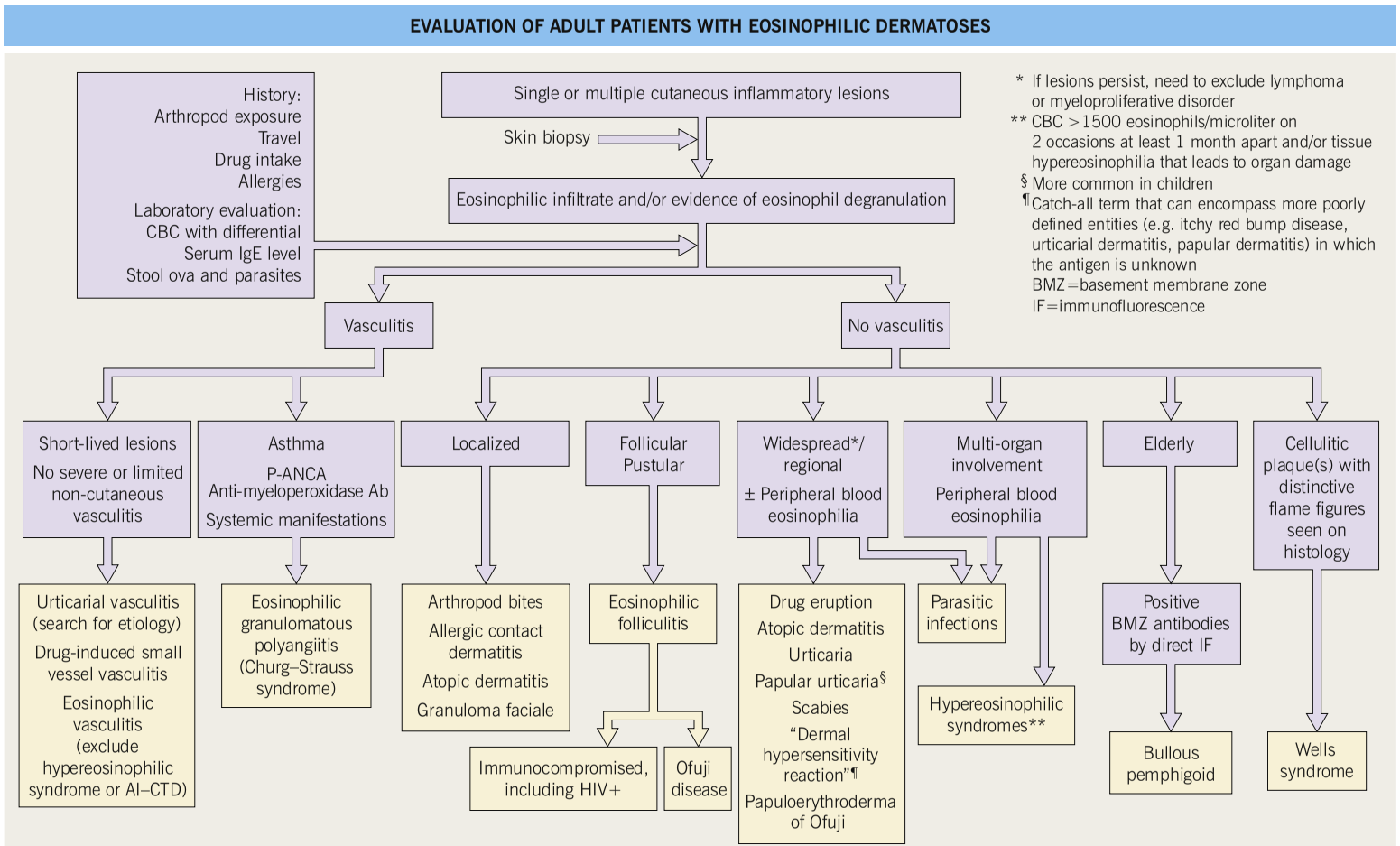


**Fig. 20.1 Evaluation of adult patients with eosinophilic dermatoses.** Histologically, these dermatoses are characterized by a prominent eosinophilic infiltrate and/or eosinophil granule protein deposition. Of note, systemic corticosteroids can significantly reduce the peripheral blood eosinophil count.

| OTHER DISORDERS WHERE EOSINOPHILS PLAY A ROLE |
|---|
| • Parasitic infections (e.g. larva migrans, onchocerciasis, gnathostomiasis, strongyloidiasis) |
| • Seabather's eruption – after ocean swimming, pruritic papules in distribution of swimsuit; due to larvae of either jellyfish (*Linuche unguiculata*) or sea anemones (*Edwardsiella lineata*) |
| • Pruritic papular eruption of HIV disease – nonfollicular pruritic papules |
| • Polymorphic eruption of pregnancy (also referred to as PUPPP) – urticarial plaques with involvement of striae and periumbilical sparing; pregnant women (third trimester, postpartum) |
| • Pemphigoid gestationis – urticarial plaques and vesicles similar to bullous pemphigoid; pregnant women |
| • Angiolymphoid hyperplasia with eosinophilia (epithelioid hemangioma) – nodules of the head and neck; adults |
| • Langerhans cell histiocytosis (see Ch. 76) |
| **Limited to neonates or infants** |
| • Erythema toxicum neonatorum – papules and pustules with erythematous flare; neonates |
| • Incontinentia pigmenti (stages I and II) – linear streaks of vesicles and keratotic papules along the lines of Blaschko |
| • Infantile eosinophilic folliculitis – recurrent crops of pruritic follicular papules and pustules, primarily of the head and neck |

**Table 20.1 Other disorders where eosinophils play a role (in addition to those listed in Fig. 20.1).** PUPPP, pruritic urticarial papules and plaques of pregnancy.




**Fig. 20.2 Granuloma faciale.** Red-brown plaques on the lateral cheek **(A)** and nose **(B)**. Note the prominent follicular openings. *A, Courtesy, YDRSC; B, Courtesy, Cloyce L. Stetson, MD.*

• **DDx:** infectious cellulitis (edematous lesions), exaggerated arthropod reactions (see above), parasitic infections, and other causes of pseudocellulitis (see Table 61.2).
• **Rx:** systemic CS; occasionally steroid-sparing agents are needed.

## Hypereosinophilic Syndrome

• Classically defined as peripheral eosinophilia (>1500 eosinophils/microliter) on two occasions at least one month apart and/or tissue hypereosinophilia leading to multi-organ involvement, but in the absence of an identifiable cause (Table 20.2).
• Divided into major forms: (1) primary (neoplastic) – characterized by specific mutations, in particular the *FIP1L1-PDGFRA* fusion gene, that lead to a clonal proliferation of eosinophils, with a male predominance, and endomyocardial disease; and (2) secondary (reactive) – characterized by a


ALGrawany

cytokine-driven hypereosinophilia due to an underlying inflammatory or neoplastic disorder (e.g. lymphoma). In the lymphocytic (lymphoid) subtype, clonal T cells produce Th2 cytokines, e.g. IL-5, which activate eosinophils.

- Mucocutaneous lesions are seen in at least 50% of patients and include nonspecific pruritic erythematous papules and nodules, urticaria, angioedema, dermatitis, erythroderma, and in the myeloproliferative form, mouth or anogenital ulcers; thromboses can lead to retiform purpura.
- **DDx:** with the exception of granuloma faciale and eosinophilic folliculitis, the entities outlined in Fig. 20.1; several of the entities in Table 20.1, in particular parasitic infections; hereditary and acquired angioedema; for lymphoproliferative form, cutaneous T-cell lymphoma; if oral ulcers, oral aphthae.
- **Rx:** *FIP1L1-PDGFRA*-positive myeloproliferative form – imatinib, other tyrosine kinase inhibitors (e.g. nilotinib); lymphoproliferative form – systemic CS ± mepolizumab (anti-IL-5 monoclonal antibody).



**Fig. 20.3 Wells syndrome.** Edematous and infiltrated nodules and plaques. *Courtesy, NYUDSC.*

**DIAGNOSTIC CRITERIA AND CLASSIFICATION OF HYPEREOSINOPHILIC SYNDROMES (HES)**

**Diagnostic criteria**

- Peripheral blood eosinophil counts >1500/microliter ($1.5 \times 10^9$/L) on two occasions at least one month apart *and/or* major tissue hypereosinophilia (includes marked deposition of eosinophil granule proteins, >20% eosinophils in bone marrow biopsy)
- Organ damage and/or dysfunction attributable to tissue hypereosinophilia
- Exclusion of other disorders or conditions as major reasons for organ damage (e.g. parasitic infection, drug hypersensitivity reaction, primary immunodeficiency [see Ch. 49])

**Subtypes**

| *Primary (neoplastic) HES* | *Secondary (reactive) HES* | *Other syndromes†* |
|---|---|---|
| • Underlying neoplasm of stem cells, myeloid cells or eosinophils<br>• Eosinophils are considered (or shown) to be clonal*<br>• Male predominance, endomyocardial disease; mucosal ulcers poor prognostic sign<br>• Some patients have high serum tryptase and vitamin $B_{12}$ levels, tissue fibrosis, splenomegaly, and bone marrow biopsies with increased numbers of $CD25^+$ atypical spindle-shaped mast cells (see Table 96.1) | • Underlying inflammatory or neoplastic disorder<br>• Hypereosinophilia is cytokine-driven rather than due to clonal proliferation of eosinophils<br>• In the lymphocytic (lymphoid) subtype, clonal T cells produce Th2 cytokines, e.g. IL-5<br>*Idiopathic HES*<br>• No identified reactive or neoplastic disorder that induces hypereosinophilia | • Episodic angioedema with eosinophilia (EAE; Gleich syndrome)<br>• *N*odules, *e*osinophilia, *r*heumatism, *d*ermatitis, and swelling (NERDS) syndrome<br>• IgG4-related diseases<br>• Eosinophilic granulomatosis with polyangiitis |

**FIP1L1-PDGFRA fusion gene and other rarer fusion genes or rearrangements involving PDGFRB or FGR1, which encode platelet-derived growth factor receptor-β and fibroblast growth factor receptor-1, respectively; included patients with eosinophilic leukemia who may have other cytogenetic abnormalities.*
*†List is not exhaustive.*

**Table 20.2 Diagnostic criteria and classification of hypereosinophilic syndromes (HES).**

For further information see Ch. 25 from *Dermatology, Fourth Edition*.

**For additional online figures visit www.expertconsult.com**



**eFig. 20.1 Granuloma faciale presenting with multiple red-brown plaques on the face.** *Courtesy, Jeffrey Callen, MD.*



**eFig. 20.2 Exaggerated insect bite-like reactions in a patient with chronic lymphocytic leukemia.** There are multiple vesicles and hemorrhagic crusts on an inflammatory base. *Courtesy, José M Mascaró, Jr, MD.*

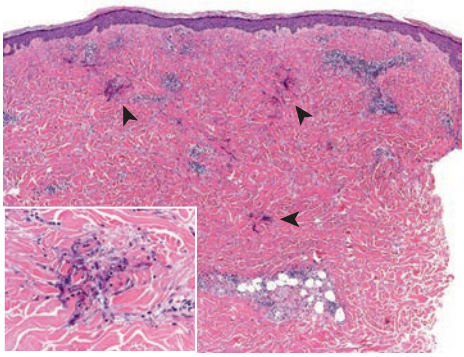

**eFig. 20.3 Wells syndrome – histopathologic features.** Perivascular and interstitial inflammatory infiltrates that contain eosinophils. There are several flame figures at sites of degranulated eosinophils (arrowheads; inset). *Courtesy, Lorenzo Cerroni, MD.*

# Neutrophilic Dermatoses 21

This group of disorders, in an untreated state, is characterized by infiltrates of neutrophils within the skin. In addition, these dermatoses lack an identifiable infectious etiology, despite the presence of neutrophils (Fig. 21.1). There can be significant overlap in the clinical presentations of the neutrophilic dermatoses; for example, in a patient with acute myelogenous leukemia, bullous pyoderma gangrenosum may be difficult to distinguish from Sweet syndrome. In addition, infiltrates of neutrophils can occur in other organs, particularly the joints, eyes, lungs, and bones. Bone involvement raises the possibility of SAPHO (*s*ynovitis, *a*cne, *p*ustulosis, *h*yperostosis, *o*steitis) syndrome.

## Sweet Syndrome (Acute Febrile Neutrophilic Dermatosis)

- Acute onset of erythematous edematous papules and plaques that are tender, but not pruritic; if the edema is intense, the lesions may become bullous and, occasionally, they resemble erysipelas; favored sites are the face, neck, upper trunk, and upper extremities (Fig. 21.2).
- Less commonly, nodules develop due to neutrophilic panniculitis or pustules form within the plaques; a variant occurs on the dorsal aspect of the hands and is referred to as "neutrophilic dermatosis of the dorsal hands" (Fig. 21.3).
- Associated systemic findings include fever, malaise, and arthralgias, and a peripheral leukocytosis is commonly observed (Table 21.1); some patients also develop systemic manifestations, including ocular, pulmonary, and skeletal involvement (Fig. 21.4, Table 21.2).
- Most often seen in adults, with a female:male ratio of 4:1 (except in the case of malignancy-associated disease); may first appear or flare during pregnancy; idiopathic in up to 50% of patients.
- Underlying disorders include: (1) *infections* – upper respiratory tract (e.g. viral, streptococcal) or gastrointestinal (e.g. yersiniosis) > HIV or atypical mycobacteria; (2) *hematologic malignancies* (10–20% of patients), particularly acute myelogenous leukemia (AML) but also myelodysplasia and myeloproliferative disorders; (3) *inflammatory bowel disease*; (4) *autoimmune connective tissue disease*, particularly systemic lupus erythematosus (SLE); (5) *drugs* – G-CSF, all-*trans*-retinoic acid > furosemide, minocycline; and (6) *carcinomas* – genitourinary, breast, colon.
- The vesiculobullous form is more often associated with AML, and in malignancy-associated Sweet syndrome, the lesions tend to be more widespread, including within the oral cavity.
- Histologically, diffuse infiltrates of neutrophils are seen within the dermis and occasionally the subcutaneous fat; leukocytoclastic vasculitis is absent or minimal. The infiltrate may include immature myeloid cells that resemble histiocytes.
- **DDx:** bullous pyoderma gangrenosum, neutrophilic eccrine hidradenitis, erysipelas, erythema multiforme, causes of pseudocellulitis (see Table 61.2), infectious cellulitis, vasculitis (urticarial, small vessel, septic), halogenoderma, autoinflammatory diseases, as well as additional entities in Fig. 21.1.
- There are differing opinions regarding whether the development of a non-bullous neutrophilic dermatosis in the setting of LE is a distinct entity or is simply Sweet syndrome associated with LE.
- **Rx:** usually spontaneously resolves over a few months, but may recur in up to 30% to 50% of patients with idiopathic versus malignancy-associated disease, respectively;

Downloaded for Novin lib (novinlibrary@yahoo.com) at United Arab Emirates University from ClinicalKey.com by Elsevier on March 26, 2022. For personal use only. No other uses without permission. Copyright ©2022. Elsevier Inc. All rights reserved.

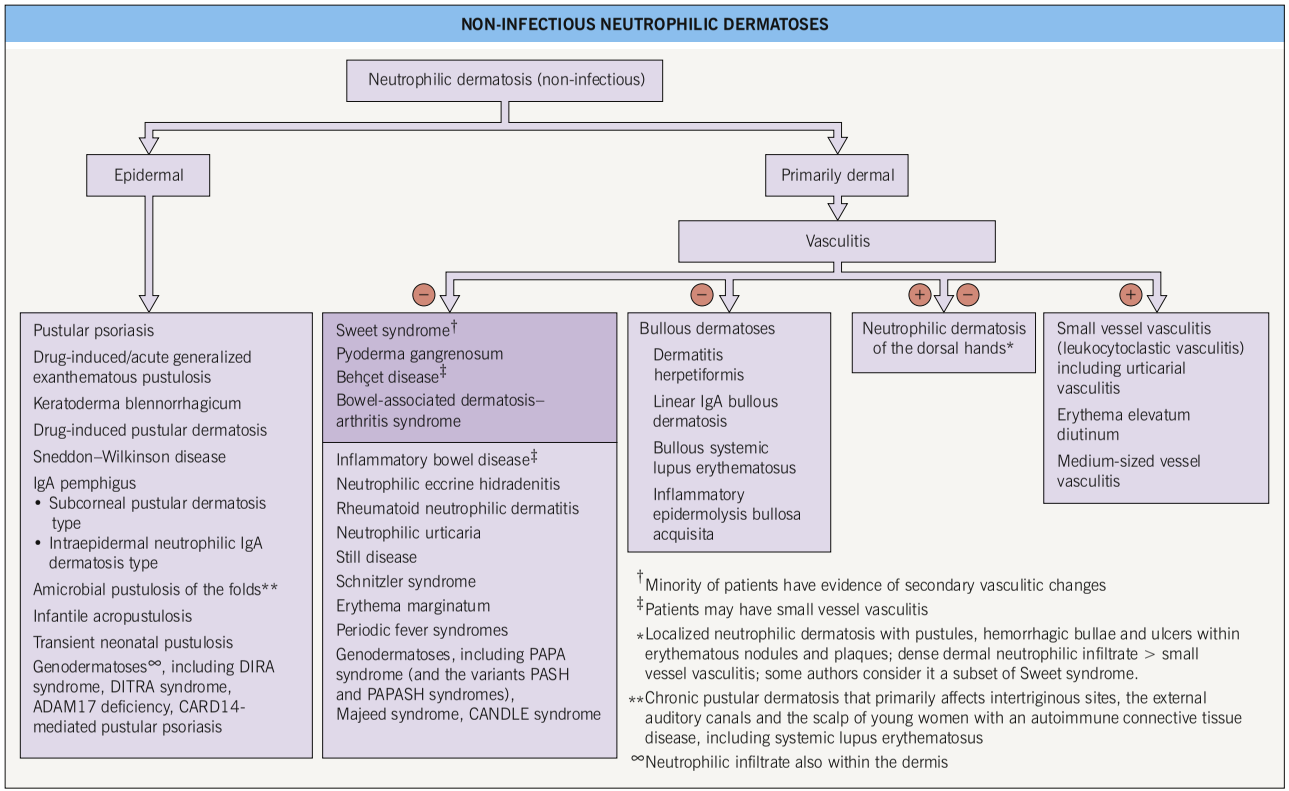


**Fig. 21.1 Non-infectious neutrophilic dermatoses.** Entities in the darker box are discussed in this chapter. CANDLE, chronic atypical neutrophilic dermatosis with lipodystrophy and elevated temperature; DIRA, deficiency of interleukin-1 receptor antagonist; DITRA, deficiency of the IL-36R antagonist; PAPA, pyogenic arthritis, pyoderma gangrenosum, and acne; PAPASH, pyogenic arthritis, pyoderma gangrenosum, acne, and suppurative hidradenitis; PASH, pyoderma gangrenosum, acne, and suppurative hidradenitis.

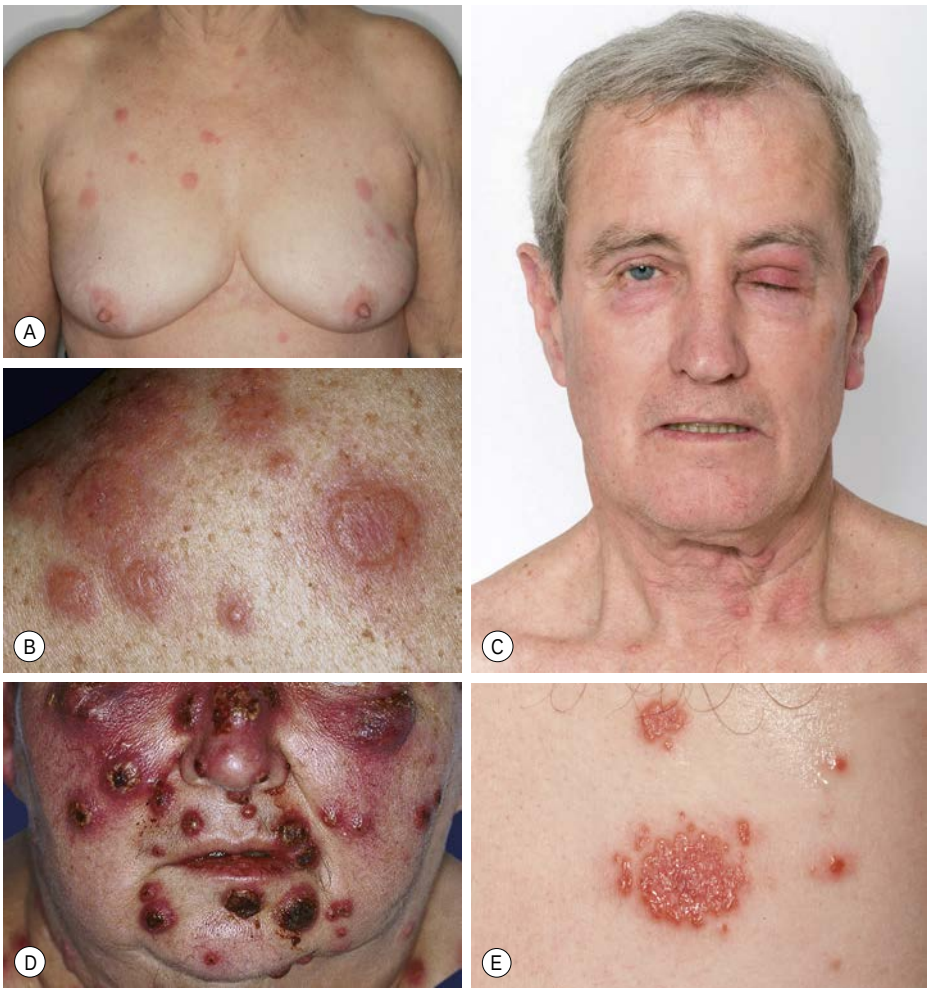


**Fig. 21.2 Spectrum of cutaneous findings in Sweet syndrome.** **A** Scattered edematous pink papules and plaques on the chest. **B** Markedly edematous plaques on the upper back, some of which are pseudovesicular while others are becoming bullous. **C** The periocular lesion demonstrates how some lesions can mimic cellulitis (pseudocellulitis). This patient also had neutrophilic esophageal ulcerations and subsequently developed colon cancer. **D** Central hemorrhagic crusts within facial plaques. **E** Plaques can also have a pseudomammillated appearance due to the associated edema. *A, C, Courtesy, Mark Davis, MD; B, D, Courtesy, Kalman Watsky, MD; E, Courtesy, Mark Davis, MD.*

antimicrobials for any underlying infection such as streptococcal pharyngitis; for moderate to severe disease, systemic CS (e.g. prednisone 0.5–1 mg/kg/day tapered over several months), dapsone, potassium iodide; for milder disease, ultrapotent topical CS and NSAIDs.

## Pyoderma Gangrenosum (PG)

- The most common presentation is a painful, rapidly enlarging ulcer of the lower extremity with a gray-violet, undermined, necrotic border; there is often a peripheral rim of erythema, and the base of the ulcer may be purulent (Fig. 21.5).
- Ulcers can occur at other sites, including the face, upper extremities, and trunk, as well as peristomally (Fig. 21.6); once partially treated, the ulcer may lose some of its characteristic features.
- Lesions can begin as an inflammatory papulopustule (which may be follicular), as a bulla on a violaceous base, or at the site of trauma



**Fig. 21.3 Neutrophilic dermatosis of the dorsal hands.** Clinically and histologically, there is overlap with Sweet syndrome and bullous pyoderma gangrenosum. *Courtesy, Mark Davis, MD.*

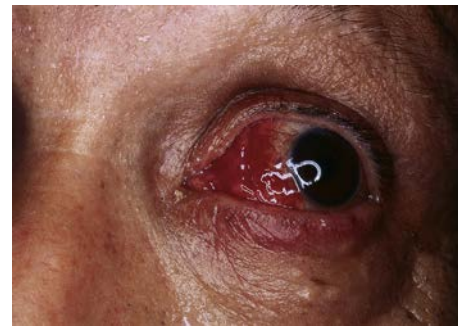

**Fig. 21.4 Ocular involvement in Sweet syndrome.** Erythema and hemorrhage of the sclera and conjunctiva. *Courtesy, Kalman Watsky, MD.*

| CRITERIA FOR THE DIAGNOSIS OF SWEET SYNDROME |
|---|
| **Major criteria** |
| 1. Abrupt onset of typical cutaneous lesions<br>2. Histopathology consistent with Sweet syndrome |
| **Minor criteria** |
| 1. Preceded by one of the associated infections or vaccinations; accompanied by one of the associated malignancies or inflammatory disorders; associated with drug exposure or pregnancy<br>2. Presence of fever and constitutional signs and symptoms<br>3. Leukocytosis<br>4. Excellent response to systemic corticosteroids |

**Table 21.1 Criteria for the diagnosis of Sweet syndrome.** Both of the major criteria and two of the minor criteria are needed for the diagnosis. *From Su WPD, Liu HNH. Diagnostic criteria for Sweet syndrome. Cutis 1986;37:167–174.*

| SYSTEMIC MANIFESTATIONS OF SWEET SYNDROME |
|---|
| **Common (≥50%)**<br>• Fever<br>• Leukocytosis |
| **Less common (20–50%)**<br>• Arthralgias<br>• Arthritis: asymmetric, non-erosive, sterile, favors knees and wrists<br>• Myalgias<br>• Ocular involvement: conjunctivitis, episcleritis, limbal nodules, iridocyclitis |
| **Uncommon**<br>• Neutrophilic alveolitis: cough, dyspnea, and pleurisy; radiographic findings include interstitial infiltrates, nodules, pleural effusions<br>• Multifocal sterile osteomyelitis, a subtype of SAPHO syndrome<br>• Renal involvement (e.g. mesangial glomerulonephritis): hematuria, proteinuria, renal insufficiency, acute renal failure |
| **Unusual/rare**<br>• Acute myositis<br>• Hepatitis, pancreatitis, ileitis, colitis<br>• Aseptic meningitis, encephalitis, bilateral sensorineural hearing loss<br>• Other: aortitis, oral aphthae, pharyngitis, pharyngeal edema |

**Table 21.2 Systemic manifestations of Sweet syndrome.** SAPHO, synovitis, acne, pustulosis, hyperostosis, osteitis.




**Fig. 21.5 Classic ulcerative pyoderma gangrenosum. A,B** The ulcers have an undermined and overhanging violet-gray edge surrounded by a violaceous border; a peripheral erythematous rim is also present in **A**. **C** In addition to an overhanging border, this deep ulceration on the elbow has a purulent base. **D** Central ulceration surrounded by inflammatory papules and pustules. **E** Centrally, there is healing with cribriform (sievelike) scarring. *A, B, E, Courtesy, Mark Davis, MD; C, D, Courtesy, YDRSC.*

(pathergy) (Fig. 21.7); in some patients, especially those with underlying inflammatory bowel disease and/or arthritis, the ulcers may expand more slowly with significant granulation tissue in their bases; healing of PG ulcers often leads to a distinctive cribriform pattern of scarring (Fig. 21.5E).

- There are several clinical variants of PG and they are outlined in Table 21.3; the diagnosis of PG requires clinicopathologic correlation and exclusion of other entities in the **DDx** (Tables 21.4 and 21.5).
- Although idiopathic in up to 50% of patients, the age distribution of PG tends to reflect the major underlying disorders, which are: (1) *inflammatory bowel disease*, either ulcerative colitis or Crohn disease (20–30% of patients); (2) *inflammatory arthritis*, including rheumatoid and seronegative (20%); (3) *plasma cell dyscrasias*, particularly an IgA monoclonal gammopathy (up to 15%); and (4) *other hematologic malignancies*, particularly AML, as well as myelodysplasia, chronic myelogenous leukemia, and hairy cell leukemia; the underlying disorder may be antecedent, coincident, or subsequent.
- PG is included in a few rare syndromes that have various combinations of sterile



**Fig. 21.6 Pyoderma gangrenosum (PG) and underlying disorders – ulcerative colitis and PAPA syndrome. A** Multiple ulcers surround an ileostomy (following a total proctocolectomy) in a patient with refractory chronic ulcerative colitis. Although peristomal PG occurs most commonly following intestinal resection of inflammatory bowel disease, it can also follow resection of gastrointestinal or bladder carcinoma. **B** Bullous PG in a patient with ulcerative colitis. **C** PG in a patient with PAPA syndrome (pyogenic arthritis, PG, and acne). *A, Courtesy, Mark Davis, MD; B, Courtesy, YDRSC; C, Courtesy, Maria Chanco Turner, MD.*

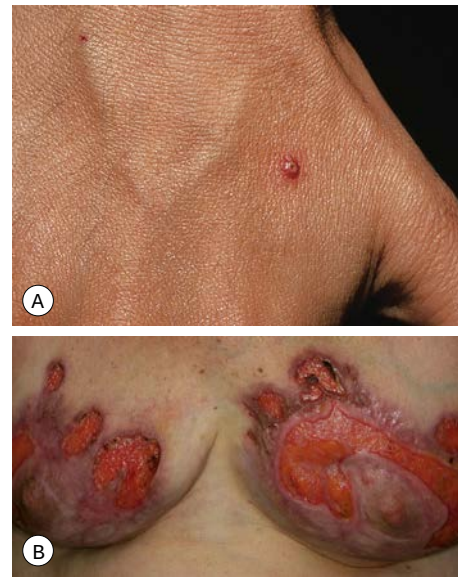

**Fig. 21.7 Pyoderma gangrenosum (PG) – early lesion and demonstration of pathergy. A** The earliest clinical lesion is a pustule with an inflammatory base; this patient had Crohn disease. **B** Postsurgical PG following a breast reduction; multiple debridements had been performed and systemic antibiotics administered because the original diagnosis was soft tissue infection. *A, Courtesy, YDRSC; B, Courtesy, Mark Davis, MD.*



**Fig. 21.8 Pyoderma gangrenosum – pustular variant.** *Courtesy, Karynne O. Duncan, MD.*

arthritis, acne, and hidradenitis suppurativa – e.g. PAPA (*p*yogenic sterile *a*rthritis, *P*G and *a*cne; Fig. 21.6C), PASH (*P*G, *a*cne, *s*uppurative *h*idradenitis), and PAPASH (*p*yogenic *a*rthritis, *P*G, *a*cne, *s*uppurative *h*idradenitis) syndromes.

• **DDx** for classic ulcerative PG: in the *untreated state*, it consists primarily of infectious etiologies and vasculitis, but in a *partially treated state* (usually with oral CS), it includes a host of other causes of ulcers, from venous ulcers to lymphoma and SCC to drug-induced (see Fig. 86.1).

• **Rx:** treatment of the underlying disorder; systemic CS (e.g. prednisone 1 mg/kg/day), intralesional CS into the edge of the ulcer (e.g. triamcinolone 5–10 mg/cc, but initially only a few test sites to confirm no worsening due to pathergy),

| CLINICAL VARIANTS OF PYODERMA GANGRENOSUM (PG) |
|---|
| **Vesiculobullous (also referred to as atypical or bullous PG)** |
| • Lesions favor the face and upper extremities, especially the dorsal hands<br>• Clinical appearance overlaps with the superficial bullous variant of Sweet syndrome (Fig. 21.6B)<br>• Occurs most commonly in the setting of acute myelogenous leukemia, myelodysplasia, and myeloproliferative disorders such as chronic myelogenous leukemia and when drug-induced (e.g. G-CSF) |
| **Pustular** |
| • Multiple, small, sterile pustules (Fig. 21.8)<br>• Lesions usually regress without scarring, but can evolve into classic PG<br>• Most commonly observed in patients with inflammatory bowel disease<br>• Similar eruption may be seen in patients with Behçet disease or bowel-associated dermatosis–arthritis syndrome |
| **Superficial granulomatous pyoderma** |
| • Localized, superficial vegetative or ulcerative lesion, which favors the trunk and usually follows trauma (e.g. surgery)<br>• Base of ulcer more likely to have granulation, rather than necrotic, tissue<br>• Histologically, a superficial granulomatous response with a less intense neutrophilic infiltrate<br>• Tends to respond to less aggressive anti-inflammatory therapy<br>• Controversy as to whether it is a variant of PG, a separate disorder, or related to granulomatosis with polyangiitis (formerly Wegener granulomatosis) |
| **Pyostomatitis vegetans** |
| • Chronic, vegetative, sterile pyoderma of the labial and buccal mucosa (Fig. 21.9A)<br>• May be associated with vegetative or ulcerative cutaneous PG (Fig. 21.9B)<br>• Seen in patients with inflammatory bowel disease |

**Table 21.3 Clinical variants of pyoderma gangrenosum (PG).** G-CSF, granulocyte colony-stimulating factor.

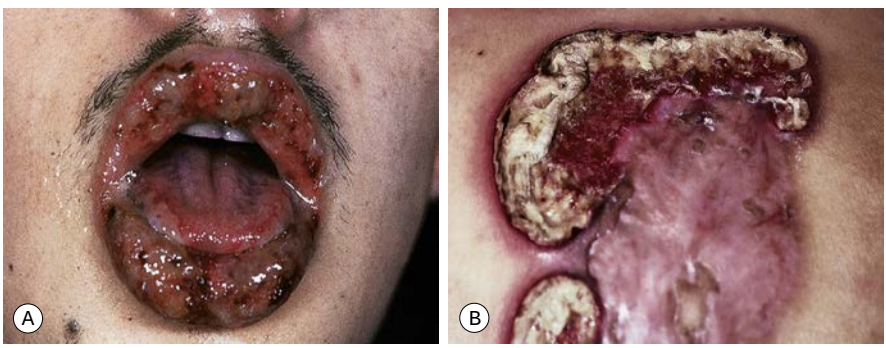


**Fig. 21.9 Pyostomatitis vegetans and vegetative pyoderma gangrenosum (PG). A** Suppurative pyostomatitis vegetans in a patient with ulcerative colitis. **B** Vegetative form of PG following trauma to the skin. *Courtesy, Samuel L. Moschella, MD.*

CS-impregnated tape when peristomal, pulse CS (1g IV for 3–5 days), cyclosporine, TNF inhibitors; for mild or slowly progressive disease, ultrapotent topical CS, topical tacrolimus, minocycline, dapsone, clofazimine.

## Behçet Disease

• A multisystem disease (Table 21.6) whose mucocutaneous features include aphthous orogenital ulcers (Fig. 21.10), sterile pustules (occasionally follicular), and palpable purpura due to small vessel vasculitis, as well as superficial thrombophlebitis and erythema nodosum-like lesions.

• Because the diagnosis is made clinically, there are several sets of criteria, including the one outlined in Table 21.7; there are countries in which the disease is more commonly seen, e.g. Turkey, Japan, and those along the

ancient Silk Road; the peak incidence is ages 20–35 years.

- **DDx:** recurrent genital and intraoral HSV (the latter is limited to keratinized/attached mucosa in immunocompetent hosts; see Ch. 59), simple aphthosis, complex aphthosis, inflammatory bowel disease, SLE, pemphigus vulgaris, lichen planus, Marshall syndrome (periodic fever, aphthous stomatitis, pharyngitis, cervical adenitis).
- Features of both Behçet disease and relapsing polychondritis are seen in MAGIC syndrome, which consists of *m*outh *a*nd *g*enital ulcers with *i*nflamed *c*artilage.

| DIAGNOSTIC CRITERIA FOR CLASSIC ULCERATIVE PYODERMA GANGRENOSUM – TWO SCHEMES |
|---|
| **Major criteria (2004)** |
| 1. Rapid[a] progression of a painful,[b] necrolytic *cutaneous ulcer*[c] *with an* irregular, violaceous and *undermined border* (*plus tenderness and peripheral erythema* for 2018 minor criterion [1])* |
| 2. Other causes of cutaneous ulceration have been excluded[d] |
| **Minor criteria (2004)** |
| 1. History suggestive of *pathergy*[e] [2] or clinical finding of *cribriform scarring* [3]** |
| 2. Systemic diseases associated with pyoderma gangrenosum[f] |
| 3. Histopathologic findings (sterile dermal **neutrophilia**, ± mixed inflammation, ± lymphocytic vasculitis) |
| 4. Treatment response (rapid response to systemic corticosteroids)[g] |
| *In the 2004 scheme, diagnosis requires both of the major criteria and at least two minor criteria. In the 2018 scheme, diagnosis requires 1 major criterion (neutrophilic infiltrate [in **bold**]) and 4 of 8 minor criteria which are in italics and numbered in [ ].* |
| *[a]Characteristic margin expansion of 1–2 cm per day, or a 50% increase in ulcer size within 1 month.* |
| *[b]Pain is usually out of proportion to the size of the ulceration.* |
| *[c]Typically preceded by a papule, pustule, or bulla (plus rapidly leading to an ulceration is 2018 minor criterion [4]).* |
| **Major difference between 2004 and 2018 schemes is that the latter requires multiple ulcerations with ≥1 on the anterior lower leg [5].* |
| *[d]Usually necessitates skin biopsy and additional evaluation (see Table 21.5) to exclude other causes; only exclusion of infection is 2018 minor criterion [6].* |
| *[e]Ulcer development at sites of minor cutaneous trauma (also 2018 minor criterion [2]).* |
| ***Or "wrinkled paper" scar [3].* |
| *[f]Inflammatory bowel disease, inflammatory arthritis, IgA gammopathy, or underlying malignancy (history of either of the first two disorders is 2018 minor criterion [7]).* |
| *[g]Generally responds to prednisone (1–2 mg/kg/day) or another corticosteroid at an equivalent dosage, with a 50% decrease in size within 1 month (2018 minor criterion states just decrease [not %] with immunosuppressive therapy [8]).* |

**Table 21.4 Diagnostic criteria for classic ulcerative pyoderma gangrenosum – two schemes.** *From Su WP, et al. Pyoderma gangrenosum: Clinicopathologic correlation and proposed diagnostic criteria. Int J Dermatol 2004;43:790–800; Maverakis E, et al. Diagnostic criteria of ulcerative pyoderma gangrenosum: A Delphi consensus of international experts. JAMA Dermatol 2018;154:461–8.*

| EVALUATION OF A PATIENT WITH PRESUMED PYODERMA GANGRENOSUM |
|---|
| 1. Thorough history and physical examination; review medications |
| 2. Sterile skin biopsy of *active* skin lesion with sufficient depth (panniculus) and sufficient tissue for special stains and culture (bacterial, mycobacterial, fungal, and viral). Possibility of future additional biopsies for immunofluorescence or PCR studies |
| 3. Gastrointestinal tract studies – stool for occult blood and parasites, colonoscopy, biopsy, radiography, liver function tests, and, if indicated, hepatitis evaluation |
| 4. Hematologic studies – complete blood and platelet count, peripheral blood smear, and, if indicated, bone marrow examination |
| 5. Serologic studies – serum protein electrophoresis, immunofixation electrophoresis, antinuclear antibodies, antiphospholipid antibodies, ANCA antibodies, VDRL |
| 6. Chest X-ray and urinalysis |

**Table 21.5 Evaluation of a patient with presumed pyoderma gangrenosum.**

| SYSTEMIC MANIFESTATIONS OF BEHÇET DISEASE | |
|---|---|
| **Ocular (leading cause of morbidity)** | **Neurologic** |
| • Occurs in 90% of patients; favors men, in whom it is more severe<br>• Can be painful and may lead to blindness<br>• Retinal vasculitis (more frequently associated with blindness)<br>• Posterior uveitis (most characteristic ocular finding)<br>• Anterior uveitis, hypopyon<br>• Secondary glaucoma, cataracts<br>• Conjunctivitis, scleritis, keratitis, vitreous hemorrhage, optic neuritis | • Usually appears later during the evolution of the disease<br>• Associated with a poor prognosis<br>• Acute meningoencephalitis that may resolve spontaneously<br>• Cranial nerve palsies<br>• Brain stem lesions that can induce swallowing difficulties, laughter, and crying<br>• Pyramidal or extrapyramidal signs |
| **Joints** | **Vascular** |
| • Approximately 50% of patients develop arthritis<br>• In majority (~80% of patients), duration of attacks is <2 months<br>• Mono- or polyarthritic and non-erosive<br>• Most commonly knees, wrists, and ankles | • Aneurysmal or occlusive arterial disease<br>• Superficial or deep venous thrombosis |
| **Gastrointestinal** | **Cardiopulmonary** |
| • Abdominal pain and/or hemorrhage may be difficult to distinguish from IBD<br>• Ulcerations* develop within the small bowel (particularly the ileocecal region) as well as the transverse and ascending colon and esophagus; perforation can occur | • Coronary arteritis, valvular disease, myocarditis<br>• Recurrent ventricular arrhythmias<br>• Pulmonary artery aneurysms |
| | **Renal** |
| | • Glomerulonephritis |

**Resemble anogenital aphthae.*

**Table 21.6 Systemic manifestations of Behçet disease.** IBD, inflammatory bowel disease.

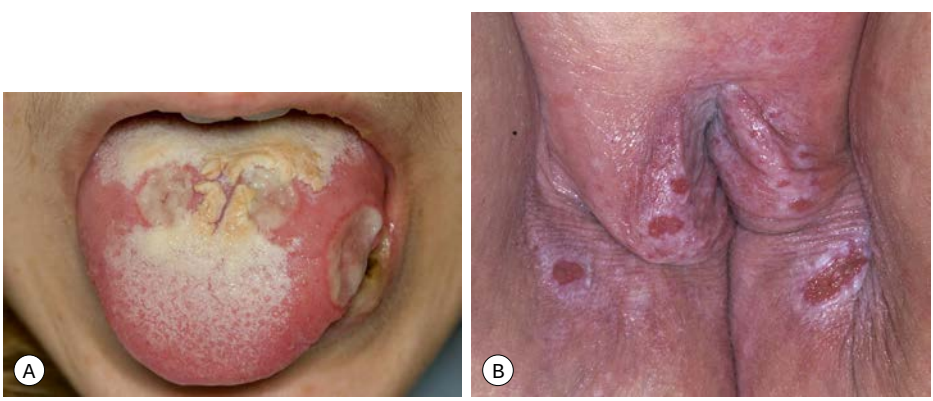


**Fig. 21.10 Oral and genital ulcers of Behçet disease. A** Three major aphthae on the tongue, which are deeper and larger than minor aphthae but share the presence of a pseudomembrane and associated pain. Oral aphthosis is often the initial symptom of Behçet disease and may flare with the onset of other symptoms. **B** Aphthae of the vulvar and inguinal region. *Courtesy, Mark Davis, MD.*

## Bowel-Associated Dermatosis–Arthritis Syndrome (Bowel Bypass Syndrome)

- Although initially described following jejunoileal bypass, this syndrome can develop in association with blind loops of bowel due to surgery or inflammatory bowel disease; presumably, there is overgrowth of bacteria and formation of immune complexes containing bacterial antigens that leads to a serum sickness-like picture.
- Cutaneous lesions include erythematous and purpuric papules and vesiculopustules as well as subcutaneous nodules that are accompanied by polyarthritis and tenosynovitis.

## Synovitis, Acne, Pustulosis, Hyperostosis, and Osteitis (SAPHO) Syndrome

- Characterized by aseptic neutrophilic dermatoses plus aseptic osteoarticular involvement, with a subtype referred to as chronic recurrent multifocal osteomyelitis; the latter favors the anterior chest and axial skeleton.
- Associated skin disorders include: (1) the "acne family" – acne fulminans, follicular occlusion tetrad; (2) the "psoriasis family" – palmoplantar pustulosis, pustular psoriasis, psoriasis vulgaris, Sneddon–Wilkinson disease; (3) linear IgA bullous dermatosis; and (4) the neutrophilic dermatoses discussed in this chapter.

**INTERNATIONAL STUDY GROUP CRITERIA FOR THE DIAGNOSIS OF BEHÇET DISEASE**

| Criteria | Required features |
|---|---|
| **Major criterion:** | |
| Recurrent oral ulceration | Aphthous (idiopathic) oral ulceration observed by physician or patient, recurring at least three times in a 12-month period |
| **Plus any two of the following minor criteria:** | |
| Recurrent genital ulceration | Aphthous genital ulceration or scarring, observed by physician or patient |
| Eye lesions | Anterior or posterior uveitis; cells in the vitreous by slit lamp examination; or retinal vasculitis observed by ophthalmologist |
| Cutaneous lesions | Erythema nodosum-like lesions observed by physician or patient; papulopustular lesions or pseudofolliculitis; or characteristic acneiform nodules observed by physician in postadolescent patient not on corticosteroids |
| Pathergy test* | Interpreted at 24–48 hours by physician |

**Pathergy test is performed on the flexor forearm by obliquely inserting a 20- to 22-gauge sterile hypodermic needle to a depth of 5 mm ± an intradermal injection of 0.1 ml of normal saline. A positive reaction is defined as the development of a papule or pustule.*

**Table 21.7 International study group criteria for the diagnosis of Behçet disease.** *From International Study Group for Behçet's disease. Criteria for the diagnosis of Behçet's disease. Lancet 1990;335:1078–1080.*

For further information see Ch. 26 from *Dermatology, Fourth Edition*.

**For additional online figures visit www.expertconsult.com**




**eFig. 21.1 Spectrum of cutaneous findings in Sweet syndrome. A** Edematous erythematous papules and plaques on the neck of a patient with acute myelogenous leukemia. **B** Some of the edematous lesions can have a targetoid appearance. *A, Courtesy, YDRSC; B, Courtesy, Mark Davis, MD.*




**eFig. 21.2 Neutrophilic dermatosis of the dorsal hands. A** This entity has overlapping clinical and histopathologic features with both Sweet syndrome and pyoderma gangrenosum. Some patients have an associated pustular vasculitis. **B** More extensive disease is often confused with an infectious process. *A, Courtesy, Jean L. Bolognia, MD; B, Courtesy, Mark Davis, MD.*

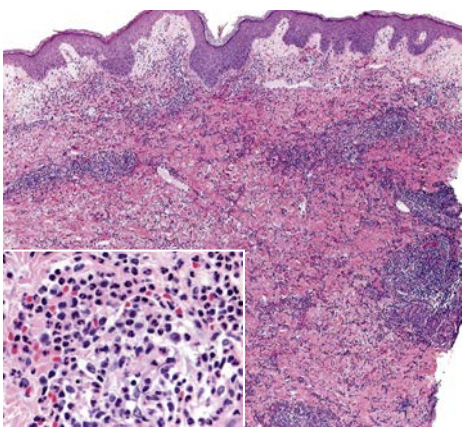

**eFig. 21.3 Sweet syndrome – histopathologic features.** Mild edema in the papillary dermis and a rather dense dermal infiltrate composed predominantly of neutrophils (inset). *Courtesy, Lorenzo Cerroni, MD.*



**eFig. 21.4 Classic ulcerative pyoderma gangrenosum.** The edge of this ulceration on the shin is undermined with a violet-gray color as well as an inflammatory rim. Note the central scarring. *Courtesy, Mark Davis, MD.*



**eFig. 21.5 Pyoderma gangrenosum.** Grouped sterile pustular nodules. *Courtesy, YDRSC.*



**eFig. 21.6 Pyoderma gangrenosum – histopathologic features.** In expanding untreated lesions, a diffuse infiltrate of neutrophils (inset) is present at the edge of an ulceration. *Courtesy, Lorenzo Cerroni, MD.*



**eFig. 21.7 Peristomal pyoderma gangrenosum.** Several ulcers surround an ileostomy in a patient who had a total proctocolectomy performed because of refractory chronic ulcerative colitis. *Courtesy, Mark Davis, MD.*



**eFig. 21.8 Pyoderma gangrenosum (PG) – demonstration of pathergy.** Pathergy with an early lesion at the site of an intravenous catheter. *Courtesy, Samuel L. Moschella, MD.*










**eFig. 21.9 Behçet disease – mucocutaneous lesions. A** Oral aphthosis involving the tongue; the ulcerations can be deep. These ulcers may be misdiagnosed as infectious (e.g. due to HSV) or neoplastic, rather than inflammatory. **B** Perianal aphthosis. In men, lesions often occur on the scrotum and penis. **C** Pathergy – a papulopustule appeared at the site of an intravenous catheter. *A, Courtesy, Luis Requena, MD; B, Courtesy, Samuel L. Moschella, MD; C, Courtesy, Mark Davis, MD.*



**eFig. 21.10 Behçet disease – systemic involvement.** Iritis in a patient who also has pustular vasculitis. *Courtesy, Samuel L. Moschella, MD.*







**eFig. 21.11 Bowel-associated dermatosis–arthritis syndrome. A, B** Papules and papulopustules can be erythematous or violaceous and purpuric. The number of lesions varies from a few to many. *Courtesy, Mark Davis, MD.*



**eFig. 21.12 Bowel-associated dermatosis–arthritis syndrome.** Multiple papulopustules on the upper extremity. *Courtesy, Joseph L. Jorizzo, MD.*



**eFig. 21.13 Abnormal bone scan in a patient with SAPHO syndrome.** There is abnormal tracer uptake within the mid and lower cervical spine and multiple thoracic vertebral bodies (T3 to T9) in addition to the manubrium and sternoclavicular joints. The pattern and anatomic distribution are indicative of increased osteoblastic activity as in the SAPHO syndrome. *Courtesy, Samuel L. Moschella, MD.*

# Pregnancy Dermatoses

# 22

There are several dermatoses that occur either during pregnancy or immediately postpartum, in particular polymorphic eruption of pregnancy, pemphigoid gestationis, and atopic eruption of pregnancy. Pruritus due to intrahepatic cholestasis of pregnancy leads to nonspecific skin lesions, including excoriations due to scratching. Impetigo herpetiformis simply represents pustular psoriasis occurring during pregnancy, and this may be related to the relative hypocalcemia of pregnancy. Lastly, there are physiologic changes that occur during pregnancy.

## Polymorphic Eruption of Pregnancy (PEP; Pruritic Urticarial Papules and Plaques of Pregnancy [PUPPP])

- Relatively common disorder (~1 in 160 deliveries) that begins late in the third trimester or during the immediate postpartum period; occurs primarily in primiparous women, with an increased frequency in those with multigestational pregnancies.
- Pruritic edematous papules and plaques, whose color varies from pink to red-brown depending on skin phototype, that often involve the abdominal striae but spare the umbilicus (Fig. 22.1); the polymorphic presentation includes patches of erythema, targetoid lesions, tiny vesicles, and eczematous plaques (Fig. 22.2).
- Lesions can become widespread, but usually spare the face, palms, and soles; the eruption spontaneously resolves within 4–6 weeks after delivery.
- In general, does not recur with subsequent pregnancies, in contrast to pemphigoid gestationis (PG), and there is no fetal risk.
- **DDx:** PG (may require direct immunofluorescence [DIF] of perilesional skin to distinguish [see Fig. 23.2]), urticarial drug eruption, viral exanthem, allergic contact dermatitis, scabies, erythema multiforme minor.
- **Rx:** topical CS and oral antihistamines usually suffice (Table 22.1); occasionally, severe cases require oral CS (prednisolone preferred during pregnancy because of significant inactivation by placenta, leading to a mother : fetus ratio of 10 : 1).

## Pemphigoid Gestationis (PG; Gestational Pemphigoid)

- Unusual pruritic vesiculobullous disorder that has significant clinical and histopathologic overlap with bullous pemphigoid (see Ch. 24).
- Usually develops during the later stages of pregnancy or immediately postpartum and is due to circulating autoantibodies against bullous pemphigoid antigen 180 (BP180) present within the hemidesmosomal component of the basement membrane zone (BMZ).
- In theory, it is related to aberrant expression of MHC class II antigens of paternal origin in the placenta that trigger an autoimmune response to the placental BMZ, followed by cross-reactivity with the BMZ of the skin.
- Lesions often begin on the abdomen, including around and within the umbilicus, but then become more widespread on the trunk as well as the extremities; in addition to vesicles and bullae, edematous urticarial plaques are seen (Fig. 22.3).
- DIF of perilesional skin shows linear deposits of C3 at the BMZ (see Fig. 23.3F).
- Increased risk of small-for-gestational age and premature neonates and ~10% of newborns have mild skin involvement; often flares at the time of delivery and recurs during subsequent pregnancies.
- **DDx:** primarily PEP (but in PEP, patients are usually primiparous, large bullae are rare unless there is marked background edema,




**Fig. 22.1 Polymorphic eruption of pregnancy.** The edematous urticarial lesions favor the striae **(A, C)** and the upper thighs **(B, D)** and spare the umbilicus. Note the pink color in a woman with skin phototype II versus the red-brown color in a more darkly pigmented patient. **E** Although there is periumbilical involvement, the umbilicus itself is spared and edematous striae point to the diagnosis. *A–D, Courtesy, YDRSC; E, Courtesy, Christina M. Ambros-Rudolph, MD.*

lesions spare the umbilicus, and DIF of perilesional skin is negative) (Fig. 22.4); urticarial drug eruption, allergic contact dermatitis.

- **Rx:** potent topical or oral CS (prednisolone 0.5 mg/kg/day; see Appendix), depending on severity.

## Atopic Eruption of Pregnancy

- Pruritic papules and eczematous plaques that usually develop earlier during pregnancy than other disorders described in this chapter (Fig. 22.5).
- Patients have an atopic diathesis, but this eruption is more likely to have its initial presentation during pregnancy and less often it represents a flare of pre-existing atopic dermatitis.
- May be explained by the predominance of a Th2 immune response during pregnancy.
- No maternal or fetal risks, but recurrence during subsequent pregnancies common.

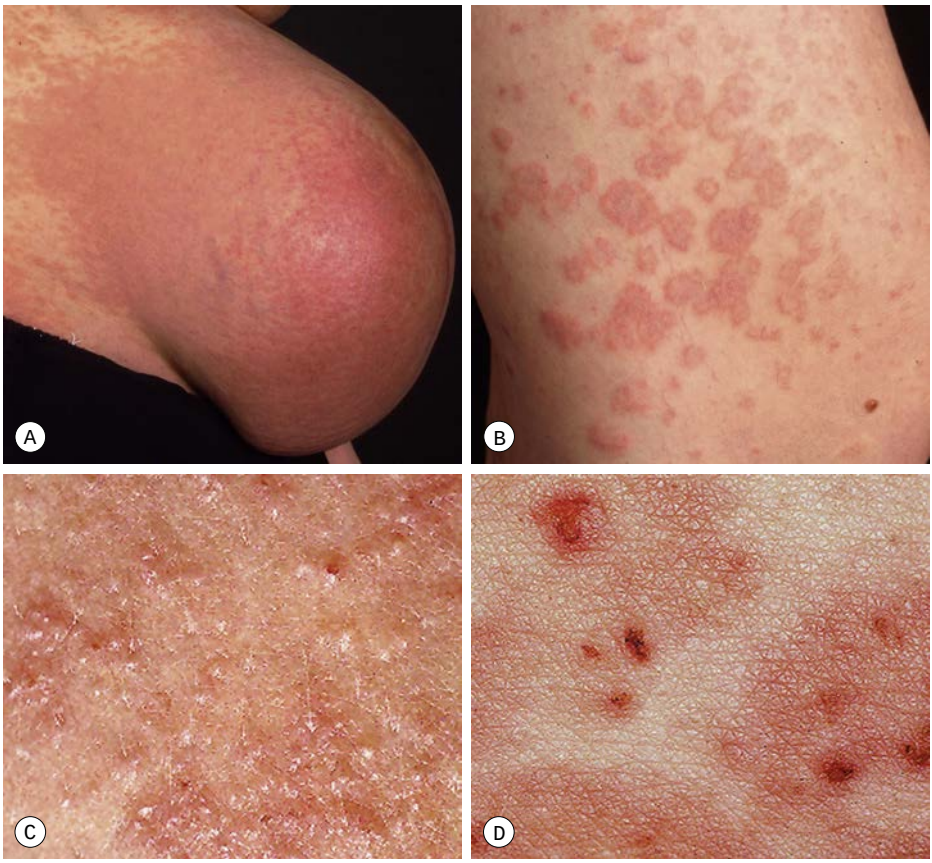


**Fig. 22.2 Polymorphic eruption of pregnancy.** The clinical spectrum includes: **(A)** macular erythema, which can be widespread; **(B)** targetoid lesions; **(C)** tiny vesicles due to marked epidermal spongiosis or dermal edema; and **(D)** eczematous plaques, especially as lesions age. *A–D, Courtesy, Christina M. Ambros-Rudolph, MD.*

- **DDx:** intrahepatic cholestasis of pregnancy, scabies, allergic contact dermatitis, PEP, drug eruption or viral exanthem (if papular).
- **Rx:** topical CS, oral antihistamines, and other routine therapies for atopic dermatitis (e.g. emollients; oral antibiotics such as cephalexin if secondary bacterial infection; see Ch. 10); NB-UVB phototherapy or oral CS for more severe cases (see Table 22.1).

## Intrahepatic Cholestasis of Pregnancy

- Onset usually during the third trimester, related in part to peak in estrogen levels; genetic predisposition with higher incidence in native South Americans; hepatitis C viral infection is also a risk factor.
- Cholestasis leads to elevated serum levels of bile acids and this leads to intense pruritus.
- Cutaneous lesions are nonspecific and vary from excoriations to prurigo nodularis (Fig. 22.6); jaundice occurs in a small minority of patients.
- Important to diagnose because cholestasis of pregnancy is associated with intrapartum fetal distress, prematurity, and stillbirths; in severe cases, vitamin K deficiency may occur, with an increased risk of hemorrhage.
- Diagnosis is based on measurement of total serum bile acids, with elevations typically ranging from 3 to 100 times normal.
- **DDx:** other causes of cholestasis (e.g. primary biliary cholangitis) and hepatitis (e.g. hepatitis B virus, hepatitis C virus), especially if pruritus does not resolve within days of

| SPECIAL CONSIDERATIONS FOR CORTICOSTEROID AND ANTIHISTAMINE USE DURING PREGNANCY | |
|---|---|
| **Corticosteroids** | |
| Topical | • Recent large, population-based studies and a Cochrane review have *not* shown an increased risk of malformations, including oral cleft palate, or preterm delivery<br>• Because fetal growth restriction has been reported with extensive use of potent corticosteroids (CS), particularly >300 gm during pregnancy, mild to moderate CS are recommended over potent CS<br>• If potent CS are required, the treatment period should be limited in duration<br>• Can add to risk of developing striae |
| Systemic | • Prednisolone is the systemic corticosteroid of choice for dermatologic indications as it is largely inactivated in the placenta (mother : fetus = 10 : 1)<br>• During the first trimester, particularly between weeks 8 and 11, there is a possible (debated) slightly increased risk of cleft lip/cleft palate, especially if high doses prescribed and for >10 days; during this same period, a longer duration of therapy appears safe if dosages are <10–15 mg daily<br>• If use is long-term and extends late into gestation, fetal growth should be monitored and the risk of adrenal insufficiency in the newborn should be addressed |
| **Antihistamines** | |
| Systemic | • During the first trimester, the classic sedating agents (e.g. chlorpheniramine, diphenhydramine, clemastine, dimethindene) are preferred because of the preponderance of safety data<br>• If a non-sedating agent is requested, loratadine is the first choice and cetirizine the second choice; both are considered safe throughout pregnancy |

**Table 22.1 Special considerations for corticosteroid and antihistamine use during pregnancy.**



**Fig. 22.3 Pemphigoid gestationis.** Intact tense bullae arising within areas of edematous erythema as well as erosions due to ruptured bullae. Lesions typically involve the umbilical region. *Courtesy, Christina M. Ambros-Rudolph, MD.*

delivery; scabies, atopic eruption of pregnancy, other causes of primary pruritus (see Fig. 4.2).

• **Rx:** oral ursodeoxycholic acid (300-600 mg twice daily); if elevated prothrombin time, vitamin K injections; alert patient that disorder recurs in at least 50% of subsequent pregnancies.

## Physiologic Changes During Pregnancy

These are outlined in Table 22.2.

## Autoimmune Progesterone Dermatitis

• Not a specific dermatosis of pregnancy, but may first appear during pregnancy or postpartum.

• Recurrent flares of dermatitis occur during the luteal phase of the menstrual cycle when there is an increase in progesterone levels; pruritus, urticaria, papulovesicles, and erythema multiforme-like lesions can also be seen.

• Urticaria or delayed induration can appear at sites of intradermal injections of progesterone (e.g. 50 mg/ml).

For further information see Ch. 27 from *Dermatology, Fourth Edition*.

**For additional online figures and tables, including dermatoses influenced by pregnancy, visit www.expertconsult.com**

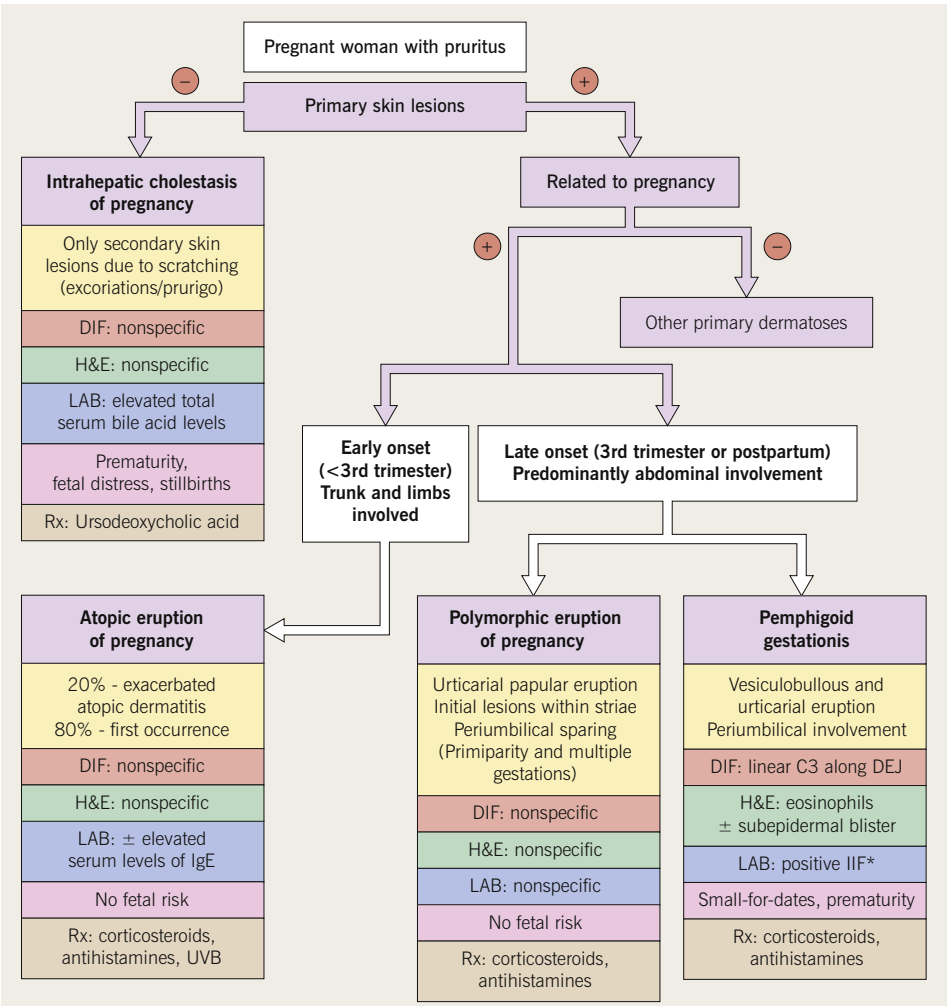


**Fig. 22.4 Approach to the pregnant woman with pruritus.** Patients with refractory pemphigoid gestationis may benefit from plasmapheresis during pregnancy. Prednisolone is the systemic CS of choice for dermatologic indications during pregnancy as it is largely inactivated in the placenta (mother : fetus ratio = 10 : 1); if use of systemic CS or potent topical CS is long-term during pregnancy, then fetal growth should monitored. During the first trimester, the classic sedating anti-histamines (e.g. chlorpheniramine, diphenhydramine, clemastine) are preferred because of the preponderance of safety data and during the second and third trimesters, if a non-sedating agent is requested, loratidine is the first choice and cetirizine the second choice; both are considered safe. *Courtesy, Christina M. Ambros-Rudolph, MD.*




**Fig. 22.5 Atopic eruption of pregnancy.** **A** Eczematous lesions involving flexural areas as well as the abdomen and breasts. **B** Excoriated papules (prurigo lesions) that favored the abdomen and extremities. The former presentation is seen in approximately two-thirds of patients, whereas the latter is seen in approximately one-third. *Courtesy, Christina M. Ambros-Rudolph, MD.*




**Fig. 22.6 Intrahepatic cholestasis of pregnancy.** Marked pruritus leads to secondary skin lesions that vary based on disease duration, from subtle linear excoriations and prurigo simplex early on **(A)** to pronounced prurigo nodularis when the pruritus is longstanding **(B).** *From Ambros-Rudolph CM, Glatz M, Trauner M, Kerl H, Müllegger RR. The importance of serum bile acid level analysis and treatment with ursodeoxycholic acid in intrahepatic cholestasis of pregnancy: A case series from central Europe. Arch. Dermatol. 2007;143:757–762. © (2006) American Medical Association. All rights reserved.*

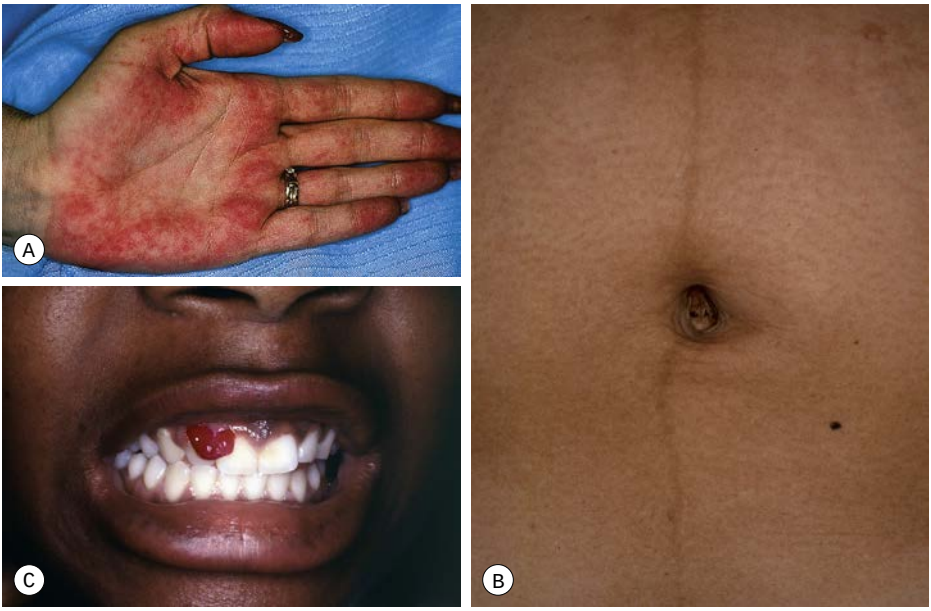


**Fig. 22.7 Physiologic changes during pregnancy.** **A** Palmar erythema of pregnancy. **B** Linea nigra. **C** Gingival pyogenic granuloma. *A, C, Courtesy, YDRSC; B, Courtesy, Jean L. Bolognia, MD.*

| PHYSIOLOGIC CHANGES DURING PREGNANCY | |
|---|---|
| **Pigmentary** | |
| Hyperpigmentation (e.g. areolae, linea nigra; Fig. 22.7B)<br>Melasma | Hyperpigmentation (up to 90% of patients) and melasma (up to 70% of patients) are presumably of hormonal etiology. Melasma tends to persist postpartum in those with darker skin phototypes |
| **Hair** | |
| Hirsutism<br>Postpartum telogen effluvium<br>Postpartum androgenetic alopecia | Some hirsutism is normal and typically regresses postpartum. Telogen effluvium may last up to 15 months. Postpartum patterned alopecia may or may not revert to normal |
| **Connective tissue** | |
| Striae | Striae gravidarum develop in up to 90% of patients and often resolve. Both hormonal factors and physical stretching of the skin appear to be relevant in their development |
| **Vascular** | |
| Spider angiomas<br>Palmar erythema (Fig. 22.7A)<br>Nonpitting edema<br>Varicosities<br>Vasomotor instability<br>Purpura<br>Gingival hyperemia or hyperplasia<br>Pyogenic granuloma (Fig. 22.7C)<br>Hemorrhoids | Vascular changes result from distention, instability, and new vessel formation. Clinically obvious changes are most pronounced during the third trimester, and most changes regress spontaneously following delivery |

**Table 22.2 Physiologic changes during pregnancy.** Nail changes are nonspecific and include subungual hyperkeratosis, distal onycholysis, transverse grooving, and brittleness. *Adapted from Kroumpouzos G, Cohen LM. Dermatoses of pregnancy. J Am Acad Dermatol. 2001;45:1–19.*



**eFig. 22.1 Polymorphic eruption of pregnancy.** Urticarial lesions as well as pseudovesicles on the hand.

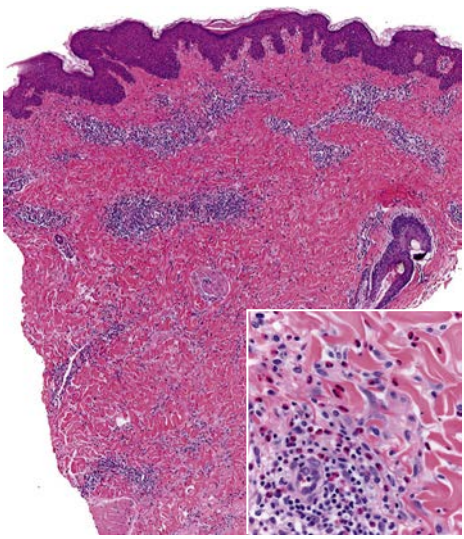

**eFig. 22.2 Polymorphic eruption of pregnancy – histopathologic features.** In this early lesion, a superficial and deep perivascular and interstitial lymphohistiocytic infiltrate is seen within the dermis. Numerous eosinophils are also present (inset). *Courtesy, Christina M. Ambros-Rudolph, MD.*



**eFig. 22.3 Pemphigoid gestationis.** *Courtesy, Jeff K. Shornick, MD.*



**eFig. 22.4 Pemphigoid gestationis.** Confluent crusted erythematous plaques studded with small vesicles. There is obvious involvement of the umbilicus. Dusky urticarial lesions are also present on the thighs. *Courtesy, Luis Requena, MD.*



**eFig. 22.5 Pemphigoid gestationis.** Tense bullae arising within urticarial plaques, reminiscent of bullous pemphigoid. *Courtesy, Luis Requena, MD.*



**eFig. 22.6 Atopic eruption of pregnancy – eczematous lesions.** The eczematous lesions often involve flexural areas and friction sites. These changes are seen in approximately two-thirds of patients. *Courtesy, Christina M. Ambros-Rudolph, MD.*



**eFig. 22.7 Linea nigra as well as polymorphic eruption of pregnancy.** The urticarial papules and plaques spare the periumbilical area and involve the striae. *Courtesy, Christina M. Ambros-Rudolph, MD.*

| DERMATOSES INFLUENCED BY PREGNANCY | |
|---|---|
| Psoriasis | • Commonly improves during pregnancy, then flares within 6–12 weeks following delivery<br>• Explanation: down-regulation of Th1 immune response during a normal pregnancy |
| Atopic dermatitis<br>Systemic lupus erythematosus<br>Pemphigus vulgaris | • Usually worsens during pregnancy and then improves after delivery<br>• Explanation: physiologic shift towards a strong Th2 immune response with an increase in Th2 cytokines (e.g. IL-4, IL-10) |
| Acne | • Can improve or flare; persistent acne often improves during pregnancy<br>• The flares in women with *acne gravidarum* can be severe, in particular late in pregnancy due to hyperandrogenemia |
| Rosacea | • Often worsens during pregnancy, presumably due to immunologic, endocrine, and vascular changes<br>• May present as *rosacea fulminans* |
| Melanocytic nevi | • With the exception of symmetric enlargement of nevi on the breasts and abdomen due to distention, changes in benign nevi are minimal; by dermoscopy, a symmetric peripheral rim of globules may be seen, which reverses after delivery<br>• Nevi may darken during pregnancy, but those with worrisome features, clinically or by dermoscopy, should be biopsied |

**eTable 22.1 Dermatoses influenced by pregnancy.** *Courtesy, Christina M. Ambros-Rudolph, MD.*

| DERMATOSES OF PREGNANCY – FETAL RISK, INVOLVEMENT OF NEWBORN SKIN, AND RISK OF RECURRENCE | | | |
|---|---|---|---|
| **Dermatosis** | **Fetal risk** | **Newborn skin involvement** | **Risk of recurrence** |
| Pemphigoid gestationis | Increased risk of prematurity and small-for-gestational age neonates; risk correlates with disease severity | Mild and transient lesions of pemphigoid gestationis in up to 10% | Commonly recurs ("skipped" pregnancies in only 5–8% of women); recurrences induced by oral contraceptives in 25–50% |
| Polymorphic eruption of pregnancy | None | None | Usually does not recur |
| Intrahepatic cholestasis of pregnancy | Increased risk of premature labor (20–60%), intrapartal fetal distress (20–30%), and stillbirths (1–2%) | None | Recurrence in 45–70% of subsequent pregnancies; may be triggered by oral contraceptives |
| Atopic eruption of pregnancy | None | None | Commonly recurs due to atopic diathesis |

**eTable 22.2 Dermatoses of pregnancy – fetal risk, involvement of newborn skin, and risk of recurrence.**

# 23 Pemphigus

Chapters 23–25 review the major autoimmune bullous diseases (Table 23.1). Because of the overlap in their clinical presentations, histopathologic examination of lesional skin as well as direct immunofluorescence (DIF) of perilesional skin are usually required in order to establish a specific diagnosis (Figs 23.1–23.3). Indirect immunofluorescence (IIF; Fig. 23.2B) and/or ELISA of sera provide additional helpful information; for example, the latter can detect anti-desmoglein 3 (Dsg3) versus anti-Dsg1 antibodies.

Pemphigus is classically divided into three major groups: (1) pemphigus vulgaris, with pemphigus vegetans representing a rare variant; (2) pemphigus foliaceus, with pemphigus erythematosus representing an unusual localized variant, and fogo selvagem, an endemic form; and (3) paraneoplastic pemphigus. Additional subtypes include the two forms of IgA pemphigus and drug-induced pemphigus.

## Pemphigus Vulgaris and Pemphigus Vegetans

- Patients have circulating IgG autoantibodies that bind to the cell surface of keratinocytes in the skin and mucous membranes; this binding leads to an inhibition of the function of desmogleins, transmembrane cadherin proteins that are a component of desmosomes and therefore play an important role in cell–cell adhesion.
- In these two disorders, the autoantibodies primarily target Dsg3, which is expressed within the lower portion of the epidermis and is the predominant isoform in mucous membranes; patients with mucosal-dominant disease as well as those with mucocutaneous disease have anti-Dsg3 autoantibodies (the latter group can also have anti-Dsg1 autoantibodies).
- The decrease in cell–cell adhesion leads to the separation of individual keratinocytes from one another (referred to as acantholysis) and the formation of a split within the epidermis or mucosal epithelium, primarily in its lower portion, just above the basal layer (Fig. 23.3B).
- Clinically, almost all patients with pemphigus vulgaris have painful erosions of the oral mucosa and at least half will have flaccid bullae of the skin plus erosions due to their rupture; lesions can be localized or widespread (Fig. 23.4), and there may be involvement of other mucosal surfaces, e.g. conjunctival, nasal, vaginal.
- Additional clinical clues include the development of hemorrhagic crusts of the vermilion lips (Table 23.2) and a positive Nikolsky sign in areas of active disease – the epidermis can be easily moved laterally with rubbing (due to reduction in intercellular adhesion).
- In pemphigus vegetans, vegetative and papillomatous plaques and nodules develop in conjunction with erosions (Fig. 23.5); lesions favor major body folds and pustules can also be seen.
- DIF of perilesional skin demonstrates immunostaining of the cell surface of keratinocytes within the epidermis or mucosa in almost all patients, and the staining may be more predominant in the lower portion of the epithelium (Fig. 23.3C); IIF and ELISA of sera is positive in more than 90% of patients (Fig. 23.2B).
- **DDx:** other forms of pemphigus, bullous pemphigoid, linear IgA bullous dermatosis (LABD), Hailey–Hailey disease; if there is only oral disease, lichen planus, mucous membrane pemphigoid, aphthous stomatitis.
- **Rx:** oral CS, rituximab, steroid-sparing agents (e.g. mycophenolate mofetil, azathioprine, cyclophosphamide), IVIg, plasmapheresis (plus immunosuppression).

| CHARACTERISTICS OF MAJOR AUTOIMMUNE BULLOUS DISEASES | | | | |
|---|---|---|---|---|
| | **PV** | **BP** | **DH** | **LABD** |
| Cutaneous lesion | Flaccid vesicles and erosions | Large tense bullae | Grouped papules and small vesicles, often excoriated | Small vesicles and/or large bullae |
| Distribution | Mucosae; can be widespread | Trunk, extremities, occasionally mucosal surfaces | Extensor surfaces, symmetrical | Similar to DH or BP |
| Histopathology | Intraepidermal vesicle with acantholysis | Subepidermal bullae with eosinophilic infiltrate | Subepidermal bullae with neutrophilic infiltrate | Subepidermal bullae with neutrophilic infiltrate |
| Direct IF | Intracellular C3, IgG; occasionally IgA* ("chicken-wire" pattern) | Linear IgG and C3 at BMZ | Granular IgA in dermal papillae | Linear IgA at BMZ, possibly also IgG |
| Site to biopsy for direct IF | Perilesional | Perilesional | Adjacent normal-appearing skin | Perilesional |
| Indirect IF | Intracellular IgG (90%) | Linear IgG at BMZ (~70%) | Negative | Linear IgA at BMZ (~70%) |
| ELISA | Distinguishes anti-Dsg1 vs anti-Dsg3 Ab | Detects anti-BP180 and -BP230 IgG antibodies | Anti-tissue transglutaminase (TG2) & anti-epidermal transglutaminase (TG3) antibodies | n/a |
| Enteropathy | None | None | >90% | Rare |
| Dapsone responsiveness | Mild** | Minimal to moderate | Excellent | Good, may also require systemic corticosteroids |

*Referred to as IgA pemphigus.
**Greater response if IgA +/or neutrophils.

**Table 23.1 Characteristics of major autoimmune bullous diseases.** BP, bullous pemphigoid; DH, dermatitis herpetiformis; LABD, linear IgA bullous disease; n/a, not commercially available; PV, pemphigus vulgaris.

## Pemphigus Foliaceus, Pemphigus Erythematosus, and Fogo Selvagem

- In pemphigus foliaceus, the circulating autoantibodies are directed solely against Dsg1 (see above) and can be detected in the vast majority of patients by IIF (~85%) or ELISA (~95%); of note, the expression of Dsg1 is greater in the upper epidermis and minimal in the mucosa.
- As a result, acantholysis and *intra*epidermal blister formation occurs within the *upper* layers of the epidermis, usually at the granular layer; by DIF, immunostaining of the cell surface of the keratinocytes is seen in >90% of patients and may be more marked in these upper layers.
- Clinically, the more superficial and fragile nature of the blisters leads to a predominance of erosions with scale-crust rather

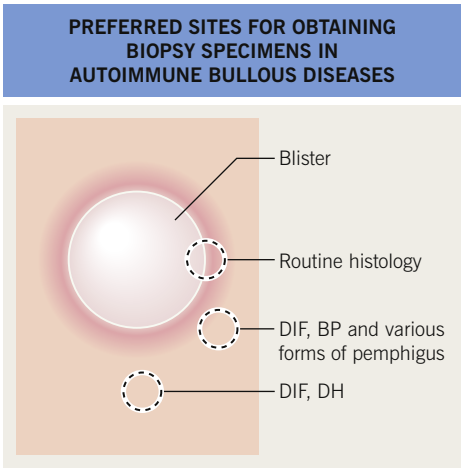


**Fig. 23.1 Preferred sites for obtaining biopsy specimens in autoimmune bullous diseases.** If the lesion is small enough, the entire vesicle can be removed for routine histopathology. If the lesion is not small, obtaining the edge of a fresh vesicle or bulla plus its inflammatory rim is recommended. For direct immunofluorescence (DIF) in bullous pemphigoid and various forms of pemphigus, perilesional skin is preferred, whereas nearby normal skin is recommended for dermatitis herpetiformis (DH).

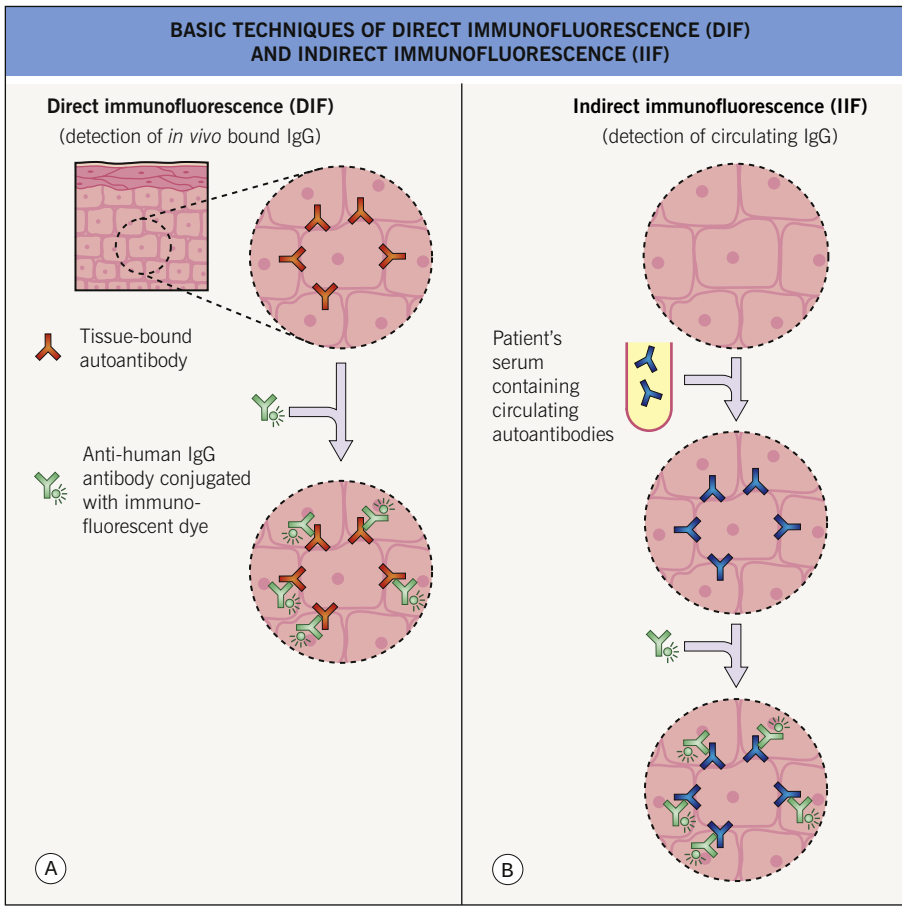


**Fig. 23.2 Basic techniques of direct immunofluorescence (DIF) and indirect immunofluorescence (IIF). A** DIF is performed on skin biopsy specimens in order to detect *in vivo* (tissue)-bound IgG and other immunodeposits such as C3 (see Fig. 23.1). **B** IIF is performed utilizing patients' sera to detect circulating autoantibodies that bind epithelial antigens. The preferred substrate for IIF is monkey esophagus for pemphigus vulgaris, guinea pig esophagus for pemphigus foliaceus, and human skin for the pemphigoid group and LABD.

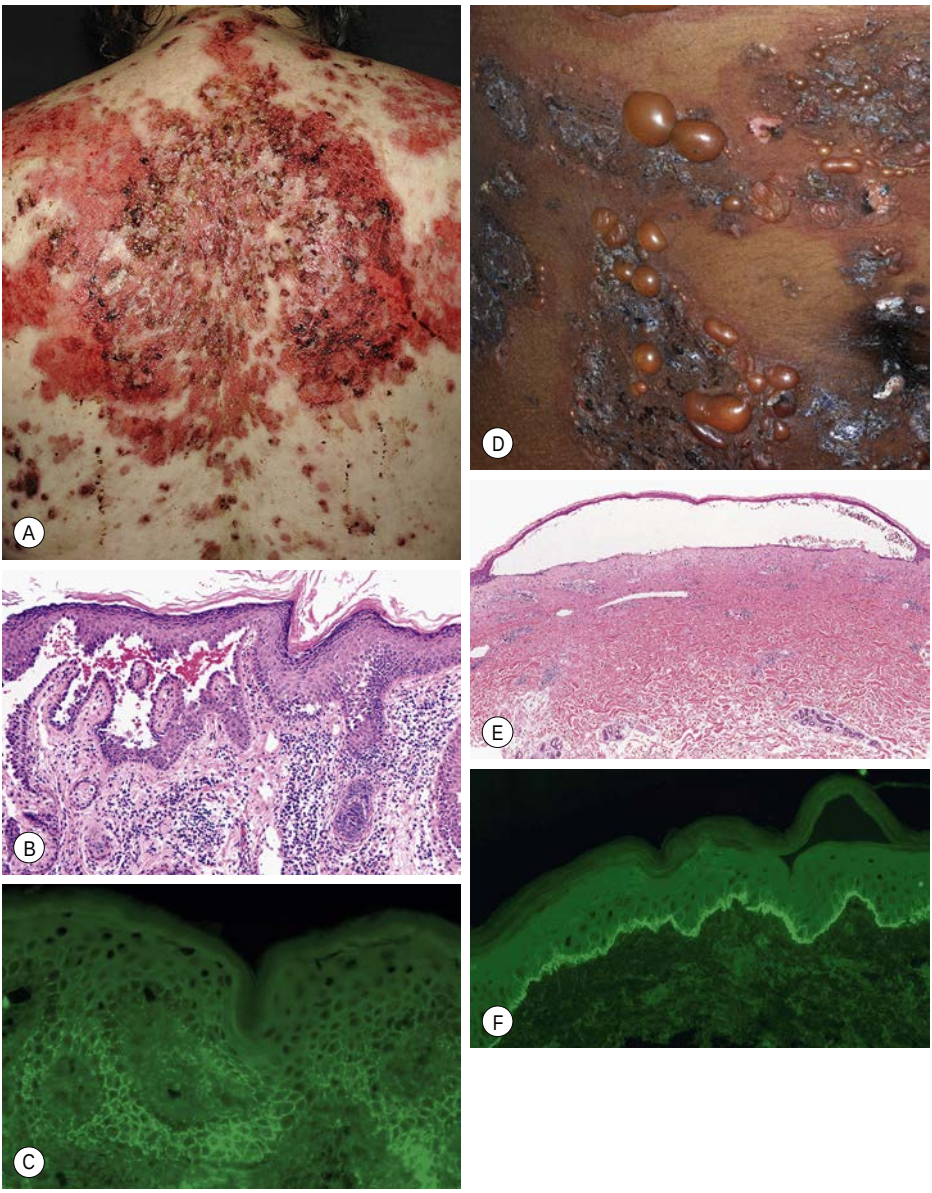


**Fig. 23.3 Pemphigus vulgaris (PV) versus bullous pemphigoid (BP).** **A** In PV, fragile blisters are short-lived and rupture easily, leading to crusting and erosions that can become extensive. **B** Acantholysis due to loss of desmosomal function from anti-desmoglein autoantibodies produces an intraepidermal split. Note the retention of hemidesmosomes between the basal cells of the epidermis and the basement membrane leads to a resemblance to tombstones. **C** DIF microscopy (see Fig. 23.2A) demonstrates *in vivo* intercellular deposits of IgG within the lower epidermis in a "chicken wire" pattern. **D** In BP, multiple tense bullae are seen; the contents of the bullae are usually serous, as in this patient. The bullae are longer-lived than in PV, but do eventually rupture, leading to erosions and crusts. **E** A subepidermal separation is seen. The cells within the blister cavity are often eosinophils. **F** DIF microscopy demonstrates linear deposits of C3 at the basement membrane zone; a similar pattern of IgA deposition is seen in linear IgA bullous dermatosis. *A, B, E, Courtesy, Lorenzo Cerroni, MD; C, F, Courtesy, Christine Ko, MD; D, Courtesy, Julie V. Schaffer, MD.*

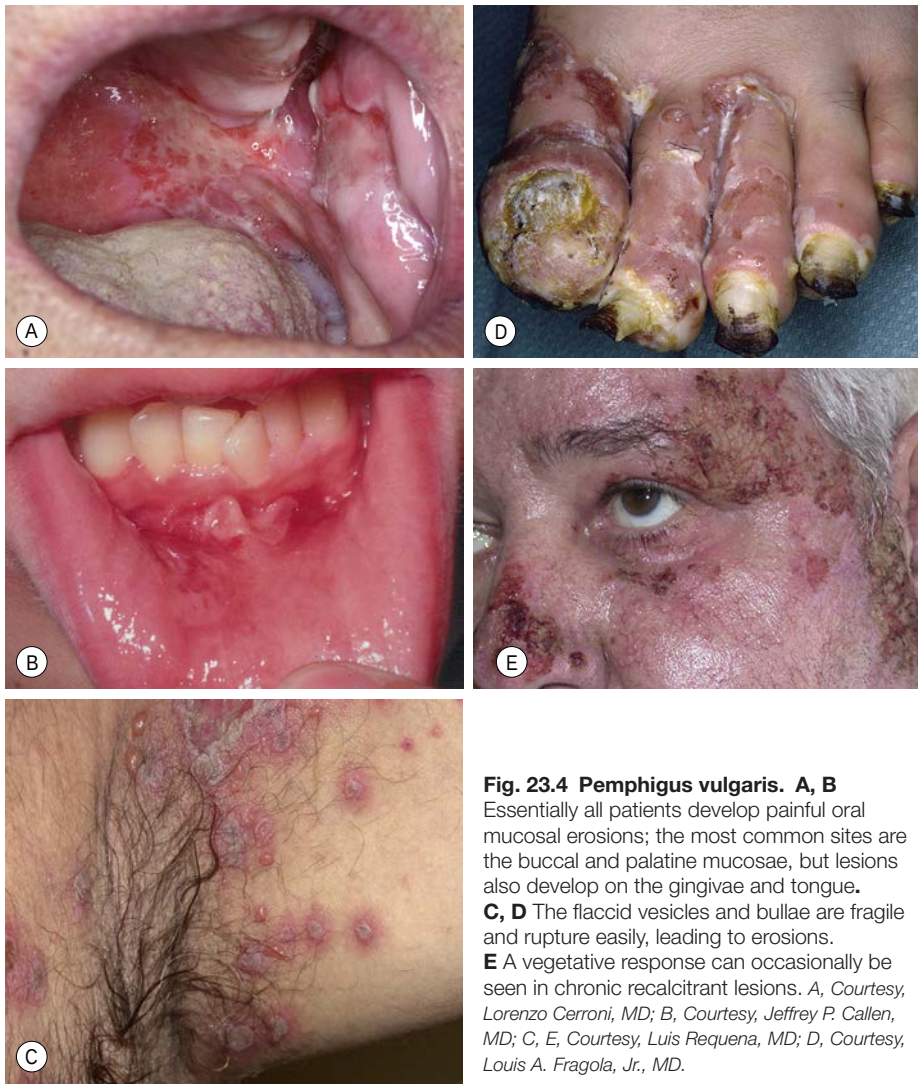


**Fig. 23.4 Pemphigus vulgaris. A, B** Essentially all patients develop painful oral mucosal erosions; the most common sites are the buccal and palatine mucosae, but lesions also develop on the gingivae and tongue. **C, D** The flaccid vesicles and bullae are fragile and rupture easily, leading to erosions. **E** A vegetative response can occasionally be seen in chronic recalcitrant lesions. *A, Courtesy, Lorenzo Cerroni, MD; B, Courtesy, Jeffrey P. Callen, MD; C, E, Courtesy, Luis Requena, MD; D, Courtesy, Louis A. Fragola, Jr., MD.*

| HEMORRHAGIC CRUSTS OF THE VERMILION LIPS |
|---|
| • Herpes simplex |
| • Herpes zoster |
| • Pemphigus vulgaris |
| • Paraneoplastic pemphigus (see Fig. 23.8) |
| • Stevens–Johnson syndrome/TEN spectrum |
| • Erythema multiforme major (see Fig. 3.9) |

**Table 23.2 Hemorrhagic crusts of the vermilion lips.**

than bullae (Fig. 23.6); the scale is said to resemble cereal cornflakes; mucosal involvement is absent.

- While lesions favor the scalp, face, and upper trunk, they can become widespread, even leading to an exfoliative erythroderma, or they can be localized to the face (pemphigus erythematosus; Fig. 23.7).
- Fogo selvagem is an endemic form of pemphigus foliaceus seen primarily in rural areas of Brazil and is thought to be related to an immune reaction to antigens introduced by insect bites.
- **DDx:** other forms of pemphigus, impetigo (early limited disease), subacute cutaneous LE, and occasionally psoriasis.
- **Rx:** topical or oral CS, occasionally dapsone; if severe, steroid-sparing agents.



**Fig. 23.5 Pemphigus vegetans.** Large, thick, vegetating papillomatous plaques arising in conjunction with erosions. Healed lesions have residual postinflammatory hyperpigmentation. *Courtesy, Masayuki Amagai, MD.*

## Paraneoplastic Pemphigus

- Develops in patients with an underlying neoplasm, often malignant, and improves slowly following successful treatment of the neoplasm; the most common tumor in children and adolescents is Castleman disease, whereas the most common ones in adults are non-Hodgkin lymphoma and chronic lymphocytic leukemia > Castleman disease and thymomas.
- Cutaneous lesions are variable and they can resemble lichen planus, erythema multiforme, or bullous pemphigoid as well as pemphigus; severe, recalcitrant oral stomatitis is a characteristic feature and conjunctival involvement is common (Fig. 23.8).
- Bronchiolitis obliterans is a serious internal manifestation.
- IgG autoantibodies are directed against at least ten antigens, including desmogleins and plakins; by DIF, there are immunodeposits on the surface of keratinocytes as well as along the basement membrane zone.

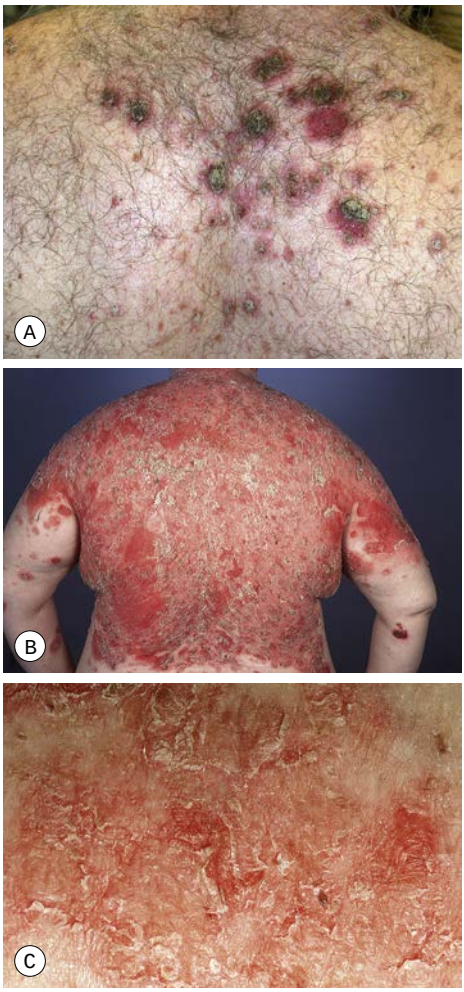


**Fig. 23.6 Pemphigus foliaceus. A** Several erosions arising on an erythematous base as well as the characteristic scale-crust; the latter can vary in thickness. A common site of involvement is the trunk. **B** As the disease progresses, the lesions become confluent, but because the vesicles are fragile and rupture easily, only erosions with scale-crust are observed. **C** The scales have been likened to cornflakes (cereal). *A, Courtesy, YDRSC; B, C, Courtesy, NYUDSC.*

- In this disorder, the anti-plakin antibodies also bind to simple epithelia such as rat urinary bladder epithelium and this allows distinction from pemphigus vulgaris.
- **DDx:** other forms of pemphigus, mucous membrane pemphigoid, erythema multiforme major, Stevens–Johnson syndrome, lichen planus, GVHD.
- **Rx:** treatment of the underlying neoplasm, but the stomatitis may prove recalcitrant



**Fig. 23.7 Pemphigus erythematosus.** Erythematous plaques with scale-crust and erosions on the nose and malar areas. Initially this disorder was thought to be a combination of pemphigus vulgaris plus lupus erythematosus, but now it is classified as a localized variant of pemphigus foliaceus. *Courtesy, Ronald P. Rapini, MD.*



**Fig. 23.8 Paraneoplastic pemphigus.** Erosions, along with hemorrhagic crusts, can extend onto the vermilion lip and involve the nasal mucosa. The chin lesion resembles pemphigus vulgaris. *Courtesy, Masayuki Amagai, MD.*

despite successful eradication of the associated neoplasm.

## IgA Pemphigus

- Two forms of this vesiculopustular eruption exist – subcorneal pustular dermatosis type and intraepidermal neutrophilic type, with the intraepidermal pustules histologically involving the upper versus entire epidermis, respectively.



**Fig. 23.9 IgA pemphigus – subcorneal pustular dermatosis type.** Pustules tend to coalesce to form an annular or figurate pattern with erosions, scale-crust, and postinflammatory hyperpigmentation present centrally. Note the accumulation of the pustular component in the dependent portion of the vesiculopustule. *Courtesy, Masayuki Amagai, MD.*

- Clinically, lesions arise within inflamed or normal skin and assume a figurate arrangement (Fig. 23.9); the most common sites are the axillae and groin.
- By DIF, there is immunostaining of the cell surface of keratinocytes within the epidermis, as in pemphigus vulgaris, but the immunodeposits are IgA rather than IgG.
- **DDx:** Sneddon–Wilkinson disease (negative DIF), pemphigus foliaceus, impetigo (when more limited), LABD, pustular psoriasis.
- **Rx:** dapsone or sulfapyridine and sometimes oral CS.

## Drug-Induced Pemphigus

- Occasionally, medications can induce pemphigus vulgaris or pemphigus foliaceus and discontinuation of those drugs can lead to clinical resolution.
- The most common medications are captopril and penicillamine, both of which contain sulfhydryl groups.

For further information see Ch. 29 from *Dermatology, Fourth Edition*.

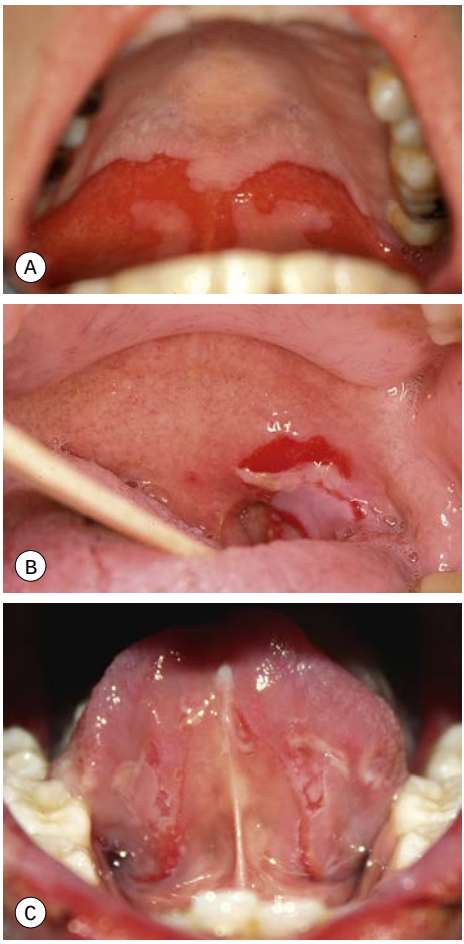


**eFig. 23.1 Pemphigus vulgaris – oral manifestations.** Essentially all patients develop painful oral mucosal erosions. The most common sites are the buccal and palatine mucosae (**A, B**), but lesions also develop on the gingivae and tongue (**C**). Note the sloughing of the mucosa in **B.** *A, Courtesy, Masayuki Amagai, MD; B, Courtesy, Louis A. Fragola, Jr., MD; C, Courtesy, Jeffrey P. Callen, MD.*



**eFig. 23.2 Pemphigus vulgaris.** Flaccid blisters and an erosion due to rupture of a bulla. *Courtesy, Louis A. Fragola, Jr., MD.*



**eFig. 23.3 Pemphigus vulgaris.** Multiple erosions and hemorrhagic crusts of the back that can become extensive. Secondary bacterial infections are a potential complication. *Courtesy, Lorenzo Cerroni, MD.*

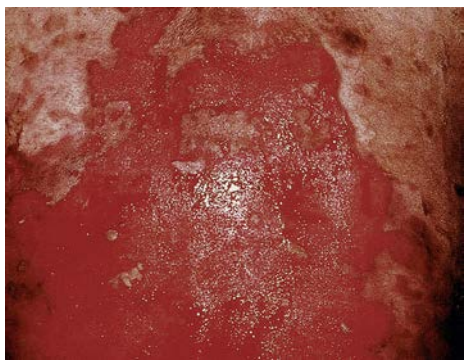

**eFig. 23.4 Pemphigus vulgaris.** Extensive involvement is associated with significant fluid loss and risk of secondary infection and bacteremia. *Courtesy, Department of Dermatology, Hamamatsu University School of Medicine.*



**eFig. 23.5 Pemphigus foliaceus.** Multiple erosions arising on an erythematous base as well as the characteristic scale-crust; the latter can vary in thickness. A common site of involvement is the trunk. *Courtesy, Masayuki Amagai, MD.*



**eFig. 23.6 Paraneoplastic pemphigus.** The characteristic clinical feature is severe intractable stomatitis with multiple erosions; there may be a resemblance to erosive oral lichen planus. *Courtesy, Luis Requena, MD.*



**eFig. 23.7 IgA pemphigus – subcorneal pustular dermatosis type.** Numerous superficial pustules arising within areas of erythema; these pustules rupture easily. The desquamation has a figurate configuration and overall there is a resemblance to pustular psoriasis. *Courtesy, Luis Requena, MD.*

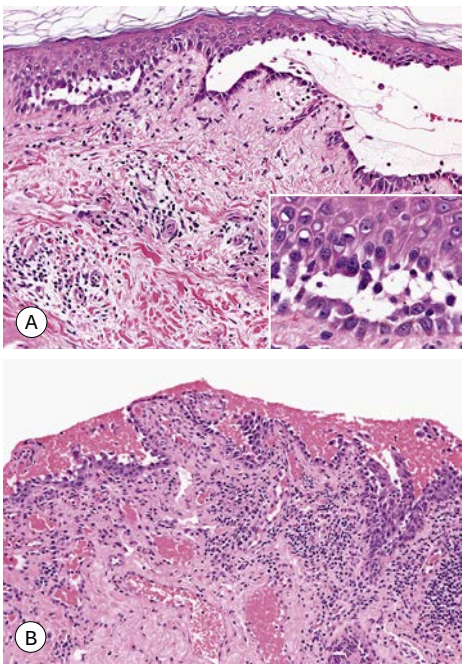


**eFig. 23.8 Pemphigus vulgaris – histopathologic features. A** Blisters in the skin show suprabasilar acantholysis with a few acantholytic cells in the blister cavity (inset). **B** Because blisters in the mouth rarely remain intact, the blister roof is often not seen in oral biopsy specimens. Nonetheless, the diagnosis can be made by the location of the split within the epithelium, the presence of acantholytic cells, and the "tombstones" appearance of the basal cells. *Courtesy, Lorenzo Cerroni, MD.*

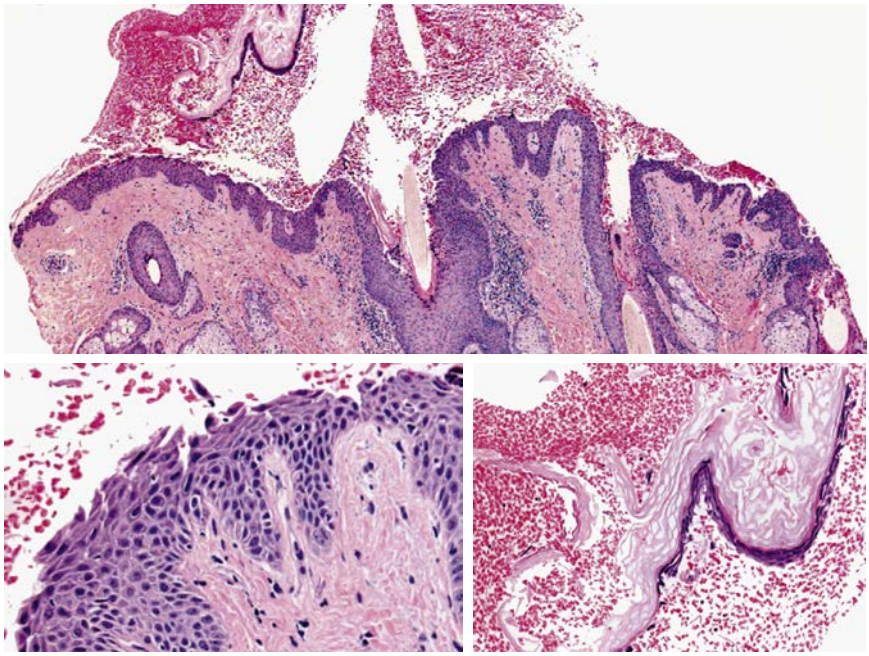

**eFig. 23.9 Pemphigus foliaceus – histopathologic features.** Because of the fragility of the blisters, the blister roof may become detached (right inset). The split is in the upper spinous layer of the epidermis and acantholytic cells are readily apparent (left inset). *Courtesy, Lorenzo Cerroni, MD.*

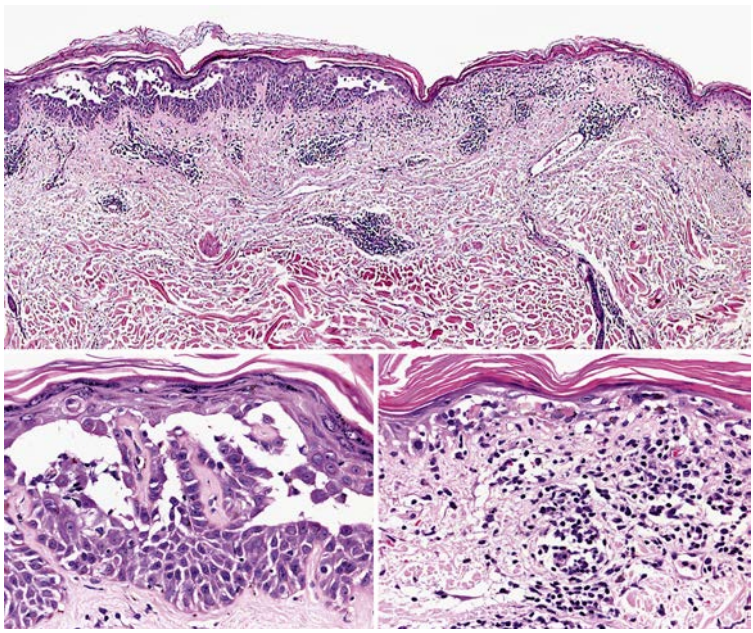

**eFig. 23.10 Paraneoplastic pemphigus – histopathologic features.** In the same biopsy specimen, there are areas of suprabasilar acantholysis (left inset) as well as an interface dermatitis with basal cell vacuolar change, necrotic keratinocytes, and lymphocytes within the epidermis (right inset). *Courtesy, Lorenzo Cerroni, MD.*

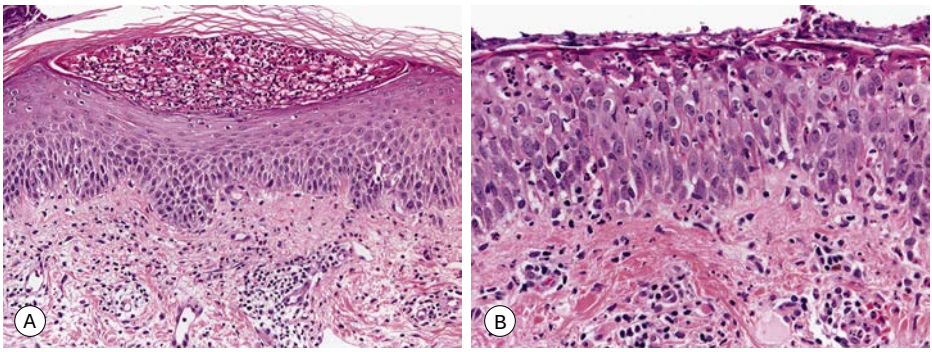


**eFig. 23.11 IgA pemphigus – histopathologic features.** Intraepidermal pustule with neutrophils present subcorneally in the subcorneal pustular dermatosis type (**A**), and within the entire epidermis in the intraepidermal neutrophilic type (**B**). *Courtesy, Lorenzo Cerroni, MD.*

**ELISA TO DETECT IgG AUTOANTIBODIES IN AUTOIMMUNE BULLOUS DISEASES – AVAILABLE TARGET AUTOANTIGENS**

| Target autoantigen | Autoimmune bullous diseases | | | | | | |
|---|---|---|---|---|---|---|---|
| | PV | PF | PNP | BP | MMP | EBA | DH |
| Dsg1 | ✓ | ✓ | ✓ | | | | |
| Dsg3 | ✓ | | ✓ | | | | |
| BP180 | | | | ✓ | ✓ | | |
| BP230 | | | ✓ | ✓ | ✓ | | |
| Laminin 332 | | | | | ✓ | | |
| Type VII collagen | | | | | ✓ | ✓ | |
| Envoplakin | | | ✓ | | | | |
| Periplakin | | | ✓ | | | | |
| Transglutaminase 2 | | | | | | | ✓ |

**eTable 23.1 ELISA to detect IgG autoantibodies in autoimmune bullous diseases – available target autoantigens.** For BP180, the NC16A domain is utilized and for BP230, the N-and/or C-terminus. BP, bullous pemphigoid; DH, dermatitis herpetiformis; EBA, epidermolysis bullosa acquisita; MMP, mucous membrane pemphigoid; PF, pemphigus foliaceus; PNP, paraneoplastic pemphigus; PV, pemphigus vulgaris.

# Bullous Pemphigoid, Mucous Membrane Pemphigoid, and Epidermolysis Bullosa Acquisita

# 24

This chapter, in addition to Chapters 23 and 25, covers the autoimmune bullous diseases. The concepts of direct immunofluorescence (DIF) and indirect immunofluorescence (IIF) are reviewed in Chapter 23 (see Fig. 23.2), as are the recommended sites for performing skin biopsies for DIF (see Fig. 23.1).

## Bullous Pemphigoid (BP)

- Immunobullous disease due to circulating autoantibodies that bind two components of hemidesmosomes, i.e. structures that provide adhesion between the epidermis and the dermis; the two antigens are collagen XVII (also referred to as BP antigen 2 [BPAG2] or BP180) and BPAG1/BP230 (Fig. 24.1).
- Occurs more commonly in the elderly and can be drug-induced (e.g. furosemide, immune checkpoint inhibitors, dipeptidyl peptidase-IV inhibitors); rarely, lesions are induced by ultraviolet light or radiation therapy.
- Both pruritic fixed urticarial plaques and tense bullae are seen (Figs 24.2–24.4); the latter can develop within normal skin or areas of erythematous skin and their rupture leads to erosions; oral lesions (10–30% of patients) are much less common than in pemphigus vulgaris.
- Pruritus and nonspecific eczematous (see Fig. 24.3B) or papular lesions can precede the more characteristic cutaneous lesions and may be the predominant finding; unusual variants include dyshidrosiform (palms and soles), vegetans (major body folds), and localized (e.g. pretibial in adults; vulvar in children, acral in infants), as well as those that mimic prurigo nodularis and toxic epidermal necrolysis (Fig. 24.5).
- Histologically, a subepidermal bulla plus an infiltrate of eosinophils is seen when

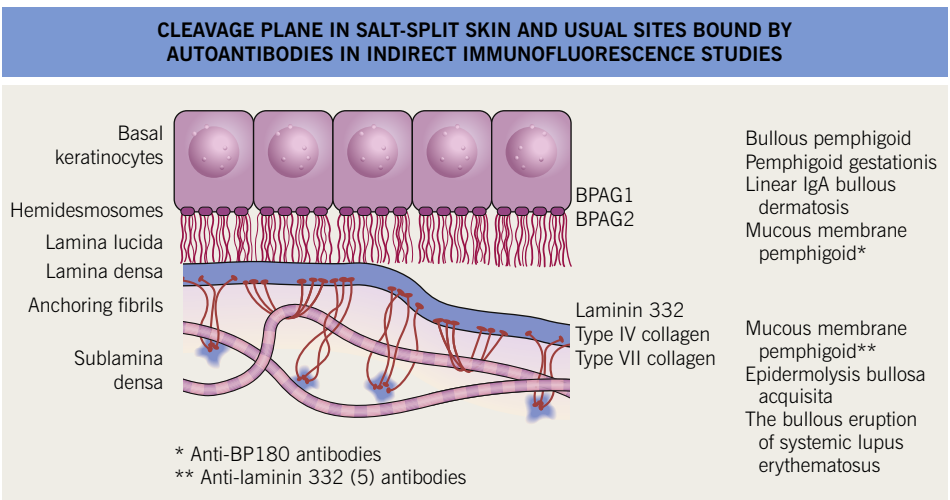


**Fig. 24.1 Cleavage plane in salt-split skin and usual sites bound by autoantibodies in indirect immunofluorescence studies.** The cleavage plane in 1 M NaCl salt-split skin is in the lower portion of the lamina lucida. Circulating autoantibodies from patients with various subepidermal immunobullous diseases bind to different sites, e.g. the epidermal versus dermal side of the split. *Courtesy, Kim Yancey, MD.*

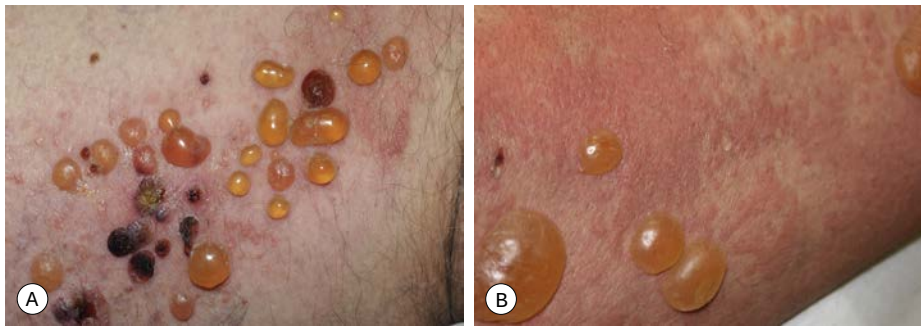

**Fig. 24.2 Bullous pemphigoid – bullous presentation. A,B** Tense vesicles and bullae vary in size from a few millimeters to several centimeters in diameter and can arise within normal-appearing skin, areas of erythema, or urticarial plaques. The blister fluid may be serous or hemorrhagic. As the bullae age, they become flaccid and rupture, leaving erosions and serous or hemorrhagic crusts. Biopsies of vesiculobullae for routine histology should be obtained from fresh tense blisters. *A, Courtesy, Kalman Watsky, MD; B, Courtesy, YDRSC.*

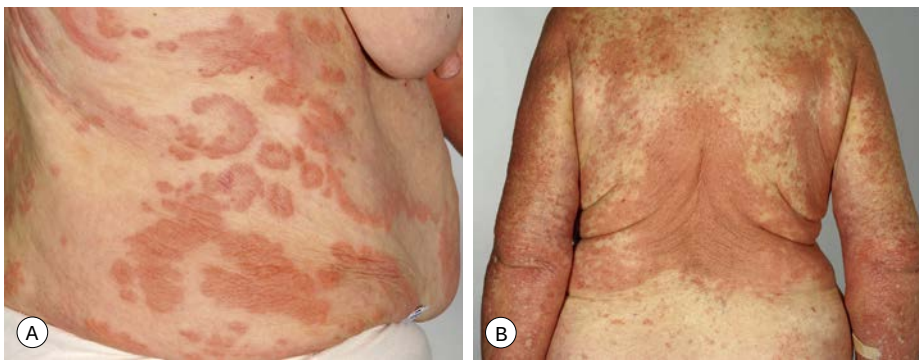

**Fig. 24.3 Bullous pemphigoid – urticarial and eczematous presentations. A** Multiple firm annular, arciform and polycyclic urticarial plaques. Note the absence of bullae. **B** Large pink eczematous plaques on the trunk and extremities. *Courtesy, Philippe Bernard, MD, and Luca Borradori, MD.*

the lesions are bullous (see Fig. 23.3E); DIF demonstrates immunodeposits of IgG and/or C3 in a linear array along the basement membrane zone (see Fig. 23.3F); in general, by salt-split skin immunofluorescence studies, the immunodeposits are in the roof (epidermal side) of the blister (see Fig. 24.1).

- Both enzyme-linked immunosorbent assay and IIF can detect circulating autoantibodies in the sera in at least 70–80% of patients (see Table 23.1). While the autoantibodies are traditionally IgG, IgE autoantibodies may also play a pathogenic role.
- At least 50% of patients have a peripheral eosinophilia.
- **DDx:** linear IgA bullous dermatosis (LABD), epidermolysis bullosa acquisita (EBA), mucous membrane pemphigoid, various forms of pemphigus, hypersensitivity reactions (including to drugs), primary pruritus, allergic contact dermatitis, scabies, urticaria (but individual lesions transient).
- **Rx:** see Table 24.1.

## Mucous Membrane (Cicatricial) Pemphigoid

- Chronic immunobullous disease due to autoantibodies that bind several components of the BMZ of the skin and mucosae, most often BP180 and laminin 332 (laminin 5); although heterogenous in its presentation, a tendency to scarring is typically seen.
- The mucous membranes represent the major site of involvement, in particular conjunctival (erosions, scarring with symblepharon formation, blindness) and oral mucosae (persistent erosions of the buccal and palatal mucosae, desquamative gingivitis) (Figs 24.6 and 24.7).
- Additional sites of involvement are the nasopharynx, larynx, and esophagus; a few




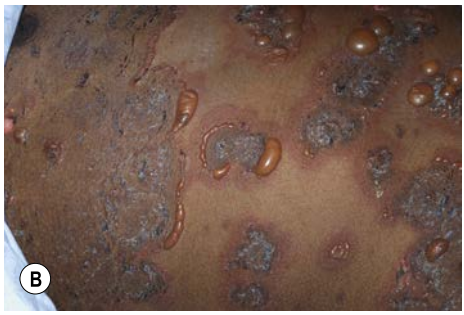


**Fig. 24.4 Childhood bullous pemphigoid.** **A** Generalized bullae, both tense (fresh) and flaccid (old with re-epithelialization), as well as erosions with hemorrhagic crusts. **B** Tense vesicles and bullae in an annular or figurate array at the edge of expanding lesions, a presentation that might be diagnosed clinically as linear IgA bullous dermatosis. *A, Courtesy, NYUDSC; B, Courtesy, Julie V. Schaffer, MD.*

| THERAPEUTIC LADDER FOR BULLOUS PEMPHIGOID |
|---|
| **Mild and/or localized disease** |
| **First-line**<br>• Superpotent topical corticosteroids (1*) |
| **Second-line**<br>• Oral corticosteroids (1)<br>• Minocycline, doxycycline, or tetracycline, alone or in combination with nicotinamide (1)<br>• Erythromycin, penicillins (3)<br>• Dapsone, sulfonamides (3)<br>• Topical immunomodulators (e.g. tacrolimus) (3) |
| **Extensive/persistent cutaneous disease** |
| **First-line, as primary treatment**<br>• Superpotent topical corticosteroids (1*)<br>• Oral corticosteroids† (1)‡ |
| **Second-line, or as adjunctive therapy**<br>• Azathioprine (2)<br>• Mycophenolate mofetil (2)<br>• Methotrexate§ (2)<br>• Rituximab (2)<br>• Omalizumab (3)<br>• Cyclophosphamide (3)<br>• IVIg (3)<br>• Plasma exchange (2)<br>• Chlorambucil (3) |
| *Key to evidence-based support: (1) prospective controlled trial; (2) retrospective study or large case series; (3) small case series or individual case reports. Note: Superpotent topical corticosteroids should be considered in any patient and may be combined with a systemic therapy.*<br>**Validated.*<br>†*Prednisone doses of at least 0.5–0.75 mg/kg/day seem to be necessary to control extensive disease but increase serious side effects, including mortality.*<br>‡*Validated for prednisone.*<br>§*In elderly patients, low-dose regimen (2.5–10 mg/week) can be effective.* |

**Table 24.1 Therapeutic ladder for bullous pemphigoid.**




**Fig. 24.5 Bullous pemphigoid – unusual clinical variants. A** In dyshidrosiform pemphigoid, clusters of vesicles and bullae appear on acral skin and can resemble dyshidrotic eczema or pompholyx. **B** Vegetating plaque in the inguinal crease (pemphigoid vegetans). **C** A predominance of acral involvement is unusual but is often seen in infants. **D** Toxic epidermal necrolysis-like lesions with large erosions. *A, D, Courtesy, Philippe Bernard, MD, and Luca Borradori, MD; B, Courtesy, YDRSC; C, Courtesy, Julie V. Schaffer, MD.*

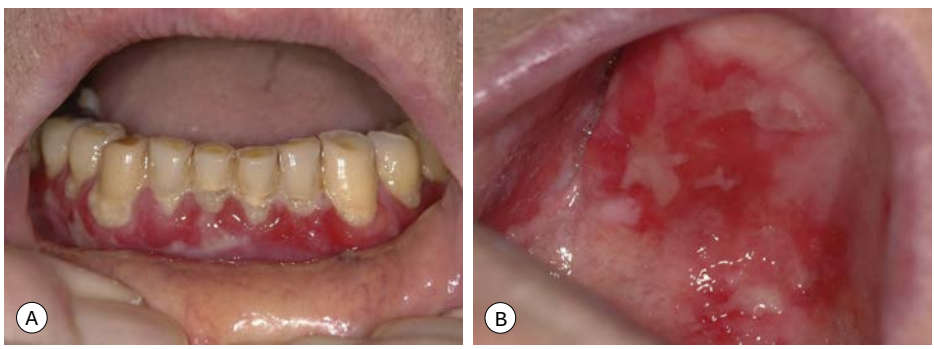


**Fig. 24.6 Mucous membrane (cicatricial) pemphigoid – mucosal involvement. A** Desquamative gingivitis with erythema and erosions of the gingival margins. Note the sloughing of the mucosa with shaggy margins. **B** Chronic erosions on the hard palate with irregular borders. Sloughing of mucosa is seen superiorly. *Courtesy, Philippe Bernard, MD, and Luca Borradori, MD.*

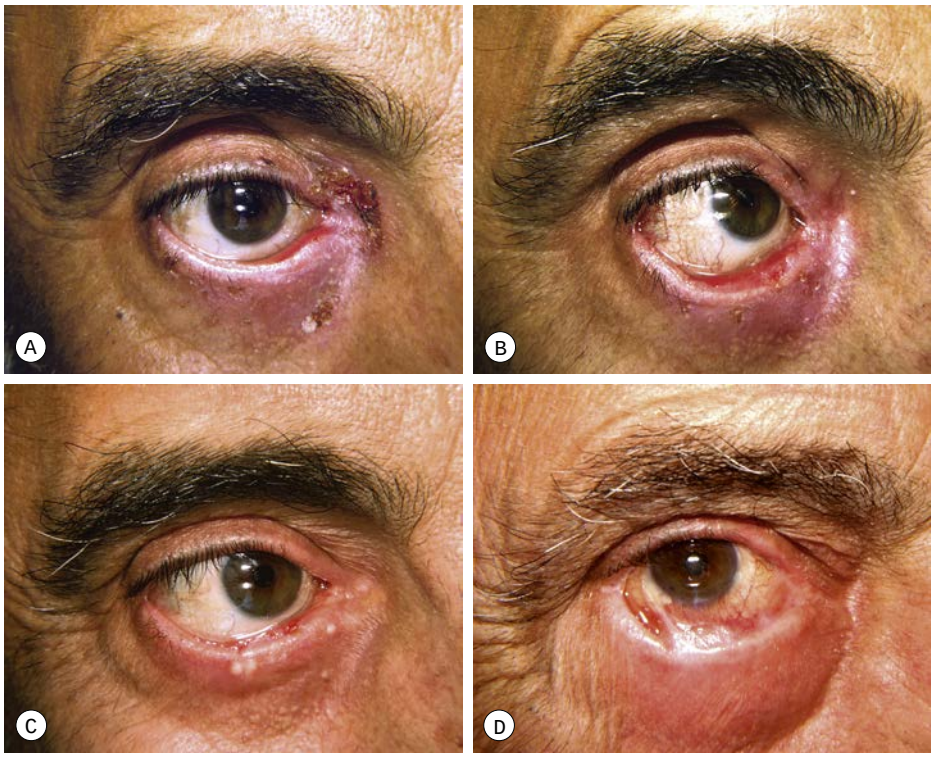


**Fig. 24.7 Mucous membrane (cicatricial) pemphigoid progression.** **A** Erosion and erythema of the lower medial eyelid margin plus scale-crust of the inner canthus and lower eyelid. **B** Three months later, ectropion and thickening of the lower eyelid in addition to erosions of the palpebral conjunctiva. **C** Six months later, smaller erosions but scarring and milia formation. **D** Seven years later, further scarring with significant shortening of the inferior fornix due to symblepharon. *Courtesy, Louis A. Fragola, Jr., MD.*

authors have suggested that patients with anti-laminin 332 immunodeposits have an increased risk of internal malignancy.

- Cutaneous lesions are seen in a quarter of patients and favor the head and neck region and upper trunk; erythematous plaques that develop vesicles, erosions, and scarring are characteristic (Fig. 24.8).
- Histopathologic and DIF features are similar to BP, but there is usually a sparser infiltrate and fewer eosinophils plus fibrosis may be present; DIF positivity (IgG and/or C3 >> IgA) is greater for mucosa (50–90%) than for skin; circulating autoantibodies are detected by IIF in a minority of patients (20–30%).
- **DDx:** pemphigus vulgaris, occasionally paraneoplastic pemphigus, BP, EBA, and LABD; if limited to oral mucosa, lichen planus or pemphigus vulgaris (see Fig. 59.7); if limited to scalp, consider other causes of scarring alopecia.
- **Rx:** potent topical or intralesional CS, dapsone, cyclophosphamide (severe or progressive ocular disease), alone or in combination with systemic CS, and rituximab.

## Epidermolysis Bullosa Acquisita (EBA)

- Autoimmune bullous disease due to autoantibodies that bind to collagen VII; the latter forms anchoring fibrils within the upper dermis and they play an important role in adhesion of the epidermis to the dermis (see Fig. 24.1).
- Two major clinical forms: (1) mechanobullous, which resembles the genetic disorder epidermolysis bullosa; and (2) inflammatory, which resembles bullous pemphigoid (Fig. 24.9).
- In the more common mechanobullous form, bullae arise in sites of friction and are followed by erosions, scarring, and milia formation (Fig. 24.10); oral lesions can also be seen (Fig. 24.11).



**Fig. 24.8 Mucous membrane (cicatricial) pemphigoid – Brunsting–Perry variant.** Crusted erosion on the lower cheek within an oval area of inflammation and scar. *Courtesy, Philippe Bernard, MD, and Luca Borradori, MD.*



**Fig. 24.10 Epidermolysis bullosa acquisita – mechanobullous presentation.** Milia and scarring that favor sites of trauma overlying joints, in association with skin fragility. Note the resemblance to dystrophic epidermolysis bullosa. *Courtesy, YDRSC.*



**Fig. 24.9 Epidermolysis bullosa acquisita – inflammatory bullous pemphigoid-like presentation.** Bullous and erosive lesions in a patient with multiple myeloma. *Courtesy, Philippe Bernard, MD, and Luca Borradori, MD.*



**Fig. 24.11 Epidermolysis bullosa acquisita – oral lesions.** Multiple erosions of the palate reminiscent of mucous membrane pemphigoid. *Courtesy, Catherine Prost, MD.*

- Associated systemic disorders include inflammatory bowel disease, in particular Crohn disease, and plasma cell dyscrasias.
- Histopathologic and DIF features are similar to BP, but there is usually a sparser infiltrate and fewer eosinophils in the mechanobullous form; DIF studies demonstrate linear IgG > C3 or IgA at the basement membrane zone; circulating autoantibodies are detected in ~50% of patients and by salt-split skin immunofluorescence studies, the immunodeposits are in the floor (dermal side) of the blister (see Fig. 24.1).
- **DDx:** inherited forms of epidermolysis bullosa, porphyria cutanea tarda (and other rare variants of porphyria), pseudoporphyria, bullous pemphigoid, LABD, mucous membrane pemphigoid, bullous systemic lupus erythematosus (also autoantibodies against collagen VII).
- **Rx:** difficult to treat; potent topical CS, oral CS, steroid-sparing agents (e.g. mycophenolate mofetil), dapsone, rituximab.

For further information see Chs 28 and 30 from *Dermatology, Fourth Edition*.

**For additional online figures visit www.expertconsult.com**



**eFig. 24.1 Bullous pemphigoid – bullous presentation.** Classic presentation with multiple tense bullae arising on normal and erythematous skin; several of the bullae have ruptured, leaving circular erosions. *Courtesy, YDRSC.*



**eFig. 24.2 Bullous pemphigoid – bullous presentation.** Bullae arising within edematous erythematous plaques. The flexor aspect of the extremities is a common site of involvement and the blister fluid may be serous or hemorrhagic. *Courtesy, Philippe Bernard, MD, and Luca Borradori, MD.*



**eFig. 24.3 Bullous pemphigoid – urticarial presentation.** Firm annular urticarial plaques. *Courtesy, Philippe Bernard, MD, and Luca Borradori, MD.*



**eFig. 24.4 Bullous pemphigoid – nonspecific lesions due to pruritus.** Multiple excoriations and nonspecific lesions of prurigo simplex are present. Bullous pemphigoid is in the differential diagnosis of pruritus in the absence of an obvious dermatosis. *Courtesy, Philippe Bernard, MD, and Luca Borradori, MD.*



**eFig. 24.5 Dyshidrosiform pemphigoid.** Clusters of vesicles and bullae on acral skin that can resemble dyshidrotic eczema or pompholyx. *Courtesy, YDRSC.*

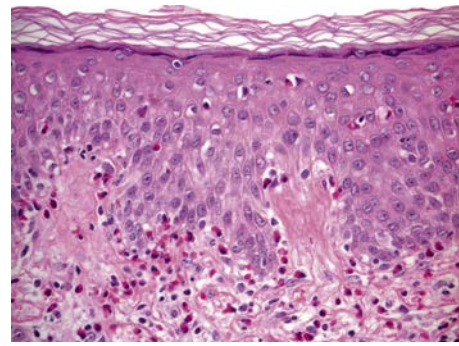

**eFig. 24.7 Urticarial phase of bullous pemphigoid (BP) – histopathologic features.** Eosinophils are present within the dermis as well as the epidermis (eosinophilic spongiosis). Some of the eosinophils have lined up at the dermal–epidermal junction, a typical finding in the urticarial phase of BP. *Courtesy, Lorenzo Cerroni, MD.*



**eFig. 24.6 Bullous pemphigoid localized to a psoriatic plaque.** No obvious trigger was detected, as the patient was not receiving phototherapy. *Courtesy, Jean L. Bolognia, MD.*

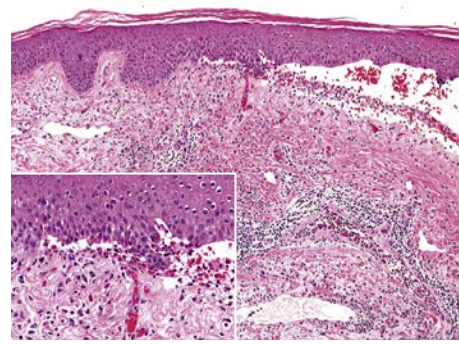

**eFig. 24.8 Bullous pemphigoid (BP) – histopathologic features.** Subepidermal blister which contains fibrin, eosinophils and mononuclear cells (see inset). *Courtesy, Lorenzo Cerroni, MD.*

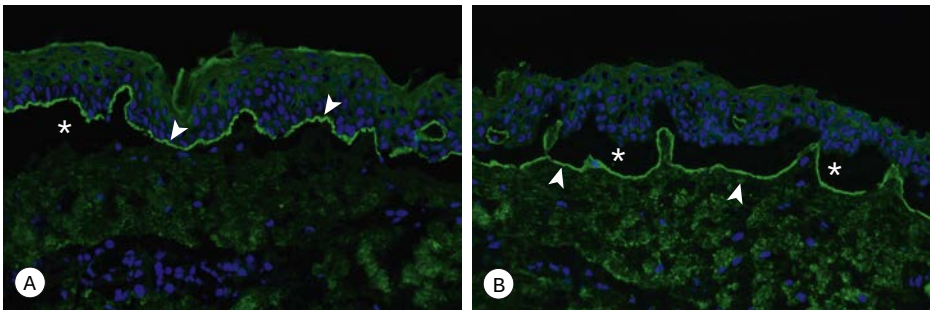


**eFig. 24.9 Indirect immunofluorescence (IIF) microscopy utilizing salt-split skin. A** Circulating IgG autoantibodies from the vast majority of bullous pemphigoid patients bind to the epidermal side (roof) of the salt-induced split (arrows); the artificial separation is indicated by an asterisk. **B** IgG autoantibodies from patients with epidermolysis bullosa acquisita, anti-laminin γ1 pemphigoid (previously known as anti-p200 pemphigoid), and certain forms of mucous membrane pemphigoid (e.g. with antibodies against laminin 332) react with the dermal side (floor) of the blister (arrows). *Courtesy, Hendri Pas, MD.*



**eFig. 24.10 Mucous membrane (cicatricial) pemphigoid – mucosal involvement.** Erythema and erosions of the gingival margins (desquamative or erosive gingivitis). *Courtesy, YDRSC.*

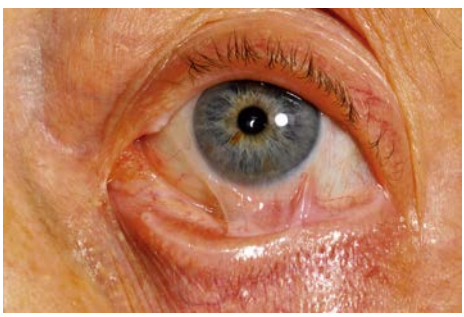

**eFig. 24.11 Mucous membrane (cicatricial) pemphigoid.** Typical ocular involvement as manifested by fibrous tracts, representing partial or incomplete symblepharon. *Courtesy, Philippe Bernard, MD, and Luca Borradori, MD.*



**eFig. 24.12 Mucous membrane (cicatricial) pemphigoid – cutaneous involvement.** An erythematous plaque with atrophy and crusting; note the scarring alopecia. In the Brunsting–Perry variant, there are cutaneous lesions in the head and neck region but minimal or no mucosal involvement. *Courtesy, Philippe Bernard, MD, and Luca Borradori, MD.*

# Dermatitis Herpetiformis and Linear IgA Bullous Dermatosis

# 25

This is the third chapter, along with Chapters 23 and 24, that deals with autoimmune bullous diseases (see Table 23.1).

## Dermatitis Herpetiformis (DH)

- Autoimmune bullous disease that is a cutaneous manifestation of celiac disease, with >90% of patients having histologic evidence of some degree of gluten-sensitive enteropathy; ~20% of patients with DH have symptomatic celiac disease.
- In predisposed individuals (e.g. those with HLA-DQ2), IgA antibodies form against gliadin cross-linked to *tissue* transglutaminase (TG2); the presumed autoantigen in the skin is *epidermal* transglutaminase (TG3; Fig. 25.1).
- Primary lesions consist of pruritic vesicles on an erythematous base and edematous erythematous papules that are often grouped (i.e. herpetiform); however, due to scratching, only excoriated papules and hemorrhagic crusts may be present (Fig. 25.2).
- Favored sites of involvement are the elbows, extensor forearms, knees, posterior neck, and presacral/buttock region, with lesions in a symmetric distribution pattern.
- Histologically, collections of neutrophils are seen within the dermal papillae of involved skin (Fig. 25.3A); by direct immunofluorescence (DIF; see Fig. 23.2), *granular* deposits of IgA are detected within dermal papillae of adjacent, normal-appearing skin in at least 90% of patients (see Fig. 23.1; Fig. 25.3B).
- Patients have circulating anti-tissue transglutaminase and anti-endomysial antibodies, with the level of the latter correlating with degree of enteropathy (Fig. 25.4); they can also develop other autoimmune disorders, in particular Hashimoto thyroiditis.
- **DDx:** linear IgA bullous dermatosis, bullous pemphigoid, prurigo simplex, and bullous systemic LE; crusted lesions of the elbows are also seen in patients with granulomatosis with polyangiitis and eosinophilic granulomatosis with polyangiitis.
- **Rx:** gluten-free diet (also reduces risk of enteropathy-associated T-cell lymphoma), dapsone (initially 25–50 mg per day after screening for glucose-6-phosphate dehydrogenase [G6PD] deficiency; average dose on a normal diet is 100 mg), and sulfapyridine; improvement of pruritus within a few days of instituting dapsone supports the diagnosis of DH.

## Linear IgA Bullous Dermatosis (LABD)

- Autoimmune bullous disease that occurs in both children and adults and can be drug-induced (Table 25.1); in children, it is sometimes referred to as 'chronic bullous disease of childhood'.
- Vesicles and bullae arise on the trunk and extremities and in children often favor the lower trunk and groin; lesions can assume a figurate arrangement and have been likened to a crown of jewels (Figs 25.5–25.7).
- Spontaneous remission in children, usually after 2–4 years; ~50% of adults have a spontaneous remission.
- Histologically, a subepidermal bulla is accompanied by an infiltrate of neutrophils; by DIF, *linear* deposits of IgA are detected at the basement membrane zone of perilesional skin (see Figs 23.1 and 23.2).
- By indirect immunofluorescence (IIF), circulating IgA autoantibodies are detected in ~70% of patients with LABD (see Fig. 23.2); the autoantigen in LABD is a cleavage product of one of the two autoantigens of bullous pemphigoid (BP180; see Ch. 24).
- **DDx:** bullous pemphigoid (linear deposits of IgG), DH (granular deposits of IgA), and mucous membrane (cicatricial) pemphigoid;

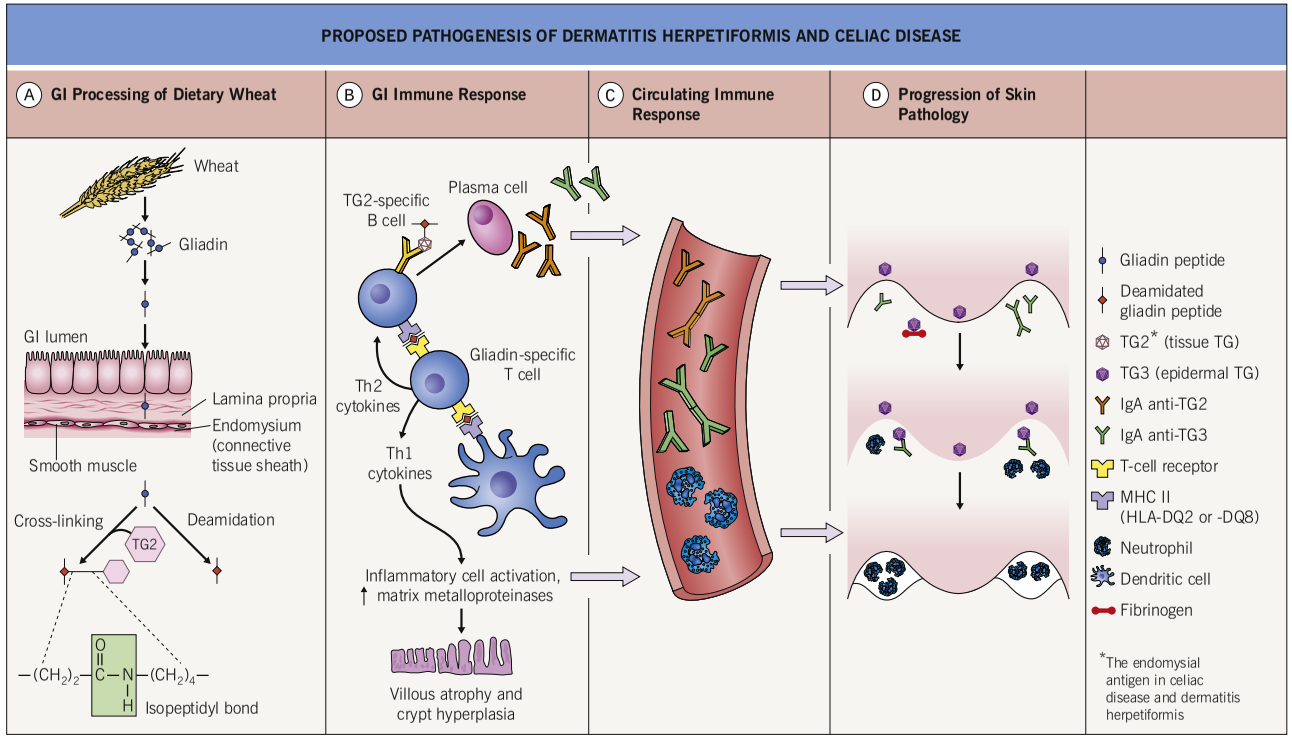


**Fig. 25.1 Proposed pathogenesis of dermatitis herpetiformis and celiac disease.** **A** Dietary wheat, barley, or rye is processed by digestive enzymes into antigenic gliadin peptides, which are transported intact across the mucosal epithelium. Within the lamina propria, tissue transglutaminase (TG2): (1) deamidates glutamine residues within gliadin peptides to glutamic acid; and (2) becomes covalently cross-linked to gliadin peptides via isopeptidyl bonds (formed between gliadin and TG2 lysine residues). **B** $CD4^+$ T cells in the lamina propria recognize deamidated gliadin peptides presented by HLA-DQ2 or -DQ8 molecules on antigen-presenting cells, resulting in the production of Th1 cytokines and matrix metalloproteinases that cause mucosal epithelial cell damage and tissue remodeling. In addition, TG2-specific B cells take up TG2–gliadin complexes and present gliadin peptides to gliadin-specific helper T cells, which stimulate the B cells to produce IgA anti-TG2. **C** Over time, IgA directed against TG3 (IgA anti-TG3) forms as a result of epitope spreading and both IgA anti-TG2 and IgA anti-TG3 circulate in the bloodstream. **D** When IgA anti-TG3 antibodies reach the dermis, they complex with TG3 antigens which have been produced by keratinocytes (epidermal TG) and then have diffused into the dermis. That is, IgA/TG3 immune complexes are formed *locally* within the papillary dermis. This leads to neutrophil chemotaxis (with formation of neutrophilic abscesses), proteolytic cleavage of the lamina lucida, and subepidermal blister formation. *Courtesy, John J. Zone, MD.*

ALGrawany




**Fig. 25.2 Dermatitis herpetiformis.** **A** Grouped vesicles and pink papulovesicles on the upper back, neck, and scalp of a child. **B** Multiple urticarial pink papules on the knee, in addition to a few erosions and small subtle intact vesicles (arrows and inked semicircles). **C** Pink papulovesicles admixed with erosions and hemorrhagic crusts on the elbow. **D** Pruritic pink papules of the buttocks, some of which have central hemorrhagic crusts. **E** Pink plaques on the knee composed of grouped papules and papulovesicles. *A, B, Courtesy, YDRSC; C, E, Courtesy, Thomas Horn, MD; D, Courtesy, Louis A. Fragola, Jr., MD.*

for vancomycin-induced LABD, toxic epidermal necrolysis.

- Important to review medications and withdraw possible culprits before instituting systemic therapy.
- **Rx:** dapsone (often higher doses than for DH) or sulfapyridine, occasionally requiring the addition of prednisone; antibiotics (e.g. dicloxacillin, doxycycline, erythromycin) can be tried initially.

For further information see Ch. 31 from *Dermatology, Fourth Edition*.

**For additional online figures and tables, including side effects of dapsone, visit www.expertconsult.com**

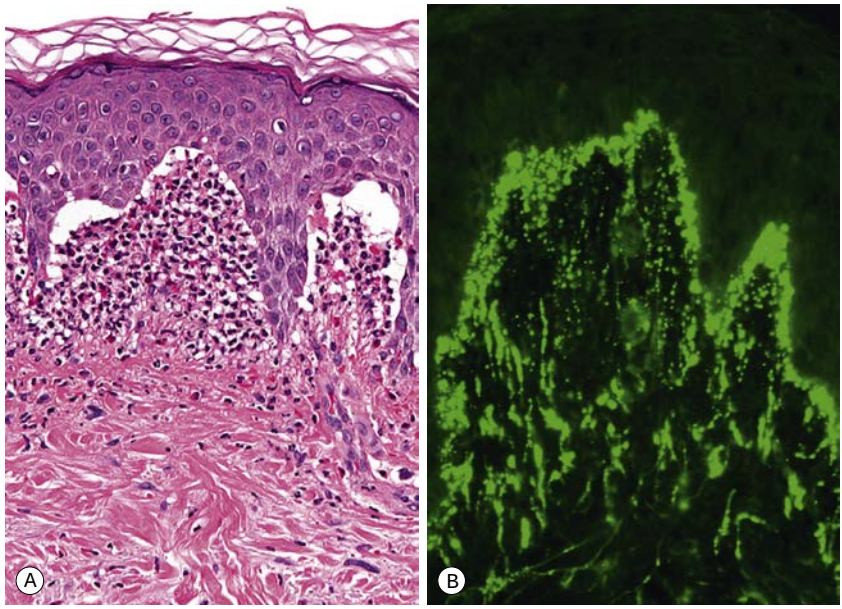


**Fig. 25.3 Dermatitis herpetiformis – histopathologic features and direct immunofluorescence (DIF). A** Subepidermal clefts beneath which are collections of neutrophils within dermal papillae. Scattered eosinophils are also present. **B** Granular and fibrillar IgA deposition along the dermal–epidermal junction of normal-appearing skin adjacent to a lesion. *A, Courtesy, Lorenzo Cerroni, MD. B, Courtesy, Kristen Leiferman, MD.*

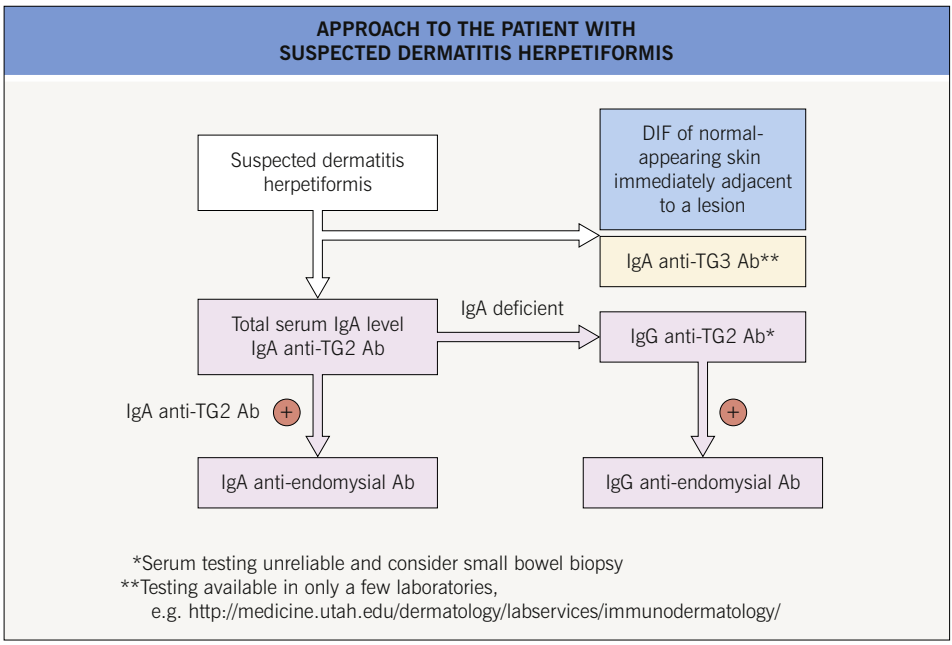


**Fig. 25.4 Approach to the patient with suspected dermatitis herpetiformis.** IgA anti-TG2 and anti-endomysial antibodies can be monitored over time to assess compliance with a gluten-free diet. Because the anti-endomysial antibody assay is based upon analysis of indirect immunofluorescence, it is more expensive than the IgA anti-TG2 antibody assay. Anti-deamidated gliadin peptide IgA/IgG testing may have utility for individuals with IgA deficiency or weakly positive anti-TG2 IgA. DIF, direct immunofluorescence; TG2, tissue transglutaminase; TG3, epidermal transglutaminase. *Courtesy, John J. Zone, MD.*










**Fig. 25.5 Linear IgA bullous dermatosis.** **A** Characteristic findings in this child include the annular array of bullae (inset) and involvement of the genital region. There are also tense bullae arising on normal-appearing skin with either clear or hemorrhagic fluid and annular bullae with central crusting. **B** Annular and herpetiform vesicles arising on an inflammatory base. Annular pink plaques are also present. **C** Striking annular vesiculobullous lesions on the thigh with central erosions and crusting. A figurate outline is seen in the area of coalescence. *A, Courtesy, Antonio Torrelo, MD; B, Courtesy, Jeffrey P. Callen, MD; Courtesy, John J. Zone, MD.*

| DRUG-INDUCED LINEAR IgA BULLOUS DERMATOSIS |
|---|
| **Common** |
| • Vancomycin* |
| **Less common** |
| • Penicillins<br>• Cephalosporins<br>• Captopril > other ACE inhibitors<br>• NSAIDs: diclofenac, naproxen, oxaprozin, piroxicam |
| **Uncommon** |
| • Phenytoin<br>• Sulfonamide antibiotics: sulfamethoxazole, sulfisoxazole |
| *Based on case reports, additional drugs have been implicated and they are listed in Table 31.5 of* Dermatology, Fourth Edition. |
| **Unusual variants include toxic epidermal necrolysis-like and morbilliform.* |

**Table 25.1 Drug-induced linear IgA bullous dermatosis.** ACE, angiotensin-converting enzyme.




**Fig. 25.6 Linear IgA bullous dermatosis.** **A** Annular and polycyclic erythematous plaques of the trunk. **B** Vesicles and bullae arising within normal-appearing skin as well as scattered annular lesions. *A, Courtesy, John J. Zone, MD; B, Courtesy, Jeffrey P. Callen, MD.*




**Fig. 25.7 Linear IgA bullous dermatosis.** **A** Annular and herpetiform vesiculobullae on the face of a child. **B** Vancomycin-induced variant with a similar arrangement of vesiculopustules. Note the central hemorrhagic crusts in both patients. *Courtesy, YDRSC.*



**eFig. 25.1 Linear IgA bullous dermatosis.** The circumferential and linear vesicles and bullae are typical of this disorder. *Courtesy, John J. Zone, MD.*



**eFig. 25.2 Linear IgA bullous dermatosis.** Edematous annular and arciform plaques of the trunk with postinflammatory changes centrally. *Courtesy, John J. Zone, MD.*



**eFig. 25.3 Ofloxacin-induced linear IgA bullous dermatosis (LABD).** Although the initial clinical diagnosis was Stevens–Johnson syndrome, the annular configuration and peripheral locations of the bullae plus the histopathologic and DIF findings led to the diagnosis of LABD. *Courtesy, José M. Mascaro Jr, MD.*

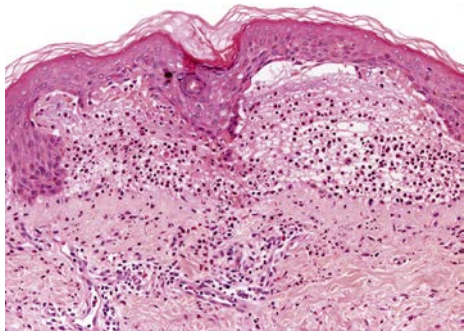

**eFig. 25.4 Linear IgA bullous dermatosis – histopathologic features.** Subepidermal blister filled with neutrophils. Neutrophils and a few eosinophils are also present within the underlying dermis. *Courtesy, Lorenzo Cerroni, MD.*

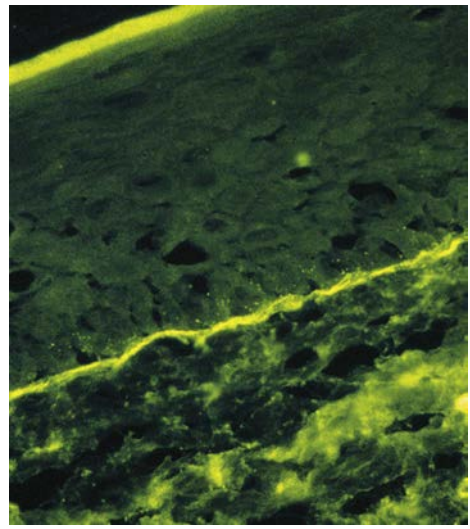

**eFig. 25.5 Linear IgA bullous dermatosis – direct immunofluorescence.** A linear pattern of IgA deposition is present within perilesional skin. *Courtesy, John J. Zone, MD.*

| CHARACTERISTICS THAT DIFFERENTIATE DH, LABD, AND BP | | | |
|---|---|---|---|
| **Characteristic** | **DH** | **LABD** | **BP** |
| Cutaneous lesion | Grouped papules and small vesicles, often excoriated | Small vesicles and/or large bullae | Large tense bullae |
| Distribution pattern | Extensor surfaces, symmetrical | Similar to DH or BP | Trunk, extremities, occasionally mucosal surfaces |
| Routine histology | Subepidermal bullae with neutrophilic infiltrate | Subepidermal bullae with neutrophilic infiltrate (sometimes eosinophils predominate) | Subepidermal bullae with eosinophilic infiltrate |
| Direct IF | Granular IgA in dermal papillae | Linear IgA at BMZ, possibly also IgG | Linear IgG and C3 at BMZ |
| Site to biopsy for direct IF | Adjacent normal-appearing skin | Perilesional | Perilesional |
| Routine indirect IF | Negative | Linear IgA at BMZ (70%) | Linear IgG at BMZ (70%) |
| Enteropathy | >90% | Rare | None |
| HLA-DQ2 | >90% | 30% | Normal (20%) |
| Dapsone responsiveness | Excellent | Good, may also require systemic corticosteroids | Minimal to moderate |

**eTable 25.1 Characteristics that differentiate dermatitis herpetiformis (DH), linear IgA bullous dermatosis (LABD), and bullous pemphigoid (BP).** BMZ, basement membrane zone; IF, immunofluorescence. *Courtesy, John J. Zone, MD.*

| SIDE EFFECTS OF DAPSONE | | |
|---|---|---|
| Red blood cell toxicity | • Hemolytic anemia<br>• Methemoglobinemia^ | |
| White blood cell toxicity | • Leukopenia<br>• Agranulocytosis | |
| Dapsone hypersensitivity syndrome | • Fever, fatigue, anorexia, hepatitis, lymphadenopathy | |
| Cutaneous reactions | • Morbilliform eruption<br>• Urticaria<br>• Fixed drug eruption<br>• Erythema nodosum<br>• Exfoliative dermatitis | • SJS/TEN<br>• Phototoxicity<br>• Drug-induced cutaneous lupus erythematosus |
| Gastrointestinal manifestations* | • Anorexia, nausea<br>• Hepatitis<br>• Cholestatic jaundice<br>• Severe hypoalbuminemia | |
| Neurologic associations* | • Headache, dizziness<br>• Peripheral neuropathy<br>• Blurred vision, tinnitus<br>• Insomnia<br>• Psychosis | |
| Miscellaneous | • Fever<br>• Nephrotic syndrome | |

*^Patients should be warned that arterial desaturation may be noted by pulse oximetry, even with relatively low levels of methemoglobinemia.*
**In decreasing order of frequency.*

**eTable 25.2 Side effects of dapsone.** SJS, Stevens–Johnson syndrome; TEN, toxic epidermal necrolysis.

# Epidermolysis Bullosa 26

- Epidermolysis bullosa (EB) is a group of genetic disorders characterized by mechanical fragility of the skin that leads to blister formation with minor trauma or friction.
- Inherited EB is traditionally divided into three major categories – EB simplex (EBS), junctional EB (JEB), and dystrophic EB (DEB) – that differ in the ultrastructural site of blister formation (Fig. 26.1).
- The overall incidence is approximately 1 in 50,000 births, with EBS representing the most common form.
- Mutations in the genes encoding at least 20 structural proteins of the skin can result in EB, with variable clinical phenotypes, ultrastructural findings, and inheritance patterns.
- The major subtypes of EB and Kindler syndrome (now classified as a fourth form of EB) are summarized in Table 26.1.
- Fig. 26.2 presents an approach to the laboratory diagnosis of EB via genetic analysis with a massively parallel (next-generation) sequencing panel as well as traditional methods utilizing immunofluorescence antigenic mapping and/or electron microscopy on a punch biopsy specimen from a freshly induced blister.

## Clinical Features of EB

- The severity and distribution of blistering vary depending on the EB subtype (see Table 26.1), the patient's age (e.g. improving over time, especially for EBS), and environmental factors (e.g. sweating, friction).
- Scarring (usually atrophic), milia, and nail dystrophy may develop in any subtype of EB, but they are most common in DEB (Fig. 26.9; see Figs 26.6 and 26.7).
- The molecular defects in EB can also affect other organs/tissues with an epithelial surface, such as the oral mucosa, eye, and gastrointestinal and genitourinary tracts (see Table 26.1).
- **DDx:** sucking blisters and other genetic (e.g. epidermolytic ichthyosis), infectious (e.g. bullous impetigo, staphylococcal scalded skin syndrome) or autoimmune blistering disorders of infancy (see Ch. 28).

## Management of EB

- Management focuses on minimizing mechanical trauma, providing wound care, and preventing infection. Protective dressings/padding, soft clothing, and bathing/soaking with dilute sodium hypochlorite (0.5 cup household bleach in full standard bathtub) or 0.25% acetic acid (1 : 20 white vinegar : water) can be helpful.
- Adhesives should be avoided and only nonadherent/"low-tack" dressing materials applied to EB skin, e.g. petrolatum-impregnated gauze (adding extra petrolatum to prevent sticking) and soft silicone dressings (e.g. Mepitel®, Mepilex®), followed by rolled gauze.
- Lancing and draining blisters with placement of a small window can relieve pressure and promote healing; antibiotics should be used judiciously, avoiding chronic treatment with topical mupirocin or oral antibiotics.
- A multidisciplinary approach is helpful, especially for more severe forms of EB, with attention to oral/dental care, growth, nutritional status, and other potential complications.
- Older children and adults with recessive DEB require periodic total-body skin examinations, with biopsy of nonhealing ulcers to exclude SCC.

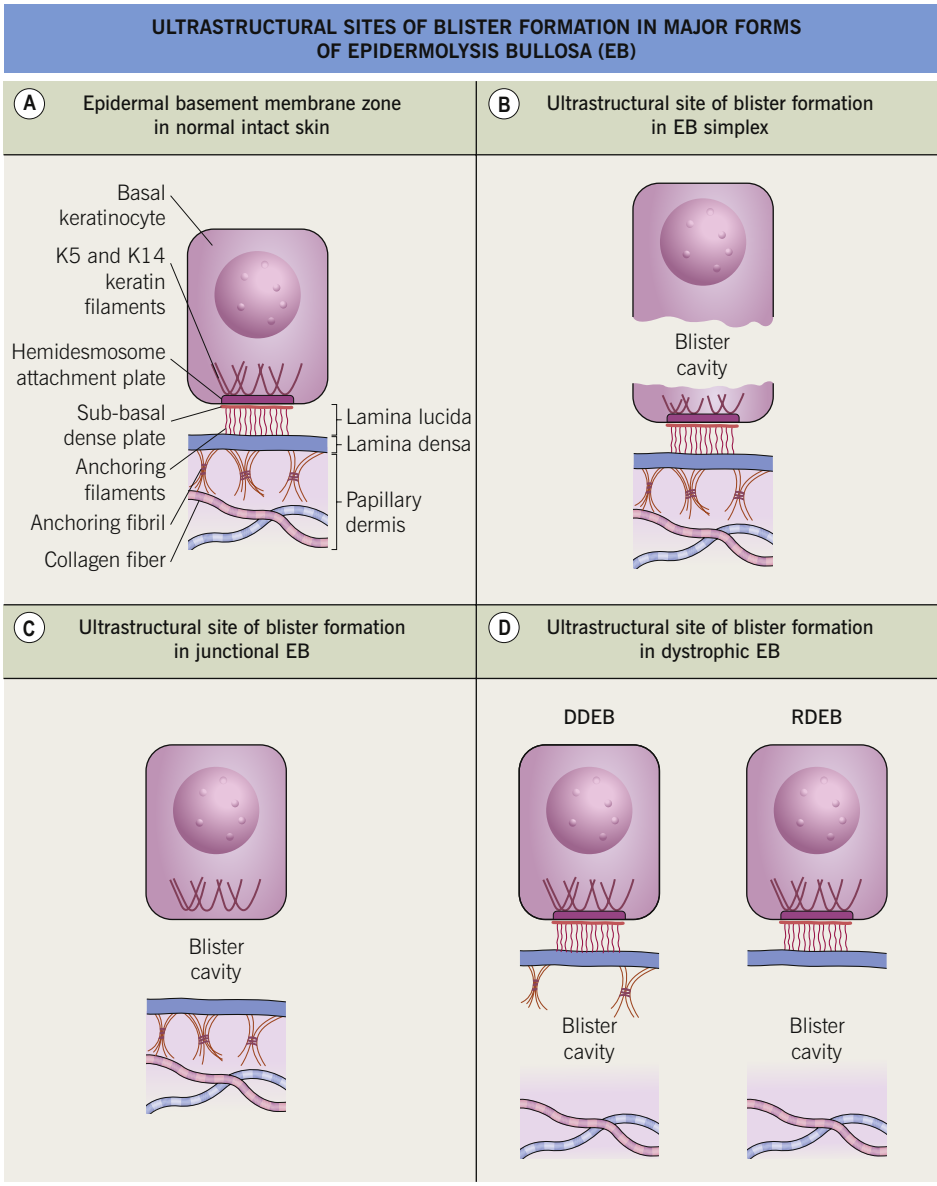


**Fig. 26.1 Ultrastructural sites of blister formation in major forms of epidermolysis bullosa (EB).** **A** In intact skin, the ultrastructural regions of the epidermal basement membrane zone consist of (1) basal keratinocytes and the hemidesmosomal plaque; (2) the lamina lucida; (3) the lamina densa; (4) the upper papillary dermis. **B** In EB simplex (EBS), blisters arise within the lower portion of basal keratinocytes. **C** In junctional EB (JEB), blisters form within the lamina lucida. **D** In dystrophic EB (DEB), blisters develop below the lamina densa. Anchoring fibrils are reduced in number in dominant DEB (DDEB) and absent or rudimentary in recessive DEB (RDEB). K5, keratin 5; K14, keratin 14.

| MAJOR EPIDERMOLYSIS BULLOSA (EB) SUBTYPES | | |
|---|---|---|
| **Subtype** | **Defective proteins (inheritance)** | **Features and complications** |
| **EB simplex (EBS)** | | |
| EBS, localized (formerly Weber–Cockayne) | Keratins 5 and 14 (AD) | • Primarily affects palms/soles (Fig. 26.3) |
| EBS, severe (formerly Dowling–Meara) | | • Arcuate/figurate array of blisters (Fig. 26.4A)<br>• PPK (Fig. 26.4B) |
| EBS, intermediate | | • Often worse in early childhood (Fig. 26.4C) |
| EBS with muscular dystrophy | Plectin (AR) | • Onset of muscular dystrophy may be delayed until adolescence/early adulthood |
| **Junctional EB (JEB)*** | | |
| JEB, severe (formerly Herlitz) | Laminin-332 (AR) | • Exuberant granulation tissue (Fig. 26.5)<br>• Often death during infancy from FTT, tracheolaryngeal involvement, and/or sepsis<br>• Systemic complications similar to RDEB-severe in survivors |
| JEB, intermediate | Laminin-332, type XVII collagen/ BPAG2 (AR) | • Large, irregularly shaped, darkly pigmented nevi ("EB nevi")† |
| JEB with pyloric atresia | $\alpha_6\beta_4$ integrin (AR) | • Born with pyloric atresia |
| **Dystrophic EB (DEB)** | | |
| Dominant DEB, localized or intermediate | Type VII collagen (AD) | • Prominent scarring, milia, and nail dystrophy (Fig. 26.6) |
| Recessive DEB, severe (formerly Hallopeau–Siemens) | Type VII collagen (AR) | • Pseudosyndactyly (mitten deformity) of hands/feet (Fig. 26.7A) and osteoporosis develop over time<br>• Microstomia, excessive dental caries<br>• Corneal ulcers/scarring, esophageal and urethral strictures, constipation, anemia, FTT, cardiomyopathy, renal failure<br>• >50% risk of cutaneous SCC (Fig. 26.7B) by age 30 years†; represents leading cause of death |
| Recessive DEB, other subtypes | | • Include intermediate, inversa, and localized forms |
| **Other** | | |
| Kindler EB (Kindler syndrome) | Kindlin-1‡ (AR) | • Acral blistering, primarily during infancy; ± webbing of fingers/toes (Fig. 26.8A, B), PPK<br>• Photosensitivity that decreases with age<br>• Progressive poikiloderma (Fig. 26.8C), "cigarette paper" atrophy (Fig. 26.8B)<br>• Gingivitis, colitis, stenoses, ectropion |

**Dental enamel hypoplasia occurs in all forms of JEB.*
*†"EB nevi" occasionally occur in other EB subtypes, and patients with severe RDEB have an increased risk of melanoma.*
*‡Mediates anchorage between the actin cytoskeleton and the extracellular matrix via focal adhesions.*

**Table 26.1 Major epidermolysis bullosa (EB) subtypes.** Other erosive skin fragility disorders due to desmosomal defects (e.g. plakophilin deficiency) feature intraepidermal blistering (with acantholysis in skin biopsy specimens), PPK, nail dystrophy, and hypotrichosis. AD, autosomal dominant; AR, autosomal recessive; BPAG, bullous pemphigoid antigen; FTT, failure to thrive; PPK, palmoplantar keratoderma.

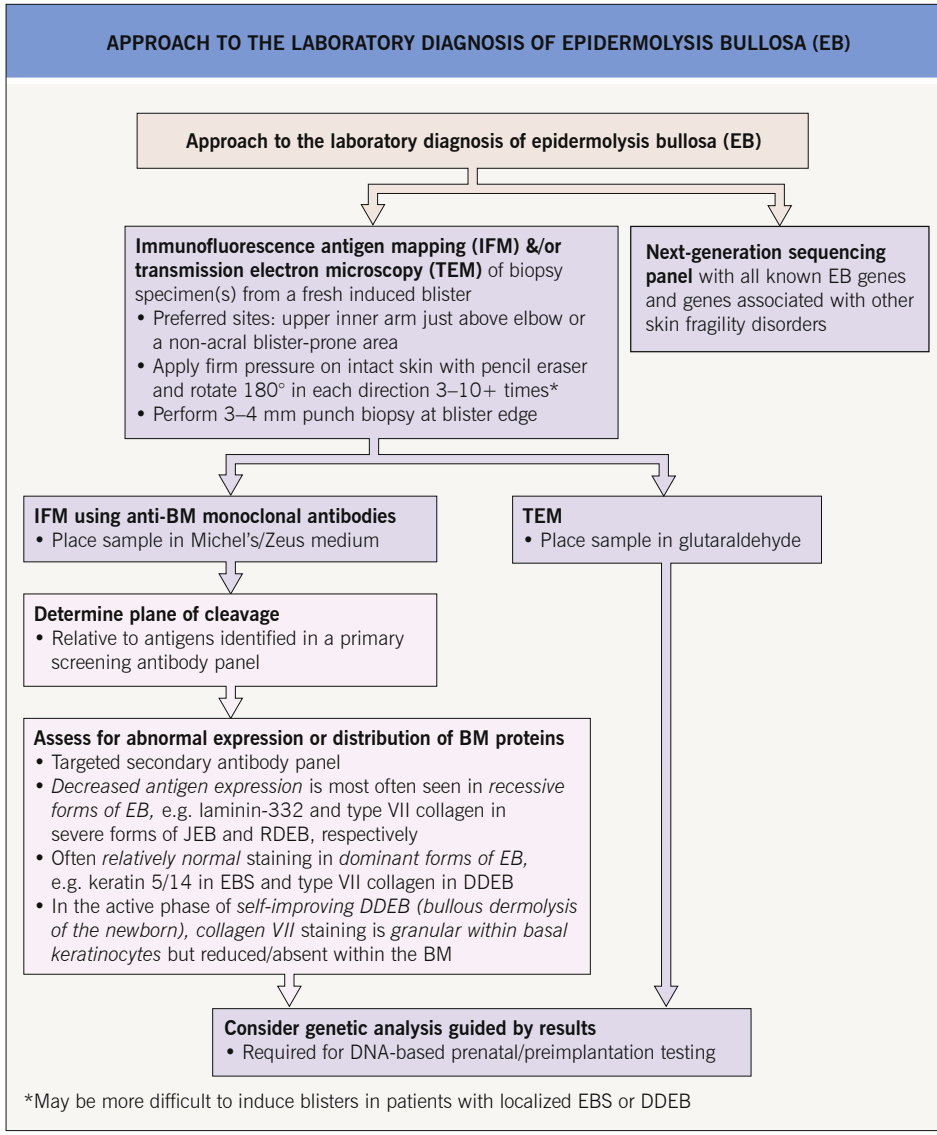


**Fig. 26.2 Approach to the laboratory diagnosis of epidermolysis bullosa (EB).** BM, basement membrane; DDEB, dominant dystrophic EB; EBS, EB simplex; JEB, junctional EB; RDEB, recessive dystrophic EB.

• Novel topical treatments (e.g. the interleukin-1β inhibitor diacerein and a betulin-based oleogel) as well as cell-based (e.g. hematopoietic stem cell transplantation) and gene therapies, including nuclease-based targeted gene editing techniques (e.g. CRISPR-Cas9 systems), are under investigation for EB patients.

• Physicians and families can obtain helpful information from websites such as www.debra.org and www.debra-international.org.

For further information see Ch. 32 from *Dermatology, Fourth Edition*.

**For additional online figures visit www.expertconsult.com**




**Fig. 26.3 Localized epidermolysis bullosa simplex. A, B** Bullae arising on the toes and plantar surfaces at sites of lateral or rotary traction. The majority of blisters occur in acral sites. *A, Courtesy, YDRSC; B, Courtesy, Julie V. Schaffer, MD.*




**Fig. 26.4 Severe forms of epidermolysis bullosa simplex (EBS). A** Arcuate array of vesicles in a child. **B** Blistering in association with focal keratoderma on the soles. **C** Widespread blistering in a toddler. *Courtesy, Julie V. Schaffer, MD.*

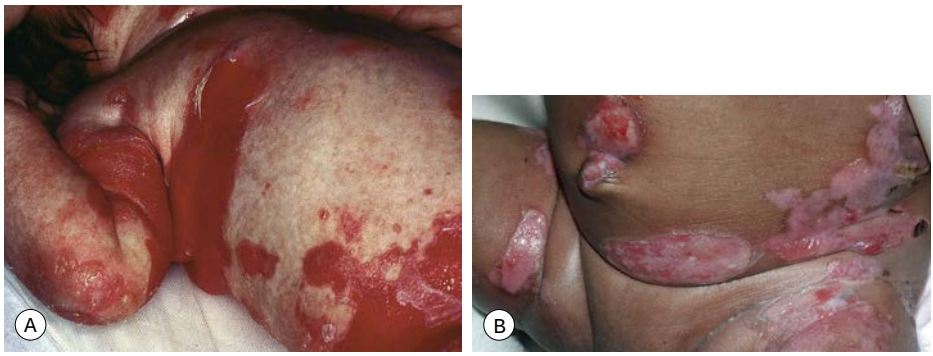


**Fig. 26.5 Severe junctional epidermolysis bullosa. A** Blisters on the elbow and large areas of denuded skin; note the bright red color in the axilla and groin. **B** Blisters and large erosions on the abdomen of an infant. *A, Courtesy, YDRSC; B, Courtesy, Julie V. Schaffer, MD.*




**Fig. 26.6 Dominant dystrophic epidermolysis bullosa.** Prominent scarring on the chest **(A)** and hands **(B)** as well as milia and loss of the fingernails **(B)** in a teenage boy. **C** Erosions, scarring, and milia on the fingers with partial loss of the nails. *A, C, Courtesy, YDRSC; B, Courtesy, Julie V. Schaffer, MD.*




**Fig. 26.7 Severe recessive dystrophic epidermolysis bullosa. A** Early proximal interdigital web formation together with atrophic scarring and loss of nails in a 5-year-old girl. **B** Large squamous cell carcinoma in a 21-year-old man. *Courtesy, Julie V. Schaffer, MD.*




**Fig. 26.8 Kindler syndrome. A** Erythema and atrophy on the dorsal hand. **B** Wrinkling due to atrophy and fusion between the fourth and fifth toes. **C** Poikiloderma of the face and neck with "skip" areas. *A, Courtesy, YDRSC; B, Courtesy, Jean L. Bolognia, MD.*

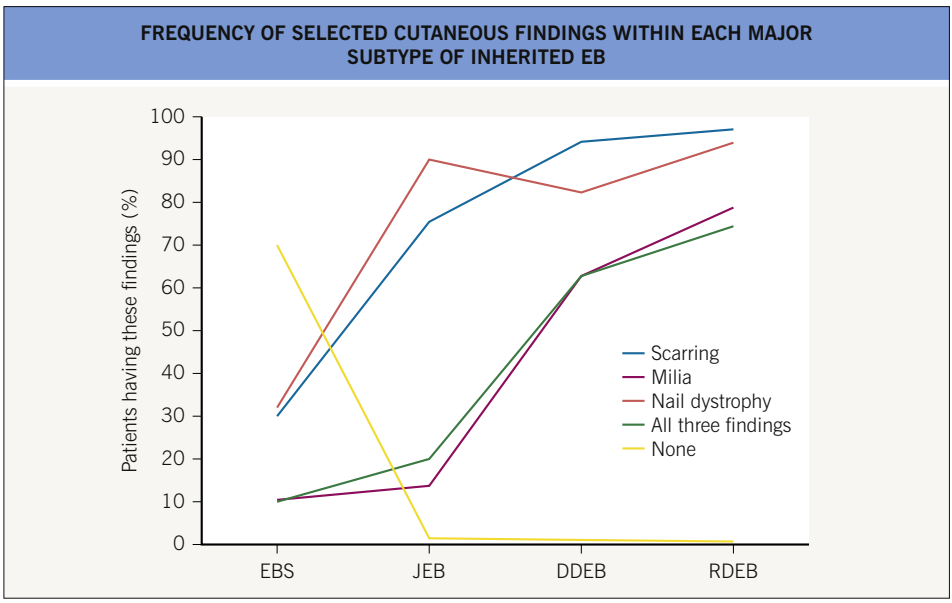


**Fig. 26.9 Frequency of selected cutaneous findings within each major subtype of inherited epidermolysis bullosa (EB).** Note the increasing frequency from localized EB simplex (EBS) to recessive dystrophic EB (RDEB). JEB, junctional EB; DDEB, dominant dystrophic EB.







**eFig. 26.1 Epidermolysis bullosa simplex (EBS). A** Diffuse palmar keratoderma in an adult. **B** Clustered vesicles in an arcuate array on the arm of a child. *A, Courtesy, YDRSC; B, Courtesy, Julie V. Schaffer, MD.*



**eFig. 26.2 Dominant dystrophic epidermolysis bullosa.** A discrete area of scarring on the elbow with blisters, crusting and milia. *Courtesy, YDRSC.*



**eFig. 26.3 Dystrophic epidermolysis bullosa, pruriginosa.** Prurigo-like papulonodules coalescing into linear plaques on the shin as a consequence of chronic scratching. *Courtesy, Jemima Mellerio, MD.*



**eFig. 26.4 Severe recessive dystrophic epidermolysis bullosa.** Partial pseudosyndactyly (mitten deformities) in an older child. *Courtesy, Jo-David Fine, MD.*

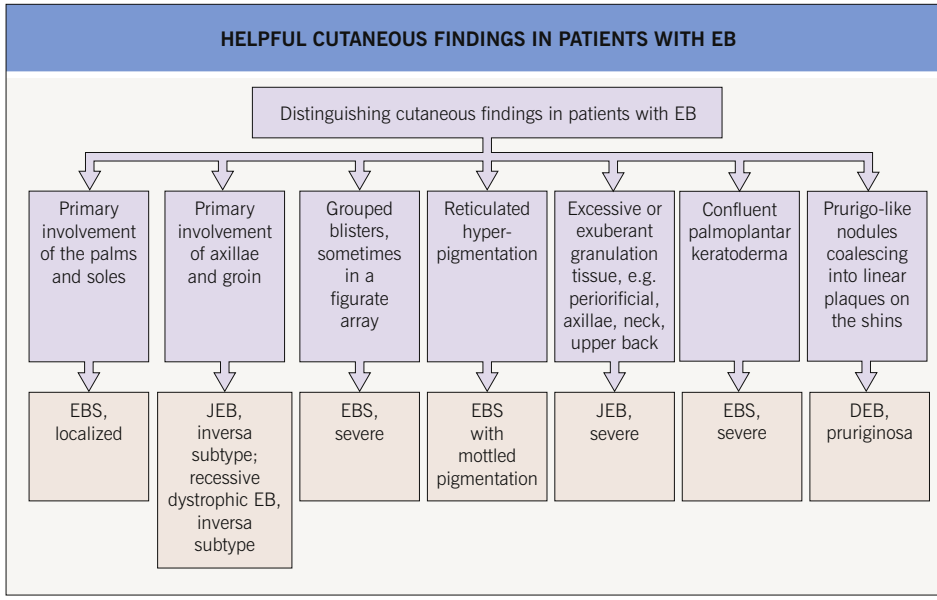


**eFig. 26.5 Helpful cutaneous findings in patients with epidermolysis bullosa (EB).** DEB, dystrophic EB; EBS, EB simplex; JEB, junctional EB.



**eFig. 26.6 Large acquired melanocytic nevus at a site of blistering in a teenage girl with junctional epidermolysis bullosa.** *Courtesy, Julie V. Schaffer, MD.*



**eFig. 26.7 Acral peeling skin syndrome.** Superficial peeling of the skin on the ankle and dorsal aspect of the foot. *Courtesy, E. Sprecher, MD, PhD.*

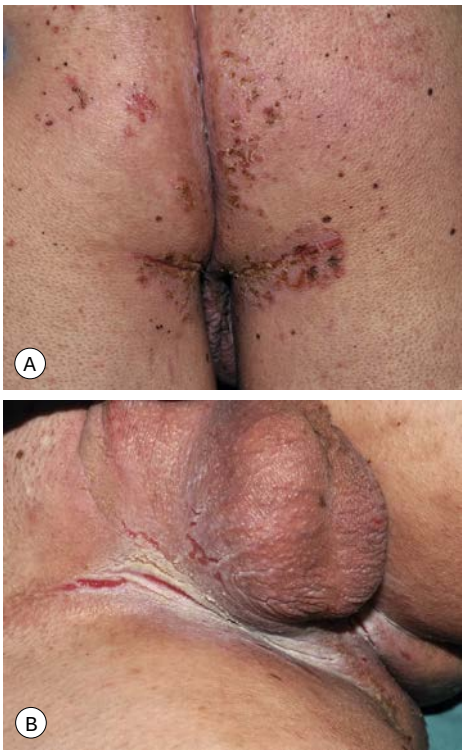


**eFig. 26.8 Skin fragility–ectodermal dysplasia syndrome due to plakophilin 1 deficiency.**
**A** Scattered erosions and crusts on the buttocks. **B** Macerated hyperkeratosis and fissures in the perineal area. *Courtesy, Antonio Torrelo, MD.*



**eFig. 26.9 SAVI (STING-*a*ssociated *v*asculopathy with onset in *i*nfancy).** This vasculopathic genetic disorder can result in digital resorption resembling that in recessive dystrophic epidermolysis bullosa.

# 27 Other Vesiculobullous Diseases

There are a number of disorders that can present with vesicles and bullae, including exaggerated insect bite reactions (Fig. 27.1; see Ch. 20), autoimmune and inherited blistering diseases (see Chs 23–26), porphyrias (see Ch. 41), the Stevens–Johnson syndrome–toxic epidermal necrolysis spectrum (see Ch. 16), and phototoxicity, from sunburn to phototoxic drug reactions (e.g. due to doxycycline). Even cutaneous small vessel vasculitis can become bullous (Fig. 27.2). This chapter examines a miscellaneous group of disorders, several of which favor the lower extremities, whereas Chapter 28 reviews vesiculobullous diseases in newborns and infants.

## Friction Blisters

- Most commonly develop on the heels, soles, and palms; the blister develops within the epidermis, contains clear or hemorrhagic fluid ("blood blister"), and heals spontaneously without scarring.
- Due to repeated friction (e.g. prolonged walking in ill-fitting shoes) and repetitive actions (e.g. raking leaves).



**Fig. 27.1 Bullous insect bite reactions.** The sterile blister fluid is serous and the ankle is a common site. *Courtesy, Luis Requena, MD.*

- **DDx:** if exaggerated response, can consider inherited blistering disease, in particular the localized form of epidermolysis bullosa simplex (see Ch. 26).
- **Rx:** if significant fluid accumulation, drainage of fluid can relieve pressure; the roof of the blister should be left in place to act as a "natural Band-Aid®"; secondary soft tissue infection is unusual in immunocompetent individuals.

## Edema Bullae (Edema Blisters)

- The bullae are bland (i.e. non-inflammatory), initially tense, and may reach several centimeters in diameter; they arise within areas of significant edema and contain sterile, usually clear but occasionally blood-tinged, fluid.
- The most common location is the distal lower extremities, often in the setting of an acute exacerbation of chronic edema in an elderly patient; in patients with anasarca and those who are bedridden, the distribution can be more widespread (Fig. 27.3).
- **DDx:** bullosis diabeticorum and bullous pemphigoid, including the variant localized to the lower extremities; if there is surrounding erythema, warmth and tenderness, then bullous cellulitis needs to be excluded.
- **Rx:** as bullae resolve in concert with the edema, only drainage of larger bullae needs to be considered (see section below).

## Bullosis Diabeticorum (Diabetic Bullae)

- In patients with diabetes mellitus, tense bland bullae arise rather suddenly within normal-appearing skin; the diameter varies from 0.5 to several centimeters (Fig. 27.4); the blister fluid is sterile and clear, but may be more viscous than that of friction or edema blisters.



**Fig. 27.2 Bullous variant of cutaneous small vessel vasculitis.** There is a background of purpuric papules and plaques. *Courtesy, Jeffrey P. Callen, MD.*



**Fig. 27.3 Edema bullae on the thigh of an infant.** The bullae are tense and are surrounded by edema. Desquamation from a ruptured bulla is also seen. *Courtesy, YDRSC.*



**Fig. 27.4 Bullosis diabeticorum.** A large, tense bulla overlying the medial malleolus. Note the absence of erythema or edema in the surrounding skin. *Courtesy, YDRSC.*

- Most commonly develops on the distal extremities (lower > upper) of adults and may be accompanied by peripheral neuropathy.
- **DDx:** bullous pemphigoid, epidermolysis bullosa acquisita, porphyria cutanea tarda, pseudoporphyria, bullous impetigo, and if significant edema, edema bullae; given the increased risk of soft tissue infections in diabetics, the possibility of bullous cellulitis needs to be excluded if there is surrounding erythema.
- **Rx:** placing a small window in a dependent location in the roof of the blister allows for both drainage and preservation of the blister roof; no further treatment is required for uncomplicated lesions, as they spontaneously heal over 3–6 weeks.

## Delayed Postburn/Postgraft Blisters

- Tense vesicles or bullae may develop within areas of previous thermal burns as well as within recipient or donor skin graft sites; occur weeks to months after initial injury has healed.
- Possible explanation is enhanced fragility due to a less mature basement membrane zone within the healing wound.
- **DDx:** limited given specific distribution, but includes ischemia within graft recipient sites, herpetic infections, bullous impetigo, and occasionally autoimmune bullous diseases (locus minoris resistentiae phenomenon).
- **Rx:** supportive as lesions heal spontaneously, but can recur.

## Coma Bullae (Coma Blisters)

- Tense cutaneous vesicles and bullae can appear within 2 or 3 days of prolonged pressure secondary to immobilization (Figs 27.5 and 27.6); there is often preceding blanchable erythema.
- The bullae develop at sites of maximum pressure and therefore often develop in the skin overlying joints or bony prominences.
- The prolonged pressure may occur in the setting of a coma, whose cause can vary from drug-induced to metabolic (e.g. hepatic encephalopathy); immobility can also result from neurologic disorders, especially cerebral vascular accidents.



**Fig. 27.5 Coma bullae.** Blisters developed in an area of pressure in a previously comatose patient. *Courtesy, José M. Mascaró Jr., MD.*



**Fig. 27.6 Neurologic blisters.** Tense blisters on the dorsal aspect of the fingers on the hemiplegic side of a patient with a previous cerebrovascular accident. *Courtesy, José M. Mascaró Jr., MD.*

- Characteristic histopathologic finding of necrosis of eccrine sweat glands, presumably secondary to local hypoxia.
- **DDx:** usually limited if history of immobilization obtained and distribution pattern limited to pressure points appreciated.
- **Rx:** supportive as lesions heal over 1 or 2 weeks; prevention requires frequent repositioning of the patient.

For further information see Ch. 33 from *Dermatology, Fourth Edition*.

**For additional online figures visit www.expertconsult.com**



**eFig. 27.1 Bullosis diabeticorum.** A tense blister on the palm as well as desquamation at sites of previous bullae. *Courtesy, José M. Mascaró Jr., MD.*



**eFig. 27.2 Bullous variant of cutaneous small vessel vasculitis.** *Courtesy, Jean L. Bolognia, MD.*

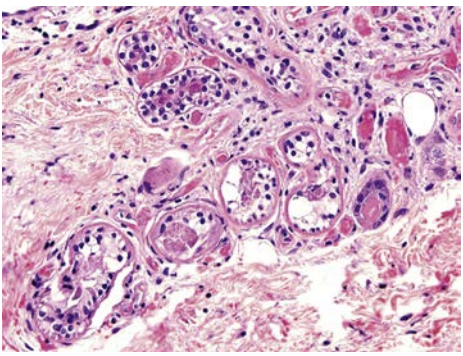

**eFig. 27.3 Bulla due to prolonged immobilization ("coma bulla") – histopathologic features.** Following a hip fracture, the patient remained immobilized on the floor for two days. Detection of the characteristic sweat gland necrosis aided in the diagnosis. *Courtesy, José M. Mascaró Jr., MD.*

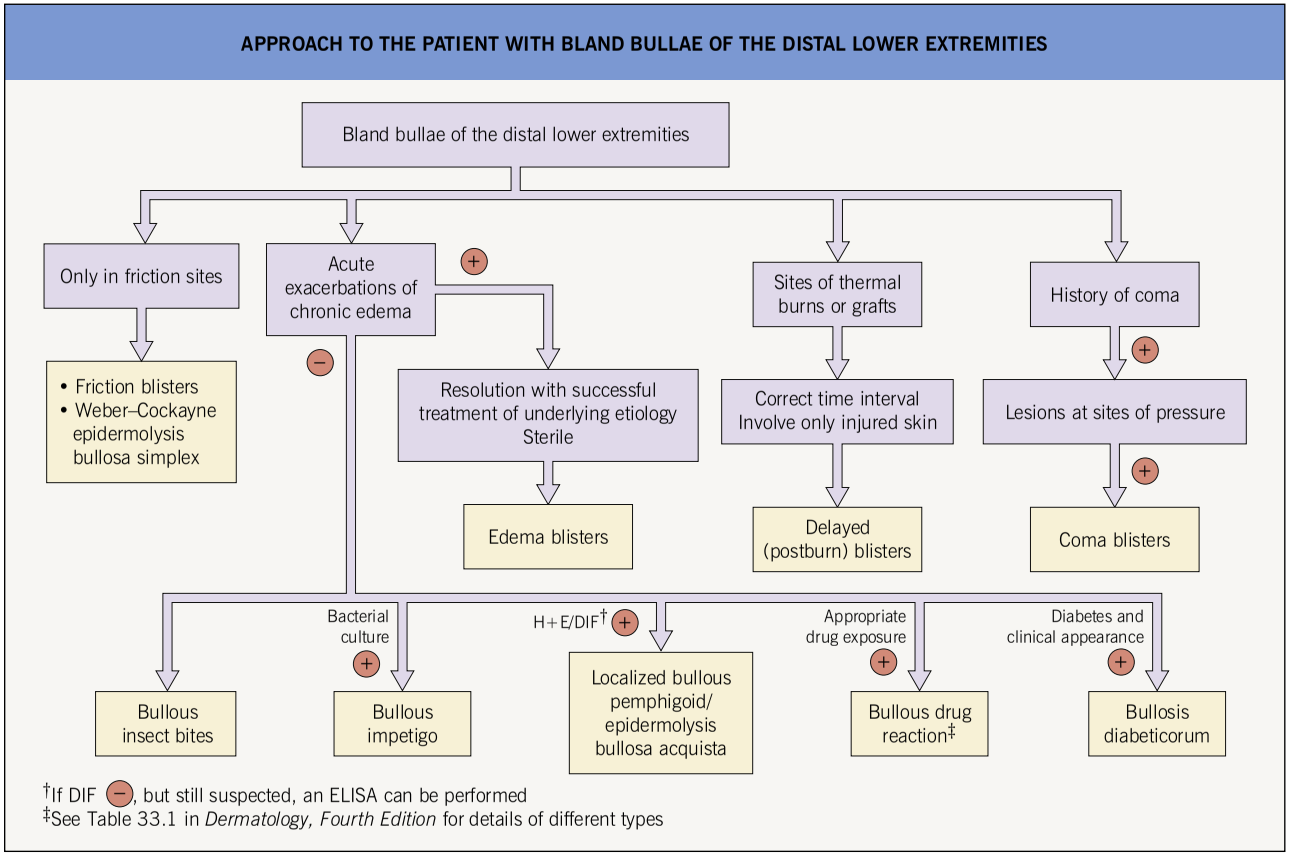


**eFig. 27.4 Approach to the patient with bland bullae of the distal lower extremities.**

# Vesiculopustular and Erosive Disorders in Newborns and Infants

# 28

This chapter covers classic transient neonatal eruptions as well as several infectious diseases and other disorders that present with vesiculopustules in the neonatal period or early infancy. Table 28.1 provides a more complete differential diagnosis of vesiculopustules, bullae, erosions, and ulcerations in neonates.

## Common Transient Conditions

### Erythema Toxicum Neonatorum ("e tox")

- Affects approximately half of full-term neonates; less common in premature infants.
- Typically appears 1–2 days after delivery and lasts up to 2 weeks, with individual lesions resolving within 1 day; occasionally present at birth, and rarely develops as late as 1 to 2 weeks of age.
- Various combinations of erythematous macules, wheals, and small (≤2 mm) papules, pustules, and vesicles surrounded by a larger erythematous flare (Fig. 28.1); lesions may be grouped at sites of mechanical irritation.
- Often begins on the face and progresses to the trunk, buttocks, and proximal extremities; usually spares the palms and soles.
- Wright or Giemsa stain of pustular contents shows numerous eosinophils.
- **Rx:** none.

### Transient Neonatal Pustular Melanosis

- Affects up to 5% of full-term neonates with darkly pigmented skin; less common in Caucasian newborns. May exist on a spectrum with erythema toxicum neonatorum.
- Lesions are almost always present at birth.
- Three stages, any of which may be present at a given time (Fig. 28.2).
  - 2- to 10-mm superficial vesiculopustules with little or no surrounding erythema
  - Collarettes of scale at sites of ruptured vesiculopustules
  - Residual brown macules representing postinflammatory hyperpigmentation, which may persist for several months
- Any region can be affected, but favors the forehead, chin, neck, lower back, and shins.
- Wright or Giemsa stain of pustular contents shows neutrophils > eosinophils.
- **Rx:** none.

### Miliaria (Heat Rash)

- Common condition in newborns, especially with overheating related to excessive swaddling, warming in an incubator, fever, occlusive dressings, and hot climates.
- Caused by blockage of eccrine sweat ducts.
- Miliaria crystallina.
  - Small clear vesicles (likened to "dew drops") without surrounding erythema (Fig. 28.3A); they are fragile and therefore short-lived
  - Most often on the forehead, upper trunk, and arms
- Miliaria rubra.
  - Usually develops at ≥1 week of age
  - Small erythematous papules, sometimes with a tiny central pustule or vesicle (Fig. 28.3B see Fig. 32.7C)
  - Favors the neck, upper trunk, and occluded areas
- **Rx:** avoid overheating and occlusion; bathing with lukewarm water.

### Neonatal Cephalic Pustulosis (Neonatal Acne)

- Affects ~20% of newborns.
- Onset usually within the first 2–3 weeks of life, with spontaneous resolution by 3 months of age.
- Papulopustular eruption on the face (cheeks > forehead, chin, eyelids) (Fig. 28.4) > neck, upper chest, and scalp.

| DIFFERENTIAL DIAGNOSIS OF NEONATAL VESICULOPUSTULES, BULLAE, EROSIONS, AND ULCERS |
|---|
| **Vesiculopustular eruptions** |
| **Infectious diseases and infestations** |
| • Bacterial (see Ch. 61): bullous impetigo; group A>B streptococcal or *Listeria* infection<br>• Candidiasis (congenital or neonatal)<br>• Viral (see Ch. 67): HSV infection, neonatal varicella, herpes zoster (age ≥2 weeks)<br>• Scabies (age ≥3–4 weeks) (see Ch. 71) |
| **Common transient conditions** |
| • Erythema toxicum neonatorum, transient neonatal pustular melanosis<br>• Miliaria crystallina and rubra<br>• Neonatal cephalic pustulosis |
| **Uncommon and rare non-infectious diseases** |
| • Acropustulosis of infancy, eosinophilic pustular folliculitis of infancy<br>• Incontinentia pigmenti<br>• Congenital Langerhans cell histiocytosis (Fig. 28.11) (see Ch.76)<br>• Neonatal papulopustular eruption of autosomal dominant hyper-IgE syndrome (see Ch. 49), neutrophilic and granulomatous dermatitis associated with primary immunodeficiencies<br>• Vesiculopustular eruption* of transient myeloproliferative disorder in Down syndrome<br>• Pustular psoriasis (see Ch. 6), deficiency of the interleukin-1 receptor antagonist (DIRA; see Ch. 37)<br>• Erosive pustular dermatosis of the scalp (more common in older adults) |
| **Bullae, erosions, and ulcers** |
| **Infectious diseases** |
| • Bacterial (see Ch. 61): staphylococcal scalded skin syndrome (Fig. 28.12), *Pseudomonas* infection (including noma neonatorum)†, congenital syphilis<br>• Fungal** (see Ch. 64): aspergillosis, zygomycosis<br>• Intrauterine HSV infection, congenital varicella (see Ch. 67) |
| **Conditions with exogenous causes** |
| • Sucking blister, perinatal/iatrogenic injury, irritant contact dermatitis (see Ch. 12) |
| **Uncommon and rare non-infectious diseases** |
| • Mastocytosis (Fig. 28.13; see Ch. 96), ulcerated infantile hemangioma (see Ch. 85)<br>• Aplasia cutis congenita (Fig. 28.14; see Ch. 53)<br>• Genodermatoses, especially epidermolysis bullosa (see Ch. 26) and epidermolytic ichthyosis (Fig. 28.15; see Ch. 46)<br>• Zinc deficiency, acquired or inherited (acrodermatitis enteropathica; see Ch. 43)<br>• Autoimmune bullous diseases (often due to maternal antibodies; see Chs 22–25)<br>• Maternofetal or transfusion-associated GVHD in infants with SCID (see Ch. 49)<br>• Congenital erosive and vesicular dermatosis<br>• Nutritional dermatitis (see Fig. 43.4) |
| **Favors the cheeks.*<br>***Evolves into necrotic ulcers; risk factors include prematurity and occlusion; "invasive fungal dermatitis" in very-low-birth-weight premature neonates can be caused by* Aspergillus *or* Trichosporon *as well as* Candida *spp.; biopsy for tissue culture and histopathology can aid in the diagnosis.*<br>*†Evolves into necrotic ulcers that favor the groin; risk factors include prematurity, immunodeficiency, and (especially for noma) malnutrition.* |

**Table 28.1 Differential diagnosis of neonatal vesiculopustules, bullae, erosions, and ulcers.** This list is not exhaustive, as other rare diseases such as ankyloblepharon–ectodermal dysplasia–clefting (AEC) syndrome and congenital Behçet disease can have vesiculopustular and erosive presentations. SCID, severe combined immunodeficiency.

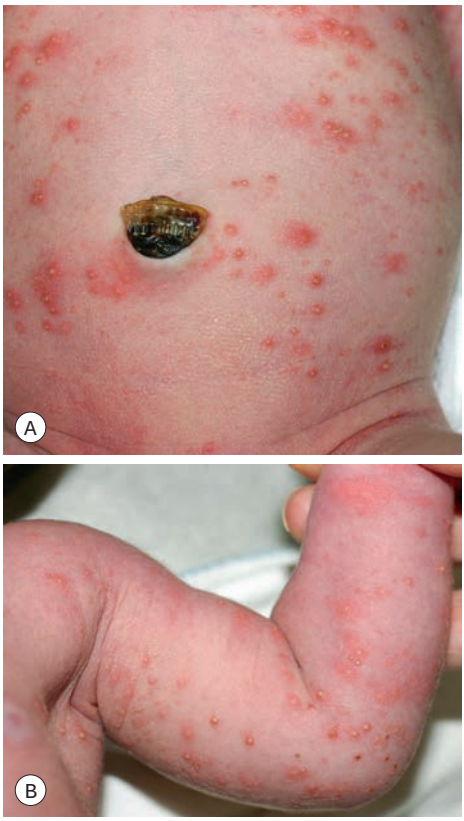

**Fig. 28.1 Erythema toxicum neonatorum.** Scattered papulovesicles and pustules with an erythematous flare on the abdomen (**A**) and upper extremity (**B**). *Courtesy, Deborah S. Goddard, MD, Amy E. Gilliam, MD, and Ilona J. Frieden, MD.*

- An absence of comedones in neonatal cephalic pustulosis distinguishes it from infantile acne, which typically develops at 3–12 months of age and is more persistent (see Ch. 29).
- May represent an inflammatory response to *Malassezia* spp., a normal component of the skin microbiome that may also trigger seborrheic dermatitis.
- **Rx:** usually not required; topical imidazole (e.g. ketoconazole cream) or hydrocortisone may be helpful.

### Sucking Blister

- Caused by habitual sucking of the affected area *in utero*, and resolves spontaneously within days to weeks of birth.
- Intact bulla, erosion, callus, or ulceration on a non-inflamed base (Fig. 28.5A).
- Common sites include the radial forearm, wrist, hand, and fingers.

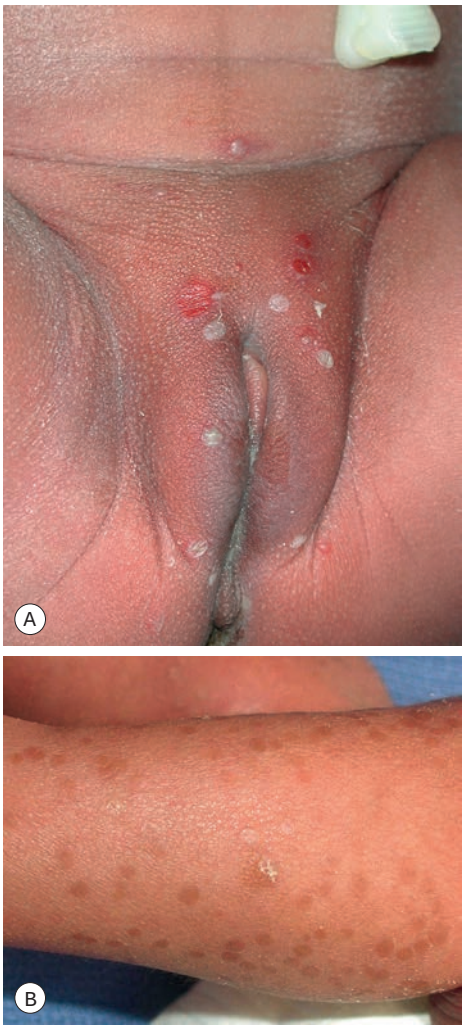

**Fig. 28.2 Transient neonatal pustular melanosis in an African-American neonate. A** One hour after birth, flaccid vesiculopustules and superficial erosions with minimal surrounding erythema are present in the groin. **B** On the 8th day of life, hyperpigmented macules and a few collarettes of scale are evident on the lower leg. *Courtesy, YDRSC.*

## Infectious Diseases

### Cutaneous Candidiasis

- *Congenital* candidiasis.
  - Uncommon condition that is acquired *in utero*; risk factors include maternal vaginal candidiasis, a foreign body in the uterus or cervix, and prematurity
  - Evident at birth or during the first week of life
  - Findings range from erythematous papules and pustules with fine scaling







**Fig. 28.3 Miliaria. A** Tiny, superficial vesicles, seen on the back and neck of this newborn, are characteristic of miliaria crystallina. **B** Widespread miliaria rubra with numerous small papules and pustules. *A, From Eichenfield LF, Frieden IJ, Esterly NB, et al (Eds).* Textbook of Neonatal Dermatology. *© 2001 Saunders. B, Courtesy, Antonio Torrelo, MD.*

in full-term neonates to an *"invasive fungal dermatitis"* presenting as diffuse, "burn-like" erythema and erosions in premature infants with a very low birth weight (often <1000 g; Fig. 28.6A, B)
  - Often widespread involvement on the face, trunk, and extremities; the palms, soles, and nails (yellow discoloration, transverse ridging) are frequently affected, but the diaper area and oral mucosa are typically spared
  - **Dx:** budding yeast and pseudohyphae are seen in a potassium hydroxide preparation of skin scrapings, and culture grows *Candida* spp. (usually *C. albicans*)
  - **Rx:** premature infants (especially if <1500 g) are at high risk for disseminated candidiasis and require systemic antifungal agents, as do full-term neonates with extracutaneous involvement (e.g. pneumonia); most full-term neonates have skin-limited disease that can be treated with topical antifungals (e.g. an imidazole cream)
- *Neonatal* candidiasis (see Ch. 64).
  - Common condition that presents at ≥1 week of age as intense erythema with desquamation and satellite papulopustules, favoring the diaper area > other intertriginous sites (see Fig. 13.4); patients may also have oral thrush
  - **Rx:** topical imidazole or nystatin



**Fig. 28.4 Neonatal cephalic pustulosis.** Papulopustules on the forehead and cheeks of a 3-week-old infant. *Courtesy, Julie V. Schaffer, MD.*

## Staphylococcal Infections – Pyoderma and Bullous Impetigo (See Ch. 61)

- Presents as early as a few days of age with pustules, flaccid vesicles or bullae evolving to superficial shiny red erosions with collarettes of scale, and occasionally furuncles.

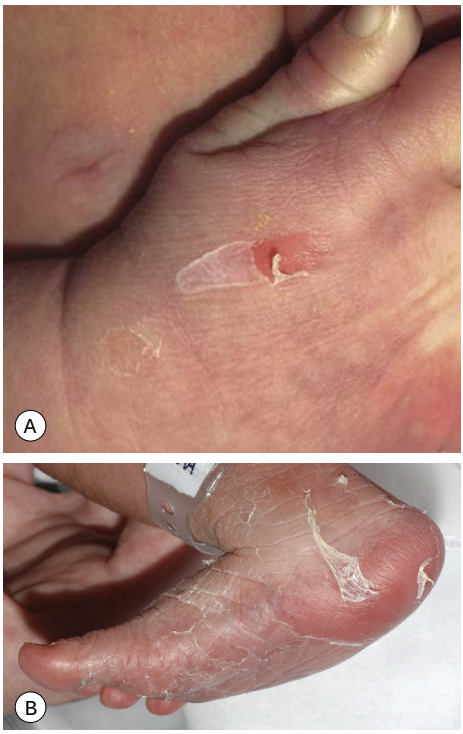

**Fig. 28.5 Physiologic skin findings in neonates. A** Sucking blister. **B** Post-term desquamation is often most evident acrally. *A, Courtesy, Ana Martín, MD. B, Courtesy, Julie V. Schaffer, MD.*

- Favors the diaper area and other intertriginous sites (Fig. 28.6C; see Fig. 13.4).
- **Dx:** Gram stain shows Gram-positive cocci in clusters, and culture grows *Staphylococcus aureus*.
- **Rx:** topical antibiotic (e.g. mupirocin) for uncomplicated localized pustulosis or bullous impetigo; systemic anti-staphylococcal antibiotic if more extensive or deeper involvement, using an intravenous agent, e.g. vancomycin, if the patient is toxic-appearing.

## Neonatal Herpes Simplex Virus (HSV) Infection (See Ch. 67)

- Risk of transmission is highest (30–50%) for a mother with her first episode of genital HSV infection (which may be asymptomatic) near the time of delivery and low (<1–3%) for recurrent genital herpes.
- Onset from birth to 2 weeks, but usually ≥5 days of age.



**Fig. 28.6 Congenital candidiasis and bullous impetigo. A** Numerous pink papules admixed with small superficial pustules and desquamation due to congenital candidiasis in a full-term neonate. Note the plantar involvement. **B** Widespread "burn-like" erosions due to congenital candidiasis in a premature neonate born at 24 weeks' gestation. This presentation is associated with a high risk of systemic involvement. **C** Multiple discrete superficial pustules with surrounding erythema in the diaper area of a 4-day-old boy due to infection with *Staphylococcus aureus*. *Courtesy, Julie V. Schaffer, MD.*

- Localized (favoring the scalp and trunk) or disseminated vesicles, pustules, and crusts; lesions are often grouped and may progress to bullae and erosions with scalloped borders (Fig. 28.7).
- Involvement of the oral mucosa, eye, CNS, and other internal organs can occur.
- **Rx:** intravenous acyclovir.



**Fig. 28.7 Neonatal HSV infection.** Note the clustering of the vesicles on an erythematous base. *Courtesy, Julie V. Schaffer, MD.*

## Uncommon Conditions

### Eosinophilic Pustular Folliculitis of Infancy

- Onset often in the first few months of life, with cyclical recurrences for several months to years.
- Pruritic perifollicular pustules and crusts favoring the scalp (Fig. 28.8) and forehead.
- **DDx:** Erythema toxicum neonatorum (in neonates), bacterial folliculitis, tinea capitis, scabies, arthropod bite reactions.
- **Rx:** potent topical CS (intermittently for flares), oral antihistamines.

### Acropustulosis of Infancy (Infantile Acropustulosis)

- Favors darkly pigmented male infants, sometimes representing a persistent hypersensitivity reaction following successful scabies treatment.
- Onset usually between 3 and 6 months of age; occasionally develops in newborns.
- Pruritic vesicles and pustules on the hands and feet (including palms/soles) (Fig. 28.9) > wrists and ankles.
- Outbreaks last 1–2 weeks, with cyclical recurrences until 2–3 years of age.
- **DDx:** scabies.
- **Rx:** potent topical CS (intermittently for flares), oral antihistamines.



**Fig. 28.8 Eosinophilic pustular folliculitis of infancy.** Crusted papules and pustules on the scalp of a 1-year-old boy. *Courtesy, Deborah S. Goddard, MD, Amy E. Gilliam, MD, and Ilona J. Frieden, MD.*

### Incontinentia Pigmenti (IP) (See Ch. 51)

- Multisystem X-linked disorder caused by mutations in the *NEMO* gene (NF-κB essential modulator); usually lethal in male fetuses.
- Typically presents in the first 2 weeks of life with vesicles on an inflammatory base in linear streaks that favor the extremities (Fig. 28.10); in subsequent weeks, verrucous streaks may develop, followed by more widespread linear and whorled grayish-brown hyperpigmentation.
- Extracutaneous findings in neonates with IP can include peripheral eosinophilia, leukocytosis, seizures, and retinal vascular abnormalities.

For further information see Ch. 34 from *Dermatology, Fourth Edition*.

**For additional online figures visit www.expertconsult.com**



**Fig. 28.9 Acropustulosis of infancy.** Multiple vesiculopustules with an erythematous base on the heels of an infant. *Courtesy, Julie V. Schaffer, MD.*



**Fig. 28.11 Congenital Langerhans cell histiocytosis.** Numerous erosions with crusting on the face and trunk of a newborn. *Courtesy, Deborah S. Goddard, MD, Amy E. Gilliam, MD, and Ilona J. Frieden, MD.*



**Fig. 28.10 Incontinentia pigmenti stage 1.** Vesicles and erythema in a linear and whorled configuration on the trunk, arm, and ear of a female neonate. *Courtesy, Luis Requena, MD.*



**Fig. 28.12 Staphylococcal scalded skin syndrome.** Perioral and periorbital erythema and scale-crust in a neonate due to exfoliative toxins. *Courtesy, Julie V. Schaffer, MD.*







**eFig. 28.1 Bullous mastocytosis. A** Tense bulla on the wrist and flaccid bullae on the dorsal hand as well as pink-tan plaques on the trunk in a 1-month-old infant. **B** Tense bulla overlying a mastocytoma on the lower back in a 4-month-old boy. *A, Courtesy, Deborah S. Goddard, MD, Amy E. Gilliam, MD, and Ilona J. Frieden, MD; B, Courtesy, Julie V. Schaffer, MD.*



**eFig. 28.2 Aplasia cutis congenita (ACC) of the forearm.** ACC in this location can be associated with underlying neurologic impairment, referred to as congenital Volkmann ischemic contracture, or bone abnormalities. The angulated borders help to distinguish it from intrauterine HSV or VZV infection. *Courtesy, Julie V. Schaffer, MD*



**eFig. 28.3 Epidermolytic ichthyosis.** Diffuse scaling and a large erosion with scale-crust in a neonate. *Courtesy, YDRSC.*



**eFig. 28.4 Erythema toxicum neonatorum.** Scattered papulovesicles with an erythematous flare. *Courtesy, Kalman Watsky, MD.*



**eFig. 28.5 Transient neonatal pustular melanosis.** Pustules, hyperpigmented macules, and collarettes of scale are seen on the chin and neck of an African-American neonate. *Courtesy, YDRSC.*



**eFig. 28.6 Bullous impetigo.** Multiple superficial erosions with collarettes of scale in the diaper area of an infant with bullous impetigo. Note the scattered vesiculopustules. *Courtesy, YDRSC.*




**eFig. 28.7 Neonatal HSV infection.** Note the clustering of the vesicles on an erythematous base. *Courtesy, YDRSC.*










**eFig. 28.8 Acropustulosis of infancy.** Multiple vesiculopustules with an erythematous base on the medial ankle (**A**), sole (**B**), and fingers (**C**). *A, C, Courtesy, Deborah S. Goddard, MD, Amy E. Gilliam, MD, and Ilona J. Frieden, MD; B, Courtesy, YDRSC.*



**eFig. 28.9 Staphylococcal scalded skin syndrome.** Radiating perioral scale-crusts due to exfoliative toxins. *Courtesy, YDRSC.*



**eFig. 28.10 Incontinentia pigmenti stage 1.** Admixture of erythematous streaks containing vesicles and yellow–brown streaks with scale on the lower extremity. *Courtesy, Julie V. Schaffer, MD.*



**eFig. 28.11 Incontinentia pigmenti stage 1.** Multiple vesicles and bullae with an erythematous border on the lower extremity. *Courtesy, Anthony J. Mancini MD.*



**eFig. 28.12 Aplasia cutis congenita.** Ulcerations on the vertex of the scalp may be misdiagnosed as an HSV infection. The angulated appearance of the larger ulceration would not be characteristic of HSV infection. *Courtesy, YDRSC.*



**eFig. 28.13 Diffuse cutaneous mastocytosis in an infant.** Diffusely infiltrated skin with multiple erosions and a leathery texture. *Courtesy, YDRSC.*




**eFig. 28.14 Congenital erosive and vesicular dermatosis. A, B** Widespread bright red, irregularly shaped erosions on the buttocks, thighs and back of a 2-week-old infant. Note the jagged outline of the healing lesion on the back. **C** Residual supple and reticulate scarring in a 9-month-old child. *A, B, Courtesy, Anthony J. Mancini, MD; C, Courtesy, Julie V. Schaffer, MD.*



**eFig. 28.15 Neonatal pemphigoid gestationis.** Vesiculobullous lesions in a neonate whose mother had active pemphigoid gestationis. *Courtesy, Jean L. Bolognia, MD.*

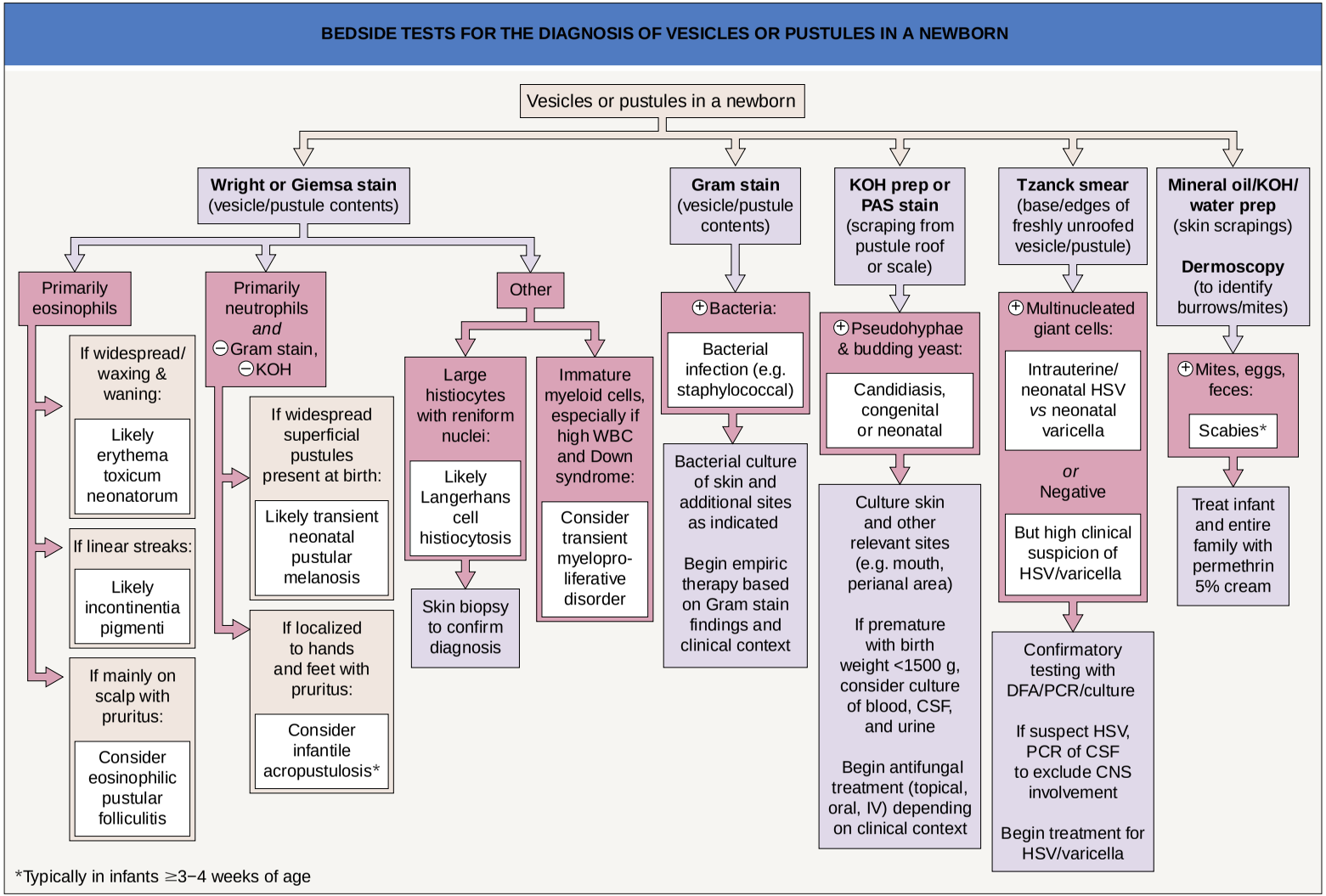


**eFig. 28.16 Bedside tests for the diagnosis of vesicles or pustules in a newborn.**

# 29 Acne Vulgaris

• Common pilosebaceous disorder that occurs in ~85% of individuals 12–24 years of age and 15–35% of adults (especially women) in their 30s–40s. Preadolescent acne affecting children between 7 and 11 years of age has also become more common due to the trend for earlier onset of puberty.
• Clinical presentations range from mild comedones to severe, explosive eruptions of suppurative nodules associated with systemic manifestations.
• May result in scarring and psychosocial repercussions such as anxiety, depression, and social withdrawal.
• A tendency to develop moderate to severe acne can run in families.
• Multiple factors affecting the pilosebaceous unit contribute to acne pathogenesis (Fig. 29.1), a process that typically begins when androgen production increases at adrenarche.
• The relationship between diet and acne is controversial, with some evidence of possible associations with milk intake (especially skim milk), whey protein supplements, and a high glycemic index diet.

## Clinical Features and Variants of Acne

• Favors the face and upper trunk, sites with well-developed sebaceous glands.
• Non-inflammatory acne
  – *Closed comedones (whiteheads)* are small (~1 mm), skin-colored papules without an obvious follicular opening (Fig. 29.2)
  – *Open comedones (blackheads)* have a dilated follicular opening filled with a keratin plug, which has a black color due to oxidized lipids and melanin (Figs 29.2 and 29.3A)
• Inflammatory acne
  – Erythematous papules and pustules (Fig. 29.3A,B)
  – Nodules and pseudocysts filled with pus or serosanguinous fluid; may coalesce and form sinus tracts (Fig. 29.3B,C)
  – *Acne conglobata* (severe nodulocystic acne) is classified in the follicular occlusion tetrad along with dissecting cellulitis of the scalp, hidradenitis suppurativa, and pilonidal cysts (see Ch. 31); it is also a part of syndromes such as *p*yogenic *a*rthritis, *p*yoderma gangrenosum, and *a*cne conglobata (PAPA); *p*yoderma gangrenosum, *a*cne, and *s*uppurative *h*idradenitis (PASH); and *p*yoderma gangrenosum, *a*cne, *p*soriasis, *a*rthritis, and *s*uppurative *h*idradenitis (PAPASH)
• Inflammatory acne commonly results in postinflammatory hyperpigmentation, especially in patients with darker skin, which fades slowly over time (Fig. 29.4A); nodulocystic acne (and less frequently other inflammatory > comedonal forms) often leads to pitted (Fig. 29.4B) or hypertrophic scars (the latter especially on the trunk; see Fig. 81.4).

### Post-Adolescent Acne

• Age >25 years; favors women and may be associated with psychological stress.
• Tends to flare in the week prior to menstruation; up to one-third of these women have hyperandrogenism.
• Typically features papulonodules on the lower face, jawline, and neck.

### Acne Excoriée

• Favors teenage girls and young women.
• Habitual picking at comedones and inflammatory papules, resulting in crusted erosions (often linear/angular) and potential scarring (see Fig. 5.4).
• Some patients have an underlying obsessive–compulsive or anxiety disorder.

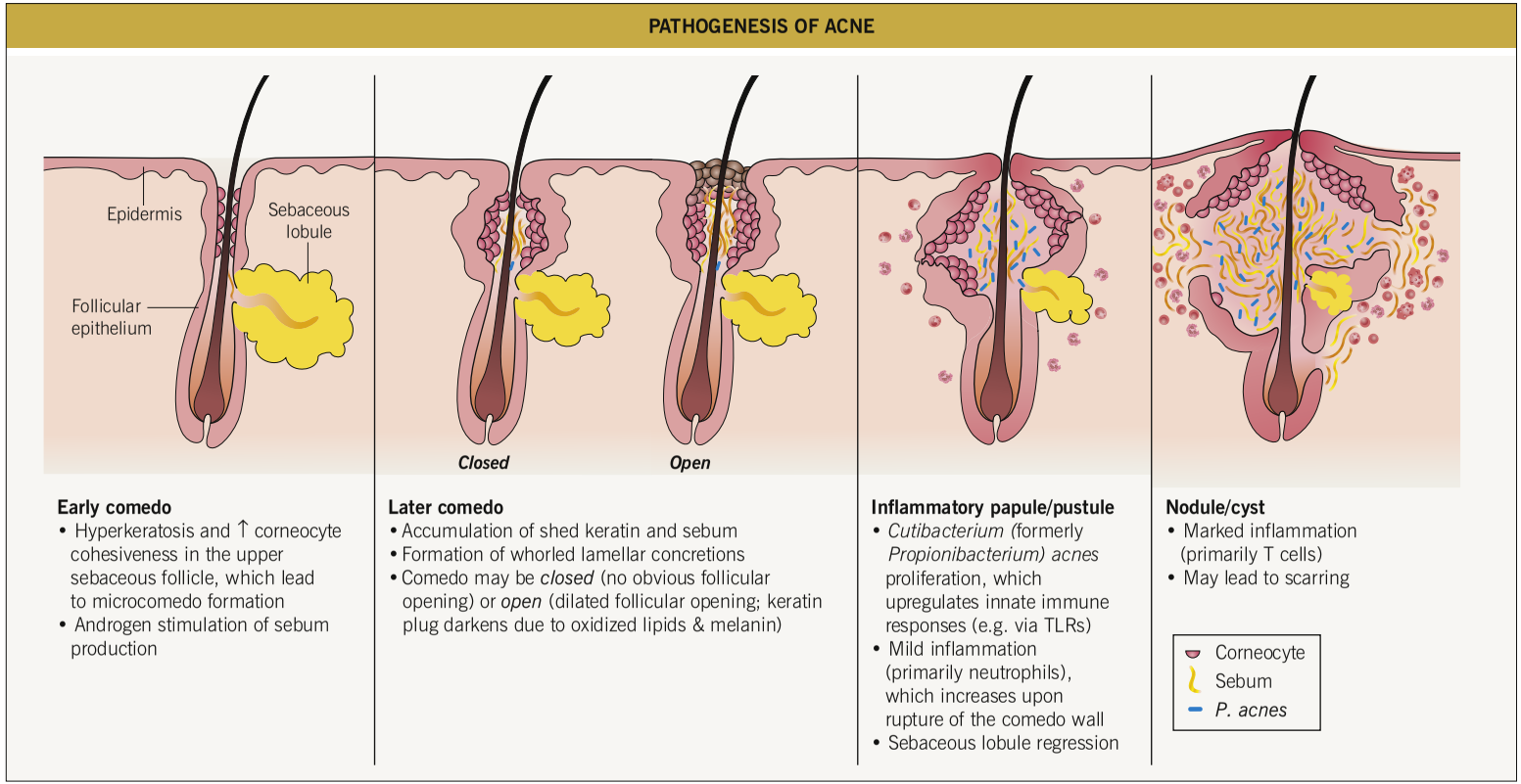


**Fig. 29.1 Pathogenesis of acne.** TLRs, toll-like receptors.




**Fig. 29.2 Comedonal acne vulgaris.** On the cheek (**A**) and forehead (**B**), there are open and closed comedones as well as postinflammatory hyperpigmentation (**A**) and inflammatory papules (**B**). *A, Courtesy, Andrew Zaenglein, MD, and Diane Thiboutot, MD; B, Courtesy, Kalman Watsky, MD.*

### Acne Fulminans

- Favors boys 13 to 16 years of age.
- Sudden development of numerous, markedly inflamed nodular lesions on the face, trunk, and upper arms.
- Coalescence into painful, oozing, friable plaques with hemorrhagic crusting, erosion/ulceration, and eventual scarring (Fig. 29.5).
- Systemic manifestations may include fever, malaise, myalgias, arthralgias, osteolytic bone lesions (most often of clavicles and sternum), and hepatosplenomegaly.
- Laboratory findings: leukocytosis and increased ESR/CRP > anemia and proteinuria.
- **DDx:** an acne fulminans-like flare is occasionally triggered by isotretinoin therapy for acne (especially when initiated at a higher dose and in younger teenage boys), and acne fulminans can be associated with *s*ynovitis, *a*cne, *p*ustulosis, *h*yperostosis, and *o*steitis (SAPHO) syndrome (see Ch. 21).
- **Rx:** prednisone 0.5–1 mg/kg/day as monotherapy for 2–6 weeks (until inflammation subsides), followed by addition of low-dose isotretinoin (e.g. 0.1 mg/kg/day) for ~4 weeks, and then a prednisone taper and slow increase of the isotretinoin dose over 1–2 months.

### Solid Facial Edema (Morbihan Disease)

- Woody induration ± erythema of the central face in the setting of chronic inflammation due to acne vulgaris or rosacea (Fig. 29.6).
- **Rx:** isotretinoin (may require an extended course).

### Neonatal Acne (Neonatal Cephalic Pustulosis) (see Ch. 28)

- Age 2 weeks to 3 months.
- Facial papulopustular eruption thought to be triggered by *Malassezia* spp.; comedones are *not* present (see Fig. 28.4).

### Infantile Acne

- Onset usually at 2–12 months of age; favors boys.
- Facial comedones, papulopustules, and nodules as in classic acne (Fig. 29.7); may result in scarring.
- Reflects physiologic elevation of androgen levels in infants 6–12 months of age (especially boys); patients often have a family history of severe acne.
- **Rx:** similar to adolescent acne; typically resolves within 6–18 months, becoming quiescent until puberty.

### Acne Associated with Endocrinologic Abnormalities

- Hyperandrogenism should be suspected in children who develop acne between 2 and 7 years of age (*mid-childhood acne*), in older adolescents/women with irregular menses, and in female patients with signs of virilization (see Table 29.1 and Ch. 57).

### Contact Acne

- *Acne mechanica*: comedogenesis due to chronic friction/occlusion from objects such as chin straps, helmets, collars, and musical instruments (e.g. "fiddler's neck" in a violinist).
- *Acne cosmetica*, *pomade acne*, and *occupational acne*: comedogenesis caused by exposure to follicle-occluding substances in




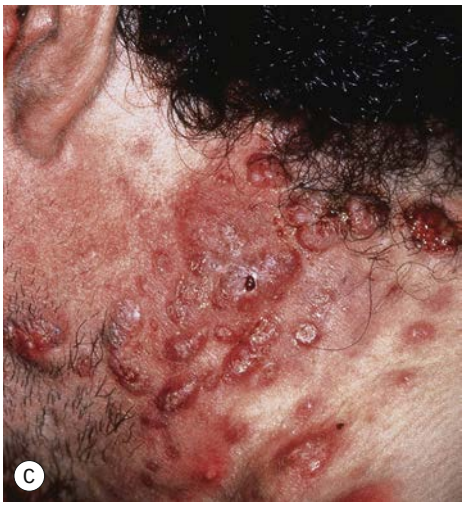





**Fig. 29.3 Inflammatory acne vulgaris.** **A** Inflammatory papules and pustules as well as both open and closed comedones are evident. Note the nodular lesion on the temple, scarring in the preauricular area, and open comedones in the concha of the ear. **B** Multiple papulopustules and papulonodules on the cheek with a sinus tract, linear scarring and depressions along the jawline. **C** Severe nodulocystic acne. This form is best treated with low doses of isotretinoin initially (± a preceding course of oral antibiotics) to avoid precipitating a flare. *A, Courtesy, Andrew Zaenglein, MD, and Diane Thiboutot, MD; B, Courtesy, Julie V. Schaffer, MD; C, Courtesy, YDRSC.*

cosmetics, hair products (favoring forehead and temples), and materials used in the workplace (e.g. cutting oils, coal tar derivatives).

### Chloracne

- Results from exposure (usually occupational) to halogenated aromatic hydrocarbons (e.g. polychlorinated dibenzodioxins and dibenzofurans) in agents such as herbicides and insecticides.
- Comedones and cystic papulonodules develop within 2 months of exposure, favoring malar and retroauricular areas of the face (see Fig. 12.19) as well as the axillae and scrotum; often persists for years.

### Drug-Induced Acne and Acneiform Eruptions

- Systemic CS can trigger an eruption of monomorphous follicular papulopustules favoring the upper trunk (Fig. 29.8).
- Acneiform eruptions represent a frequent side effect of epidermal growth factor receptor (EGFR) inhibitors (e.g. cetuximab, erlotinib) used to treat solid tumors; patients present with follicular pustules and papules on the face, scalp, and upper trunk, usually 1–3 weeks after beginning treatment, which may correlate with a therapeutic response (Fig. 29.9; see Fig. 17.16 and Table 17.9).
- Other common causes of drug-induced acne include anabolic steroids, bromides (found in sedatives and cold remedies), iodides (found in contrast dyes and supplements), isoniazid (Fig. 29.10), lithium, phenytoin, and progestins.

### Acne Associated with a Syndrome

- Examples include Apert, PAPA, PASH, PAPASH, and SAPHO (see Ch. 21) syndromes.




**Fig. 29.4 Sequelae of acne. A** Postinflammatory hyperpigmentation. Such pigmentary changes are most common in patients with darker skin colors. **B** "Ice-pick" scarring secondary to nodulocystic acne. *A, Courtesy, Andrew Zaenglein, MD, and Diane Thiboutot, MD; B, Courtesy, YDRSC.*



**Fig. 29.5 Acne fulminans.** Inflamed, friable papulopustules and plaques with erosions, oozing, and formation of granulation tissue. *Courtesy, Julie V. Schaffer, MD.*



**Fig. 29.6 Solid facial edema due to acne vulgaris.** There is soft tissue swelling in the central portion of the face. *Courtesy, Boni Elewski, MD.*




**Fig. 29.7 Infantile acne.** Presentations can range from numerous open comedones (**A**) to primarily papulopustules (**B**). *A, Courtesy, Julie V. Schaffer, MD; B, Courtesy, Kalman Watsky, MD.*

| HISTORY AND PHYSICAL EXAMINATION OF THE ACNE PATIENT | |
|---|---|
| **History** | **Physical examination** |
| • Sex<br>• Age*<br>• Degree of motivation for treatment<br>• Lifestyle/hobbies, occupation<br>• Current and previous acne treatments<br>• Use of cosmetics, sunscreens, cleansers, moisturizers<br>• Menstrual history* and oral contraceptive use<br>• Medications (see text on drug-induced acne)<br>• Other medical conditions<br>• Family history of acne, polycystic ovary syndrome, and inflammatory disease | • Skin type (e.g. oily vs dry)<br>• Skin color/phototype<br>• Distribution of acne<br>– Face (e.g. "T-zone," cheeks, jawline)<br>– Neck, chest, back, upper arms<br>• Overall degree of involvement (mild, moderate, or severe)<br>• Lesion morphology<br>– Comedones<br>– Inflammatory papules and pustules<br>– Nodules and cysts, sinus tracts<br>• Postinflammatory pigmentary changes<br>• Scarring (e.g. pitted, hypertrophic, atrophic)<br>• Signs of virilization* (in female patients)<br>– Hirsutism, androgenetic alopecia<br>– Deep voice, muscular habitus, clitoromegaly |
| *Evaluation often includes serum levels of testosterone (total and free), DHEAS, and 17-hydroxyprogesterone (see Fig. 57.10) as well as hand/wrist x-rays to evaluate bone age in prepubertal children. | |

**Table 29.1 History and physical examination of the acne patient.**



**Fig. 29.8 Acneiform eruption secondary to systemic corticosteroid therapy.** Abrupt eruption of monomorphous follicular papules and pustules on the chest. *Courtesy, Andrew Zaenglein, MD, and Diane Thiboutot, MD.*



**Fig. 29.9 Acneiform eruptions due to epidermal growth factor receptor inhibitors.** Numerous monomorphous follicular pustules and crusted papules on the face of an adolescent boy treated with erlotinib. *Courtesy, Julie V. Schaffer, MD.*

## Evaluation and Treatment of Acne

- Table 29.1 lists key components in the history and physical examination of an acne patient.
- **DDx:** presented in Table 29.2.
- **Rx:** outlined in Tables 29.3 and 29.4.
- Once active acne has been successfully treated, intralesional CS (for hypertrophic scars) or surgical modalities (e.g. fractional or traditional laser resurfacing, dermabrasion, fillers) can be used for residual scarring if needed.

For further information see Ch. 36 from *Dermatology, Fourth Edition*.

**For additional online figures visit www.expertconsult.com**



**Fig. 29.10 Drug-induced acne due to isoniazid.** *Courtesy, Kalman Watsky, MD.*

| DIFFERENTIAL DIAGNOSIS OF ACNE VULGARIS |
|---|
| **Comedonal acne** |
| • Contact acne, chloracne, drug-induced acne<br>• "Pseudoacne" of the transverse nasal crease (in prepubertal children; Fig. 29.11A) |
| **Closed comedones** |
| • Milia, sebaceous hyperplasia, adnexal neoplasms (e.g. syringomas, fibrofolliculomas), osteoma cutis, colloid milia<br>• Eruptive vellus hair cysts or steatocystomas (for truncal lesions) |
| **Open comedones** |
| • Childhood flexural comedones (double-orifice; axilla > groin), dilated pore of Winer (solitary lesion)<br>• Trichostasis spinulosa (Fig. 29.11B), trichofolliculoma (solitary lesion)<br>• Favre–Racouchot disease (in photoaged skin), radiation-induced comedones<br>• Nevus comedonicus, basaloid follicular hamartoma, familial dyskeratotic comedones, Dowling–Degos disease<br>• Follicular spines (e.g. drug-induced [e.g. BRAF inhibitors] and in trichodysplasia spinulosa, multiple myeloma, and HIV-associated follicular syndrome) |
| **Inflammatory acne** |
| • Rosacea, periorificial dermatitis, idiopathic facial aseptic granuloma (solitary nodule in young children)<br>• Folliculitis: normal flora, staphylococcal, *Pityrosporum*, Gram-negative, eosinophilic, *Demodex*<br>• Drug-induced acne/acneiform eruptions, neutrophilic dermatoses<br>• Pseudofolliculitis barbae, acne keloidalis nuchae<br>• Keratosis pilaris, angiofibromas, follicular mucinosis (Fig. 29.11C)<br>• Tinea faciei, molluscum contagiosum (inflamed lesions), trichodysplasia spinulosa |

**Table 29.2 Differential diagnosis of acne vulgaris.** Folliculotropic mycosis fungoides can mimic comedonal or inflammatory acne.

**TREATMENT OF ACNE VULGARIS**

**Topical retinoids** (comedolytic > anti-inflammatory effects): tretinoin*, adapalene, tazarotene*, trafarotene
- Response requires 3–4 weeks (sometimes preceded by pustular flare); use a small amount and treat all acne-prone areas
- Initial use of lower concentration and/or alternate-night application can minimize irritation

**Topical antimicrobials**: benzoyl peroxide (BPO)** and/or antibiotic (e.g. clindamycin†, erythromycin†, minocycline, sodium sulfacetamide/sulfur)

**Oral antibiotics**: *first-line* – tetracycline derivatives (doxycycline, minocycline, sarecycline); *alt.* – azithromycin, trimethoprim–sulfamethoxazole
- Often used for 3–6 months; tetracyclines are avoided in children <8 years of age (although use for ≤21 days is acceptable) and pregnant women

**OCPs**: FDA-approved for acne – Ortho Tri-Cyclen® (EE 35 mcg, norgestimate 180/215/250 mcg), Yaz®/Loryna®/Nikki®/Melamisa®/Lo-Zumandimine® (EE 20 mcg, drospirenone 3000 mcg), Estrostep® (EE 20/30/35 mcg, norethindrone 1000 mcg)

**Antiandrogens**: spironolactone (50–200 mg/day)

**Oral isotretinoin**§: typically 0.5–1 mg/kg/day (lower initially, especially if acne fulminans) × 4–6 months (cumulative dose 120–150+ mg/kg)

| | Mild acne | | Moderate acne | Severe acne (e.g. conglobata, fulminans) |
|---|---|---|---|---|
| | **Comedonal** | **Mostly inflammatory** | | |
| First-line | • Topical retinoid | • Topical antimicrobial‡ + topical retinoid | • Oral antibiotic + topical retinoid ± BPO | • Oral isotretinoin (+ oral CS for acne fulminans) |
| Second-line | • Alt. topical retinoid<br>• Azelaic acid<br>• Salicylic acid<br>• Clascoterone | • Alt. topical retinoid + antimicrobial<br>• Azelaic acid<br>• Topical dapsone<br>• Clascoterone | • Alt. oral antibiotic + alt. topical retinoid ± BPO/azelaic acid<br>• Oral isotretinoin (if nodular, scarring or recalcitrant) | • Oral dapsone<br>• High-dose oral antibiotic + topical retinoid + BPO |
| Options for female patients | | | • OCP/ oral antiandrogen | • OCP/ oral antiandrogen |
| Procedural options | • Comedo extraction | | • Comedo extraction<br>• Intralesional CS (2–5 mg/ml triamcinolone) | • Intralesional CS (2–5 mg/ml triamcinolone) |
| Refractory to treatment | | Exclude Gram-negative folliculitis (see Ch. 31) | | |
| | | | • Female patient: exclude adrenal or ovarian dysfunction<br>• Exclude use of anabolic steroid or other acne-exacerbating drugs | |
| Maintenance | • Topical retinoid | • Topical retinoid ± BPO | • Topical retinoid ± BPO | |

**Standard tretinoin is photolabile and inactivated by BPO (so generally applied at night, separately from BPO); tazarotene is the most irritating of the topical retinoids and is contraindicated during pregnancy.*
***Can bleach clothing/bedding and cause contact dermatitis (irritant > allergic); unlike topical antibiotics, bacterial resistance does not occur.*
*†Increased effectiveness when used in conjunction with BPO or a retinoid.*
*§Severe teratogenicity; in the United States, prescribers and patients must register in a risk management program (iPLEDGE™) that requires monthly visits. The most common side effects are cheilitis > mucosal dryness (ocular, nasal) and xerosis (Fig. 29.12).*
*‡BPO ± a topical antibiotic may also be used as monotherapy, especially as an initial treatment in a younger patient.*

**Table 29.3 Treatment of acne vulgaris.** Lack of response should prompt consideration of non-adherence and alternative diagnoses. In general, monotherapy with a topical or oral antibiotic should be avoided. Laser (e.g. 1450-nm diode), light (e.g. blue, intense pulsed), or photodynamic therapies may be of benefit to some patients but are not first-line, and superficial chemical peels (e.g. 20–30% salicylic acid, 30–50% glycolic acid) are occasionally useful to reduce comedones. Alt, alternative; EE, ethinyl estradiol; OCP, oral contraceptive pill.

| TIPS FOR TOPICAL ACNE THERAPY | |
|---|---|
| **Improve adherence** – often compromised due to patients having busy schedules or quitting when the response is not rapid | • Simplify the regimen: once daily when possible; consider combination products (e.g. benzoyl peroxide + adapalene or clindamycin; tretinoin + clindamycin), especially in less motivated adolescents<br>• Inform patients that it will take 6–8 weeks of treatment for substantial improvement<br>• Ask specifically about adherence: "Out of 7 nights, how many times do you apply the medication?" |
| **Educate on proper use** | • In general, topical medications (especially retinoids) should be used to the entire acne-prone region rather than as "spot treatment" of individual lesions<br>• Provide instructions on where to apply the medication and how much to use |
| **Minimize irritation** – most common in adolescents with atopic dermatitis and adults | • Note that using too much medication or applying it too frequently can increase irritation<br>• Devise a gradual initial approach to improve tolerance in patients with sensitive skin; for example, a single agent may be used for the first 2–3 weeks (starting every other day for retinoids), followed by slow introduction of a second medication (e.g. transitioning from alternate days to daily)<br>• Advise to avoid harsh scrubs and other irritating agents (e.g. toners, acne products that are not part of the regimen)<br>• Suggest use of a non-comedogenic sensitive skin moisturizer if dryness occurs |
| **Avoid exacerbation** | • Review all skin care products and cosmetics; having patients bring everything that they apply to their face to a visit may help to determine the source of problems<br>• Advise non-comedogenic products (e.g. moisturizers, sunscreens, make-up) and to avoid having oily hair or using pomades that may contribute to acne<br>• Instruct patients not to pick or manipulate lesions |
| **Reinforce the plan** – patients often forget what is recommended and are bombarded by advertising and false information about acne | • Provide a written handout with your specific instructions<br>• Recommend additional reliable educational resources about acne and its treatment, e.g.:<br>www.aad.org/public/diseases/acne<br>www.webmd.com/skin-problems-and-treatments/acne/default.htm |

**Table 29.4 Tips for topical acne therapy.**




**Fig. 29.11 Disorders in the differential diagnosis of comedonal acne vulgaris. A** "Pseudoacne" of the transverse nasal crease in a young child. Note the milia and comedones located along this anatomical demarcation line. **B** Trichostasis spinulosa. Multiple vellus hairs and keratinous debris are found within the dilated follicular orifices. **C** Acneiform follicular mucinosis on the cheek of a woman. *A, Courtesy, Julie V. Schaffer, MD; B, Courtesy, Judit Stenn, MD; C, Courtesy, Lorenzo Cerroni, MD.*




**Fig. 29.12 Cutaneous complications of isotretinoin therapy. A** Multiple serous crusts are evident. Dryness and fragility of the skin, lips, and nasal mucosa in patients treated with isotretinoin increase susceptibility to staphylococcal infections. **B** Pyogenic granuloma-like healing on the chest of an adolescent boy receiving his third month of isotretinoin therapy. *Courtesy, Andrew Zaenglein, MD, and Diane Thiboutot, MD.*

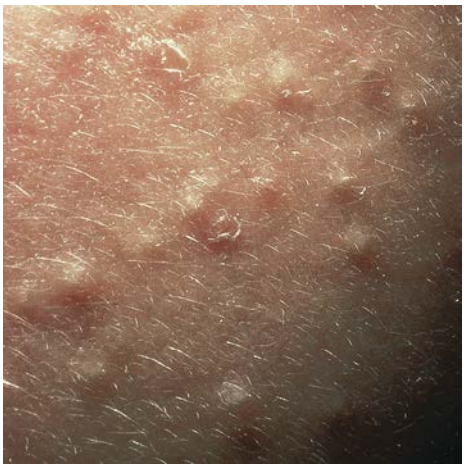

**eFig. 29.1 Comedonal acne vulgaris.** Closed comedones highlighted by side lighting. *Courtesy, Ronald P. Rapini, MD.*



**eFig. 29.2 Moderate acne vulgaris.** Scattered papulopustules and papulonodules are present on the cheek. *Courtesy, Kalman Watsky, MD.*



**eFig. 29.3 Moderate to severe acne vulgaris.** Multiple coalescing papules, pustules, and small nodules are present on the cheek. *Courtesy, Kalman Watsky, MD.*



**eFig. 29.4 Large open comedones in a patient with scarring nodular acne.** *Courtesy, YDRSC.*




**eFig. 29.5 Infantile acne. A** Multiple open and closed comedones, papules and mild atrophic scarring. **B** Multiple coalescing inflammatory papulonodules. *A, Courtesy, Holly Gunn, MD; B, Courtesy, Kalman Watsky, MD.*



**eFig. 29.6 Neonatal cephalic pustulosis.** Papulopustules on the forehead and cheeks of a 3-week-old infant. *Courtesy, Julie V. Schaffer, MD.*



**eFig. 29.7 Acneiform eruption secondary to systemic corticosteroid therapy.** Abrupt eruption of monomorphous follicular papules and pustules on the chest. *Courtesy, Scott Jackson, MD, and Lee T. Nesbitt, Jr., MD.*




**eFig. 29.8 Acneiform eruptions due to epidermal growth factor receptor inhibitors. A** Numerous monomorphous follicular pustules and crusted papules on the face. **B** Pustules on an erythematous base on the upper back. **C** Multiple follicular papulopustules, hyperpigmented scars, and a large inflamed cyst on the cheek. *A, Courtesy, Andrew Zaenglein, MD, and Diane Thiboutot, MD; B, Courtesy, Lauren Levy, MD, and Jonathan Leventhal, MD; C, Courtesy, Kalman Watsky, MD.*



**eFig. 29.9 Follicular mycosis fungoides.** Numerous lesions with a comedonal appearance are evident on the chest, abdomen, and back. *Courtesy Julie V. Schaffer, MD.*

# 30 Rosacea and Periorificial Dermatitis

## Epidemiology

- Seen in all skin types, but considerably more common in patients with skin phototypes I–II.
- Onset generally in the 4th decade of life.

## Clinical Features

- Highly variable degree of severity, from a few papulopustules to extreme distortion of the nose.
- Lesions typically develop on the face, especially its central portion; uncommonly other sites such as the scalp and chest are involved.
- Etiology is multifactorial, including vascular hyperreactivity, alterations in innate immunity, e.g. cathelicidins, and *Demodex* plus its commensal bacteria. There is some evidence to suggest association of rosacea with cardiovascular disorders.
- Table 30.1 lists diagnostic phenotypes and features of rosacea (Figs 30.1–30.5) and their characteristics.



**Fig. 30.1 Rosacea.** Moderate papulopustular rosacea of the forehead. Note the superficial nature of the inflammatory lesions. *Courtesy, Frank C. Powell, MD.*

- Variants include granulomatous rosacea and periorificial dermatitis
  - Granulomatous rosacea
    - Red to red-brown papules secondary to granulomatous inflammation (Fig. 30.6)
  - Periorificial dermatitis
    - Originally referred to as perioral dermatitis but lesions can surround other orifices, hence the term periorificial
    - Affects children and adults
    - Lesions around the mouth and nose > eyes
    - Monomorphic pink papules and fine pustules (Figs 30.7 and 30.8) admixed with eczematous patches and thin plaques, sometimes with fine scale
    - Lesions recur over weeks to months
    - May initially improve with topical CS but ultimately this treatment leads to exacerbation and should not be used
    - If topical CS are an exacerbating factor, taper strength of CS over a period of weeks or substitute topical calcineurin inhibitors in order to reduce rebound
  - Mid-facial edema
    - Erythematous, firm, non-pitting, painless swelling of the mid-face (Fig. 30.9)
  - Rosacea fulminans
    - Acute facial plaque studded with pustules
- **DDx**: Table 30.2.
- **Rx**: Tables 30.3 and 30.4.

For further information see Ch. 37 from *Dermatology, Fourth Edition*.

**For additional online figures visit www.expertconsult.com**



**Fig. 30.2 Rosacea dermatitis.** When there is more severe disease, scaling and superficial crusting may be seen as on the cheek of this woman. *Courtesy, Kalman Watsky, MD.*



**Fig. 30.3 Inflammatory rosacea with edematous changes.** An intensely erythematous plaque is present on the medial aspect of the cheek. This may improve once the underlying inflammation is treated appropriately. *Courtesy, Frank C. Powell, MD.*




**Fig. 30.4 Rhinophyma – early versus advanced disease. A** Tortuous, telangiectatic vessels on the distal aspect of the nose contribute to its hyperemic appearance; this hyperemia may predispose to the subsequent hypertrophic changes of rhinophyma. Note the early sign of dilated follicles. **B** Distortion of nasal tissue due to tissue hypertrophy. Electrosurgery or laser therapy can be used to debulk and resculpt this nose. *Courtesy, Frank C. Powell, MD.*

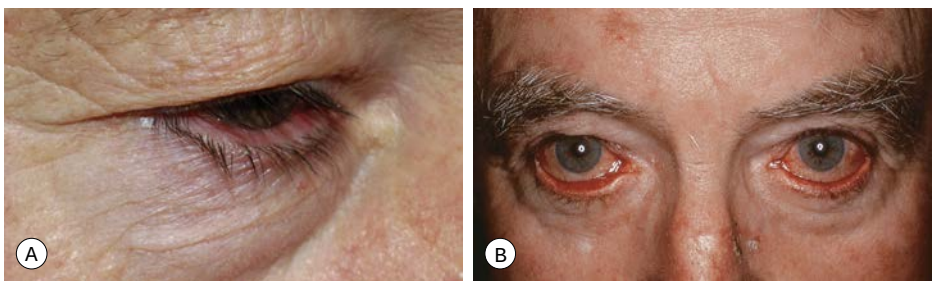


**Fig. 30.5 Ocular rosacea. A** Erythema of the mucosal portion of the lower eyelid and ectropion. **B** Marked injection of the conjunctivae, leading to the appearance of red eyes. Ectropion is also present. *A, Courtesy, Kalman Watsky, MD; B, Courtesy, YDRSC.*

| TYPES OF ROSACEA | | |
|---|---|---|
| **Types** | | **Major features (presence of 2 or more are diagnostic)** |
| **A Fixed centrofacial erythema in a characteristic pattern that may periodically intensify** | | |
| Erythemato-telangiectatic (neurovascular) |  | 1. Recurrent flushing/blushing, may eventuate in fixed central facial erythema<br>2. Telangiectasias |
| Papulopustular (inflammatory) |  | 3. Intermittent pink to red papules and inflammatory pustules (Fig. 30.1) |
| **B Phymatous** | | |
| |  | Hypertrophy and irregular (lumpy) thickening of nose (Fig. 30.4) >> forehead, cheeks, chin, or ears |
| **Ocular** | | |
| **Symptoms** Burning, stinging, pruritus, foreign-body sensation in the eye, photophobia, dryness, blurry vision | **Signs** Blepharitis, conical dandruff or "honey crust" on eyelashes, periorbital edema, recurrent "styes" (chalazia or hordeola), irregularity of lid margin, ectropion (see Fig. 30.5), rapid tear breakup time<br> | 4. Lid margin telangiectasia<br>5. Interpalpebral conjunctival injection (Fig. 30.5B)<br>*On slit-lamp examination*<br>6. Spade-shaped infiltrates in the cornea<br>7. Scleritis and sclerokeratitis |

**Table 30.1 Types of rosacea.** A diagnosis of rosacea can be based on cutaneous presentations in **A** or **B** OR the presence of 2 or more major features. Some patients also have seborrheic dermatitis and/or actinic damage. Edema of the facial skin can also develop.



**Fig. 30.6 Granulomatous rosacea.** Discrete skin-colored to brown papules scattered on the face. *Courtesy, Frank C. Powell, MD.*



**Fig. 30.7 Periorificial dermatitis, granulomatous form.** Discrete dull pink-red papules around the mouth and nose. While periorificial dermatitis is often misdiagnosed as eczema, this more granulomatous form may be misdiagnosed as sarcoidosis if a biopsy has been performed. *Courtesy, Julie V. Schaffer, MD.*







**Fig. 30.8 Periorificial dermatitis (often referred to as perioral dermatitis). A, B** Pink papules, patches and thin plaques as well as pinpoint superficial pustules around orifices, i.e. in a perioral, perinasal, and/or periorbital distribution pattern. In contrast to papulopustular rosacea, the papules are usually at the same stage of evolution. *A, Courtesy, Frank C. Powell, MD; B, Courtesy, Kalman Watsky, MD.*

| DIFFERENTIAL DIAGNOSIS OF ROSACEA | |
|---|---|
| **Disease** | **Distinguishing feature(s) from rosacea** |
| **Erythematotelangiectatic rosacea** | |
| Actinic damage | May be difficult to distinguish because this also leads to telangiectasias and erythema, and some patients have both disorders |
| Seborrheic dermatitis | Erythema with greasy scale in nasolabial folds, ear canals, eyebrows, and scalp |
| Keratosis pilaris rubra | • Usually presents during adolescence<br>• Background erythema of the lateral cheeks with superimposed tiny follicular papules |
| Erythromelanosis follicularis faciei | Pink to red-brown patches with multiple pinpoint follicular white papules on the lateral cheeks |
| Acute cutaneous lupus erythematosus | • Absence of inflammatory papulopustules and ocular changes<br>• At least 75–80% of patients have systemic signs/symptoms<br>• Often more well-demarcated edematous plaques |
| Flushing (idiopathic or secondary) | • Intermittent erythema and warmth<br>• Flushing in patients with rosacea is usually limited to the face<br>• Consider other common etiologies (e.g. menopause, anxiety disorder) or a tumor-related phenomenon (carcinoid syndrome, occult pheochromocytoma, mastocytosis) when additional anatomic sites are involved or there are associated symptoms such as tachycardia and sweating |
| **Papulopustular rosacea** | |
| Acne (vulgaris) | Onset at a younger age |
| | Comedones, both open and closed |
| | Cysts |
| | Greater involvement of the upper trunk |
| Demodicosis (*Demodex* folliculitis) | Patients often immunosuppressed (HIV infection, leukemia) |
| | Daily cleansing of face with mild soaps, sulfacetamide washes<br>Responds to topical permethrin ± oral ivermectin |
| Steroid-induced rosacea | Clinical overlap with periorificial dermatitis (see above) (Fig. 30.11) |
| Papulopustular eruption due targeted inhibitors (e.g. epidermal growth factor receptor [EGFR] inhibitor) | More abrupt onset after starting the targeted inhibitor (Fig. 30.10)<br>May also involve the scalp, neck, and trunk |
| **Ocular rosacea** | |
| Seborrheic dermatitis | Involvement beyond the eyelid margin; may be accentuated in the eyelid creases |
| Drug-induced ocular rosacea | Eyedrops used to treat other ocular disorders, e.g. glaucoma |

**Table 30.2 Differential diagnosis of rosacea.**

| MEDICAL AND SURGICAL THERAPIES FOR ROSACEA AND PERIORIFICIAL DERMATITIS | |
|---|---|
| **Papulopustular rosacea** | **Periorificial dermatitis** |
| **Topical agents – mild disease, adjunct to oral therapy or maintenance after oral therapy (daily to BID)**<br>• Metronidazole (0.75–1%)<br>• Sodium sulfacetamide wash<br>• Azelaic acid (15%)<br>• Ivermectin (1%)<br>• Benzoyl peroxide (5%)/clindamycin (1%)<br>• Clindamycin (1%)<br>• Erythromycin (2%) | **Adults**<br>Similar to papulopustular rosacea, but often unresponsive to topicals and a 4- to 8-week course of oral antibiotics is required<br>**Children**<br>• Topical metronidazole (0.75–1%)<br>• Oral antibiotic for 4–8 weeks<br>Azithromycin 5–10 mg/kg TIW *-or-*<br>Erythromycin 15–25 mg/kg BID *-or-*<br>Doxycycline/minocycline (see to the left) if age >8 years |
| **Oral medications (discontinue or taper to lowest effective dose)**<br>• Initially:<br>Doxycycline 20 to 100 mg orally BID *-or-*<br>Tetracycline 500 mg orally BID *-or-*<br>Minocycline 100 mg orally BID *-or-*<br>Doxycycline 40 mg orally daily*<br>• After 4–8 weeks:<br>Decrease dose by ½ or to once daily<br>• Long term:<br>Topicals ± doxycycline 20–50 mg TIW<br>• If very severe:<br>Isotretinoin 10–40 mg orally daily for several months | **Erythematotelangiectatic rosacea**<br>• Laser (e.g. PDL, KTP) or intense pulsed light therapy<br>• Use of topical vasoconstrictors (e.g. brimonidine, oxymetazoline HCl)<br>**Ocular rosacea**<br>• Warm compresses<br>• Gentle digital massage with baby shampoo or 50% tea tree oil scrubs<br>• Low-dose doxycycline<br>• Ophthalmology consultation<br>**Phymatous rosacea**<br>• Surgical excision<br>• Electrosurgery (Fig. 30.12) |
| **Sub-antimicrobial dose.* | |

**Table 30.3 Medical and surgical therapies for rosacea and periorificial dermatitis.** KTP, potassium titanyl phosphate laser; PDL, pulsed dye laser; TIW, three times per week.



**Fig. 30.9 Facial edema secondary to rosacea (Morbihan disease).** Erythematous, firm, non-pitting, non-painful swelling of the upper face. Areas of greatest involvement have acquired a "peau d'orange" appearance. *Courtesy, Frank C. Powell, MD.*



**Fig. 30.10 Papulopustular eruption due to an epidermal growth factor receptor (EGFR) inhibitor.** There is resemblance to rosacea but the onset is more abrupt. *Courtesy, Frank C. Powell, MD.*

| GENERAL RECOMMENDATIONS FOR FACIAL SKIN CARE AND EDUCATION IN PATIENTS WITH ROSACEA |
|---|
| **Facial skin care** |
| • Wash with lukewarm water and use soap-free cleansers that are pH balanced<br>• Cleansers are applied gently with fingertips<br>• Use sunscreens with both UVA and UVB protection and an SPF ≥30<br>• Sun-blocking creams containing the physical barriers titanium dioxide and/or zinc oxide are usually well tolerated<br>• Use cosmetics and sunscreens that contain protective silicones<br>• Water-soluble facial powder containing inert green pigment helps to neutralize the perception of erythema<br>• Moisturizers containing humectants (e.g. glycerin) and occlusives (e.g. petrolatum) help to repair the epidermal barrier<br>• Avoid astringents, toners, and abrasive exfoliators<br>• Avoid cosmetics that contain alcohol, menthols, camphor, witch hazel, fragrance, peppermint, and eucalyptus oil<br>• Avoid waterproof cosmetics and heavy foundations that are difficult to remove without irritating solvents or physical scrubbing<br>• Avoid procedures such as glycolic peels or dermabrasion |
| **Patient education** |
| • Reassure the patient about the benign nature of the disorder and the rarity of rhinophyma, particularly in women<br>• Emphasize the chronicity of the disease and the likelihood of exacerbations<br>• Direct patients to information websites such as those of the National Rosacea Society (http://www.rosacea.org) or the American Academy of Dermatology (http://www.aad.org)<br>• Advise to avoid recognized triggers<br>• Explain the importance of compliance with topical regimens<br>• Educate on the importance of sun avoidance |

**Table 30.4 General recommendations for facial skin care and education in patients with rosacea.** *Adapted from Powell FC. Rosacea. N Engl J Med 2005;352:793–803; Pelle MT, Crawford GH, James WD. Rosacea: II. Therapy. J Am Acad Dermatol 2004;51:499–512; and Del Rosso JQ, Baum EW. Comprehensive medical management of rosacea: An interim study report and literature review. J Clin Aesthet Dermatol 2008;1:20–25.*



**Fig. 30.11 Steroid rosacea.** Severe disease in a child with confluence of erythematous papulopustules. *Courtesy, YDRSC.*

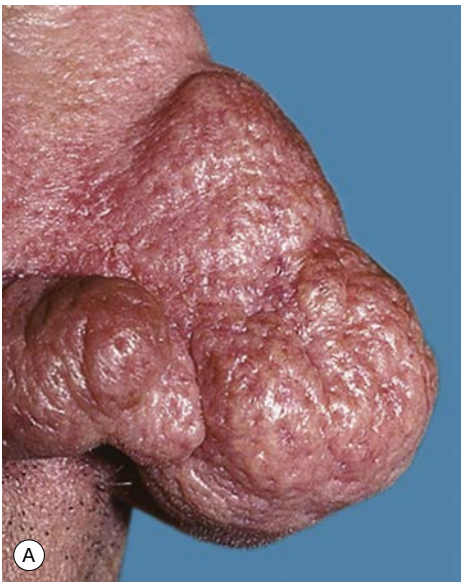








**Fig. 30.12 Rhinophyma. A** Moderately severe rhinophyma in a middle-aged man. **B** Immediately after electrosurgical planing of excess sebaceous glands. Care is taken to perform subtotal removal as very aggressive therapy can result in significant scarring and possible deformity caused by scar contracture. **C** Four weeks later, healing with good cosmetic outcome is noted. During healing, the wound is kept moist with an ointment and semi-occlusive dressings. *Courtesy, Sheldon V. Pollack, MD.*



**eFig. 30.1 Rosacea fulminans (pyoderma faciale).** Striking plaque on the cheek studded with pustules. *Courtesy, YDRSC.*



**eFig. 30.3** Prominent follicular openings or patulous follicles with evidence of the early swelling of glandular rhinophyma.



**eFig. 30.2 Periorificial dermatitis (often referred to as perioral dermatitis).** Granulomatous periorificial dermatitis in a child with monomorphous pink papules that have become confluent around the mouth. The eruption, which had previously worsened upon treatment with topical and oral corticosteroids, resolved with a 6-week course of azithromycin. *Courtesy, Julie V. Schaffer, MD.*

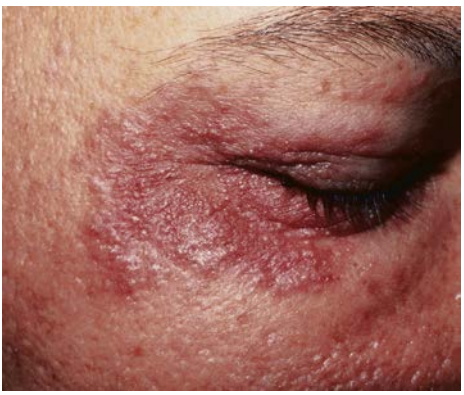

**eFig. 30.4** Periocular dermatitis with multiple fine papules and pustules superimposed on a pink plaque. *Courtesy, Ronald P. Rapini, MD.*



**eFig. 30.5 Moderate to severe papulopustular rosacea.** There is a typical centrofacial distribution of erythema, telangiectasias, papules and pustules. In addition, the skin has a scaly, crusty surface and this is often a sign of more severe disease.

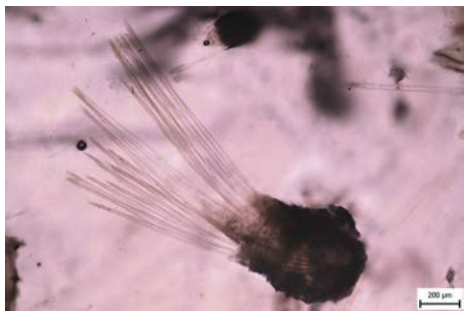

**eFig. 30.6 Trichostasis spinulosa – microscopic examination of follicular contents.** Tuft of multiple vellus hairs.

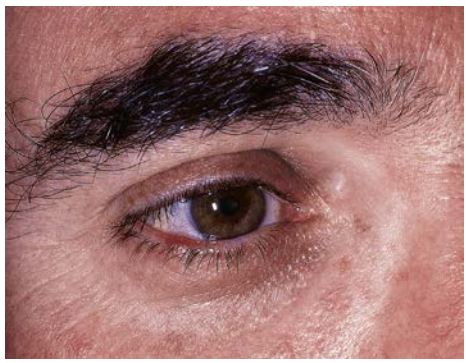

**eFig. 30.7 Ocular rosacea.** A stye is present on the lower eyelid margin as a manifestation of ocular rosacea.



**eFig. 30.8 Granulomatous rosacea.** Discrete red to red-brown papules that are a reflection of granulomatous inflammation.



**eFig. 30.9 Moderate to severe steroid rosacea.** More significant disease in a teenager. *Courtesy, Ronald P. Rapini, MD.*

# 31 Folliculitis

- The folliculitides are divided into superficial and deep forms (Table 31.1).
- Follicular papules and pustules can be distinguished from non-follicular lesions by the presence of a hair piercing the lesion in the former; if hair shafts are not apparent, then determining if the lesions correspond to the spatial pattern of hair follicles can aid in diagnosis.

## Superficial Folliculitis

- Common; characterized by follicular papules or pustules that are often on an erythematous base.
- Often pruritic, sometimes painful.
- Favors areas with terminal hairs, such as the scalp and beard; also common on the trunk, buttocks, and thighs > axillae and groin.
- The most common type is culture-negative/normal flora, followed by bacterial folliculitis caused by *Staphylococcus aureus*.
- Multiple, less common etiologies (Table 31.1), require a systematic approach for adequate diagnosis and treatment (Fig. 31.1; Table 31.2).
- **DDx:** acne vulgaris, pseudofolliculitis barbae, rosacea; Grover disease in adults; pustular miliaria in children.

**CLASSIFICATION OF THE FOLLICULITIDES**

| Superficial folliculitides | Deep folliculitides |
|---|---|
| **Infectious** | • Furuncles<br>• Sycosis (Table 31.3)<br>1. Barbae (Fig. 31.2B)<br>2. Lupoid<br>3. Mycotic (Fig. 31.7)<br>4. Herpetic<br>• Pseudofollicultis barbae<br>• Acne keloidalis<br>• Hidradenitis suppurativa* |
| • Bacterial<br>1. *Staphylococcus aureus* (Fig. 31.2)<br>2. Gram-negative bacilli<br>3. Hot tub folliculitis (Fig. 31.3)<br>• Fungal<br>1. Dermatophyte (Fig. 31.4A)<br>2. *Malassezia* spp. (*Pityrosporum*)<br>3. *Candida* spp.<br>• Viral<br>1. Herpes simplex (Fig. 31.4B)<br>2. Varicella zoster<br>• Other<br>1. *Demodex* (Fig. 31.4C, D) | |
| **Non-infectious** | |
| • Culture-negative/normal flora (Fig. 31.5)<br>• Irritant<br>• Drug-induced<br>• Eosinophilic (Fig. 31.6)<br>1. Eosinophilic pustular folliculitis (Ofuji disease)<br>2. Immunosuppression (or HIV)-associated eosinophilic pustular folliculitis<br>3. Eosinophilic pustular folliculitis of infancy<br>• Disseminate and recurrent infundibulofolliculitis | |

*Part of the follicular occlusion tetrad, which also includes acne conglobata (see Ch. 29), dissecting cellulitis of the scalp (see Ch. 56), and pilonidal sinus/cyst (see Ch. 90).

**Table 31.1 Classification of the folliculitides.**

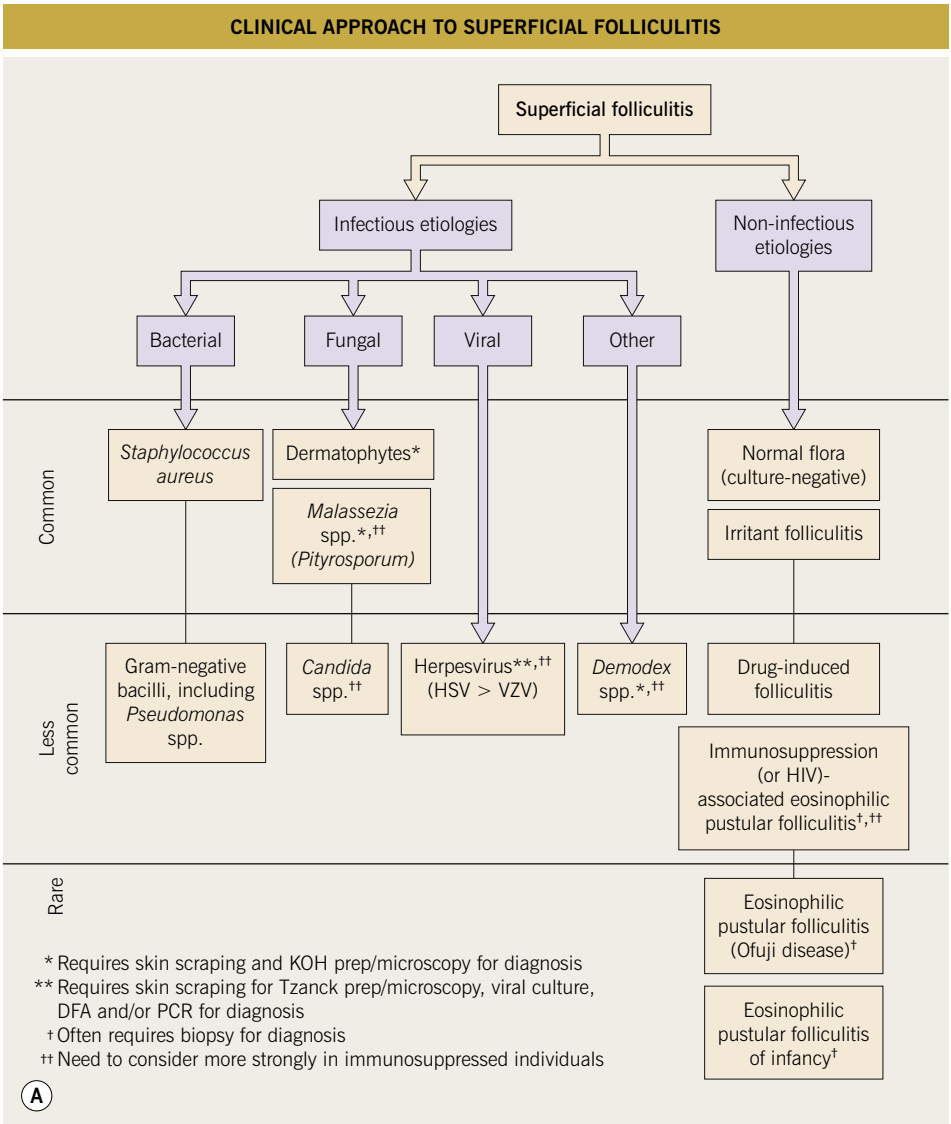


**Fig. 31.1 Superficial folliculitis – clinical approach. A** Edematous lesions of folliculitis are most suggestive of eosinophilic folliculitis, *Demodex* folliculitis, and *Pseudomonas* "hot tub" folliculitis. *Continued*

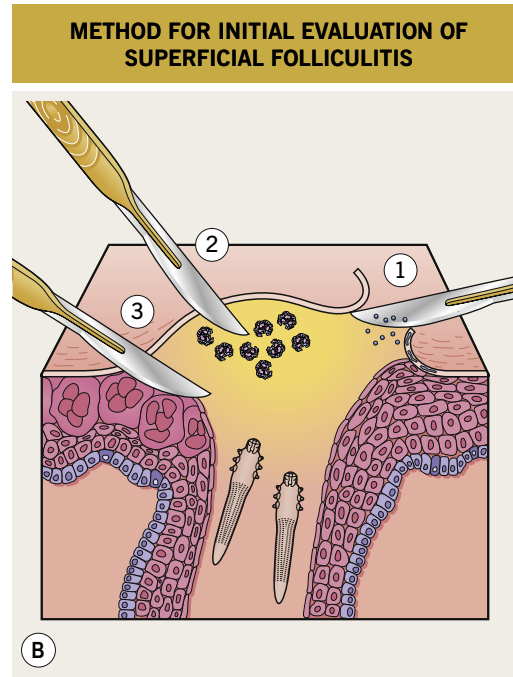


**Fig. 31.1** *Continued* **Superficial folliculitis – initial evaluation. B** If considering dermatophytes, *Malassezia* spp., or *Candida* spp., then obtain scrapings from the peripheral scale and the roof of the follicular pustule for KOH (potassium hydroxide) microscopy (1). If considering bacterial etiologies, and depending on the host, the pustular fluid should be sent for Gram stain, culture, and sensitivity (2). If considering viral etiologies, the base of the unroofed lesion should be vigorously scraped in order to collect the viral-laden keratinocytes for Tzanck prep/microscopy, viral culture, DFA (direct fluorescent antibody), and/or PCR (polymerase chain reaction) (3). Likewise, if considering *Demodex* folliculitis, scrape the base of the lesion vigorously for KOH microscopy (3) (see Fig. 31.4D).

## Deep Folliculitis

- The major forms of deep folliculitis are outlined in Tables 31.1 and 31.3.
- Lesions are characterized by firm, tender, erythematous papules or nodules that may measure up to 2 cm in diameter.
- Should avoid manipulating (i.e. squeezing) furuncles as this may cause bacteremia or seeding of heart valves (endocarditis), brain (abscess), or bones (osteomyelitis).
- The "follicular occlusion tetrad" is a term that was coined for the common association of acne conglobata, hidradenitis suppurativa, dissecting cellulitis of the scalp, and pilonidal sinus/cyst; also called "acne inversa."

### Pseudofolliculitis Barbae (PFB)

- A common, chronic inflammatory disorder occurring most often in the beard area of men who shave.
- Favors males > females; African-Americans, and others with darkly pigmented skin and tightly curled hair.
- The proposed etiology is tightly curled hairs that curve back into the skin when shaved (Fig. 31.8).
- Also, there is a genetic predisposition if carrying a mutation in the 1A α-helical subdomain of the hair follicle companion layer-specific keratin K6hf (K75).
- Lesions range from inflammatory papules and pustules to firm papules and keloidal scars (Fig. 31.9).
- Intervention during the acute phase of PFB is essential.
- **Rx:** while the easiest way to cure PFB is to stop shaving, this may not be practical; laser hair removal systems that are skin-color appropriate offer the best option for a more permanent solution.
- In addition, shaving techniques can be optimized (Table 31.4) and other treatments may provide some control (Table 31.5).

### Acne Keloidalis

- Begins as a chronic folliculitis of the posterior neck and occipital scalp; with time, keloidal papules and plaques develop (Fig. 31.10).
- Seen almost exclusively in males of African descent.
- Lesions are usually pruritic and sometimes painful and disfiguring.

| CLINICAL FEATURES AND TREATMENT OF SELECTED SUPERFICIAL FOLLICULITIDES | | |
|---|---|---|
| **Type** | **Clinical features** | **Therapy** |
| **Infectious folliculitides** | | |
| *Bacterial* | | |
| *Staphylococcus aureus folliculitis* | | |
| • Most common infectious folliculitis<br>• Increased risk with diabetes, atopic dermatitis, hot and humid weather, occlusion, waxing/plucking/shaving hair, use of topical CS | • Follicular pustules or papules on erythematous base (Fig. 31.2)<br>• Favors face, trunk, axillae, buttocks<br>• If no pustules present, clue to diagnosis may be a superimposed collarette of scale | **Localized**<br>• Topical mupirocin 2% ointment TID for 7–10 days<br>**Widespread or recurrent**<br>• Weekly–twice weekly washes (e.g. benzoyl peroxide, chlorhexidine, bleach baths*)<br>• Treat chronic *S. aureus* nasal carriage<br>• Culture-guided oral antibiotics |
| *Gram-negative folliculitis* | | |
| • Due to *Klebsiella, Enterobacter*, and *Proteus* spp.<br>• Typically seen in acne patients receiving long-term antibiotics<br>• Also seen in adult men with oily skin | • Pustules in the T-zone and perinasal regions of face | • Topical gentamicin or benzoyl peroxide<br>• Systemic quinolones<br>**Severe or recurrent**<br>• Isotretinoin 0.5–1 mg/kg/day for up to 16 weeks |
| *Hot tub folliculitis* | | |
| • Due to *Pseudomonas aeruginosa* in the setting of hot tub/whirlpool use 12–48 hours prior to onset | • Edematous pink-red follicular papules and pustules<br>• Favors trunk (Fig. 31.3); often pruritic<br>• Usually self-limited in immunocompetent host<br>• More serious in immunocompromised | • Maintenance of hot tub/whirlpool to ensure adequate chlorine levels<br>**Severe or immunocompromised host**<br>• Oral quinolones for 1–2 weeks |

**Table 31.2 Clinical features and treatment of selected superficial folliculitides.** *Continued*

| CLINICAL FEATURES AND TREATMENT OF SELECTED SUPERFICIAL FOLLICULITIDES | | |
|---|---|---|
| **Type** | **Clinical features** | **Therapy** |
| *Fungal* | | |
| *Dermatophyte folliculitis* | | |
| • Tinea barbae in beard area (*Trichophyton mentagrophytes* or *T. verrucosum*); classically occurs in farmworkers<br>• Majocchi granuloma (usually due to *T. rubrum*); classically occurs on the legs of women who shave; additional risk factors include immunosuppression, occlusion, and the use of potent topical CS | • Inflammatory follicular papules and pustules in beard area; crusts; loosened hairs<br>• Follicular pustules, papules, or nodules, most often on lower legs (Fig. 31.4A) | • Topical antifungals often ineffective<br>• Terbinafine, 250 mg/day PO for 2–3 weeks<br>• Micronized or ultramicronized griseofulvin, 500–1000 mg/day or 500–750 mg/day PO, respectively, for 4–6 weeks<br>• Itraconazole, 200 mg PO twice daily for 1 week per month, for 2 pulses |
| *Malassezia (Pityrosporum) folliculitis* | | |
| • Caused by *Malassezia* spp.<br>• Typically seen in young adults<br>• Inciting factors include warm weather, occlusion, excessive sebum production, antibiotic therapy, iatrogenic immunosuppression | • Pruritic follicular pustules and papules<br>• Favors chest, back, shoulders<br>• Abundant yeast forms on KOH microscopy | **Topicals**<br>• Antifungals (e.g. ketoconazole cream)<br>• Selenium sulfide or antifungal shampoos<br>**Systemic**<br>• Fluconazole 100–200 mg/day PO for 3 weeks or 200–300 mg once weekly for 1–2 months<br>• Itraconazole 200 mg/day PO for 1–3 weeks |
| *Candida folliculitis* | | |
| • Seen primarily in diabetics<br>• Also in immunocompromised hosts and patients on antibiotic or CS therapy<br>• Common in hospitalized or bedridden, febrile patients on the back | • Pruritic follicular pustules on erythematous base<br>• Favors warm, moist and occluded environments, such as intertriginous areas<br>• Often present as satellite pustules surrounding areas of intertriginous candidiasis<br>• Facial lesions may mimic tinea barbae | • Prevent skin-to-skin contact in intertriginous areas<br>• If possible, discontinue antibiotics or CS therapy<br>**Mild**<br>• Topical antifungals<br>**Severe or recalcitrant**<br>• Fluconazole 100 mg/day PO × 1 week, then every other day × 1 month |

**Table 31.2** *Continued* **Clinical features and treatment of selected superficial folliculitides.** *Continued*

| CLINICAL FEATURES AND TREATMENT OF SELECTED SUPERFICIAL FOLLICULITIDES | | |
|---|---|---|
| **Type** | **Clinical features** | **Therapy** |
| *Viral* | | |
| *Herpes simplex folliculitis* | | |
| • **Immunocompetent host:** most common scenarios are occurrence on the face of men or pubic area of women (with histories of recurrent HSV infections) who shave with blade razors<br>• **Immunocompromised host:** widespread or unusual presentations seen; consider VZV when submitting specimens for culture, DFA, and/or PCR | • Rapid development of individual and grouped follicular pustules and vesicles on an erythematous base (Fig. 31.4B)<br>• Multinucleated giant cells seen on Tzanck smear | • Acyclovir 200 mg PO 5 times per day for 5–10 days<br>• Famciclovir 500 mg PO 3 times per day for 5–10 days<br>• Valacyclovir 500 mg PO 3 times per day for 5–10 days |
| *Other* | | |
| *Demodex folliculitis* | | |
| • May be associated with immune suppression<br>• Sometimes associated with flares of rosacea | • Erythematous follicular papules and pustules on the face, often within a background of diffuse erythema (Fig. 31.4C)<br>• Skin scrapings under microscopy reveal numerous *Demodex* mites (Fig. 31.4D) | • Topical 1% ivermectin cream, 5% permethrin cream<br>• Systemic single dose of ivermectin 200 mcg/kg PO<br>• Prevention with daily cleansing using a medicated wash, e.g. sulfacetamide |
| **Non-infectious folliculitides** | | |
| *Culture-negative/normal flora folliculitis* | | |
| • The most common of all the folliculitides | • May look like *S. aureus* folliculitis clinically but cultures reveal no growth or only normal flora<br>• Favors trunk and scalp (Fig. 31.5)<br>• Often pruritic | • Topical benzoyl peroxide<br>• Topical antibiotics (e.g. clindamycin)<br>• Oral antibiotics (e.g. doxycycline, tetracycline) used primarily for their anti-inflammatory effects |
| *Irritant folliculitis* | | |
| • Usually occurs following the application of a topical medication or ointment (e.g. tar preparations)<br>• May be seen on thighs from rubbing of denim jeans | • Follicular pustules in the sites of application or rubbing<br>• Favors areas with terminal hairs | • Stop inciting agent<br>• Apply topical medications in the same direction as hair growth<br>• Topical mid-potency CS lotion or cream |

**Table 31.2** *Continued* **Clinical features and treatment of selected superficial folliculitides.** *Continued*

| CLINICAL FEATURES AND TREATMENT OF SELECTED SUPERFICIAL FOLLICULITIDES | | |
|---|---|---|
| **Type** | **Clinical features** | **Therapy** |
| *Drug-induced folliculitis* | | |
| • Most common in acne-prone patients and age groups<br>• Can develop within 2 weeks of starting the culprit agent<br>• Risk is proportional to the dose and duration of therapy<br>• Common culprits: CS, androgenic hormones, EGFR inhibitors, MEK inhibitors, sirolimus, iodides, bromides, lithium, isoniazid, anti-convulsants | • Acute eruption of monomorphic erythematous follicular papules and pustules<br>• Favors trunk, shoulders, and upper arms<br>• Multiple papulopustules of the face and scalp, sometimes admixed with scale-crust (see Fig. 17.16)<br>• Unlike acne vulgaris, typically no comedones | • Stop culprit medication, if possible<br>**Topicals**<br>• Benzoyl peroxide, clindamycin, erythromycin, or retinoids<br>**Systemic**<br>• Tetracycline, doxycycline, minocycline |
| ***Eosinophilic folliculitis*** | | |
| *Eosinophilic pustular folliculitis (Ofuji disease)* | | |
| • Most reported cases from Japan<br>• Not associated with systemic disease | • Recurrent episodes of follicular papulopustules; erythematous patches and plaques with superimposed coalescent pustules; and later central clearing which leads to figurate lesions<br>• Favors face, upper extremities, and trunk; occasionally palms and soles<br>• Pruritus often severe<br>• Lesions last 7–10 days<br>• Spontaneous resolution with relapse is the norm | • Topical antipruritics, oral antihistamines, and topical CS for relief of pruritus<br>**First-line**<br>• Oral indomethacin 50 mg/day PO<br>**Second-line**<br>• UVB phototherapy<br>• Oral minocycline, dapsone, CS, or colchicine |
| *Immunosuppression (or HIV)-associated eosinophilic folliculitis* | | |
| • Correlates with a low CD4 count (<300/mm$^3$)<br>• Also reported in other immunosuppressed individuals, such as those with lymphoma, leukemias, and stem cell transplant recipients<br>• Can be part of the *i*mmune *r*econstitution *i*nflammatory *s*yndrome (IRIS) | • Chronic, persistent pruritic follicular papules; perhaps no pustules (Fig. 31.6)<br>• Favors the face, scalp, and upper trunk<br>• Intense pruritus | • Clinical improvement occurs with elevation of CD4 count via ART<br>• Topical and oral antipruritics and CS often inadequate<br>• UVB phototherapy can be helpful for pruritus<br>• Additional: topical tacrolimus, permethrin; oral antibiotics, itraconazole, isotretinoin |

**Bleach bath involves mixing ¼ cup of household bleach into a half-filled, regular-sized bathtub.*

**Table 31.2** *Continued* **Clinical features and treatment of selected superficial folliculitides.** Most common etiologies are in green shade.

- Often there is patchy alopecia or complete hair loss; occasionally there are subcutaneous abscesses with malodorous draining sinuses.
- The sooner this condition is treated, the less likely it will become disfiguring.
- **Rx:** outlined in Table 31.6.
- Prevention is important, and patients should avoid mechanical irritation of the posterior hairline.

### Hidradenitis Suppurativa

- An inflammatory disorder originating from the hair follicle that targets the apocrine gland-bearing skin sites, particularly the axillae and anogenital region.
- A chronic condition characterized by recurrent "boils" and draining sinus tracts with subsequent scarring.
- Favors females > males and persons of African descent; onset at or soon after puberty.
- **Initially** inflammatory nodules and sterile abscesses arise in the axillae, groin, perianal, and/or inframammary areas; often very painful (Fig. 31.11A, B).
- **With time** sinus tracts (Fig. 31.11B, C) and hypertrophic scars develop (Fig. 31.11D); chronic, malodorous drainage also occurs.
- **Complications** may include anemia of chronic disease, secondary amyloidosis, lymphedema, fistulas, arthropathy, and the rare development of SCCs within the chronic scars.
- **DDx:** staphylococcal furunculosis, Crohn disease, granuloma inguinale, mycetoma, and scrofuloderma (a form of tuberculous lymphadenitis with cutaneous extension).
- **Rx:** difficult to treat and no one perfect treatment exists; a therapeutic approach, based on disease severity is outlined in Table 31.7.
- Avoid incision and drainage, as may lead to further scarring and sinus tract formation.
- In general, medical treatment is recommended in early stages; surgical treatment should be performed as early as possible once abscesses, fistulas, sinus tracts, and scars develop.

For information on the following follicular disorders, refer to the associated chapters: lichen spinulosus (Ch. 9), trichostasis spinulosa (Ch. 29), erythromelanosis follicularis faciei (Ch. 30), phrynoderma (Ch. 43), viral-associated trichodysplasia (Ch. 68), and keratosis pilaris atrophicans (Ch. 82)

For further information see Ch. 38 from *Dermatology, Fourth Edition*.

**For additional online figures visit www.expertconsult.com**




**Fig. 31.2 Folliculitis of the axilla and beard area due to *Staphylococcus aureus*. A** Numerous follicular pustules with an erythematous rim emanating from the axillary vault. **B** Discrete papulopustules are seen posteriorly, while centrally there is deeper involvement with plaque formation (sycosis barbae). *A, Courtesy, Kalman Watsky; B, Courtesy, YDRSC.*




**Fig. 31.3 *Pseudomonas* "hot tub" folliculitis. A, B** Edematous follicular papules on the flank that began to develop 2–3 days following the use of a hot tub. The number and size can vary. *A, Courtesy, YDRSC; B, Courtesy, Kalman Watsky, MD.*

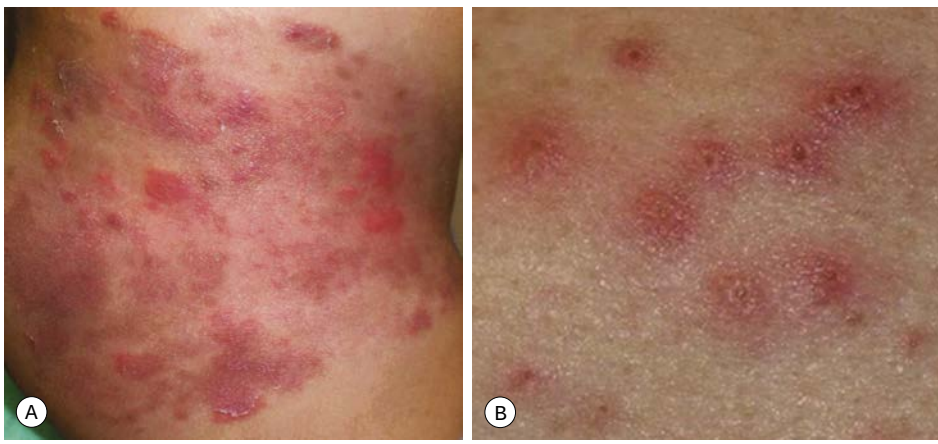


**Fig. 31.4 Folliculitis – fungal, viral, and ectoparasitic. A** Firm follicular papules of dermatophyte folliculitis (Majocchi granuloma) in the setting of extensive tinea corporis. **B** Follicular herpes simplex viral infection in an immunocompromised host. *A, Courtesy, Amy McMichael, MD; B, Courtesy, Karynne O. Duncan, MD.* *Continued*







**Fig. 31.4** *Continued* **Folliculitis – fungal, viral, and ectoparasitic. C** Numerous papules and papulopustules of *Demodex* folliculitis on the face and neck; note the edematous nature of several of the lesions. **D** Microscopic findings of follicular contents obtained via scraping of *Demodex* folliculitis. *C, Courtesy, Angela Hernandez-Martin, MD; D, Courtesy, YDRSC.*

| FORMS OF SYCOSIS | |
|---|---|
| **Type** | **Characteristics** |
| Barbae | • Bacterial folliculitis of the beard and/or mustache areas, usually caused by *Staphylococcus aureus* (see Fig. 31.2B)<br>• Deep-seated, edematous, perifollicular papules and pustules that may coalesce to form plaques studded with pustules and crusts<br>• Subacute to chronic course with frequent relapses |
| Lupoid | • Scarring form of deep folliculitis, typically affecting the beard area; may be caused by *S. aureus* (although cultures often fail to reveal pathogenic organisms)<br>• Peripheral extension of perifollicular papules and pustules with central atrophic scarring/cicatricial alopecia; granulomatous inflammation can lead to an appearance reminiscent of lupus vulgaris<br>• Chronic course, refractory to treatment |
| Mycotic | • Dermatophyte folliculitis of the beard area (most often the chin), usually caused by zoophilic organisms<br>• Inflammatory perifollicular papules and pustules coalesce to form nodules and plaques with purulent discharge from patulous follicles, crusting, and loose hairs that can be painlessly removed (Fig. 31.7) |
| Herpetic | • See Table 31.2 |

**Table 31.3 Forms of sycosis.** Sycosis is defined as chronic inflammation of hair follicles, especially of the beard.



**Fig. 31.5 Folliculitis (culture-negative).** Follicular pustules with an erythematous rim are present on the upper back. The differential diagnosis is primarily folliculitis due to *Staphylococcus aureus* and acne. *Courtesy, YDRSC.*







**Fig. 31.6 Immunosuppression-associated eosinophilic folliculitis. A** Multiple follicular papules on the anterior trunk in a patient who had received an allogeneic hematopoietic stem cell transplant. Note the edematous nature of some of the lesions. Very few pustules were present. **B** In some patients, multiple follicular pustules are seen. *A, Courtesy, Dennis Cooper, MD; B, Courtesy, Luis Requena, MD.*



**Fig. 31.7 Mycotic sycosis.** Firm plaque of the upper cutaneous lip studded with multiple pustules due to a zoophilic dermatophyte. *Courtesy, Kalman Watsky, MD.*

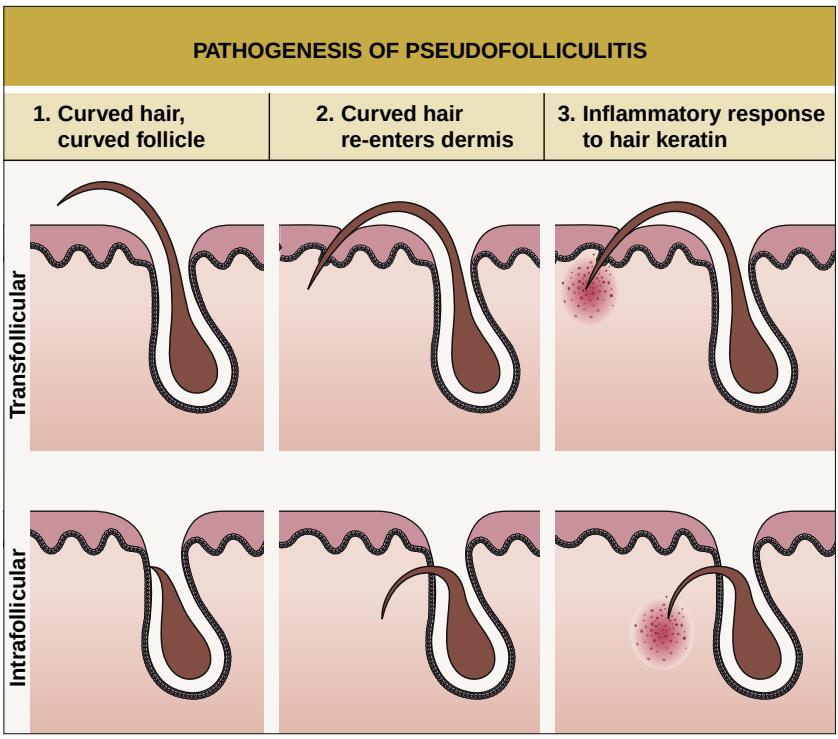


**Fig. 31.8 Pathogenesis of pseudofolliculitis.** *Courtesy, M.A. Abdallah, MD.*



**Fig. 31.9 Pseudofolliculitis barbae.** Multiple firm hyperpigmented papules on the lower face and neck (beard distribution). *Courtesy, A. Paul Kelly, MD.*

| ADVICE ON SHAVING METHODS FOR PATIENTS WITH PSEUDOFOLLICULITIS BARBAE |
|---|
| **Important points** |
| • Do not pull the skin taut<br>• Do not shave against the grain/direction of hair growth<br>• Use a sharp razor each time, preferably multiblade<br>• Take short strokes (with the grain of the hair) and do not shave over the same areas more than twice |
| **Method** |
| 1. Remove pre-existing hairs with electric clippers, leaving approximately 1–2 mm of stubble<br>2. Wash area with non-abrasive acne soap and rough wash cloth; in areas with "ingrown hairs," gentle massaging with a soft toothbrush may help<br>3. Rinse area with water, then compress face with warm tap water for several minutes<br>4. Using shaving cream of your choice, massage moderate amount of lather on area to be shaved (do not allow lather to dry; if it does, reapply it)<br>5. Use a sharp blade (whichever type seems to cut best but not too close) and shave with the grain of the hair using short even strokes with minimal tension (and no more than twice over one area); in hard-to-shave areas, you may need to shave against the grain<br>6. After shaving, rinse with tap water and then apply the most soothing aftershave preparation of your choice. If significant burning or itching ensues, a topical CS cream or lotion (1–2.5% hydrocortisone) can be used as an alternative aftershave preparation |

**Table 31.4 Advice on shaving methods for patients with pseudofolliculitis barbae.** *Courtesy, A. Paul Kelly, MD.*

| THERAPEUTIC APPROACH TO PSEUDOFOLLICULITIS BARBAE | |
|---|---|
| Shaving | • Mild to moderate disease: continue shaving daily, but follow guidelines in Table 31.4<br>• Severe disease: discontinue shaving until all inflammatory lesions have cleared and all "ingrown hairs" are released; during this period, the patient can trim beard to a minimum length of 0.5 cm using scissors or electric clippers |
| Compresses and release of ingrowing hairs | • Warm tap water, saline, or Burow's solution (aluminum acetate) compresses for 10 minutes three times daily to soothe lesions, remove any crusts, reduce drainage secondary to inflammation and/or excoriations, and soften the epidermis to allow easier release of "ingrown hairs" |
| Topical therapy | • Low-potency topical CS lotion and/or topical clindamycin should be applied after compresses and freeing of embedded hairs |
| Secondary bacterial infection | • Appropriate systemic antibiotic should be prescribed, based upon bacterial cultures |
| Recalcitrant disease | • Prednisone (45–60 mg) or its equivalent every morning for 7–10 days may be necessary<br>• Topical eflornithine cream twice daily may be helpful*<br>• Laser hair removal (utilizing appropriate laser for skin color) with goal of permanent hair reduction |
| **Based upon case series.* | |

**Table 31.5 Therapeutic approach to pseudofolliculitis barbae.** *Courtesy, A. Paul Kelly, MD.*







**Fig. 31.10 Acne keloidalis. A** Keloidal papulonodules and a large plaque of the occipital scalp, associated with scarring alopecia. Note the tufts of hair at the superior border of the scar (arrows). **B** A close-up view, showing an admixture of follicular papules, crusted papules, and firm fibrotic hyperpigmented papules on the posterior neck and occipital scalp. There is associated alopecia. *A, Courtesy, A. Paul Kelly, MD; B, Courtesy, A. Paul Kelly, MD, and Amy McMichael, MD.*

| THERAPEUTIC OPTIONS FOR ACNE KELOIDALIS | |
|---|---|
| Non-inflamed papules and plaques | Mixture of tretinoin gel and potent CS gel twice daily |
| Inflamed lesions with pustules | Bacterial culture and appropriate systemic antibiotic or a course of oral isotretinoin |
| Small keloidal papules | Intralesional CS (e.g. triamcinolone acetonide 5–20 mg/ml)<br>Punch excision to below level of hair follicles |
| | Close primarily or allow to heal secondarily<br>Laser hair removal for permanent hair reduction |
| Plaques ≤1.5 cm in vertical diameter | Excise and close primarily |
| Larger plaques and nodules (>1.5 cm in vertical diameter) | Excise with horizontal ellipse |
| | Extend excision below posterior hairline and include fascia or deep subcutaneous tissue |
| | Allow to heal by second intention |
| | Do not inject CS into postoperative site |
| | Laser excision and cryosurgery are sometimes successful |
| Postoperative care | Topical imiquimod daily for 6 weeks (8 weeks every other day if irritation) |
| Maintenance | Tretinoin–CS gel mixture, intermittent intralesional CS and/or oral or topical antibiotics (when needed) |

**Table 31.6 Therapeutic options for acne keloidalis.** *Courtesy, A. Paul Kelly, MD.*

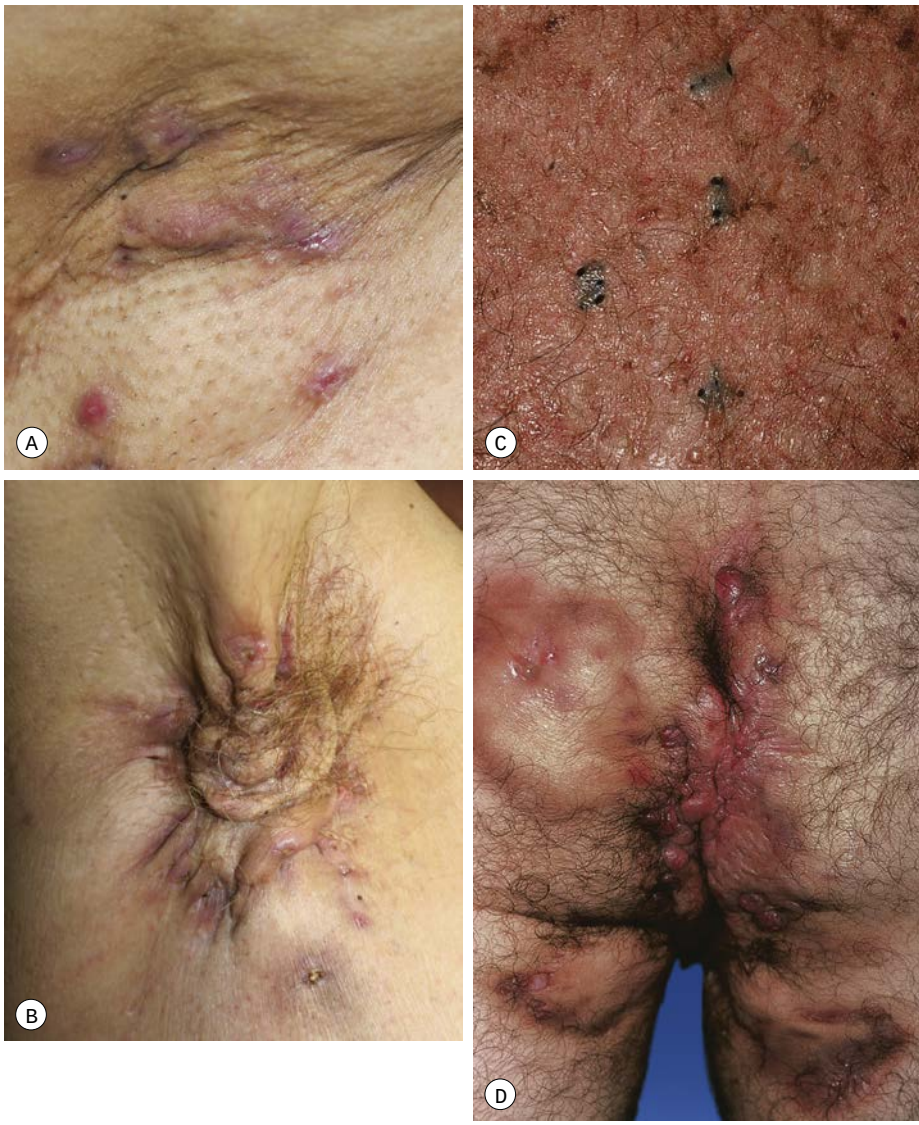


**Fig. 31.11 Hidradenitis suppurativa. A, B** Papulopustules, nodules, sinus tracts, and scarring in the axilla (Hurley stage II **[A]** and III **[B]**). **C** Superficial sinus tracts that serve as a clue to the diagnosis, even in the absence of active disease. **D** Severe disease (Hurley stage III) with inflammatory nodules, hypertrophic scarring, draining fistulae, and sinus tract formation of the perianal region, buttocks, and upper thighs. This is the type of patient who is at risk for the development of squamous cell carcinoma and secondary amyloidosis. *A, Courtesy, Kalman Watsky, MD; B, Courtesy, Marco Romanelli, MD; C, D, Courtesy, YDRSC.*

| HIDRADENITIS SUPPURATIVA (HS) – GRADING SYSTEMS AND THERAPEUTIC LADDER | |
|---|---|
| **Hurley staging system** | |
| Stage I – one or more abscesses with no sinus tract or scar formation<br>Stage II – one or more widely separated recurrent abscesses, with sinus tract and scar formation<br>Stage III – multiple interconnected sinus tracts and abscesses throughout an affected region; more extensive scarring | |
| **Other grading/scoring systems** | |
| 1. **Sartorius grading system** (based upon anatomical regions, types of lesions, and distance between lesions)<br>2. **Modified Sartorius score** (more detailed, requiring measurements and precise counting of lesions)<br>3. **HS-PGA** (categorizes patients into clear, minimal, mild, moderate, severe, or very severe disease)<br>4. HS clinical response (HiSCR) score (a binary scoring system for patients with 3 or more abscesses or inflammatory nodules) | |
| **Therapeutic ladder** | |
| **Indication** | **Therapeutic interventions** |
| General measures | • If obese or overweight, weight reduction<br>• Reduce friction and moisture via loose undergarments, absorbent powders, and topical aluminum chloride<br>• Antiseptic soaps (e.g. chlorhexidine)<br>• Smoking cessation |
| Hurley Stage I | • Intralesional triamcinolone (5–10 mg/ml) injections into early inflammatory lesions<br>• Topical clindamycin<br>• Eradication of *S. aureus* carriage with topical mupirocin in nose, axillae, umbilicus, and perianal regions<br>• Oral antibiotics tailored to results of bacterial cultures from pustular discharge or abscess contents<br>• Oral antibiotic therapy (alone or in combination) for its anti-inflammatory effect (rifampin + clindamycin*, tetracycline, doxycycline, minocycline, dapsone, trimethoprim–sulfamethoxazole)<br>• Oral anti-androgen therapy (e.g. oral contraceptives, spironolactone, finasteride [for males]) |
| Hurley Stage II (see Fig. 31.11A) | • Oral antibiotic therapy (see Stage I)<br>• Acitretin<br>• Systemic immunosuppressive agents including adalimumab^, infliximab, and cyclosporine<br>Surgical treatments†<br>• Limited local excisions with second intention healing<br>• $CO_2$ laser ablation with second intention healing<br>• Nd:YAG laser treatments, at least 3–4 monthly sessions |
| Hurley Stage III (see Fig. 31.11B, D) | Medical treatments outlined for Stages I and II<br>Surgical treatments†<br>• Early wide surgical excision of involved areas<br>• $CO_2$ laser ablation with second intention healing |

**There is the most evidence of effectiveness for this combination of antibiotics, each dosed at 300 mg twice a day; note that rifampin may turn body secretions orange in color.*
*^FDA-approved dosing regimen: 160 mg (four 40 mg injections) on Day 1 -or- 80 mg daily on Days 1 and 2 followed by 80 mg on Day 15 then 40 mg on Day 29 and weekly thereafter.*
*†Incision and drainage is discouraged given high rate of recurrence.*

**Table 31.7 Hidradenitis suppurativa (HS) – grading systems and therapeutic ladder.** For further information see Ch. 38 from *Dermatology, Fourth Edition*. PGA, physician global assessment.

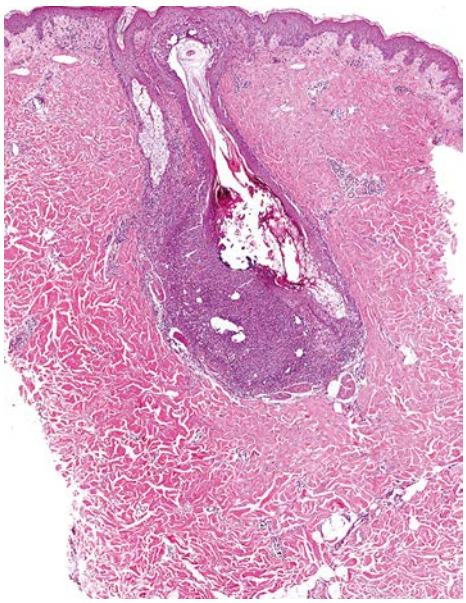

**eFig. 31.1 Histopathologic features of folliculitis.** Follicular and perifollicular abscess composed predominantly of neutrophils. The hair follicle is dilated and focally ruptured. *Courtesy, Lorenzo Cerroni, MD.*

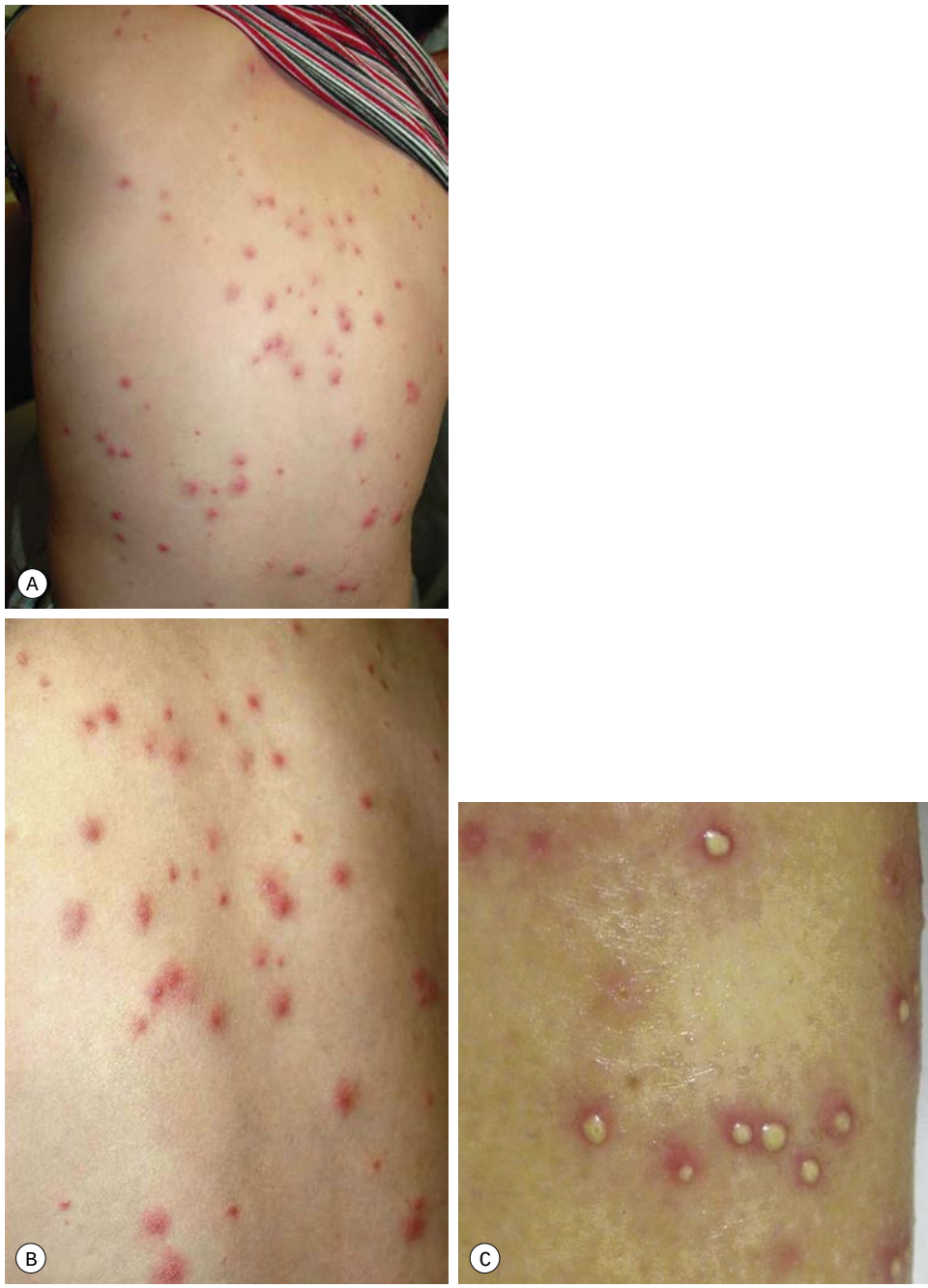


**eFig. 31.2 Folliculitis due to *Staphylococcus aureus*. A** Widespread follicular pustules limited to the back of a sedated psychiatric patient. On closer examination **(B)**, the characteristic follicular papulopustules on an erythematous base are seen, along with a collarette of scale on an older lesion, located centrally in the photo. **C** Close-up follicular pustules on the leg. *A, B, Courtesy, Julie V. Schaffer, MD; C, Courtesy, Luis Requena, MD*.



**eFig. 31.3 Folliculitis – ectoparasitic.** Edematous papules of *Demodex* folliculitis superimposed on the characteristic background erythema. *Courtesy, Kalman Watsky, MD*




**eFig. 31.4 Immunosuppression-associated eosinophilic folliculitis. A** Multiple follicular papules on the chest in the setting of AIDS. There are two punch biopsy sites. Note the edematous nature of some of the lesions. **B** Multiple pruritic follicular papules on the face of an HIV-infected woman. There is also postinflammatory hyperpigmentation. *Courtesy, YDRSC.*

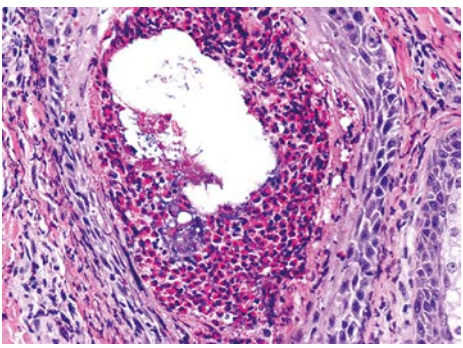

**eFig. 31.5 Histopathologic features of immunosuppression-associated eosinophilic folliculitis.** A dilated hair follicle with an intrafollicular collection of eosinophils; a few eosinophils are also present within the follicular epithelium. *Courtesy, Luis Requena, MD.*



**eFig. 31.6 Eosinophilic pustular folliculitis of infancy.** Crusted papules and pustules on the scalp of a one-year-old boy. *Courtesy, Deborah S. Goddard, MD, Amy E. Gilliam, MD, and Ilona J. Frieden, MD.*



**eFig. 31.7 Disseminate and recurrent infundibulofolliculitis (of Hitch and Lund).** Numerous monotonous follicular papules on the chest. *Courtesy, Jean L. Bolognia, MD.*



**eFig. 31.8 Acne keloidalis.** Keloidal papulonodules and a large plaque of the occipital scalp, associated with scarring alopecia in a Hispanic patient. *Courtesy, Luis Requena, MD.*

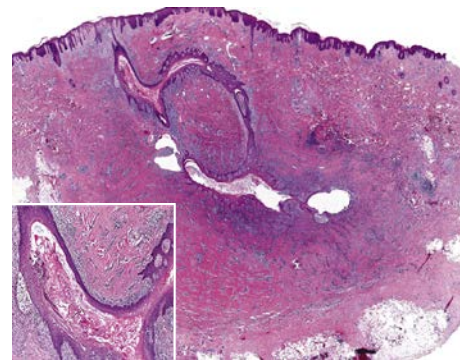

**eFig. 31.9 Histopathologic features of hidradenitis suppurativa.** A keratin-filled sinus tract (inset) is seen within the dermis, extending into the subcutaneous fat. It is surrounded by marked fibrosis and mixed inflammatory infiltrates. *Courtesy, Lorenzo Cerroni, MD.*

# 32 Disorders of Eccrine and Apocrine Glands

Eccrine and apocrine glands represent the two major types of sweat glands (see Fig. 91.1).

## Eccrine Glands

- Functional from birth and activated by thermal stimuli via the hypothalamic sweat center; while their major function is thermoregulation by evaporative heat loss, they are also activated by emotional stimuli.
- Innervated by sympathetic fibers that have acetylcholine as their major neurotransmitter.
- Generalized distribution, with greatest concentration on the palms and soles.
- The eccrine duct opens directly onto the skin surface, and the excretory product is a clear hypotonic fluid that is mostly water but also contains NaCl.

## Apocrine Glands

- Unclear function in humans; functional development requires androgens.
- More limited distribution – primarily axillae, nipples/areolae, and umbilical and anogenital regions; modified apocrine glands are found in the external auditory canals and eyelid margins.
- The apocrine duct drains into the superficial portion of the hair follicle (see Fig. 91.1).
- "Decapitation" of apocrine gland cells produces an odorless and viscous fluid; however, its degradation by flora on the skin surface can lead to an odor.

## Hyperhidrosis

- Excessive production of eccrine sweat is usually due to *primary cortical* (emotional) hyperhidrosis and the favored sites are the axillae or palms and soles (Fig. 32.1) > the face (Fig. 32.2); involvement is bilateral and symmetric (Fig. 32.3).
- *Secondary cortical* hyperhidrosis is associated with genodermatoses, including palmoplantar keratodermas and epidermolysis bullosa simplex; associated odor reflects maceration and degradation of keratin by bacteria.



**Fig. 32.1 Volar hyperhidrosis (primary cortical).** The palmoplantar skin displays excessive eccrine sweat production, including the portions that extend onto the sides of the hands, feet, and digits. Its onset is during childhood as opposed to axillary hyperhidrosis, which has its onset around puberty. *Courtesy, Jean L. Bolognia, MD.*



**Fig. 32.2 Primary cortical (emotional) hyperhidrosis involving the face.** Sweat droplets are evident on the upper cutaneous lip, jawline, and chin. *Reproduced from Hurley HJ. Hyperhidrosis. Curr Opin Dermatol. 1997;4:105–114. Philadelphia: Rapid Science Publishers.*



**Fig. 32.3 Palmar hyperhidrosis as assessed by the semiquantitative starch paper–iodine technique.** Sweating can also be demonstrated directly on palmar skin by the starch–iodine technique, as shown in Figs 32.4 and 32.5. *Courtesy, Harry Hurley, MD.*

| CAUSES OF SECONDARY HYPOTHALAMIC HYPERHIDROSIS |
|---|
| • **Infections**, e.g. acute febrile bacterial and viral infections (defervescence), malaria |
| • **Neoplasms**, e.g. lymphoma (B symptom), pheochromocytoma |
| • **Endocrinologic disorders**, e.g. hypoestrogenemia of menopause, hyperthyroidism |
| • **Vasomotor disorders**, e.g. cold injury, Raynaud phenomenon, RSD |
| • **Neurologic diseases**, e.g. CNS tumors, CVAs (contralateral) |
| • **Drugs and toxins**, e.g. opioid withdrawal, alcohol withdrawal, combination of drugs that result in the serotonin syndrome (MAOI plus tricyclic or SSRI antidepressant) |
| • **Miscellaneous**, e.g. compensatory in the setting of a sympathectomy, extensive miliaria or diabetes mellitus |

**Table 32.1 Causes of secondary hypothalamic hyperhidrosis.** CVA, cerebrovascular accident; MAOI, monoamine oxidase inhibitor; RSD, reflex sympathetic dystrophy, also referred to as complex regional pain syndrome. Linezolid is an MAOI.

• *Secondary hypothalamic* (thermoregulatory) hyperhidrosis can be due to a number of systemic diseases, from infections to neoplasms (Table 32.1).
• *Secondary medullary* (gustatory) hyperhidrosis can be physiologic as exemplified by the facial sweating that occurs with spicy foods, or pathologic as occurs in Frey syndrome (Fig. 32.4); in the former, taste receptors send afferent impulses, whereas in the latter, disrupted nerves for sweat aberrantly connect with nerves for salivation.
• Injuries or diseases affecting the spinal cord can result in segmental hyperhidrosis.
• In addition to embarrassment, hyperhidrosis can lead to overhydration of the skin and a higher risk of bacterial and fungal infections.



**Fig. 32.4 Gustatory sweating in the auriculotemporal (Frey) syndrome, as a consequence of parotid surgery.** The blue-black area represents sweating (starch–iodine technique). Salivary stimulation induced this sweating response. *Reproduced from Hurley HJ. Hyperhidrosis. Curr Opin Dermatol. 1997;4:105–114. Philadelphia: Rapid Science Publishers.*

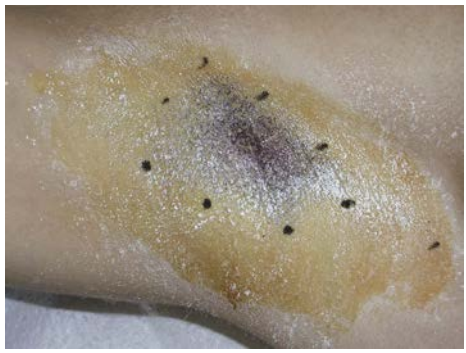

**Fig. 32.5 Delineation of area for injections of botulinum toxin A for axillary hyperhidrosis (starch–iodine technique).** Blue-black areas represent foci of sweating. In the case of onabotulinumtoxin A, a total of 50–100 U is injected, utilizing 10–15 injection sites. *Courtesy, Alastair Carruthers, MD, and Jean Carruthers, MD.*

- Sweating only during waking hours points to primary cortical (emotional) hyperhidrosis; after consideration of possible underlying etiologies, topical antiperspirants containing aluminum chloride (e.g. Certain Dri®) or aluminum chloride hexahydrate (e.g. Xerac™ AC [6.25%], Drysol® [20%]) can be applied at bedtime, and if necessary, initially preceded by oral glycopyrrolate or oxybutynin. A glycopyrronium-containing cloth can also be applied daily.
- Injection of botulinum toxin type A every ~6 months is very effective for primary cortical (emotional) hyperhidrosis (Fig. 32.5); tap water iontophoresis is less effective.

## Hypohidrosis (and Anhidrosis)

- There are multiple etiologies of hypohidrosis and anhidrosis including the following:
  - A side effect of medications with anticholinergic properties (e.g. atropine, tricyclic antidepressants, glycopyrrolate)
  - Manifestation of inherited disorders, in particular ectodermal dysplasias (see Ch. 52), as well as acquired disorders such as Sjögren syndrome
  - Neurologic disorders, from tumors or infarcts of the hypothalamus, pons or medulla to peripheral neuropathies
  - Rarely, and primarily in Asians, due to acquired idiopathic generalized anhidrosis
- Increased risk of developing hyperthermia.
- Evaluation includes colorimetric testing (see Fig. 32.5) and biopsy of affected skin.

## Bromhidrosis (Foul-Smelling Sweat)

- *Eccrine* variant associated with degradation of sweat by resident microflora; most commonly involves the feet.
- *Apocrine* variant associated with degradation of odiferous substances by skin flora (e.g. the breakdown of a precursor molecule into a sulfurous thioalcohol by *S. hominis*)
- The smell can be rancid (*Corynebacterium*) or sweaty (*Micrococcus*).
- Rarely, it is a sign of an inherited metabolic disorder, e.g. maple syrup urine disease.

## Chromhidrosis

- Colored sweat can be *intrinsic* and due to the lipofuscin content of apocrine sweat (yellow, green, black) or *extrinsic* and due to staining of sweat by clothing or chromogenic bacteria (e.g. *Corynebacterium*) or fungi.

## Sweat Retention Disorders

### Miliaria

- Excessive sweating leads to maceration and blockage of eccrine ducts; can be exacerbated by occlusion, e.g. clothing, athletic equipment, prolonged bed rest.
- Classically divided into three major types: (1) *crystallina* – tiny, superficial, short-lived, clear vesicles (Fig. 32.6; see Fig. 28.3A); (2) *rubra* (prickly heat) – pruritic erythematous papulovesicles and occasionally pustules that favor the upper trunk (Fig. 32.7); and (3) *profunda* – white papules due to excessive sweating in a hot climate (rare); these three forms reflect ductal occlusion within the stratum corneum, mid-epidermis, and dermal–epidermal junction, respectively.
- If extensive, decrease in eccrine function can give rise to hyperpyrexia.
- **DDx:** miliaria rubra needs to be distinguished from folliculitis, Grover disease, neutrophilic eccrine hidradenitis, and cutaneous candidiasis.
- **Rx:** cool environment.

### Fox–Fordyce Disease (Apocrine Miliaria)

- Occlusion then rupture of apocrine sweat gland ducts in the axillae > anogenital or periareolar region > periumbilical or presternal area; seen primarily in women ages 15–35 years.



**Fig. 32.6 Miliaria crystallina.** Multiple small superficial vesicles with clear fluid. *Courtesy, YDRSC.*

- Multiple skin-colored papules that are follicular, dome-shaped, and often pruritic (Fig. 32.8).
- May improve with oral contraceptive pills (OCPs) or pregnancy.
- **Rx:** topical CS or calcineurin inhibitors and OCPs.

### Grover Disease

- Grover disease (transient acantholytic dermatosis) is covered in Ch. 73.

## Hidradenitis

### Neutrophilic Eccrine Hidradenitis

- Most commonly related to administration of chemotherapy (e.g. cytarabine) and is thought to result from excretion of the drug(s) into the eccrine sweat, leading to a toxic insult.
- Erythematous papules and plaques that may have clinical overlap with Sweet syndrome (Fig. 32.9).




**Fig. 32.7 Miliaria rubra.** Multiple erythematous nonfollicular papules and papulovesicles on the back (**A**) and arm (**B**) of two adults and the upper trunk and neck of a neonate (**C**). Note that several of the lesions in the neonate have become pustular. *A, Courtesy, YDRSC; B, Courtesy, Jennifer Powers, MD; C, Courtesy, Julie V. Schaffer, MD.*



**Fig. 32.8 Fox–Fordyce disease.** Monomorphic skin-colored papules in the axillary vault. The dome shape is appreciated in the inset. *Courtesy, YDRSC.*



**Fig. 32.9 Neutrophilic eccrine hidradenitis.** Pink annular plaque on the dorsal hand. *Courtesy, Jeffrey P. Callen, MD.*

- **Rx:** spontaneously resolves but sometimes a short course of systemic CS is prescribed once an infectious process such as cellulitis or septic emboli is excluded.

### Idiopathic Palmoplantar Hidradenitis

- Occurs following vigorous physical activity, primarily in healthy children.
- Thought to be precipitated by rupture of eccrine glands.
- Erythematous, tender nodules appear suddenly, most often on the soles (Fig. 32.10), and then spontaneously resolve over days to weeks.



**Fig. 32.10 Idiopathic palmoplantar hidradenitits.** Tender erythematous papules and nodules on the plantar surface. *Courtesy, Michael L. Smith, MD.*



**Fig. 32.11 Keratolyis exfoliativa.** Small annular collarettes of scale on the palm. *Courtesy, Jean L. Bolognia, MD.*

- **DDx:** *Pseudomonas* hot-foot syndrome, pernio, symmetric lividity of the soles, delayed pressure urticaria.

## Other

### Keratolysis Exfoliativa

- Common disorder in healthy individuals; affects the palms >> soles.
- Multiple annular and semi-annular collarettes of white scale that usually measure <5 mm, but may be larger (Fig. 32.11); no preceding vesicles or inflammation clinically.
- Recurrent and sometimes associated with hyperhidrosis.
- **Rx:** nonspecific; effectiveness of topical agents, e.g. 12% ammonium lactate, 20% urea, is limited.

For further information see Chs 35 and 39 from *Dermatology, Fourth Edition*.

**For additional online figures visit www.expertconsult.com**



**eFig. 32.1 Volar hyperhidrosis (primary cortical).** The palmoplantar skin displays excessive eccrine sweat production. Its onset is during childhood as opposed to axillary hyperhidrosis, which has its onset around puberty. *Courtesy, Jean L. Bolognia, MD.*

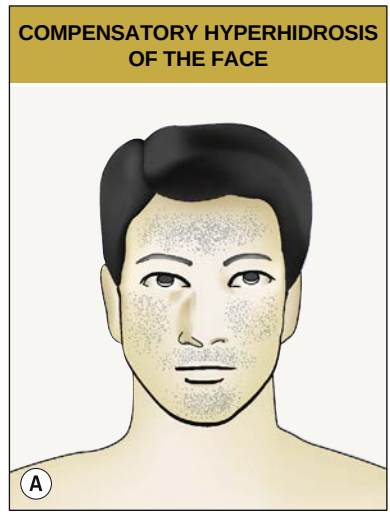





**eFig. 32.2 Compensatory hyperhidrosis of the face. A** Outline of the sites of facial compensatory hyperhidrosis in patients with extensive miliaria. **B** Facial compensatory hyperhidrosis (upper lip and chin) in a patient with diabetes mellitus (starch–iodine technique). *Courtesy, Harry Hurley, MD.*



**eFig. 32.3 Eccrine angiomatous hamartoma.** Cluster of painful pink-violet papules and plaques on the thigh and knee that had been present since one year of age. There was associated hyperhidrosis, but not hypertrichosis. Histologically, an increased number of both eccrine glands and small blood vessels is seen. *Courtesy, Julie V. Schaffer, MD.*

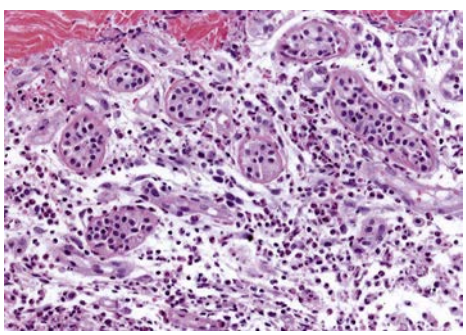

**eFig. 32.4 Neutrophilic eccrine hidradenitis – histopathologic features.** Neutrophils surround and infiltrate the eccrine glands and coils. There are degenerative changes of primarily secretory cells. *Courtesy, Lorenzo Cerroni, MD.*

# Lupus Erythematosus 33

## General

- A multisystem AI-CTD disorder that prominently affects the skin.
- Broadly divided into systemic lupus erythematosus (SLE), cutaneous lupus erythematosus (CLE), and drug-induced lupus erythematosus (DI-LE) (Fig. 33.1).
- CLE is further classified into *specific* and *nonspecific* skin lesions, based on the histopathologic presence (*specific*) or absence (*nonspecific*, Table 33.1) of an "interface dermatitis"; however, this is not a perfect classification scheme because some specific entities (e.g. LE tumidus, lupus panniculitis) do not demonstrate an "interface dermatitis" and other, non-lupus entities may display an "interface dermatitis" on histopathology (e.g. dermatomyositis).
- Classically, the three major forms of *specific* skin lesions are chronic cutaneous LE (CCLE), subacute cutaneous LE (SCLE), and acute cutaneous LE (ACLE), with CCLE being subdivided into four different entities (see Fig. 33.1 and Fig. 33.2).
- Cutaneous lesions may be the sole manifestation of LE or they may be associated with systemic disease (SLE), either concurrently or sequentially.
- For all types of LE: women > men; African Americans or Black Africans > other populations; onset typically post-puberty to middle age.
- Histopathologic examination of cutaneous lesions often plays an important role in establishing the diagnosis of CLE; direct immunofluorescence of lesional skin can be helpful in distinguishing CLE from other disorders, in particular lichen planus; accurate subtyping requires clinicopathologic correlation.
- Once a diagnosis of CLE is made, initial and longitudinal evaluation for systemic manifestations of SLE is recommended (Tables 33.2–33.3).
- Before making a definitive diagnosis of cutaneous lupus, it is necessary to exclude a drug-induced etiology (Tables 33.4–33.5).
- Treatment options for the various subtypes of CLE are fairly similar (Table 33.6).

## Drug-Induced Lupus Erythematosus

- There are two major forms: *drug-induced SLE (DI-SLE)* and *drug-induced SCLE (DI-SCLE)*; skin lesions are indistinguishable from classic, non-drug-related LE (Table 33.4).
- Attention should be given to those medications that were initiated within weeks to 9 months prior to the onset of the eruption (see Tables 33.4–33.5).
- Usually resolves upon discontinuation of the responsible medication along with sun protection and topical therapy; occasionally a patient will require systemic therapy for persistent disease.

## Cutaneous Lupus Erythematosus: Specific Lesions

### Chronic Cutaneous Lupus Erythematosus (CCLE)

#### DISCOID LUPUS ERYTHEMATOSUS (DLE)

- Most common skin manifestation of LE; the terms CCLE and DLE are often used interchangeably, but CCLE encompasses four entities (see Fig. 33.1).
- Overall, ~5–10% of patients will go on to develop SLE; DLE can also be a presenting manifestation of SLE.
- Three clinical variants of DLE are recognized:

**SPECTRUM OF LUPUS ERYTHEMATOSUS AND CLASSIFICATION OF CUTANEOUS LUPUS ERYTHEMATOSUS**

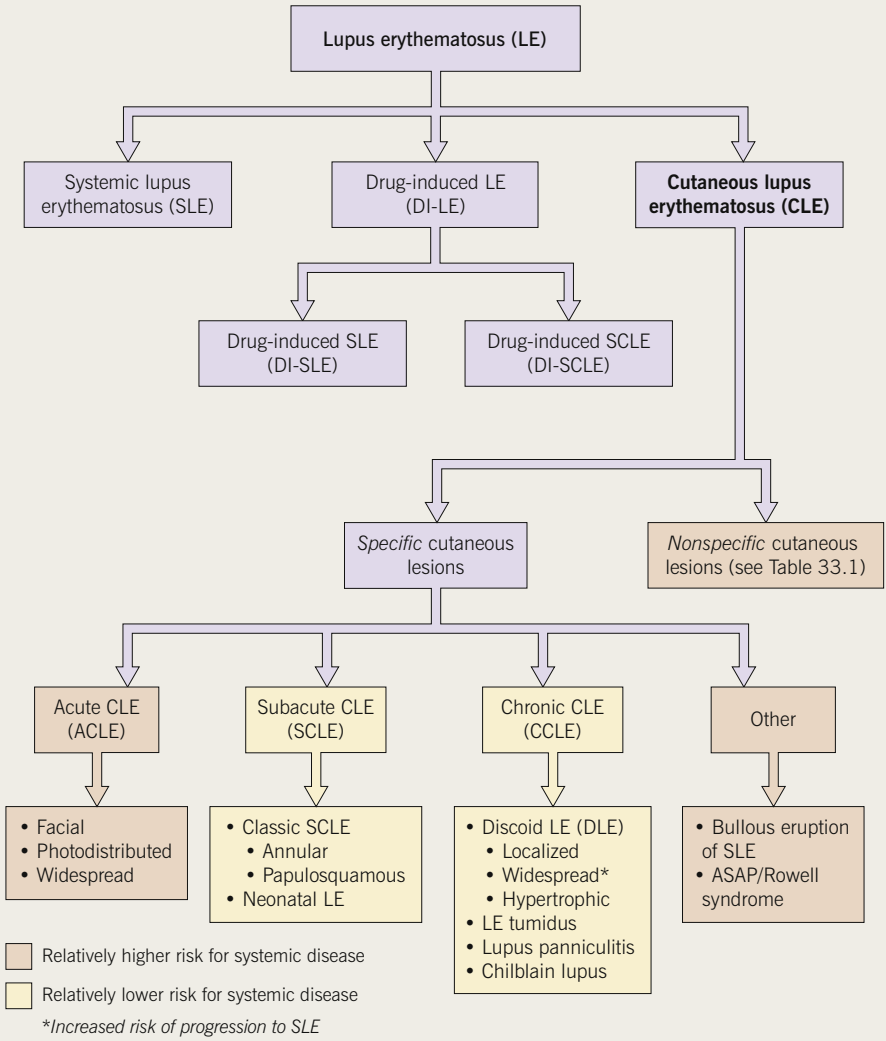


**Fig. 33.1 Spectrum of lupus erythematosus (LE) and classification of cutaneous LE.** The classification of cutaneous LE is based upon the classification system originally proposed by Gilliam and Sontheimer (Gilliam JN, Sontheimer RD. Distinctive cutaneous subsets in the spectrum of lupus erythematosus. J Am Acad Dermatol 1981; 4:471–5). ASAP, acute syndrome of apoptotic pan-epidermolysis.

- *Localized:* Most common; involves the head and neck region; ≤5% risk of progression to SLE
- *Widespread:* Lesions extend beyond the head and neck region to involve the extremities and/or trunk; up to 20% of patients can progress to SLE
- *Hypertrophic:* Unusual variant; favors extensor arms > face, upper trunk (Fig. 33.3H); thick scale overlying or at periphery of DLE lesions; may resemble hypertrophic actinic keratoses, SCC, hypertrophic lichen planus, or prurigo nodularis

• Occasionally can involve mucosal surfaces, palms and soles (see Fig. 33.3F,G).

• May occur in sun-exposed or sun-protected sites (e.g. scalp).

| CUTANEOUS FINDINGS (NONSPECIFIC) THAT SUGGEST THE DIAGNOSIS OF SYSTEMIC LUPUS ERYTHEMATOSUS |
|---|
| **Vascular lesions** |
| • Vasculitis<br>– Urticarial vasculitis<br>– Small vessel vasculitis<br>– Polyarteritis nodosa-like lesions<br>• Vasculopathy<br>– Raynaud phenomenon<br>– Livedo reticularis<br>– Nailfold telangiectasias and erythema<br>– Palmar erythema<br>– Livedoid vasculopathy<br>• Cutaneous signs of antiphospholipid syndrome<br>– Livedo reticularis (more widespread and persistent)<br>– Multiple subungual splinter hemorrhages<br>– Digital gangrene and cutaneous necrosis<br>– Superficial thrombophlebitis<br>– Degos-like lesions<br>– Atrophie blanche-like lesions<br>– Anetoderma |
| **Other** |
| • Alopecia<br>– "Lupus hair," diffuse and nonscarring<br>– Telogen effluvium<br>• Papulonodular mucinosis<br>• Sweet syndrome–like neutrophilic dermatosis |

**Table 33.1 Cutaneous findings (nonspecific) that suggest the diagnosis of systemic lupus erythematosus.** These cutaneous lesions are associated with LE but are not specific to LE itself. The presence of nonspecific LE skin lesions raises the possibility of SLE and may signify more significant internal disease. The presence of these nonspecific lesions should prompt an evaluation for SLE (see Tables 33.2 and 33.3).

**CHARACTERISTIC SITES OF INVOLVEMENT FOR THE THREE MAJOR SUBTYPES OF CUTANEOUS LUPUS ERYTHEMATOSUS**

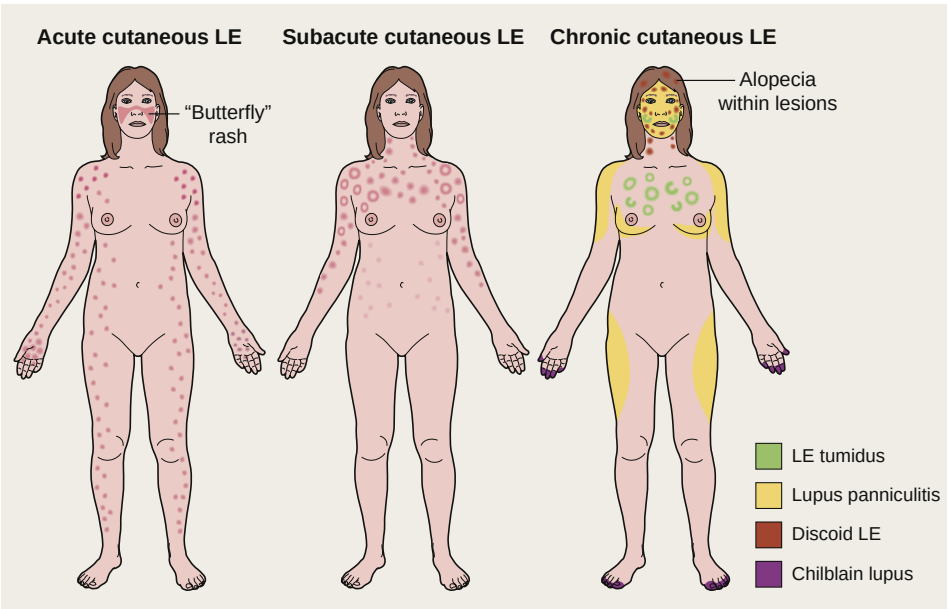


**Fig. 33.2 Characteristic sites of involvement for the three major forms of cutaneous lupus erythematosus (LE).**

| NEW EULAR/ACR CRITERIA FOR THE CLASSIFICATION OF SLE | | | |
|---|---|---|---|
| **Clinical domains** | **Points** | **Immunologic domains** | **Points** |
| **Constitutional domain** | | **Antiphospholipid antibody domain** | |
| Fever | 2 | Anticardiolipin IgG >40 GPL or anti β2GP1 IgG >40 units or lupus anticoagulant | 2 |
| **Cutaneous domain** | | **Complement proteins domain** | |
| Non-scarring alopecia | 2 | Low C3 or low C4 | 3 |
| Oral ulcers | 2 | Low C3 and low C4 | 4 |
| Subacute cutaneous or discoid lupus | 4 | **Highly specific antibodies domain** | |
| Acute cutaneous lupus | 6 | Anti-dsDNA antibody | 6 |
| **Arthritis domain** | | Anti-Smith antibody | 6 |
| Synovitis in at least two joints or tenderness in at least two joints, and at least 30 min of morning stiffness | 6 | All patients classified as having SLE must have a serum titer of antinuclear antibody of at least 1 : 80 on human epithelial-2 positive cells or an equivalent positive test. In addition, a patient must tally at least 10 points from these criteria. A criterion is not counted if it has a more likely explanation than SLE. Occurrence of the criterion only once is sufficient to tally the relevant points, and the time when a patient is positive for one criterion need not overlap with the time when the patient is positive for other criteria. SLE classification requires points from at least one clinical domain, and *if a patient is positive for more than one criterion in a domain, only the criterion with the highest point value counts.* | |
| **Neurologic domain** | | Please refer to online Tables 33.2 and 33.3 for 1) The 1997 Update of the 1982 American College of Rheumatology revised criteria for classification of systemic lupus erythematosus and 2) The 2012 Systemic Lupus International Collaborating Clinics classification criteria for SLE, respectively. | |
| Delirium | 2 | | |
| Psychosis | 3 | | |
| Seizure | 5 | | |
| **Serositis domain** | | | |
| Pleural or pericardial effusion | 5 | | |
| Acute pericarditis | 6 | | |
| **Hematologic domain** | | | |
| Leukopenia | 3 | | |
| Thrombocytopenia | 4 | | |
| Autoimmune hemolysis | 4 | | |
| **Renal domain** | | | |
| Proteinuria >0.5 gm/24 hr | 4 | | |
| Class II or V lupus nephritis | 8 | | |
| Class III or IV lupus nephritis | **10** | | |

**Table 33.2 New European League Against Rheumatism (EULAR) and American College of Rheumatology (ACR) criteria for the classification of SLE.** GPL refers to IgG Phospholipid Units; anti–β2GP1, anti–β2–glycoprotein 1; dsDNA, double-stranded DNA. *From Aringer M, Costenbader K, Daikh D, et al. 2019 European League Against Rheumatism/American College of Rheumatology classification criteria for systemic lupus erythematosus. Arthritis Rheumatol 2019; 71(9):1400–12. Copyright © 2019 American College of Rheumatology. Adapted with permission of John Wiley & Sons Inc.*

- **Early lesions:** inflamed, indurated plaques with erythema and scale.
- **Well-established lesions:** typically display follicular plugging, atrophy, scarring (and alopecia), and dyspigmentation (see Fig. 33.3A–E); the follicular plugging is often best appreciated in the conchal bowl of the ear.
- **DDx: Early lesions:** lymphocytic infiltrate of Jessner, polymorphic light eruption (PMLE), cutaneous lymphoid hyperplasia, lymphoma cutis, follicular mucinosis, granuloma faciale, sarcoidosis; **Late lesions:** tinea (e.g. capitis, corporis), lichen planus (hypertrophic, palmoplantar and mucosal variants), lichen planopilaris, sarcoidosis.
- **Typical Rx:** high-potency topical CS, intralesional CS (5 mg/ml), and/or antimalarials (see Table 33.6).

| EVALUATION FOR SYSTEMIC LUPUS ERYTHEMATOSUS |
|---|
| **History and review of systems** |
| **Physical examination** |
| • Specific cutaneous lesions (see Fig. 33.1)<br>• Nonspecific cutaneous lesions (see Table 33.1)<br>• Lymphadenopathy, arthritis, friction rubs |
| **Laboratory tests** |
| • ANA with profile (anti-dsDNA, -Sm)<br>• Urinalysis<br>• CBC with differential, platelet count<br>• Chemistries (BUN, Cr) and LFTs<br>• ESR, CRP<br>• Complement levels (C3, C4)<br>• Antiphospholipid antibodies |

**Table 33.3 Evaluation for systemic lupus erythematosus.** ds, double-stranded; Sm, Smith.

| CLASSIC DISTINCTIONS BETWEEN DRUG-INDUCED SUBACUTE CUTANEOUS LUPUS ERYTHEMATOSUS (DI-SCLE) AND DRUG-INDUCED SYSTEMIC LUPUS ERYTHEMATOSUS (DI-SLE) | | | | |
|---|---|---|---|---|
| **Disease** | **Most commonly associated medications** | **Cutaneous findings** | **Systemic findings** | **Associated autoantibodies** |
| DI-SCLE | • See Table 33.5 | • Identical to SCLE | • **Typically no systemic symptoms**<br>• Occasionally arthralgias | • Anti-SSA/Ro<br>• Anti-SSB/La |
| DI-SLE | • TNF inhibitors*, minocycline, hydralazine, procainamide, isoniazid, quinidine, methyldopa, chlorpromazine, interferons | • **Typically no skin findings**<br>• Occasionally malar or photodistributed erythema | • Constitutional symptoms such as fever, weight loss, myalgia<br>• Serositis (e.g. arthritis, pericarditis, pleuritis) | • Anti-histone**<br>• Anti-dsDNA (reported with TNF inhibitors) |

*TNF inhibitors have been associated with both DI-SCLE and DI-SLE (as well as drug-induced discoid lupus erythematosus).
**Anti-histone antibodies are not specific for DI-SLE as they are commonly found in patients with classic SLE, as well as in other autoimmune connective tissue diseases.

**Table 33.4 Classic distinctions between drug-induced SCLE (DI-SCLE) and drug-induced SLE (DI-SLE).**

### LUPUS ERYTHEMATOSUS (LE) TUMIDUS

- LE tumidus is an entity that overlaps with lymphocytic infiltrate of Jessner and reticular erythematous mucinosis (REM); there is debate as to whether it is a distinct entity or whether it should be considered a specific type of lupus.
- Photo-induced, but often this is not appreciated because of the delay of 1–2 weeks between UVR exposure and onset of the eruption.
- Most common on the face and upper trunk; reportedly <1% of patients eventually develop SLE.
- Lesions characterized by erythema, induration, and often central clearing (Fig. 33.4); scale, follicular plugging, scarring, and atrophy are absent.
- **DDx:** lymphocytic infiltrate of Jessner, PMLE, REM (chest lesions), papulonodular mucinosis, cutaneous lymphoid hyperplasia.

| MEDICATIONS ASSOCIATED WITH DRUG-INDUCED SUBACUTE CUTANEOUS LUPUS ERYTHEMATOSUS (DI-SCLE) |
|---|
| **More common/higher risk*** |
| **Terbinafine**<br>**Thiazide diuretics** (e.g. hydrochlorothiazide)<br>TNF inhibitors**<br>Proton pump inhibitors (e.g. lansoprazole, pantoprazole, omeprazole, esomeprazole**)<br>Calcium channel blockers (e.g. diltiazem, nifedipine, verapamil)<br>Anti-epileptics (e.g. carbamazepine, phenytoin)<br>Taxanes (e.g. docetaxel, paclitaxel)<br>Thrombocyte inhibitors (e.g. ticlopidine)<br>Anti-PD1 and anti-PD-L1 immunotherapy (nivolumab, pembrolizumab) |
| **Less common*** |
| ACE inhibitors (e.g. captopril, enalapril, lisinopril)<br>β-blockers<br>Doxorubicin<br>Interferon-α and -β<br>Leflunomide<br>Ranitidine<br>HMG-CoA reductase inhibitors ("statins")<br>Capecitabine** |
| **Medications are classified as being more common or having a higher risk if there were >10 cases reported in the literature as of 2020 or the relative risk was ≥2.0. Medications are classified as being less common if there have been 3–10 cases reported and the relative risk was <2.0.*<br>***Have also been associated with drug-induced discoid lupus erythematosus as well as drug-induced SLE (TNF inhibitors).* |

**Table 33.5 Medications associated with drug-induced subacute cutaneous lupus erythematosus (DI-SCLE).** Most common drugs are in bold. ACE, angiotensin converting enzyme.

#### LUPUS PANNICULITIS (SEE CH. 83)

- Initially characterized by intense inflammation in the subcutaneous fat; eventuates into lipoatrophy.
- The most common sites of involvement are the face, upper outer arms, upper trunk, breasts, buttocks, and thighs, with the majority representing sites of abundant fat (Fig. 33.5).
- Sometimes overlying DLE lesions are seen (termed "lupus profundus").

#### CHILBLAIN LUPUS (SLE PERNIO)

- Typically presents with erythematous to dusky purple papulonodules and plaques on the toes, fingers > nose, elbows, knees, and lower legs (Fig. 33.6).
- Lesions are triggered or exacerbated by cold temperatures, often in combination with damp conditions.
- With time, some lesions may progress to resemble DLE both clinically and histopathologically.
- **DDx:** idiopathic chilblains (following exclusion of SLE), familial chilblain lupus (*TREX1* or *SAMHD1* mutations), other cold-induced syndromes (see Ch. 74).
- Up to 20% of patients may go on to develop SLE.

### Subacute Cutaneous Lupus Erythematosus (SCLE)

- Characterized by non-scarring, annular, or papulosquamous eruptions in photodistributed sites (Fig. 33.7).
- Favors the upper trunk and upper outer arms > lateral neck, forearms, hands (see Fig. 33.7).
- Interestingly, often spares the mid-face
- Two common clinical presentations are recognized:
  - *Annular*: raised erythematous borders with central clearing (see Fig. 33.7B, C)
  - *Papulosquamous*: psoriasiform or eczematous appearance (see Fig. 33.7A)
- Long-term residual changes include dyspigmentation (most often hypo- to depigmentation).
- Approximately 10–15% of patients may over time develop SLE.

| SUGGESTED THERAPIES FOR CUTANEOUS LUPUS ERYTHEMATOSUS (CLE) |
|---|
| **General measures for all patients** |
| • Sun protective measures* |
| • Avoid potentially photosensitizing medications |
| • Stop smoking |
| • Oral vitamin $D_3$ supplementation, guided by serum vitamin $D_3$ levels |
| **Localized treatment options** |
| • Topical and intralesional CS |
| • Topical calcineurin inhibitors (facial lesions) |
| • Topical retinoids (perhaps helpful in hypertrophic DLE) |
| • Topical imiquimod 5% (anecdotal) |
| **Systemic treatment options** |
| **First-line** (antimalarials**) |
| • Hydroxychloroquine (*Adult*: 200 mg daily – twice daily, up to 5.0 mg/kg actual body weight/day or 400 mg/day (whichever is lower); *Children*: ≤5.0 mg/kg actual body weight/day up to a maximum of 400 mg/day) |
| • Chloroquine (*Adult*: 125–250 mg/day, up to 2.3 mg/kg actual body weight/day; *Children*: ≤2.3 mg/kg actual body weight/day) |
| • Quinacrine*** (in case of retinopathy) (*Adult* and *Children*: 100 mg/day) |
| **Second-line** (these agents may be combined with antimalarials or used alone) |
| • Methotrexate (7.5–25 mg/week, orally, IM, SC) |
| • Mycophenolate mofetil (1000–2000 mg/day) |
| • Oral retinoids† (e.g. acitretin, isotretinoin) |
| • Dapsone‡ (primarily for bullous eruption of SLE; 50–150 mg/day) |
| • Thalidomide† (50–100 mg/day for clearing and, if necessary, 25–50 mg/day – twice weekly for maintenance) |
| • Sulfasalazine |
| • Lenalidomide |
| **Third-line** (refractory cases) |
| • Azathioprine |
| • IVIg (costly) |
| • Belimumab (not as effective in African-Americans) |
| • Rituximab (best for SLE with severe active CLE) |
| **Life-threatening or severe inflammatory cutaneous disease** (e.g. ASAP/Rowell syndrome) |
| • Systemic CS |
| **Broad-spectrum sunscreen, sun avoidance, sun-protective clothing.* |
| ***Delayed onset of action (4–8 weeks); earlier institution may stave off progression of CLE to SLE; recommended monitoring includes baseline and every 6 month CBC, LFTs, BUN/Cr; and baseline/serial eye examinations.* |
| ****Quinacrine can be added, as combination therapy, to either hydroxychloroquine or chloroquine.* |
| *†Risk of teratogenicity; best if used concurrently with antimalarials, as the latter may reduce risk of thrombosis.* |
| *‡Exclude glucose-6-phosphate dehydrogenase deficiency.* |

**Table 33.6 Suggested therapies for cutaneous lupus erythematosus (CLE).** All patients should be counseled about daily sun protection, as both UVA and UVB can trigger flares of CLE and may even lead to exacerbations of systemic symptoms. Topical therapy is indicated in local disease and as an adjunct to systemic therapy in severe and widespread CLE. Systemic therapy is indicated when skin lesions are widespread, disfiguring, scarring, or refractory to topical agents, or when extracutaneous manifestations are present, e.g. arthritis. ASAP, acute syndrome of apoptotic pan-epidermolysis; DLE, discoid lupus erythematosus.

• Depending on the laboratory, ~70% of patients have associated anti-SSA/Ro antibodies.
• Roughly 50% of patients fulfill ≥4 American College of Rheumatology (ACR) criteria for SLE (see Table 33.2), but they rarely develop serious systemic involvement; arthralgias most common.
• **DDx: Annular variant:** dermatophytosis, granuloma annulare, erythema annulare centrifugum, or other annular erythemas (see Ch. 15);

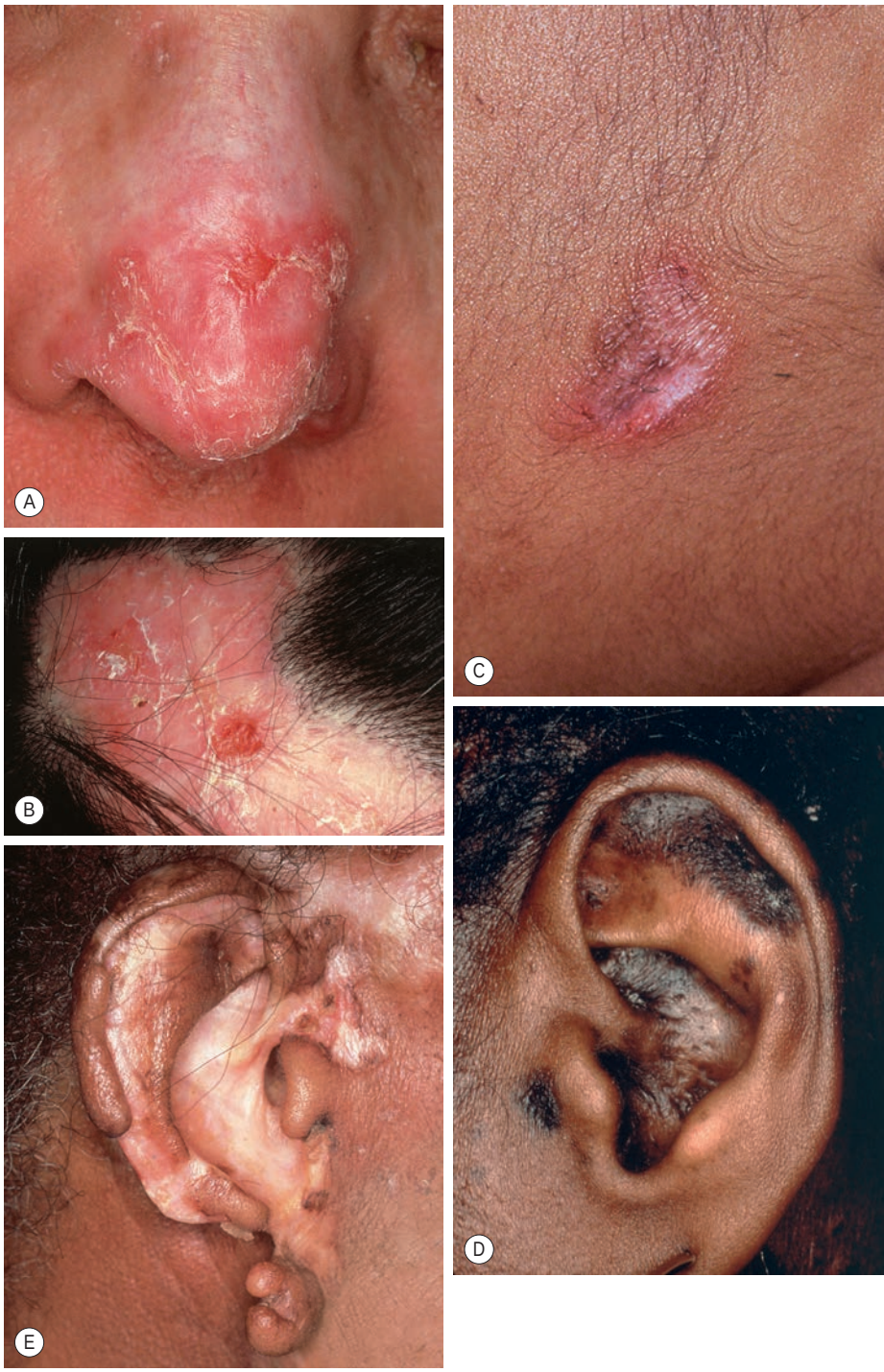


**Fig. 33.3 Various presentations of discoid lesions of lupus erythematosus (DLE).** Lesions, which favor the head and neck region may show erythema, scaling, atrophy, and dyspigmentation in addition to scarring (and alopecia) **(A–D).** The scarring process may be destructive **(E)**. *Continued*







**Fig. 33.3** *Continued* **Various presentations of discoid lesions of lupus erythematosus (DLE).** Less common sites include the palms and soles, where lesions can be keratotic or ulcerative **(F, G),** as seen in lichen planus. The latter patient had systemic lupus erythematosus and responded well to isotretinoin. **H** Occasionally, hypertrophic lesions develop within significant hyperkeratosis. **I** Discoid lupus lesions with dyspigmentation and scarring alopecia. Hypopigmentation often develops centrally with areas of hyperpigmentation at the periphery. Note the plugging of follicular openings at 12 o'clock. *A, B, D–G, Courtesy, YDRSC; C, I, Courtesy, Kalman Watsky, MD; H, Courtesy, Julie V. Schaffer, MD.*

**papulosquamous variant:** photo-lichenoid drug reaction (e.g. HCTZ, antimalarials), psoriasis, photo-exacerbated eczema, GVHD, lichen planus, PMLE, pemphigus foliaceus.

- Before a diagnosis of classic SCLE can be made, exclude the possibility of DI-SCLE (see Table 33.4).

### NEONATAL LUPUS ERYTHEMATOSUS (NLE)

- Occurs in infants whose mothers have anti-SSA/Ro autoantibodies that are passively transferred to the fetus.
- These infants primarily have anti-SSA/Ro antibodies (>98%), but they may also have anti-SSB/La or anti-U1RNP antibodies.

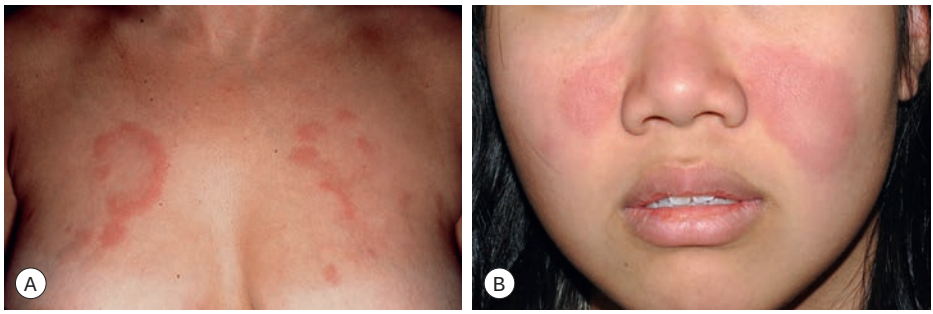


**Fig. 33.4 Lupus erythematosus tumidus.** Annular pink plaques on the chest **(A)** and pink-violet plaques on the face **(B).** None of the lesions have epidermal change. *A, Courtesy, YDRSC; B, Courtesy, Julie V. Schaffer, MD.*



**Fig. 33.5 Lupus panniculitis.** Erythematous plaque on the upper arm. The lesions may resolve with lipoatrophy. *Courtesy, YDRSC.*



**Fig. 33.6 Chilblain lupus.** Violaceous plaques, some with scale, on toes. If there is a family history of this disorder, the possibility of mutations in *TREX1*, which encodes a DNA exonuclease, or *SAMHD1*, which encodes a host restriction nuclease that plays a role in the innate immune response, can be considered. *Courtesy, YDRSC.*

- Approximately 1–5% of mothers with anti-SSA/Ro antibodies will have infants with NLE, with risk increasing to 10–25% with subsequent pregnancies.
- Cutaneous lesions are similar to adult SCLE but favor the face and periorbital areas and may be atrophic (Fig. 33.8).
- Photosensitivity is common, but sun exposure is not necessary for lesion formation.
- New lesions typically cease to develop by 6–9 months of age, i.e. once the antibodies are cleared; however, there may be residual changes such as dyspigmentation and telangiectasias.
- The most common internal manifestations are: (1) congenital heart block (± associated cardiomyopathy); (2) hepatobiliary disease; (3) thrombocytopenia > neutropenia or anemia; (4) macrocephaly or skeletal dysplasia.
- Heart block, if it is going to occur, is almost always present at birth and a pacemaker is often required.
- If skin signs of NLE are present, an evaluation, including physical examination, ECG, echocardiogram, CBC, and LFTs is indicated; the latter laboratory tests should be repeated periodically over the first 6 months of life.

## Acute Cutaneous Lupus Erythematosus (ACLE)

- The CLE variant most closely associated with SLE and if diagnosed the patient should be evaluated for internal disease.
- Three clinical presentations are recognized:
  - *Facial (malar)*: the classic "butterfly" eruption, presenting with symmetric erythematous patches or more infiltrated plaques over the nasal bridge and cheeks; spares nasolabial folds (Fig. 33.9A–C)
  - *Photodistributed*: exanthematous to urticarial eruption involving primarily UV-exposed skin, e.g. upper chest, extensor arms (Fig. 33.9D), dorsal hands (with sparing of the knuckles)
  - *Widespread*: extends beyond photodistributed sites

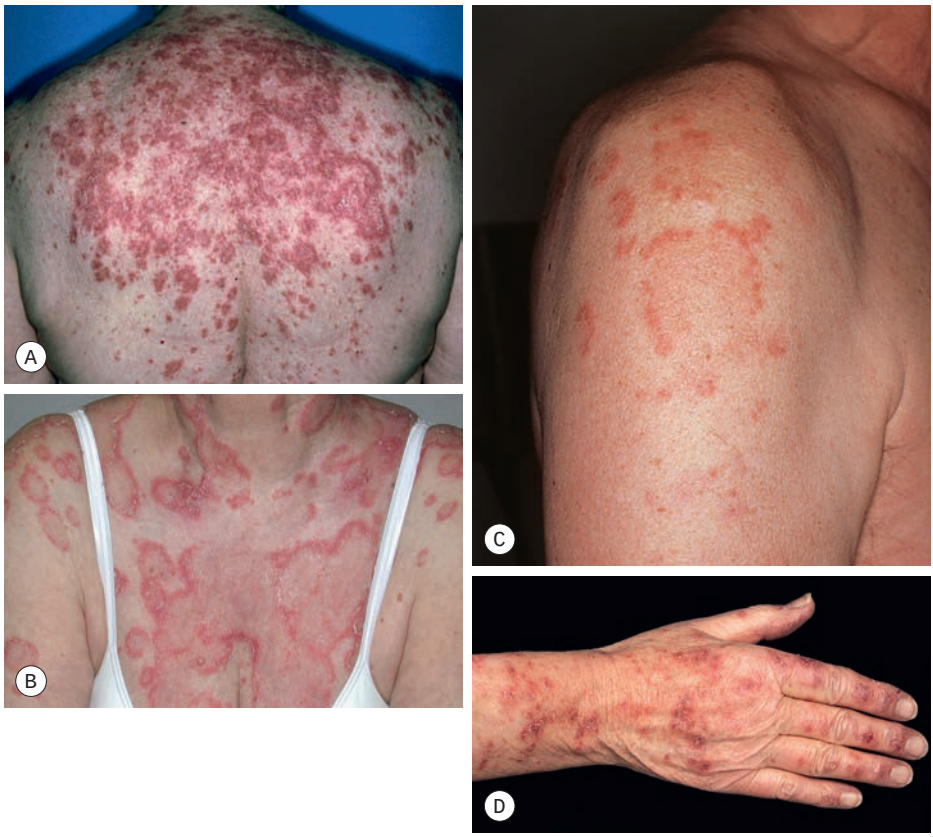


**Fig. 33.7 Subacute cutaneous lupus erythematosus (SCLE).** **A** Numerous erythematous annular plaques on the back, some of which have associated white scale. **B** Lesions are most commonly seen on the upper trunk and sun-exposed aspects of the upper extremities. The margins of the annular lesions may have scale-crust (**B**) or be composed of multiple papules (**C**). **D** Note the peripheral scale and relative sparing of the proximal interphalangeal joints. *A, Courtesy, Kathryn Schwarzenberger, MD; B, Courtesy, Lela Lee, MD and Victoria Werth, MD; C, Courtesy, YDRSC; D, Courtesy, Lorenzo Cerroni, MD.*



**Fig. 33.8 Neonatal lupus erythematosus (NLE).** Annular erythematous plaques on the forehead and scalp. Note the resemblance to the annular form of subacute cutaneous lupus erythematosus. *Courtesy, Julie V. Schaffer, MD.*

- A particular patient's ACLE clinical presentation will often repeat itself with subsequent flares, representing a "signature" pattern.
- Lesions typically respond to systemic CS and resolve without scarring, may leave residual dyspigmentation.
- **DDx: Facial:** seborrheic dermatitis, rosacea, sunburn, perioral dermatitis, tinea faciei, cellulitis/erysipelas, contact dermatitis; **Photodistributed**: drug-induced photosensitivity, dermatomyositis; **Widespread**: exanthem (viral or drug-induced).

## Other

### BULLOUS ERUPTION OF SLE

- Clinically presents as blisters (ranging from tiny vesicles to large tense bullae) on an erythematous base, typically involving the




**Fig. 33.9 Acute cutaneous lupus erythematosus (ACLE).** The facial erythema, often referred to as a "butterfly rash," may be variable **(A),** edematous **(B),** or have associated scale **(C).** The presence of small erosions can aid in the clinical differential diagnosis. This patient **(D)** had ACLE lesions on the arms as well as the face. *A, Courtesy, Kalman Watsky, MD; B–D, Courtesy, Lela Lee, MD.*

face, neck, upper trunk, proximal extremities, and mucosal surfaces; seen in patients with underlying SLE (Fig. 33.10).

- Autoantibodies against type VII collagen are present.
- **DDx: Clinical:** autoimmune blistering diseases, contact dermatitis, acute syndrome of apoptotic pan-epidermolysis (ASAP); **Histopathological**: dermatitis herpetiformis.

### ACUTE SYNDROME OF APOPTOTIC PAN-EPIDERMOLYSIS (ASAP)/ROWELL SYNDROME

- The term *ASAP* embraces various entities in which there is acute and widespread epidermal cleavage resulting from hyperacute apoptotic injury of the epidermis from various causes (e.g. drug-induced toxic epidermal necrolysis [TEN], TEN-like GVHD, and TEN-like ACLE).



**Fig. 33.10 Bullous eruption of systemic lupus erythematosus.** Vesicles and bullae due to autoantibodies against type VII collagen can develop in patients with systemic disease. *Courtesy, YDRSC.*

- Rowell syndrome and TEN-like ACLE are thought to occur along a spectrum of ASAP, with the former representing a less severe erythema multiforme major-like presentation in the setting of lupus and the latter a potentially



**Fig. 33.11 Acute syndrome of apoptotic pan-epidermolysis (ASAP).** One form of ASAP is a potentially life-threatening TEN-like presentation in the setting of ACLE. *Courtesy, YDRSC.*

life-threatening TEN-like presentation in the setting of ACLE (Fig. 33.11).

- This spectrum of cutaneous findings may occur *de novo* or in the setting of rebound ACLE or SCLE; significant internal organ involvement (e.g. kidney and CNS) is common.

## Cutaneous Lupus Erythematosus: Nonspecific Lesions

- A variety of cutaneous lesions not entirely specific to LE may be seen, signaling not only internal organ involvement (SLE) but also increased systemic disease activity (see Table 33.1).

### VASCULAR LESIONS AND THE ANTIPHOSPHOLIPID SYNDROME (APS)

- Vascular lesions and APS are common in patients with LE, especially those with SLE (see Table 33.1).
- Approximately one-third of APS cases occur in the setting of lupus (see Ch. 18); compared to primary APS, these patients are more likely to have arthritis, livedo reticularis (LR), and cytopenias.
- Patients with LE and APS may benefit from antimalarial therapy.

## Systemic Lupus Erythematosus (SLE)

- The organ systems most commonly involved are the joints, skin, hematologic, lungs, kidneys, and CNS, which in large part are reflected in the ACR criteria for SLE diagnosis (see Table 33.2); however, this list is not exhaustive and clinical judgment is required.
- In individual patients it is often only one or a few organs that are significantly affected.
- ACLE is the specific CLE variant most closely associated with SLE, but patients with any type of CLE may develop internal involvement (SLE).
- Indicators of an increased risk for SLE in patients presenting with CLE include fever, weight loss, fatigue, myalgia, lymphadenopathy, and *nonspecific* skin findings (see Table 33.1).
- The basic evaluation for SLE is highlighted in Table 33.3, and it is important to exclude drug-induced SLE (see Table 33.4).
- A negative ANA is helpful because it is highly unlikely that a patient with a negative ANA has SLE.
- A positive ANA is less helpful, as it may occur in normal individuals (usually at low titers) and in patients with CLE.
- Specific antibodies to SLE include dsDNA and Sm.

For further information see Ch. 41 from *Dermatology, Fourth Edition*.

**For additional online figures and tables visit www.expertconsult.com**

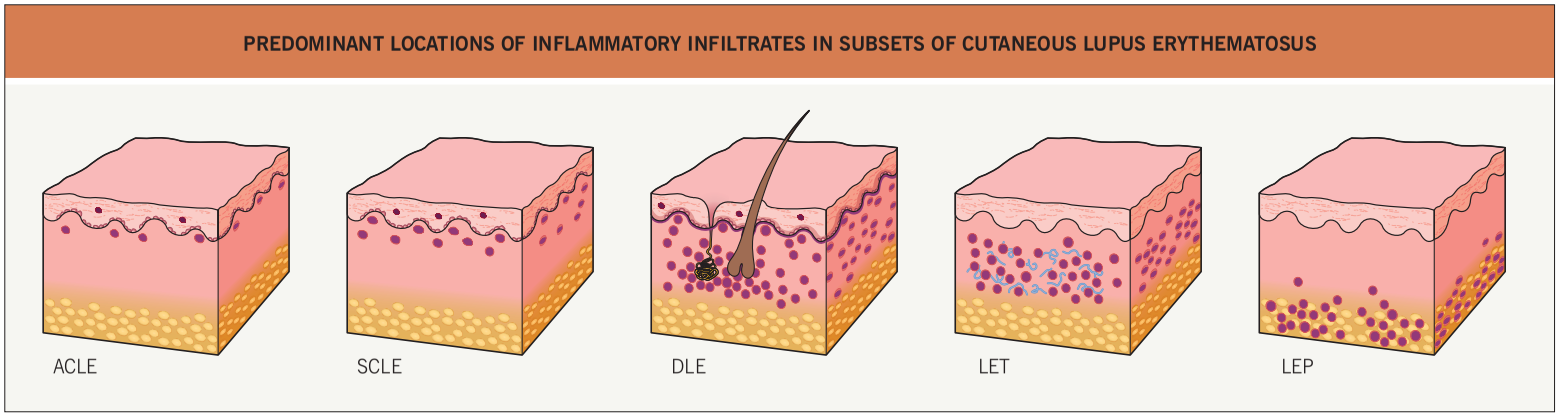


**eFig. 33.1 Predominant locations of inflammatory infiltrates in subsets of cutaneous lupus erythematosus.** The types of cutaneous lupus erythematosus are: acute cutaneous lupus erythematosus (ACLE), subacute cutaneous lupus erythematosus (SCLE), discoid lupus erythematosus (DLE), lupus erythematosus tumidus (LET) and lupus panniculitis (LEP); the latter three are forms of chronic cutaneous lupus erythematosus. The primary locations of the infiltrates are as follows: superficial dermis, ACLE and SCLE; superficial plus deep dermis and periadnexal, DLE; superficial and deep dermis, LET; and subcutaneous fat, LEP. The final diagnosis requires clinicopathologic correlation.

ALGrawany

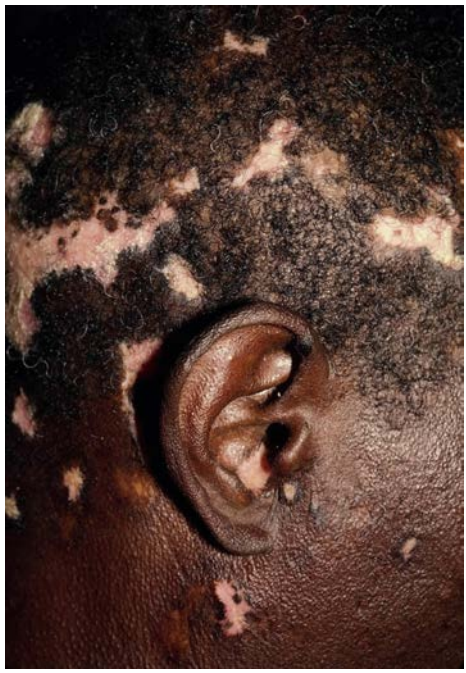

**eFig. 33.2 Discoid lesions of lupus erythematosus.** Discoid lupus lesions with vitiligo-like depigmentation. *Courtesy, Joyce Rico, MD.*




**eFig. 33.3 Subacute cutaneous lupus erythematosus (SCLE). A** Annular lesions with peripheral scale-crust located on the upper outer arm. **B** The lesions on the hands conform to the typical distribution of lupus lesions, sparing the knuckles. *A, Courtesy, Jean L. Bolognia, MD; B, Courtesy, Lela Lee, MD.*



**eFig. 33.4 Neonatal lupus erythematosus (NLE).** Annular erythematous plaques on the forehead and scalp. Note the resemblance to the annular form of subacute cutaneous lupus erythematosus. *Courtesy, Julie V. Schaffer, MD.*

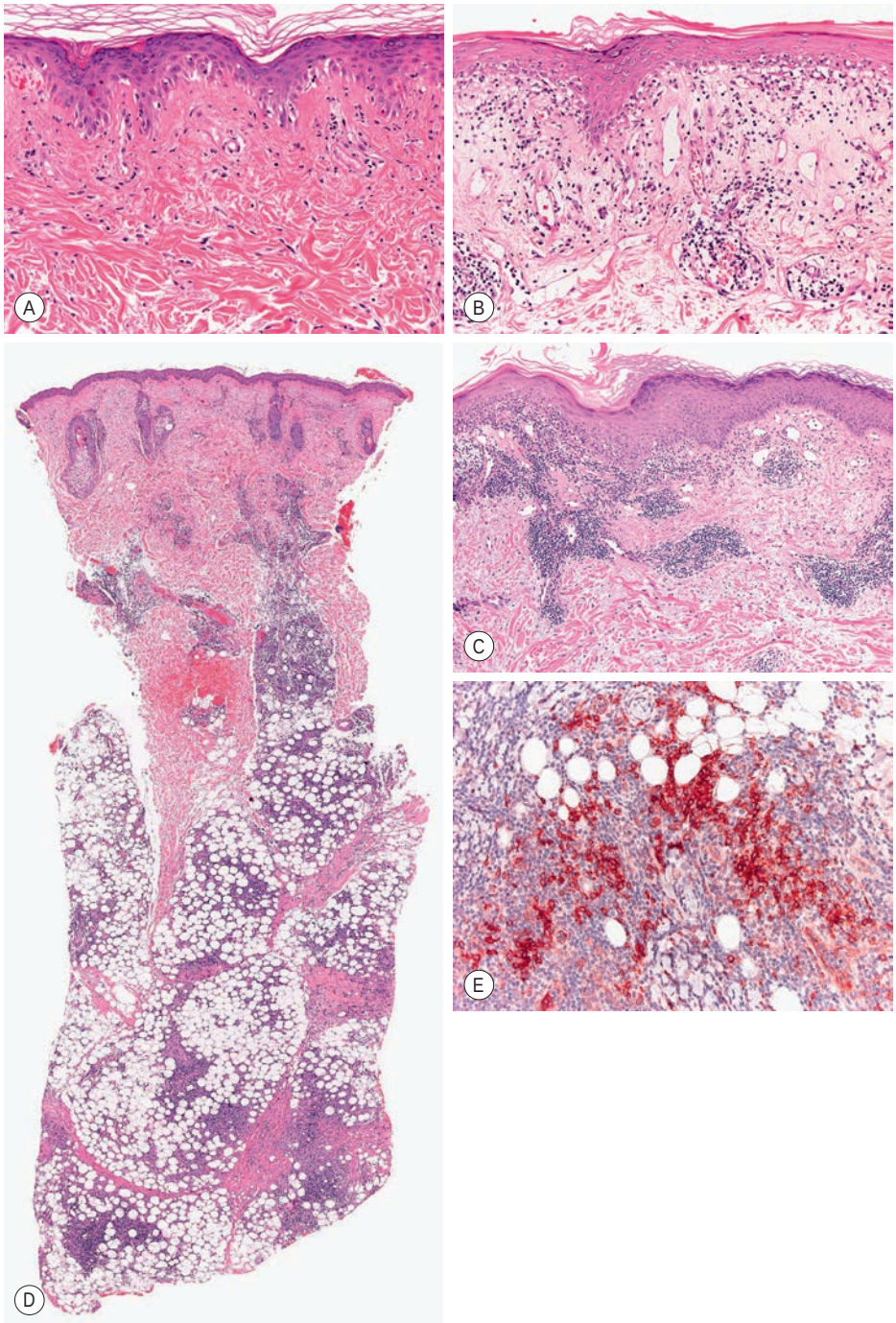


**eFig. 33.5 Histopathologic features of cutaneous lupus erythematosus.** **A** Acute cutaneous LE showing mild interface dermatitis with vacuolization of basal keratinocytes and sparse superficial lymphoid infiltrates. **B** Subacute cutaneous LE with more obvious interface dermatitis and perivascular inflammation. **C** Discoid LE showing focal interface dermatitis and dense perivascular lymphoid infiltrates throughout the dermis. **D** Lupus panniculitis with prominent inflammatory infiltrates within the lobules of the subcutaneous fat. Perivascular and periadnexal lymphocytic infiltrates are also present in the dermis. **E** The pattern and intensity of immunohistochemical staining for CD123 (plasmacytoid dendritic cells) may help to distinguish cutaneous lupus, including lupus panniculitis, from other disorders. *Courtesy, Lorenzo Cerroni, MD.*

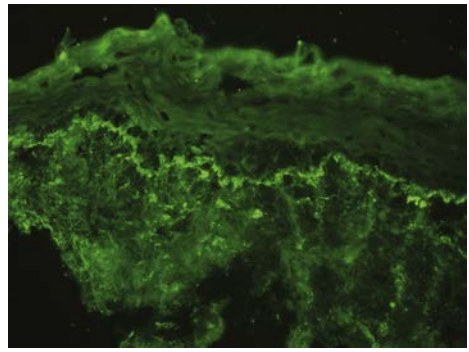

**eFig. 33.6 Direct immunofluorescence of cutaneous lupus.** Granular deposits of IgM are present at the dermal–epidermal junction within lesional skin. Antibody deposits at the dermal–epidermal junction are the most characteristic immunohistologic finding in lesions of cutaneous lupus and normal skin of patients with systemic lupus erythematosus. *Courtesy, Janet Fairley, MD.*

| SYSTEMIC EVALUATION OF AN INFANT WITH CUTANEOUS NEONATAL LUPUS ERYTHEMATOSUS |
|---|
| **Initial and serial evaluations until 6–9 months of age** |
| **History, review of systems & physical examination:** examination includes monitoring of growth and head circumference*; frequency depends upon degree of systemic involvement<br>**Laboratory studies:** electrocardiogram, echocardiogram, CBC with differential and platelet count, LFTs; if tests are initially normal and infant without signs or symptoms, then tests repeated every 2–3 months × 2–3 (otherwise more frequently)<br>**Family counseling and care coordination:** risk for NLE in subsequent pregnancies, risk for development of AI-CTD in mother and, possibly, child<br>**Preemptive treatment:** for mothers of infants with cardiac NLE, consider hydroxychloroquine during subsequent pregnancies |
| **Long-term considerations** |
| **History and physical examination:** periodically per pediatrician<br>**Laboratory studies:** if normal or return to normal and the child remains healthy, further testing is not required<br>Risk of AI-CTD as adolescent/adult |
| **Macrocephaly/hydrocephalus and chondrodysplasia punctata (stippled epiphyses) have been reported as possible manifestations of NLE.* |

**eTable 33.1 Systemic evaluation of an infant with cutaneous neonatal lupus erythematosus (NLE).** In the setting of characteristic skin lesions, the diagnosis is established via autoantibody testing in the mother (anti-SSA/Ro autoantibodies) +/– in the infant (anti-SSA/Ro, -RNP); if skin lesions are atypical, histopathologic examination may be required.

| 1997 UPDATE OF THE 1982 AMERICAN COLLEGE OF RHEUMATOLOGY REVISED CRITERIA FOR CLASSIFICATION OF SYSTEMIC LUPUS ERYTHEMATOSUS* | |
|---|---|
| **Criterion** | **Basic definition** |
| 1. Malar rash | Fixed erythema, flat or raised over malar eminences |
| 2. Discoid rash | Typical DLE lesions |
| 3. Photosensitivity | Skin rash due to an unusual reaction to sunlight |
| 4. Oral ulcers | Oral or nasal ulceration, observed by a physician |
| 5. Arthritis | Non-erosive, involving ≥2 peripheral joints |
| 6. Serositis | Pleuritis *or* pericarditis |
| 7. Renal disorder | Persistent proteinuria *or* cellular casts |
| 8. Neurologic disorder | Seizures *or* psychosis |
| 9. Hematologic disorder | Hemolytic anemia *or* leukopenia *or* thrombocytopenia |
| 10. Immunologic disorder | Anti-dsDNA *or* anti-Sm *or* antiphospholipid antibodies |
| 11. Antinuclear antibody | Abnormal ANA titer, in the absence of drug-induced SLE |

**The proposed classification is based on 11 criteria. For the purpose of identifying patients in clinical studies, a person shall be said to have SLE if any 4 or more of the 11 criteria are present, serially or simultaneously, during any interval of observation.*

**eTable 33.2 1997 Update of the 1982 American College of Rheumatology revised criteria for classification of systemic lupus erythematosus.** Although these criteria are very helpful in distinguishing SLE from other rheumatologic conditions, they are not very helpful in distinguishing other skin diseases from LE. DLE, discoid lupus erythematosus.

| THE SYSTEMIC LUPUS INTERNATIONAL COLLABORATING CLINICS (SLICC) CLASSIFICATION SYSTEM – CLINICAL AND IMMUNOLOGIC CRITERIA |
|---|
| **Clinical criteria** |
| 1. Acute cutaneous lupus, including:<br>• Lupus malar rash (do not count if malar discoid)<br>• Toxic epidermal necrolysis variant of SLE<br>• Photosensitive lupus rash in the absence of dermatomyositis<br>• Bullous lupus<br>• Maculopapular lupus rash<br>*OR*<br>Subacute cutaneous lupus (non-indurated psoriasiform and/or annular polycyclic lesions that resolve without scarring, although occasionally with postinflammatory dyspigmentation or telangiectasias) |
| 2. Chronic cutaneous lupus, including:<br>• Classic discoid rash<br>Localized (above the neck)<br>Generalized (above and below the neck)<br>• Hypertrophic (verrucous) lupus<br>• Mucosal lupus<br>• Lupus panniculitis (profundus)<br>• Lupus erythematosus tumidus<br>• Chilblain lupus<br>• Discoid lupus erythematosus/lichen planus overlap |

**eTable 33.3 The Systemic Lupus International Collaborating Clinics (SLICC) classification system – clinical and immunologic criteria.** *Continued*

| THE SYSTEMIC LUPUS INTERNATIONAL COLLABORATING CLINICS (SLICC) CLASSIFICATION SYSTEM – CLINICAL AND IMMUNOLOGIC CRITERIA |
|---|
| **Clinical criteria** |
| 3. Oral ulcers*: palate, buccal, tongue *OR* nasal ulcers* |
| 4. Non-scarring alopecia** |
| 5. Synovitis involving 2 or more joints, characterized by swelling or effusion *OR* tenderness in 2 or more joints and at least 30 minutes of morning stiffness |
| 6. Serositis<br>• Typical pleurisy for more than 1 day *OR* pleural effusions *OR* pleural rub<br>• Typical pericardial pain (pain with recumbency improved by sitting forward) for more than 1 day *OR* pericardial effusion *OR* pericardial rub *OR* pericarditis by electrocardiography# |
| 7. Renal<br>• Urine protein-to-creatinine ratio (or 24-hour urine protein) representing 500 mg protein/24 hours *OR* red blood cell casts |
| 8. Neurologic<br>• Seizures<br>• Psychosis<br>• Mononeuritis multiplex##<br>• Myelitis<br>• Peripheral or cranial neuropathy§<br>• Acute confusional state§§ |
| 9. Hemolytic anemia |
| 10. Leukopenia (<4000/mm$^3$ at least once)¶ *OR* lymphopenia (<1000/mm$^3$ at least once)¶¶ |
| 11. Thrombocytopenia (<100,000/mm$^3$ at least once)¶¶¶ |
| **Immunologic criteria** |
| 1. ANA level above laboratory reference range |
| 2. Anti-dsDNA antibody level above laboratory reference range (or >2-fold the reference range if tested by ELISA) |
| 3. Anti-Sm: presence of antibody to Sm nuclear antigen |
| 4. Antiphospholipid antibody positivity as determined by any of the following:<br>• Positive test result for lupus anticoagulant<br>• False-positive test result for rapid plasma reagin<br>• Medium- or high-titer anti-cardiolipin antibody level (IgA, IgG, or IgM)<br>• Positive test result for anti-β2-glycoprotein I (IgA, IgG, or IgM) |
| 5. Low complement: low C3, low C4, low CH50 |
| 6. Direct Coombs test in the absence of hemolytic anemia |
| **In the absence of other causes, such as vasculitis, Behçet disease, infection (herpesvirus), inflammatory bowel disease, reactive arthritis, and acidic foods.*<br>***Diffuse thinning or hair fragility with visible broken hairs in the absence of other causes such as alopecia areata, drugs, iron deficiency, and androgenic alopecia.*<br>#*In the absence of other causes, such as infection, uremia, and Dressler pericarditis.*<br>##*In the absence of other known causes such as primary vasculitis.*<br>§*In the absence of other known causes such as primary vasculitis, infection, and diabetes mellitus.*<br>§§*In the absence of other causes, including toxic/metabolic, uremia, drugs.*<br>¶*In the absence of other known causes, such as Felty syndrome, drugs, and portal hypertension.*<br>¶¶*In the absence of other known causes, such as corticosteroids, drugs, and infection.*<br>¶¶¶*In the absence of other known causes, such as drugs, portal hypertension, and thrombotic thrombocytopenic purpura.* |

**eTable 33.3** *Continued* **The Systemic Lupus International Collaborating Clinics (SLICC) classification system – clinical and immunologic criteria.** Criteria are cumulative and need not be present concurrently. Anti-dsDNA, anti-double-stranded DNA. *Adapted from M Petri, AM Orbai, GS Alarcón, et al.: Derivation and validation of the Systemic Lupus International Collaborating Clinics classification criteria for systemic lupus erythematosus. Arthritis Rheum. 2012;64:2677–2686.*

# 34 Dermatomyositis

Dermatomyositis is an autoimmune connective tissue disease (AI-CTD) that may overlap with other AI-CTDs. It may be triggered by outside factors, most commonly malignancy (e.g. breast cancer, ovarian cancer) and occasionally drugs (e.g. "statins," hydroxyurea, checkpoint inhibitors) or rarely infectious agents (e.g. picornavirus).

- Bimodal age distribution (juvenile – mean 8 years of age; adult – mean 52 years of age); female predominance.
- Often clinical and laboratory evidence of proximal inflammatory myopathy (the term polymyositis is used when the disease affects only muscles; Table 34.1); patients may report difficulty combing hair or rising from a sitting position.
- Pathogeneses of dermatomyositis and polymyositis are different (humoral immunity versus cell-mediated immunity, respectively).
- May affect the skin only (amyopathic dermatomyositis, formerly termed dermatomyositis sine myositis; see Table 34.1); Fig. 34.1 outlines an approach to the diagnosis of this form of dermatomyositis.

| REVISED CLASSIFICATION SYSTEM FOR THE IDIOPATHIC INFLAMMATORY DERMATOMYOPATHIES |
|---|
| This classification scheme recognizes, with equal weighting, the cutaneous and muscle manifestations of this group of disorders. |
| Dermatomyositis (DM)<br>Adult-onset<br>Classic DM<br>Classic DM with malignancy*<br>Classic DM as part of an overlapping connective tissue disorder**<br>Clinically amyopathic DM†<br>Amyopathic DM<br>Hypomyopathic DM<br>Juvenile-onset<br>Classic DM<br>Clinically amyopathic DM†<br>Amyopathic DM<br>Hypomyopathic DM<br>Polymyositis<br>Isolated polymyositis<br>Polymyositis as part of an overlapping connective tissue disorder<br>Inclusion body myositis |
| *In up to 25% of adults; ovarian, colon, breast, lung, gastric, pancreatic carcinomas (nasopharyngeal in Southeast Asian populations), and lymphoma; risk decreases to normal after 2–5 years.<br>**Systemic sclerosis > SLE, Sjögren syndrome, rheumatoid arthritis.<br>†Provisional = cutaneous findings without muscle weakness and with normal muscle enzymes for >6 months; confirmed = for 24 months. |

**Table 34.1 Revised classification system for the idiopathic inflammatory dermatomyopathies.** *Adapted from Sontheimer RD. Would a new name hasten the acceptance of amyopathic dermatomyositis (dermatomyositis sine myositis) as a distinctive subset within the idiopathic inflammatory dermatomyopathies spectrum of clinical illness? J Am Acad Dermatol 2002;46:626–36.*

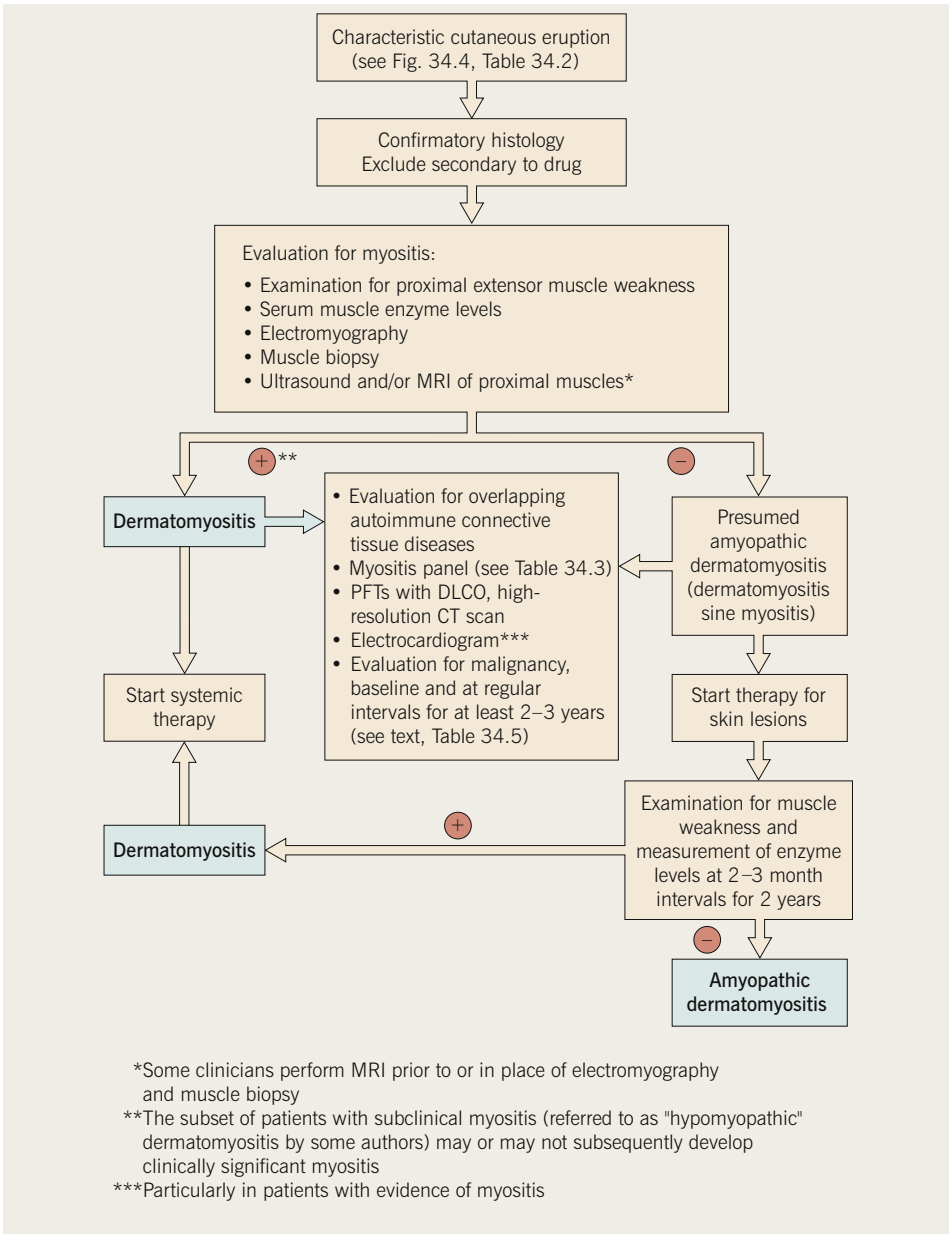


**Fig. 34.1 Approach to adult dermatomyositis.** The approach for children is similar but without the malignancy evaluation. Some authors classify patients with no evidence of myositis for 6 months after the onset of skin disease as having amyopathic dermatomyositis, but such individuals may go on to develop muscle disease. If planning administration of chronic systemic CS, a baseline DEXA bone density scan is recommended. DLCO, diffusing capacity of the lung for carbon monoxide; PFTs, pulmonary function tests.



**Fig. 34.2 Dermatomyositis – eyelid edema and heliotrope sign. A** Inflammation of the upper eyelids can be more subtle in darkly pigmented skin; note involvement of the lateral nasal root and the cheeks. **B** The characteristic pink-violet color is seen with involvement of the hairline, lower forehead, upper eyelids, and cheeks; the edema is striking and involves the nasal root as well as the eyelids. *A, Courtesy, YDRSC; B, Courtesy, Jean L. Bolognia, MD.*



**Fig. 34.3 Dermatomyositis – cuticular dystrophy and nail-fold telangiectasias.** The cuticles are "ragged" and within the proximal nail fold, dilated capillary loops alternate with vessel dropout (inset). Atrophy, telangiectasias, and hypopigmentation are present on the fingers. *Courtesy, Julie V. Schaffer, MD.*

- Characteristic cutaneous findings include a violaceous hue of the upper eyelids with periorbital edema (Fig. 34.2), Gottron papules/Gottron sign, and nail-fold telangiectasias (Fig. 34.3), as well as the cutaneous findings outlined in Table 34.2 and represented in Fig. 34.4A; these may precede systemic manifestations (Fig. 34.4B).
- Interstitial lung disease affects 15–30% of patients, and baseline pulmonary function tests that include the CO diffusion coefficient are recommended; high-resolution CT may be required to detect involvement.
- May overlap with other AI-CTDs (1 in 5 adult cases) (Table 34.1).
- Histopathologic changes: skin – interface dermatitis with mucin deposits in the dermis; muscle – lymphocytic myositis.
- Various associated autoantibodies with clinical implications (Table 34.3); antinuclear antibodies may be negative as many autoantibodies are directed against cytoplasmic antigens.
- **DDx** can be broad (Table 34.4).
- **Rx** of cutaneous disease: topical CS, topical tacrolimus, antimalarials (e.g. hydroxychloroquine), immunosuppressives (e.g. methotrexate); pruritus and scalp involvement often refractory to treatment; skin disease may be less responsive to treatment than muscle inflammation.
- **Rx** of muscle/systemic involvement (Fig. 34.5): systemic CS (e.g. prednisone 1 mg/kg/day with slow taper) ± other immunosuppressive drugs (e.g. methotrexate); for severe cases, consider IVIg or JAK inhibitors.
- In classic dermatomyositis with malignancy (Table 34.5), cutaneous findings may improve gradually over time in the setting of a treatment-responsive tumor.

For further information see Ch. 42 from *Dermatology, Fourth Edition*.

**For additional online figures visit www.expertconsult.com**

| CUTANEOUS MANIFESTATIONS OF DERMATOMYOSITIS |
|---|
| **Distribution of common cutaneous features (Figs 34.6–34.11)** |
| **Sun-exposed sites** |
| ***May resemble a photodrug eruption*** |
| Pink-violet color and/or telangiectasias (e.g. face (Fig. 34.6); V of the chest/upper back, referred to as the "shawl sign" (Fig. 34.7)) |
| Poikiloderma with hyperpigmentation, hypopigmentation, and atrophy in addition to telangiectasias |
| **Extensor surfaces of hands (knuckles), elbows, and knees** |
| ***May resemble psoriasis*** |
| Violaceous discoloration over joints (knuckles, knees, elbows), referred to as Gottron sign (Fig. 34.10) |
| Over time, flat-topped papules develop on the knuckles (Gottron papules; (Fig. 34.11), and they may become atrophic |
| **Scalp** |
| ***May resemble seborrheic dermatitis*** |
| Scaly, pink patches (Fig. 34.12) |
| Very pruritic |
| Posterior > anterior scalp |
| **Periocular** |
| ***May resemble an airborne contact dermatitis*** |
| Pink-violet discoloration of the upper eyelids (heliotrope rash) (Fig. 34.2) |
| Periocular edema that may be severe |
| These findings can be subtle and wax and wane |
| **Nail folds** |
| Dilated capillary loops alternating with dropout of capillaries (Fig. 34.3) |
| Ragged cuticles |
| **Additional cutaneous features** |
| **Calcinosis cutis** |
| More common in juvenile-onset dermatomyositis (Fig. 34.13) |
| Associated with delay in Rx or Rx-resistant disease |
| Hard, irregular nodules or plaques that can become extensive; may discharge chalky material |
| **Pruritus** |
| **Raynaud phenomenon** |
| **Less common mucocutaneous features** |
| When disease is severe, there may be erosions or ulcerations (Fig. 34.14) as well as anasarca<br>Pink-violet patches of the lateral thighs (holster sign)<br>Flagellate erythema (Fig. 34.14)<br>Panniculitis/lipoatrophy (more common in children)<br>Gingival telangiectasias |

**Table 34.2 Cutaneous manifestations of dermatomyositis.** For a schematic representation of the cutaneous features, see Fig. 34.4A.

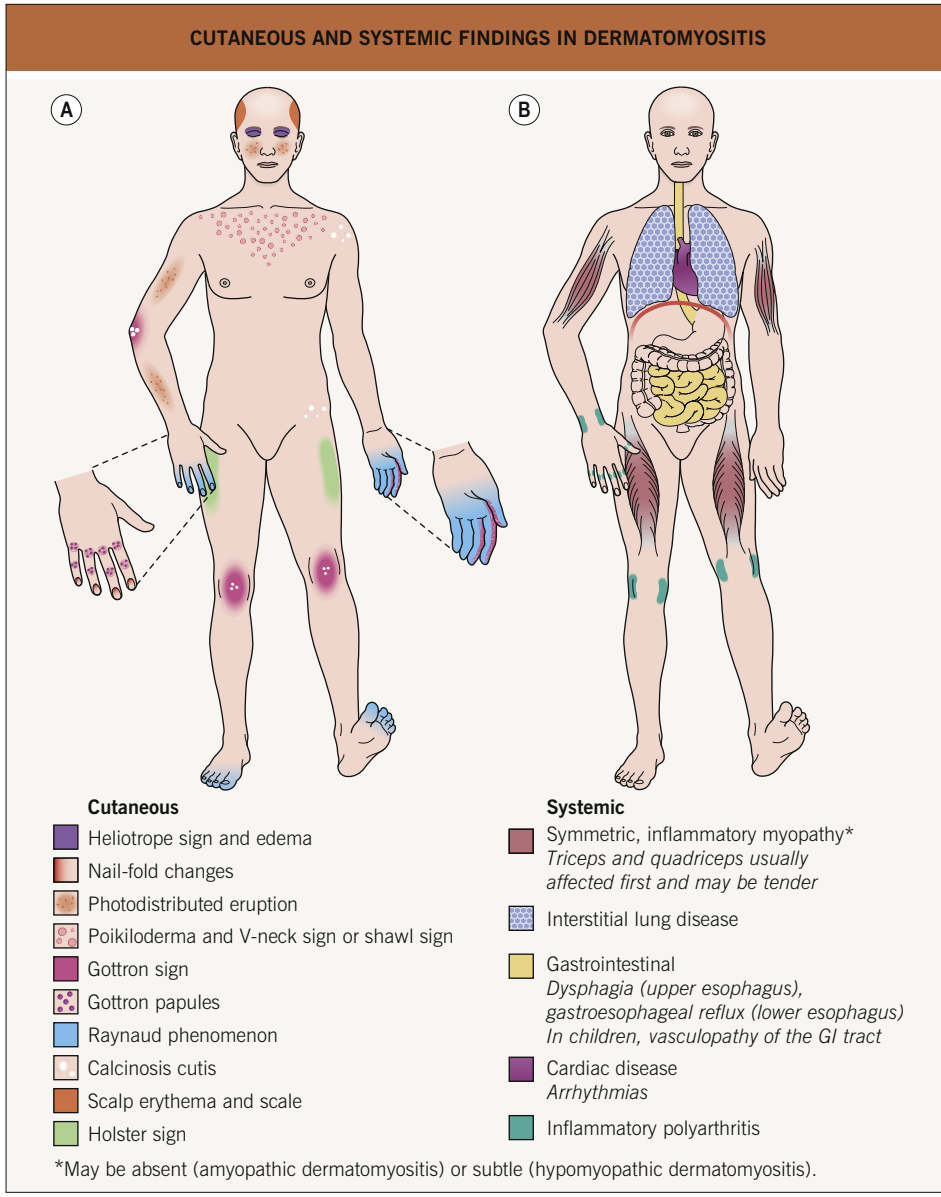


**Fig. 34.4 Cutaneous and systemic findings in dermatomyositis.** **A** Cutaneous. **B** Systemic. Nail-fold changes include dilated capillary loops, capillary dropout, cuticular hypertrophy, and ragged cuticles.

| AUTOANTIBODIES ASSOCIATED WITH DERMATOMYOSITIS (DM) AND THEIR CLINICAL RELEVANCE | |
|---|---|
| **Autoantibody** | **Clinical relevance** |
| Anti-**aminoacyl**-tRNA synthetases:<br>• Anti-Jo1 (**histidyl**)<br>• Anti-PL-7 (**threonyl**)<br>• Anti-PL-12 (**alanyl**)<br>• Anti-EJ (**glycyl**)<br>• Anti-OJ (**isoleucyl**) | • Antisynthetase syndrome (fever, polyarthritis, "mechanic's hands," Raynaud phenomenon, interstitial lung disease)<br>• Present in up to 20% of adult patients |
| Anti-Mi-2 | • Adult and juvenile DM<br>• Hallmark is cutaneous disease; milder muscle disease<br>• Good response to treatment<br>• Present in up to 10–15% of patients |
| Anti-SRP | • Acute onset necrotizing myopathy<br>• Often cardiac involvement<br>• May be refractory to treatment |
| Anti-TIF1-γ (p155) | • Cancer-associated myositis in adult DM<br>• Extensive cutaneous disease in adult and juvenile DM<br>• Palmar hyperkeratotic papules, psoriasiform lesions, red-on-white telangiectatic patches, ovoid palatal patch |
| Anti-MDA5 (CADM-140) | • Clinically amyopathic DM (CADM)<br>• Characteristic mucocutaneous findings, including tender palmar papules, ulcerations on the knuckles/elbows, oral/gum pain, diffuse alopecia<br>• Rapidly progressive interstitial lung disease (ILD) |
| Anti-NXP-2 (p140) | • Cancer-associated myositis in adult DM<br>• Adult and juvenile DM with calcinosis<br>• Peripheral edema, myalgia, dysphagia, mild skin disease |
| Anti-SAE<br>*(not yet available for commercial testing)* | • Adult DM<br>• May present with CADM first<br>• ILD uncommon |

**Table 34.3 Autoantibodies associated with dermatomyositis (DM) and their clinical relevance.** MDA5, melanoma differentiation-associated protein 5; Mi-2, a DNA helicase; NXP-2, nuclear matrix protein; SAE, small ubiquitin-like modifier-activating enzyme; SRP, signal recognition particle; TIF1, transcriptional intermediary factor 1.

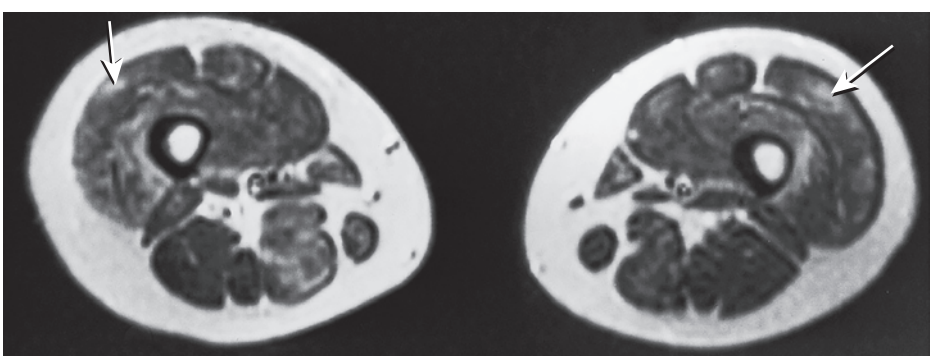

**Fig. 34.5 T2-weighted MR images of the proximal thigh in a patient with dermatomyositis.** Note the increased signal intensity, primarily in the extensor muscles (white color, arrows). The increased signal correlates with inflammation.

| DIFFERENTIAL DIAGNOSIS OF DERMATOMYOSITIS |
|---|
| **Systemic lupus erythematosus** |
| Physician might notice the nail-fold telangiectasias and photodistributed poikiloderma but miss the muscle weakness, heliotrope rash, extensor distribution, pruritus, and the violaceous hue (true lupus erythematosus might be present in the setting of an overlap syndrome) |
| **Psoriasis** |
| Involvement of elbows and knees with papulosquamous lesions can lead to misdiagnosis |
| **Airborne or allergic contact dermatitis** |
| Eyelid edema can be marked in dermatomyositis; look for additional sites of dermatitis |
| **Photodrug eruption** |
| Photodistribution |
| **Cutaneous T-cell lymphoma** |
| The poikiloderma often begins in intertriginous zones rather than on the scalp, face, and extensor surfaces |
| **Atopic dermatitis** |
| Usually in children, where the physician focuses on the pruritus and secondary lichenification |
| **Systemic sclerosis (scleroderma)** |
| The nail-fold telangiectasias are similar in appearance, but the dyspigmentation is quite different; edema of the hands is an early sign (true systemic sclerosis may be present in the setting of an overlap syndrome) |
| **Trichinosis** |
| Patients have painful muscles and periorbital edema, but not other features |
| **Photodistributed form of multicentric reticulohistiocytosis (rare)** |
| Firm papules have distinct histologic features |

**Table 34.4 Differential diagnosis of dermatomyositis.**



**Fig. 34.6 Dermatomyositis.** Misdiagnoses include psoriasis and acute cutaneous lupus erythematosus. *Courtesy, Joseph L. Jorizzo, MD.*

| SUGGESTED MALIGNANCY SCREENING TESTS FOR ADULTS WITH DERMATOMYOSITIS |
|---|
| • Urinalysis<br>• Stool occult blood testing<br>• Serum prostate-specific antigen (PSA) in men<br>• Serum CA125 (women)<br>• Mammogram and transvaginal pelvic ultrasound (women)<br>• CT of chest, abdomen, and pelvis<br>• Colonoscopy (if age-appropriate, iron deficiency anemia, occult blood in stool, or symptoms)<br>• Upper endoscopy (if colonoscopy negative in the setting of iron deficiency anemia, occult blood in stool, or symptoms)<br>• Serum protein and immunofixation electrophoresis |

**Table 34.5 Suggested malignancy screening tests for adults with dermatomyositis.** Screening should be performed at the time of diagnosis and annually for a minimum of 3 years thereafter; history and physical examination can be performed more frequently.



**Fig. 34.7 Dermatomyositis – involvement of the upper back.** The pink-violet plaques, some with associated scale, were very pruritic, as evidenced by multiple excoriations. Linear streaks of erythema are also seen. *Courtesy, Jean L. Bolognia, MD.*



**Fig. 34.8 Dermatomyositis, holster sign.** Poikiloderma of the lateral thigh. *Courtesy, Sara Perkins, MD.*









**Fig. 34.9 Gottron sign with violaceous poikiloderma over the knuckles.**




**Fig. 34.10 Dermatomyositis – Gottron sign.** Pink-violet papules (**A**) and thin pink plaques (**B**) of the elbows and knee (**C**). Some of the papules on the elbow are flat-topped (lichenoid) and others have white scale. The presence of plaques on the elbows and knees can lead to the misdiagnosis of psoriasis. *A, Courtesy, Ruth Ann Vleugels, MD; B, C, Courtesy, Julie V. Schaffer, MD.*




**Fig. 34.11 Dermatomyositis – Gottron papules.** **A** Only a few Gottron papules are present, but there is definite accentuation of the pink-violet inflammation over the metacarpophalangeal (MCP) joints and proximal and distal interphalangeal (PIP, DIP) joints as well as the proximal nail folds. Note the ragged cuticles. **B** The flat-topped (lichenoid) papules overlying the DIP, PIP, and MCP joints (knuckles) are subtle and were misdiagnosed as verrucae vulgares in this child. **C** More obvious disease in which the multiple pink-violet lichenoid papules are coalescing and there is some involvement of the interphalangeal skin. **D** Flat-topped (lichenoid) papules over the knuckles, ragged cuticles, and poikiloderma of the dorsal hand. *A, Courtesy, Kalman Watsky, MD; B, C, Courtesy, Julie V. Schaffer, MD; D, Courtesy, Sara Perkins, MD.*



**Fig. 34.12 Seborrheic-like dermatitis due to dermatomyositis.** This patient presented with severe pruritus of the scalp. In addition to the scalp involvement, she had Gottron papules and a photodistributed poikiloderma. *Courtesy, Jeffrey P. Callen, MD.*



**Fig. 34.13 Juvenile dermatomyositis – calcinosis cutis.** The nodules favor the extensor surface of the knees and result in a decrease in joint mobility.

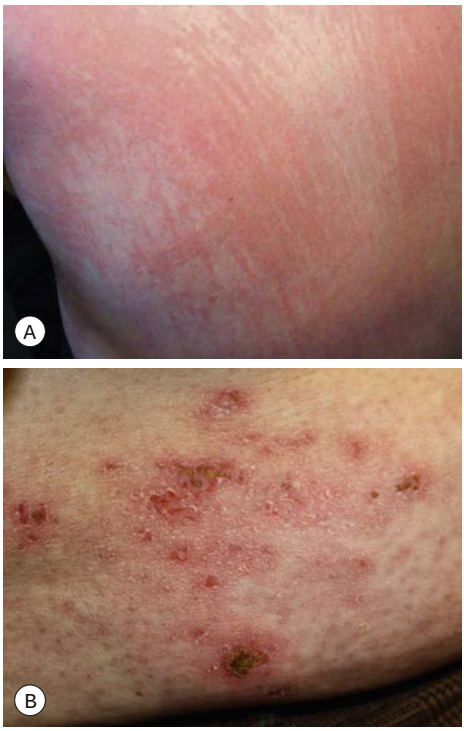


**Fig. 34.14 Dermatomyositis – less common presentations. A** Flagellate erythema of the posterior trunk. **B** Secondary changes include scale, erosions, and serous as well as hemorrhagic crusts. *A, Courtesy, Ruth Ann Vleugels, MD; B, Courtesy, YDRSC.*

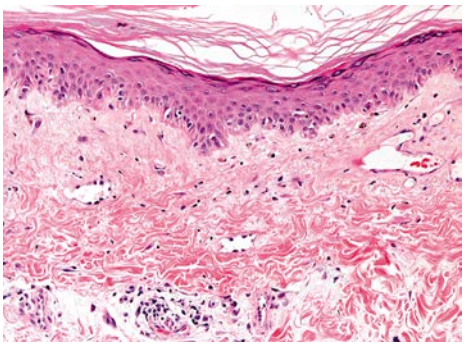

**eFig. 34.1 Dermatomyositis – histopathologic features.** The vacuolar changes within the basal layer can be subtle. In the dermis, dilated blood vessels and a sparse lymphocytic infiltrate are seen (poikilodermatous changes). *Courtesy, Lorenzo Cerroni, MD.*

# 35 Systemic Sclerosis and Sclerodermoid Disorders

- The spectrum of sclerosing skin disorders is outlined in Fig. 35.1.

## Systemic Sclerosis (SSc, Scleroderma)

- An uncommon autoimmune connective tissue disease (AI-CTD) that affects the skin, blood vessels, and various internal organs (e.g. kidney, lung, gastrointestinal tract, heart).

**THE SPECTRUM OF SCLEROSING SKIN DISORDERS**

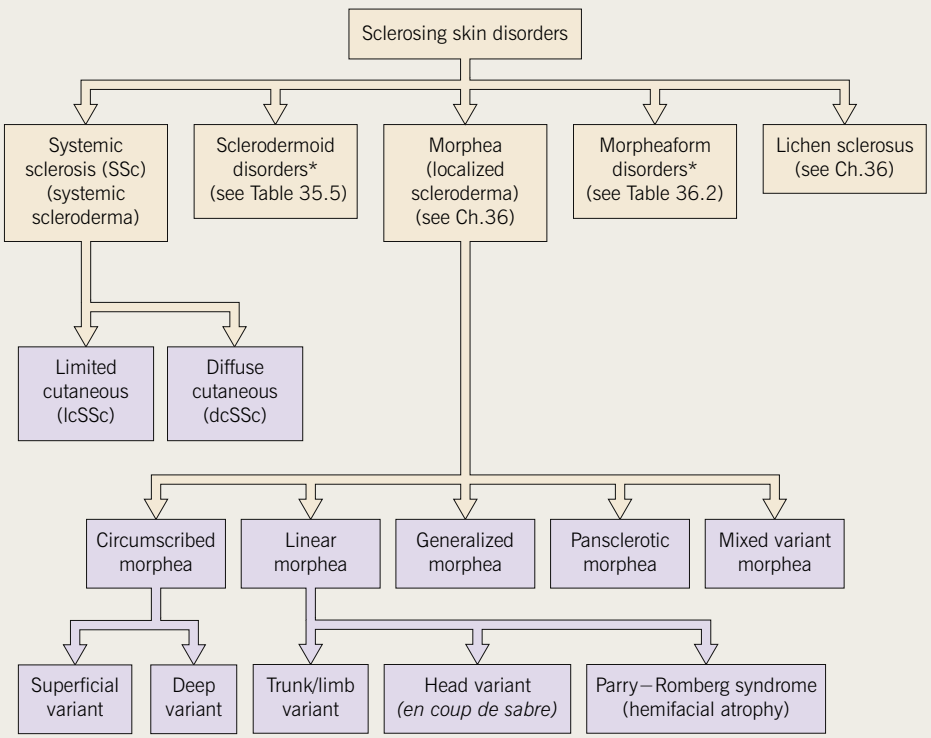


*Disorders with a clinical presentation similar to systemic sclerosis are referred to as *sclerodermoid*, while those reminiscent of morphea are referred to as *morpheaform*. As with any disease spectrum, there can be overlapping clinical features.

**Fig. 35.1 The spectrum of sclerosing skin disorders.**

| ACR/EULAR CRITERIA FOR THE CLASSIFICATION OF SYSTEMIC SCLEROSIS | | |
|---|---|---|
| **Item** | **Sub-item** | **Weight/score** |
| Skin thickening of the fingers of both hands extending proximal to the MCP joints (*sufficient criterion)* | – | 9 |
| Skin thickening of the fingers | Puffy fingers<br>- *or* - sclerodactyly | 2<br>4 |
| Fingertip lesion | Digital tip ulcers<br>- *or* - pitting scars | 2<br>3 |
| Telangiectasias | – | 2 |
| Abnormal nail-fold capillaries | – | 2 |
| Pulmonary arterial hypertension<br>-*or*- interstitial lung disease | | 2<br>2 |
| Raynaud phenomenon | – | 3 |
| SSc-related autoantibodies | Anti-centromere<br>Anti-topoisomerase I<br>Anti-RNA polymerase III | 3 |

**Table 35.1 2013 American College of Rheumatology (ACR)/European League Against Rheumatism (EULAR) criteria for the classification of systemic sclerosis (SSc).** The total score is determined by adding the maximum weight (score) in each category. Patients with a total score of ≥9 are classified as having *definite* SSc. *From Van den Hoogen F, Khanna D, Fransen J, et al. 2013 classification criteria for systemic sclerosis. Arthritis Rheum 2013;65:2737–47.*

- Etiology is unknown but pathogenesis involves vascular dysfunction, immune activation with autoantibody production, and tissue sclerosis.
- Seen more frequently in women; onset is typically in the 3rd to 4th decades of life; diffuse cutaneous SSc is more frequently seen in African-Americans.
- The criteria for the classification/diagnosis of SSc were updated in 2013 (Table 35.1).
- There are two *major* clinical subtypes of SSc, based upon the amount of skin sclerosis (Fig. 35.2): *limited cutaneous SSc (lcSSc)* and *diffuse cutaneous SSc (dcSSc)*.
- LcSSc is characterized by skin sclerosis involving the distal extremities and face; whereas in dcSSc, the distal and proximal extremities, trunk, and face are involved; internal organ involvement can be seen in both subtypes.
- LcSSc and dcSSc can also occur in conjunction with other AI-CTDs (called "overlap syndrome"), most notably polymyositis and SLE.
- Raynaud phenomenon is present in almost all SSc patients and is often the earliest presenting feature (Table 35.2; Figs 35.3–35.5).
- Mat telangiectasias (Fig. 35.6), proximal nail-fold capillary abnormalities, and cutaneous ulcerations (Fig. 35.7) are present in both lcSSc and dcSSc subtypes and are important clues to the Dx; additional common cutaneous findings are outlined in Table 35.2.
- Patients often have a characteristic facies with microstomia, retraction of the lips, perioral furrows, and a beaked nose; three types of dyspigmentation can also be seen, including diffuse hyperpigmentation and leukoderma of SSc (Fig. 35.8).
- Internal organ involvement is seen in both lcSSc and dcSSc (Table 35.3), but patients with dcSSc are at increased risk for more clinically severe extracutaneous disease and overall worse outcomes.
- Most patients (>95%) with SSc are ANA (+); antinuclear autoantibodies unique to SSc, in particular anti-centromere, anti-topoisomerase I, and anti-RNA polymerase III,

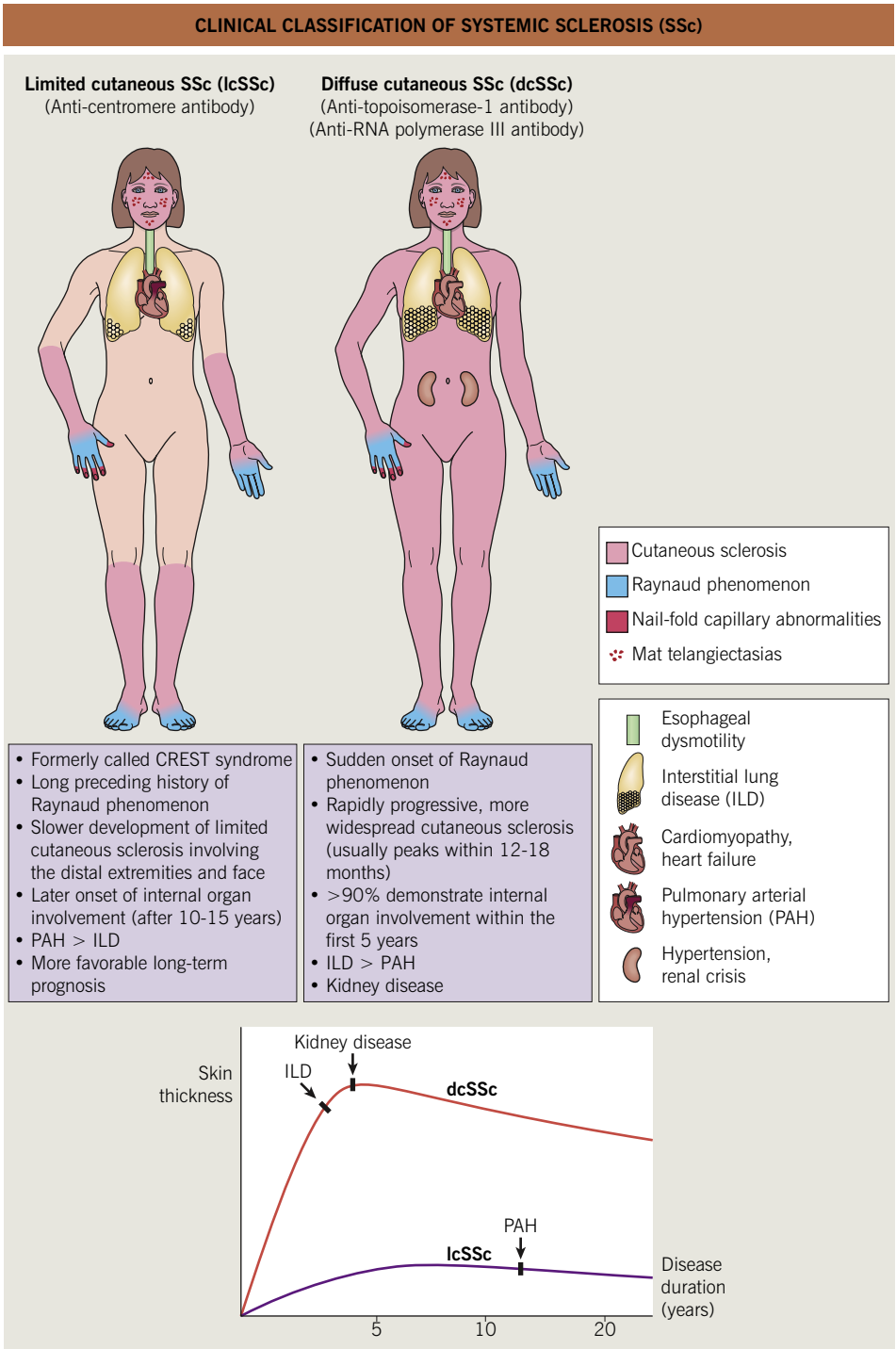


**Fig. 35.2 Clinical classification of systemic sclerosis (SSc).** In addition to the two major clinical subsets shown here, two others are recognized: *systemic sclerosis sine scleroderma (ssSSc)*, considered a subset of lcSSc, in which cutaneous sclerosis is absent, but the presence of internal organ involvement, Raynaud phenomenon, nail-fold capillary abnormalities, and positive serologies are present; and overlap syndrome, in which either lcSSc or dcSSc coexists with another AI-CTD, e.g. polymyositis or SLE. CREST, *c*alcinosis, *R*aynaud phenomenon, *e*sophageal dysmotility, *s*clerodactyly, *t*elangiectasias.

| CUTANEOUS FEATURES OF SYSTEMIC SCLEROSIS – POSSIBLE TREATMENTS | |
|---|---|
| **Cutaneous feature** | **Possible treatment options** |
| **Cutaneous sclerosis** (Figs 35.3 and 35.5) | • Topical therapies<br>• UV phototherapy<br>• D-penicillamine*<br>• Minocycline**<br>• Methotrexate (if no ILD)†<br>• Mycophenolate mofetil (when ILD) |
| **Raynaud phenomenon** (Fig. 35.9) (Tables 35.6 and 35.7) | **First-line**<br>• Cold avoidance<br>• Hand and feet warming packets<br>• Discontinue all tobacco products<br>**Second-line**<br>• Calcium channel blockers (e.g. nifedipine SR 30 mg daily–BID, amlodipine 2.5–10 mg daily)<br>**Third-line** (especially when accompanied by ulceration)<br>• Phosphodiesterase type 5 inhibitors (e.g. sildenafil, tadalafil)<br>• α-Adrenergic blockers (e.g. prazosin)<br>• Angiotensin II receptor blockers (e.g. losartan)<br>• Endothelin receptor antagonists (e.g. bosentan)<br>**Fourth-line**<br>• Serotonin reuptake inhibitors (e.g. fluoxetine) |
| **Cutaneous ulcers** (Figs 35.5B and 35.7) | • Avoid excessive debridement<br>• Moist, nonadherent dressings<br>• Therapies listed above for Raynaud phenomenon<br>• Low-dose aspirin or clopidogrel<br>• IV prostanoid (e.g. epoprostenol) |
| **Calcinosis cutis** (Fig. 35.4) (see Ch. 42) | • Low-dose warfarin<br>• Calcium channel blockers<br>• Sodium thiosulfate |
| **Mat telangiectasias** (Fig. 35.6) | • Lasers appropriate for vascular lesions |

**Nowadays used infrequently.*
***Minimal effect.*
*†Methotrexate-induced pneumonitis may complicate SSc-ILD picture.*

**Table 35.2 Cutaneous features of systemic sclerosis – possible treatments.** ILD, interstitial lung disease; SR, slow release.



**Fig. 35.3 Pitted scars of the digital pulp in a patient with systemic sclerosis.** *Courtesy, Kalman Watsky, MD.*



**Fig. 35.4 Calcinosis cutis of the finger in a patient with systemic sclerosis.** *Courtesy, YDRSC.*




**Fig. 35.5 Early versus late stages of systemic sclerosis (SSc) involving the hands. A** Early edematous phase of SSc (note the demonstration of pitting edema on two of the digits). **B** Late stage of dcSSc with fixed flexion contractures, sclerodactyly, and digital ulceration overlying the third proximal interphalangeal joint. *A, Courtesy, Jean L. Bolognia, MD; B, Courtesy, M. Kari Connolly, MD.*

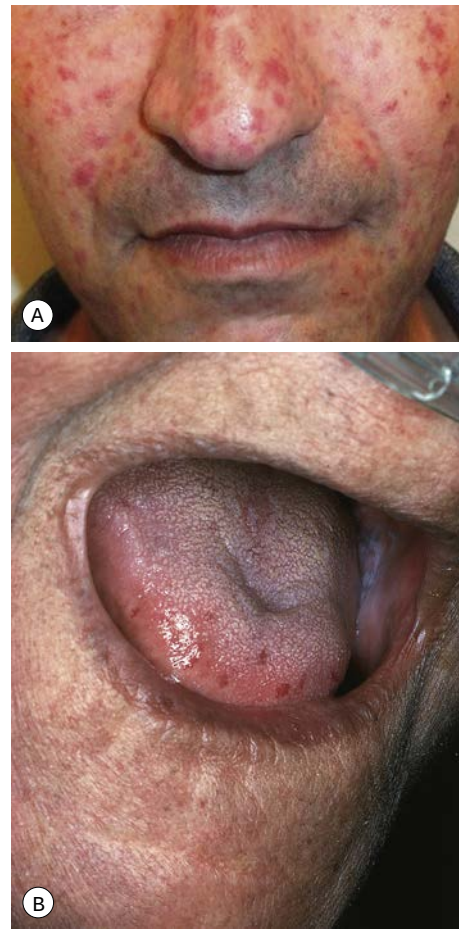


**Fig. 35.6 Mat (squared-off) telangiectasias in systemic sclerosis (SSc).** The first patient **(A)** had limited cutaneous systemic sclerosis (lcSSc) while the second patient **(B)** presented with diffuse hyperpigmentation and interstitial lung disease. *A, Courtesy, M. Kari Connolly, MD; B, Courtesy, Jean L. Bolognia, MD.*

are useful for diagnostic and prognostic purposes (Table 35.4).

- There are three phases of cutaneous disease:
  - **(1) Early edematous phase**, featuring puffy hands and pitting edema of the digits (see Fig. 35.5A)
  - **(2) Indurated phase**, characterized by hardening of the skin with taut and shiny appearance (see Fig. 35.5B)
  - **(3) Atrophic phase**, with potential/gradual softening of the skin
- The degree of skin sclerosis does not predict the degree of internal organ involvement, and survival is dependent on the type and degree of internal organ involvement.
- Pulmonary disease (interstitial lung disease [ILD] > pulmonary arterial hypertension [PAH]) is the most common cause of mortality.
- All SSc patients should be screened and periodically monitored for internal organ involvement, especially lung and renal disease (Table 35.3).




**Fig. 35.7 Cutaneous ulcerations in systemic sclerosis (SSc).** Ulcers favor the digits (**A**) and sites of trauma, such as the elbow (**B**). Note the calcinosis cutis at the base of the forefinger and the pterygium inversum unguis of the third finger. *A, Courtesy, Kalman Watsky, MD; B, Courtesy, Joyce Rico, MD.*



**Fig 35.8 The "salt and pepper" sign.** Leukoderma with retention of perifollicular pigmentation in a patient with systemic sclerosis. *Courtesy, Joyce Rico, MD.*



**Fig. 35.9 Raynaud phenomenon in a patient with early systemic sclerosis (SSc).** There is obvious blanching of two fingers, as well as violaceous hue of the forefinger. *Courtesy, Jeffrey P. Callen, MD.*

- **DDx** includes other sclerodermoid conditions (Table 35.5) and other AI-CTDs (e.g. mixed connective tissue disease; see Ch. 37).
- Recommendations for the initial evaluation of all patients with suspected SSc are presented in Table 35.3.
- **Rx** options for various cutaneous and extracutaneous features of SSc are outlined in Tables 35.2 and 35.3.

## Raynaud Phenomenon

- Characterized by episodic vasospasm of the digital arteries, resulting in white, blue, and red discoloration of the fingers and toes secondary to cold stimuli (Fig. 35.9).
- Occurs in two settings: *primary* Raynaud phenomenon (Raynaud disease) and *secondary* Raynaud phenomenon (Table 35.6).
- *Primary* Raynaud phenomenon is common, affecting 3–5% of the population and typically develops in adolescent girls and young women (median age at onset, ~14 years) and is not associated with any underlying medical issues.
- *Secondary* Raynaud phenomenon is uncommon and is associated with an underlying medical problem, including SSc (Table 35.7).
- An approach to differentiating primary from secondary Raynaud phenomenon is presented in Fig. 35.10.
- **Rx:** Table 35.2.

| INTERNAL ORGAN INVOLVEMENT IN SYSTEMIC SCLEROSIS – SCREENING AND TREATMENT OPTIONS | | |
|---|---|---|
| **Internal organ** | **Screening tools*** | **Treatment options** |
| **Lung*** | | |
| • Interstitial lung disease (ILD) | • **PFTs (DLCO, spirometry, and lung volumes)**<br>• **High-resolution CT**<br>• Bronchoalveolar lavage and lung biopsy | • Immunosuppression (e.g. mycophenolate mofetil, cyclophosphamide, rituximab)<br>• Nintedanib**, tocilizumab**<br>• Lung transplantation |
| • Pulmonary arterial hypertension (PAH) | • **Transthoracic echocardiography**<br>• **Serum *N*-Tpro-BNP level**<br>• Right heart catheterization | • Oxygen<br>• Anticoagulation<br>• Endothelin receptor antagonists (e.g. bosentan)<br>• Phosphodiesterase inhibitors (e.g. tadalafil)<br>• Prostaglandins (e.g. epoprostenol)<br>• Prostacyclin analogues (e.g. treprostinil)<br>• Prostacyclin receptor agonists (e.g. selexipag)<br>• Soluble guanylate cyclase stimulators (e.g. riociguat)<br>• Lung transplantation |
| **Kidney** | | |
| • Renal crisis<br>• Hypertension | • **Close monitoring of blood pressure**<br>• **BUN/Cr**<br>• **Urinalysis** | • ACE inhibitors instituted early for treatment but not helpful for prevention |
| **Heart** | | |
| • Fibrosis/restrictive cardiomyopathy<br>• Heart failure secondary to PAH | • Echocardiography | • ACE inhibitors |
| **Gastrointestinal tract** | | |
| • Esophageal dysmotility<br>• Small bowel involvement | • Barium swallow with small bowel follow through<br>• Manometry<br>• Endoscopy | • Proton pump inhibitors<br>• Promotility agents (e.g. ondansetron) |

**Patients are typically asymptomatic in the early stages of ILD and PAH, which is when the diagnosis should be made and treatment instituted; cough, dyspnea on exertion, and shortness of breath are typical later-onset symptoms.*
***FDA-approved for SSc-ILD.*

**Table 35.3 Internal organ involvement in systemic sclerosis – screening and treatment options.** Items in bold signify those screening tests that are recommended at baseline in all newly diagnosed patients. In addition, autologous hematopoietic stem cell transplantation should be considered for patients with rapidly progressive SSc who are at risk of organ failure. ACE, angiotensin converting enzyme; DLCO, diffusing capacity of the lung for carbon monoxide; *N*-Tpro-BNP, *N*-terminal pro b-type natriuretic peptide; PFTs, pulmonary function tests.

| SYSTEMIC SCLEROSIS (SSc) AUTOANTIBODY PROFILE AND THE MORE FREQUENTLY ASSOCIATED CLINICAL PRESENTATIONS | |
|---|---|
| **SSc autoantibody** | **Clinical features** |
| **Limited skin sclerosis** | |
| Anti-centromere* | • Increased risk isolated PAH > ILD<br>• Esophageal involvement<br>• Small intestinal involvement with malabsorption |
| Anti-Th/To | • Frequent in patients with ssSSc<br>• More severe internal organ involvement (ILD, PAH) |
| Anti-U11/U12 RNP** | • Greatest risk for developing ILD, which is often severe and rapidly progressive |
| **Diffuse skin sclerosis** | |
| Anti-topoisomerase-I* (*formerly Scl-70*) | • Increased risk ILD >PAH<br>• Poor prognosis |
| Anti-RNA polymerase III* | • Most severe diffuse skin sclerosis; rapidly progressive<br>• Greatest risk for renal crisis<br>• Gastric antral vascular ectasia (GAVE)<br>• Increased risk of internal malignancy (especially breast cancer) |
| Anti-U3 RNP | • More frequent in African-Americans<br>• Non-inflammatory skeletal myopathy<br>• Early, often severe internal organ involvement (e.g. PAH, cardiomyopathy, small bowel involvement with malabsorption) |
| **Overlap syndromes** | |
| Anti-PM/Scl | • Polymyositis – SSc overlap<br>• Acute-onset inflammatory myositis<br>• Less serious internal organ involvement<br>• Usually better prognosis because responsive to oral CS |
| Anti-U1RNP† | • MCTD<br>• Increased risk ILD and PAH<br>• Usually better prognosis because responsive to oral CS |
| Anti-Ku | • Myositis and arthritis<br>• Increased risk of ILD |
| Anti-RuvBL1/2** | • Combination of diffuse skin sclerosis + myositis |

**The most frequently identified autoantibodies in SSc and currently used as criteria for classification/diagnosis (see Table 35.1).*
***Testing is currently not commercially available.*
*†The U1RNP antibody is specific for MCTD, which is often considered a distinct clinical entity (see Ch. 37).*

**Table 35.4 Systemic sclerosis (SSc) autoantibody profile and the more frequently associated clinical presentations.** Over 95% of SSc patients will have a (+) ANA. The value of a (+) ANA lies in the subsequent identification of the patient's SSc-specific autoantibody. More than 90% will have one of ten SSc autoantibodies; rarely (~2–3%) will a patient have more than one SSc autoantibody. The ten autoantibodies are mostly mutually exclusive and tend not to change with time. These autoantibodies are rarely found in patients with other AI-CTDs, unless features of SSc are also present. ILD, interstitial lung disease or pulmonary fibrosis; MCTD, mixed connective tissue disease; PAH, pulmonary arterial hypertension; ssSSc, systemic sclerosis sine scleroderma.

| DIFFERENTIAL DIAGNOSIS OF SCLERODERMOID CONDITIONS | |
|---|---|
| **Mucinoses** | **Neurologic** |
| • Scleredema<br>• Scleromyxedema | • Complex regional pain syndrome*<br>• Spinal cord injury |
| **Immunologic** | **Toxin-mediated** |
| • Chronic scleroderma-like GVHD*<br>• Eosinophilic fasciitis<br>• Generalized morphea*<br>• Fibroblastic rheumatism<br>• Overlap syndromes | • Nephrogenic systemic fibrosis*<br>• Eosinophilia-myalgia syndrome (historic)<br>• Toxic oil syndrome* (historic)<br>• Silicosis |
| **Paraneoplastic** | **Drug- or chemical-induced** |
| • POEMS syndrome<br>• Amyloidosis (primary systemic)**<br>• Carcinoid syndrome<br>• Paraneoplastic scleroderma-like syndrome | • Bleomycin*<br>• Taxanes<br>• Vinyl chloride, chlorinated hydrocarbons* |
| **Neoplastic** | **Venous insufficiency** |
| • Carcinoma *en cuirasse** | • Lipodermatosclerosis* |
| **Metabolic** | **Other** |
| • Diabetic cheiroarthropathy<br>• Porphyria cutanea tarda*,† | • Restrictive dermopathy§<br>• Stiff skin syndrome* |

**Can overlap with morpheaform disorders, which are listed in Table 36.2.*
***Primary cutaneous amyloidosis can also occur in patients with systemic sclerosis and generalized morphea.*
*†May also be observed in patients with congenital erythropoietic porphyria and hepatoerythropoietic porphyria.*
*§Sclerodermoid changes are typically present at birth.*

**Table 35.5 Differential diagnosis of sclerodermoid conditions.** POEMS, polyneuropathy, organomegaly, endocrinopathy, monoclonal gammopathy, and skin changes.

| CLINICAL AND LABORATORY FEATURES OF PRIMARY AND SECONDARY RAYNAUD PHENOMENON | | |
|---|---|---|
| **Feature** | **Primary Raynaud** | **Secondary Raynaud** |
| Sex | F:M 20:1 | F:M 4:1 |
| Age at onset | Puberty | >25 years |
| Frequency of attacks | Usually <5 per day | 5–10+ per day |
| Precipitants | Cold, emotional stress | Cold |
| Ischemic injury | Absent | Present |
| Abnormal capillaroscopy | Absent | >95% |
| Other vasomotor phenomena | Yes | Yes |
| Antinuclear antibodies | Absent/low titer | 90–95% |
| Anticentromere antibody | Absent | 30–40% |
| Anti-topoisomerase I (Scl-70) antibody | Absent | 20–30% |
| Anti-RNA polymerase III antibody | Absent | 10–20% |
| *In vivo* platelet activation | Absent | >75% |

**Table 35.6 Clinical and laboratory features of primary and secondary Raynaud phenomenon.** *Adapted from Hochberg MC, Silman AJ, Smolen JS, et al. Rheumatology, 3rd edn. Edinburgh: Mosby, 2003. © Elsevier 2003.*

| DIFFERENTIAL DIAGNOSIS OF RAYNAUD PHENOMENON |
|---|
| **Structural vasculopathies** |
| *Large and medium-sized arteries* |
| • Thoracic outlet syndrome<br>• Brachiocephalic trunk disease (atherosclerosis, Takayasu arteritis)<br>• Buerger disease (thromboangiitis obliterans)*<br>• Crutch pressure |
| *Small arteries and arterioles* |
| • Systemic sclerosis<br>• Systemic lupus erythematosus<br>• Dermatomyositis<br>• Overlap syndromes<br>• Cold injury<br>• Vibration disease (hand–arm vibration syndrome, hypothenar hammer syndrome)<br>• Chemotherapy (bleomycin, vinca alkaloids, cisplatin, carboplatin)<br>• Vinyl chloride disease<br>• Arsenic poisoning |
| **Normal blood vessels – abnormal blood elements** |
| • Cryoglobulinemia (monoclonal or mixed)<br>• Cryofibrinogenemia<br>• Cold agglutinin disease<br>• Myeloproliferative disorders (e.g. essential thrombocythemia) |
| **Normal blood vessels – abnormal vasomotion** |
| • Primary (idiopathic) Raynaud phenomenon<br>• Drug-induced (ergot alkaloids, bromocriptine, interferon, estrogen, cyclosporine, sympathomimetic agents, clonidine, cocaine, nicotine)<br>• Carpal tunnel syndrome<br>• Pheochromocytoma<br>• Carcinoid syndrome<br>• Reflex sympathetic dystrophy<br>• Other vasospastic disorders (migraine, Prinzmetal) |
| *Can also affect small arteries. |

**Table 35.7 Differential diagnosis of Raynaud phenomenon.** Paraneoplastic acral vascular syndrome, which can present with Raynaud phenomenon as well as acrocyanosis and gangrene, has been observed in patients with various solid tumors (e.g. lung or ovarian carcinoma). *Adapted from Hochberg MC, Silman AJ, Smolen JS, et al. (Eds.). Rheumatology, 3rd edn. Edinburgh: Mosby, 2003.* *© Elsevier 2003.*

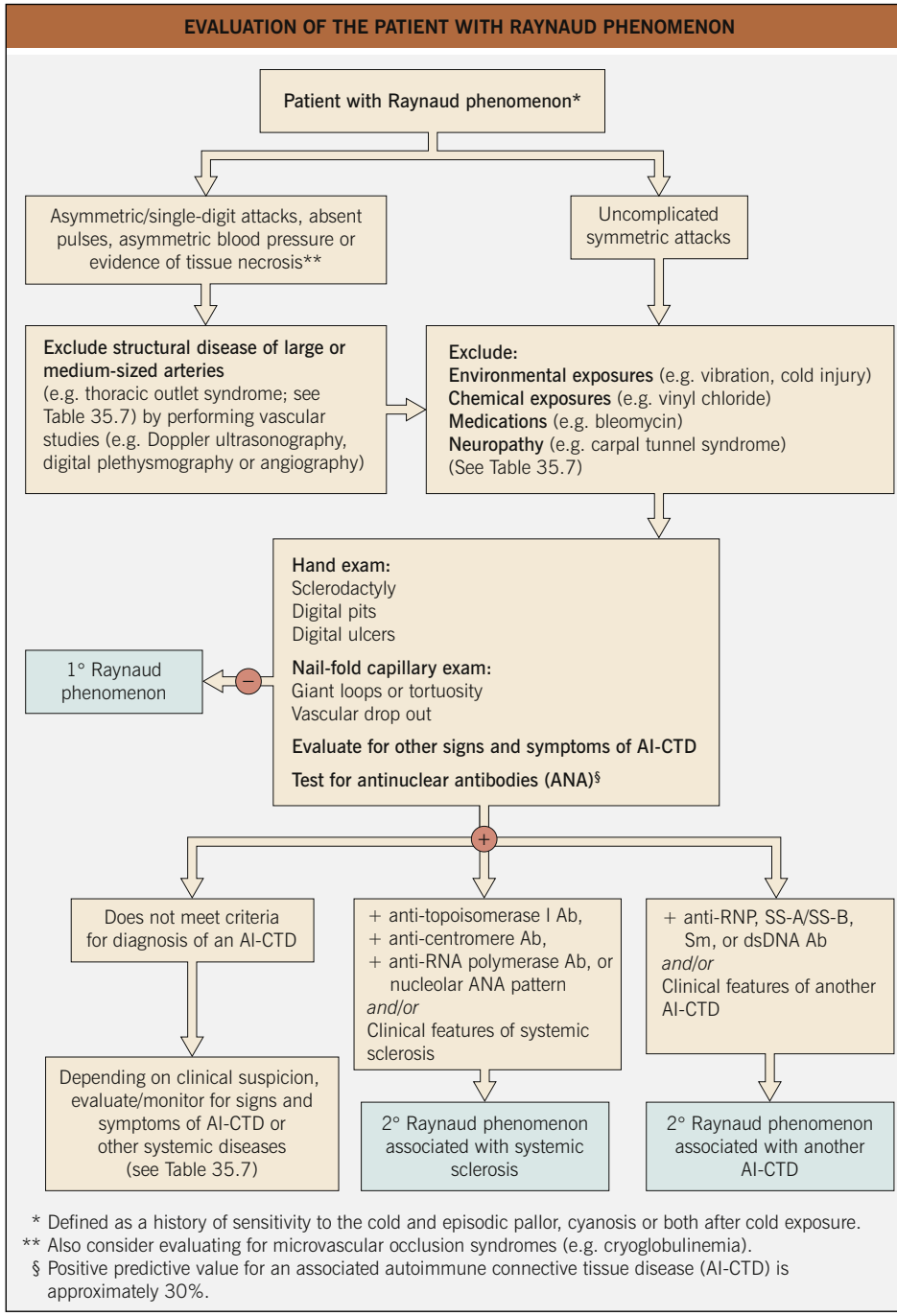


**Fig 35.10 Evaluation of the patient with Raynaud phenomenon.** RNP, ribonucleoprotein; Sm, Smith; ds, double-stranded.

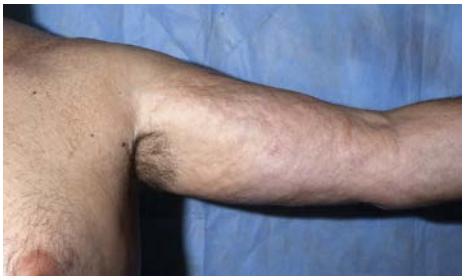

**Fig. 35.11 Eosinophilic fasciitis – clinical features.** Induration of the arm with a dimpled or "pseudo-cellulite" appearance, also referred to as rippling or puckering. *Courtesy, Edward Cowen, MD.*



**Fig. 35.12 Nephrogenic systemic fibrosis (NSF) – clinical features.** Orange-brown indurated plaques. Note the "ameboid" outline of one of the plaques on the left foot. *Courtesy, Edward Cowen, MD.*

## Sclerodermoid Disorders

- Disorders with a clinical presentation similar to SSc are referred to as "sclerodermoid disorders" (Table 35.5).

### Eosinophilic Fasciitis (Shulman Syndrome)

- Characterized initially by the rapid onset of edema and pain of the extremities, followed by symmetric, woody induration (spares hands, feet, face) (Fig. 35.11), and a dimpled or "pseudo-cellulite" appearance; associated with peripheral eosinophilia; ~30% of cases are preceded by strenuous physical activity.
- May be one of the presentations of chronic GVHD (see Ch. 44)
- Prompt treatment with oral CS is necessary to preserve mobility and function; slow taper over 6–24 months.

### Nephrogenic Systemic Fibrosis (NSF)

- Occurs in individuals with impaired renal function, most commonly (~90%) dialysis-dependent chronic kidney disease, in association with exposure to gadolinium-based contrast medium.
- Presents on the extremities with symmetrically distributed, ill-defined, thick, indurated, erythematous to hyperpigmented plaques (Fig. 35.12).
- Confluence of lesions can result in joint contracture, pain, and loss of mobility.
- Systemic fibrosis affecting the heart, lungs, and skeletal muscles can also occur.
- No effective treatment; most helpful intervention is to restore renal function (e.g. via renal transplantation).

### Stiff Skin Syndrome

- Congenital or onset in early childhood; pathogenesis unknown, but a subset with fibrillin gene mutations; chronic course with no effective treatment, other than physical therapy to prevent contractures.
- Characterized by "rock hard" induration of the skin and subcutaneous tissues of thighs and buttocks, usually bilateral; noticeable sparing of inguinal folds; associated hypertrichosis of affected areas; joint contractures; typically, no internal organ involvement.

For further information see Ch. 43 from *Dermatology, Fourth Edition*.

**For additional online figures and tables visit www.expertconsult.com**

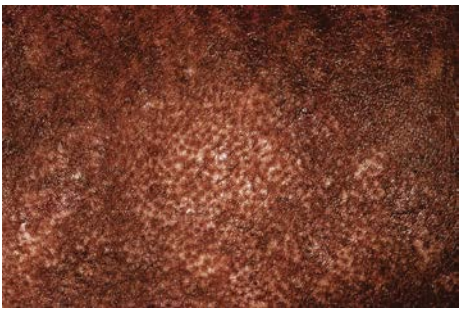

**eFig. 35.1 The "salt and pepper" sign.** Leukoderma with retention of perifollicular pigmentation in a patient with systemic sclerosis. *Courtesy, YDRSC.*

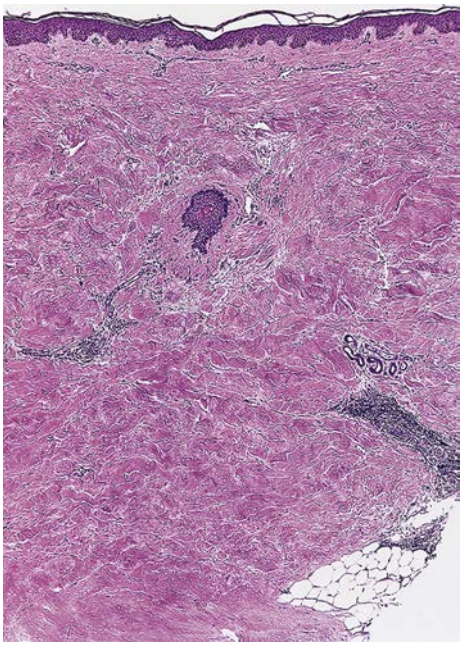

**eFig. 35.2 Systemic sclersosis – histopathologic features.** There is a dense sclerosis of the dermis with decreased adnexal structures and "trapping" of remaining adnexal structures that are encased by collagen. Sparse perivascular infiltrates of lymphocytes are present. *Courtesy, Ronald P. Rapini, MD.*



**eFig. 35.3 Raynaud phenomenon in a patient with severe sclerodermoid chronic GVHD.** The fingers have a violaceous hue as well as areas of blanching (white) and digital ulceration. Oral sildenafil led to a significant improvement. *Courtesy, YDRSC.*

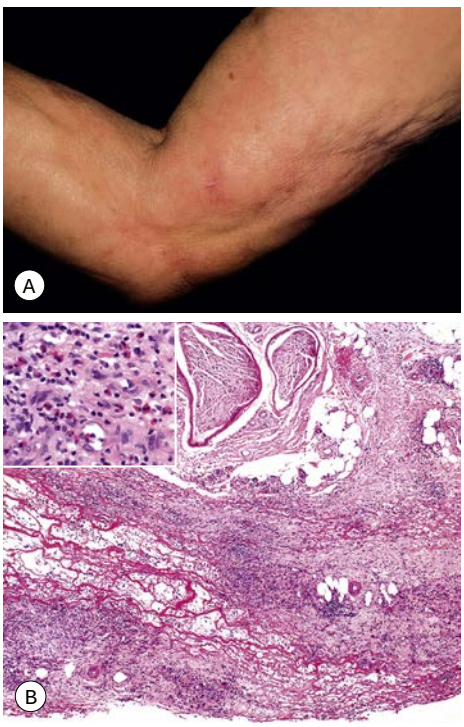


**eFig. 35.4 Eosinophilic fasciitis – clinical and histopathologic features. A** Induration of the skin with a dimpled or "pseudo-cellulite" appearance, also referred to as rippling or puckering. **B** Thickening of the deep fascia and septae of the subcutis with an inflammatory infiltrate composed of lymphocytes, histiocytes, and eosinophils. *A, Courtesy, Joyce Rico, MD; B, Courtesy, Luis Requena, MD.*

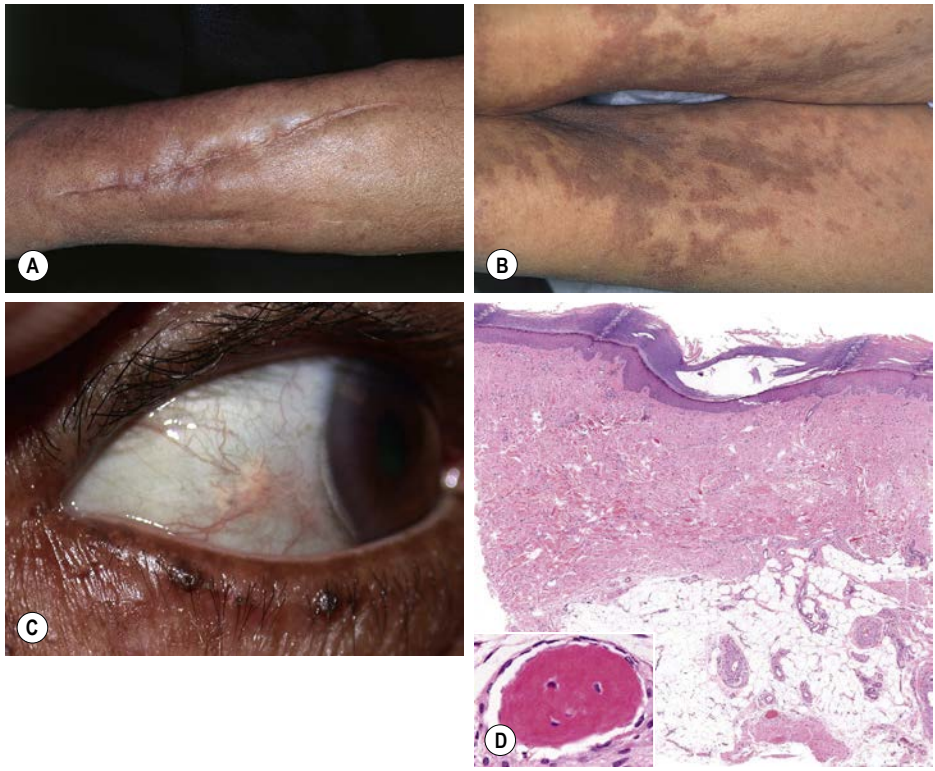


**eFig. 35.5 Nephrogenic systemic fibrosis (NSF) – clinical and histopathologic features.** Thickening and induration of the skin can be obvious (**A**), or lesions may present as purple-brown plaques (**B**). **C** Scleral plaques in a patient younger than 45 years of age is a minor criterion for NSF. **D** There is an increase in the cellularity and amount of collagen in the dermis and within the septae of the panniculitis. The spindle cells stain positively for CD34 and procollagen I. If present, osseous metaplasia ("osteoid bodies") is a useful clue to the diagnosis (inset). *A, Courtesy, Jean L. Bolognia, MD; B, Courtesy, Kalman Watsky, MD; C, Courtesy, YDRSC; D, Courtesy, Lorenzo Cerroni, MD.*

| MAJOR CLINICAL AND LABORATORY MANIFESTATIONS OF SYSTEMIC SCLEROSIS AND OTHER SELECTED CONDITIONS CHARACTERIZED BY CUTANEOUS INDURATION | | | | | | | |
|---|---|---|---|---|---|---|---|
| | **Systemic sclerosis** | **Morphea** | **Eosinophilic fasciitis** | **Scleredema** | **Scleromyx-edema** | **NSF** | **Chronic GVHD** |
| Major clinical variants | • Limited<br>• Diffuse | • Plaque-type (circum-scribed) morphea<br>• Linear morphea<br>• Generalized morphea | | • Postinfectious (type I)<br>• Monoclonal gammopathy-associated (type II)<br>• Diabetes mellitus-associated (type III) | | | • Lichen sclerosis-like<br>• Morphea-like<br>• Scleroderma-like<br>• Fasciitis |
| Raynaud phenomenon | ++ | – | – | – | – | – | – |
| Symmetric induration | ++* | – plaque-type and linear<br>± generalized | ++* | ++ | ++ | + | + |
| Sclerodactyly | ++ | – | – | – | – | – | – |
| Facial involvement | + | – plaque-type and general-ized<br>+ linear (en coup de sabre) | – | ± types I and II<br>– type III | + | – | ± |
| Systemic involvement | ++ | – for plaque-type but ± for linear involving head (ocular, CNS) | + | – | ++ | + | + |
| Antinuclear antibodies | ++ | ± generalized and linear<br>– plaque-type | – | – | – | – | ± |
| Anti-centromere antibodies | + limited | – | – | – | – | – | – |

**eTable 35.1 Major clinical and laboratory manifestations of systemic sclerosis and other selected conditions characterized by cutaneous induration.** *Continued*

| MAJOR CLINICAL AND LABORATORY MANIFESTATIONS OF SYSTEMIC SCLEROSIS AND OTHER SELECTED CONDITIONS CHARACTERIZED BY CUTANEOUS INDURATION | | | | | | | |
|---|---|---|---|---|---|---|---|
| | **Systemic sclerosis** | **Morphea** | **Eosinophilic fasciitis** | **Scleredema** | **Scleromyx-edema** | **NSF** | **Chronic GVHD** |
| Anti-topoisomerase I (Scl-70) antibodies | + diffuse | – | – | – | – | – | – |
| Anti-RNA polymerase III | + diffuse | – | – | – | – | – | – |
| Monoclonal gammopathy | – | – | ± | + type II | ++ | – | – |
| Spontaneous remission | – | ++ plaque-type<br>+ generalized<br>± linear | ++ | ++ type I<br>± types II and III | – | ±† | – |

**May be preceded by edematous phase.*
*†With improved renal function.*

**eTable 35.1** *Continued* **Major clinical and laboratory manifestations of systemic sclerosis and other selected conditions characterized by cutaneous induration.** NSF, nephrogenic systemic fibrosis; ++, almost always; +, common; ±, sometimes; –, rare or unusual. *Courtesy, Vincent Falanga, MD.*

# 36 Morphea and Lichen Sclerosus

## Morphea (Localized Scleroderma)

- An uncommon fibrosing disorder that is limited to the skin, subcutaneous tissues, and occasionally the underlying bone; if present on the face and/or scalp, it can be associated with underlying CNS abnormalities.
- It is distinct from limited systemic sclerosis (SSc; see Ch. 35) in that morphea is not associated with sclerodactyly, Raynaud phenomenon, nail-fold capillary abnormalities, or internal organ involvement.
- Morphea does not transition into SSc, except for a few rare case reports.
- Equal prevalence in adults and children; more common in females and Caucasians.
- Pathogenesis unknown but thought to involve (like SSc) vascular damage, immune activation, and increased connective tissue production by fibroblasts.
- Approximately 2–5% of children and 30% of adults with morphea have a concomitant autoimmune disease (e.g. alopecia areata, vitiligo) as well as a family history of autoimmunity.
- Classified based on clinical presentation, with five major variants recognized (see Fig. 35.1; Table 36.1).
- Early morphea lesions present as erythematous to violaceous patches and plaques (Fig. 36.1); active lesions often have a lilac border with central hypo- or dyspigmentation;

**APPROACH TO THE TREATMENT OF MORPHEA**

| Morphea variant | Treatment |
|---|---|
| Circumscribed (plaque) morphea | First line*<br>• Topical class I or intralesional CS<br>• Topical tacrolimus<br>Second line<br>• Lesion-limited phototherapy** ***or***<br>• Topical imiquimod ***or***<br>• Topical vitamin D analogue under occlusion ± class I topical CS |
| Generalized morphea | • Phototherapy** (if no joint contractures; see Fig. 36.8)<br>• Weekly methotrexate† ± systemic CS‡<br>• Mycophenolate mofetil, JAK inhibitors (e.g. tofacitinib) |
| Linear morphea | ***(Involving face or crossing joints)***<br>First line<br>• Weekly methotrexate† ± systemic CS‡<br>Second line<br>• CS-sparing agents (e.g. mycophenolate mofetil) |
| Pansclerotic morphea | See systemic therapies for generalized morphea<br>• Consider tocilizumab for refractory cases |

**If not improved after ~8 to 10 weeks, progress to next line of therapy.*
***Phototherapy choice based on local availability (UVA1, PUVA); NB-UVB may be considered for limited plaque disease.*
*†Weekly methotrexate doses: adults, 15–25 mg/week; children, 0.3–0.6 mg/kg/week.*
*‡Especially for early/progressive lesions; pulsed IV or oral daily × 2-3 months, then tapered.*

**Table 36.1 Approach to the treatment of morphea.** Treatment is most effective in active, inflammatory lesions. Topical monotherapy should not be used if any of the following are present: progressing functional impairment, joint contractures or involvement across joints, linear facial involvement.



**Fig. 36.1 Early inflammatory circumscribed (plaque) morphea of the trunk.** Early stage lesion presenting as an erythematous edematous plaque. *Courtesy, Martin Rocken, MD, and Kamran Ghoreschi, MD.*







**Fig. 36.2 Mid to later stage circumscribed (plaque) morphea. A** Sclerotic plaques with the characteristic lilac-colored rim. Histopathologic findings will differ depending upon whether the biopsy specimen is obtained from the inflammatory edge or the central area of the sclerosis. **B** The predominant lesion is a large, well-demarcated, hyperpigmented plaque that is depressed centrally; the trunk is a common location for circumscribed (plaque) morphea. *Courtesy, Martin Rocken, MD.*

inactive lesions are hyperpigmented with variable central sclerosis (Fig. 36.2); usually progresses for several years before regressing; linear variant (below) is more persistent.



**Fig. 36.3 Generalized morphea.** Multiple hyperpigmented plaques on the trunk that are becoming confluent. *Courtesy, Martin Rocken, MD.*

- Both ANA and anti-ssDNA Ab can be present.
- *Circumscribed (plaque) morphea* is the most common variant in adults, presenting with ≤3 discrete indurated plaques; the latter favor the trunk and tend to develop in areas of pressure (e.g. hips, waist, and bra line in women); superficial and deep variants (morphea profunda) exist.
- *Generalized morphea* is a rare variant that presents with >3 indurated plaques larger than 3 cm and/or involving ≥2 body sites; spares the face and hands (Figs 36.3, 36.4 and see Fig. 36.8); more likely to have a (+) ANA and systemic symptoms.
- *Linear morphea* is the most common variant in children and may cause a significant degree of morbidity because of either ocular involvement and occasionally CNS involvement in the head variant (Fig. 36.5), or muscle atrophy, discrepancies in limb length, and joint contractures in the limb variant (Fig. 36.6).




**Fig. 36.4 Comparison of deep morphea and eosinophilic fasciitis.** It is often difficult to distinguish between deep morphea and eosinophilic fasciitis based upon clinical presentation. **A** Note the "pseudo-cellulite" appearance of the involved skin of the upper arm and the depression or groove in the forearm (due to deep sclerosis) in deep morphea. This patient also had biopsy-proven, generalized morphea on the trunk. The lack of involvement of the hands is a clue that this is not systemic sclerosis (SSc). **B** In eosinophilic fasciitis, the level of fibrosis is also deep, resulting in a similar rippled appearance. This patient had the eosinophilic fasciitis-like form of chronic GVHD, also referred to as chronic GVHD-related fasciitis. *A, Courtesy, Karynne O. Duncan, MD; B, Courtesy, Edward Cowen, MD.*

- *Pansclerotic morphea* is the most debilitating and treatment-resistant variant, but is very rare; it affects the subcutaneous tissues down to and often including the bone; presents as expanding plaques that may eventually coalesce over the entire trunk or extend circumferentially down the extremities; increased risk of cutaneous SCC.
- *Mixed morphea* involves a combination of ≥2 other morphea variants and constitutes ~15% of all morphea cases; overlap with lichen sclerosus can also occur.
- Extracutaneous manifestations are most common in patients with generalized morphea and in children; arthralgia is the most common finding.
- **DDx:** morpheaform disorders (Table 36.2), SSc and sclerodermoid disorders (see Table 35.5), lichen sclerosus, keloids (Fig. 36.7), atrophoderma of Pasini and Perini.
- Morphea and SSc cannot be differentiated by histopathologic examination.
- **Rx:** best utilized during the early, inflammatory stage (see Table 36.1); in general, therapy will not readily reverse established sclerosis; however, the plaques of circumscribed and generalized morphea often soften over a period of years, especially those on the trunk, eventually resembling atrophoderma or completely resolving (Fig. 36.8).

## Lichen Sclerosus (LS)

- Formerly called lichen sclerosus et atrophicus.
- A clinically distinct inflammatory disease of the superficial dermis that leads to white, scar-like lesions with surface wrinkling due to epidermal atrophy.
- Most commonly affects female or male genitalia, less often non-genital skin.
- Approximately 80% of LS patients have IgG autoantibodies against extracellular matrix (ECM-1).
- Ultrapotent topical CS are highly effective for treatment of LS; other treatment options are listed in Table 36.3.

### Genital LS in Females

- Bimodal presentation: 4–12 years of age and 6th–7th decade.
- Favors vulva and perianal regions; confluent, symmetric involvement of the labial, perineal, and perianal areas has been likened to a "figure 8 configuration".




**Fig. 36.5 Linear morphea, head variant.** **A** Parry–Romberg syndrome, demonstrating unilateral sclerosis and loss of subcutaneous tissue, leading to facial asymmetry. **B–D** *En coup de sabre.* On the forehead, the linear band(s) of sclerosis and atrophy are usually paramedian (rather than midline). **B** Both hyper- and hypopigmentation are present as well as subtle depression. **C** An obviously depressed and sclerotic linear band. **D** When linear morphea extends onto the scalp, it results in scarring alopecia. Note the "lonely hairs" that are seen in various forms of scarring alopecia. *A, Courtesy, Lorenzo Cerroni, MD; B, D, Courtesy, Martin Rocken, MD; C, Courtesy, NYUDSC.*

- **Early:** well-demarcated, erythematous thin plaque(s) ± erosions (Fig. 36.9).
- **Mid:** evolves into dry, hypopigmented sclerotic lesion(s).
- **Late:** obliteration of the labia minora and peri-clitoral structures; narrowing of the vaginal introitus.
- Purpura and perineal fissures are common findings and sometimes mistaken for sexual abuse; lentigines and melanocytic nevi may also be seen within areas of LS.
- Associated symptoms: severe pruritus, soreness, dysuria, dyspareunia, and pain upon defecation.
- May be complicated by possible SCC development, especially if untreated.
- **DDx:** vitiligo, erosive lichen planus, sexual abuse, intraepithelial neoplasia (see Ch. 60), SCC, extramammary Paget disease.

## Genital LS in Males

- Also known as balanitis xerotica obliterans.
- Bimodal presentation: prepubertal and older males; more common if uncircumcised.
- Often presents with recurrent balanitis or acquired phimosis; rarely affects perianal region.




**Fig. 36.6 Linear morphea, limb variant. A** Linear sclerotic band of the arm with both hyper- and hypopigmentation. The majority of patients with linear morphea have unilateral involvement. **B** More inflammatory phase with ulceration in addition to induration. The differential diagnosis includes linear melorheostosis, which is often associated with underlying candlewax-like linear hyperostosis. **C** Extensive linear morphea of the right leg leading to hypoplasia. In addition to marked hypoplasia, there is induration and a flexion contracture of the knee. *A, Courtesy, Julie V. Schaffer, MD; B, Courtesy, YDRSC; C, Courtesy, Martin Rocken, MD.*

| DIFFERENTIAL DIAGNOSIS OF MORPHEAFORM SKIN LESIONS |
|---|
| • Morphea (circumscribed [superficial or deep*], linear, generalized*) |
| • Chronic graft-versus-host disease* |
| • Lichen sclerosus (may coexist with morphea) |
| • Lipodermatosclerosis* |
| • Sclerosis at injection sites** (e.g. vitamin $K_1$ or $B_{12}$, silicone or paraffin implants, intralesional bleomycin, interferon-β, glatiramer, enfuvirtide, opioids, vaccinations, antisense oligonucleotides) |
| • Chemical/toxin exposures (e.g. aromatic/chlorinated hydrocarbons*, nephrogenic systemic fibrosis*, toxic oil syndrome [historical]*) |
| • Radiation-induced morphea |
| • Porphyria (e.g. porphyria cutanea tarda) |
| • H syndrome |
| • Stiff skin syndrome*, linear melorheostosis |
| • Reflex sympathetic dystrophy* |
| • Cutaneous metastases (e.g. carcinoma *en cuirasse*) |
| **Can overlap with sclerodermoid disorders, which are outlined in Table 35.5; in particular, deep morphea and eosinophilic fasciitis may have a similar appearance (see Fig. 36.4).* |
| ***Systemic medications for which there have been reports of an association with morpheaform lesions include bleomycin, taxanes (e.g. paclitaxel, docetaxel), bromocriptine, ethosuximide, valproic acid, appetite suppressants, and penicillamine.* |

**Table 36.2 Differential diagnosis of morpheaform skin lesions.** The location of the morpheaform lesions may offer a clue to the diagnosis, e.g. in lipodermatosclerosis, lesions are located on the lower extremities, and in radiation-induced morphea, lesions are within the radiation port site.



**Fig. 36.7 Nodular (keloidal) morphea.** Elevated, firm pink papulonodules arising within an area of hyperpigmented induration. *Courtesy, Jean L. Bolognia, MD.*

- **Early:** glans and inner foreskin have well-demarcated, erythematous thin plaques ± erosions.
- **Mid:** evolves into atrophic, white, sclerotic, scar-like lesion(s) (Fig. 36.10).
- **Late:** phimosis or complete occlusion of glans.

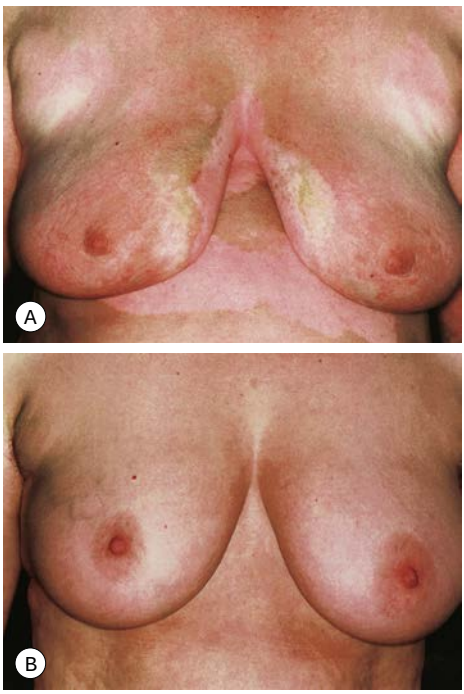


**Fig. 36.8 Phototherapy of generalized morphea.** Generalized morphea with trunk involvement before **(A)** and after PUVA bath photochemotherapy **(B)**. Note that generalized morphea may involve the breasts but characteristically spares the nipples. *Courtesy, Martin Rocken, MD, and Kamran Ghoreschi, MD.*

| TREATMENT OPTIONS FOR LICHEN SCLEROSUS (LS) | |
|---|---|
| **Disease severity** | **Treatment** |
| Mild to moderate | **Clearance**: 6–12 weeks (may need to be repeated yearly if remains clinically active)<br>• Topical class I CS* – daily<br>• Topical calcineurin inhibitors* – daily<br>• Intralesional CS – once to three times during clearance phase, depending upon extent and severity<br>**Maintenance**<br>• Topical petrolatum-based ointments – daily<br>• Topical class VII CS* – daily<br>• Topical class I CS* – occasional, e.g. twice weekly<br>• Topical calcineurin inhibitors* – occasional, e.g. twice weekly |
| Severe or refractory | • Oral retinoids (acitretin 10–50 mg/day for ≥6 months)<br>• Phototherapy** (e.g. bath PUVA, NB-UVB, UVA1) |

**Ointments are preferred over creams for genital LS because they are less irritating.*
***Not recommended for genital LS because increases risk of genital SCC.*

**Table 36.3 Treatment options for lichen sclerosus (LS).** Some clinicians limit the use of calcineurin inhibitors for genital LS.







**Fig. 36.9 Anogenital lichen sclerosus.** **A** Characteristic vulvar, perineal and perianal involvement in a child. Symmetric ivory-colored plaques with a thin pink peripheral rim are seen; a perianal pyramidal protrusion is also present. **B** Perianal lichen sclerosus in which the hypopigmented plaques are accompanied by a linear erosion (skin tear) at 6 o'clock and central fissuring of the perineum. *Courtesy, Martin Rocken, MD.*

• Associated with pruritus and soreness, painful erections, dysuria, urinary obstruction, and possible development of SCC.
• **DDx:** SCC *in situ*, sexual abuse, erosive lichen planus, candidiasis, intraepithelial neoplasia (see Ch. 60), extramammary Paget disease.

## Extragenital LS

• Affects all ages with slight female predominance.
• Favors the neck (Fig. 36.11), shoulders, trunk, proximal extremities, flexor wrists, and sites of trauma or pressure; associated xerosis and mild pruritus.



**Fig. 36.10 Genital lichen sclerosus involving the penis (balanitis xerotica obliterans).** Note the ivory color, erosion, and scarring. *Courtesy, USCDRSC.*

- **Early:** polygonal, white, shiny, papules that often coalesce into plaques.
- **Mid:** evolve into scar-like, atrophic, wrinkled patches and plaques; follicular plugging (Fig. 36.12A).
- **Late:** telangiectasias and occasional hemorrhagic bullae (Fig. 36.12B).
- **DDx:** localized morphea, scar, chronic GVHD; of note, LS (including the genital form) may coexist with morphea and/or vitiligo.




**Fig. 36.11 Extragenital lichen sclerosus (LS).** Shiny ivory-colored plaques of the breast **(A)** and the lower back **(B)**. Several guttate satellite lesions are present on the breast. *A, Courtesy, Martin Rocken, MD; B, Courtesy, Martin Rocken, MD, and Kamran Ghoreschi, MD.*

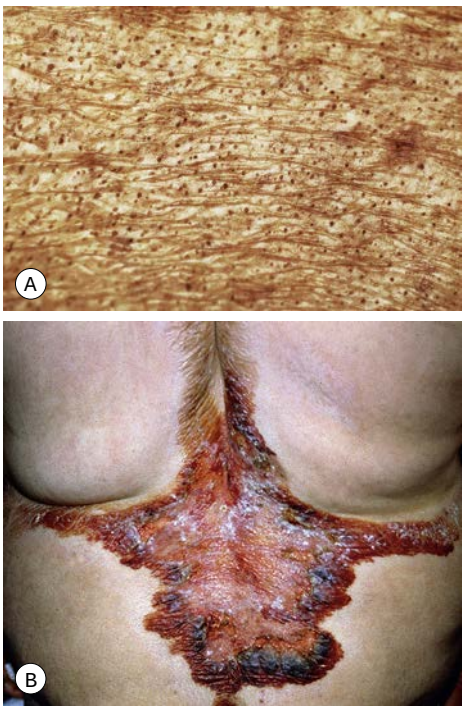


**Fig. 36.12 Extragenital lichen sclerosus (LS). A** Follicular plugging in a plaque of LS on the back of a patient with chronic GVHD. **B** Hemorrhagic bullae primarily at the periphery of a large plaque on the back. *A, Courtesy, Jean L. Bolognia, MD; B, Courtesy, Luis Requena, MD.*

For further information see Ch. 44 from *Dermatology, Fourth Edition*.



**eFig. 36.1 Mid to later stage circumscribed (plaque) morphea.** Multiple, large hyperpigmented plaques, several of which have an inflammatory border. *Courtesy, NYUDSC.*



**eFig. 36.2 Generalized morphea.** Circumferential involvement with sparing of the central portion of the breast is a classic distribution pattern. *Courtesy, Luis Requena, MD.*




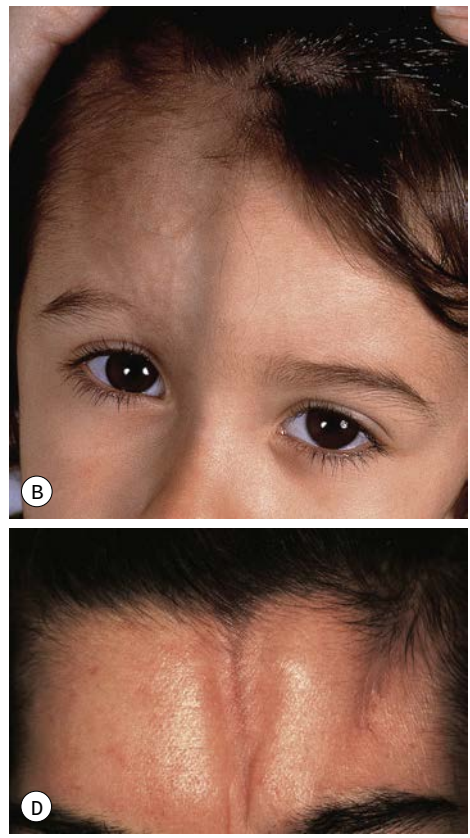


**eFig. 36.3 Linear morphea, head variant.** **A** Parry–Romberg syndrome, demonstrating hyperpigmentation and loss of subcutaneous tissue, leading to facial asymmetry. **B–D** *En coup de sabre* with linear paramedian depressions and sclerosis – **(B)** (wide) and **(C)** (narrow) – being more common than midline involvement as in **(D)**. Note the prominent veins and loss of the medial eyebrow in **(B)**. *A, C, Courtesy, Julie V. Schaffer, MD; B, Courtesy, NYUDSC; D, Courtesy, Martin Rocken, MD, and Kamran Ghoreschi, MD.*




**eFig. 36.4 Linear morphea, limb variant.** **A** Linear distribution of coalescing sclerotic plaques on the thigh; note the lilac-colored border. **B** Extensive induration of the left leg with hypoplasia and an obvious flexion contracture of the knee; there is also involvement of the right foot. *A, Courtesy, Julie V. Schaffer, MD; B, Courtesy, Martin Rocken, MD, and Kamran Ghoreschi, MD.*

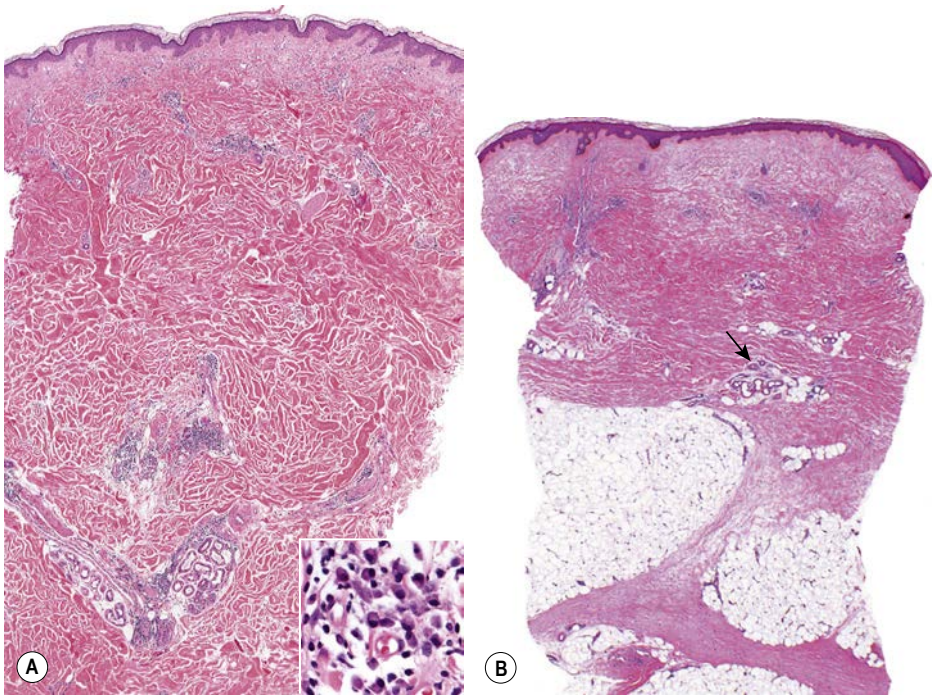


**eFig. 36.5 Morphea – histopathologic features.** In general, it is difficult to distinguish between morphea and systemic sclerosis (SSc) based upon histopathology, although the presence of plasma cells points more towards morphea. Ultimately, it is the clinical findings that help the clinician make the correct diagnosis. **A** Overview with thickening of the dermis and perivascular and peri-eccrine infiltrates of lymphocytes and plasma cells (inset). These changes can be seen in the inflammatory border. **B** Advanced sclerosis of the entire dermis extending into the fat with thickened collagen bundles and "trapped" eccrine glands (arrow). This corresponds to the areas of induration within the plaque. *Courtesy, Lorenzo Cerroni, MD.*



**eFig. 36.6 Genital lichen sclerosus involving the vulva of a young female.** Centrally, there is erythema with superficial erosion and purpura. More peripherally, white plaques with a wrinkled surface are seen. Note fissuring of the perineum. *Courtesy, Martin Rocken, MD, and Kamran Ghoreschi, MD.*




**eFig. 36.7 Extragenital lichen sclerosus (LS).** **A** LS of the neck presenting as white papules and small plaques. **B** Hemorrhagic bullae on the leg. *A, Courtesy, Martin Rocken, MD, and Kamran Ghoreschi, MD; B, Courtesy, YDRSC.*




**eFig. 36.8 Ultrapotent topical corticosteroids in the treatment of lichen sclerosus in a 12-year-old girl.** Before **(A)** and after **(B)** topical application of clobetasol propionate 0.05% cream daily for 5 months. *Courtesy, Martin Rocken, MD, and Kamran Ghoreschi, MD.*

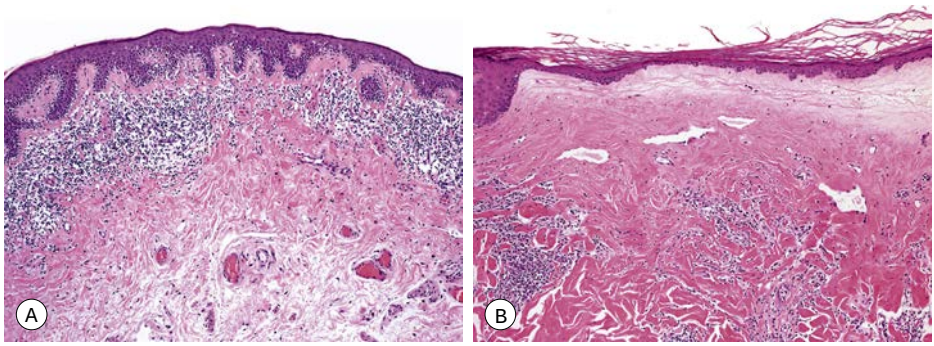


**eFig. 36.9 Lichen sclerosus – histopathologic features. A** Early lesion with band-like infiltrate of lymphocytes in the upper dermis and vacuolar change at the dermal–epidermal junction. Mild homogenization of the papillary dermis is present. **B** Late lesion with orthokeratosis, thinning of the epidermis and homogenization of the upper dermis. There is also hyalinization and sclerosis of the papillary dermis, telangiectasias and an interstitial lymphocytic infiltrate. *Courtesy, Lorenzo Cerroni, MD.*

# 37 Other Rheumatologic Disorders and Autoinflammatory Diseases

## Systemic-Onset Juvenile Idiopathic Arthritis (SoJIA; Still Disease) and Adult-Onset Still Disease (AoSD)

- Among the major types of juvenile idiopathic arthritis (JIA; formerly juvenile rheumatoid arthritis [JRA]), cutaneous manifestations are most common in SoJIA, psoriatic arthritis (see Ch. 6), and rheumatoid factor (RF)-positive polyarthritis (rheumatoid nodules and other findings similar to rheumatoid arthritis [RA]; see below).
- SoJIA can develop at any age prior to 16 years and affects both sexes equally; AoSD has peaks in the second and fourth decades and affects women more often than men.
- Both SoJIA and AoSD are characterized by daily spiking fevers (especially in the late afternoon/early evening) accompanied by an *evanescent* eruption of salmon-pink macules and slightly edematous papules and plaques (Fig. 37.1A; see Table 37.3); these lesions are usually asymptomatic and favor sites of pressure or trauma, often occurring in a linear array.
- Less common skin findings include periorbital edema and persistent pruritic papules and plaques that are scaly, violaceous to reddish brown in color, and linear in configuration (Fig. 37.1B).
- Additional features include a prodromal sore throat and arthralgias/myalgias, arthritis (usually polyarticular; ± carpal ankylosis in AoSD), lymphadenopathy, hepatosplenomegaly, and serositis; occasionally patients may develop macrophage activation syndrome (also characterized by markedly elevated ferritin).
- Leukocytosis with neutrophilia, thrombocytosis, anemia, elevated ESR/CRP, and extremely high serum ferritin levels (e.g. >4000 mg/ml) are common laboratory findings, whereas ANA and RF are usually absent.
- **DDx:** serum sickness-like reactions, urticarial vasculitis, Schnitzler syndrome (in adults; see Ch. 14), other autoimmune connective tissue diseases, rheumatic fever, infections (e.g. parvovirus B19, rat bite fever, malaria), hereditary periodic fever syndromes (see Table 3.2), and malignancies (e.g. leukemia, lymphoma).
- **Rx:** NSAIDs (for mild disease), systemic CS, methotrexate, antagonists of IL-1 (e.g. anakinra, canakinumab) or IL-6 (e.g. tocilizumab), and TNF inhibitors (the latter especially for arthritis).

## Rheumatoid Arthritis

- Chronic inflammatory disorder characterized primarily by destructive arthritis.
- Affects 1–3% of adults, with a female:male ratio of 2–3:1 and a peak onset between 35 and 60 years of age.
- RF and anti-cyclic citrullinated peptide (CCP) antibodies represent serologic markers of RA.
- Cutaneous manifestations of RA are presented in Table 37.1 and Fig. 37.2; these findings can serve as diagnostic clues or signs of serious systemic disease.

## Sjögren Syndrome

- Autoimmune disorder primarily affecting the lacrimal and salivary glands, resulting in xerophthalmia and xerostomia; may coexist with other AI-CTDs (e.g. LE).
- Affects ~0.5% of the general population, with a female:male ratio of 9:1; peak onset is in the fourth and fifth decades of life, but can occur at any age.
- Cutaneous manifestations include xerosis, palpable purpura due to small vessel




**Fig. 37.1 Cutaneous findings in Still disease.** **A** Evanescent pink papules and figurate plaques in a child. **B** Flagellate array of pinkish-tan, scaly persistent plaques on the upper back in a teenage girl. *A, Courtesy, YDRSC; B, Courtesy, Julie V. Schaffer, MD.*

vasculitis (including cryoglobulinemic vasculitis), hypergammaglobulinemic purpura of Waldenström, urticarial vasculitis, annular erythema, and Raynaud phenomenon.

- Additional features can include vaginal dryness, arthritis, peripheral neuropathy, internal organ involvement (e.g. kidneys), and development of B-cell lymphoma (often extranodal marginal zone).
- Majority of patients have anti-SSA/Ro and anti-SSB/La antibodies, a positive RF, and an elevated ESR.
- Diagnostic criteria for Sjögren syndrome are presented in Table 37.2.
- **Rx:** mostly symptomatic – use of artificial tears and saliva (e.g. methylcellulose drops), chewing sugar-free gum, meticulous dental hygiene, and treatment of superimposed oral candidiasis; sicca symptoms may improve with cyclosporine eye drops, lifitegrast eye drops, or cholinergic agonists (e.g. pilocarpine, cevimeline); vasculitis or internal involvement often require systemic CS, conventional immunosuppressive agents, or rituximab.

## Relapsing Polychondritis

- Uncommon autoimmune condition that affects cartilaginous structures; pathogenesis is thought to involve a reaction against type II collagen.
- Most patients develop erythema, swelling and pain of the cartilaginous portion of the auricle, with sparing of the earlobe (Fig. 37.3A).
- Other manifestations include cutaneous small vessel vasculitis (Fig. 37.3B), aphthae (oral or genital; may overlap with Behçet disease), nasal chondritis (potentially producing a saddle nose deformity), involvement of cartilage of the respiratory tract (e.g. larynx, trachea, bronchi) and costochondral junctions, arthritis, ocular inflammation, audiovestibular damage, and myelodysplastic syndrome.
- **DDx:** *early phase* – erysipelas, cellulitis, infectious chondritis or zoster; *nasal destruction* – granulomatosis with polyangiitis, nasal natural killer/T-cell lymphoma, infections (e.g. mucocutaneous leishmaniasis) (see Table 19.3).
- **Rx:** prednisone (for acute flares), dapsone, immunosuppressive agents, TNF inhibitors; surgical repair of damaged cartilaginous structures.

## Mixed Connective Tissue Disease (MCTD)

- Characterized by high-titer anti-U1 ribonucleoprotein (U1-RNP) antibodies plus a constellation of clinical features including arthritis, myositis, and findings of systemic sclerosis; the latter range from swollen hands and Raynaud phenomenon to esophageal dysmotility and pulmonary hypertension (the most serious complication) or fibrosis (often mild).
- Favors women (female:male ratio ~9:1) in the second and third decades of life.
- Edema and erythema of the digits is an early manifestation; digital infarcts, periungual telangiectasias with dropout areas, sclerodactyly, and calcinosis cutis may also develop.
- Poikiloderma on the upper trunk and proximal extremities is common; photosensitivity,

| CUTANEOUS MANIFESTATIONS OF RHEUMATOID ARTHRITIS (RA) | |
|---|---|
| **Condition** | **Features** |
| **Palisading granulomas** | |
| Rheumatoid nodules | • Affect ~20% of RA patients, often associated with high-titer RF<br>• Firm, semi-mobile papulonodules favoring periarticular locations (e.g. elbows; Fig. 37.2A) and other sites of repetitive trauma or pressure (e.g. the sacral region if bedridden)<br>• **DDx:** subcutaneous granuloma annulare, gouty tophi, synovial hyperplasia/cysts (softer, painful)<br>• Histologically, central zone of eosinophilic fibrin surrounded by palisaded histiocytes |
| Interstitial granulomatous dermatitis (IGD) and palisaded neutrophilic & granulomatous dermatitis (PNGD) | • See Ch. 78; the PNGD spectrum includes *rheumatoid papules* (Fig. 37.2B) and *superficial ulcerating rheumatoid necrobiosis* (Fig. 37.2C) |
| **Neutrophilic dermatoses** | |
| Rheumatoid neutrophilic dermatitis | • Erythematous papules and plaques that may be vesiculated or crusted; favors extensor extremities<br>• Unlike Sweet syndrome, *not* tender or associated with fevers and malaise |
| Sweet syndrome and pyoderma gangrenosum (PG)* | • See Ch. 21; Fig. 37.2D |
| Neutrophilic lobular panniculitis | • Tender red nodules favoring the lower legs; may ulcerate with purulent drainage |
| **Vasculitis and vascular reactions** | |
| Bywaters lesions | • Punctate purpuric papules on the distal digits due to cutaneous small vessel vasculitis (Fig. 37.2E) |
| Rheumatoid vasculitis | • Associated with long-standing (often "burnt out") joint disease, high-titer RF, and mononeuritis multiplex; may also affect the eyes and internal organs<br>• Cutaneous involvement is usually the first manifestation<br>– *Small vessel vasculitis*: purpuric macules and papules<br>– *Medium-sized vessel vasculitis*: nodules, ulcers, digital gangrene, livedo reticularis, atrophie blanche-like scars<br>• Systemic disease requires aggressive immunosuppressive therapy |
| Intravascular/intralymphatic histiocytosis | • Erythema, induration and papules in a reticular pattern overlying swollen joints, most often the elbows |
| Erythema elevatum diutinum | • Firm, red to yellow-brown papulonodules and plaques, usually on extensor surfaces (see Ch. 19) |
| **Complications of therapy for RA** | |
| NSAIDs | • Pseudoporphyria, toxic epidermal necrolysis |
| Methotrexate >> TNF inhibitors | • Accelerated rheumatoid nodulosis – sudden appearance of multiple papulonodules, especially on the hands (Fig. 37.2F) |
| TNF inhibitors | • Injection site reactions, urticaria, urticarial eruptions, vasculitis, IGD, cutaneous LE, psoriasiform eruptions, palmoplantar pustulosis, dermatomyositis |

**"PG-like" leg ulcers are a feature of Felty syndrome, which is characterized by the triad of neutropenia, splenomegaly, and RA; Felty syndrome may be associated with T-cell large granular lymphocyte leukemia.*

**Table 37.1 Cutaneous manifestations of rheumatoid arthritis (RA).**




**Fig. 37.2 Cutaneous findings in rheumatoid arthritis. A** Rheumatoid nodules in a periarticular location on the hands. **B** Rheumatoid papules presenting as coalescing red-brown lesions, some with scale-crust, on the lower extremity. **C** Superficial ulcerating rheumatoid necrobiosis manifesting as shiny, yellow-brown plaques with red-brown borders and areas of ulceration; these clinical findings are reminiscent of necrobiosis lipoidica, although both this entity and rheumatoid papules are categorized as forms of palisaded neutrophilic and granulomatous dermatitis (see Ch. 78). **D** Pyoderma gangrenosum resulting in recurrent ulcerations on the lower extremities. **E** Bywaters lesions. These tender purpuric papules on the distal fingers are characterized histologically by leukocytoclastic vasculitis. **F** Methotrexate-induced nodulosis. *A, Courtesy, Kalman Watsky, MD; B, C, E, Courtesy, Jeffrey Callen, MD; D, Courtesy, Carlos Nousari, MD; F, Courtesy, Jean L. Bolognia, MD.*

malar erythema, and subacute cutaneous LE occasionally occur.

- **DDx:** features overlap with those of systemic sclerosis, dermatomyositis/polymyositis, and SLE; for this reason, the debate continues regarding the distinction between MCTD (a specific entity requiring the presence of elevated U1-RNP) and less specific "overlap syndromes" (features of two or more AI-CTDs in a single patient).



A L G r a w a n y

| AMERICAN COLLEGE OF RHEUMATOLOGY (ACR)/EUROPEAN LEAGUE AGAINST RHEUMATISM (ELAR) 2016 CLASSIFICATION CRITERIA FOR PRIMARY SJÖGREN'S SYNDROME (SjS) | |
|---|---|
| The classification of primary SjS applies to any individual who meets the inclusion criteria*, does not have any of the conditions listed as exclusion criteria^, and has a score of ≥4 when the weights from the five criteria items below are summed | |
| **Criterion** | **Weight/score** |
| Labial salivary gland with focal lymphocytic sialadenitis and focus score of ≥1 foci/4 $mm^2$ | 3 |
| Anti-SSA/Ro-positive | 3 |
| Ocular staining score ≥5 (or van Bijsterveld score >4) in at least one eye^^ | 1 |
| Schirmer's test ≤5 mm/5 min in at least one eye^^ | 1 |
| Unstimulated whole saliva flow rate ≤0.1 mL/min^^ | 1 |

**Inclusion criteria apply to any patient with at least one symptom of ocular or oral dryness, defined as a positive response to at least 1 of the following questions: (1) Have you had daily, persistent, troublesome dry eyes for more than 3 months? (2) Do you have a recurrent sensation of sand or gravel in the eyes? (3) Do you use tear substitutes more than 3 times a day? (4) Have you had a daily feeling of dry mouth for more than 3 months? (5) Do you frequently drink liquids to aid in swallowing dry food? or in whom there is suspicion of SjS from the ELAR SjS Disease Activity Questionnaire (at least 1 domain with a positive item).*

*^Exclusion criteria include prior diagnosis of any of the following conditions: (1) history of head and neck radiation treatment; (2) active hepatitis C infection (with confirmation by PCR); (3) AIDS; (4) sarcoidosis; (5) amyloidosis; (6) GVHD; (7) IgG4-related disease.*

*^^Patients taking anticholinergic drugs should be evaluated after a sufficient interval without these medications for tests to be valid.*

**Table 37.2 American College of Rheumatology (ACR)/European League Against Rheumatism (ELAR) 2016 classification criteria for primary Sjögren syndrome.** Other possible causes of similar findings include chronic GVHD, primary systemic amyloidosis, sarcoidosis, and radiation therapy of the head and neck. *Adapted from Shiboski et al. Ann Rheum Dis 2017;76:9.*




**Fig. 37.3 Cutaneous findings in relapsing polychondritis. A** Erythema and swelling of the ear with sparing of the earlobe. **B** Small vessel vasculitis presenting as palpable purpura in a patient who also had a myelodysplastic syndrome. *A, Courtesy, Kalman Watsky, MD; B, Courtesy, Jean L. Bolognia, MD.*

• **Rx:** varies depending on the organs involved and disease severity.

## Autoinflammatory Diseases

• Monogenic diseases related to aberrant activation of the innate immune system that are characterized by recurrent fevers and/or flares of multi-organ inflammation; the skin is frequently involved as are the musculoskeletal system, eyes, and serosae.

• This group includes the hereditary periodic fever syndromes (see Table 3.2), type I interferonopathies, deficiency of interleukin (IL)-1 receptor (DIRA), and CARD14-mediated pustular psoriasis.

• Cutaneous lesions vary from evanescent urticarial papules and sterile pustules to pyoderma gangrenosum and pernio-like lesions (Table 37.3).

• Increased production of IL-1 via inflammasomes can be seen and several of these entities respond to IL-1 antagonists, e.g. anakinra, rilonacept, canakinumab.

• Complex disorders such as Schnitzler syndrome and systemic-onset juvenile idiopathic arthritis (Still disease) share mechanistic and clinical features.

For further information see Ch. 45 from *Dermatology, Fourth Edition*.

**For additional online figures and tables visit www.expertconsult.com**

**RANGE OF CUTANEOUS FINDINGS IN INHERITED AUTOINFLAMMATORY DISEASE**

| | Cutaneous and histologic features | Inherited autoinflammatory disease(s) – examples | | Sporadic or complex disorders with similar findings |
|---|---|---|---|---|
| | | Disorder | Other features† | |
|  | **Evanescent maculopapular/urticarial eruption**, often cold-induced and (in CAPS) with a dermal neutrophilic infiltrate | CAPS<br>PLAID | • CAPS: conjunctivitis, hearing loss, oral ulcers; LAN, HSM, and aseptic meningitis in NOMID variant<br>• PLAID: recurrent infections, antibody deficiency, autoimmunity; occasionally cutaneous granulomas | • Schnitzler syndrome (Ch. 14)<br>• *Adult-onset Still disease* (pictured)<br>• *Systemic-onset juvenile idiopathic arthritis (SoJIA; Still disease)* |
| 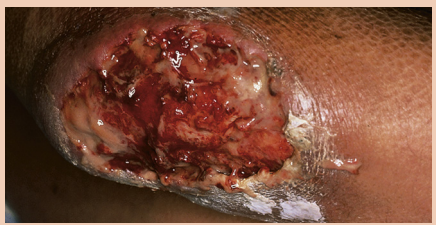 | **Ulcerations**, with a sterile neutrophilic infiltrate within the dermis* (pyoderma gangrenosum) | PAPA syndrome** | • Arthritis | Pyoderma gangrenosum – idiopathic and in the setting of associated disorders (e.g. ulcerative colitis) (Ch. 21) (pictured) |

*Untreated lesion.
**PASH (pyoderma gangrenosum, acne, and suppurative hidradenitis) and PAPASH (pyogenic arthritis, pyoderma gangrenosum, acne, and suppurative hidradenitis) syndromes are considered variants of PAPA syndrome.
†Recurrent fevers also occur in many of these disorders.

**Table 37.3** *Continued* **Range of cutaneous findings in inherited autoinflammatory diseases.** Disorders discussed in this chapter are in italics. CAPS, cryopyrin-associated periodic syndrome; PAPA, pyogenic arthritis, pyoderma gangrenosum, and acne; PLAID, PLCG2-associated antibody deficiency and immune dysregulation; NOMID, neonatal-onset multisystem inflammatory disease. *Picture courtesies: Diane Davidson, MD (adult-onset Still disease); Gillian Clarke, MD (DIRA); Kalman Watsky, MD (Sweet syndrome); Edward Cowen, MD (ADA2 deficiency); Julie V. Schaffer, MD (AGS, Blau syndrome). Continued*

| RANGE OF CUTANEOUS FINDINGS IN INHERITED AUTOINFLAMMATORY DISEASE | | | | |
|---|---|---|---|---|
| | **Cutaneous and histologic features** | **Inherited autoinflammatory disease(s) – examples** | | **Sporadic or complex disorders with similar findings** |
| | | **Disorder** | **Other features†** | |
|  | **Pustules** (sterile) | DIRA (pictured)<br>DITRA<br>PAPA syndrome**<br>CAMPS | • DIRA: sterile osteolytic bone lesions, neonatal distress<br>• PAPA: arthritis | Generalized pustular psoriasis<br>Impetigo herpetiformis<br>SAPHO syndrome (Ch. 21)<br>Acne fulminans |
|  | **Edematous plaques**, with a sterile neutrophilic infiltrate within the dermis or panniculus | Majeed syndrome<br>VEXAS<br>Haploinsufficiency of A20 (Behçet-like)<br>ORAS | • Majeed: sterile multifocal osteomyelitis, dyserythropoietic anemia<br>• VEXAS: periorbital edema, polyarteritis nodosa; myelodysplastic syndrome, arthralgias, polychondritis, pulmonary infiltrates<br>• ORAS: lipodystrophy, joint swelling, diarrhea | Sweet syndrome – idiopathic or occurring in the setting of associated disorders (e.g. acute myelogenous leukemia) (Ch. 21) (pictured)<br>Behçet disease (Ch. 21) |

**Table 37.3** *Continued* **Range of cutaneous findings in inherited autoinflammatory diseases.** CAMPS, CARD-14-mediated pustular psoriasis; DIRA, deficiency of interleukin-1 receptor antagonist; DITRA, deficiency of interleukin-36 receptor antagonist; ORAS, *OTULIN*-related autoinflammatory syndrome; SAPHO, synovitis, acne, pustulosis, hyperostosis, osteitis; VEXAS, vacuoles, E1 enzyme, X-linked, autoinflammatory, somatic. *Continued*

**RANGE OF CUTANEOUS FINDINGS IN INHERITED AUTOINFLAMMATORY DISEASE**

| | Cutaneous and histologic features | Inherited autoinflammatory disease(s) – examples | | Sporadic or complex disorders with similar findings |
|---|---|---|---|---|
| | | Disorder | Other features† | |
| 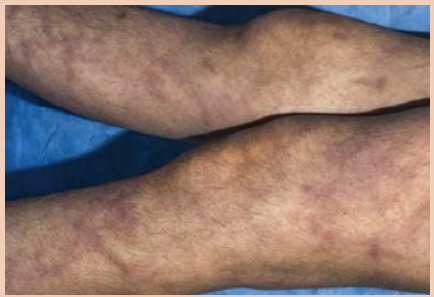 | **Livedo racemosa with nodules** | ADA2 deficiency (pictured) | • Early-onset strokes, HSM, lymphopenia | Sneddon syndrome<br>Sporadic polyarteritis nodosa |
|  | **Violaceous plaques** that resemble pernio, cutaneous LE, or dermatomyositis; periorbital edema & erythema | PRAAS/CANDLE syndrome‡<br>Aicardi-Goutières syndrome (AGS) (pictured)/familial chilblain lupus (FCL)‡ | • PRAAS: lipomuscular atrophy, joint contractures<br>• AGS: encephalopathy, white matter changes, progressive intellectual disability<br>• FCL: arthritis | Lupus erythematosus<br>Dermatomyositis |
|  | **Small papules with dermal granulomatous infiltrate** | Blau syndrome (familial juvenile systemic granulomatosis) (pictured) | • Uveitis, polyarticular arthritis | Sarcoidosis |

‡*Type I interferonopathies; this group also includes SAVI (STING [stimulator of interferon genes]-associated vasculopathy with onset in infancy), which features acral violaceous plaques/ulcers/gangrene/bone resorption and interstitial lung disease. Of note, the violaceous plaques of PRAAS typically have dermal infiltrates of myeloid cells (immature or mature)*

**Table 37.3** *Continued* **Range of cutaneous findings in inherited autoinflammatory diseases.** ADA, adenosine deaminase; CANDLE, chronic atypical neutrophilic dermatosis with lipodystrophy and elevated temperature; PRAAS, proteasome-associated autoinflammatory syndrome. *Continued*



**eFig. 37.1 Still disease.** Evanescent pink papules and plaques in a child. Note the linear array of some of the lesions. *Courtesy, Carlos Nousari, MD.*

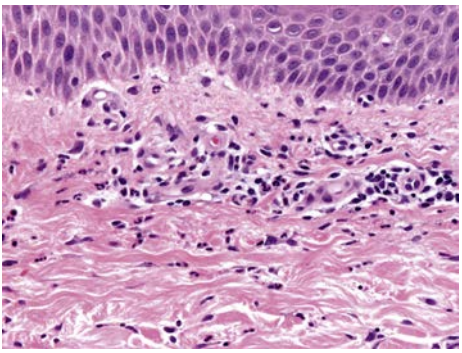

**eFig. 37.2 Adult-onset Still disease – histologic features of evanescent eruption.** There is a mixed perivascular and interstitial infiltrate composed of neutrophils and lymphocytes. *Courtesy, Lorenzo Cerroni, MD.*




**eFig. 37.3 Cutaneous small vessel vasculitis associated with rheumatologic disorders.** The underlying diseases were Sjögren syndrome (**A**) and rheumatoid arthritis (**B**). Note the Koebner phenomenon in **A** and rheumatoid nodules in **B**.

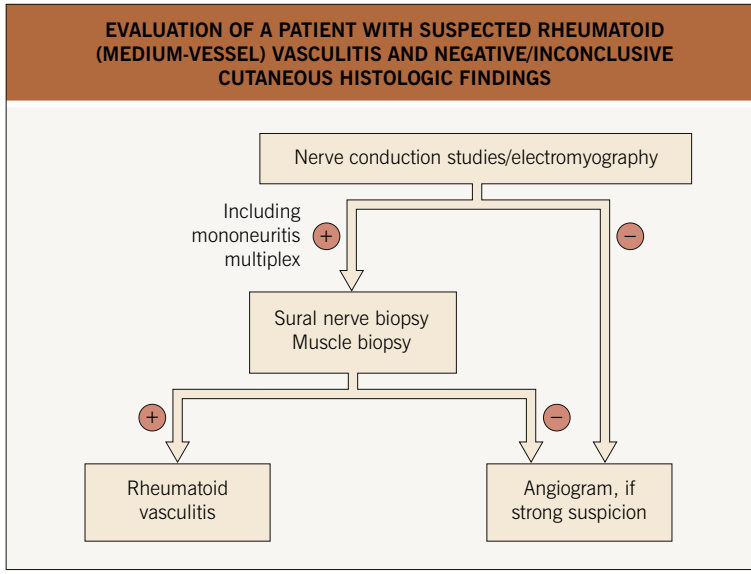


**eFig. 37.4 Evaluation of a patient with suspected rheumatoid vasculitis (involving medium-sized vessels) in whom cutaneous histologic findings are negative or inconclusive.**

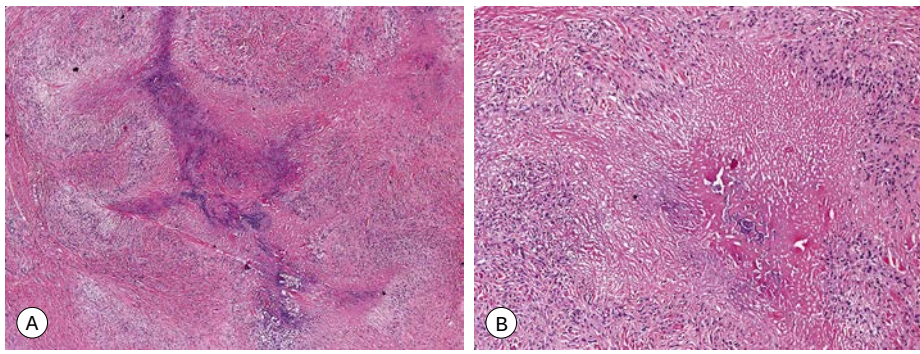


**eFig. 37.5 Rheumatoid nodule – histiologic features. A** Large, irregular area of necrobiosis surrounded by a palisade of histiocytes. **B** Details of necrobiosis and palisade of histiocytes with elongated nuclei. *Courtesy, Lorenzo Cerroni, MD.*



**eFig. 37.6 Hypergammaglobulinemic purpura in a patient with Sjögren syndrome.** Purpuric macules and thin papules are admixed with hemosiderin deposition at previous sites of involvement. *Courtesy, Julie V. Schaffer, MD.*




**eFig. 37.7 Cutaneous manifestations of inherited autoinflammatory disorders. A** A child with deficiency of the interleukin-36 receptor antagonist (DITRA) presenting with widespread psoriasiform plaques whose edges contain pustules (most apparent on the right chest). **B, C** STING (*st*imulator of *in*terferon *g*enes)-associated vasculopathy with onset in infancy (SAVI) is characterized by acral violaceous plaques and resorption of digits and loss of nails; patients may be diagnosed as having vasculitis, antiphospholipid antibody syndrome, Aicardi-Goutières syndrome, or epidermolysis bullosa. **D** CANDLE syndrome with deforming arthritis (e.g. swan neck deformity) and thin pink plaques overlying the metacarpophalangeal joints that resemble dermatomyositis. *A, Courtesy, Antonio Torrelo, MD; B–D, Courtesy, Edward Cowen, MD.*

| CLASSIFICATION OF JUVENILE IDIOPATHIC ARTHRITIS | |
|---|---|
| **Systemic onset** (15–20%) (Still disease) | **Features required for diagnosis**<br>• High episodic fevers – daily for ≥2 weeks and documented to be quotidian for ≥3 days<br>• At least one of the following: *evanescent eruption*, generalized lymphadenopathy, hepatomegaly or splenomegaly, serositis<br>• Symmetric polyarticular arthritis > oligoarticular arthritis (erosive in 20%)*<br>***Other features***<br>• Leukocytosis with neutrophilia, anemia (often severe), thrombocytosis, elevated ESR, elevated ferritin and C-reactive protein levels<br>• Occasionally myocarditis, pneumonitis, anterior uveitis (<1%), CNS involvement, macrophage activation syndrome (~10%); rarely amyloidosis or interstitial lung disease due to pulmonary alveolar proteinosis and/or endogenous lipoid pneumonia (PAP/ELP)<br>• RF- and ANA-negative in >95% of patients |
| **RF-negative polyarticular arthritis** (15%) | • 3–9 years of age<br>• ≥5 joints in the first 6 months<br>• Small joints of the hands & feet > knees, wrists, ankles; erosive arthritis (15%)<br>• RF-negative; ANA-negative |
| **RF-positive polyarticular arthritis** (5%) | • 10–16 years of age<br>• ≥5 joints in the first 6 months<br>• Small joints of the hands & feet > knees, wrists, ankles; erosive arthritis (>50%)<br>• *Rheumatoid nodules*, low-grade fever, mild anemia, weight loss<br>• RF-positive (100%): ≥2 tests at least 3 months apart during first 6 months; ANA-positive (70%) |
| **Oligo/pauciarticular arthritis** (50%):<br>• type I – majority<br>• type II – minority | • ≤4 joints in the first 6 months†<br>• Knees > ankles, wrists; often asymmetric<br>• Type I: 1–8 years of age; uveitis 30–50%; ANA-positive 60%; RF-negative<br>• Type II: 9–16 years of age; HLA-B27; RF-negative; ANA-negative |
| **Enthesitis-related arthritis** (5–10%) | • Arthritis *and* enthesitis<br>- or -<br>• Arthritis *or* enthesitis plus ≥2 of the following: sacroiliac joint tenderness/inflammatory lumbosacral pain, HLA-B27, family history of HLA-B27-associated disease in first- or second-degree relative, acute anterior uveitis, onset of arthritis in a boy after age 6 years |
| **Psoriatic arthritis** (~5%) | • Arthritis and *psoriasis*<br>- or -<br>• Arthritis and ≥2 of the following: dactylitis, *nail pitting, onycholysis*, family history of psoriasis in ≥1 first-degree relative<br>• Other features: anterior uveitis, ANA-negative |
| **Other arthritis** | • Children with arthritis of unknown cause persisting ≥6 weeks that does not fulfill criteria for any other categories or fulfills criteria for more than one category |

**Onset may be delayed for months to years.*
*†The persistent oligoarticular arthritis subtype never affects more than 4 joints, whereas the extended oligoarticular arthritis subtype affects a cumulative total of ≥5 joints after the first 6 months of disease.*

**eTable 37.1 Classification of juvenile idiopathic arthritis.** The previous term was juvenile rheumatoid arthritis. Enthesitis is inflammation at the site of insertion of muscles. For all the types, diagnosis requires onset before 16 years of age and duration of arthritis for ≥6 weeks in at least one joint. RF, rheumatoid factor.

| DIFFERENTIAL DIAGNOSIS OF NASAL DEFORMITY OR DESTRUCTION |
|---|
| **Neoplastic disorders** |
| Nasal natural killer/T-cell lymphoma* |
| Squamous cell and basal cell carcinomas |
| Olfactory neuroblastoma, salivary gland tumors |
| Rhabdomyosarcoma, chondrosarcoma, other sarcomas |
| **Inflammatory disorders** |
| Relapsing polychondritis |
| Granulomatosis with polyangiitis (Wegener granulomatosis) |
| Sarcoidosis |
| SAVI (STING [*st*imulator of *in*terferon *g*enes]-associated vasculopathy with onset in infancy) |
| PLAID (PLCG2-associated antibody deficiency and immune dysregulation) |
| **Infectious disorders** |
| Bacterial |
| Rhinoscleroma |
| Glanders |
| Noma |
| Syphilis (late congenital and tertiary) |
| Yaws (gangosa) |
| Mycobacterial |
| Leprosy |
| Tuberculosis (lupus vulgaris) |
| Fungal |
| Paracoccidioidomycosis > other dimorphic fungal infections |
| Zygomycosis (mucormycosis and entomophthoramycosis) |
| Aspergillosis |
| Parasitic |
| Mucocutaneous leishmaniasis (espundia) |
| Amebiasis due to free-living organisms† |
| Rhinosporidiosis‡ |
| **Other etiologies** |
| Substance abuse (e.g. cocaine) |
| Nasal myiasis |
| Factitious/traumatic, including trigeminal trophic syndrome |

**Previously referred to as angiocentric T-cell lymphoma and lethal midline granuloma.*
*†Include Acanthamoeba spp. and Balamuthia mandrillaris; granulomatous centrofacial skin lesions may lead to fatal amebic encephalitis.*
*‡Characterized by nasal polyps; recent molecular studies have classified the causative organism, Rhinosporidium seeberi, as an aquatic protistan parasite, phylogenetically at the animal–fungus boundary.*

**eTable 37.2 Differential diagnosis of nasal deformity or destruction.**

| XEROSTOMIA – PATIENT INSTRUCTIONS | |
|---|---|
| **General measures** | |
| Avoid smoking cigarettes, cigars | • Smoking exacerbates dryness |
| Reduce intake of salty, spicy and acidic foods | • These foods can exacerbate dryness and cause irritation |
| Limit carbohydrate intake, including sugars | • These foods or drinks increase risk of dental caries |
| Avoid acidic (low pH) drinks | • Examples: cola (pH 2.6), herbal tea (pH varies, but can be as low as 2.5–3), coffee (pH 5)<br>• Acceptable drinks: black tea (pH 5.7–7), tap water (pH 7) |
| Reduce alcohol and caffeine consumption | • They can worsen dryness |
| Avoid excessive sipping | • Can reduce mucous film |
| Avoid OTC antihistamines and decongestants | • Further decrease saliva production |
| Use sodium bicarbonate mouth rinse* twice daily | • Analgesic effects via its buffer action<br>• May improve taste disturbance<br>• Can reduce tendency for oral candidiasis |
| Use a humidifier in bedroom overnight | • Adds moisture to the ambient air |
| **Saliva substitutes (oral moisturizers)** | |
| • Contain various combinations of xylitol, hydroxyethyl cellulose, glycerin and sorbitol; should be alcohol-free and contain fluoride or calcium phosphate<br>• Try different products as they vary in taste, viscosity, feel of lubrication, duration of efficacy; choice based upon patient preference | |
| Spray, e.g. Biotene® Moisturizing Mouth Spray, Oasis® Dry Mouth Moisturizing Spray | • Use prior to speaking and during the day to assist in talking |
| Solution, e.g. Salivart® Oral Moisturizer, Saliva Substitute™ (Roxane) | • Use prior to eating to assist in swallowing and to form food bolus |
| Gel, e.g. Biotene® Oral Balance Gel | • At bedtime |
| Lozenges, e.g. Xylimelts®, ACT® Dry Mouth Lozenges | • Use overnight |
| **Saliva stimulants – sialagogues** | |
| **Local** | |
| Sugar-free**, acid-free gum or candy that contains xylitol | • Should not contain lemon, orange or citric acid<br>• Acceptable examples: Biotene® Dry Mouth Gum<br>• Recaldent®-containing gum may also enhance remineralization, e.g. Trident Xtra Care® |
| Dried fruit slices | • Example: dried peaches |
| **Systemic†** | |
| • Approximately 50% of patients respond<br>• Judge response at 8–12 weeks; at that time point, dosage can be increased<br>• Contraindicated in patients with pulmonary disease (e.g. asthma, bronchiolitis obliterans due to GVHD), narrow angle glaucoma | |
| Pilocarpine (Salagen®) | • 5 mg three times daily |
| Cimevuline (Evoxac®) | • 30 mg three times daily |

**eTable 37.3 Xerostomia patient instructions.** *Continued*

| XEROSTOMIA – PATIENT INSTRUCTIONS | |
|---|---|
| **Dental care** | |
| Avoid toothpastes that contain detergent (e.g. SLS), whiteners, or flavorings if this causes burning | • Whitening toothpastes have abrasives that can be irritating<br>• Acceptable toothpastes: Biotene® PBF Dry Mouth Fluoride Toothpaste |
| Avoid commercial mouthwashes that contain alcohol or peroxide | • Acceptable mouthwashes: Biotene® Dry Mouth Oral Rinse; supersaturated calcium phosphate rinses, e.g. NeutraSal®, Caphosol® |
| Avoid anti-bacterial mouthwashes that contain alcohol or phenol | • Acceptable anti-bacterial mouthwashes: alcohol-free chlorhexidine gluconate mouth rinse USP 0.12% (GUM®) |
| Professional dental cleaning | • 3 to 4 times per year |
| Topical fluorides | • Fluoride rinses, e.g. ACT® Total Care Dry Mouth Rinse<br>• Brush-on fluoride gel (can also be applied in mouth tray 5 minutes/day), e.g. Previ-Dent® 5000 |
| Remineralizing agents, e.g. Seal-Rite™ | • Can be applied by dentist |

**Half teaspoon of sodium bicarbonate in glass of tap water.*
***Not sugarless, as these products may contain fructose.*
*†Also helpful for xerophthalmia.*

**eTable 37.3** *Continued* **Xerostomia patient instructions.** SLS, sodium lauryl sulfate. *Courtesy, Alison Bruce, MD.*

# 38 Mucinoses

In this group of disorders, there is deposition of glycosaminoglycans, previously referred to as mucopolysaccharides ("mucin"), within the skin, especially the dermis. Most often, the deposit is composed of hyaluronic acid. While several of the entities are idiopathic, underlying disorders include autoimmune thyroid disease, a monoclonal gammopathy, diabetes mellitus, and LE.

## Scleredema

- Symmetric diffuse induration of the skin, usually limited to the upper back and posterior neck, that may require palpation to be appreciated; a *peau d'orange* appearance may be present with prominent follicular orifices, and occasionally there is blanching erythema in the sites of involvement (Fig. 38.1).
- While scleredema is often asymptomatic, some patients may complain of tightness or decreased range-of-motion; occasionally there is also involvement of the face and upper extremities and, rarely, the muscles, eyes, or heart.



**Fig. 38.1 Scleredema in association with diabetes mellitus.** Diffuse induration of the upper back and neck with overlying erythema. *Courtesy, USCDRSC.*

- The three major types have different associations: type I – preceding streptococcal infections; type II – monoclonal gammopathy; and type III – diabetes mellitus, with men representing the majority of patients.
- **DDx:** systemic sclerosis (diffuse form), scleromyxedema, and other sclerodermoid disorders (see Table 35.5); occasionally, cellulitis if erythema is present.
- **Rx:** sometimes there is spontaneous resolution, especially with type I disease, but control of underlying diabetes mellitus usually does not lead to improvement; anecdotal therapies include phototherapy (UVA1, PUVA), methotrexate, electron beam therapy, IVIg, and multiple myeloma therapies (e.g. bortezomib) if there is an associated monoclonal gammopathy.

## Scleromyxedema/Papular Mucinosis

- A spectrum of clinical findings that varies from multiple linear arrays of firm, 2- to 3-mm, waxy, skin-colored papules (Fig. 38.2) to diffuse induration of the skin with thickened folds, including leonine facies (Fig. 38.3; Table 38.1); involvement is symmetric and often widespread.
- Associated with an underlying monoclonal gammopathy; in addition to skin stiffness, there can be decreased range-of-motion of joints and contractures as well as myositis, peripheral neuropathy, and encephalopathy (dermato-neuro syndrome).
- **DDx:** systemic sclerosis, scleredema; if primarily papules are present, primary systemic amyloidosis, lipoid proteinosis, and especially the various types of skin-limited (localized) mucinoses, e.g. acral persistent papular mucinosis, the discrete papular form of lichen myxedematosus, self-healing cutaneous mucinosis (also has nodules).
- **Rx:** similar to that of multiple myeloma (see primary systemic amyloidosis, Ch. 39),

systemic retinoids, phototherapy (UVA1, PUVA), IVIg.

## Pretibial Myxedema

- In the vast majority of patients, associated with hyperthyroidism which is primarily due to Graves disease, an autoimmune disorder with circulating anti-thyroid-stimulating hormone receptor autoantibodies; skin lesions may appear following treatment of the thyroid disease, i.e. when the patient is euthyroid or has developed hypothyroidism.
- Favors the shins but can involve the foot and presents as indurated, waxy nodules or plaques that vary from skin-colored to red-brown (Fig. 38.4); prominent follicular openings may be seen (a *peau d'orange* appearance) and occasionally elephantiasis develops.
- Additional clinical findings include exophthalmos, goiter, and thyroid acropachy.
- **DDx:** obesity-associated lymphedematous mucinosis (no history of hyperthyroidism), lymphedema, lipedema, lichen amyloidosis.




**Fig. 38.2 Scleromyxedema/papular mucinosis. A, B** Numerous monomorphic, firm, skin-colored to tan papules which can have a striking linear arrangement. This is most obvious on the upper posterior neck. **C** The skin can also become shiny and indurated, leading to a sclerodermoid appearance, but the small firm papules in a linear array are a clue to the diagnosis. *A,B, Courtesy, Edward Cowen, MD; C, Courtesy, Lorenzo Cerroni, MD.*

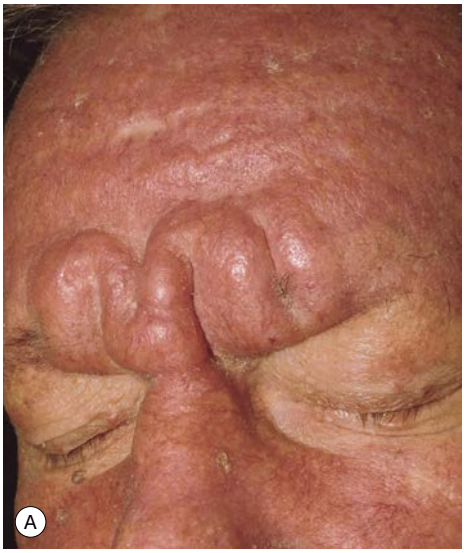





**Fig. 38.3 Scleromyxedema.** Thickening of the skin of the forehead **(A)** and trunk **(B)**, leading to deep furrows and folds. Scleromyxedema is one of the causes of leonine facies. *A, Courtesy, Joyce Rico, MD; B, Courtesy, Lorenzo Cerroni, MD.*

| LEONINE FACIES – ASSOCIATED DERMATOLOGIC DISEASES |
|---|
| • Scleromyxedema/papular mucinosis |
| • Lepromatous leprosy |
| • Leishmaniasis |
| • Cutaneous lymphoma (T-cell, B-cell) |
| • Actinic reticuloid form of chronic actinic dermatitis |
| • Leukemia cutis |
| • Primary systemic amyloidosis |
| • Pachydermoperiostosis |
| • Lipoid proteinosis |

**Table 38.1 Leonine facies – associated dermatologic diseases.** Additional causes include sarcoidosis, mastocytosis, multicentric reticulohistiocytosis, and progressive nodular histiocytosis.

• **Rx:** although lesions may clear spontaneously over a period of several years, treatment of the underlying thyroid disease usually has no effect; anecdotal therapies include topical and intralesional CS, surgical shave removal, and for severe disease, IVIg, rituximab, octreotide, and plasmapheresis. Compression stockings and pneumatic compression can be used for associated lymphedema.



**Fig. 38.4 Pretibial myxedema.** Purple-brown plaques on the shins of a patient with Graves disease. A *peau d'orange* appearance is present due to prominent follicular openings. *Courtesy, Franco Rongioletti, MD, and Alfredo Rebora, MD.*

## Generalized Myxedema

• As a result of profound hypothyroidism, the skin is diffusely dry, cool, and pale, with a waxy appearance; the hair and nails can be brittle, leading to a diffuse non-scarring alopecia of the scalp and alopecia of the lateral eyebrows.
• Additional mucocutaneous findings include eczema craquelé, acquired ichthyosis, carotenoderma, and a puffiness of the hands and the face, including the eyelids; the tongue may be enlarged.
• In the congenital form, developmental delay, stunted growth, poor muscle tone, constipation, somnolence and a large fontanelle are characteristic findings.
• Because the most common underlying disease in adults is Hashimoto thyroiditis, women are more commonly affected; in addition to the skin changes outlined above, patients may gain weight, have cold intolerance and constipation, feel sluggish, and can occasionally develop cutaneous xanthomas.
• **Rx:** thyroid hormone replacement.



**Fig. 38.5 Self-healing cutaneous mucinosis.** Pink to skin-colored dermal and subcutaneous nodules as well as periorbital swelling. *Courtesy, Drs. Hansgeorg Müller and Heinz Kofler.*

## Self-Healing Cutaneous Mucinosis

- Acute eruption of multiple firm papules and nodules favoring the face (especially the forehead and periorbital region), scalp, and periarticular areas (Fig. 38.5).
- No underlying disorder and characterized by spontaneous resolution over months to years.

## Reticular Erythematous Mucinosis (REM)

- Persistent erythematous papules of the central chest and central back that can form a net-like pattern and/or coalesce into plaques (Fig. 38.6); may be photo-aggravated.
- Overlaps with LE tumidus, lymphocytic infiltrate of Jessner (minimal to no dermal mucin), and papulonodular mucinosis (see below).
- **Rx:** topical or intralesional CS, antimalarials (hydroxychloroquine, chloroquine), sunscreens.

## Cutaneous Lupus Mucinosis/ Papulonodular Mucinosis (of Gold)

- Occurs in the setting of autoimmune connective tissue diseases, with LE >> dermatomyositis or systemic sclerosis; ~75% of patients with LE who develop these lesions have systemic involvement.
- Skin-colored to erythematous papules and nodules that may require side-lighting to appreciate; favors the back, central chest, and upper extremities (Fig. 38.7).
- Overlaps with LE tumidus, reticular erythematous mucinosis, and lymphocytic infiltrate of Jessner (minimal to no dermal mucin).
- **Rx:** antimalarials (hydroxychloroquine, chloroquine), topical or intralesional CS, sunscreens.



**Fig. 38.6 Reticular erythematous mucinosis (REM).** Grouped pink papules on the central chest with no surface changes; there is a subtle annular and reticulated configuration. Note the significant tan. *Courtesy, YDRSC.*



**Fig. 38.7 Cutaneous lupus mucinosis/ papulonodular mucinosis.** Skin-colored papules and nodules leading to a "lumpy" appearance to the skin that is best appreciated by side-lighting. *Courtesy, Franco Rongioletti, MD, and Alfredo Rebora, MD.*

## Follicular Mucinosis (Alopecia Mucinosis)

- In contrast to the other disorders in this chapter, here the mucin is deposited within the epithelium of hair follicles rather than in the dermis.
- In the primary form, there are pink to violet-brown plaques, primarily in the head and neck region, that have associated alopecia and sometimes scale (Fig. 38.8A); in some patients, there are grouped follicular papules (Fig. 38.8B), and in patients with darkly pigmented skin, lesions may be hypopigmented.
- The primary form most commonly occurs in children and young adults and represents a benign, self-limited disease; in older adults, especially when the lesions are more widespread and persistent, the possibility of co-existing mycosis fungoides needs to be considered.
- In addition to the characteristic histopathologic finding of mucin deposition within the follicular epithelium, it is important to comment on the presence or absence of atypical lymphocytes.
- **DDx:** cutaneous LE, tinea faciei or capitis, facial discoid dermatosis, various forms of dermatitis; if diagnosed histologically, consider the possibility it represents an incidental finding (e.g. associated with atopic dermatitis).
- **Rx:** for primary, observation until spontaneous resolution, topical or intralesional CS, antimalarials; if associated with mycosis fungoides, treat the latter (see Ch. 98).

## Other Entities

Digital mucous cyst is covered in Chapter 90. Cutaneous mucin deposits can also be seen within tumors (e.g. basal cell carcinomas, cutaneous metastases) and inflammatory disorders (e.g. granuloma annulare, cutaneous LE, dermatomyositis).




**Fig. 38.8 Follicular mucinosis. A** Pink plaque containing follicular papules in a young boy. **B** Grouped follicular papules on the leg of an older adult in association with violet-brown plaques; note the associated alopecia. The hemorrhagic crust is the site of a previous biopsy. *A, Courtesy, Lorenzo Cerroni, MD; B, Courtesy, YDRSC.*

For further information see Ch. 46 from *Dermatology, Fourth Edition*.

**For additional online figures visit www.expertconsult.com**

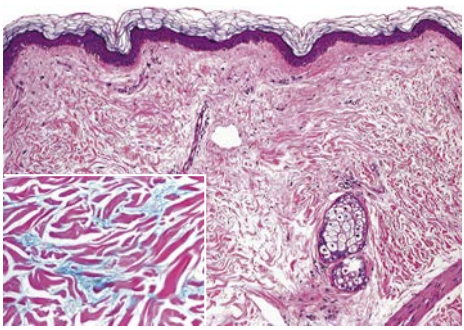

**eFig. 38.1 Scleredema – histopathologic features.** Slightly separated collagen bundles and normal dermal cellularity. Inset: Mucin deposits between collagen bundles. *Courtesy, Lorenzo Cerroni, MD.*



**eFig. 38.3 Scleromyxedema.** Thickening of the skin of the trunk**,** leading to deep furrows and folds. *Courtesy, Joyce Rico, MD.*

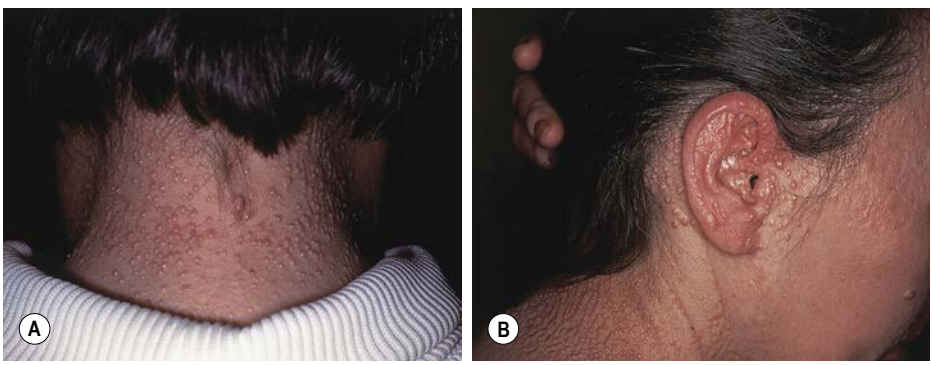


**eFig. 38.2 Scleromyxedema/papular mucinosis. A, B** Numerous monomorphic, firm, skin-colored papules which can have a linear arrangement (most obvious on the upper back). *Courtesy, YDRSC.*



**eFig. 38.4 Localized lichen myxedematosus – discrete papular type.** Persistent whitish papules on the arms. *Courtesy, Franco Rongioletti, MD, and Alfredo Rebora, MD.*



**eFig. 38.5 Acral persistent papular mucinosis.** Skin-colored to tan papules on the dorsal aspect of the hands. *Courtesy, Franco Rongioletti, MD, and Alfredo Rebora, MD.*



**eFig. 38.6 Cutaneous mucinosis of infancy.** Skin-colored papules on the back of the neck in a young girl. *Courtesy, Franco Rongioletti, MD.*



**eFig. 38.7 Generalized myxedema in an adult with hypothyroidism.** The face is puffy with a dull expression and the hair is dry. *Courtesy, Franco Rongioletti, MD, and Alfredo Rebora, MD.*



**eFig. 38.8 Reticular erythematous mucinosis (REM).** Grouped pink papules on the central chest and upper abdomen. No surface changes are present and there is a reticulated configuration. *Courtesy, Lorenzo Cerroni, MD.*



**eFig. 38.9 Follicular mucinosis.** Skin-colored papules on the cheek of a child. *Courtesy, Julie V. Schaffer, MD.*

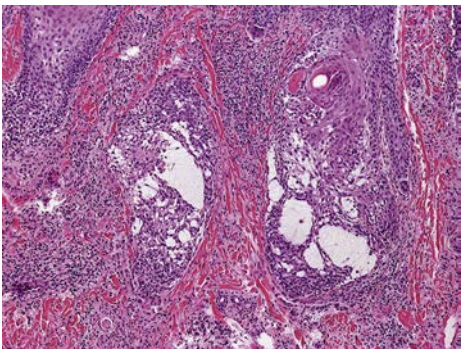

**eFig. 38.10 Follicular mucinosis – histopathologic features.** Mucin deposition (wispy) within the follicular epithelia. *Courtesy, Lorenzo Cerroni, MD.*

# 39 Amyloidosis

Amyloidosis encompasses a wide range of disorders, several of which have cutaneous manifestations. The common thread is the formation of extracellular deposits that are composed of a β-pleated sheet by X-ray crystallography. In general, amyloid deposits exhibit a red color with Congo red stain and demonstrate birefringence (apple green color) under polarized light. Precursor proteins of amyloid vary from keratin to immunoglobulin (Ig) light chains to transthyretin. If necessary, tandem mass spectrometry can be performed to characterize the specific protein.

In dermatology, the initial distinction is between amyloidosis that is systemic versus skin-limited (Fig. 39.1). The former is less common than the latter.

## Systemic Amyloidosis

- *Primary systemic amyloidosis* is due to a plasma cell dyscrasia, but most patients do not fulfill the criteria for symptomatic multiple myeloma (≥10% plasma cells in a bone marrow biopsy *plus* bone lesions, anemia, hypercalcemia, and/or renal disease); the precursor protein is almost always Ig light chains (AL; lambda > kappa) rather than Ig heavy chains (AH).
- Firm, skin-colored to pink to yellow-brown, waxy papules or plaques occur most commonly on the face (Fig. 39.2); infiltration of the tongue can lead to macroglossia (Fig. 39.3), and occasionally there is diffuse waxy induration of the skin (sclerodermoid

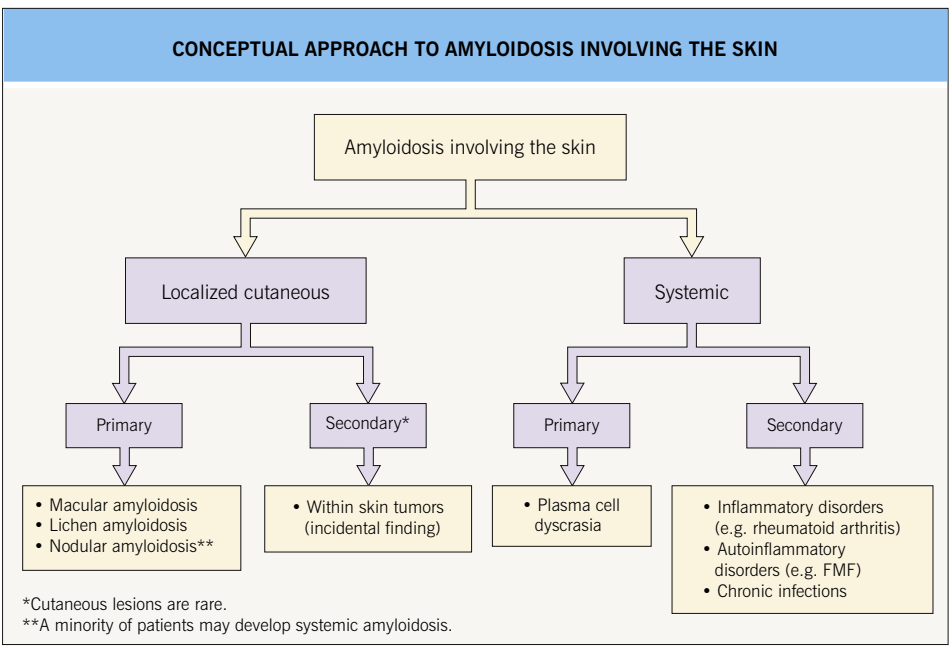


**Fig. 39.1 Conceptual approach to amyloidosis involving the skin.** FMF, familial Mediterranean fever.



**Fig. 39.2 Primary systemic amyloidosis.** **A** Numerous waxy translucent facial papules. Some have a yellow to yellow-brown color. **B** Some of the waxy papules have become purpuric, but this may be difficult to appreciate because of the pigmentation of the skin (compare to Fig. 39.4); the periorbital region is a characteristic site of involvement. *A, Courtesy, Jean L. Bolognia, MD; B, Courtesy, Judit Stenn, MD.*



**Fig. 39.3 Primary systemic amyloidosis.** **A** Macroglossia with dental impressions on the tongue. **B** Papulonodules of the tongue; some are purpuric while others are translucent with a yellowish hue. The combination of macroglossia plus carpal tunnel syndrome is a classic clinical presentation. *A, Courtesy, YDRSC; B, Courtesy, Dennis Cooper, MD.*

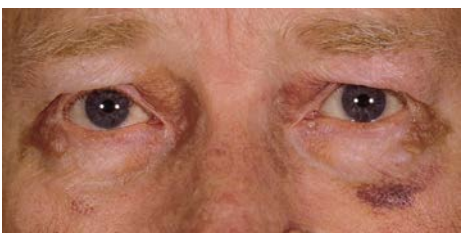

**Fig. 39.4 Primary systemic amyloidosis.** Purpura and yellow-brown plaques in a periorbital distribution. *Courtesy, Joyce Rico, MD.*

presentation); purpura due to trauma or pinching of the skin can also be seen and is due to the fragility of blood vessels surrounded by amyloid deposits (Fig. 39.4).

- *Secondary systemic amyloidosis* develops in the setting of chronic inflammation, e.g. rheumatoid arthritis, tuberculosis, and in several autoinflammatory disorders (see Ch. 37); the precursor protein is (apo) serum AA, which is produced by the liver; cutaneous lesions rarely occur.
- Amyloid deposits can also lead to a restrictive cardiomyopathy and congestive heart failure as well as renal dysfunction, especially nephrotic syndrome (Fig. 39.5).
- Histologically, cutaneous papules are composed of dermal deposits of amyloid while clinically uninvolved skin (abdominal fat) can show perivascular deposits of amyloid; serum protein electrophoresis (SPEP) and immunofixation electrophoresis (IFE) aid in identifying a gammopathy, but the serum free light-chain assay is the most sensitive test available and the presence of monoclonal free light chains in the blood or urine is required to establish the diagnosis.
- **DDx:** for facial papules, mucinoses, multiple adnexal tumors, colloid milium, lipoid proteinosis (see Fig. 91.16).
- **Rx:** for primary systemic amyloidosis, it is similar to myeloma, e.g. dexamethasone, melphalan, bortezomib or carfilzomib,

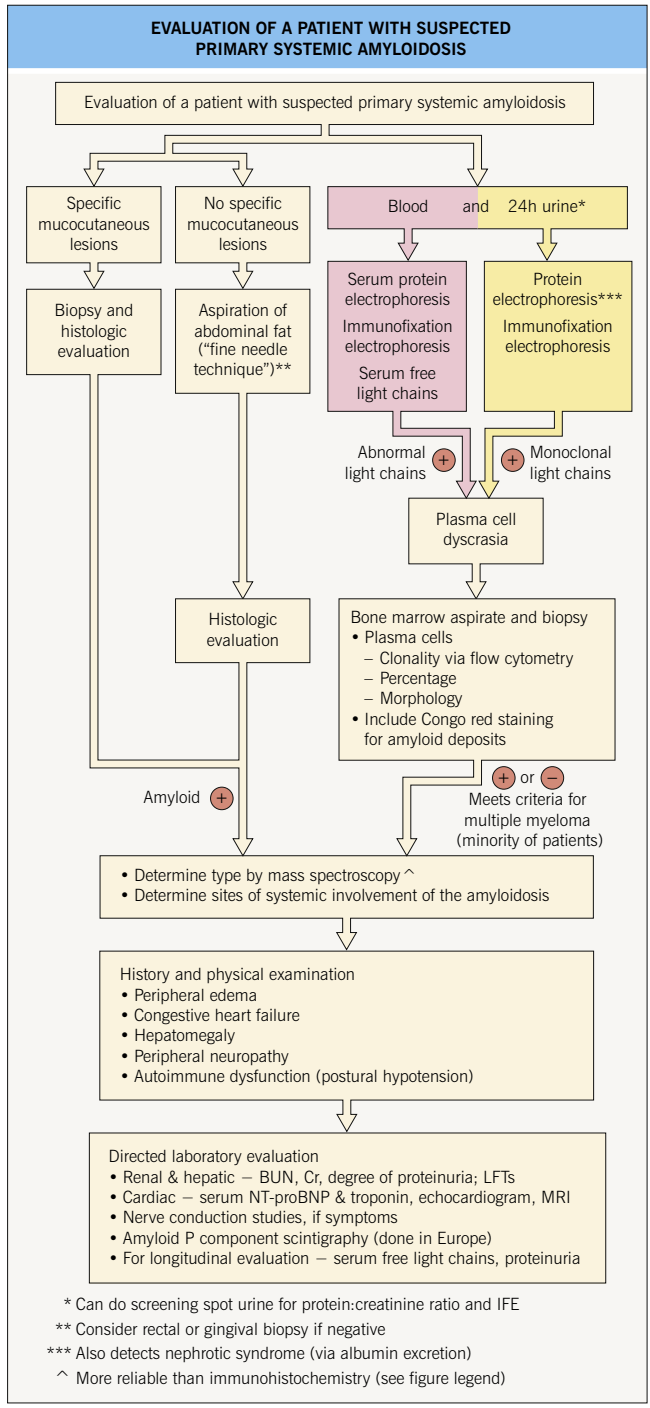


**Fig. 39.5 Evaluation of a patient with suspected primary systemic amyloidosis.** Because the amyloid is formed from immunoglobulin light chains, an abnormality of light chains in the blood or urine (e.g. increased concentration or abnormal ratio in the blood, positive immunofixation electrophoresis [IFE] of the urine) is required for diagnosis. Mass spectroscopy has become more routine given the potential for misdiagnosis of older patients with wild-type ATTR deposits in the heart or ALect2 deposits in the kidney and liver in the setting of a monoclonal gammopathy of unknown significance. NT-proBNP, N-terminal pro-brain natriuretic peptide.

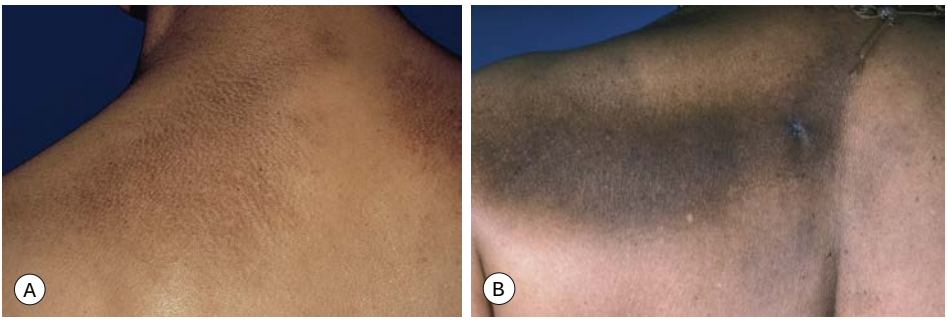

**Fig. 39.6 Macular amyloidosis (primary localized cutaneous amyloidosis). A** Characteristic rippled hyperpigmentation on the upper back. **B** Occasionally, a linear accentuation is seen. *Courtesy, Richard W. Groves, MD, and Martin M. Black, MD.*



**Fig. 39.7 Lichen amyloidosis (primary localized cutaneous amyloidosis).** **A** Numerous monomorphic papules on the shin. The rippled appearance is most obvious laterally. **B** Keratotic, hyperpigmented papules and linear plaques on the shin. *A, Courtesy, YDRSC; B, Courtesy, St. John's Institute of Dermatology.*

lenalidomide or pomalidomide, daratumumab, hematopoietic stem cell transplant (for younger patients).

## Localized Cutaneous Amyloidosis

- The three major forms of *primary* localized cutaneous amyloidosis are macular, lichen, and nodular amyloidosis (see Fig. 39.1); an overlap of the first two forms is referred to as biphasic because these two entities exist on a spectrum.
- Both *macular* and *lichen amyloidosis* are due to rubbing, scratching, or friction and have a rippled appearance as well as hyperpigmentation; the macular form favors the upper back of adults while the lichenoid form favors the extensor surfaces of the extremities, primarily the anterolateral shins, and has a palpable component (Figs 39.6 and 39.7).

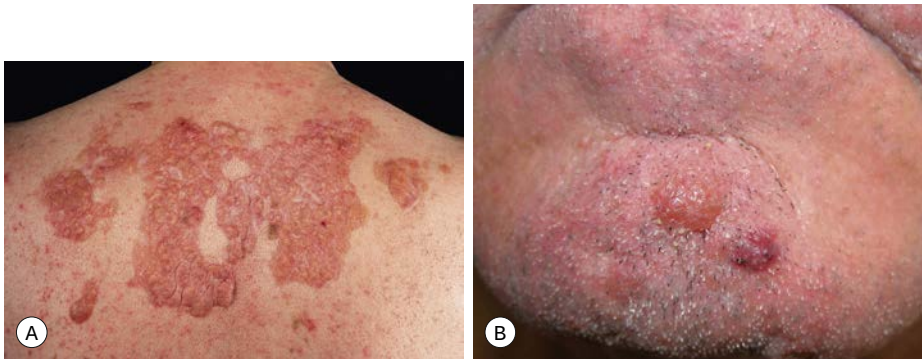


**Fig. 39.8 Nodular amyloidosis. A, B** Firm waxy plaques and nodules on the back and chin. The color can vary from skin-colored to pink-yellow to violaceous. *A, Courtesy, Richard W. Groves, MD, and Martin M. Black, MD; B, Courtesy, YDRSC.*

- Both forms occur more commonly in individuals with skin phototypes III and IV; cutaneous amyloidosis of the upper back is seen in patients with Sipple syndrome (multiple endocrine neoplasia [MEN] type 2A), but with an onset during childhood.
- In patients with familial primary cutaneous amyloidosis, mutations in three genes have been detected which encode the following proteins: (1) oncostatin M receptor β (a component of the IL-31 receptor); (2) the α subunit of the IL-31 receptor; and (3) GPNMB (dyschromic form in Asians); of note, IL-31 plays a role in pruritus.
- The precursor protein for both macular and lichen amyloidosis is keratin, presumably from nearby keratinocytes; deposits of amyloid in the upper dermis can be subtle, especially in the macular form, and stain positively with anti-keratin antibodies.
- *Nodular amyloidosis* presents as one or more waxy skin-colored to pink-orange plaques or nodules, most commonly on the trunk or extremities (Fig. 39.8); the precursor protein is Ig light chains ± $\beta_2$-microglobulin, thought to be produced by cutaneous infiltrates of plasma cells.
- A minority of patients with nodular amyloidosis may develop systemic amyloidosis, so longitudinal evaluation is recommended.
- Occasionally, deposits of amyloid are seen in cutaneous tumors, e.g. basal cell carcinomas, dermatofibromas, intradermal melanocytic nevi, as an inconsequential *secondary* phenomenon.
- **DDx:** back – notalgia paresthetica, lichen simplex chronicus (LSC) with postinflammatory hyperpigmentation; lower extremity – LSC, hypertrophic lichen planus, pretibial myxedema; nodular – cutaneous lesions of systemic amyloidosis, pretibial myxedema, cutaneous lymphoma, BCC.
- **Rx:** difficult; can try topical antipruritics, e.g. pramoxine, topical or intralesional CS; physical coverings, e.g. zinc oxide-impregnated gauze (Unna boot) or hydrocolloid dressings, can lead to improvement but recurrences common when discontinued.

For further information see Ch. 47 from *Dermatology, Fourth Edition*.

**For additional online figures visit www.expertconsult.com**

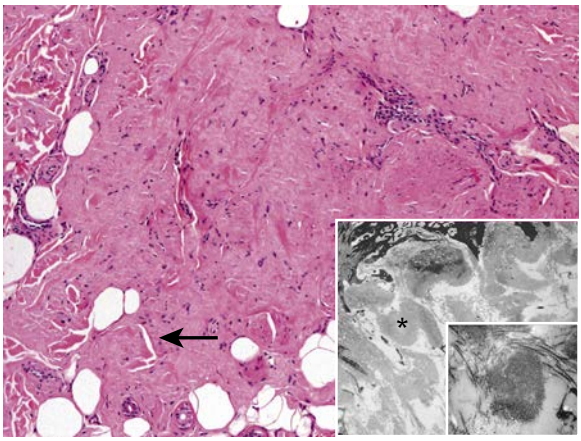

**eFig. 39.1 Histopathologic features of amyloid deposits within the skin.** In this example of nodular amyloidosis, the dermal deposits are eosinophilic, amorphous, and contain fissures (arrow). By electron microscopy, there are clusters of filamentous deposits (*) and 7–10-nm non-branching fibrils (inset). *Courtesy, Lorenzo Cerroni, MD, and St. John's Institute of Dermatology.*

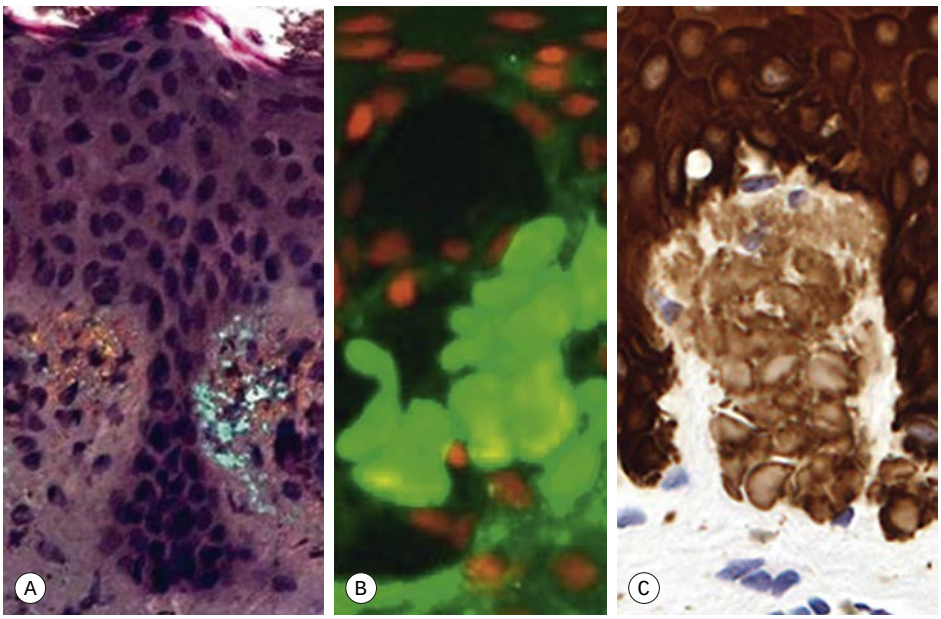


**eFig. 39.2 Use of special stains to identify amyloid deposits within the papillary dermis in lichen amyloidosis. A** With a Congo red stain, there is characteristic green birefringence with polarized light; the color can vary from yellow-green to blue-green. **B** With a thioflavin T stain, amyloid deposits stain brightly with ultraviolet fluorescence microscopy. **C** Positive immunohistochemical stain for keratin (MNF 116, broad-spectrum anti-keratin antibody). *A, B, Courtesy, St. John's Institute of Dermatology; C, Courtesy, Jennifer McNiff, MD.*

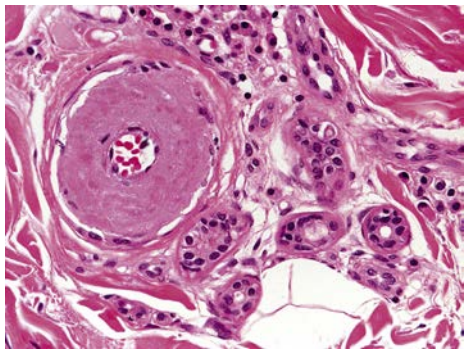

**eFig. 39.3 Primary systemic amyloidosis – histopathologic features.** Amyloid deposits are seen in a perivascular location. *Courtesy, Lorenzo Cerroni, MD.*

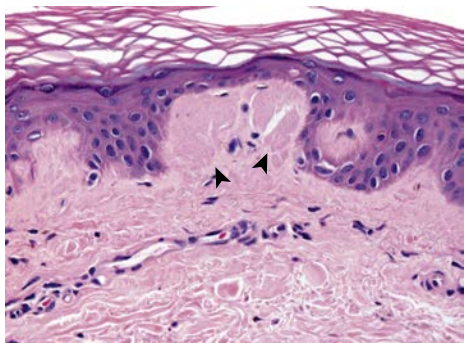

**eFig. 39.4 Macular amyloidosis.** Deposits of amyloid (arrowheads) as well as melanophages are present within the papillary dermis. Note the characteristic fissure in the amyloid deposit. These deposits may be subtle. *Courtesy, Lorenzo Cerroni, MD.*



**eFig. 39.5 Lichen amyloidosis.** Keratotic hyperpigmented papules in a rippled pattern (see inset). The shin is the most common location for this form of primary localized cutaneous amyloidosis. *Courtesy, St. John's Institute of Dermatology.*

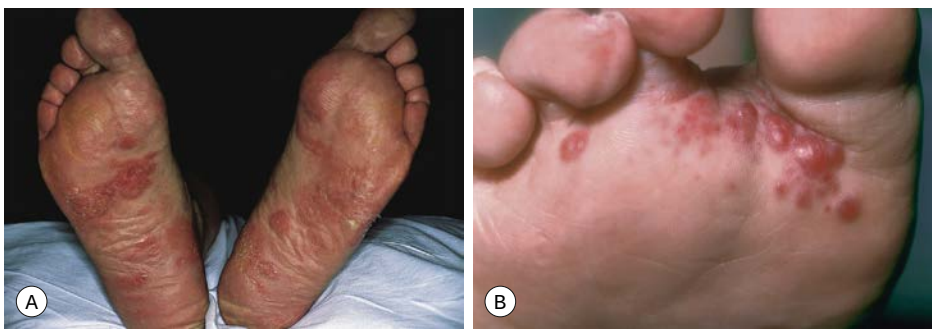


**eFig. 39.6 Nodular amyloidosis involving the feet. A, B** Firm pink plaques and papulonodules on the plantar surfaces. *A, Courtesy, YDRSC; B, Courtesy, Richard W. Groves, MD.*

# Deposition Disorders 40

A heterogeneous group of disorders in which there are deposits, usually of endogenous materials, within the skin. Entities belonging to this group that are covered in other chapters include mucinoses (Ch. 38), amyloidosis (Ch. 39), porphyrias (Ch. 41), and calcinosis cutis (Ch. 42).

## Gout

- Metabolic disorder in which there is hyperuricemia due to increased production and/or decreased excretion of uric acid; often idiopathic but secondary causes include chronic kidney disease and medications such as diuretics or cyclosporine; affects primarily adult men.
- Crystals of monosodium urate can deposit within the skin (tophi) as well as the joints and kidneys; when expressed from the skin or aspirated from the joints, the crystals are needle-like and exhibit negative birefringence under polarized light.
- Tophi present as firm, skin-colored to white or yellow papules and nodules, usually around joints and on the helices of the ears (Figs 40.1 and 40.2); in general, they appear ~10 years after the initial episode of acute arthritis and occur in ~10% of patients with gout.
- Tophi can become inflamed (Fig. 40.3), and they may or may not resolve following normalization of serum uric acid levels.
- **DDx:** rare cutaneous involvement in pseudogout (rhomboid crystals) as well as calcinosis cutis, xanthomas, and rheumatoid nodules. Significant associated inflammation may lead to the misdiagnosis of cellulitis.
- **Rx** for tophi: diet, allopurinol, febuxostat; for refractory disease, pegloticase.

## Lipoid Proteinosis

- Autosomal recessive disease due to loss-of-function mutations in *ECM1*, which encodes extracellular matrix protein 1; the result is deposition of hyalin-like material in multiple sites, in particular the brain (seizures) and larynx (hoarseness), as well as the skin and oral mucosa.
- Skin-colored to yellowish waxy papules and nodules favor the face, including the eyelid margin, and the tongue (Fig. 40.4); atrophic scarring, verrucous changes (especially on the elbows and knees), and a diffuse waxy appearance are additional findings; during infancy, fragility, vesicles, and crusting of the face, extremities, and mouth can occur.
- **DDx:** mucinoses, erythropoietic protoporphyria, primary systemic amyloidosis, colloid milium, and in infants, hyaline fibromatosis syndrome (see Ch. 81).

## Colloid Milium

- Two major variants – inherited juvenile form and acquired adult form; because the latter is related to cumulative photodamage, it occurs primarily in adults with lightly pigmented skin.



**Fig. 40.1 Tophaceous gout of a digit.** The deposits create a multilobulated appearance. A small incision over the yellow-white areas followed by microscopic examination of the expressed material would allow a bedside diagnosis. *Courtesy, YDRSC.*

• Dermal deposits lead to dome-shaped, translucent to yellowish papules in chronically sun-exposed sites, in particular the face, ears, posterior neck, and dorsal aspect of the



**Fig. 40.2 Severe tophaceous gout of a digit leading to a multilobulated appearance.** Some of the yellow papules have become erythematous due to associated inflammation. *Courtesy, YDRSC.*



**Fig. 40.3 Tophaceous gout of the tragus.** The erythema reflects surrounding inflammation. *Courtesy, Harald Gollnick, MD.*




**Fig. 40.4 Lipoid proteinosis. A** Beaded eyelid papules, hemorrhagic crusts, and confluent waxy papules of the glabella leading to an early leonine facies. **B** A firm tongue with numerous tiny papules on its dorsal surface. **C** Characteristic verrucous changes of the elbow. **D** Multiple, round hypopigmented and depressed scars on the shoulder. *A, Courtesy, NYUDSC; B, D, Courtesy, Julie V. Schaffer, MD; C, Courtesy, Judit Stenn, MD.*

distal extremities; the lesions can become nodular or even pigmented if topical agents such as hydroquinone have been applied.

- **DDx:** similar to that of lipoid proteinosis (see above).
- **Rx:** laser, cryosurgery.

## Mucopolysaccharidoses (MPS)

- Group of inherited metabolic disorders in which there is an accumulation of glycosaminoglycans (GAGs; previously referred to as mucopolysaccharides) due to deficiencies in lysosomal enzymes that break down sulfated GAGs (e.g. heparan sulfate, dermatan sulfate).
- The accumulation of GAGs can lead to intellectual disability, hepatosplenomegaly, skeletal and joint disease, corneal clouding, and a coarse facies; in addition to thickening of the skin, some patients have hypertrichosis; in Hunter syndrome (MPS II), grouped skin-colored to white papules can develop in the scapular region ("pebbling"), and in both Hurler syndrome (MPS I) and Hunter syndrome, patients may have extensive dermal melanocytosis.
- Following measurement of urinary GAGs and examination of peripheral leukocytes for vacuoles, genetic analyses can be performed.
- **Rx:** for several of the types (MPS I, II, IVA, VI, VII), enzyme replacement therapy is available; hematopoietic stem cell transplant is another option.

For further information see Ch. 48 from *Dermatology, Fourth Edition*.

**For additional online figures visit www.expertconsult.com**

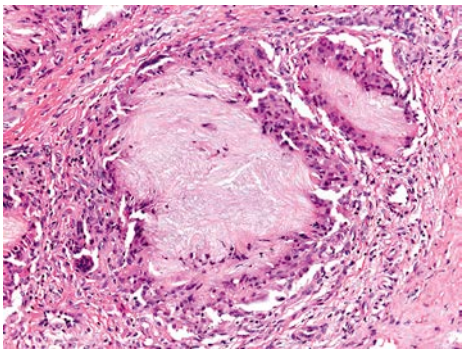

**eFig. 40.1 Tophaceous gout – histopathologic features.** Deposits of amorphous, acellular material within the dermis. Histiocytes and multinucleated giant cells surround the deposits. *Courtesy, Lorenzo Cerroni, MD.*




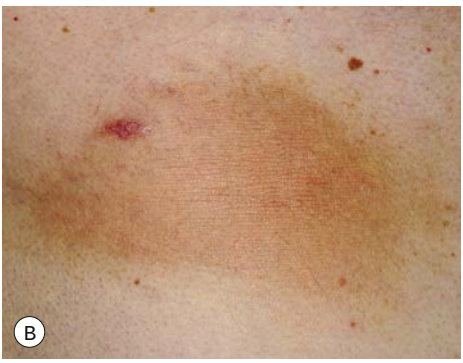


**eFig. 40.2 Lipoid proteinosis. A** Skin-colored papulonodules of the elbow as well as irregular hypopigmented scars of the extensor forearm. **B** Waxy, yellowish plaque on the back. *Courtesy, Julie V. Schaffer, MD*

# 41 Porphyrias

The porphyrias represent a group of metabolic disorders in which there is dysfunction of the enzymes involved in heme synthesis (Fig. 41.1). With the exception of acquired porphyria cutanea tarda (PCT), the underlying etiology is monogenetic mutations. Porphyrins absorb light energy (400–410 nm) and their accumulation within the skin can lead to photosensitization, with water-soluble porphyrins producing blisters and lipophilic porphyrins leading to acute burning and erythema. This chapter focuses on those porphyrias with cutaneous manifestations.

## Porphyria Cutanea Tarda (PCT)

- The most common form of cutaneous porphyria; clinical findings typically appear during the 3rd to 4th decade of life.
- Dysfunction of uroporphyrinogen decarboxylase (UD) is usually acquired (type I) but can be inherited in an autosomal dominant manner (type II); the ratio of type I : type II is ~3 : 1.
- In type I PCT, the enzyme is only dysfunctional in the liver, rather than in all tissues; hepatotoxins (e.g. alcohol, iron overload), hepatitis C virus or HIV infection, and estrogens can precipitate or exacerbate PCT.
- In addition to photosensitivity, characteristic skin findings include fragility, erosions, vesiculobullae, milia, and scars in sun-exposed areas, especially on the dorsal aspects of the hands (Fig. 41.2); hypertrichosis (malar region) and hyperpigmentation can develop on the face (Fig. 41.3); a sclerodermoid appearance or morpheaform plaques are seen less often (Fig. 41.4).
- Histologically, if a bulla is biopsied, there is a subepidermal split with minimal inflammation; thickened basement membranes around capillaries in the dermis with festooning of the dermal papillae are also seen.
- Diagnosis is based on the detection of elevated levels of *urinary* uro- and coproporphyrins (water-soluble; Table 41.1) or elevated plasma uroporphyrins or fecal isocoproporphyrins; genetic analysis can be performed for type II PCT.
- Additional evaluation includes serum ferritin and if elevated, analysis of the hemochromatosis gene; screening for hepatitis B or C viral infection; and if risk factors, HIV infection.
- **DDx:** pseudoporphyria due to medications (Table 41.2) or in patients with chronic kidney disease and those undergoing dialysis; phototoxic drug eruption; epidermolysis bullosa acquisita (sites of trauma but not limited to sun-exposed sites); rare forms of porphyria with similar cutaneous findings plus neurologic manifestations similar to acute intermittent porphyria (AIP) – variegate porphyria (see below) and hereditary coproporphyria (elevated coproporphyrins in feces consistently and in urine when symptomatic) – and mild forms of congenital erythropoietic porphyria.
- **Rx:** photoprotection via clothing and sunscreens containing titanium dioxide and zinc oxide (blocks visible light); avoidance of exacerbating factors; phlebotomy, initially 500 ml every 2–3 weeks, depending on the hematocrit; oral antimalarials, but at much lower doses than are used for cutaneous LE, i.e. hydroxychloroquine 200 mg *twice weekly*.
- In the setting of chronic kidney disease or renal dialysis and the associated anemia, the inability to use phlebotomy and/or antimalarials limits therapeutic options.

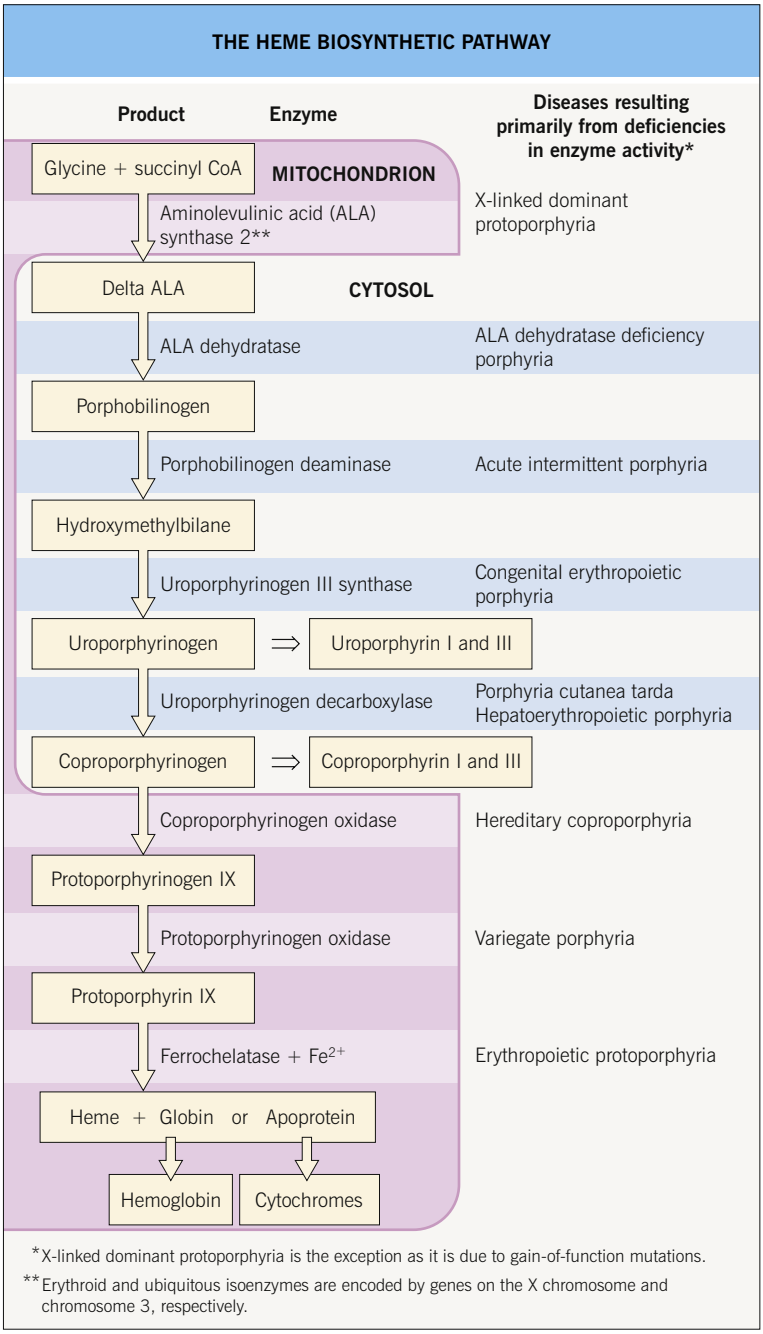


**Fig. 41.1 The heme biosynthetic pathway.** *Courtesy, Jorge Frank, MD, and Pamela Poblete-Gutiérrez, MD.*




**Fig. 41.2 Porphyria cutanea tarda. A** Marked fragility with multiple hemorrhagic crusts, erosions, and milia as well as scars. **B** Flaccid bulla and tense vesicle with clear fluid on the forefinger, accompanied by crusts and scars. *A, Courtesy, YDRSC; B, Courtesy, Jorge Frank, MD, and Pamela Poblete-Gutiérrez, MD.*

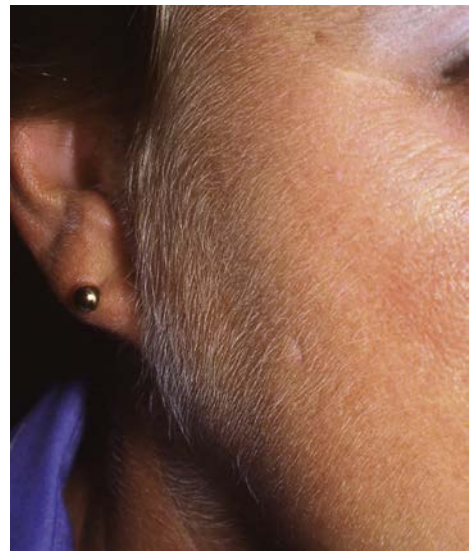

**Fig. 41.3 Porphyria cutanea tarda.** Hypertrichosis of the face in a woman. *Courtesy, Jeffrey P Callen, MD.*



**Fig. 41.4 Porphyria cutanea tarda – sclerodermoid presentation.** The patient had shiny, yellow-white to brown firm plaques on the neck and upper back. *Courtesy, Jorge Frank, MD.*

| BASIC APPROACH TO THE PATIENT WITH SUSPECTED PCT BASED UPON PHYSICAL EXAMINATION |
|---|
| • Review all medications (Table 41.2) and observe for resolution when incriminating drug discontinued |
| • ROS for chronic kidney disease, precipitating factors, and symptoms of variegate porphyria (see text) |
| • Measure urinary uroporphyrins and coproporphyrins (24-hour urine sample) and/or plasma uroporphyrins |
| • If abnormal porphyrin profile for PCT, measure CBC, LFTs, BUN, Cr, and screen for exacerbating factors, in particular HIV, viral hepatitis, and iron overload including hemochromatosis; also consider rare forms of porphyria |
| • If no elevation of uroporphyrins, consider alternative diagnoses, e.g. EBA, phototoxic drug reaction, pseudo-PCT, rare forms of porphyria |

**Table 41.1 Basic approach to the patient with suspected PCT based upon physical examination.** EBA, epidermolysis bullosa acquisita; ROS, review of systems.

| DRUG-INDUCED PSEUDOPORPHYRIA: MOST COMMONLY INCRIMINATED MEDICATIONS | |
|---|---|
| **NSAIDs*** | **Diuretics** |
| **Naproxen** (proprionic acid derivative)**<br>**Mefenamic acid**<br>Nabumetone<br>Ketoprofen (proprionic acid derivative)<br>Diflunisal<br>Celecoxib | **Furosemide**<br>**Hydrochlorothiazide/triamterene**<br>Chlorthalidone<br>Bumetanide |
| | **Retinoids** |
| **Antibiotics** | Isotretinoin<br>Acetretin/etretinate |
| **Nalidixic acid**<br>**Tetracycline, doxycycline**<br>**Ciprofloxacin** | **Miscellaneous** |
| | Amiodarone<br>Voriconazole |

*When caused by NSAIDs, consider prescribing diclofenac, indomethacin, or sulindac.
**Most frequently implicated NSAID.

**Table 41.2 Drug-induced pseudoporphyria: most commonly incriminated medications.** The most commonly incriminated medications are in **bold**. For a more complete list, see Table 49.5 in *Dermatology, Fourth Edition*. *Courtesy, Misty Sharp, MD.*




**Fig. 41.5 Erythropoietic protoporphyria (EPP). A** Erythema, edema, and hemorrhagic crusts on the nose as well as the fingers in a young girl. **B** Subtle scarring on the nose and linear scars on the upper cutaneous lip in a 6-year-old child. *A, Courtesy, YDRSC; B, Courtesy, Gillian Murphy, MD.*

## Erythropoietic Protoporphyria (EPP)

- Complaints of erythema, edema, and a painful burning sensation of the skin following sun exposure usually begin during early childhood; purpura and crusts may also be seen and over time, a waxy texture and scarring develop in areas of greatest cumulative UV exposure, i.e. on the nose and dorsal hands (Fig. 41.5).
- Inherited primarily in a semidominant pattern (mutation in one allele and specific polymorphism in second allele); internal manifestations include gallstones and cholestatic liver disease which can lead to liver failure (~5% of patients).
- Diagnosis is based on the detection of elevated levels of *erythrocyte (RBC) free* protoporphyrin (lipophilic); elevated protoporphyrins are also present in the stool and genetic analysis can be performed; of note, zinc protoporphyrins are also elevated but this can be seen in other disorders, e.g. lead poisoning.
- **DDx:** solar urticaria, phototoxic or photoallergic contact dermatitis and drug reactions, hydroa vacciniforme, cutaneous LE, other causes of early onset photosensitivity (e.g. xeroderma pigmentosum, Rothmund–

Thomson syndrome), and a very rare form of porphyria with similar cutaneous and hepatic findings – X-linked dominant protoporphyria.

- **Rx:** photoprotection (see PCT), β-carotene, afamelanotide; cholestyramine or charcoal, if liver disease.

## Variegate Porphyria (VP)

- Rare form of porphyria, except in South Africa; autosomal dominant inheritance pattern.
- While the cutaneous findings are similar to PCT, the systemic manifestations are similar to those of AIP, in particular acute attacks of abdominal pain, vomiting, paresthesias, motor and sensory neuropathies, and/or psychosis.
- Diagnosis is based on detection of elevated levels of urinary uro- and coproporphyrins (as in PCT) as well as elevated aminolevulinic acid and porphobilinogen (as in AIP), but these elevations may only be present during periods of symptomatic disease; elevated fecal porphyrins are present consistently and in the plasma, a characteristic peak fluorometric emission at 624–626 nm is observed in symptomatic patients; genetic analysis can also be performed.
- **DDx:** for cutaneous findings, PCT, pseudoporphyria, epidermolysis bullosa acquisita (see PCT **DDx**).



**Fig. 41.6 Congenital erythropoietic porphyria.** Severe mutilation of the hands due to scarring. *Courtesy, José Mascaro, MD.*

- **Rx:** photoprotection (see PCT); avoidance of exacerbating factors (e.g. alcohol, fasting); for acute attacks, heme preparations.

## Congenital Erythropoietic Porphyria (CEP)

- Rare severe form of porphyria in which erythema, edema, blisters, erosions, and scarring, as well as hyperpigmentation and hypertrichosis, develop in sun-exposed areas during infancy; autosomal recessive inheritance.
- Over time, the degree of scarring can become marked, leading to mutilation, e.g. mitten deformities of the hand (Fig. 41.6); additional manifestations include hemolytic anemia, hepatosplenomegaly, and pink-red urine stains and pink-red teeth (erythrodontia).
- Diagnosis is based on detection of elevated levels of uro- and coproporphyrins in the urine, RBCs, and plasma and elevated coproporphyrins in the stool; genetic analysis can also be performed.
- **DDx:** hepatoerythropoietic porphyria, which represents the rare autosomal recessive variant of PCT (Fig. 41.7); other causes of early onset photosensitivity (see EPP above).
- **Rx:** strict photoprotection (see PCT), splenectomy, hematopoietic stem cell transplantation.

## Pseudoporphyria (Pseudo-PCT, Bullous Dermatosis of Dialysis)

- Clinical presentation similar to PCT but without abnormal elevation of porphyrins, although patients with renal disease can have borderline elevations in porphyrin levels.
- Seen in patients with chronic kidney disease and those undergoing dialysis, usually hemodialysis (Fig. 41.8); it is also associated with certain medications (Table 41.2).
- Can also occur following tanning bed use.
- **DDx:** see PCT.
- **Rx:** discontinue suspect drug; photoprotection (see PCT).



**Fig. 41.7 Hepatoerythropoietic porphyria.** Hypertrichosis and severe scarring are present, resulting in a clinical appearance similar to congenital erythropoietic porphyria. *Courtesy, José Mascaro, MD.*



**Fig. 41.8 Dialysis-associated pseudoporphyria.** Vesicles filled with clear fluid formed on the dorsal aspects of the hand in this patient with chronic kidney disease. *Courtesy, Kalman Watsky, MD.*

For further information see Ch. 49 from *Dermatology, Fourth Edition*.

**For additional online figures visit www.expertconsult.com**



**eFig. 41.1 Porphyria cutanea tarda.** Hypertrichosis of the malar region of the cheek. *Courtesy, Judit Stenn, MD.*



**eFig. 41.2 Porphyria cutanea tarda presenting as yellow-brown morpheaform plaques.** The plaques were in sun-exposed areas in this patient with a history of alcohol abuse. *Courtesy, YDRSC.*

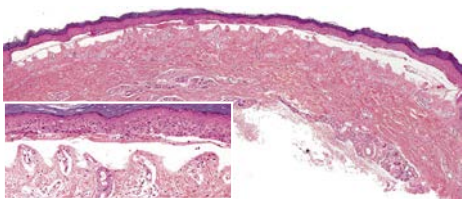

**eFig. 41.3 Porphyria cutanea tarda – histopathologic features.** Subepidermal blister of acral skin with a minimal ("cell-poor") dermal inflammatory infiltrate. Festooning of the dermal papillae (inset). *Courtesy, Lorenzo Cerroni, MD.*



**eFig. 41.4 Pseudoporphyria in a patient with rheumatoid arthritis.** The cause was a nonsteroidal anti-inflammatory drug (NSAID). *Courtesy, Kalman Watsky, MD.*



**eFig. 41.5 Erythropoietic protoporphyria.** Extensive scarring of the cheeks and linear scars on the upper cutaneous lip and chin in an adult. *Courtesy, Luis Requena, MD.*



**eFig. 41.6 Congenital erythropoietic porphyria.** Erythrodontia due to massive protoporphyrin deposition in the teeth. *Courtesy, Jorge Frank, MD.*

# 42 Calcinosis Cutis and Osteoma Cutis

There are four major forms of cutaneous calcification (calcinosis cutis): (1) *dystrophic* – locally within sites of pre-existing skin damage; (2) *metastatic* – due to systemic metabolic derangements; (3) *iatrogenic* – secondary to medical treatment or testing; and (4) *idiopathic*. An occasional patient will have a mixed form. Cutaneous ossification (osteoma cutis) occurs in the setting of several genetic disorders, in a miliary form on the face, and within neoplasms and sites of inflammation (secondary).

## Calcinosis Cutis

- Deposition of amorphous, insoluble calcium salts within the skin.

### Calcinosis Cutis – Dystrophic

- Often seen in autoimmune connective tissue diseases (AI-CTDs), in particular the limited form of systemic sclerosis (previously referred to as CREST syndrome) and childhood dermatomyositis (Figs 42.1 and 42.2); in the former, hard, skin-colored to white papules overlie the bony prominences of the extremities (upper > lower), whereas in the latter the deposits are often larger and sometimes plate-like.
- Extrusion (transepidermal elimination or "perforation"; see Ch. 79) of the calcium deposits appears as a white chalky material and it can be followed by a persistent ulceration.
- Other underlying causes are listed in Table 42.1.
- **Rx:** aggressive treatment of AI-CTDs, when possible, prior to the appearance of calcinosis cutis; excision of symptomatic localized deposits, if feasible; sodium thiosulfate and calcium channel blockers, e.g. diltiazem, may be effective in some patients.



**Fig. 42.1 Dystrophic form of calcinosis cutis.** Note the cluster of small white papules in this patient with the limited form of systemic sclerosis (previously referred to as CREST syndrome). *Courtesy, Janet Fairley, MD.*

### Calcinosis Cutis – Metastatic

- The most common cause is end-stage chronic kidney disease with its associ-



**Fig. 42.2 Radiograph of calcinosis cutis in a patient with generalized morphea.** Areas that were previously firm became rock-hard, and lesions of perforating calcinosis cutis (transepidermal elimination) developed on both legs. *Courtesy, Jean L. Bolognia, MD.*

| DISORDERS OF CUTANEOUS CALCIFICATION |
|---|
| **Dystrophic** |
| • Autoimmune connective tissue diseases, especially dermatomyositis and the limited form of systemic sclerosis<br>• Cutaneous tumors or cysts, e.g. pilomatricomas, pilar cysts<br>• Infections, especially when cysts form around larvae or worms<br>• Trauma, including "heel sticks" in neonates (Fig. 42.3), injection sites, surgical scars<br>• Panniculitis, e.g. pancreatic, lupus profundus, subcutaneous fat of the newborn<br>• Genetic disorders, e.g. pseudoxanthoma elasticum, Ehlers–Danlos syndrome (spheroids) |
| **Metastatic** |
| • End-stage chronic kidney disease<br>– Calciphylaxis*<br>– Benign nodular calcification of renal disease<br>• Hypervitaminosis D<br>• Milk–alkali syndrome<br>• Sarcoidosis<br>• Tumoral calcinosis (familial; hyper- or normophosphatemic)<br>• Hyperparathyroidism<br>• Neoplasms (e.g. multiple myeloma, adult T-cell leukemia/lymphoma, SCC of the lung or head and neck) |
| **Idiopathic** |
| • Idiopathic calcified nodules of the scrotum<br>• Subepidermal calcified nodule (favors head and neck of children)<br>• Tumoral calcinosis (sporadic)<br>• Milia-like calcinosis |
| **Iatrogenic** |
| • Extravasation of intravenous solutions containing calcium or phosphate<br>• Application of calcium-containing electrode paste for EMGs and EEGs<br>• Application of calcium alginate dressings to denuded skin<br>• Organ transplantation, especially liver<br>• Gadolinium (nephrogenic systemic fibrosis) |
| **Can occasionally occur in the setting of severe primary hyperparathyroidism and, less often, in the absence of chronic kidney disease.* |

**Table 42.1 Disorders of cutaneous calcification.**

ated hyperphosphatemia and decreased 1,25-dihydroxyvitamin D levels (Fig. 42.4).

• The two major presentations in patients with chronic kidney disease are: (1) *benign nodular calcification* in which deposits occur within otherwise normal skin, especially around joints; and (2) *calciphylaxis*, which is associated with significant morbidity and mortality.

• Calciphylaxis is characterized by cutaneous ischemia and necrosis which presents as markedly painful retiform purpura and ulcerations (Fig. 42.5); risk factors include obesity and hypercoagulability (e.g. protein C dysfunction, anti-phospholipid Ab); deposits of calcium within blood vessel walls of the subcutis are usually present, but not always, presumably due to sampling error.

• Other etiologies are listed in Table 42.1.



**Fig. 42.3 Dystrophic calcification in an infant at the site of a previous "heel stick" for obtaining blood.** *Courtesy, Julie V. Schaffer, MD.*

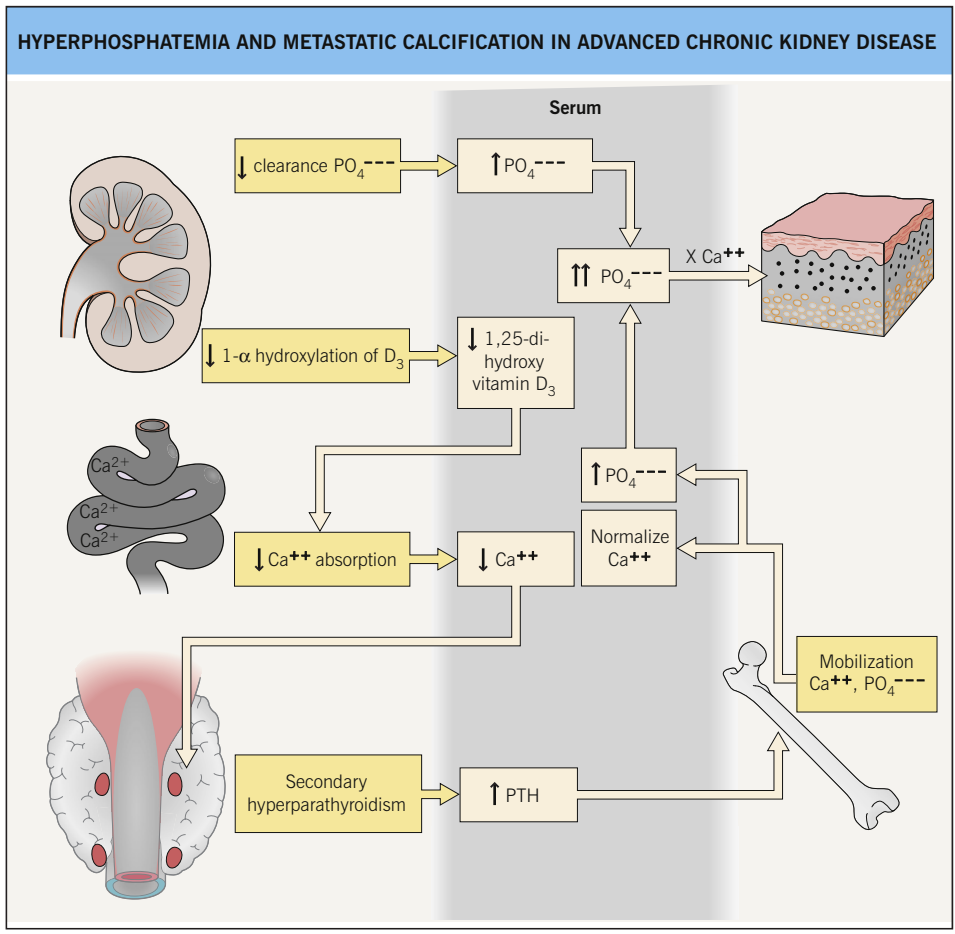


**Fig. 42.4 Mechanisms of hyperphosphatemia and metastatic calcification in patients with chronic kidney disease.**

- **Rx** of calciphylaxis is difficult but includes aggressive wound care and normalization of the $Ca^{++} \times PO_4^{---}$ product via the use of phosphate binders and sometimes parathyroidectomy; drugs such as sodium thiosulfate and cinacalcet can also be tried as well as local injections of sodium thiosulfate. Anticoagulants such as apixaban can also be prescribed.

## Calcinosis Cutis – Iatrogenic and Idiopathic

- Iatrogenic causes and idiopathic forms are listed in Table 42.1.
- Calcification of epidermoid inclusion cysts is the major cause of calcified nodules of the scrotum.
- **Rx:** if symptomatic and feasible, surgical excision.

## Osteoma Cutis

- Deposition of a protein matrix plus hydroxyapatite ($Ca^{++}$, $PO_4^{---}$) within the skin.
- The four genetic disorders that often have cutaneous or subcutaneous ossification are outlined in Fig. 42.6.
- Miliary osteomas of the face is a rather common entity; small hard papules, whose color can vary from white or skin-colored to blue (Fig. 42.7), gradually appear on the face of adult women > men; the role of preexisting acne vulgaris and its treatment with oral antibiotics is debated.
- Ossification can also occur within cysts and tumors (e.g. pilomatricomas, melanocytic nevi) as well as at sites of inflammation; it is often preceded by cutaneous calcification.




**Fig. 42.5 Calciphylaxis. A** Large reticulated violaceous plaques in an obese woman. Centrally there is retiform purpura (inset) which precedes the ulcerations that are also present. **B** Irregular violaceous plaques on the leg with retiform purpura and hemorrhagic crusts overlying ulcerations. **C** Large ulceration with leathery black eschar. Retiform purpura and scarring are seen in the surrounding skin. *A, B, Courtesy, Lorenzo Cerroni, MD; C, Courtesy, YDRSC.*

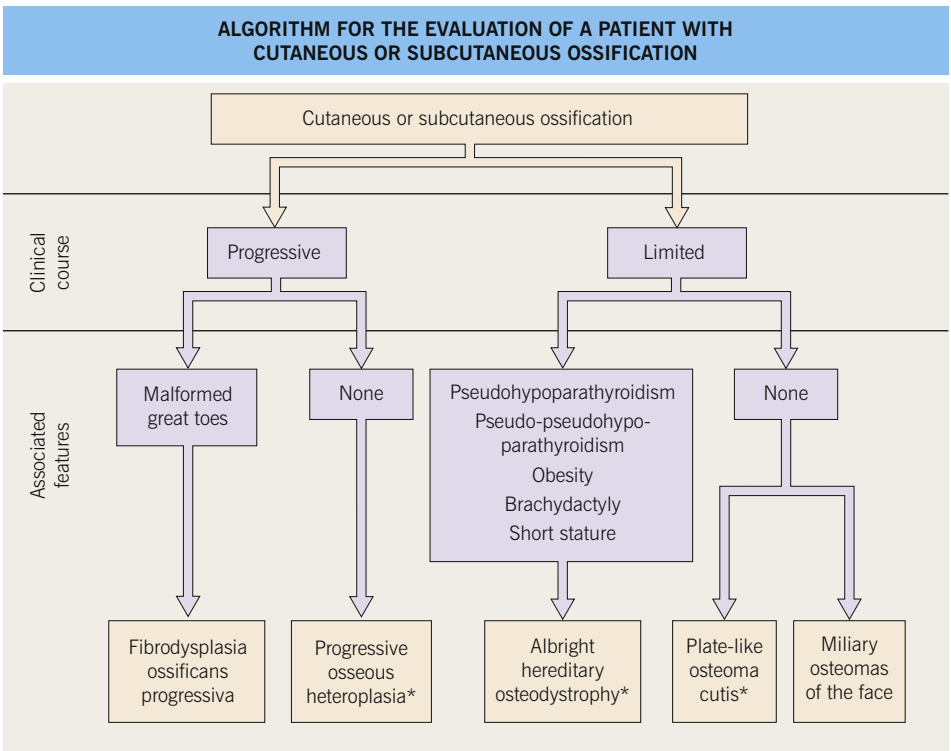


**Fig. 42.6 Algorithm for the evaluation of a patient with cutaneous or subcutaneous ossification.** *Associated with mutations in *GNAS1*, which encodes the alpha subunit of the stimulatory G protein that regulates adenyl cyclase activity (thought to be negative regulator of bone formation); clinical phenotype may be a reflection of imprinting.

• **Rx:** if symptomatic and feasible, surgical excision. For removal of miliary lesions of the face, a small incision with a #11 blade can be followed by extraction.

• The evaluation of a patient with calcinosis cutis or osteoma cutis is outlined in Table 42.2.




**Fig. 42.7 Miliary osteomas of the face. A** Small, white, firm papules in a patient without a history of acne. **B** Multiple blue-colored papules in a patient with a history of acne vulgaris. *A, Courtesy, Janet Fairley, MD; B, Courtesy, YDRSC.*

| LABORATORY EVALUATION OF PATIENTS WITH CUTANEOUS CALCIFICATION/OSSIFICATION |
|---|
| • Special histopathologic stains for calcium, e.g. von Kossa |
| • Serum levels of: |
| – Calcium |
| – Phosphate |
| – Parathyroid hormone (PTH) |
| – 25-OH Vitamin D (routine test); 1,25-di-OH vitamin D (calcitriol; specialized test) |
| • 24-Hour urinary calcium excretion (in some patients) |
| • Hypercoagulability evaluation, e.g. protein C activity, anti-phospholipid Ab (if calciphylaxis suspected) |
| • Genetic analysis (if hereditary disorder suspected; Table 42.1 and Fig. 42.6) |

**Table 42.2 Laboratory evaluation of patients with cutaneous calcification/ossification.** OH, hydroxy.

For further information see Ch. 50 from *Dermatology, Fourth Edition*.

**For additional online figures visit www.expertconsult.com**

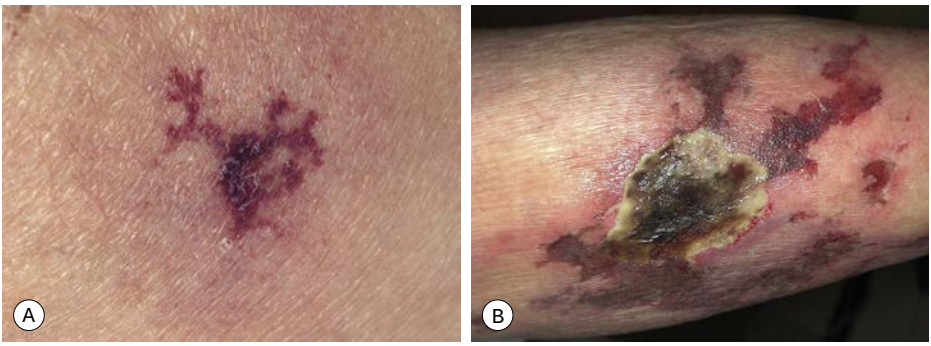


**eFig. 42.1 Calciphylaxis in two patients with chronic kidney disease. A, B** Characteristic painful reticulated purpuric plaques that can develop ulceration. *A, Courtesy, Kalman Watsky, MD; B, Courtesy, YDRSC.*

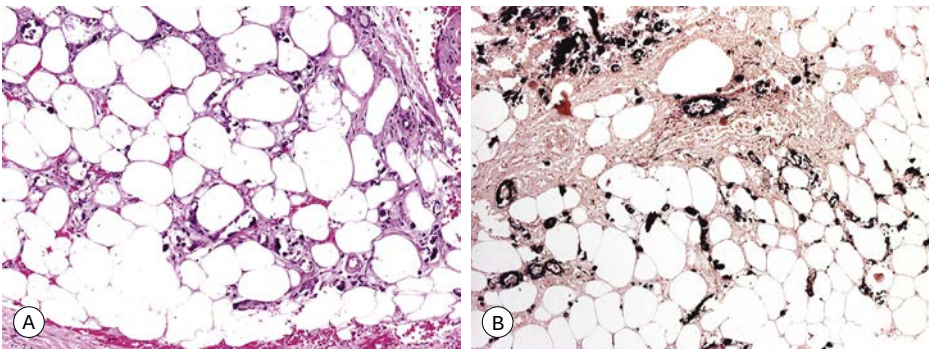


**eFig. 42.2 Calciphylaxis – histopathologic features. A** Perivascular deposition of calcium is seen within the walls of blood vessels in the subcutaneous fat. **B** Staining for calcium (von Kossa) highlights calcium deposition within blood vessel walls (black circular deposits) as well as focal, irregular calcification of connective tissue. Of note, even when the clinical lesions are impressive, the degree of calcification seen histologically may be subtle and clinical suspicion should remain high despite the absence of overt calcium deposits. Ultrasound of involved areas can be performed prior to skin biopsy to increase yield. *Courtesy, Lorenzo Cerroni, MD.*



**eFig. 42.3 Miliary osteomas of the face.** This patient has a history of acne vulgaris and the lesions are skin-colored. *Courtesy, YDRSC.*

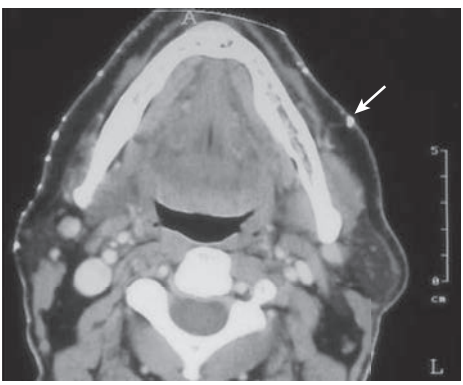

**eFig. 42.4 Miliary osteomas of the face – radiographic findings.** The foci of ossification are readily apparent on the CT scan (arrow). *Courtesy, Janet Fairley, MD.*

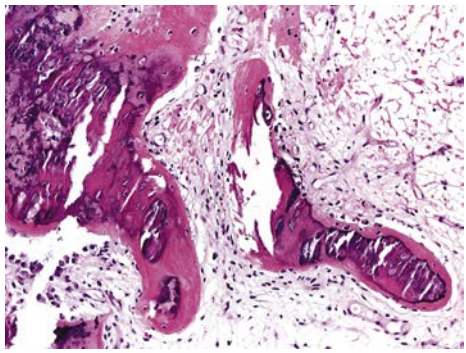

**eFig. 42.5 Osteoma cutis – histopathologic features.** Islands of bone formation are present within the dermis. Occasionally, osteoblasts and bone marrow elements can also be seen.
*Courtesy, Lorenzo Cerroni, MD.*

# Nutritional Disorders 43

## Malnutrition

- Poor nutrition resulting from an insufficient or poorly balanced diet or from defective digestion or utilization of foods.
- Malnutrition encompasses both deficiencies and excesses (e.g. obesity) (Fig. 43.1; Tables 43.1 and 43.2).
- Primary or exogenous: related to the ingestion of food.
- Secondary or endogenous: inadequate or faulty absorption and/or defective metabolism of food and nutrients.
- In low-income populations, exogenous protein-energy malnutrition (marasmus), due to diminished or inadequate food ingestion, is often observed.
- In high-income populations, obesity due to excessive food consumption and primary or secondary deficiencies due to psychiatric or medical (e.g. cystic fibrosis, Crohn disease) conditions are more commonly seen.

## Protein–Energy Malnutrition

- Worldwide is the most prevalent nutritional deficiency; two forms are recognized (see below).
- In developed countries, either form may occur in the setting of "fad" diets or restrictions due to food allergy, e.g. infants given rice milk formula.

### Marasmus

- Most commonly seen in young children but can affect all age groups.
- Results from prolonged, inadequate intake of calories and energy.
- Patients present with low body weight (Fig. 43.2) and recurrent infections due to an impaired ability to mount a normal immune response.

### Kwashiorkor

- A more acute form of protein–energy malnutrition.
- Patients present with peripheral edema, or even anasarca, in association with hypoalbuminemia (Fig. 43.3).
- Because of edema, body weight is higher than seen with marasmus (~60–80% of expected weight, rather than <40%).
- Most commonly affects weaning children; less often seen in children older than 5 years of age or adults (e.g. in the setting of an acute illness superimposed on a milder state of malnutrition).

## Vitamins

- Organic compounds that are biologically active and indispensable for normal physiologic functions.
- Serve as coenzymes of cellular metabolic processes essential for the adequate functioning and growth of tissues.
- Supplied exogenously.
- Both vitamin deficiency (hypovitaminosis) and excess (hypervitaminosis) can cause dermatologic abnormalities (see Tables 43.1 and 43.2; Figs 43.4–43.11).
- Vitamin excess is more common with the fat-soluble vitamins (A, D, K, E).

### Vitamin D

- Fat-soluble vitamin that regulates calcium and phosphate homeostasis and bone metabolism; also involved in gene regulation, cell differentiation, and the normal functioning of the innate and adaptive immune system.
- Initial step in synthetic pathway occurs in the skin (Fig. 43.11); many tissues, in addition to the kidney, have been shown to hydroxylate vitamin D precursors to produce the active form.

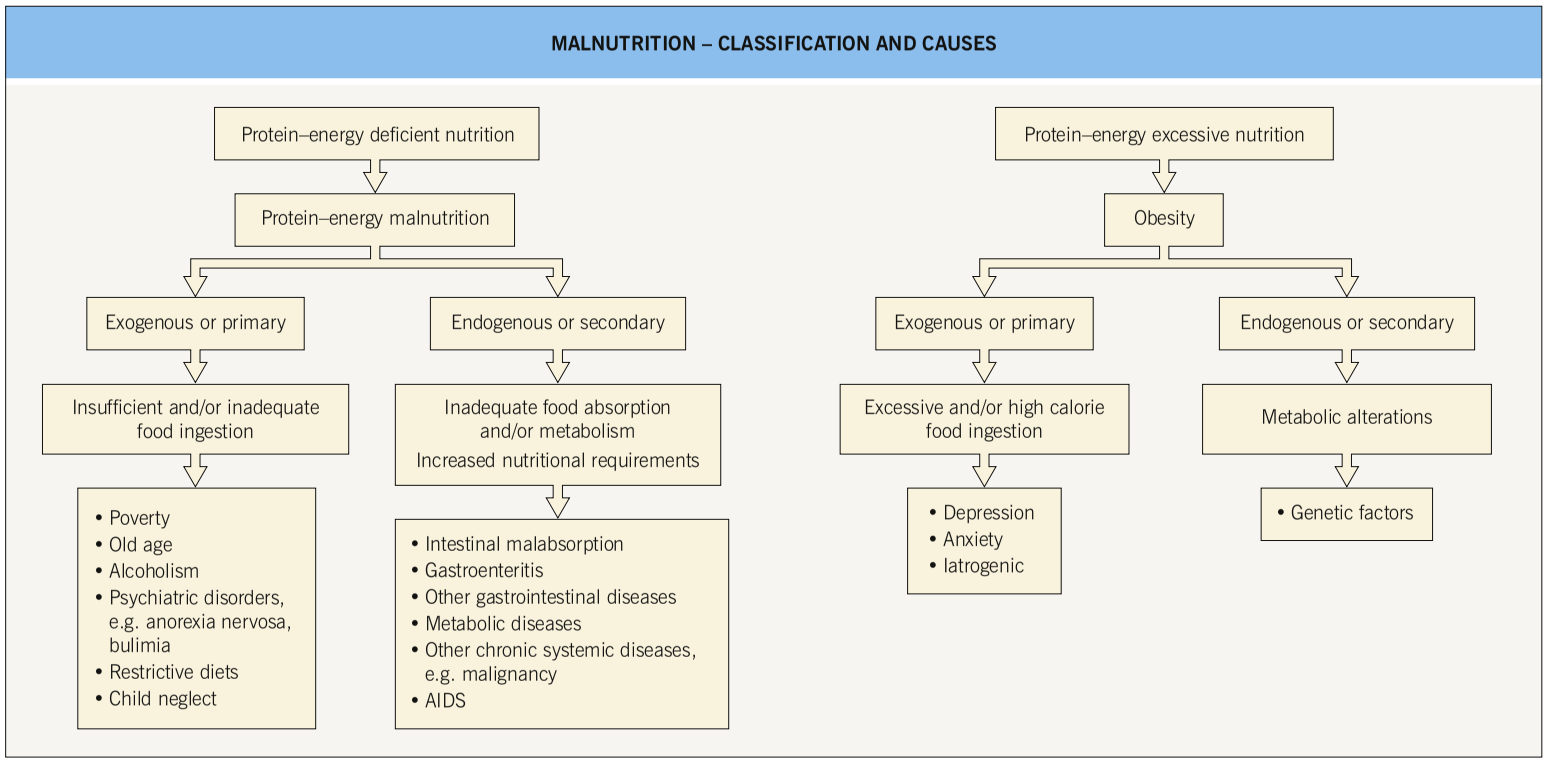


**Fig. 43.1 Malnutrition – classification and causes.** *Courtesy, Ramón Ruiz-Maldonado, MD.*




**Fig. 43.2 Marasmus. A** This child is emaciated and has obvious hyperpigmentation. Both erosions and desquamation are present on the scalp. **B** Multiple sites of purpura are seen. *Courtesy, Ramón Ruiz-Maldonado, MD.*




**Fig. 43.3 Kwashiorkor. A** There is intense edema of the buttocks and lower extremities in addition to areas of erythema with erosions and desquamation. **B** This child's arm has edema and superficial epidermal necrosis with a "flaky paint" appearance. *Courtesy, Ramón Ruiz-Maldonado, MD.*

- Endogenous synthesis and exogenous sources (fortified foods and supplements) represent the major sources.
- Individual vitamin D requirements vary depending on an individual's age, skin pigmentation, underlying diseases, current medications, geographic location, and season of the year; vitamin D receptor polymorphisms may play an important role in disease risk.
- Vitamin D body stores decline with age, during the winter months, and at higher latitudes.
- Phototypes V and VI require about threefold more UVB exposure than phototypes I and II to maintain adequate vitamin D body stores.
- Oral glucocorticoids inhibit the vitamin D-dependent intestinal absorption of calcium.
- Vitamin D *insufficiency* is actually quite common and is thought to contribute to the development of osteoporosis; it has been associated with decreased immune function, bone pain, and possibly cardiovascular disease and certain malignancies.
- True vitamin D *deficiency* is more rare and results in rickets in children and osteomalacia in adults.
- Deficiency of vitamin D can result from inadequate dietary intake, fat malabsorption, lack of adequate UVB exposure, older age with its associated decrease in endogenous

| MALNUTRITION-DEFICIENCY SYNDROMES WITH MUCOCUTANEOUS MANIFESTATIONS | | |
|---|---|---|
| **Deficiency syndrome** | **Mucocutaneous features** | **Systemic features** |
| **Marasmus**<br>(see Fig. 43.2) | Xerotic, thin, pale, lax, wrinkled skin<br>Occasionally fine scaling and hyperpigmentation<br>Follicular hyperkeratosis and folliculitis in adults<br>Ulcerations<br>Lanugo-like hair<br>Slow-growing, thin hair that readily falls out<br>Impaired nail growth and fissured nails<br>Purpura | **Emaciated** appearance<br><40–60% expected body weight<br>Loss of subcutaneous fat and muscle<br>Suppression of growth<br>"Monkey facies" due to loss of buccal fat<br>Bradycardia, hypotension, and hypothermia |
| **Kwashiorkor**<br>(see Fig. 43.3) | Dyschromia<br>Pallor due to distention of skin and loss of pigment<br>**"Enamel"** or **"flaky paint"** areas of superficial desquamation<br>Erythema, petechiae, purpura, and ecchymoses<br>Sparse, dry, lusterless, brittle hair with reddish tinge<br>**"Flag sign"** or alternating light- and dark-colored bands in hair, reflecting intermittent periods of malnutrition<br>Soft and thin nails<br>Cheilitis, xerophthalmia, vulvovaginitis | **Edema**<br>At 60–80% expected body weight<br>Edema or even anasarca<br>Moon facies<br>Anorexia, irritability, apathy<br>Growth retardation and failure to thrive<br>Secondary infections<br>Bilateral parotitis<br>Hepatomegaly<br>Diarrhea<br>Decreased muscle mass |
| Essential fatty acids | Dry, scaly, leathery skin with underlying erythema<br>Intertriginous erosions (Figs 43.4–43.5)<br>Alopecia and more lightly pigmented hair<br>Increase in transepidermal water loss<br>Petechiae | Growth failure<br>Poor wound healing<br>Impaired fertility<br>Capillary fragility<br>Neurologic damage<br>Increased susceptibility to infections |
| Vitamin A<br>(Fig. 43.6) | **Phrynoderma** manifests as follicular hyperkeratosis, favoring the extensor surfaces<br>Xerosis<br>Sparse, fragile hair | Ocular abnormalities, including night blindness, xerophthalmia, **Bitot's spots** (gray-white patches on the conjunctiva), keratomalacia, corneal scarring, and blindness<br>Growth and intellectual disability<br>Low serum vitamin A (retinol) levels |

| | | |
|---|---|---|
| Vitamin K | Purpura and ecchymoses | Bleeding diathesis<br>Low plasma vitamin K levels |
| Vitamin C (ascorbic acid)<br>**Scurvy**<br>(Fig. 43.7) | Follicular hyperkeratosis<br>Corkscrew hairs<br>Perifollicular hemorrhages<br>Petechiae and ecchymoses<br>Gingival hypertrophy with erosions and bleeding gums | Subperiosteal hemorrhage<br>Loose teeth<br>Weakness, fatigue, pseudoparalysis<br>Weight loss, diarrhea, anemia, depression, arthralgias<br>Long-term: edema, hypotension, seizures, increased infections<br>Low plasma vitamin C levels |
| Thiamine (vitamin $B_1$)<br>**Beriberi** | Glossitis and glossodynia | **Wernicke encephalopathy***<br>Korsakoff syndrome**<br>Leigh syndrome† |
| Riboflavin (vitamin $B_2$)<br>**Oro-oculo-genital syndrome** | Seborrheic dermatitis-like changes in periorificial sites (see Figs 43.4–43.5)<br>Painless scaly papules<br>Indolent fissures and ulcers<br>Depapillated glossitis<br>Conjunctivitis and photophobia | Anemia<br>Intellectual disability<br>Electroencephalographic changes<br>Low serum and plasma riboflavin levels |
| Niacin/nicotinic acid (vitamin $B_3$)<br>**Pellagra**<br>(Fig. 43.8 and see Figs 43.4–43.5)<br>***Acquired***<br>Dietary insufficiency, prolonged isoniazid therapy, carcinoid syndrome<br>***Genetic***<br>Hartnup disease | Dermatitis begins as a symmetric erythema in sun-exposed areas, that later becomes scarlet or hyperpigmented, with desquamation and crusting<br>**Casal's necklace** is the photosensitive eruption forming a broad band around the neck<br>Shellac-like appearance<br>Perianal inflammation and erosions<br>Painful fissures on palms and soles<br>Mucosal membranes with edema, cheilitis, atrophic glossitis<br>Buccal and vaginal mucosae susceptible to ulceration and secondary infection | **Classic triad** of diarrhea, dementia, and dermatitis<br>Abdominal pain<br>Achlorhydria<br>Low plasma niacin level |
| Vitamin $B_5$ (pantothenic acid) | None | Fatigue<br>Headaches<br>Vomiting<br>Paresthesias, dysesthesias<br>"Burning feet syndrome" |

**Table 43.1 Malnutrition-deficiency syndromes with mucocutaneous manifestations.** *Continued*

| MALNUTRITION-DEFICIENCY SYNDROMES WITH MUCOCUTANEOUS MANIFESTATIONS | | |
|---|---|---|
| **Deficiency syndrome** | **Mucocutaneous features** | **Systemic features** |
| Vitamin $B_6$ (pyridoxine) | Periorificial scaly, seborrheic dermatitis-like eruption (see Figs 43.4–43.5)<br>Glossitis<br>Conjunctivitis<br>Stomatitis | Anorexia, nausea, vomiting<br>Hematologic abnormalities, e.g. sideroblastic anemia, lymphopenia, eosinophilia<br>Neurologic changes, e.g. peripheral neuropathy, weakness, confusion, seizures<br>Low plasma vitamin $B_6$ levels |
| Biotin (vitamin H; vitamin $B_7$)<br>**Multiple carboxylase deficiency**<br>***Acquired*** – parenteral nutrition deficient in biotin, GI disorders, excessive intake of raw egg whites, chronic anticonvulsant therapy<br>***Genetic***<br>1. **Biotinidase deficiency** (juvenile onset)<br>2. **Holocarboxylase synthetase deficiency** (neonatal onset) | Alopecia<br>Blepharitis, conjunctivitis<br>Secondary infections<br>Eczematous dermatitis resembling acrodermatitis enteropathica (see Figs 43.4–43.5) | Vomiting<br>Metabolic acidosis<br>Hypotonia, lethargy, seizures<br>Developmental delay<br>Optic atrophy, hearing loss<br>Ataxia<br>Low serum biotin levels |
| Folic acid (vitamin $B_9$) | Mucocutaneous features overlap with those seen with $B_{12}$ deficiency<br>Cheilitis, glossitis, and mucosal erosions<br>Gray-brown pigmentation in sun-exposed areas | Megaloblastic anemia, which may present with weakness or congestive heart failure<br>Neuropsychiatric symptoms<br>Low RBC folate levels |
| Vitamin $B_{12}$ (cyanocobalamin) | Smooth, red, painful tongue<br>Generalized hyperpigmentation with accentuation in flexural areas, palms, soles, nails, and oral cavity<br>Increased incidence of poliosis, vitiligo, and alopecia areata in patients with pernicious anemia | **Pernicious anemia**<br>Megaloblastic anemia<br>Pancytopenia<br>If untreated can lead to degenerative neurologic disease<br>Low serum $B_{12}$ levels‡ |
| Zinc (Fig. 43.9)<br>***Acquired*** – low zinc in maternal milk, deficient parenteral nutrition, GI disorders, high-fiber diets, HIV infection<br>***Genetic* (acrodermatitis enteropathica)** – onset days–weeks after birth if bottle-fed or onset typically after weaning if breast-fed | Acral and periorificial dermatitis with erythematous patches and plaques, secondary scaling and crust, erosions and possible vesicles and bulla (see Figs 43.4–43.5)<br>Chronic: may see rough, dry skin, seborrheic dermatitis-like eruptions, lichenified psoriasiform plaques, and poor wound healing<br>Necrosis present in severe cases<br>Stomatitis, glossitis, and cheilitis<br>Pustular paronychia and nail dystrophy | **Classic triad** of diarrhea, dermatitis, and alopecia<br>Failure to thrive<br>Apathy and irritability<br>Photophobia<br>Low serum zinc and alkaline phosphatase levels |

| | | |
|---|---|---|
| Copper<br>***Acquired*** – rare; excessive zinc intake, gastrointestinal surgeries, and malabsorptive syndromes<br>***Genetic*** **(Menkes disease or kinky hair disease)** (Fig. 43.10) – autosomal recessive; mutation in gene that encodes a copper transporting ATPase | ***Acquired***<br>May rarely see pigmentary dilution of hair and skin<br>Genetic<br>Onset age 2–3 months<br>Diffuse cutaneous pigmentary dilution<br>Characteristic facies with pudgy cheeks, cupid bow of upper lip, and horizontal eyebrows<br>Light-colored, sparse, fragile, **kinky hair**<br>Characteristic structural abnormalities of hair, e.g. pili torti, monilethrix, trichorrhexis nodosa<br>**Obligate female carriers –** as a result of lyonization may see patches of swirled hypopigmentation or pili torti in lines of Blaschko | ***Acquired***<br>Anemia, neutropenia, bone marrow dysplasia<br>Neuropathy<br>Failure to thrive<br>***Genetic***<br>Failure to thrive<br>Lethargy, hypotonia<br>Hypothermia<br>Seizures<br>Intellectual disability<br>Osseous alterations<br>Anemia<br>Low serum copper levels |
| Selenium | Hypopigmentation of skin and hair<br>White nails | Weakness<br>Myalgias and elevated muscle enzymes<br>Cardiomyopathy<br>Low serum selenium levels |
| Iron | **May see prior to clinically evident anemia**<br>Koilonychia, brittle nails<br>Glossitis, angular cheilitis<br>Pruritus<br>Alopecia; dry, dull, and brittle hair<br>**If significant anemia present**<br>Skin and nail bed pallor | **Anemia and its associated symptoms**<br>Lethargy, fatigue<br>Decreased exercise tolerance<br>Shortness of breath<br>Congestive heart failure<br>Restless legs syndrome<br>Low serum iron and ferritin levels |

**Wernicke encephalopathy characterized by ophthalmoplegia, ataxia, confusion.*
***Korsakoff syndrome characterized by peripheral neuropathy, memory loss, confabulation.*
*†Leigh syndrome characterized by subacute necrotizing encephalomyopathy; anorexia, weakness, constipation; congestive heart failure; low serum or plasma thiamine levels.*
*‡Elevated serum homocysteine and methylmalonic acid levels are more reliable indicators of $B_{12}$ deficiency and are useful to obtain if $B_{12}$ deficiency is strongly suspected but serum levels of $B_{12}$ are low–normal.*

**Table 43.1** *Continued* **Malnutrition-deficiency syndromes with mucocutaneous manifestations.**

| MALNUTRITION-EXCESS SYNDROMES WITH MUCOCUTANEOUS MANIFESTATIONS | | |
|---|---|---|
| **Excess syndrome** | **Mucocutaneous features** | **Systemic features** |
| Obesity (Fig. 43.12) | Plantar hyperkeratosis<br>Acanthosis nigricans<br>Acrochordons<br>Striae distensae<br>Intertrigo<br>Frictional hyperpigmentation<br>Hyperhidrosis<br>Stasis dermatitis<br>Leg ulcers, mostly venous > arterial<br>Lipodermatosclerosis, including the pannus<br>Stasis mucinosis | Body mass index >30<br>Hypertension<br>Diabetes and insulin resistance<br>Gastroesophageal reflux disease<br>Atherosclerotic cardiovascular disease<br>Steatorrhea |
| Vitamin A | Mucocutaneous findings similar to patients on oral retinoids<br>Xerotic, rough, pruritic, and scaly skin<br>Xerotic cheilitis<br>Diffuse alopecia | Anorexia, weight loss, lethargy<br>Elevated liver enzymes<br>Painful swellings in limbs due to bony changes<br>Radiographic bone changes, e.g. skeletal hyperostosis, extraspinal tendon and ligament calcification |
| Beta carotene (the natural provitamin of vitamin A)<br>**Carotenemia** | **Carotenoderma** (Fig. 43.13) – orange-yellow skin pigmentation primarily in sebaceous gland-rich areas (forehead, nasolabial fold) and in areas with a thicker stratum corneum (palms, soles)<br>Differentiated from jaundice, which has prominent yellow discoloration of the sclerae and mucosae | |
| Copper<br>***Acquired*** – rare<br>***Genetic* (Wilson disease)** – autosomal recessive; mutation in gene that encodes a copper-transporting P-type ATPase | ***Genetic***<br>**Kayser–Fleischer** corneal rings | ***Genetic***<br>Liver disease and cirrhosis<br>Dysarthria, dyspraxia, ataxia, and parkinsonian-like extrapyramidal signs |
| Iron<br>***Acquired*** – numerous blood transfusions; excess intake<br>***Genetic* (type I hemochromatosis)** – autosomal recessive; mutation in gene (*HFE*) that regulates absorption of iron; two most common mutations of *HFE* gene are C282Y and H63D | Generalized hyperpigmentation (bronzing) | Chronic fatigue<br>Diabetes<br>Liver disease, cirrhosis<br>Arthritis<br>Cardiac disease<br>Impotence<br>Hypothyroidism |

**Table 43.2 Malnutrition-excess syndromes with mucocutaneous manifestations.**

vitamin D production, impairment in liver and kidney hydroxylation of active vitamin D precursors, and end-organ resistance to vitamin D metabolites.

- Excess vitamin D, typically resulting from prolonged and excessive intake of vitamin D supplements, can present with anorexia, vomiting, diarrhea, headaches, hypercalcemia, hypercalciuria, muscle weakness, and bone demineralization.
- No specific cutaneous features have been described with vitamin D deficiency or excess.
- The best indicator of vitamin D stores is a measurement of the *serum 25-hydroxyvitamin D level*, and this laboratory value is sometimes used to guide individual vitamin D requirements.
- Guidelines for vitamin D supplementation have been in flux, but oral supplementation is generally recommended for exclusively

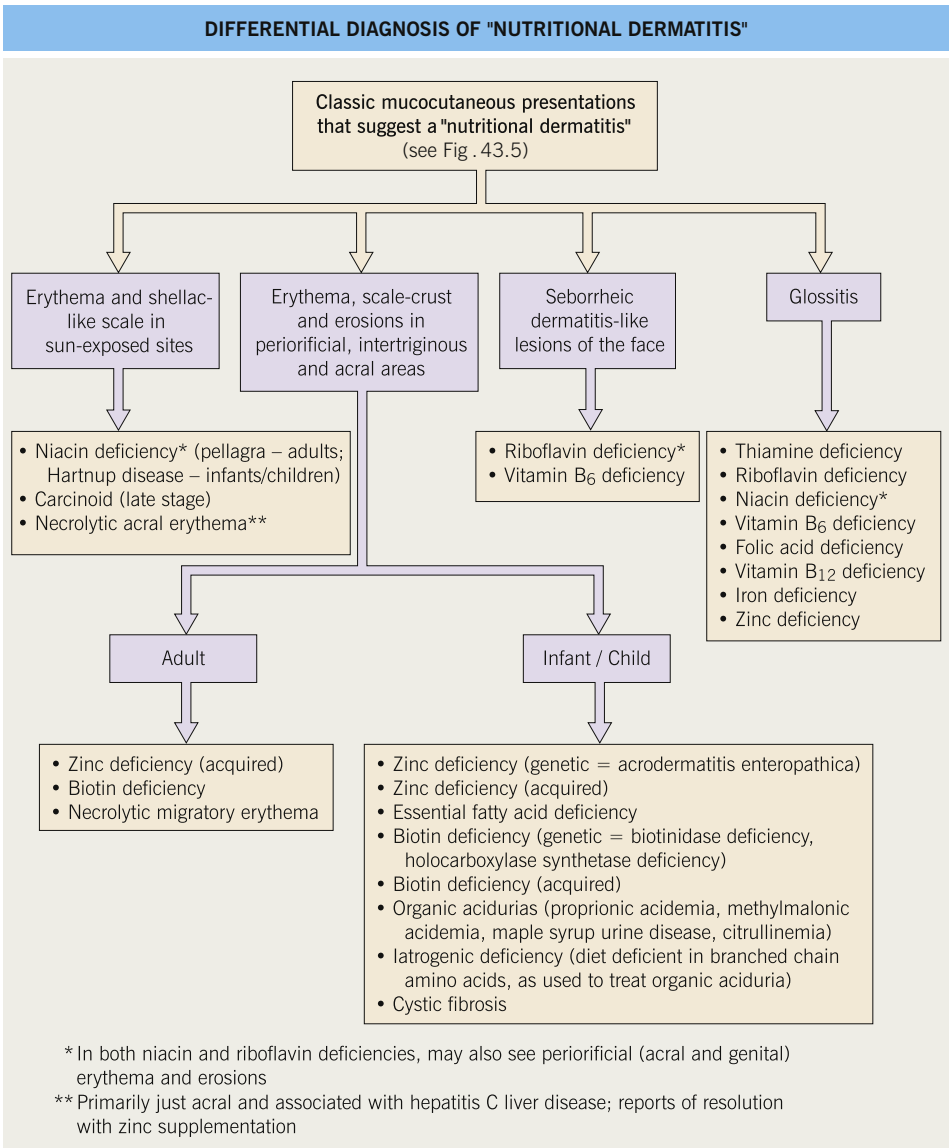


**Fig. 43.4 Clinical approach to the patient with a presumed nutritional disorder.** Differential diagnosis of "nutritional dermatitis."

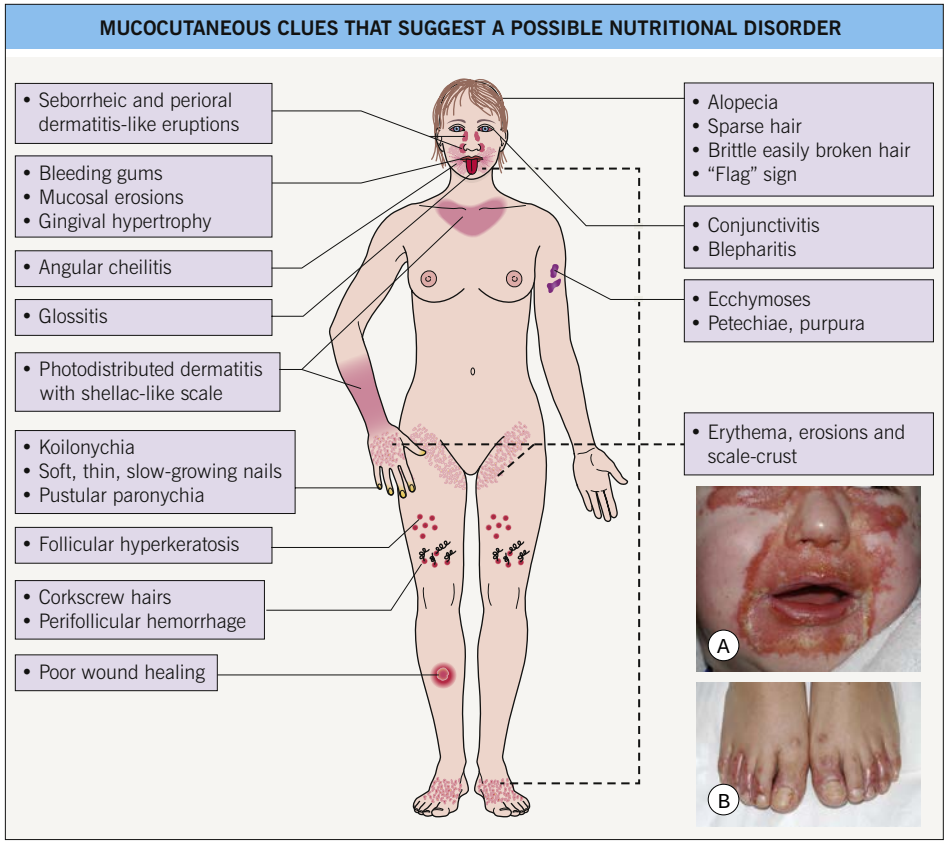


**Fig. 43.5 Mucocutaneous clues that suggest a possible nutritional disorder.** Erythema, erosions and desquamation favor periorificial (**A**) and acral (**B**) sites. *A, B, Courtesy, Julie V. Schaffer, MD.*



**Fig. 43.6 Phrynoderma of vitamin A deficiency.** Multiple clusters of follicular papules with central keratotic plugs. Histopathologically, keratinous plugs within follicles, hyperkeratosis and atrophy of sebaceous glands are seen. It must be differentiated from pityriasis rubra pilaris and keratosis pilaris. *Courtesy, Chad M. Hivnor, MD.*

breast-fed infants, children who drink less than a liter of fortified milk per day, pregnant women, the elderly, most adults for the prevention of osteoporosis, and individuals on long-term oral glucocorticoids.

- Dermatologists recommend oral vitamin D supplementation over the practice of getting more UVB exposure to maintain adequate vitamin D stores.

## Minerals

- Inorganic elements that constitute about 3–4% of body weight.
- Located primarily in the bones and muscle.
- Some are trace elements essential for human nutrition.
- The trace elements of dermatologic importance are zinc, copper, selenium, and iron (see Tables 43.1 and 43.2).

## Essential Fatty Acids (EFAs)

- Unsaturated fatty acids that the body needs but cannot synthesize, and therefore must be obtained from the diet.

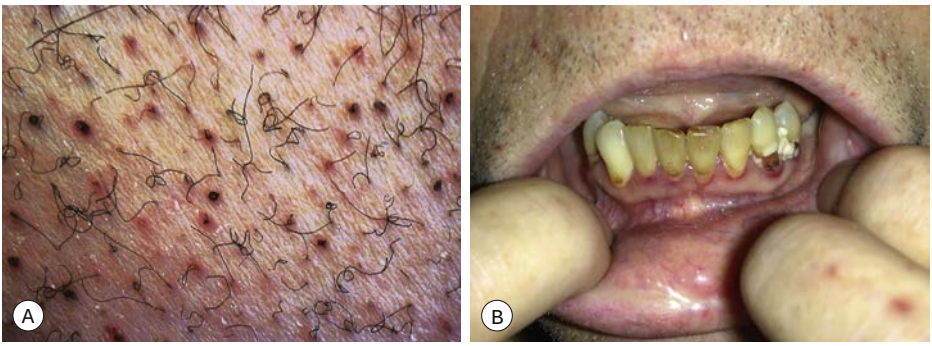


**Fig. 43.7 Scurvy. A** Corkscrew hairs and perifollicular hemorrhage on the lower extremities. **B** Gingivitis and gingival erosions. *A, Courtesy, YDRSC; B, Courtesy, Jeffrey Callen, MD.*




**Fig. 43.8 Pellagra. A** Hyperpigmentation with desquamation of the dorsal aspects of the hands and forearms. The shellac-like scale is seen best on the forearms. **B** Striking hypopigmentation with peripheral desquamation of the sun-exposed area of the chest in a man from sub-Saharan Africa. *A, Courtesy, YDRSC; B, Courtesy, Rosemarie Moser, MD.*




**Fig. 43.9 Zinc deficiency.** Erythema with erosions and scale-crust that is often shellac-like favors the perioral (**A**), acral (**B–D**), and anogenital (**E, F**) regions. The degree of involvement can vary from subtle to striking and may mimic other types of "nutritional dermatitis" (see Figs 43.4–43.5), necrolytic migratory erythema, and more common disorders such as seborrheic dermatitis and psoriasis.
*A, C, F, Courtesy, Julie V. Schaffer, MD; B, D, E, Courtesy, YDRSC.*



**Fig. 43.10 Menkes disease.** This child has the characteristic pale skin and sparse kinky hair. *Courtesy, Ramón Ruiz-Maldonado, MD.*

- The three major EFAs are linoleic, linolenic, and arachidonic acids.
- In most patients, EFA deficiency is seen along with other nutritional deficiencies.
- Isolated deficiencies of EFAs are uncommon but can be seen in patients receiving parenteral nutrition without lipid supplementation and with overly aggressive low-fat diets.

## Anorexia/Bulimia

- Eating disorders that may lead to nutritional deficiencies.
- Associated cutaneous findings include xerosis, telogen effluvium, lanugo-like hair, brittle nails, carotenoderma, cheilitis, acrocyanosis, and worsening of chilblains (Fig. 43.12).
- In addition, patients with bulimia may develop parotid and salivary gland swelling, erosion of tooth enamel, and abrasions or calluses on the dorsal fingers and knuckles (Russell's sign).

## Carotenoderma

- Orange-yellow skin pigmentation (Fig. 43.13) that develops when carotene levels are 3–4 times normal (carotenemia).
- Can result from the high intake of carotenoid-rich foods (carrots) or the inability to convert ingested beta-carotene into vitamin A (some patients with diabetes, hypothyroidism, or anorexia nervosa).
- An excess intake of lycopene-rich foods (tomato, papaya) may induce lycopenemia and skin findings similar to carotenoderma.

## Obesity

- Defined as a body mass index (BMI) >30; may be acquired or inherited.
- Predisposing genetic syndromes that result in an earlier, childhood onset include Prader–Willi, Bardet–Biedl, Alström, and Wilson–Turner syndromes.
- Predisposing endocrine conditions include Cushing disease, Cushing syndrome, polycystic ovarian syndrome, and insulin resistance.
- Acquired obesity is at epidemic levels, especially in high-income populations.
- The cutaneous manifestations of obesity are outlined in Table 43.2 and Fig. 43.12.
- May have associated metabolic syndrome (see Ch. 45).
- Post-bariatric surgery patients are at risk for developing nutritional deficiencies due to altered gastrointestinal absorption of micronutrients (e.g. zinc, iron, copper) and vitamins (e.g. A, D, E, folate, $B_{12}$).

For further information see Ch. 51 from *Dermatology, Fourth Edition*.

**For additional online figures visit www.expertconsult.com**

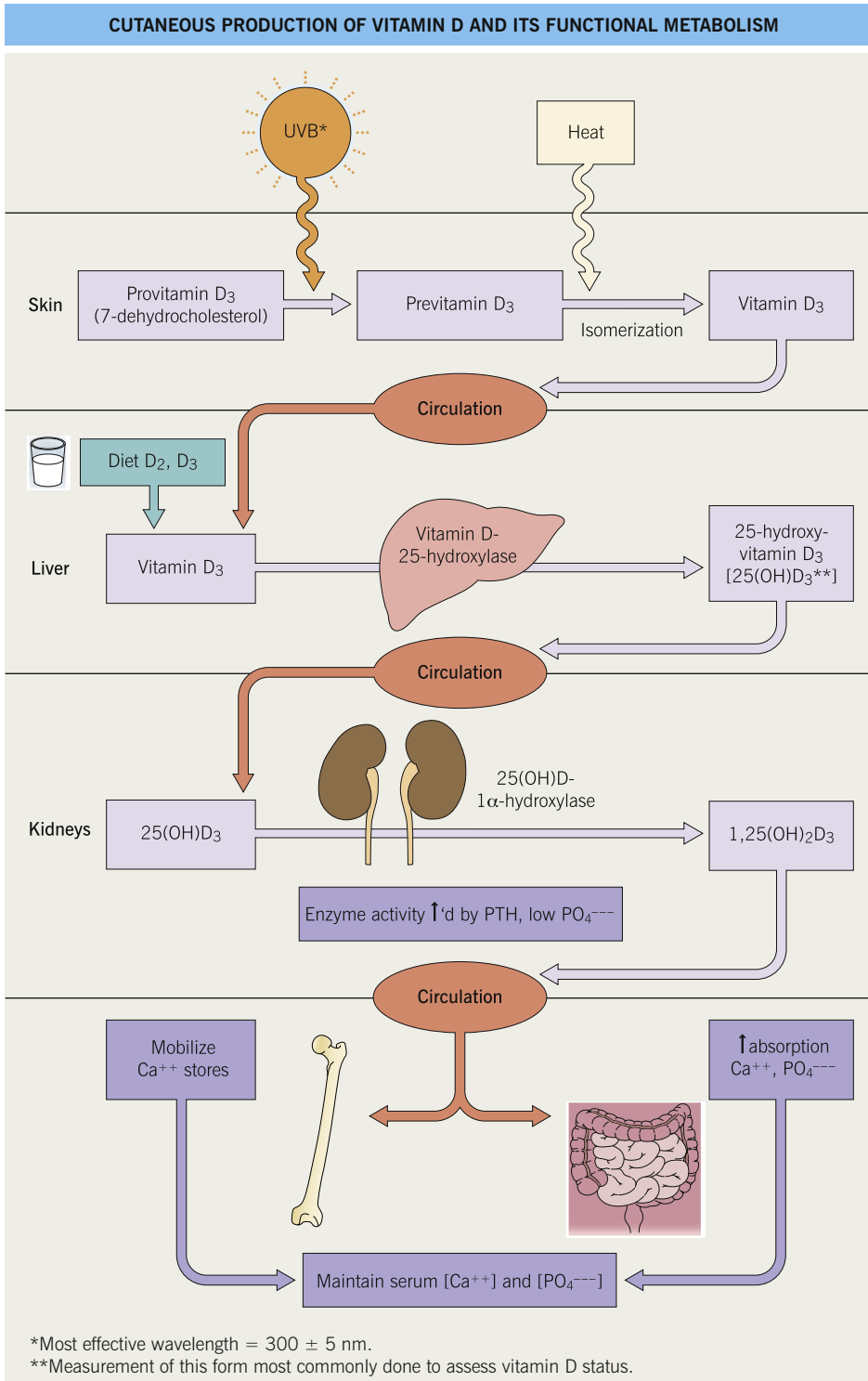


**Fig. 43.11 Cutaneous production of vitamin D and its functional metabolism.** *See next page for figure legend.*

**Fig. 43.11 Cutaneous production of vitamin D and its functional metabolism.** During exposure to ultraviolet B radiation, 7-dehydrocholesterol within the skin is converted to previtamin $D_3$, which is then immediately converted to vitamin $D_3$ in a heat-dependent process. Of note, the heat from excessive sunlight exposure can degrade previtamin $D_3$ and vitamin $D_3$ into inactive photoproducts. Both forms of vitamin D ($D_3$ and $D_2$) are biologically inactive and they require activation in the liver and then the kidney. After binding to carrier proteins, vitamin D is transported to the liver, where it is enzymatically hydroxylated to 25-hydroxyvitamin D [25(OH)D], the major circulating form of vitamin D. 25-Hydroxyvitamin D is then converted into its active form, 1,25-dihydroxyvitamin D [$1,25(OH)_2D$], within the kidney by the enzyme 1α-hydroxylase. Of interest, this final hydroxylation step can also occur in keratinocytes when the enzyme CYP27B1 is upregulated in response to wounding or by Toll-like receptor (TLR) activation from microbial-derived ligands. Serum levels of phosphate, calcium, and fibroblast growth factor 23 can either increase or decrease renal production of $1,25(OH)_2D$. $1,25(OH)_2D$ decreases its own synthesis via feedback inhibition and decreases the synthesis and secretion of parathyroid hormone by the parathyroid glands. $1,25(OH)_2D$ also enhances intestinal calcium absorption in the small intestine by interacting with the vitamin D receptor–retinoic acid X receptor complex (VDR-RXR) to enhance the expression of the epithelial calcium channel and calbindin-D 9K, a calcium-binding protein. In addition, $1,25(OH)_2D$ is recognized by its receptor in osteoblasts, leading to a series of events that maintain calcium and phosphorus levels in the blood which in turn promotes mineralization of the skeleton.

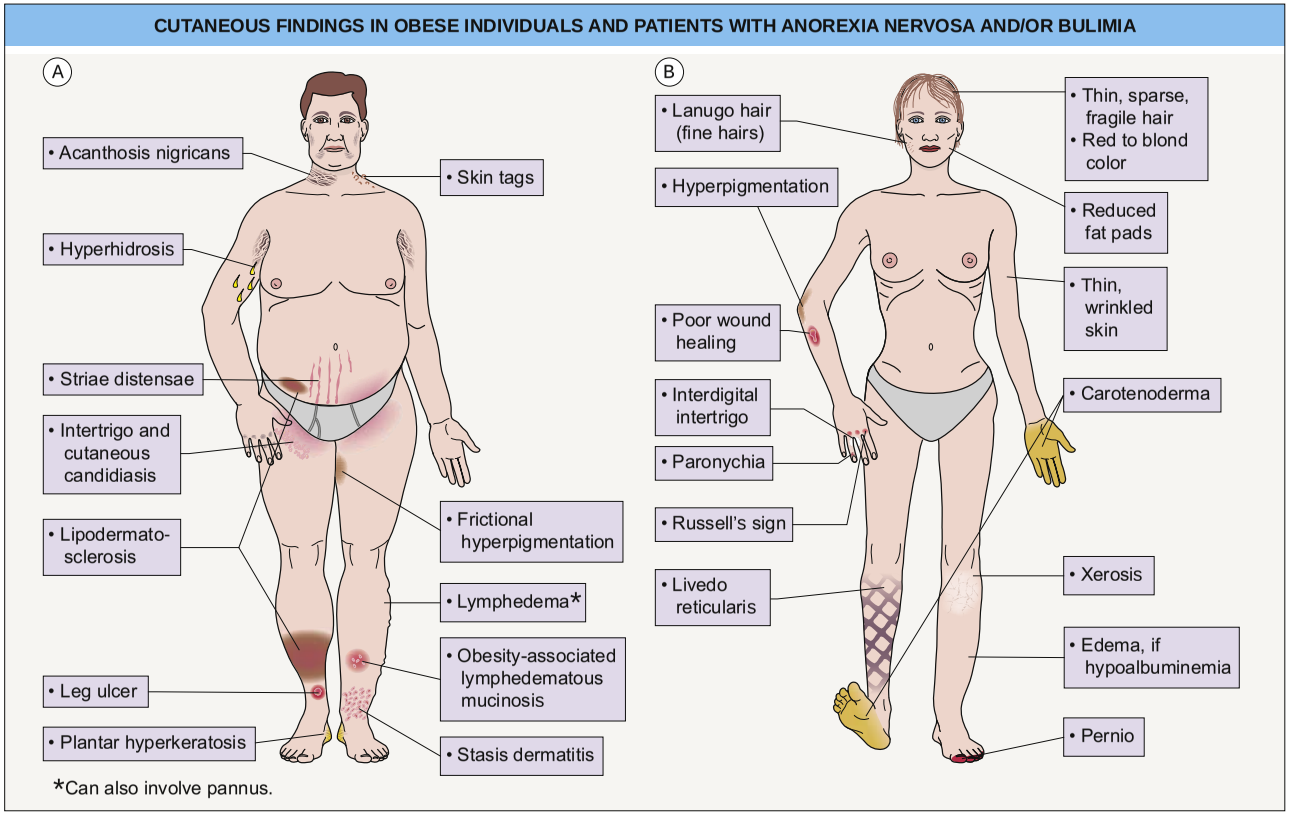


**Fig. 43.12 Cutaneous findings in obese individuals (A) and patients with anorexia nervosa and/or bulimia (B).** (See Fig. 43.5 for signs of nutritional deficiences).



**Fig. 43.13 Carotenoderma.** The patient's legs are noticeably orange when compared to the photographer's hand. *Courtesy, Chad M. Hivnor, MD.*



**eFig. 43.1 Vitamin A deficiency.** Blindness and corneal scarring. *Courtesy, Peter Erhnstrom, MD.*



**eFig. 43.2 Scurvy.** Gingival hypertrophy and infection, with loosened teeth. *Courtesy, YDRSC.*




**eFig. 43.3 Pellagra. A** Hyperpigmented desquamation of the distal lower extremity. Note the shiny shellac-like appearance on the lateral ankle. The photodistribution of erythema (**B**), erythema plus shiny desquamation (**C**), and erythema plus bullae (**D**) is apparent. Note the sparing under the watchband and shoes. *A, Courtesy, YDRSC; B–D, Courtesy, Luis Requena, MD.*




**eFig. 43.4 Acquired zinc deficiency. A, B** The findings within flexural areas are more subtle in this patient. **C** There is also nail dystrophy – thickening, yellow discoloration, and loss of cuticle. *Courtesy, Luis Requena, MD.*




**eFig. 43.5 Inherited zinc deficiency. A** Erythema and erosions on the buttocks, perineal, and genital regions of this infant. Lesions favor the acral (**B**) and periorificial sites (**C**), and pustular paronychia may also be seen (**D**). *A, Courtesy, YDRSC; B–D, Courtesy, Julie V. Schaffer, MD.*



**eFig. 43.6 Histopathology of zinc deficiency.** Epidermal hyperplasia with superficial necrosis (pallor of superficial keratinocytes). *Courtesy, Lorenzo Cerroni, MD.*

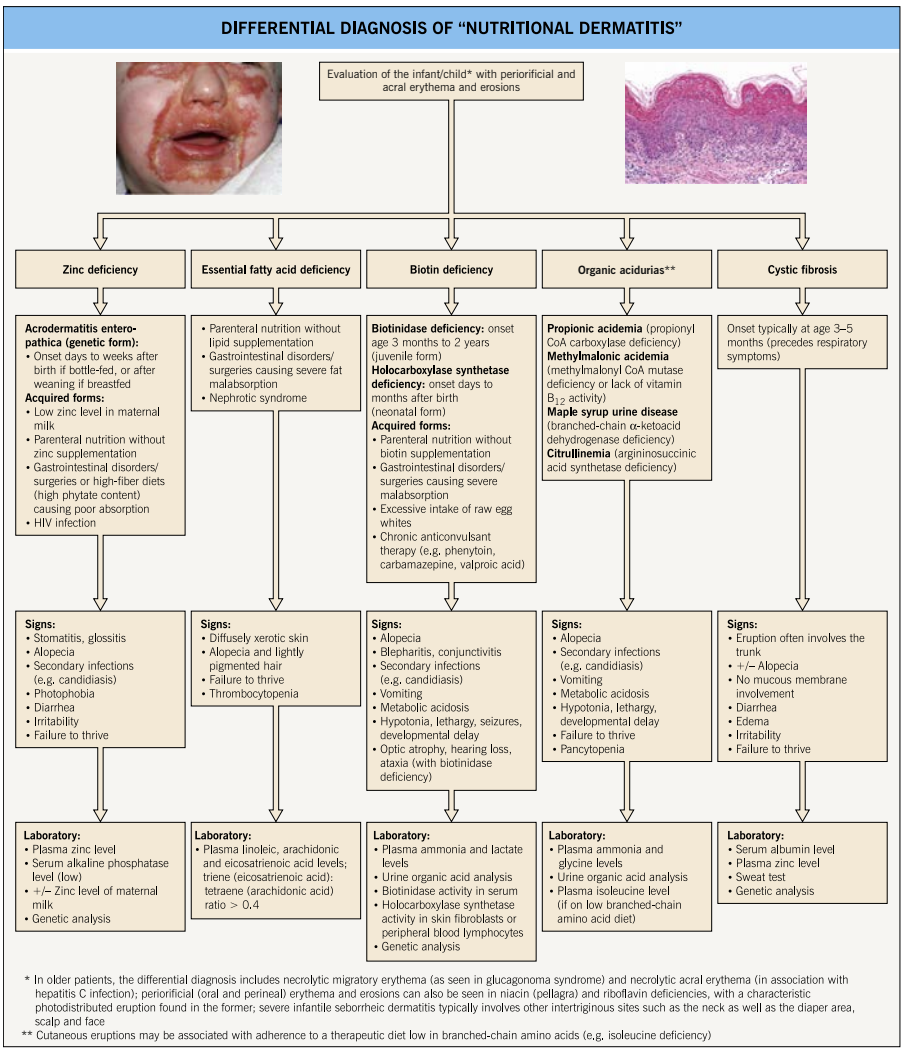


**eFig. 43.7 Differential diagnosis of "nutritional dermatitis" (in addition to exogenous protein–energy malnutrition).** *Courtesy, Julie V. Schaffer, MD. Photomicrograph, courtesy, Luis Requena, MD.*

# 44 Graft-Versus-Host Disease

- Multiorgan disorder that most commonly results from the transfer of donor hematopoietic stem cells into a recipient via an allogeneic hematopoietic stem cell transplant (HSCT).
- Despite advances in HSCT procedures and post-transplantation immunosuppressive therapy, more than half of HSCT recipients develop chronic GVHD, which remains a major cause of morbidity and mortality.
- Table 44.1 lists risk factors for GVHD in HSCT recipients.
- Less frequent settings of GVHD include transfusion of non-irradiated blood products to an immunocompromised patient, maternal–fetal transmission to an immunodeficient neonate, and solid organ transplantation.
- Divided into acute and chronic forms based on clinical features.
- Pathogenesis of acute GVHD occurs in three steps: (1) HSCT conditioning regimen leads to epithelial cell injury and activation of *host* antigen presenting cells; (2) activation of *donor* T cells; (3) tissue destruction by cytotoxic T cells, natural killer cells, and soluble factors (e.g. TNF).
- Chronic GVHD shares features (e.g. autoantibody production, cutaneous sclerosis) with autoimmune connective tissue diseases.
- Histopathologically, acute GVHD and epidermal involvement in chronic GVHD are characterized by variable degrees of keratinocyte necrosis (often accentuated in appendages), vacuolar degeneration of the basal layer, and a band-like lymphocytic infiltrate.

## Acute GVHD

- Most often arises 4–6 weeks after HSCT with traditional regimens.
- Persistent, recurrent, and delayed variants of acute GVHD can occur during a time period (>100 days post-transplant) traditionally reserved for chronic GVHD, especially following interventions such as tapering of immunosuppression and donor lymphocyte infusions.
- Typically presents as a morbilliform exanthem, often with perifollicular accentuation.
- Initial predilection for acral sites (e.g. dorsal hands and feet, palms, soles, ears), forearms, and upper trunk.
- Clinical staging is based on the proportion of the cutaneous surface involved: Stage 1, <25%; Stage 2, 25–50%; and Stage 3, >50%. Stage 4 represents erythroderma with bullae/epidermal detachment resembling toxic epidermal necrolysis (Fig. 44.1).
- Mucosal surfaces (including the conjunctiva), the gastrointestinal tract (nausea, diarrhea, abdominal pain), and the liver (transaminitis, cholestasis) are frequently affected.
- Histopathologic evaluation is helpful but not necessarily diagnostic, and clinicopathologic correlation is essential.
- **DDx:** drug eruption, viral exanthem, engraftment syndrome (nonspecific erythematous eruption, fever, pulmonary edema; onset day 10–14 post-transplant), toxic erythema of chemotherapy (especially with palmoplantar or intertriginous involvement).
- **Rx:** topical CS if limited cutaneous involvement only; most patients require systemic CS, which are typically added to ongoing prophylactic treatment with a systemic calcineurin inhibitor; second-line treatments include JAK inhibitors (e.g. ruxolitinib) and other immunosuppressive agents (e.g. mycophenolate mofetil [MMF], TNF inhibitors).

## Chronic GVHD

- Can occur as a continuation of acute GVHD, as a recurrence following a GVHD-

| RISK FACTORS ASSOCIATED WITH THE DEVELOPMENT OF GRAFT-VERSUS-HOST DISEASE (GVHD) |
|---|
| **Donor** |
| HLA incompatibility with recipient<br>Unrelated to recipient<br>Female (especially multiparous) with male recipient<br>Older age |
| **Recipient** |
| Age (elderly > middle aged > pediatric) |
| **Stem cell source** |
| Peripheral blood* > bone marrow > cord blood<br>T-cell replete graft |
| **Transplantation protocol**** |
| More intense/myeloablative conditioning regimen (increases risk of acute GVHD)<br>Less aggressive administration of prophylactic immunosuppressive agents |
| **Clinical course** |
| Reduction of immunosuppression ± donor lymphocyte infusions if recurrence of malignancy<br>Reduction of immunosuppression if decrease in donor chimerism |
| **More rapid engraftment but increased risk of chronic GVHD.*<br>***Post-transplantation cyclophosphamide administration reduces the risk of GVHD.* |

**Table 44.1 Risk factors associated with the development of graft-versus-host disease (GVHD).** HLA, human leukocyte antigen.

free interval, or without a history of acute GVHD.

- Skin and mucosal involvement are extremely common and highly variable in their presentations (Table 44.2; Fig. 44.2A), and almost any organ system can be affected (Fig. 44.2B).
- Reticulate pink to violet papules with scale (*lichen planus-like*) favoring the dorsal hands and feet, forearms, and trunk represent one characteristic manifestation (Fig. 44.3A).
- The spectrum of sclerotic involvement includes:
  - *Lichen sclerosus-like* shiny, wrinkled, gray-white plaques, ± follicular plugging, favoring the upper trunk (Fig. 44.3B,C)
  - Localized or widespread *morphea-like* indurated, hyperpigmented to skin-colored plaques favoring the trunk (Fig. 44.3D). Longstanding fibrosis may result in skin ulceration, especially of the legs (Fig. 44.3E)
  - *Eosinophilic fasciitis-like* presentations with acute edema and pain evolving into areas of firm skin with subcutaneous rippling ("pseudo-cellulite"; Fig. 44.3F) and linear depressions following a vein or between muscle groups (groove sign); favors the extremities (sparing the hands and feet) and may result in joint contractures
- Often affects the nails and the oral and genital mucosa (Fig. 44.4; see Table 44.2).
- Other frequent sites of involvement include the eyes (keratoconjunctivitis sicca, blepharitis), salivary glands (sicca syndrome), and lungs (bronchiolitis obliterans); may also affect the esophagus (strictures), liver, and pancreas (exocrine insufficiency).
- **DDx:** drug eruption (e.g. lichenoid, photosensitive), AI-CTDs (e.g. lupus erythematosus, morphea), papulosquamous disorders.
- **Rx:** skin-directed with topical CS or calcineurin inhibitors (for superficial disease; tacrolimus under occlusion may increase systemic levels) or phototherapy (narrowband UVB, UVA1, PUVA); for topical treatment of oral disease, see Table 59.2; components of systemic combination therapy may include CS, calcineurin inhibitors, methotrexate, ruxolitinib, ibrutinib, imatinib, rituximab, acitretin, and extracorporeal photopheresis; physical therapy (for joint mobility), sun protection, and regular skin examinations, especially if prolonged immunosuppression.

For further information see Ch. 52 from *Dermatology, Fourth Edition*.




**Fig. 44.1 Clinical spectrum of acute cutaneous graft-versus-host disease. A** *Stage 1* – discrete and coalescing small pink papules on the upper chest and neck of a woman 6 weeks following allogeneic bone marrow transplant. **B, C** *Stage 2* – pink macules and papules on the dorsal aspect of the hands becoming confluent 4 weeks post allogeneic bone marrow transplant and widespread pink-violet macules and minimally elevated papules on the abdomen in a liver transplant recipient. **D** *Stage 3* – diffuse erythema with desquamation, but without bullae formation. **E** *Stage 4* – widespread bullae and epidermal necrosis in a patient who received a donor lymphocyte infusion following allogeneic bone marrow transplant; note the resemblance to toxic epidermal necrolysis. *A, Courtesy, YDRSC; B, D, E, Courtesy, Edward Cowen, MD; C, Courtesy, Julie V. Schaffer, MD.*

| MUCOCUTANEOUS MANIFESTATIONS OF CHRONIC GRAFT-VERSUS-HOST DISEASE (GVHD) |
|---|
| **Skin and subcutaneous tissues** |
| Inflammatory manifestations<br>• **Lichen planus-like (lichenoid)**<br>• Psoriasiform, eczematous/dyshidrotic, psoriasiform, pityriasis rosea-like<br>• Photosensitive eruptions resembling subacute cutaneous lupus erythematosus |
| Sclerotic manifestations<br>• **Lichen sclerosus-like**<br>• **Morphea-like (morpheaform)**<br>• **Scleroderma-like (sclerodermoid)**<br>• **Fasciitis**† |
| Skin breakdown*<br>• Bullae and ulcerations |
| Hyperkeratotic and/or adnexal manifestations<br>• Eczema craquelé, keratosis pilaris-like, ichthyosiform<br>• Alopecia (scarring or non-scarring), alopecia areata<br>• Impaired sweating** |
| Vascular manifestations<br>• **Poikiloderma**<br>• Angiomatous papules/nodules |
| Pigmentary alterations<br>• Hypo- or depigmentation (e.g. vitiligo-like leukoderma)<br>• Premature graying, leukotrichia<br>• Hyperpigmentation (e.g. leopard-like) |
| Nail changes<br>• Longitudinal ridging/splitting, brittleness/thinning, onycholysis<br>• Pterygium (dorsal), anonychia |
| **Mucosae** |
| Oral manifestations<br>• **Lichen planus-like** (e.g. lacy white plaques, ulcers)<br>• **Keratotic plaques**<br>• Mucositis, gingivitis, erosions, ulcerations, pseudomembranes<br>• **Restriction of oral opening from sclerosis**<br>• Xerostomia, mucosal atrophy, mucocele |
| Genital manifestations<br>• **Lichen planus-like**<br>• Erosions/ulcers, fissures (especially of the vulva), balanitis, phimosis<br>• **Vaginal scarring and/or stenosis** |
| **Often overlying areas of cutaneous sclerosis.*<br>†*Magnetic resonance imaging can help to establish the diagnosis.*<br>***May be related to destruction of eccrine glands.* |

**Table 44.2 Mucocutaneous manifestations of chronic graft-versus-host disease (GVHD).** Diagnostic features are in bold; other signs and symptoms listed are not considered sufficient to establish a diagnosis of chronic GVHD without further testing (e.g. histopathologic assessment) or evidence of other organ system involvement. *Based on Filipovich AH, Weisdorf P, Pavletic S, et al. National Institutes of Health Consensus Development Project on Criteria for Clinical Trials in Chronic Graft-versus-Host Disease: I. Diagnosis and Staging Working Group report. Biol Blood Marrow Transplant. 2005;11:945–956.* For manifestations in other organs (including the eye), see this reference as well as the text.

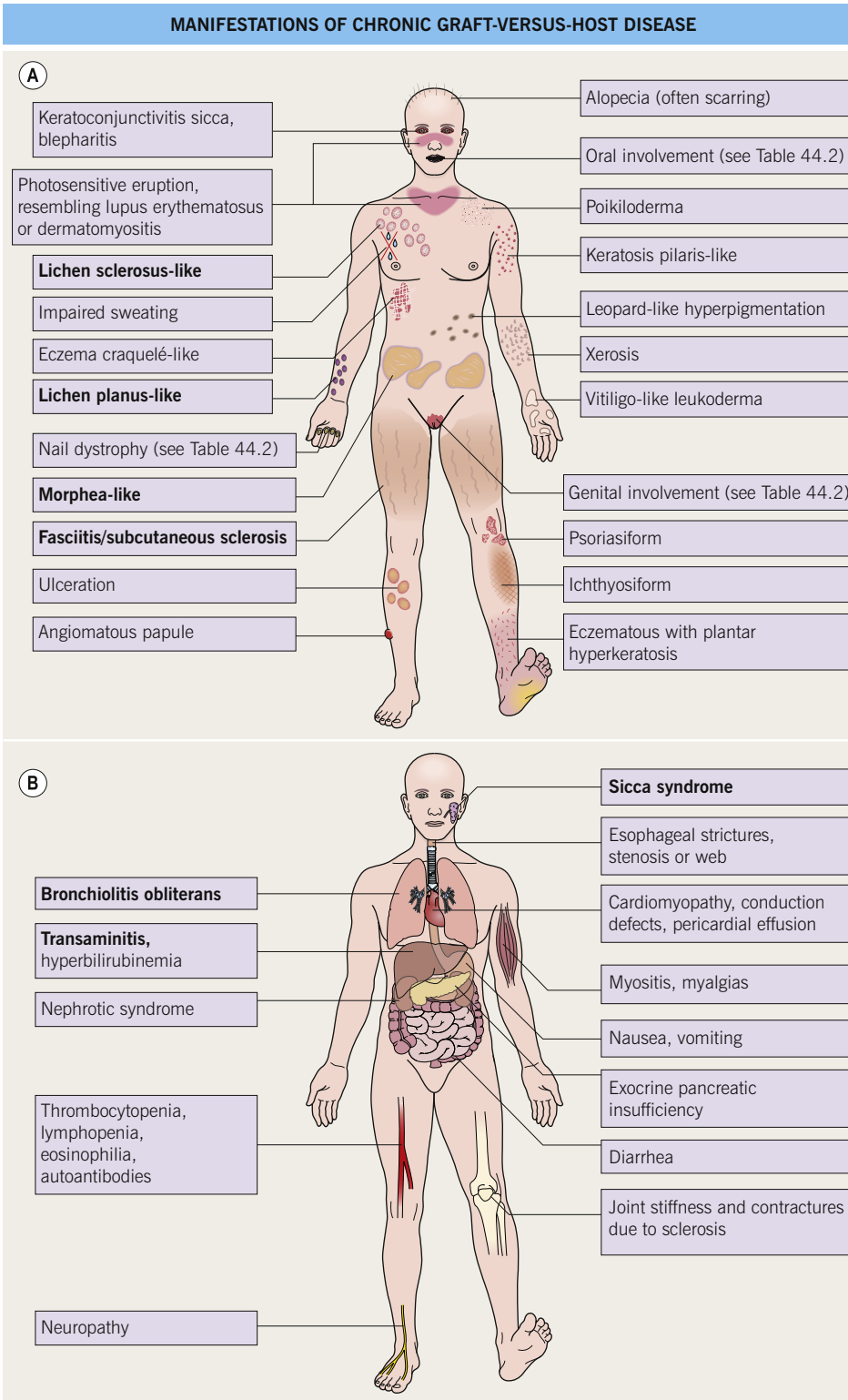


**Fig. 44.2 Manifestations of chronic graft-versus-host disease. A** Mucocutaneous findings. Lichen sclerosus-like lesions may be prominent on the back. Highly characteristic manifestations are in bold. **B** Internal involvement. The most common manifestations are in bold.

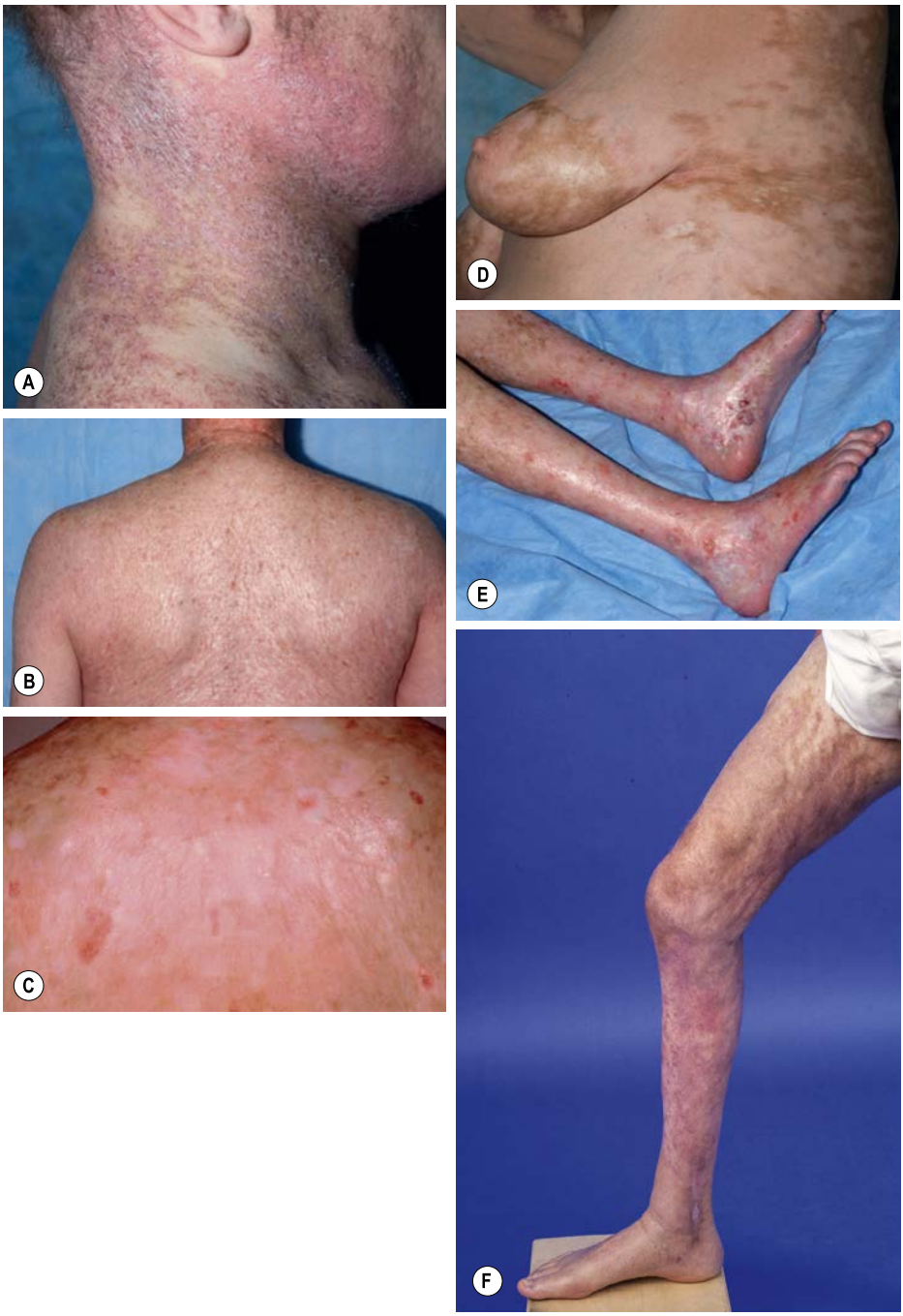


**Fig. 44.3 Clinical spectrum of chronic cutaneous graft-versus-host disease.** **A** Lichen planus-like – thin pink-violet papules and plaques with scale, admixed with postinflammatory hyperpigmentation. **B** Lichen sclerosus-like (early) – multiple gray-white thin plaques with obvious wrinkling are present on the mid back. **C** Lichen sclerosus-like (late) – thicker shiny white plaques on the upper back admixed with erosions. **D** Morphea-like (morpheaform) – shiny, hyperpigmented, sclerotic plaques extending from the breast to the lateral trunk. **E** Scleroderma-like (sclerodermoid) – the skin is shiny and bound-down with dyspigmentation, hair loss, angiomatous nodules, multiple erosions and ulceration; range of motion of the ankles is markedly reduced. **F** Eosinophilic fasciitis-like presentation of chronic cutaneous graft-versus-host disease. A rippled appearance and irregular nodular texture to the skin is indicative of involvement of subcutaneous tissues. Especially in the earlier, edematous phase, the presence of hypereosinophilia may be a clue to the diagnosis. *A, B, D–F, Courtesy, Edward Cowen, MD; C, Courtesy, Joyce Rico, MD.*

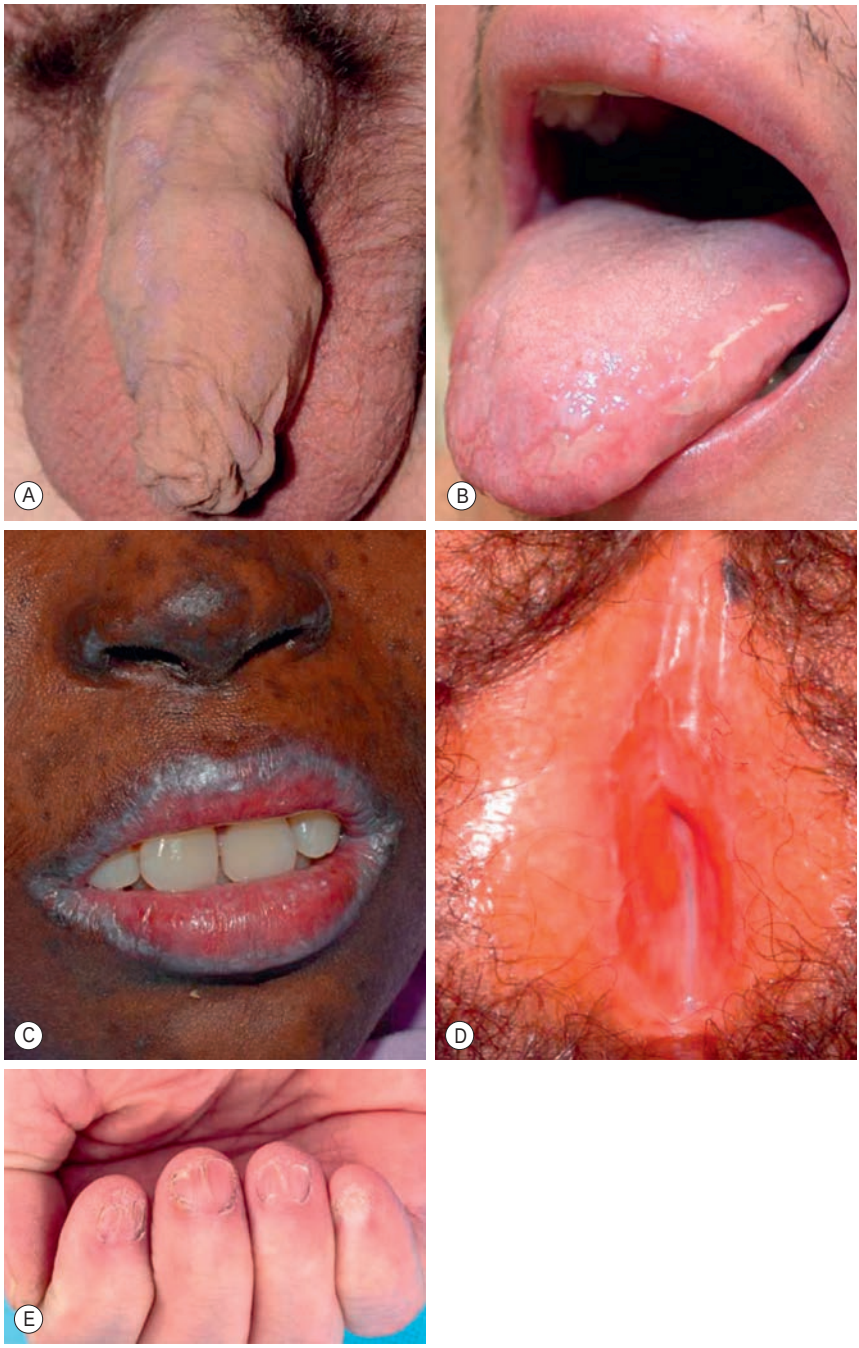


**Fig. 44.4 Orogenital and nail involvement in chronic cutaneous graft-versus-host disease. A–C** Lichen planus-like – flat-topped violet papules on the penis (**A**), several ulcers on the tongue (**B**), and a lacy white pattern on the lips, distal dorsal tongue, and alar rim (**B, C**). Note the hyperpigmented macules in surrounding skin (**C**). **D** Severe erosive disease of the vulva, with nearly total resorption of the labia minora and agglutination of the lips of the clitoral hood. The vulvar introitus is also markedly narrowed. **E** Nail thinning, splitting and dorsal pterygium formation. *A, D, E, Courtesy, Edward Cowen, MD; B, Courtesy, Jean L. Bolognia, MD; C, Courtesy, Julie V. Schaffer MD.*




**eFig. 44.1 Clinical spectrum of acute cutaneous graft-versus-host disease.**
**A** *Stage 2* – pink macules and papules of the palms that are becoming confluent 14 weeks post allogeneic bone marrow transplant.
**B** *Stage 4* – coalescence of bullae plus epidermal necrosis leading to large areas of denudation in a patient who had received an allogeneic bone marrow transplant; note the resemblance to toxic epidermal necrolysis. *A, Courtesy, Dennis Cooper, MD; B, Courtesy, YDRSC.*

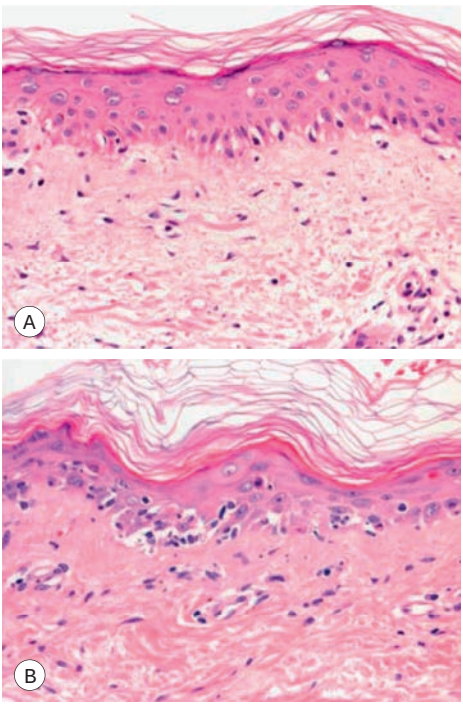


**eFig. 44.2 Acute cutaneous graft-versus-host disease – histologic grades.** **A** Grade I: focal vacuolar changes of the basal layer of the epidermis and sparse lymphocytic infiltrate.
**B** Grade II: necrosis of keratinocytes and more obvious vacuolar degeneration of the basal layer.
*Courtesy, Lorenzo Cerroni, MD.*




**eFig. 44.3 Lichen planus-like chronic GVHD. A** Lacy grayish-white pattern on the helical rim with background hyperpigmentation and surrounding hyperpigmented macules and thin papules. **B** Painful plaques with healing erosions on the soles. **C** Lacy white pattern on the mucosal surface of the lower lip. *A, B, Courtesy, Julie V. Schaffer, MD; C, Courtesy, YDRSC.*




**eFig. 44.4 Clinical spectrum of sclerotic chronic cutaneous graft-versus-host disease.** **A, B** Lichen sclerosus-like (early) – multiple gray-white thin plaques with obvious wrinkling are present on the mid back. **C, D** Morphea-like (morpheaform) – shiny, hyperpigmented, sclerotic plaques extending circumferentially along the waistline to the inguinal area (**C**) and with a healing ulcer on the shoulder (**D**). **E** Scleroderma-like (sclerodermoid) – the skin is shiny and bound-down with dyspigmentation, hair loss, small angiomatous nodules, nail loss, multiple erosions and ulceration; range of motion of the ankles is markedly reduced. **F** Eosinophilic fasciitis-like – a rippled appearance and irregular nodular texture to the skin is indicative of involvement of subcutaneous tissues; extension of the elbow is limited. Especially in the earlier, more edematous phase, the presence of hypereosinophilia may be a clue to the diagnosis. *A, Courtesy, Dennis Cooper, MD; B, C, E, F, Courtesy, Edward Cowen, MD; D, Courtesy, YSCRSC.*



**eFig. 44.5 Residual dyspigmentation from chronic cutaneous graft-versus-host disease.** Extensive hyper- and hypopigmentation in an African-American child with a history of epidermal involvement of GVHD. *Courtesy, Edward Cowen, MD.*




**eFig. 44.6 Additional cutaneous findings in chronic graft-versus-host disease.**
**A** Vitiligo with patches of amelanosis; note the nail dystrophy. **B** Scarring alopecia and vitiligo in the setting of extensive sclerotic chronic GVHD. *Courtesy, Edward Cowen, MD.*

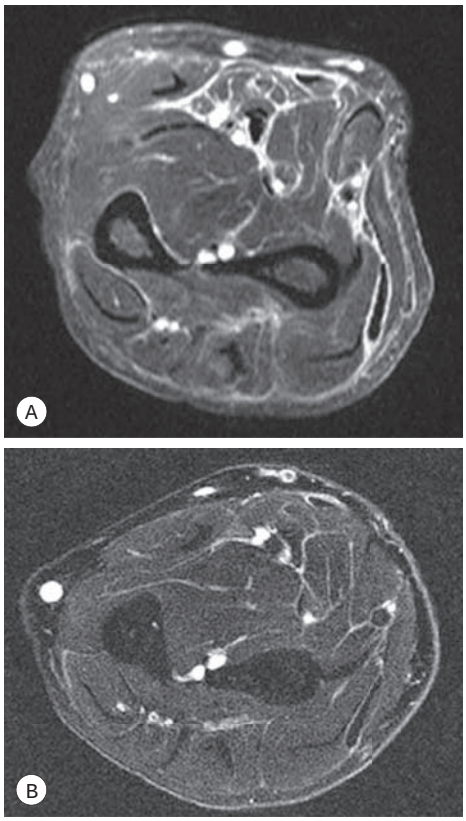


**eFig. 44.7 Magnetic resonance imaging of the eosinophilic fasciitis-like presentation of chronic cutaneous graft-versus-host disease.** **A** Prior to treatment (systemic corticosteroids), with a lace-like white pattern representing edema of the fascia. **B** After treatment, with marked diminution of edema. The round white circles represent blood vessels. *Courtesy, Dennis Cooper, MD.*

| CLINICAL FEATURES OF ENGRAFTMENT SYNDROME VERSUS ACUTE GRAFT-VERSUS-HOST DISEASE (GVHD) | | |
|---|---|---|
| **Clinical feature** | **Engraftment syndrome** | **Acute GVHD** |
| Type of transplant | Autologous or allogeneic | Allogeneic |
| Exanthem | Yes | Yes |
| Pruritus | Variable | Variable |
| Fever | Yes | Uncommon |
| Peripheral eosinophilia | Variable | Variable |
| Diarrhea | No | Yes |
| Transaminitis/cholestasis | Uncommon | Yes |
| Pulmonary edema | Yes | No |
| Weight gain | Yes | No |
| Renal insufficiency | Variable | No |
| Encephalopathy | Uncommon | No |
| Rapid response to corticosteroids | Yes | Variable |
| Timing post-transplant | ~10–12 days (coinciding with myeloid recovery) | Peak incidence at 30–40 days |

**eTable 44.1 Clinical features of engraftment syndrome versus acute graft-versus-host disease (GVHD).**

# Skin Signs of Systemic Disease

# 45

## Introduction

- Recognizing the skin signs of systemic disease is an important aspect of dermatology; however, the vast number of cutaneous manifestations, combined with the infrequency with which each sign is encountered, can be daunting.
- The approach in this chapter is to provide several examples of the most commonly observed or most characteristic cutaneous findings, based on the organ system most often involved – for example, papulonodules of sarcoidosis (lung), diffuse induration of systemic sclerosis (kidney), and melanotic macules of Peutz–Jeghers syndrome (gastrointestinal tract).
- With the exception of endocrinologic disorders and paraneoplastic dermatoses, most of these skin signs have been discussed in other chapters – for example, pyoderma gangrenosum in Chapter 21, telangiectasias of hereditary hemorrhagic telangiectasia (HHT) in Chapter 87, and sebaceous neoplasms of Muir–Torre syndrome in Chapters 52 and 91.

## Pulmonary Disease and the Skin

- Table 45.1 and Fig. 45.1.




**Fig. 45.1 Skin signs of pulmonary disease.** **A** Periorificial and facial papules of sarcoidosis. The presence of lesions on the nasal rim is often associated with granulomatous inflammation of the upper respiratory tract. **B** Hereditary hemorrhagic telangiectasia. Several small red macules and papules on the lips. **C** Yellow nail syndrome. *A, Courtesy, Jeffrey P. Callen, MD; B, Courtesy, Irwin Braverman, MD; C, Courtesy, Karynne O. Duncan, MD.*

| EXAMPLES OF SKIN SIGNS OF PULMONARY DISEASE | | |
|---|---|---|
| **Disorder** | **Cutaneous findings** | **Pulmonary disease** |
| **Genetic** | | |
| Birt–Hogg–Dubé syndrome (see Ch. 91) | • Classic triad of fibrofolliculomas, trichodiscomas, and acrochordons | • Lung cysts, spontaneous pneumothoraces |
| Hereditary hemorrhagic telangiectasia (HHT) (see Ch. 87) | • Mucosal, facial, and acral telangiectatic macules and papules (Fig. 45.1B) | • Pulmonary AVMs |
| **Inflammatory/autoimmune** | | |
| Sarcoidosis (see Ch. 78) | • Acute: erythema nodosum<br>• Chronic: papules, nodules (Fig. 45.1A), plaques, lupus pernio, lesions in scars and tattoos; acquired ichthyosis | • Acute: bilateral hilar lymphadenopathy<br>• Chronic: fibrosis due to granulomatous inflammation |
| Granulomatosis with polyangiitis (Wegener granulomatosis; see Ch. 19) | • Vasculitic lesions (e.g. palpable purpura or nodules), crusted papules due to PNGD, cutaneous granulomas, pyoderma gangrenosum-like ulcers, "strawberry gums" (see Fig. 59.17), oral ulcers (see Fig. 19.10B) | • Dyspnea, cough, hemoptysis, and/or pleuritis<br>• Irregular pulmonary infiltrates or nodules that may cavitate |
| Eosinophilic granulomatosis with polyangiitis (Churg–Strauss syndrome; see Ch. 19) | • Palpable purpura, urticarial plaques, nodules, crusted papules of the elbows due to PNGD, ulcers | • Asthma<br>• Eosinophilic pneumonia |
| Yellow nail syndrome (Fig. 45.1C) | • Thickened, slow-growing, excessively curved, yellow-to-green nails with onycholysis, transverse ridging, onychomadesis, and absent cuticles and lunulae | • Bronchopulmonary disease: pleural effusions, bronchiectasis<br>• Lymphedema, sinusitis<br>• Malignancy |
| Dermatomyositis (see Ch. 34) | • Gottron papules, heliotrope, photodistributed poikiloderma (see Fig. 34.4) | • ILD, aspiration pneumonitis, hypoventilation |
| Systemic sclerosis (see Ch. 35) | • DcSSc: Raynaud disease (sudden onset); more widespread sclerosis<br>• LcSSc: Raynaud disease (preceding long duration); limited, acrofacial sclerosis | • DcSSc: ILD > PAH<br>• LcSSc: PAH > ILD (see Fig. 35.2) |
| **Neoplastic/paraneoplastic** | | |
| Lymphomatoid granulomatosis (see Ch. 99) | • Papulonodules, plaques, ulcers | • Cough, dyspnea and chest pain due to angiocentric, angiodestructive infiltrate of atypical lymphocytes |
| Paraneoplastic pemphigus (see Ch. 23) | • See Table 45.9 and Fig. 23.8 | • Bronchiolitis obliterans |

**Table 45.1 Examples of skin signs of pulmonary disease.** *Continued*

| EXAMPLES OF SKIN SIGNS OF PULMONARY DISEASE | | |
|---|---|---|
| **Disorder** | **Cutaneous findings** | **Pulmonary disease** |
| **Infectious** | | |
| Tuberculosis (see Ch. 62) | • Lupus vulgaris, acute miliary, scrofuloderma, tuberculous gumma, orificial | • Apical infiltrates, cavitating infiltrates; nonproductive or productive cough |
| Blastomycosis* (see Ch. 64) | • Verrucous, ulcerated plaques or nodules | • Patchy infiltrates or normal chest X-ray |
| Cryptococcosis (see Ch. 64) | • Variable cutaneous findings, from papulonodules and plaques to molluscum contagiosum-like lesions and cellulitis | • Varies from asymptomatic infection to severe pneumonia and acute respiratory distress syndrome |
| Aspergillosis (see Ch. 64) | • Plaques with black crusts<br>• Cutaneous emboli: necrotic papules and plaques, often with ulceration and rapidly progressive | • In those with disseminated cutaneous emboli, cavitating infiltrates and nodules |
| Varicella (see Ch. 67) | • Lesions in various stages of development, including papules, papulovesicles, pustules, and hemorrhagic crusts | • Pulmonary involvement correlates with severity of skin involvement. Interstitial infiltrates or patchy airway disease leads to cough and dyspnea. |
| **Other** | | |
| Toxic epidermal necrolysis (TEN) (see Ch. 16) | • Widespread necrosis and detachment | • Acute respiratory distress syndrome |

**Primary pulmonary infection also occurs in other systemic mycoses due to dimorphic pathogens, including coccidioidomycosis, histoplasmosis, and paracoccidioidomycosis.*

**Table 45.1** *Continued* **Examples of skin signs of pulmonary disease.** Patients with Kaposi sarcoma, urticarial vasculitis, and tuberous sclerosis complex can also have pulmonary disease. AVM, arteriovenous malformation; PNGD, palisaded neutrophilic and granulomatous dermatitis; DcSSc, diffuse cutaneous systemic sclerosis; LcSSc, limited cutaneous systemic sclerosis; ILD, interstitial lung disease; PAH, pulmonary arterial hypertension.

## Cardiac Disease and the Skin

- Table 45.2 and Fig. 45.2.

## Gastrointestinal Disease and the Skin

- Tables 45.3–45.5 and Figs 45.3 and 45.4.

## Liver Disease and the Skin

- Table 45.6 and Fig. 45.5.

## Renal Disease and the Skin

- Table 45.7.

## Skin Signs of Internal Malignancy

- Tables 45.8 and 45.9 and Figs 45.6 and 45.7.

## Skin Signs of Endocrine Disorders and Metabolic Disease

- Tables 45.10–45.13 and Figs 45.8–45.12.

For further information see Ch. 53 from *Dermatology, Fourth Edition*.

**For additional online figures visit www.expertconsult.com**

| EXAMPLES OF SKIN SIGNS OF CARDIAC DISEASE | |
|---|---|
| **Disorder** | **Cardiac disease** |
| **Genetic** | |
| Cardio-facio-cutaneous (CFC) syndrome | • Pulmonic stenosis, atrial septal defects, hypertrophic cardiomyopathy |
| Heritable connective tissue diseases: cutis laxa, Ehlers–Danlos syndrome (EDS), pseudoxanthoma elasticum, Marfan syndrome (see Ch. 80); cardiac disease varies from mitral valve prolapse to arterial/aortic aneurysms, dissection, and rupture | |
| Carney complex (NAME and LAMB syndromes) (see Ch. 92) | • Atrial myxomas |
| Tuberous sclerosis complex (TSC) (see Ch. 50) | • Cardiac rhabdomyomas, arrhythmias |
| **Inflammatory/autoimmune** | |
| Psoriasis (see Ch. 6) | • Increased risk of cardiovascular disease |
| Systemic lupus erythematosus (see Ch. 33) | • Pericarditis, verrucous endocarditis (Libman–Sacks), coronary artery disease |
| Neonatal lupus erythematosus (see Ch. 33) | • Congenital heart block |
| Systemic sclerosis (see Ch. 35) | • PAH, conduction defects, pericarditis, visceral Raynaud phenomenon |
| Rheumatic fever (see Ch. 15) | • Pancarditis in the acute phase; late manifestations include mitral and/or aortic valve dysfunction |
| Sarcoidosis (see Ch. 78 and Fig. 45.1A) | • Conduction defects, congestive heart failure |
| Kawasaki disease (mucocutaneous lymph node syndrome) (see Ch. 3) | • Coronary arteritis, coronary artery aneurysms |
| DRESS/DIHS (see Ch. 17) | • ECG changes may simulate acute myocardial infarction; acute myocardial dysfunction and hypotension, which may initially appear during taper of CS |
| **Other** | |
| Hyperlipidemia (see Ch. 77) | • Coronary artery disease |
| Primary systemic amyloidosis (AL) (see Ch. 39) | • Restrictive cardiomyopathy, conduction disturbances |
| Endocarditis – bacterial or fungal (see Chs 61 and 64) | • Vegetations and dysfunction of the valves |
| Exfoliative erythroderma (see Ch. 8) | • High-output cardiac failure |

**Table 45.2 Examples of skin signs of cardiac disease.** The cutaneous features of these disorders are discussed in the chapters cited. Cardio-facio-cutaneous syndrome is characterized by generalized ichthyosis-like scaling, keratosis pilaris, café-au-lait macules, sparse curly hair, and developmental delay. Patients with neurofibromatosis 1, hemochromatosis and relapsing polychondritis (see Fig. 45.2) can also have cardiac involvement. PAH, pulmonary arterial hypertension.

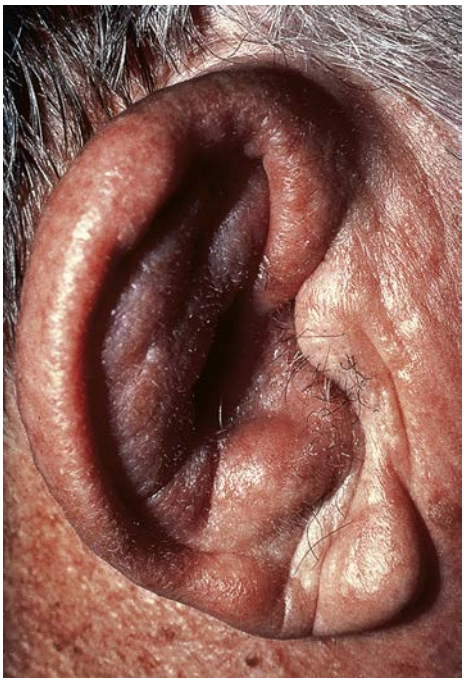

**Fig. 45.2 Relapsing polychondritis.** The inflammation spares the earlobes, which lack cartilage. Aortic insufficiency and dissecting aortic aneurysm are potential cardiac abnormalities associated with this condition. *Courtesy, Jeffrey P. Callen, MD.*

| EXAMPLES OF SKIN SIGNS OF GASTROINTESTINAL (GI) DISEASE | |
|---|---|
| **Disorder** | **Gastrointestinal disease/other** |
| **Genetic** | |
| Hereditary hemorrhagic telangiectasia (HHT) (see Ch. 87; Table 45.1; Fig. 45.1B) | • Recurrent hemorrhage in the upper GI tract due to AVMs<br>• Subset of patients have both juvenile GI polyposis due to mutations in *SMAD4*; associated risk of early onset colorectal cancer |
| Blue rubber bleb nevus syndrome (see Ch. 85; Fig. 45.3A) | • GI vascular malformations |
| Pseudoxanthoma elasticum (see Ch. 80; Table 45.2) | • Upper or lower GI hemorrhage |
| Ehlers–Danlos syndrome, vascular type (type IV) (see Ch. 80; Table 45.2) | • GI hemorrhage due to arterial rupture, intestinal perforation |
| Gardner syndrome (see Chs 90, 91, and 95) | • Hemorrhage from adenomatous colonic polyps. Adenocarcinoma of the colon is universal if the colon is not removed<br>• Congenital *h*ypertrophy of the *r*etinal *p*igment *e*pithelium (CHRPE) |
| Peutz–Jeghers syndrome (see Ch. 92; Fig. 45.3B) | • Hamartomatous polyps throughout the GI tract. Intussusception or hemorrhage may occur |
| Cowden disease (multiple hamartoma syndrome; PTEN hamartoma syndrome) (see Chs 52 and 91; Fig. 45.3C) | • Hamartomatous polyps throughout the GI tract. Bleeding is rare |
| Muir–Torre syndrome (see Ch. 91) | • Colorectal and gastric carcinoma > carcinoma of the small bowel |

**Table 45.3 Examples of skin signs of gastrointestinal (GI) disease.** *Continued*

| EXAMPLES OF SKIN SIGNS OF GASTROINTESTINAL (GI) DISEASE | |
|---|---|
| **Disorder** | **Gastrointestinal disease/other** |
| **Autoimmune/inflammatory** | |
| Ulcerative colitis (see Ch. 21; Table 45.4) | • Uniform and continuous inflammation of the large bowel. Rectal involvement is present in majority (>95%) of patients. Toxic megacolon may develop |
| Crohn disease (see Ch. 21; Fig. 45.4; Table 45.4) | • Chronic inflammation, often granulomatous, of the bowel. Skip areas occur |
| Cronkhite–Canada syndrome | • Adenomatous GI polyps, diarrhea, abdominal pain |
| Vasculitis (see Ch. 19) | • Ulcerations secondary to vasculitis of the vessels in the bowel. May be more common in IgA-associated vasculitis (Henoch–Schönlein purpura) |
| Malignant atrophic papulosis (Degos disease) (see Ch. 18) | • Small infarctions in the GI mucosa; hemorrhage and intestinal perforation may result in death |
| **Other** | |
| Scurvy (see Ch. 43) | • Collagen degeneration in the vasculature due to vitamin C deficiency. GI blood loss results in anemia |
| Kaposi sarcoma (see Ch. 94) | • Similar tumors may occur in the GI tract; possible complications include ulceration, bleeding, perforation and ileus, which are more common in HIV-associated than classic type |

**Table 45.3** *Continued* **Examples of skin signs of gastrointestinal (GI) disease.** AVMs, arteriovenous malformations.

| SKIN FINDINGS IN CROHN DISEASE AND ULCERATIVE COLITIS |
|---|
| • Erythema nodosum – often reflective of active bowel disease<br>• Urticaria<br>• Cutaneous small vessel vasculitis<br>• Cutaneous polyarteritis nodosa<br>• "Pustular" vasculitis or bowel-associated dermatosis–arthritis syndrome-like lesions<br>• Pyoderma gangrenosum – primarily the classic (typical) ulcerative form (see Fig. 21.5) or peristomal lesions (Fig. 45.4B); a vegetative pustular variant (pyoderma vegetans; see Fig. 21.9) occasionally occurs. These lesions may or may not reflect activity of the bowel disease<br>• Other neutrophilic dermatoses, ranging from acneiform lesions to Sweet syndrome and neutrophilic panniculitis<br>• Oral lesions<br>– Granulomatous infiltrates (with Crohn disease only)<br>– Aphthosis<br>– Angular cheilitis<br>– Pyostomatitis vegetans (mucosal variant of pyoderma gangrenosum)<br>• Contiguous (anogenital) and "metastatic" Crohn disease (Fig. 45.4A)<br>• Fistulae (perianal and abdominal)<br>• Genital lymphedema<br>• Perianal skin tags<br>• Acquired acrodermatitis enteropathica-like lesions (patients with zinc deficiency and/or essential fatty acid deficiency)<br>• Epidermolysis bullosa acquisita<br>• Psoriasis |

**Table 45.4 Skin findings in Crohn disease and ulcerative colitis.**

| PERISTOMAL SKIN DISORDERS | |
|---|---|
| **Skin disorder** | **Comments** |
| Irritant contact dermatitis | Most common cause of peristomal dermatitis, especially in patients with an ileostomy. Primarily attributed to exposure to feces or urine |
| Pre-existing skin disease (e.g. psoriasis, seborrheic dermatitis, atopic dermatitis) | Exclude primary contact dermatitis or infection or superimposed contact dermatitis |
| Cutaneous infection (*Candida* spp., dermatophyte, herpesvirus [primarily simplex], bacteria [especially *Staphylococcus aureus*]) | Colonization with bacteria and/or yeast is common. Recent treatment with antibiotics predisposes to candidiasis. May initially improve and then worsen if treated inappropriately with topical corticosteroids |
| Allergic contact dermatitis | Relatively uncommon. Potential allergens include adhesive pastes, adhesive ring or wafer of stoma bag, ostomy bag, epoxy resin, rubber, lanolin, and fragrances. Patch test with both standardized allergens and patient's own products |
| Pyoderma gangrenosum | Infrequent cause of peristomal dermatitis; most common in patients with inflammatory bowel disease (Fig. 45.4B) |
| Pseudo-verrucous papules and nodules | Seen more commonly in association with urostomies; may be misdiagnosed as verrucae |

**Table 45.5 Peristomal skin disorders.** Peristomal skin disorders are common and may limit use and efficacy of the stoma appliance. When the etiology is uncertain, evaluation can include KOH examination, microbial cultures, patch testing, and histopathologic examination. *Adapted from Lyon CC, Smith AJ, Griffiths CE, et al. The spectrum of skin disorders in abdominal stoma patients. Br J Dermatol. 2000;143:1248–1260.*

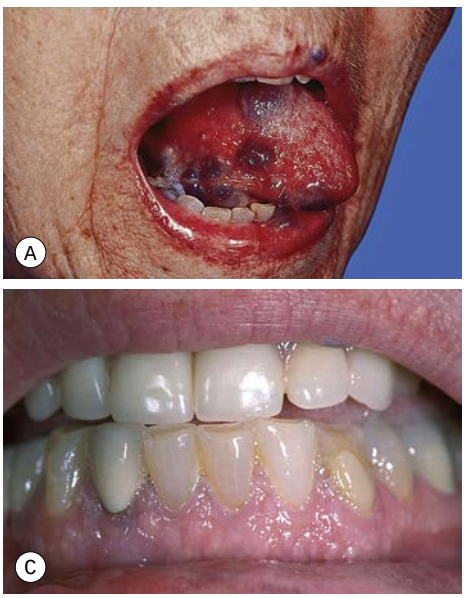


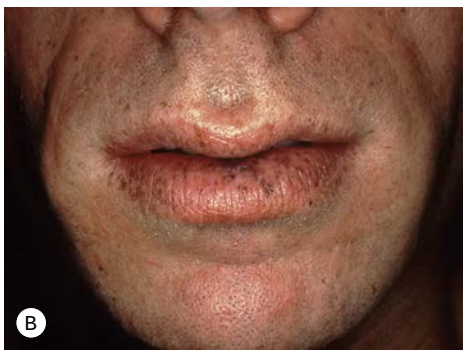


**Fig. 45.3 Skin signs of gastrointestinal disease. A** Blue rubber bleb nevus syndrome. Several venous malformations are evident on this patient's tongue. **B** Peutz–Jeghers syndrome. Multiple brown macules on the vermilion lips and a few on the lower cutaneous lip. **C** Gingival cobblestoning in Cowden disease. This patient also had tricholemmomas and a "Cowden nodule" or sclerotic fibroma on the neck. *A, C, Courtesy, Jeffrey P. Callen, MD; B, Courtesy, YDRSC.*

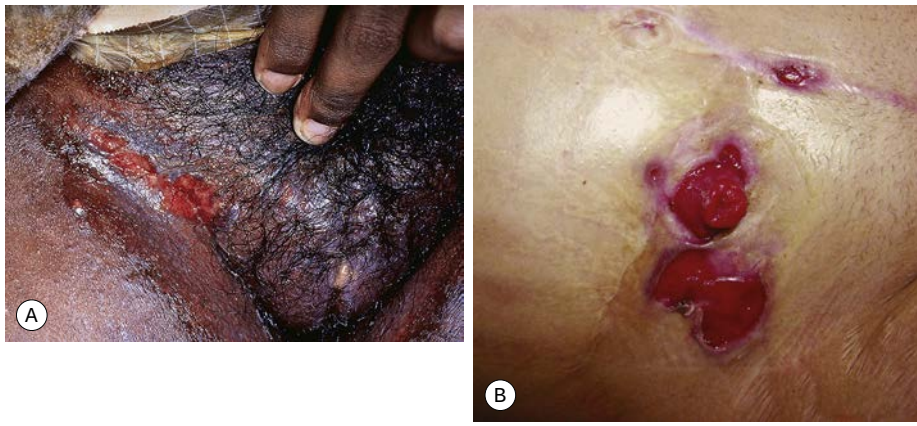


**Fig. 45.4 Skin signs of inflammatory bowel disease (IBD). A** "Metastatic" Crohn disease. Non-contiguous granulomatous inflammation of the skin is often manifested by deep inflammatory fissures in the inguinal folds. These have been described as "knife-like" fissures. **B** Peristomal pyoderma gangrenosum (PG) in the setting of inflammatory bowel disease. Patients with ostomies, particularly ileostomies, are at risk for peristomal dermatoses, including PG. Patients with IBD can also develop PG elsewhere on the skin (see Ch. 21; Figs 21.5–21.9) *Courtesy, Jeffrey P. Callen, MD.*

| EXAMPLES OF SKIN SIGNS OF LIVER DISEASE | | |
|---|---|---|
| **Disorder** | **Cutaneous findings** | **Other** |
| Cirrhosis | • Spider angiomas and other telangiectasias, palmar erythema, Terry and Muehrcke nails (see Ch. 58), pruritus, jaundice | • Gynecomastia<br>• Parotid enlargement |
| Primary biliary cholangitis (PBC) | • Jaundice, diffuse hyperpigmentation, pruritus, xanthomas (eruptive, planar, sometimes tuberous), may coexist with systemic sclerosis | • Ursodiol, fibrates, cholestyramine, rifampin, sertraline and naloxone may help to relieve the pruritus |
| Hepatitis B (HBV) and C (HCV) viral infections | • See Table 68.4<br>• Cutaneous sarcoidosis has been seen with interferon and/or ribavirin therapy<br>• Necrolytic acral erythema (Fig. 45.5) | • Treatment of chronic HBV and HCV infection depends on the type and severity of disease; includes specific antiviral agents, such as entecavir and tenofovir for HBV infection and direct-acting antiviral agents, often in combination with other agents, for HCV infection |
| Hemochromatosis ("bronze diabetes") | • Generalized hyperpigmentation | • Due to mutations in *HFE*, most commonly C282Y. Phlebotomy to reduce iron stores or chelation (e.g. deferasirox) |
| Wilson disease (hepatolenticular degeneration) | • Kayser–Fleischer ring<br>• Blue lunulae<br>• Pretibial hyperpigmentation | • Autosomal recessive; due to mutations in *ATP7B*<br>• Treatment with copper chelating agents (e.g. penicillamine) or metallothionein-inducer drugs (zinc acetate) |

**Table 45.6 Examples of skin signs of liver disease.**



**Fig. 45.5 Skin signs of liver disease.** Necrolytic acral erythema. This is a manifestation of hepatitis C viral infection. *Courtesy, Jeffrey P. Callen, MD.*




**Fig. 45.6 Skin signs that are associated with an internal malignancy in most or all cases.** **A, B** Bazex syndrome (acrokeratosis paraneoplastica). Acral psoriasiform lesions that have a violaceous hue, accompanied by nail dystrophy (**A**). This patient had an SCC of the tonsillar pillar. Thin hyperpigmented plaques of the helix and antihelix (**B**) in a patient with SCC of the pharynx. **C** Erythema gyratum repens. This patient had cancer of the breast. **D** POEMS syndrome. This patient had multiple angiomas (glomeruloid hemangiomas histopathologically) on his trunk as well as his face and scalp. In addition, he had peripheral neuropathy, adult-onset diabetes, hypothyroidism, and peripheral edema. His underlying disorder was an osteosclerotic myeloma. *A, C, D, Courtesy, Jeffrey P. Callen, MD; B, Courtesy, Jean L. Bolognia, MD.*

| EXAMPLES OF SKIN SIGNS OF RENAL DISEASE | |
|---|---|
| **Disorder** | **Renal disease/other** |
| **Genetic** | |
| Tuberous sclerosis complex (TSC) (see Ch. 50; Table 45.2) | • Renal hamartomas (angiomyolipomas). Polycystic kidney disease may occur in a contiguous gene syndrome with *TSC2* |
| Nail patella syndrome (see Ch. 58) | • Congenital nephrosis, glomerulonephritis |
| Birt–Hogg–Dubé syndrome (see Ch. 91; Table 45.1) | • Renal tumors, particularly chromophobe, oncocytic, and/or hybrid carcinomas |
| Hereditary leiomyomatosis and renal cell cancer (HLRCC; Reed syndrome; see Ch. 95) | • Predisposition to develop aggressive renal carcinoma |
| **Inflammatory/autoimmune** | |
| Systemic lupus erythematosus (see Ch. 33; Table 45.2) | • Glomerulonephritis – focal, membranous, or proliferative |
| Systemic sclerosis (see Ch. 35; Table 45.1) | • Hypertension, renal crisis |
| Henoch–Schönlein purpura (see Ch. 19) | • IgA-associated glomerulonephritis, which may be chronic |
| Polyarteritis nodosa (see Ch. 19) | • Renal artery aneurysms, renovascular hypertension, renal failure |
| Granulomatosis with polyangiitis (Wegener granulomatosis; see Ch. 19; Table 45.1) | • Glomerulonephritis |
| Cutaneous small vessel vasculitis (CSVV) (see Ch. 19) | • Glomerulonephritis may occur but is less common than in the vasculitides mentioned previously |
| **Other** | |
| Primary systemic amyloidosis (AL) (see Ch. 39; Table 45.2) | • Proteinuria, including nephrotic syndrome, and renal insufficiency |
| Cutaneous changes of end-stage renal disease | 1. Pale color, sallowness<br>2. Xerosis or acquired ichthyosis (see Fig. 4.3)<br>3. Pruritus (see Ch. 4)<br>4. Acquired perforating dermatosis (see Ch. 79 and Figs 4.3, 79.1, and 79.2)<br>5. Pseudoporphyria (see Ch. 41 and Fig. 41.8)<br>6. Calciphylaxis (see Ch. 42)<br>7. Uremic frost |
| Nephrogenic systemic fibrosis (NSF) (see Ch. 35 and Fig. 35.12) | • Occurs primarily in patients with dialysis-dependent chronic kidney disease in association with exposure to gadolinium-based contrast medium |

**Table 45.7 Examples of skin signs of renal disease.**

| PARANEOPLASTIC DERMATOSES | | |
|---|---|---|
| **Disorder** | **Cutaneous findings** | **Comments** |
| **Disorders that are associated with cancer in most or all cases** | | |
| Bazex syndrome (acrokeratosis paraneoplastica) | Acral psoriasiform plaques, typically with involvement of the nose and helices; often the lesions are violaceous (Fig. 45.6A,B). Longitudinal and horizontal ridging of the nails occurs in 75% of patients | By definition, this condition is linked to malignancy, generally occurring in the upper aerodigestive tract (pharynx, larynx, or esophagus) |
| Carcinoid syndrome | Flushing and erythema of the head and neck. Pellagra-like dermatitis and sclerodermoid changes may develop in advanced disease | Flushing associated with ~10% of midgut tumors (small intestine, appendix, proximal colon) and liver metastases are required; type III gastric and bronchial carcinoid tumors are also associated with flushing (liver metastases are not required) |
| Erythema gyratum repens | Concentric erythematous lesions, often giving the appearance of grains of wood (Fig. 45.6C; see Ch. 15) | Variable sites and types of malignancy |
| Acquired hypertrichosis lanuginosa (malignant down) | Growth of fine lanugo hairs in a generalized distribution or localized to the face. With time, these hairs may become coarser (see Ch. 57) | Associated with a variety of internal malignancies, most often carcinoma of the lung, colon, or breast |
| AESOP syndrome | Large red to violet-brown patch | Patch overlies a plasmacytoma |
| Ectopic adrenocorticotropic hormone (ACTH) syndrome | Generalized hyperpigmentation that may be accentuated in sun-exposed sites | Production of ACTH by a tumor (often a small cell carcinoma of the lung) may result in hyperpigmentation and features of Cushing syndrome |
| Glucagonoma syndrome | Necrolytic migratory erythema, angular cheilitis, glossitis | Due to a glucagon-secreting tumor of the pancreas. Patients are often treated for intertrigo before the syndrome is diagnosed. Weight loss and diabetes mellitus accompany the dermatosis |
| Paraneoplastic pemphigus | Erosive disease of the mucous membranes (see Fig. 23.8) and erythema multiforme-like, bullous pemphigoid-like, or lichenoid skin lesions (see Ch. 23) | Most often associated with non-Hodgkin lymphoma, chronic lymphocytic leukemia, or Castleman disease (with the latter accounting for the majority of cases in children and Asian populations). Castleman tumors have been shown to produce the autoantibodies responsible for paraneoplastic pemphigus, and their resection can lead to remission of mucocutaneous lesions. Bronchiolitis obliterans is a common complication |
| Tripe palms | Ridged velvety lesions on the palms | May or may not be accompanied by acanthosis nigricans |

**Table 45.8 Paraneoplastic dermatoses.** *Continued*

| PARANEOPLASTIC DERMATOSES | | |
|---|---|---|
| **Disorder** | **Cutaneous findings** | **Comments** |
| **Disorders that are strongly associated with cancer in a subset of cases** | | |
| Acanthosis nigricans | Rapid onset of hyperpigmented velvety changes of the flexural surfaces (e.g. neck, axillae, and groin). May also involve extensor surfaces (e.g. elbows, knees, and knuckles) and, in malignancy-associated cases, the lips, oral mucosa, and palms (see above, tripe palms). Glossitis is also frequently present in malignancy-associated acanthosis nigricans | Association with adenocarcinoma of the stomach or other sites within the GI or GU tracts; in this setting, acanthosis nigricans is often accompanied by weight loss. Acanthosis nigricans is more commonly associated with endocrinologic abnormalities, particularly insulin resistance (Figs 45.8 and 45.9); such patients are typically overweight, and the onset of the condition is usually insidious |
| Anti-epiligrin cicatricial pemphigoid*/anti-laminin 332 mucous membrane pemphigoid | Oral ulcerations, conjunctival erosions, and scarring. Tense blisters and erosions of the skin may also develop (see Ch. 24) | Roughly one-third of patients have or develop cancer within the first year following diagnosis. The cancer is usually an adenocarcinoma and is often at an advanced stage at the time of diagnosis, possibly accounting for the high mortality rate |
| Dermatomyositis (adult)* | Heliotrope, Gottron papules, photodistributed poikiloderma, nailfold overgrowth with dilated capillary loops, pruritus and diffuse scaling of the scalp (see Ch. 34) | Population-based studies demonstrate an overrepresentation of ovarian, lung, colorectal, and pancreatic carcinomas and non-Hodgkin lymphoma in Caucasians |
| Neutrophilic dermatoses | Sweet syndrome or pyoderma gangrenosum (particularly the atypical bullous form) (see Ch. 21) | Approximately 10–20% of cases are associated with hematologic disorders such as acute myelogenous leukemia or plasma cell dyscrasia (IgA). Underlying solid tumors are rare |
| **Disorders associated with a monoclonal gammopathy**** | | |
| Acquired angioedema due to C1 esterase inhibitor dysfunction | Acquired angioedema without associated wheals (see Ch. 14) | Associated with B-cell lymphoproliferative disorders, including lymphomas, as well as monoclonal gammopathy of undetermined significance (MGUS) |
| Amyloidosis, primary systemic | Waxy, translucent, or purpuric papules; periorbital and pinch purpura; macroglossia (see Ch. 39) | Monoclonal gammopathy due to plasma cell dyscrasia >> multiple myeloma; deposits composed of immunoglobulin light chain (AL) |
| Cryoglobulinemia, type I | Retiform purpura and necrosis that favors cooler acral sites; acral cyanosis; livedo reticularis (see Ch. 18) | Monoclonal gammopathy due to lymphoplasmocytic disorders |
| Necrobiotic xanthogranuloma | Indurated xanthomatous plaques with necrosis and ulceration, usually in a periorbital location (see Ch. 76) | Paraproteinemia (>80% of cases, most often IgG with κ light chains); multiple myeloma or a lymphoproliferative disorder develop in a minority of patients |

**Table 45.8** *Continued* **Paraneoplastic dermatoses.** *Continued*

| PARANEOPLASTIC DERMATOSES | | |
|---|---|---|
| **Disorder** | **Cutaneous findings** | **Comments** |
| Normolipemic plane xanthoma | Yellowish patches and thin plaques that favor the skin folds, upper trunk, and periorbital area (see Ch. 77) | Paraproteinemia, due to a plasma cell dyscrasia or lymphoproliferative disorder |
| POEMS syndrome (*p*olyneuropathy, *o*rganomegaly, *e*ndocrinopathy, *M*-protein, and *s*kin changes) | Although the glomeruloid hemangioma (see Fig. 45.6D) is considered to be pathognomonic, it is present in a minority of patients. Other skin findings include cherry angiomas, hyperpigmentation, hypertrichosis, sclerodermatous thickening, hyperhidrosis, digital clubbing, plethora, acrocyanosis, and leukonychia | Osteosclerotic myeloma, Castleman disease, and plasmacytomas have been reported in patients with POEMS. In addition to the findings designated in the acronym, patients may have peripheral edema, ascites, pulmonary effusions, papilledema, thrombocytosis, polycythemia, and increased serum levels of VEGF |
| Schnitzler syndrome | Chronic urticarial lesions; histopathologically, a neutrophil-rich dermal infiltrate is often seen (see Ch. 14) | Associated with an IgM usually κ paraproteinemia; lymphoplasmacytic malignancies develop in approximately 15% of patients. Additional manifestations include fevers, arthralgias, and bone pain |
| Scleromyxedema | Sclerodermoid induration plus firm, waxy papules arranged in linear arrays (see Ch. 38) | Almost always associated with paraproteinemia (usually IgG with λ light chains); multiple myeloma develops in <10% of cases |
| **Disorders that may be associated with cancer in a subset of patients** | | |
| Acquired ichthyosis | Resembles ichthyosis vulgaris; most often located on the legs | Lymphoma typically predates the diagnosis of the ichthyosis |
| Cutaneous small vessel vasculitis | Palpable purpura; may be widespread and/or in unusual locations (see Ch. 19) | Less than 5% of patients with vasculitis have an associated malignancy, most commonly plasma cell dyscrasias, myelodysplasia, myelo- or lymphoproliferative disorders, and hairy cell leukemia |
| Dermatitis herpetiformis (DH) | Pruritic erosions and blisters on extensor surfaces, scalp, and/or buttocks (see Ch. 25) | Through the association of DH with gluten-sensitive enteropathy, enteropathy-associated T-cell lymphoma occasionally |
| Exfoliative erythroderma | Diffuse, scaly, erythematous skin (see Ch. 8) | May be associated with cutaneous T-cell lymphoma or, occasionally, with a systemic lymphoma or leukemia |
| Juvenile xanthogranulomas (JXGs) in the setting of neurofibromatosis 1 (NF1) | Pink-yellow to red-brown, dome-shaped papules and nodules, most often located on the head and neck (see Ch. 76) | A triple association between JXGs, NF1, and JMML has been described |
| Multicentric reticulohistiocytosis | Nodular lesions, most often on the dorsal aspects of the hands (see Ch. 76) | A variety of associated malignancies have been reported, developing in approximately 25% of adult patients |

**Table 45.8** *Continued* **Paraneoplastic dermatoses.** *Continued*

| PARANEOPLASTIC DERMATOSES | | |
|---|---|---|
| **Disorder** | **Cutaneous findings** | **Comments** |
| Mycosis fungoides | Patch, plaque, or nodular disease (see Ch. 98) | Some studies have demonstrated an increased risk of second malignancies, especially other lymphoid malignancies |
| Porphyria cutanea tarda (PCT) | Erosions, blisters, and scars on the dorsal aspect of the hands, hyperpigmentation, hypertrichosis, milia (see Ch. 41) | Through its association with hepatitis C virus, PCT may also be associated with primary hepatocellular carcinoma (hepatoma) |
| **Disorders whose association with cancer is controversial** | | |
| Sign of Leser–Trélat | Rapid appearance or growth of multiple seborrheic keratoses; keratoses may be inflamed | Often these patients have acanthosis nigricans and generalized pruritus. Controversy continues regarding the existence of this sign in the absence of generalized pruritus and acanthosis nigricans, in part because determining whether seborrheic keratoses are eruptive can be difficult. Eruptive seborrheic keratoses can also develop in erythrodermic patients who do not have an underlying malignancy |

*Statistical association.
**For complete list, see Table 97.4.

**Table 45.8** *Continued* **Paraneoplastic dermatoses.** AESOP syndrome, adenopathy, extensive skin patch overlying (a) plasmacytoma; GU, genitourinary; JMML, juvenile myelomonocytic leukemia; VEGF, vascular endothelial growth factor.

| INTERNAL MALIGNANCIES IN FAMILIAL CANCER SYNDROMES WITH CUTANEOUS MANIFESTATIONS |
|---|
| • Cowden disease (breast, thyroid, and GI carcinomas), Muir–Torre syndrome (GI and GU carcinomas), Gardner syndrome (GI carcinoma), Peutz–Jeghers syndrome (various malignancies) – see Table 45.3 |
| • Costello syndrome (rhabdomyosarcoma, bladder carcinoma), Werner syndrome (sarcomas and other malignancies) |
| • Birt–Hogg–Dubé syndrome, hereditary leiomyomatosis and renal cell cancer – see Tables 45.1 and 45.7 |
| • Howel–Evans syndrome (esophageal carcinoma) – see Ch. 47 |
| • Ataxia–telangiectasia (leukemia, lymphoma, breast cancer) – see Ch. 49 and Fig. 49.1 |
| • Neurofibromatosis (malignant peripheral nerve sheath tumors, JMML, rhabdomyosarcoma, pheochromocytoma, carcinoid, breast cancer), tuberous sclerosis (renal carcinoma) – see Ch. 50 |
| • Multiple endocrine neoplasia syndromes – see Ch. 52, Table 52.2, and Fig. 52.2 |
| • Dyskeratosis congenita (leukemia, Hodgkin lymphoma) – see Table 55.6 and Fig. 55.18 |
| • Basal cell nevus syndrome (medulloblastoma, fibrosarcoma) – see Ch. 88 |
| • Bloom syndrome (lymphoproliferative and GI malignancies), Rothmund–Thomson syndrome (osteosarcoma), xeroderma pigmentosum (brain, especially sarcomas, and oral cavity [not just anterior tongue]) – see Table 73.5 |
| • Familial melanoma (pancreatic carcinoma, neural tumors, renal cell carcinoma, and gliomas, when mutations in *CDKN2A* [p16], *CDKN2A* [p14], *MITF*, and *POT1*, respectively; uveal melanoma, mesothelioma, renal cell carcinoma, and cholangiocarcinoma with *BAP1* mutations) |

**Table 45.9 Internal malignancies in familial cancer syndromes with cutaneous manifestations.** GU, genitourinary; JMML, juvenile myelomonocytic leukemia.



**Fig. 45.7 Paget disease of the breast.** A chronic, eroded erythematous plaque surrounds the nipple and is due to epidermal extension of an underlying ductal adenocarcinoma of the breast. Paget disease may also occur in extramammary locations (see Ch. 60). *Courtesy, Robert Hartmann, MD.*

| SELECTED DERMATOLOGIC ASSOCIATIONS OF DIABETES MELLITUS (DM) | | |
|---|---|---|
| **Dermatosis** | **Clinical description** | **Comments** |
| Acanthosis nigricans (AN) | Velvety hyperpigmentation of the intertriginous/flexural areas (Fig. 45.8A,B) and, less often, extensor surfaces (Fig. 45.8C) | Commonly associated with insulin resistance and most of the patients are obese. More common in Hispanics and individuals of African descent. Recent evidence strongly links AN in children with insulin resistance and diabetes |
| Acral dry gangrene | Necrosis of the toes > fingertips | Ischemia due to vascular disease in larger vessels |
| Acral erythema | Erysipelas-like blanching erythema of the hands and/or feet | May be due to small vessel occlusive disease with compensatory hyperemia |
| Carotenoderma | Diffuse orange-yellow skin color (see Fig. 43.13) | Related to an increase in serum carotene level |
| Diabetic bullae (bullosis diabeticorum) | Tense non-inflammatory bullae on the lower extremities (Fig. 45.10A) | Unknown pathogenesis |
| Diabetic cheiroarthropathy | Thickened skin and limited joint mobility of the hands and fingers, leading to flexion contractures (starting with the fifth digit and progressing radially) and an inability to approximate the palmar surfaces of the hands and fingers ("prayer sign"; Fig. 45.10F) | Postulated to result from increased glycosylation of collagen in the skin. Associated with retinopathy, nephropathy, and duration (but not control) of the DM |
| Diabetic dermopathy | Brown atrophic macules and patches on the legs (Fig. 45.10B) | Possibly precipitated by trauma |
| Disseminated granuloma annulare | Erythematous, often annular lesions composed of papules | There is controversy about the exact relationship of disseminated granuloma annulare and DM (see Ch. 78) |

**Table 45.10 Selected dermatologic associations of diabetes mellitus (DM).** *Continued*

| SELECTED DERMATOLOGIC ASSOCIATIONS OF DIABETES MELLITUS (DM) | | |
|---|---|---|
| **Dermatosis** | **Clinical description** | **Comments** |
| Eruptive xanthomas | Red-yellow papules that appear over a period of weeks to months; favor the extensor surfaces of the extremities and buttocks (Fig. 45.10C and see Ch. 77 and Figs 77.1–77.3) | Associated with elevated serum triglycerides in patients with poorly controlled diabetes. Control of the DM results in a disappearance of the xanthomas (see Ch. 77) |
| Hemochromatosis | Bronzing of the skin due to an increase in melanin rather than iron | Excess of iron stores associated with cirrhosis and cardiac dysfunction as well as DM. Due to mutations in *HFE*, most commonly C282Y. Also risk factor for porphyria cutanea tarda |
| Necrobiosis lipoidica | Yellow atrophic patches, most often on the shins. A red-brown rim may indicate activity at the border (Fig. 45.10D). Ulceration can occur and is often slow to heal | Develops in <1% of patients with DM; not always associated with DM (see Ch. 78) |
| Neuropathic leg ulcers | Non-painful ulcerations at sites of pressure, most commonly on the foot, including the plantar surface (Fig. 45.10E); a keratotic rim is characteristic | Associated with sensory neuropathy (see Ch. 86) |
| Perforating disorders (e.g. acquired perforating dermatosis) | Keratotic papules, primarily on the extremities | Often occurs in African-American diabetic patients with chronic kidney disease on dialysis (see Ch. 79) |
| Rubeosis | Chronic, flushed appearance of the face, neck, and upper extremities | Improved by dietary diabetic control. Flares with vasodilator therapies |
| Scleredema (adultorum of Buschke) | Erythematous induration of the upper back and nape due to glycosaminoglycan deposition; may have overlying erythema | Unknown etiology. No relationship to control of the DM; also referred to as type III scleredema |

**Table 45.10** *Continued* **Selected dermatologic associations of diabetes mellitus (DM).** Additional cutaneous conditions associated with DM include hirsutism (e.g. related to polycystic ovary syndrome or HAIR-AN – *h*yperandrogenemia, *i*nsulin *r*esistance, *a*canthosis *n*igricans; see Ch. 57), necrolytic migratory erythema (in the setting of DM due to a glucagon-secreting pancreatic tumor; see Table 45.8), compensatory and gustatory hyperhidrosis, and infections such as mucocutaneous candidiasis, erythrasma (especially the disciform variant), cellulitis, and necrotizing fasciitis. *Adapted from Jorizzo JL, Callen JP. Dermatologic manifestations of internal disease. In: Arndt KA, Robinson JK, LeBoit PE, et al (eds). Cutaneous Medicine and Surgery. Philadelphia: Saunders, 1996:1863–1889.*

| CRITERIA FOR THE CLINICAL DIAGNOSIS OF THE METABOLIC SYNDROME |
|---|
| • Elevated waist circumference (population- and country-specific definitions)<br>• Elevated triglycerides (≥150 mg/dl)<br>• Reduced HDL (<40 mg/dl in males; <50 mg/dl in females)<br>• Elevated blood pressure (systolic ≥130 and/or diastolic ≥85 mmHg)<br>• Elevated fasting blood glucose (≥100 mg/dl) |

**Table 45.11 Criteria for the clinical diagnosis of the metabolic syndrome.** Metabolic syndrome is identified by the presence of three or more of these five criteria. Drug treatment for dyslipidemia, hypertension, or hyperglycemia also fulfills the corresponding criterion. Most patients with type 2 diabetes mellitus meet criteria for metabolic syndrome.

| DERMATOLOGIC MANIFESTATIONS OF THYROID DISEASE | | |
|---|---|---|
| | **Hyperthyroidism** | **Hypothyroidism** |
| Cutaneous changes | Fine, velvety, smooth skin | Dry, rough, coarse skin |
| | Warm and moist due to increased sweating | Cold and pale |
| | | Boggy and edematous skin (myxedema) |
| | Hyperpigmentation – localized or generalized | Yellow discoloration as a result of carotenemia |
| | Pruritus | Easy bruising (capillary fragility) |
| Cutaneous diseases | Pretibial myxedema* (see Fig. 38.4), thyroid acropachy (acral soft tissue swelling, periostitis, and clubbing of the digits) | Acquired ichthyosis and palmoplantar keratoderma |
| | | Eruptive and/or tuberous xanthomas |
| | Urticaria, dermographism | Increased incidence of vitiligo |
| | Increased incidence of vitiligo | |
| Hair changes/ diseases | Fine, thin | Dull, coarse, brittle |
| | Mild, diffuse alopecia | Slow growth (increase in telogen hair phase) |
| | Increased incidence of alopecia areata | Alopecia of the lateral third of the eyebrows |
| | | Increased incidence of alopecia areata |
| Nail changes | Onycholysis | Thin, brittle, striated |
| | Koilonychia | Slow growth |
| | Clubbing from thyroid acropachy | Onycholysis (rare) |

**Can persist when patient is treated and becomes euthyroid or can be associated with euthyroid Graves disease.*

**Table 45.12 Dermatologic manifestations of thyroid disease.** Serum thyroid-stimulating hormone (TSH) level is the most reliable test of thyroid function; it is usually markedly suppressed in patients with hyperthyroidism. Additional laboratory findings in hyperthyroid patients include elevated free T3 and/or free T4 levels. Patients with primary hypothyroidism have elevated TSH levels and decreased free T4 levels. The detection of anti-thyroid peroxidase and/or anti-thyroglobulin antibodies suggests autoimmune thyroid disease (Hashimoto thyroiditis, Graves disease), while the presence of anti-TSH receptor antibodies points to Graves disease. Ascher syndrome consists of blepharochalasis, double lip, and goiter.

| DERMATOLOGIC MANIFESTATIONS OF ADRENAL DISORDERS | |
|---|---|
| **Cushing disease*** | **Addison disease** |
| **Altered subcutaneous fat distribution**<br>• Rounded "moon" facies<br>• Dorsal cervical fat deposition "buffalo hump" (Fig. 45.11A)<br>• Pelvic girdle fat deposition<br>• Reduced fat in the arms and legs | Hyperpigmentation (MSH-like effect of ACTH)<br>• Diffuse with accentuation in sun-exposed skin (Fig. 45.12)<br>• Prominent at sites of trauma<br>• Axillae, perineum, nipples<br>• Palmar creases<br>• Mucous membranes<br>• Hair<br>• Nails (longitudinal melanonychia)<br>• Melanocytic nevi and lentigines |
| **Skin atrophy**<br>• Multiple striae (Fig. 45.11B)<br>• Fragile skin<br>• Prolonged wound healing<br>• Purpura from minor trauma | Loss of androgen-stimulated (axillary, pubic) hair in postpubertal women |
| **Cutaneous infections**<br>• Pityriasis (tinea) versicolor<br>• Dermatophytosis and onychomycosis<br>• Candidiasis | Fibrosis and calcification of cartilage, including ear (rare) |
| **Adnexal effects**<br>• Acne<br>• Hirsutism | In patients with candidiasis endocrinopathy syndrome, vitiligo and chronic mucocutaneous candidiasis |

**Screening tests include late-night salivary cortisol, urine free cortisol (24-hour), 1-mg overnight low-dose dexamethasone suppression test (DST), and longer low-dose DST (2 mg/d for 48 hours).*

**Table 45.13 Dermatologic manifestations of adrenal disorders.** Both over- and underproduction of adrenal hormones lead to characteristic skin findings. The plasma adrenocorticotropic hormone (ACTH) level is elevated in Cushing disease (pituitary overproduction) and ectopic ACTH syndrome, whereas it is suppressed in patients with adrenal tumors. Plasma ACTH levels are also elevated in patients with primary adrenocortical insufficiency (Addison disease) and suppressed in secondary adrenocortical insufficiency due to exogenous corticosteroid administration. When adrenal insufficiency is suspected, including in patients receiving a prolonged course of corticosteroids, an ACTH stimulation test can provide useful information. MSH, melanocyte-stimulating hormone.




**Fig. 45.8 Acanthosis nigricans (AN).** **A** Involvement of the posterior neck in a young woman with obesity and insulin resistance. There is also an acrochordon. **B** Axillary involvement in an obese 10-year-old Filipino boy with insulin resistance and a strong family history of type 2 diabetes mellitus. **C** AN over the knuckles. AN can involve extensor surfaces as well as flexural areas. *A, Courtesy, Jeffrey P. Callen, MD; B, Courtesy Julie V. Schaffer, MD; C, Courtesy, Jean L. Bolognia, MD.*

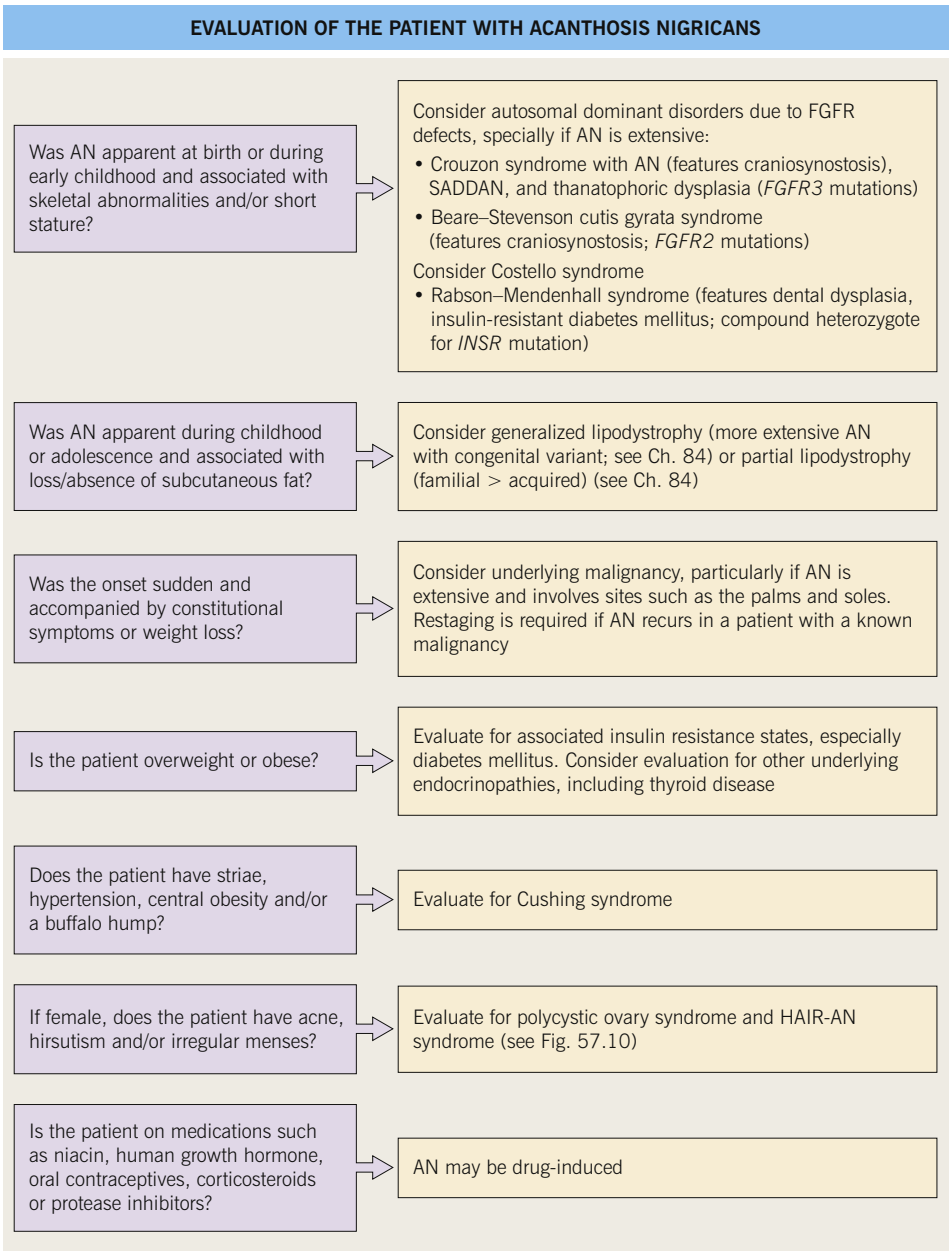


**Fig. 45.9 Evaluation of the patient with acanthosis nigricans (AN).** FGFR, fibroblast growth factor receptor; HAIR-AN, *h*yper*a*ndrogenemia, *i*nsulin *r*esistance, *a*canthosis *n*igricans; INSR, insulin receptor; SADDAN, severe *a*chondrodysplasia with *d*evelopmental *d*elay and *AN*.



















**Fig. 45.10 Skin signs of diabetes mellitus.** **A** Bullosis diabeticorum (diabetic bullae) with non-inflammatory bullae on the lower extremity. **B** Diabetic dermopathy characterized by brown macules and patches on the shins. **C** Eruptive xanthomas are frequently associated with poorly controlled diabetes mellitus. This patient was first discovered to have diabetes following the appearance of these yellow-red papules. **D** Necrobiosis lipoidica. This plaque on the shin has an inflammatory border and a yellow color with atrophy and telangiectasias centrally. Controversy exists about the exact risk of diabetes mellitus in such patients, but it is more strongly associated with diabetes than is granuloma annulare. **E** Neuropathic ulcers on the toes of a patient with diabetic sensory neuropathy. **F** Diabetic cheiroarthropathy (diabetic stiff hand syndrome). Because of limited joint mobility and thickening of the skin of the hand, the patient is unable to appose the palms ("prayer sign"). *A, C–E, Courtesy, Jeffrey P. Callen, MD; B, F, Courtesy, Jean L. Bolognia, MD.*




**Fig. 45.11 Skin signs of Cushing disease.** **A** "Buffalo hump" of Cushing syndrome due to fat redistribution. The patient also has evidence of hirsutism. **B** Cushing syndrome with multiple striae. *Courtesy, Judit Stenn, MD.*



**Fig. 45.12 Skin signs of Addison disease.** The hyperpigmentation (shown in contrast to the physician's hand) is accentuated in sun-exposed skin and can also involve sites of trauma, skin creases, and mucosae. *Courtesy, Jeffrey P. Callen, MD.*

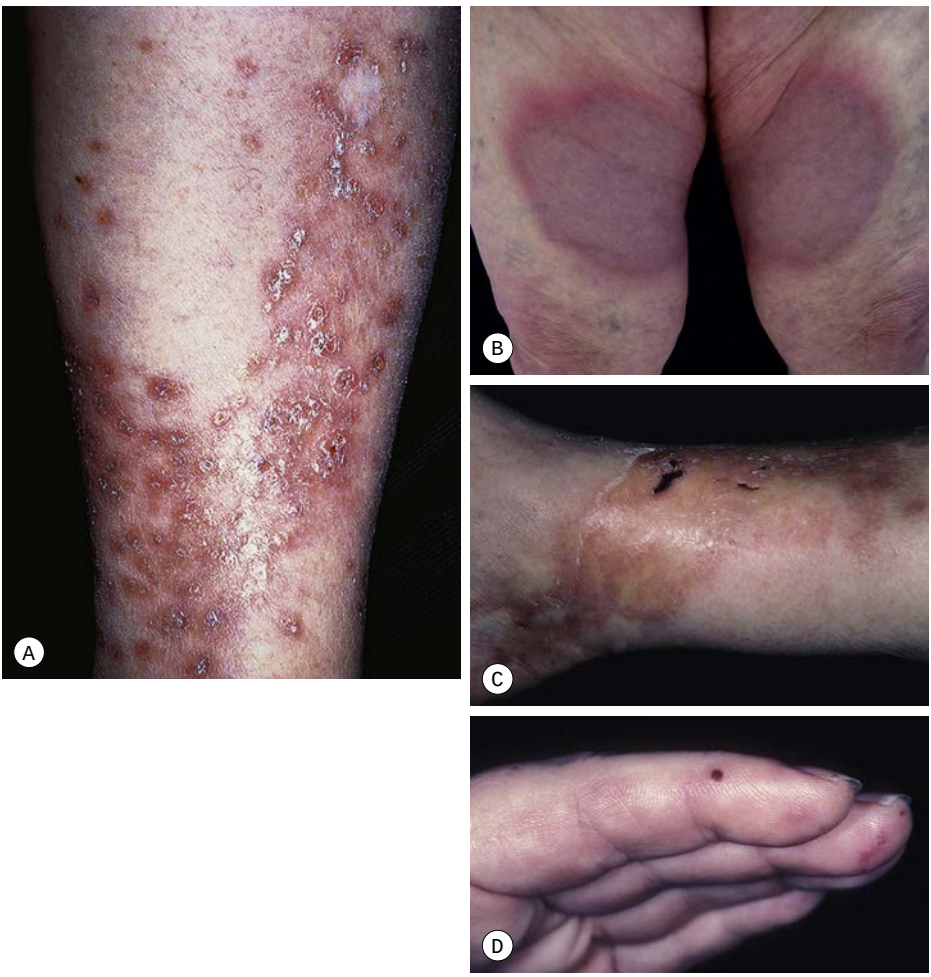


**eFig. 45.1 Cutaneous manifestations of rheumatoid arthritis (see Ch. 37). A** Rheumatoid papules. Multiple red-brown papules, some with scale-crust, on the lower extremity. This entity is within the spectrum of palisaded neutrophilic and granulomatous dermatitis (PNGD). **B** Annular variant of interstitial granulomatous dermatitis (IGD). This clinical presentation with annular plaques on the medial thighs is often seen in the setting of rheumatoid arthritis. Of note, IGD has also been implicated as a side effect of medications (e.g. statins, calcium channel blockers, TNF inhibitors). **C** Superficial ulcerating rheumatoid necrobiosis. Shiny, yellow plaques with red-brown edges and areas of ulceration that clinically resemble necrobiosis lipoidica. This patient had active rheumatoid arthritis. **D** Bywaters lesions. Tender purpuric papules on the distal fingers in a patient with rheumatoid vasculitis. Histopathologically, leukocytoclastic vasculitis is seen. *Courtesy, Jeffrey P. Callen, MD.*



A L G r a w a n y



**eFig. 45.2 Hereditary hemorrhagic telangiectasia.** Multiple small bright red macules and papules on the tongue and lips.
*Courtesy, Jeffrey P. Callen, MD.*







**eFig. 45.3 Skin signs of cardiac disease. A** Multiple tendinous xanthomas in a patient with familial hypercholesterolemia. **B** Antiphospholipid syndrome. In addition to bland thromboses, these patients may also have cardiac valve vegetations.
*A, Courtesy, Dermatology Department, Hospital Regional Honorio Delgado Espinoza de Arequipa Perú; B, Courtesy, Jeffrey P. Callen, MD.*



**eFig. 45.4 Peutz–Jeghers syndrome.** Multiple brown macules on the lips and oral mucosa.



**eFig. 45.5 Pyoderma gangrenosum in a patient with ulcerative colitis and relapsing polychondritis.** Central ulceration preceded by a violaceous bulla with an inflammatory border.
*Courtesy, Frank Samarin, MD.*




**eFig. 45.6 Skin signs that are associated with an internal malignancy in most or all cases.** **A,B** Paraneoplastic pemphigus (see Ch. 23). Lesions that resemble bullous pemphigoid on the leg (**A**) and in the mouth (**B**) in patients with immunopathologic confirmation of paraneoplastic pemphigus despite underlying malignancies not having been detected. **C** Multicentric reticulohistiocytosis (see Ch. 76). Multiple nodules are present on the dorsal hands in this adolescent. This patient did not have a malignancy. **D** Extramammary Paget disease (see Ch. 60). Eroded erythematous plaque with exudate, especially in the inguinal crease. The patient refused any further evaluation and had never undergone colonoscopy or cystoscopy. *Courtesy, Jeffrey P. Callen, MD.*




**eFig. 45.7 Acanthosis nigricans (AN). A** AN and acrochordons of the neck in the setting of insulin resistance and obesity. Note the velvety texture of the skin. **B** Diffuse involvement of the dorsal aspect of the fingers. Evaluation for an internal malignancy is recommended in patients with this type of clinical presentation. *A, Courtesy, Jeffrey P. Callen, MD; B, Courtesy, Joyce Rico, MD.*



**eFig. 45.8 Necrobiosis lipoidica.** Controversy exists about the exact risk of diabetes mellitus in such patients, but it is more strongly associated with diabetes than is granuloma annulare. *Courtesy, Jeffrey P. Callen, MD.*



**eFig. 45.9 Calciphylaxis.** This patient presented with these necrotic skin lesions and was found to have severe end-stage renal disease due to amyloidosis of the kidney. *Courtesy, Jeffrey P. Callen, MD.*

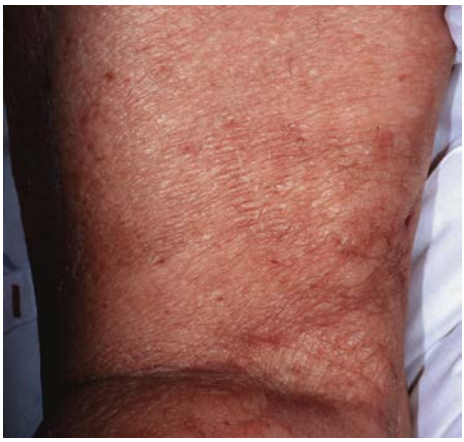

**eFig. 45.10 Nephrogenic systemic fibrosis.** This sclerosing disorder is seen almost exclusively in patients with renal failure who have received gadolinium-containing contrast media. In addition to the peau d'orange appearance of the skin, this patient had severe restriction of the movement of his hands, wrists, and feet. *Courtesy, Jeffrey P. Callen, MD.*

# 46 Ichthyoses and Erythrokeratodermas

- Ichthyoses and erythrokeratodermas represent a diverse group of disorders of cornification, which are characterized by a defective epidermal barrier due to abnormal differentiation and/or desquamation of keratinocytes.
- *Ichthyoses* feature diffuse scaling of the skin, often in a widespread distribution, whereas *erythrokeratodermas* present with circumscribed areas of hyperkeratosis without prominent scaling.
- These conditions usually have a genetic basis, with the occasional exception of acquired ichthyosis associated with disorders such as malnutrition, hypothyroidism, sarcoidosis, lymphoma, leprosy, or HIV infection.
- A thorough family history helps in recognizing the inheritance pattern; an affected parent suggests dominant inheritance, whereas inheritance in patients with unaffected parents may be autosomal recessive (especially with affected siblings or parental consanguinity), X-linked recessive (especially for a male patient with affected maternal male relatives), or dominant (e.g. due to a "new" mutation or with incomplete penetrance).
- Clinical features that are useful in determining the type of ichthyosis include the time of presentation (e.g. at birth, ± a collodion membrane, vs later in life), the quality and distribution of the scaling, other cutaneous manifestations (e.g. erythroderma, blistering, abnormal hair), and extracutaneous or laboratory findings (Table 46.1).
- A few ichthyoses such as epidermolytic ichthyosis have characteristic histologic features (see below).
- For conditions with a known molecular etiology, genetic testing can confirm the diagnosis in the patient and affected relatives as well as provide the basis for prenatal/preimplantation testing.

## Ichthyosis Vulgaris (IV)

- The most common disorder of cornification, with a prevalence of ~1 in 100 to 1 in 250.
- Autosomal semi-dominant inheritance – mild ichthyosis with a heterozygous filaggrin (*FLG*) mutation and more severe ichthyosis with mutations in both *FLG* alleles.
- Filaggrin deficiency results in impaired cornification, increased transepidermal water loss, enhanced penetration of irritants or allergens, and a propensity for inflammatory responses to the latter; this explains the association of *FLG* mutations with atopic dermatitis and increased risk of contact dermatitis (irritant and allergic) as well as IV.
- IV typically becomes apparent during infancy or early childhood and improves by adulthood; worsens in a cold, dry environment.
- Mild to moderate scaling favors the extensor extremities (Fig. 46.1), ranging from fine white scales to larger adherent scales (especially on the lower legs); the trunk, scalp, and forehead are occasionally affected, and flexural sites are characteristically spared.
- Associated findings include hyperlinear palms (Fig. 46.2), keratosis pilaris, and atopic dermatitis (25–50% of patients).
- **DDx:** xerosis, acquired ichthyosis, X-linked ichthyosis.
- **Rx:** emollients, humectants (e.g. urea), and keratolytic agents (e.g. lactic, salicylic, and glycolic acids); the latter group may be irritating in patients with coexistent atopic dermatitis.

## X-Linked Recessive Ichthyosis (XLRI; Steroid Sulfatase Deficiency)

- Incidence of ~1 in 5000 male births; almost exclusively affects boys and men,

| CLUES TO THE DIAGNOSIS OF ICHTHYOSES AND ERYTHROKERATODERMAS |
|---|
| **Cutaneous findings in neonates** |
| ***Collodion membrane:*** lamellar ichthyosis, CIE, "self-healing" form >> SLS, TTD, NLSD, others (e.g. infantile Gaucher disease, ectodermal dysplasias)<br>***Blisters/erosions/peeling:*** EI, superficial EI, Netherton syndrome, peeling skin syndromes<br>***Erythroderma:*** EI, CIE, Netherton syndrome, ichthyosis en confetti > SLS, TTD, NLSD, KID, CHH (along lines of Blaschko) |
| **Other findings** |
| ***Hair shaft abnormalities or hypotrichosis***: Netherton, TTD, KID, IFAP<br>***Ocular findings***: X-linked recessive ichthyosis, SLS, NLSD, TTD, KID§, IFAP§, CHH (unilateral), Refsum<br>***Sensorineural hearing impairment***: KID, NLSD > Refsum, CHH, CHILD<br>***Neurologic abnormalities/developmental delay***: SLS, NLSD, TTD, IFAP, Refsum<br>***Severe pruritus***: ichthyosis vulgaris (with atopic dermatitis), Netherton, SLS, inflammatory peeling skin syndrome<br>Also evaluate for microcephaly, facial dysmorphism, asymmetry, contractures, and hepatosplenomegaly. |
| **Initial evaluation of a neonate/infant with a collodion membrane or other signs of ichthyosis** |
| History<br>• Prenatal diagnoses, prolonged labor (suggestive of steroid sulfatase deficiency), prematurity<br>• Consanguinity makes autosomal recessive ichthyosis more likely<br>• Family history of epidermal nevi, ichthyosis, or erythrokeratoderma<br><br>Laboratory evaluation and additional assessment<br>• Complete blood count, electrolytes*, hepatic panel**, IgE level†; peripheral blood smear to evaluate for leukocyte vacuoles if suspect NLSD<br>• Trichoscopy and light microscopic evaluation of clipped hairs (scalp and eyebrows)<br>• ± Skin biopsy – e.g. if bullae (to assess for EI), to assess for diminished granular layer if suspect ichthyosis vulgaris, to detect dystrophic calcification if suspect CHH, or after resolution of collodion membrane for TGM-1 immunostaining<br>• Ophthalmologic examination, hearing screen, ± X-rays of epiphyses (if mosaic distribution, for stippling of CHH > CHILD)<br>• ***Consider genetic testing,*** especially a multigene panel if the diagnosis is not evident based on clinical and laboratory findings |
| *§Keratitis has variable onset.*<br>**Hypernatremic dehydration occurs primarily in collodion babies and neonates with Netherton syndrome, EI, or Harlequin ichthyosis.*<br>***Elevated transaminases are common in NLSD.*<br>*†Increased in Netherton and inflammatory peeling skin syndromes.* |

**Table 46.1 Clues to the diagnosis of ichthyoses and erythrokeratodermas.** The disorders in this table are discussed in greater detail in the text or Table 46.2. Other rare ichthyoses and related disorders can also present with these findings. CIE, congenital ichthyosiform erythroderma; CHH, Conradi–Hünermann–Happle syndrome; EI, epidermolytic ichthyosis; CHILD, congenital hemidysplasia with ichthyosiform nevus and limb defects; IFAP, ichthyosis follicularis with atrichia and photophobia; KID, keratitis–ichthyosis–deafness syndrome; NLSD, neutral lipid storage disease; SLS, Sjögren–Larsson syndrome; TGM-1, transglutaminase-1; TTD, trichothiodystrophy.

with transmission by asymptomatic female carriers.

• The underlying steroid sulfatase deficiency is caused by deletion of the entire *STS* gene on chromosome Xp22 in ~90% of patients; ~5% of patients have a larger contiguous gene deletion with manifestations that may also include Kallmann syndrome (hypogonadotropic hypogonadism with anosmia), X-linked recessive chondrodysplasia punctata, ocular albinism, and/or intellectual disability/autism. A higher prevalence of attention deficit hyperactivity disorder has also been reported in children with XLRI.

• Affected neonates may have generalized exfoliation of translucent scales, followed during infancy by the development of characteristic dark brown, polygonal, adherent scales favoring the neck, preauricular area, scalp (especially in young children), extremities,




**Fig. 46.1 Ichthyosis vulgaris.** Fine, whitish, flaky scales (**A**) and larger, darker scales (**B**) on the legs of children with skin phototypes II and IV, respectively. *A, Courtesy, Angela Hernández-Martín, MD; B, Courtesy, Julie V. Schaffer, MD.*

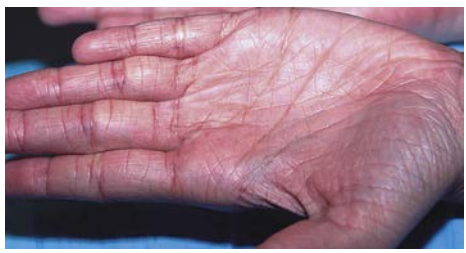

**Fig. 46.2 Hyperlinear palms in ichthyosis vulgaris.** *Courtesy, S. J. Bale, PhD, and J. J. DiGiovanna, MD.*

and trunk; the palms, soles, and flexural sites tend to be spared (Fig. 46.3).

- Often improves substantially in the summer.
- Associated findings include a perinatal history of prolonged labor due to low placental estrogen production (frequently resulting in birth via cesarean section), cryptorchidism, and asymptomatic corneal opacities.
- **Dx:** fluorescence *in situ* hybridization (FISH) or microarrays (targeted or whole-genome) can detect the underlying deletion in most patients; other methods include genetic testing, detection of increased (hydroxy) cholesterol sulfate (e.g. via increased migration of the β-fraction in serum lipoprotein electrophoresis), and measurement of leukocyte STS activity.
- Prenatal findings include decreased unconjugated estriol levels in maternal serum and the presence of non-hydrolyzed sulfated steroids in maternal urine.
- **Rx:** topical humectants, keratolytics, and retinoids.

## Epidermolytic Ichthyosis (EI; Bullous Congenital Ichthyosiform Erythroderma, Epidermolytic Hyperkeratosis [EHK])

- Uncommon autosomal dominant disorder due to mutations in the keratin 1 (*KRT1*) or keratin 10 (*KRT10*) gene; occasionally occurs in the offspring of an individual with an epidermolytic epidermal nevus due to a mosaic *KRT1/10* mutation that involves the gonads as well as the skin.
- Presents at birth with erythroderma, peeling skin, and erosions (Fig. 46.4A); sepsis, dehydration, and electrolyte imbalances may occur.
- Skin fragility decreases over time, with development of widespread hyperkeratosis that forms corrugated ridges in flexures and a cobblestone pattern on extensor surfaces of joints (Fig. 46.4B–D); palmoplantar keratoderma (PPK) is seen in patients with *KRT1* mutations.
- Other manifestations include episodic blistering, secondary skin infections, and a pungent body odor.
- Characteristic histologic changes of epidermolytic hyperkeratosis (e.g. keratinocyte vacuolization and clumped keratin filaments) help to establish the diagnosis.
- **DDx:** *in neonates* – epidermolysis bullosa, staphylococcal scalded skin syndrome, other erosive disorders (see Ch. 28); *in children/adults* – superficial EI, ichthyosis hystrix of Curth–Macklin, other ichthyoses with non-scaling hyperkeratosis (e.g. Sjögren–Larsson and KID syndromes).
- **Rx:** *in neonates* – protective isolation, emollients, and monitoring.
- **Rx:** *in children and adults* – emollients/humectants, mechanical exfoliation of hyperkeratotic areas, antiseptic washes

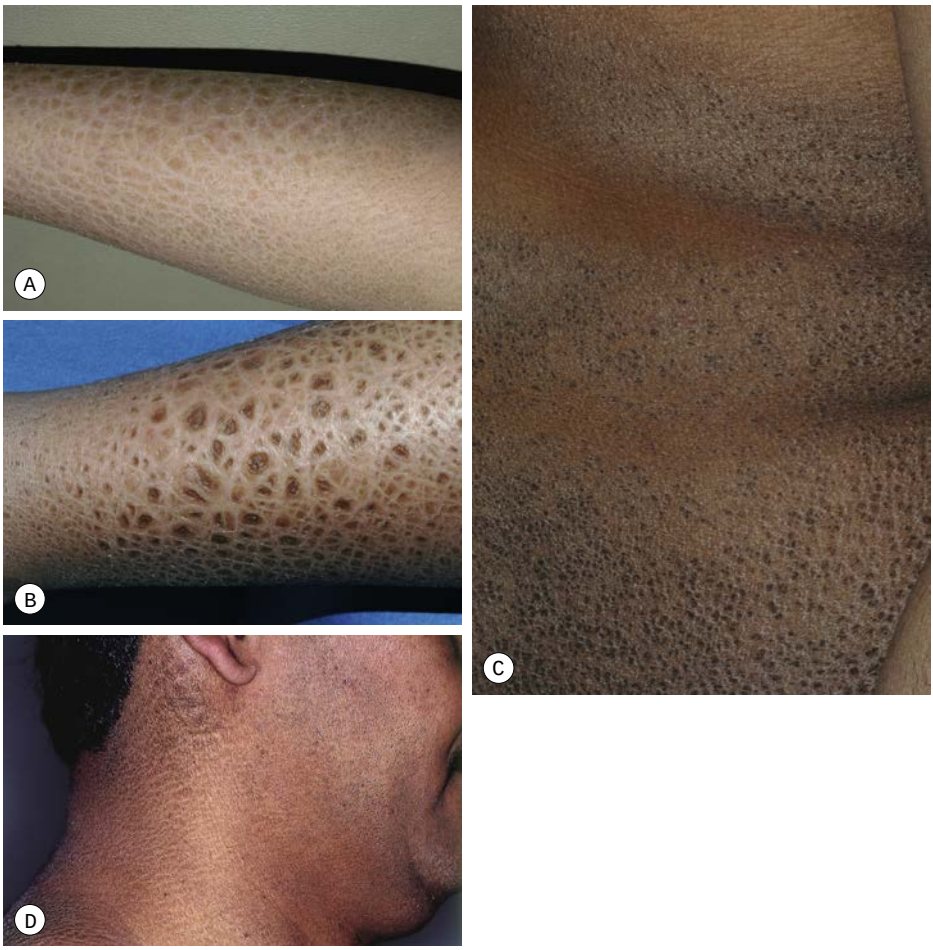


**Fig. 46.3 X-linked recessive ichthyosis.** Large light brown **(A)** and more prominent dark brown **(B)** scales on the lower leg. **C** Smaller dark brown scales on the trunk, with sparing of the skin folds. **D** Dark scales on the neck, sometimes referred to as a "dirty neck." *A–C, Courtesy, Julie V. Schaffer, MD; D, Courtesy, Gabriele Richard, MD, and Franziska Ringpfeil, MD.*

(e.g. dilute sodium hypochlorite baths), antimicrobial therapy for superinfections; keratolytics and retinoids (topical or oral) can improve hyperkeratosis but may lead to irritation and exacerbate skin fragility; widespread application of concentrated salicylic acid preparations should be avoided due to risk of salicylism.

- ***Superficial epidermolytic ichthyosis (ichthyosis bullosa of Siemens)*** is a related autosomal dominant condition due to mutations in the keratin 2 gene (*KRT2*), which is expressed only in the upper epidermis; affected individuals have milder, more superficial skin shedding ("molting"; Fig. 46.5), minimal erythema, and no PPK.
- ***Ichthyosis hystrix of Curth–Macklin***, which is caused by specific *KRT1* mutations, features hyperkeratosis (sometimes severe and spiky) and PPK similar to epidermolytic ichthyosis, but no skin fragility or histologic evidence of epidermolysis.
- ***Ichthyosis with confetti*** due to heterozygous frameshift mutations in *KRT10* > *KRT1* presents with ichthyosiform erythroderma at birth, with subsequent development of numerous small, confetti-like "islands" of normal skin that reflect revertant clones.

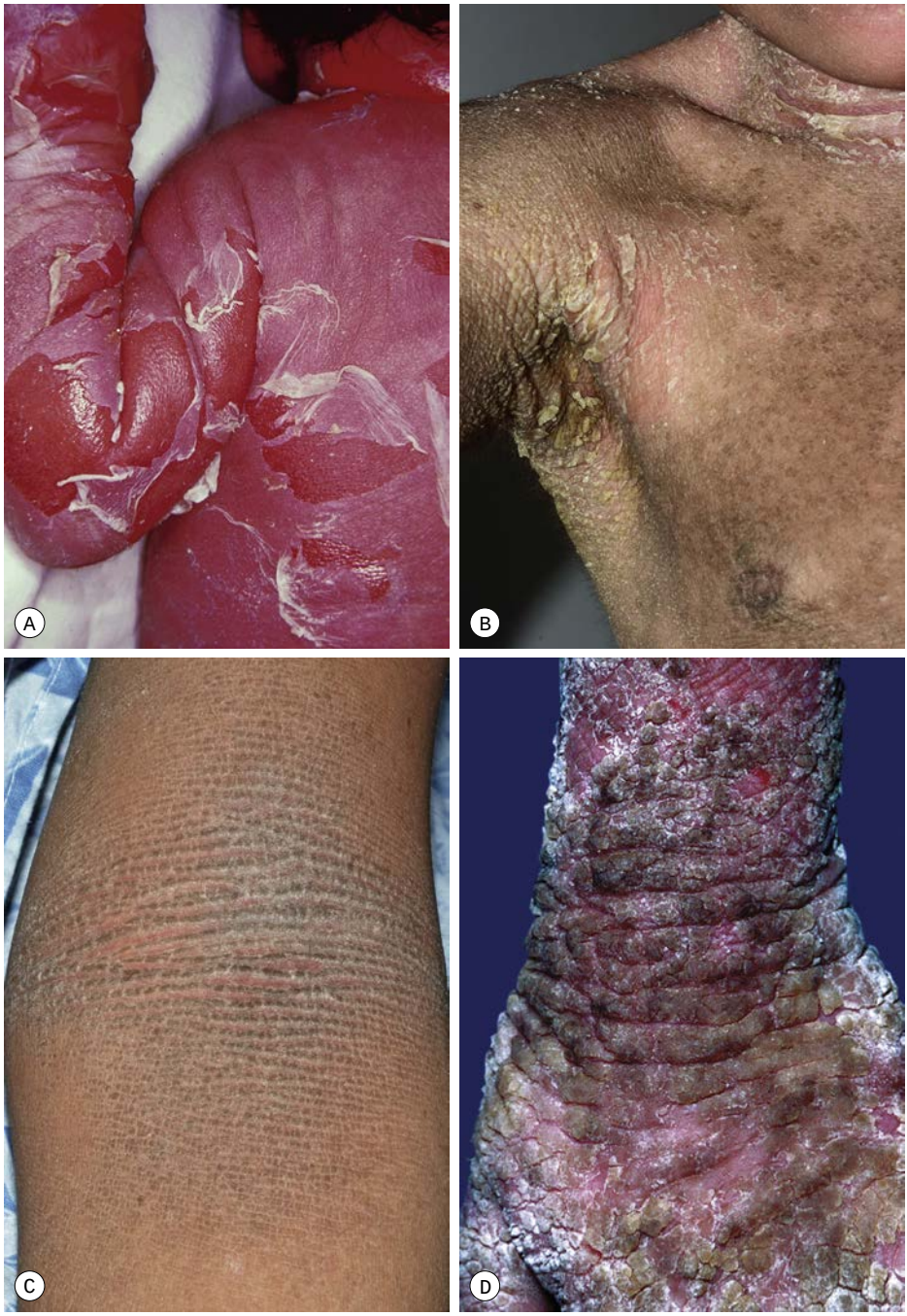


**Fig. 46.4 Epidermolytic ichthyosis.** **A** Erythroderma with widespread peeling and erosions during the neonatal period. **B** Later development of marked hyperkeratosis with focal erosions. **C** Corrugated hyperkeratosis in the antecubital fossa. **D** Hyperkeratosis with a cobblestone pattern on the dorsal hand. *A, Courtesy, Eugene Mirrer, MD; B, C; D, Courtesy, S. J. Bale, PhD, and J. J. DiGiovanna, MD.*

*Continued*




**Fig. 46.4** *Continued* **Epidermolytic ichthyosis. E** Severe palmoplantar keratoderma with digital contractures in a patient with a *KRT1* mutation. *E, Courtesy, Julie V. Schaffer, MD.*



**Fig. 46.5 Superficial epidermolytic ichthyosis.** Increased skin markings and "collarettes" where the skin has been superficially shed ("Mauserung"). *Courtesy, Anthony Mancini, MD.*

## Nonsyndromic Autosomal Recessive Congenital Ichthyosis (ARCI): Lamellar Ichthyosis and Congenital Ichthyosiform Erythroderma (CIE)

• Lamellar ichthyosis and CIE exist on a phenotypic spectrum, and nonsyndromic ARCI with these clinical findings can be caused by mutations in at least 11 different genes, including those encoding transglutaminase 1 (*TGM1*; most common), two lipoxygenases (*ALOX12B*, *ALOXE3*), and an ABC lipid transporter (*ABCA12*).

### Collodion Baby

• Infants with ARCI (and occasionally other ichthyoses; see Table 46.1) are often born covered by a taut, shiny, transparent membrane resembling plastic wrap, which leads to ectropion, eclabium, and distortion of the nose and ears (Fig. 46.6).
• Neonatal complications can include impaired sucking, restricted ventilation, fluid and electrolyte imbalances, skin infections, and sepsis.
• **Rx:** humidified incubator, emollients, and monitoring for complications; keratolytic agents and manual debridement of the membrane are *not* advised due to risk of systemic absorption and infection, respectively.
• Within 2 weeks, the membrane peels off in sheets and a transition to the underlying disease phenotype takes place; a subset of collodion babies with underlying mutations in *TGM1*, *ALOX12B*, *ALOXE3*, or other genes have a *self-improving collodion ichthyosis* phenotype where the skin is fairly normal in appearance when the membrane resolves.

### Lamellar Ichthyosis

• Characterized by large, brown, plate-like scales with little or no associated erythema (Fig. 46.7).
• Usually generalized, although involvement is limited to the trunk and scalp in the South African "bathing suit ichthyosis" variant (due to a particular *TGM1* mutation).
• Associated findings can include ectropion (which may result in conjunctivitis or keratitis), eclabium, scarring alopecia (especially of the peripheral scalp), PPK, nail dystrophy, and heat intolerance due to disruption of sweat ducts.
• **Rx:** oral retinoids (e.g. acitretin) for severe disease; use of topical retinoids (e.g. tazarotene) and keratolytics is limited by irritation and (for the latter agents) potential systemic absorption if applied to an extensive area; longitudinal ophthalmologic care can help to prevent complications of ectropion.

### Congenital Ichthyosiform Erythroderma

• Characterized by erythroderma and small white scales, often with a powdery consistency, in a generalized distribution (Fig. 46.8).
• The degree of erythema and type of scale varies, and phenotypic overlap with lamellar ichthyosis is often observed; for example, larger, darker scales may be evident, especially on the lower extremities, and some patients have relatively small scales but little associated erythema.
• PPK and nail dystrophy are frequently present, but ectropion and scarring alopecia are less common than in lamellar




**Fig. 46.6 Collodion baby.** **A** Day 1 with ectropion and eclabium. **B** Day 8 with erythema and diffuse mild scaling and misshapen ears. *Courtesy, YDRSC.*

ichthyosis; severe exfoliative erythroderma represents a substantial metabolic stress that can result in poor growth and failure to thrive in children.

- **Rx:** similar to lamellar ichthyosis, although oral retinoids are more beneficial for scaling than the associated erythema; increased intake of fluids, calories, and protein is required for erythrodermic patients. Considering that Th17-associated inflammation plays a role in this and other forms of ichthyosiform erythroderma, drugs that block this pathway may have potential therapeutic benefit.

## Other Ichthyoses and Erythrokeratodermas

- Major features of several additional ichthyoses and erythrokeratodermas are summarized in Table 46.2 (Figs 46.9–46.15); many other rare disorders of cornification with diverse cutaneous and extracutaneous manifestations also exist.

For further information see Ch. 57 from *Dermatology, Fourth Edition*.

**For additional online figures visit www.expertconsult.com**




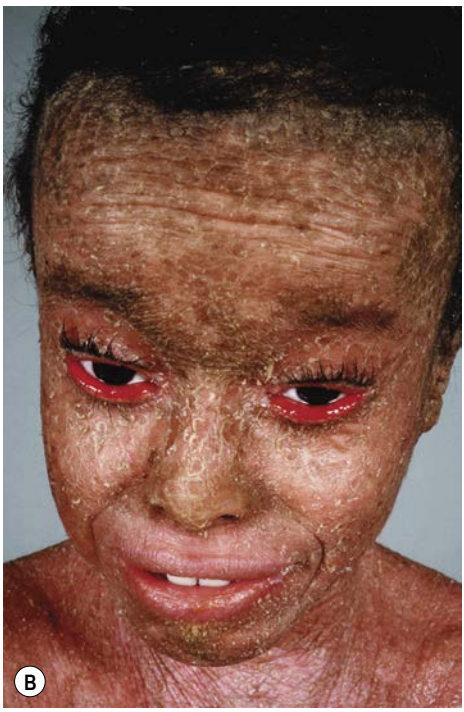


**Fig. 46.7 Lamellar ichthyosis. A** Large, plate-like scales on the lower extremities forming a mosaic pattern. **B** Obvious ectropion as well as plate-like scales. *A, Courtesy, Gabriele Richard, MD, and Franziska Ringpfeil, MD; B, Courtesy, NYUDSC.*










**Fig. 46.8 Congenital ichthyosiform erythroderma.** The differential diagnosis may include other causes of erythroderma (see Ch. 8). **A** Intense redness and fine, flaky, white scale on the trunk and arms. Close-up of fine white **(B)** and coarser yellowish **(C)** scale in a background of prominent erythema. *A, B, Courtesy, S. J. Bale, PhD, and J. J. DiGiovanna, MD; C, Courtesy, YDRSC.*



**Fig. 46.9 Harlequin ichthyosis.** Severe hyperkeratosis with fissuring as well as eclabium and ectropion. *Reproduced from Morillo M, Novo R, Torrelo A, et al. Feto arlequin. Actas Dermosifiliogr 1999;90:185–7.*

| MAJOR FEATURES OF OTHER SELECTED ICHTHYOSES AND ERYTHROKERATODERMAS | | |
|---|---|---|
| **Diagnosis** | **Gene, inheritance pattern** | **Major features** |
| **Other nonsyndromic ichthyoses** | | |
| Harlequin ichthyosis | *ABCA12* (or rarely *KDSR*), AR | • Extremely thick, armor-like plates of scale with deep fissures encase the neonate (Fig. 46.9)<br>• Extreme ectropion, eclabium, and deformities of the ear, nose, and hands/feet<br>• Often premature birth and neonatal death due to sepsis or respiratory insufficiency<br>• Acitretin therapy may allow survival with a severe CIE-like phenotype |
| **Syndromic ichthyoses presenting in the neonatal period** | | |
| Netherton syndrome | *SPINK5*, AR | • Erythroderma and peeling in neonates, with risk of hypernatremic dehydration and FTT<br>• Later ichthyosis linearis circumflexa (circinate erythematous plaques bordered with double-edged scale) or a CIE-like phenotype (Fig. 46.10A–C)<br>• Fragile hair with trichorrhexis invaginata ("bamboo hair"; eyebrow > scalp) (Fig. 46.10D)<br>• Pruritus, eczematous dermatitis, food allergies, elevated serum IgE, recurrent infections<br>• **DDx:** generalized inflammatory peeling skin syndrome (corneodesmosin mutations) |
| Sjögren–Larsson syndrome (SLS) | *ALDH3A2*, AR | • Pruritic non-scaling hyperkeratosis (Fig. 46.11) > scaling (fine to plate-like); favors abdomen, neck, flexures<br>• Spastic di- and tetraplegia, intellectual disability, perifoveal glistening white dots |
| Neutral lipid storage disease with ichthyosis (NLSD) | *ABHD5*, AR | • Generalized scaling (fine, plate-like on legs) with variable erythema<br>• Hepatomegaly, myopathy, developmental delay, hearing impairment, cataracts<br>• Lipid-containing vacuoles in leukocytes |
| Trichothiodystrophy with ichthyosis (TTD; Tay syndrome, [P]IBIDS) | *ERCC2* > *ERCC3* > *GTF2H5*, AR | • *P*hotosensitivity; *I*chthyosis: generalized scaling with minimal erythema beyond infancy<br>• *B*rittle hair (tiger-tail banding, trichoschisis) and nails<br>• *I*ntellectual impairment, *D*ecreased fertility, *S*hort stature, cataracts (occasionally) |

**Table 46.2 Major features of other selected ichthyoses and erythrokeratodermas.** *ABCA12*, ATP-binding cassette, subfamily A, member 12; *ABHD5*, abhydrolase domain-containing 5; *ALDH3A2*, aldehyde dehydrogenase 3A2; AR, autosomal recessive; CIE, congenital ichthyosiform erythroderma; *ERCC2/3*, excision repair cross-complementing 2/3; FTT, failure to thrive; *GTF2H5*, general transcription factor IIH, polypeptide 5; *KDSR*, 3-ketodihydrosphingosine reductase; *SPINK5*, serine protease inhibitor Kazal type 5. *Continued*

| MAJOR FEATURES OF OTHER SELECTED ICHTHYOSES AND ERYTHROKERATODERMAS | | |
|---|---|---|
| **Diagnosis** | **Gene, inheritance pattern** | **Major features** |
| **Syndromic X-linked dominant ichthyosiform conditions** | | |
| CHILD (congenital hemidysplasia with ichthyosiform nevus & limb defects) syndrome | *NSDHL*, X-D | • Unilateral erythematous, thickened skin with striking midline demarcation and a waxy surface or adherent scale in neonates (Fig. 46.12)<br>• Later less erythematous and more verrucous, with affinity for skin folds<br>• Ipsilateral skeletal abnormalities and organ hypoplasia |
| Conradi–Hünermann–Happle syndrome (CHH) | *EBP*, X-D | • Ichthyosiform erythroderma with feathery, adherent scale along the lines of Blaschko in neonates (Fig. 46.13)<br>• Later follicular atrophoderma along lines of Blaschko and patchy scarring alopecia<br>• Unilateral cataracts, asymmetric skeletal abnormalities, chondrodysplasia punctata (infants) |
| **Erythrokeratodermas** | | |
| Keratitis–ichthyosis–deafness (KID) syndrome | *GJB2*, AD | • Transient neonatal erythroderma; later well-demarcated, erythematous, furrowed hyperkeratotic plaques favoring the face and extremities (Fig. 46.14A) > diffusely thickened, grainy skin<br>• Cheilitis, stippled PPK (Fig. 46.14B), follicular keratoses, follicular occlusion triad, cysts<br>• Congenital sensorineural hearing impairment; progressive keratitis and conjunctivitis<br>• Recurrent mucocutaneous infections (especially candidiasis); risk of SCC (oral and cutaneous)<br>• **DDx:** *I*chthyosis *F*ollicularis, *A*trichia and *P*hotophobia (IFAP) syndrome (*MBTPS2*) |
| Erythrokeratodermia variabilis (EKV) | *GJB3* or *GJB4* > *GJA1*, AD | • Transient erythematous patches (Fig. 46.15A), especially in childhood (occasionally circinate)<br>• Fixed, geographic hyperkeratotic plaques on extremities and trunk (Fig. 46.15B); ± PPK<br>• **DDx:** progressive symmetric erythrokeratoderma (no transient lesions, often affects face), including *KDSR*-related erythrokeratoderma (thrombocytopenia) |

**Table 46.2** *Continued* **Major features of other selected ichthyoses and erythrokeratodermas.** Additional rare conditions include ichthyosis prematurity syndrome, Refsum disease, and erythrokeratodermia–cardiomyopathy syndrome. AD, autosomal dominant; *EBP*, emopamil binding protein (sterol isomerase); *GJB2/3/4* and *GJA1*, gap junction β2/3/4 and α1 (encoding connexins 26/31/30.3 and 43); *KDSR*, 3-ketodihydrosphingosine reductase; MBTPS2, membrane bound transcription factor peptidase, site 2; PPK, palmoplantar keratoderma; SCC, squamous cell carcinoma; X-D, X-linked dominant.

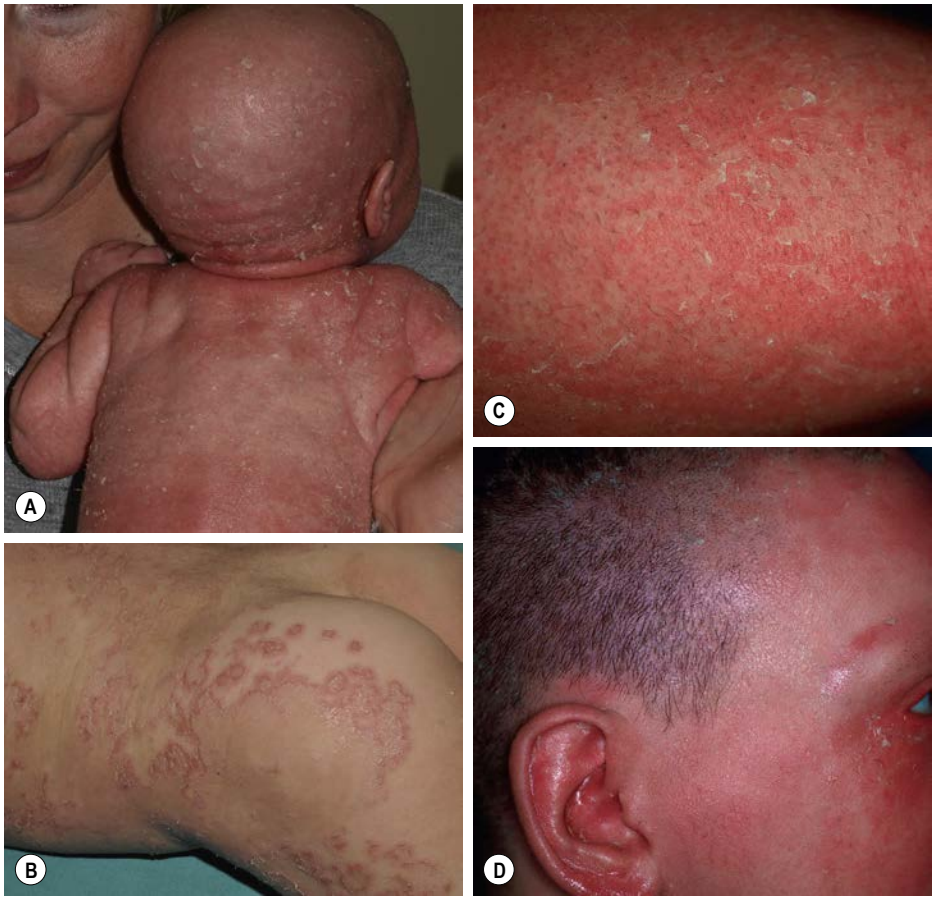


**Fig. 46.10 Netherton syndrome. A** Erythroderma in a neonate who also presented with hypernatremic dehydration. **B** Ichthyosis linearis circumflexa. Note the double-edged scale. **C** Close-up showing "peeling" quality of the scale. **D** Short, thin hair on the scalp, sparse eyebrows, and a lack of eyelashes. *A, Courtesy, Julie V. Schaffer, MD; B, Courtesy, Antonio Torrelo, MD; C, D, Courtesy, YDRSC.*



**Fig. 46.11 Sjögren–Larsson syndrome.** Yellowish-brown hyperkeratosis with accentuated skin markings. *Courtesy, Julie V. Schaffer, MD.*



**Fig. 46.12 CHILD syndrome.** Note the sharp midline demarcation on the trunk. *From Happle R, Mittag H, Kuster W. Dermatology 1995;191:210–6, with permission. Courtesy, Rudolph Happle, MD.*



**Fig. 46.13 Conradi–Hünermann–Happle syndrome.** Erythroderma and linear streaks and whorls of hyperkeratosis. *Courtesy, Rudolph Happle, MD.*




**Fig. 46.14 KID syndrome. A** Diffusely thickened, hyperkeratotic skin with a coarse-grained texture and an erythematous component; note the characteristic radial furrows around the mouth. **B** Bright pink, keratotic periorificial plaques with crusting. *Courtesy, Julie V. Schaffer, MD.*




**Fig. 46.15 Erythrokeratodermia variabilis.** **A** Transient erythematous patches and generalized brownish hyperkeratosis. **B** Symmetrically distributed hyperkeratotic plaques with hypertrichosis. *A, Courtesy, Gabriele Richard, MD, and Franziska Ringpfeil, MD; B, Courtesy, Julie V. Schaffer, MD.*

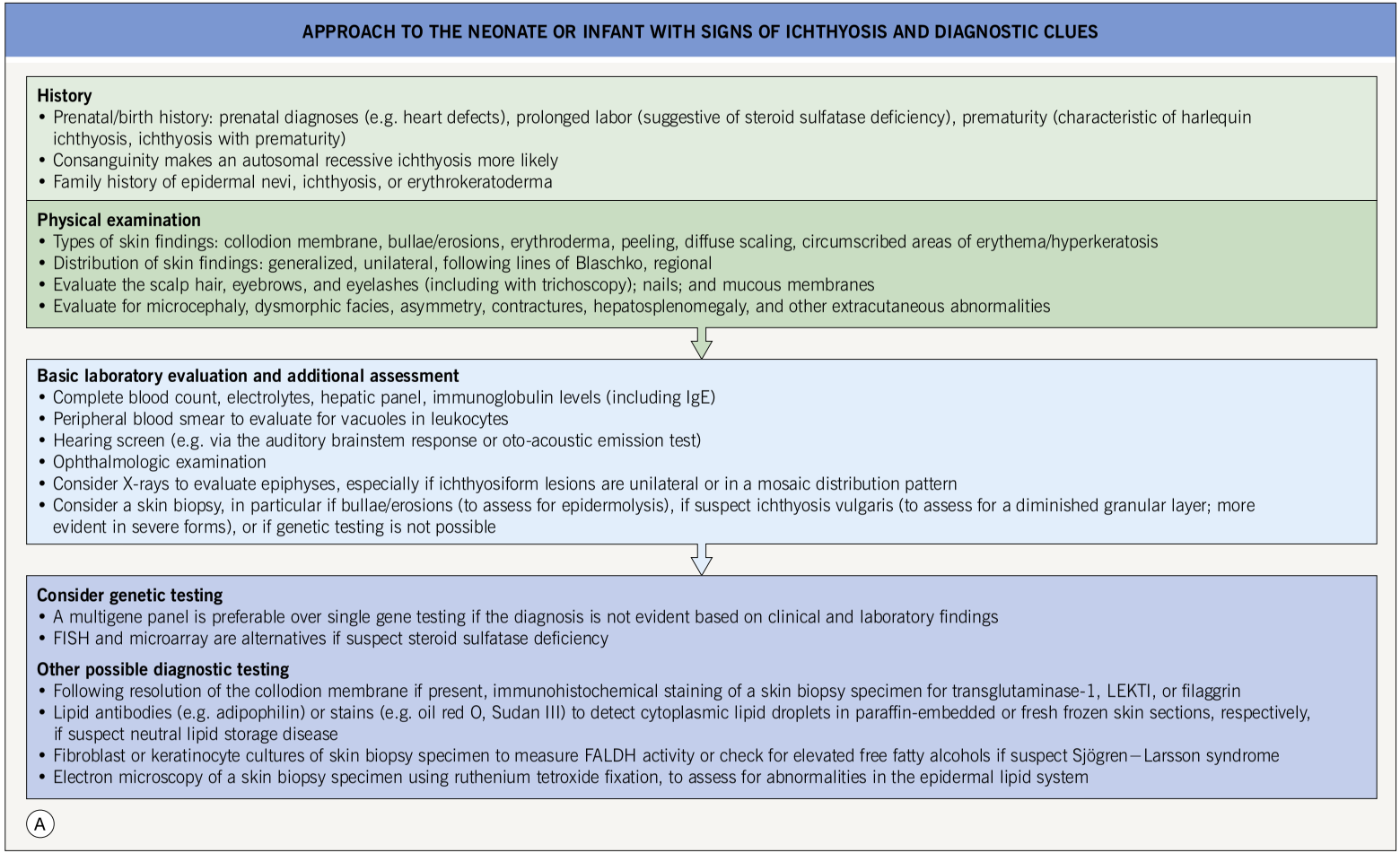


**eFig. 46.1 Approach to the neonate or infant with signs of ichthyosis and diagnostic clues.** *Continued*

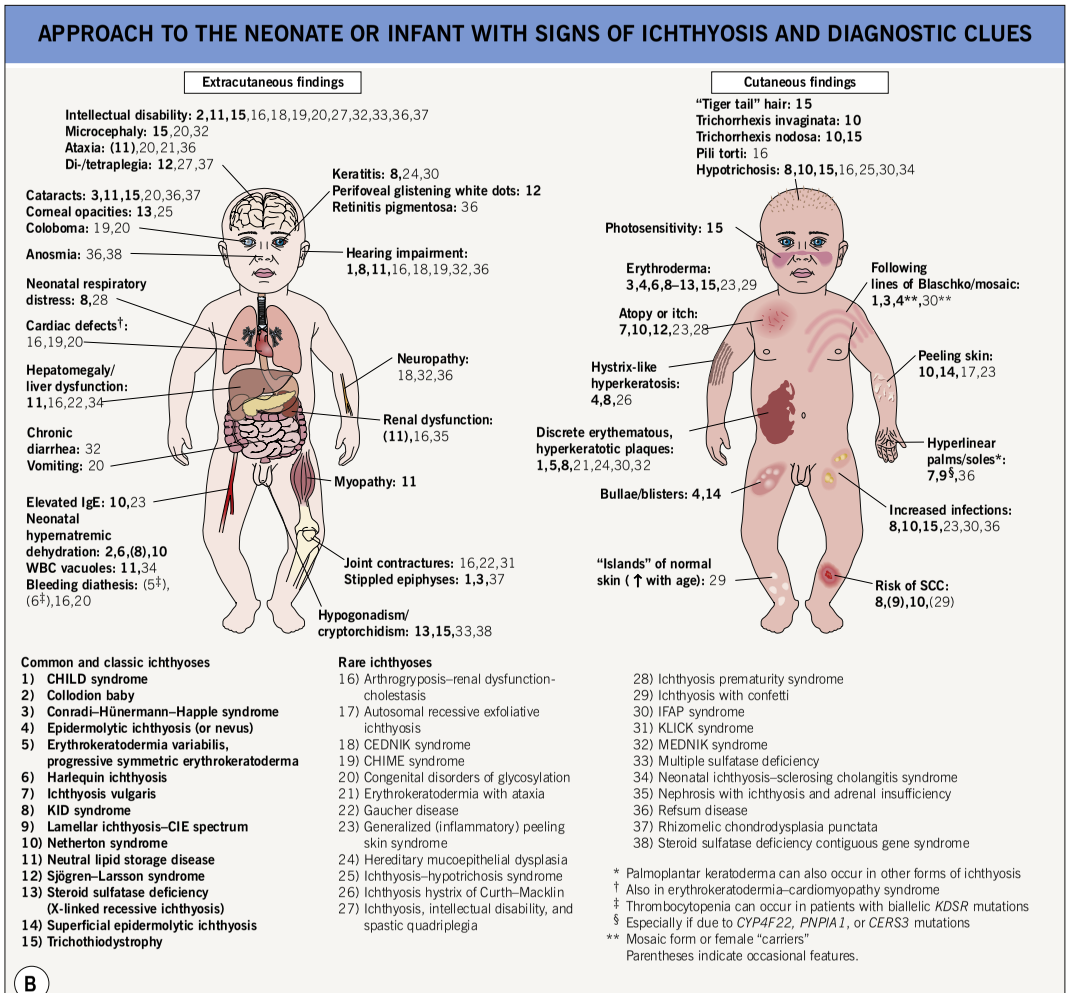


**eFig. 46.1** *Continued* **Approach to the neonate or infant with signs of ichthyosis and diagnostic clues.**

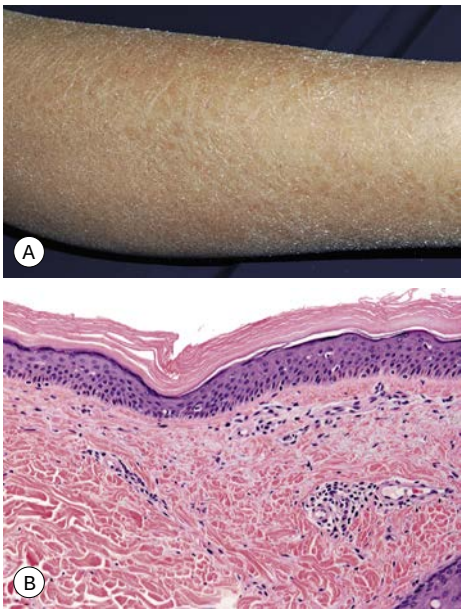


**eFig. 46.2 Ichthyosis vulgaris. A** Fine, white scales on the leg. **B** Histologically, orthokeratotic hyperkeratosis and a diminished granular layer are evident. *A, Courtesy, Julie V. Schaffer, MD; B, Courtesy, Lorenzo Cerroni, MD.*




**eFig. 46.3 Epidermolytic ichthyosis. A** Erythroderma with fine scaling and erosions on the face and thigh in an infant. **B** Hyperkeratosis with focal erosions. **C, D** Corrugated hyperkeratosis on the arm (**C**) and neck (**D**). *A, Courtesy, Angela Hernández-Martín, MD; B, Courtesy, Eugene Mirrer, MD; C, Courtesy, Julie V. Schaffer, MD.*

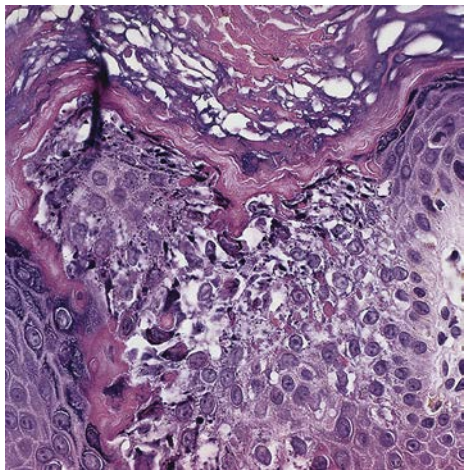

**eFig. 46.4 Histology of epidermolytic ichthyosis.** Striking ortho-hyperkeratosis, intracellular vacuolization of keratinocytes, and a prominent granular layer with clumped keratin filaments are seen.







**eFig. 46.5 Ichthyosis with confetti. A, B** Numerous small, confetti-like "islands" in the background of ichthyosiform erythroderma reflect revertant mosaicism. *Courtesy, Antonio Torrelo, MD.*



**eFig. 46.6 Lamellar ichthyosis.** Brown scales of various sizes with accentuation on the neck and in the axilla. *Courtesy, Julie V. Schaffer, MD.*



**eFig. 46.7 Netherton syndrome.** Generalized involvement with features of congenital ichthyosiform erythroderma. *Courtesy, YDRSC.*

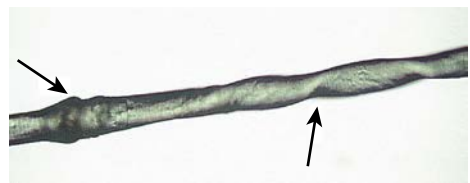

**eFig. 46.8 Abnormal hair shaft in Netherton syndrome.** Trichorrhexis invaginata with its ball-and-socket appearance (left arrow) and twist in the hair shaft (right arrow).



**eFig. 46.9 Ichthyosis linearis circumflexa.** Note the double-edged scale.



**eFig. 46.10 Sjögren–Larsson syndrome.** Yellowish-brown hyperkeratosis, accentuated skin markings and areas of scaling on the lower back and buttocks. *Courtesy, Julie V. Schaffer, MD.*

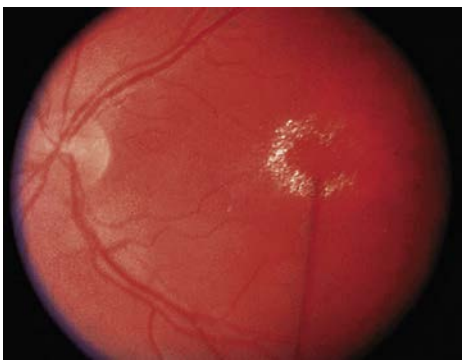

**eFig. 46.11 Sjögren–Larsson syndrome.** Perifoveal glistening white dots of the ocular fundus. *Courtesy, W. B. Rizzo, MD.*

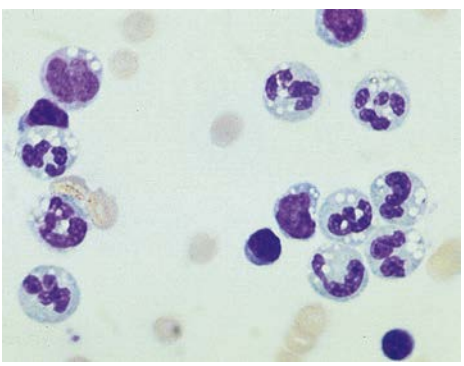

**eFig. 46.12 Neutral lipid storage disease.** Lipid droplets in circulating granulocytes and monocytes but not lymphocytes or erythrocytes. *Courtesy, Mary L. Williams, MD.*




**eFig. 46.13 KID syndrome. A** Erythematous plaques around the mouth have characteristic radial furrows. **B** Palmar keratoderma with a grainy surface. **C** Bright pink, keratotic periorificial plaques with crusting. **D** Plantar keratoderma with a grainy surface. *A, Courtesy, L. Russell, MD, and S. J. Bale, PhD; B, Courtesy, Gabriele Richard, MD, and Franziska Ringpfeil, MD; C, Courtesy, J. Tercedor, MD; D, Courtesy, Richard Antaya, MD.*



**eFig. 46.14 Erythrokeratodermia variabilis.** Symmetrically distributed hyperkeratotic plaques with hypertrichosis. *Courtesy, Gabriele Richard, MD, and Franziska Ringpfeil, MD.*




**eFig. 46.15 Progressive symmetric erythrokeratoderma. A, B** Well-demarcated, symmetrically distributed hyperkeratotic plaques with underlying erythema and/or hyperpigmentation. The patients also had a plantar keratoderma. **C** Note the overlying scale on the symmetric lesions. *B, C, Courtesy, Antonio Torrelo, MD.*



**eFig. 46.16 Conradi–Hünermann–Happle syndrome.** Epiphyseal stippling at the knee. *Courtesy, Jean L. Bolognia, MD.*

# 47 Keratodermas

- Palmoplantar keratodermas (PPKs) represent a group of hereditary and acquired disorders characterized by hyperkeratosis of the skin on the palms and soles.
- Three major types of involvement:
  - *Diffuse PPK*: confluent over the entire palmoplantar surface; onset by early childhood in hereditary forms, with initial erythema evolving into thick, yellow hyperkeratosis that may be waxy or verrucous (Fig. 47.1)
  - *Focal PPK*: primarily in areas of friction or pressure; the *areata/nummular* (oval) pattern affects the soles (Fig. 47.2A) > palms; the *striate* (linear) pattern extends from the palms to the volar fingers (Fig. 47.2B)
  - *Punctate PPK*: small (≤1 cm) keratotic papules on the palms and soles; onset is usually in adolescence or early adulthood, with initial pinhead-sized translucent papules that may become larger and callus-like (Fig. 47.3)
- Other possible features include hyperhidrosis, an erythematous border (see Fig. 47.1C), extension beyond the palmoplantar

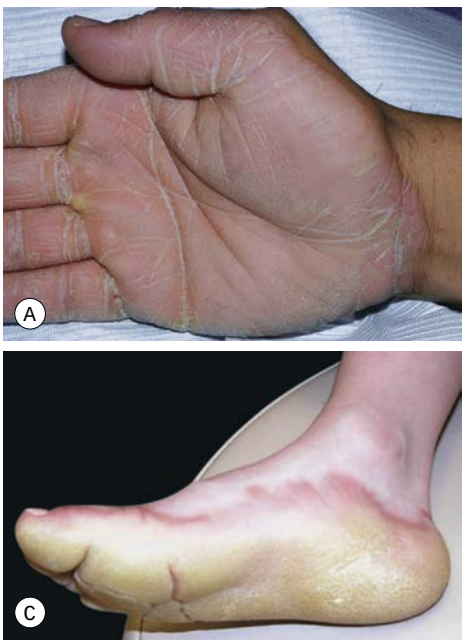





**Fig. 47.1 Diffuse palmoplantar keratoderma. A** Non-epidermolytic keratoderma with sharp demarcation at the wrist and side of the thumb. **B** Epidermolytic keratoderma with greater thickness in sites of pressure. **C** Epidermolytic keratoderma with prominent erythema at the border. In general, epidermolytic and non-epidermolytic forms cannot be distinguished clinically. *A, Courtesy, Julie V. Schaffer, MD; B, Courtesy, Dieter Metze, MD, and Vinzenz Oji, MD; C, Courtesy, Alfons L. Krol, MD, and Dawn Siegel, MD.*







**Fig. 47.2 Focal palmoplantar keratoderma.** **A** Areata type on the soles. **B** Striate type on the palm. *A, Courtesy, Alfons L. Krol, MD, and Dawn Siegel, MD; B, Courtesy, Dieter Metze, MD, and Vinzenz Oji, MD.*







**Fig. 47.3 Punctate palmoplantar keratoderma.** Keratotic papules, some coalescing to form plaques, on the palm **(A)** and soles **(B).** *A, Courtesy, Kalman Watsky, MD; B, Courtesy, YDRSC.*

skin (e.g. onto dorsal hands/feet, flexor wrists; "transgrediens"), digital constriction bands (pseudoainhum; Fig. 47.4B), and the histopathologic finding of epidermolytic hyperkeratosis ("epidermolytic PPK").

- Table 47.1 outlines major forms of PPK, either isolated or associated with additional cutaneous and extracutaneous manifestations (Figs 47.4–47.11).
- **Rx:** keratolytics (e.g. salicylic acid 4–6% in petrolatum, urea 40%), mechanical debridement, topical or oral retinoids; treatment of secondary fungal and bacterial infections.

For further information see Ch. 58 from *Dermatology, Fourth Edition*.

**For additional online figures and a table on palmoplantar pits, visit www.expertconsult.com**

| MAJOR FORMS OF PALMOPLANTAR KERATODERMA (PPK) | |
|---|---|
| **Forms with primarily cutaneous manifestations** | **Forms with adnexal and/or extracutaneous manifestations** |
| **Hereditary diffuse PPK** | |
| • **Isolated epidermolytic PPK**, *Vörner(–Unna–Thost) type* (AD, keratin 9 > 1)<br>• **Isolated non-epidermolytic PPK** (AD) | • **Deafness*** **+ "honeycombed" PPK** (AD, connexin 26) (Fig. 47.4)<br>• *Hidrotic ectodermal dysplasia* (*Clouston syndrome*): **hypotrichosis + nail dystrophy + grid-like acral papules** (Fig. 47.5, see Ch. 52)<br>• *Olmsted syndrome:* **mutilating PPK + periorificial plaques**<br>• *Papillion–Lefèvre syndrome:* **periodontitis + psoriasiform plaques + pyogenic infections** |
| • Other: e.g. ichthyoses & erythrokeratodermas (see Ch. 46), epidermolysis bullosa simplex (see Fig. 26.4B), Mal de Meleda (malodorous transgredient PPK) | |
| **Hereditary diffuse *or* focal PPK** (with infantile onset) | • **Woolly hair + arrhythmogenic cardiomyopathy†**: *Naxos disease* (**diffuse PPK**; AR, plakoglobin), *Carvajal syndrome* (**striate PPK**; AR>>AD, desmoplakin) |
| **Hereditary focal PPK** | |
| • **Isolated striate/areata PPK**: onset usually in childhood, increased severity with repetitive friction (AD; desmoglein 1, desmoplakin, keratin 1 or 6c) | • *Pachyonychia congenita:* **painful areata PPK** (soles > palms; often hyperhidrosis, blisters) **+ hypertrophic nail dystrophy** with wedge-shaped subungual hyperkeratosis (Fig. 47.7) ± follicular keratoses, oral leukokeratosis, steatocystomas/other cysts (esp. PC-17) > natal teeth (PC-17), pili torti (AD, keratin 6a > 16 or 17 > 6b or 6c)<br>• *Howel–Evans syndrome:* **esophageal carcinoma** (in adulthood) **+ areata PPK** (Fig. 47.6) **+ oral leukokeratosis + follicular keratoses** (AD)<br>• *Richner–Hanhart syndrome:* **dendritic keratitis** (in infancy) **+ areata PPK** (Fig. 47.8) **+ intellectual disability** |
| **Hereditary punctate PPK** | |
| • **Isolated punctate PPK§** (AD)<br>• **Punctate keratoses of the palmar creases§** (Fig. 47.9)<br>• *Acrokeratoelastoidosis/focal acral hyperkeratosis:* **small papules at margins of hands/feet** (Fig. 47.10) (AD) | • Other: e.g. Darier disease§ (see Ch. 48), PTEN hamartoma tumor syndrome§ (see Ch. 52)<br>• DDx: warts, punctate porokeratosis§ (see Ch. 89), arsenical keratoses (see Ch. 74) |
| • **Spiny keratoderma** (AD) | |
| **Acquired PPK** | |
| • *Keratoderma climactericum:* **focal PPK on heels/weight-bearing areas of soles, esp. in women >45 y of age**; associated with obesity, cold climate, backless shoes<br>• DDx**:** see Table 13.1 and Fig. 13.1 | • Associations: **hypothyroidism**, **cancer** (e.g. lung, GI), **drugs** (e.g. sorafenib)<br>• *Aquagenic PPK:* **thickening + white/translucent "pebbling" of palms > soles upon water immersion** (Fig. 47.11); usually isolated, but affects >50% of cystic fibrosis patients |

**Deafness + PPK may also occur in mitochondrial disorders.*
*†Cardiac disease usually becomes evident after puberty and can present with sudden death; desmocollin 2 mutations have also been described.*
*§May leave a pit upon removal of the keratotic plug; DDx of palmoplantar pits also includes pitted keratolysis (see Ch. 61) and basal cell nevus syndrome (see Ch. 88).*

**Table 47.1 Major forms of palmoplantar keratoderma (PPK).** The most common types in children and adults are shaded pink and yellow, respectively. Selected genetic etiologies are in parentheses. AD, autosomal dominant; AR, autosomal recessive.




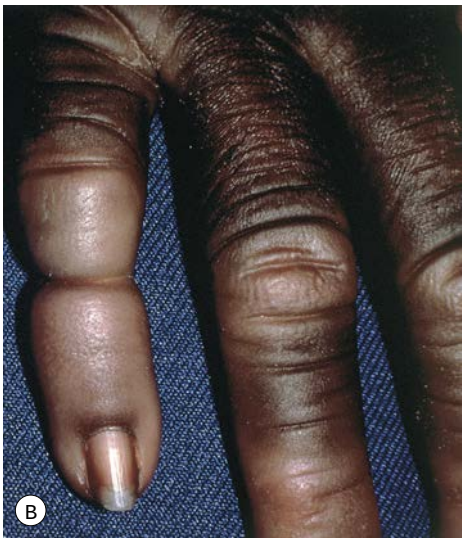


**Fig. 47.4 Palmoplantar keratoderma associated with deafness due to connexin 26 mutations. A** Diffuse "honeycombed" keratoderma on the sole. **B** Pseudoainhum formation in Vohwinkel syndrome, which can also feature "starfish" keratoses on the knuckles. **C** Leukonychia and knuckle pads in Bart–Pumphrey syndrome. *A, C, Courtesy, Alfons L. Krol, MD, and Dawn Siegel, MD; B, Courtesy, YDRSC.*



**Fig. 47.5 Hidrotic ectodermal dysplasia (Clouston syndrome).** Note the "pebbled" skin on the dorsal aspect of the toes as well as the dystrophic nail plates. *Courtesy, D. Sasseville, MD, and R. Wilkinson, MD.*



**Fig. 47.6 Howel–Evans syndrome.** Focal palmoplantar keratoderma, usually with onset at 5–15 years of age, associated with development of carcinoma of the esophagus in adulthood. *Courtesy, Alfons L. Krol, MD, and Dawn Siegel, MD.*




**Fig. 47.7 Pachyonychia congenita.** **A** Painful focal plantar keratoderma with associated erythema and blistering. **B** Plantar hyperkeratosis accentuated over pressure points. **C** Steatocystomas in the axilla. **D, E** Hypertrophic nail dystrophy with wedge-shaped subungual hyperkeratosis. *A, Courtesy, Alfons L. Krol, MD, and Dawn Siegel, MD; B, D, Courtesy, Julie V. Schaffer, MD; C, Courtesy, J. Valverde, MD; E, Courtesy, YDRSC.*



**Fig. 47.8 Richner–Hanhart syndrome (tyrosinemia II).** Focal painful keratoses on the plantar surface in a patient with corneal ulcers and intellectual disability. In this disorder, the onset of keratoderma ranges from early childhood to adolescence. *Courtesy, Jean L. Bolognia, MD.*



**Fig. 47.9 Punctate keratoses of the palmar creases in an African American.** *Courtesy, YDRSC.*



**Fig. 47.11 Aquagenic keratoderma.** White "pebbly" changes on the palm following immersion in water for a few minutes in a healthy teenage girl. *Courtesy, Julie V. Schaffer, MD.*







**Fig. 47.10 Marginal papular keratoderma.** **A** Acrokeratoelastoidosis presenting with multiple skin-colored to yellowish papules at the margin of the palmar skin. **B** Focal acral hyperkeratosis presenting with umbilicated keratotic papules at the margin of volar skin in an African-American woman. *A, Courtesy, YDRSC; B, Courtesy, Boni Elewski, MD.*

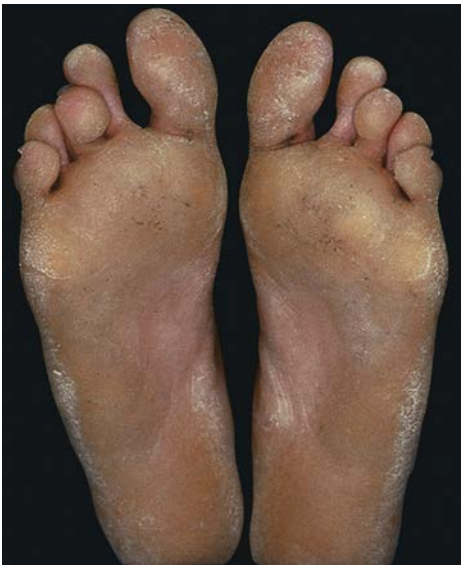

**eFig. 47.1 Diffuse palmoplantar keratoderma.** Hyperkeratosis of the entire plantar surface with sharp demarcation. *Courtesy, Alfons L. Krol, MD, and Dawn Siegel, MD.*



**eFig. 47.2 Diffuse palmoplantar keratoderma.** Hyperkeratosis of the entire palmar surface. *Courtesy, Dieter Metze, MD, and Vinzenz Oji, MD.*




**eFig. 47.3 Focal palmoplantar keratoderma. A, B** Striate type on the palm. **C** Areata type on the soles. The patient in **C** has an incidental digital anomaly. *A, C, Courtesy, Dieter Metze, MD, and Vinzenz Oji, MD; B, Courtesy, YDRSC.*




**eFig. 47.4 Punctate palmoplantar keratoderma.** Keratotic papules, some coalescing to form plaques, on the palms **(A, B)** and soles **(C).** *A, B, Courtesy, Dieter Metze, MD, and Vinzenz Oji, MD; C, Courtesy, YDRSC.*

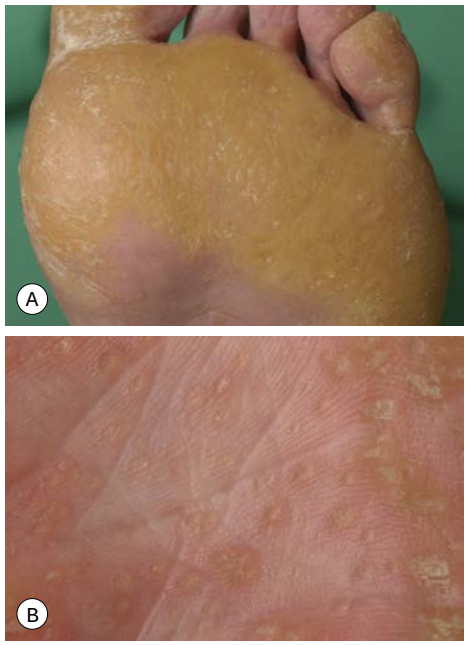


**eFig. 47.5 Punctate palmoplantar keratoderma. A** Lesions can coalesce over pressure points on the sole. **B** Close-up view of coalescing small keratotic papules on the palm. *Courtesy, Dieter Metze, MD, and Vinzenz Oji, MD.*



**eFig. 47.6 Diffuse epidermolytic palmoplantar keratoderma.** Diffuse, hyperkeratosis with waxy surface on the palm, with sharp demarcation. Note the red borders. *Courtesy, Dieter Metze, MD, and Vinzenz Oji, MD.*

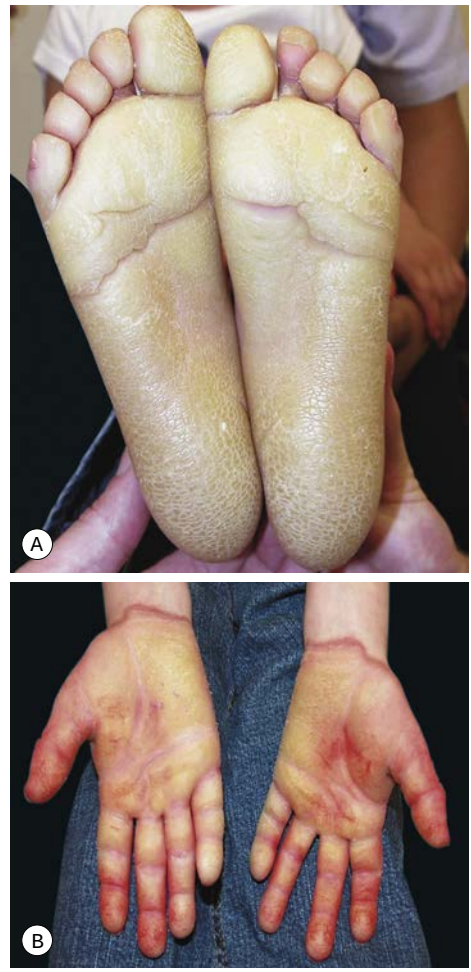


**eFig. 47.7 Diffuse epidermolytic palmoplantar keratoderma. A** Diffuse hyperkeratosis on the soles. **B** Erythema is present at the border on the flexor wrist as well as in areas where there is reduced hyperkeratosis. *Courtesy, Alfons L. Krol, MD, and Dawn Siegel, MD.*

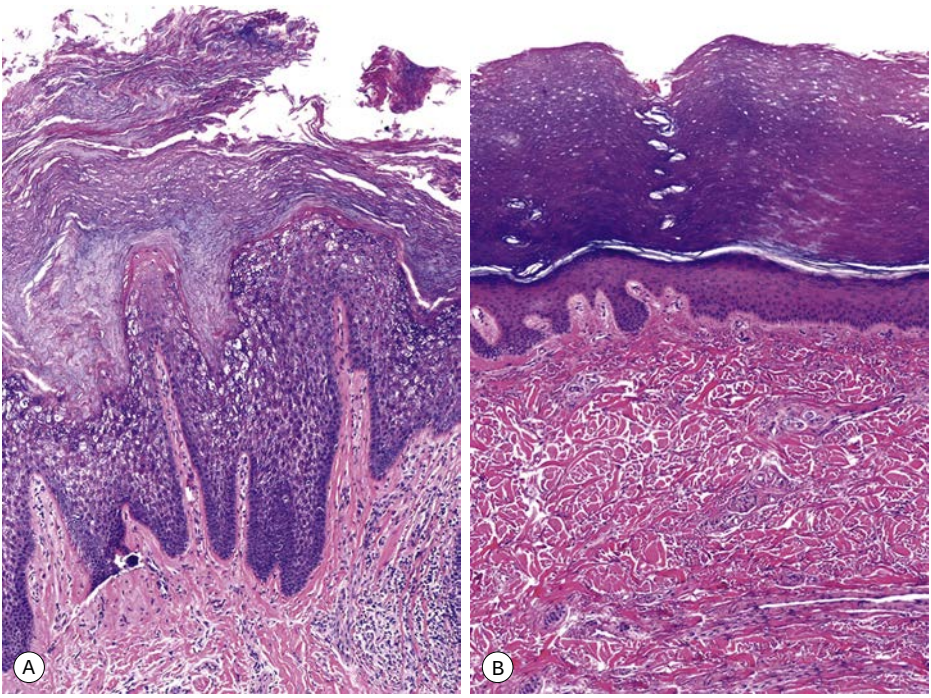


**eFig. 47.8 Histopathologic features of palmoplantar keratoderma. A** In epidermolytic hyperkeratosis, suprabasal keratinocytes show vacuolated cytoplasm, intracytoplasmic eosinophilic granules, and coarse keratohyaline granules. **B** In non-epidermolytic keratoderma, an extremely thick orthohyperkeratotic horny layer and acanthotic epidermis are seen. *Courtesy, Luis Requena, MD.*



**eFig. 47.9 Mal de Meleda.** Diffuse, yellow hyperkeratosis characterized by maceration, erythema in areas with reduced hyperkeratosis, progression beyond the palmar area (transgrediens), and a well-defined red border. *Courtesy, Dieter Metze, MD, and Vinzenz Oji, MD.*



**eFig. 47.10 KLICK syndrome.** Diffuse keratoderma and hyperkeratotic papules in parallel lines around the wrist. *Courtesy, Dieter Metze, MD, and Vinzenz Oji, MD.*




**eFig. 47.11 Huriez syndrome. A** Mild palmar hyperkeratosis. **B** Hypoplastic nail changes and scleroatrophic skin. *Courtesy, Dieter Metze, MD, and Vinzenz Oji, MD.*

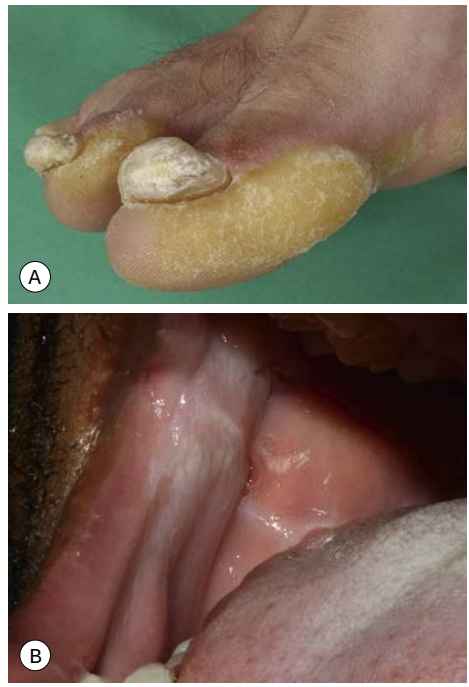


**eFig. 47.12 Pachyonychia congenita. A** Plantar hyperkeratosis accentuated over pressure points and hypertrophic nail dystrophy with marked subungual hyperkeratosis. **B** Oral leukokeratosis. *A*, *Courtesy, Dieter Metze, MD, and Vinzenz Oji, MD; B, Courtesy, Julie V. Schaffer, MD.*



**eFig. 47.13 Pachyonychia congenita.** Focal hyperkeratosis over pressure points on the sole. *Courtesy, Dieter Metze, MD, and Vinzenz Oji, MD.*




**eFig. 47.14 Carvajal syndrome. A** Focal plaque-like hyperkeratosis over pressure points on the soles. **B** Woolly hair. *Courtesy, Dieter Metze, MD, and Vinzenz Oji, MD.*



**eFig. 47.15 Spiny palmoplantar keratoderma.** Multiple tiny keratotic spines project from palms and soles. *Courtesy, Dieter Metze, MD, and Vinzenz Oji, MD.*

| DIFFERENTIAL DIAGNOSIS OF PALMOPLANTAR PITS |
|---|
| **Hereditary disorders** |
| Basal cell nevus syndrome<br>Basaloid follicular hamartoma syndrome<br>Darier disease<br>Reticulate acropigmentation of Kitamura<br>Punctate PPK (including punctate keratoses of the palmar creases)*<br>Cowden syndrome*<br>Porokeratotic adnexal ostial nevus (PAON; encompasses porokeratotic eccrine ostial and dermal duct nevus [PEODDN])* |
| **Acquired disorders** |
| Pitted keratolysis<br>Associated with Dupuytren contracture<br>Punctate porokeratoses* |
| **Characterized primarily by keratoses, which may leave a pit upon removal of the keratotic plug.* |

**eTable 47.1 Differential diagnosis of palmoplantar pits.** They are rarely seen in alkaptonuria, epidermodysplasia verruciformis, Blau syndrome, and lesions of lichen nitidus, lichen planus or psoriasis. Occasionally, lesions of circumscribed palmar or plantar hypokeratosis can be multiple and <5 mm. PPK, palmoplantar keratoderma.

# 48 Darier Disease and Hailey–Hailey Disease

## Darier Disease (Keratosis Follicularis)

- Autosomal dominant.
- Mutation in *ATP2A2* leads to dysfunction of SERCA2 protein, interfering with cellular calcium signaling.
- Clinical features:
  - Onset usually between ages 6 and 20 years, with peak during adolescence
  - Chronic course, often worse in summer
  - Crusted, pink-red to brown papules that may coalesce into plaques (Fig. 48.1) in a "seborrheic" and sometimes intertriginous distribution (Figs 48.2–48.3)
  - Hypopigmented macules may be the predominant feature, especially in darker skin types (Fig. 48.4)
  - Itching and malodor can be prominent
  - Flat-topped, skin-colored to brown papules (resembling flat warts) on the dorsal hands and feet (Fig. 48.5)
  - Palmoplantar keratotic papules (Fig. 48.6)
  - Nail changes, e.g. distal notching with longitudinal erythronychia (Fig. 48.7; see Ch. 58)
  - Whitish papules of the oral mucosa (Fig. 48.8)
- Rare subtypes – acral hemorrhagic, segmental (see Ch. 51).
- Exacerbating factors include sunlight, heat, occlusion, sweat, bacterial colonization.
- There may be an association with neuropsychiatric disease (e.g. major depression).
- Complications include bacterial (e.g. *Staphylococcus aureus*), fungal (e.g. tinea corporis), viral (e.g. HSV) infections; consider Kaposi varicelliform eruption due to HSV in a patient with a sudden onset of uniform hemorrhagic crusts, fever, and malaise (Fig. 48.9).
- Histopathologic features – acantholytic dyskeratosis above suprabasilar clefting.
- **DDx:** mild forms – severe seborrheic dermatitis, Grover disease; predominantly intertriginous – Hailey–Hailey disease, pemphigus vegetans, blastomycosis-like pyoderma, papular acantholytic dyskeratosis (vulvar); acral lesions – acrokeratosis verruciformis of Hopf (may be an allelic disorder or forme fruste; Fig. 48.10), flat warts, stucco keratoses, Flegel disease.
- **Rx:**
  - General measures: lightweight clothing, sunscreen, antimicrobial cleansers, keratolytic emollients
  - For symptomatic disease: topical retinoids ± topical CS (to decrease irritation from the former), oral retinoids (e.g. isotretinoin)
  - As-needed basis: topical and oral antibiotics and antifungals, systemic antivirals (e.g. acyclovir) for Kaposi varicelliform eruption, destructive modalities (e.g. laser treatment) for refractory lesions

## Hailey–Hailey Disease (Familial Benign Chronic Pemphigus)

- Autosomal dominant.
- Mutation in *ATP2C1* gene causing dysfunction of a Golgi-associated protein and interference with cellular calcium signaling.
- Clinical features:
  - Onset during the second or third decade but sometimes delayed into the fourth or fifth decade
  - Variable course with remissions and flares
  - Mainly affects the major body folds (see Fig. 48.2), including inframammary in women (Fig. 48.11); sometimes other sites affected, e.g. trunk (Fig. 48.12)
  - Moist, malodorous plaques, with erosions, fissures, and flaccid blisters (see Fig. 48.11); circinate plaques with eroded/crusted borders (see Fig. 48.12)
- Rare subtype – segmental (see Ch. 51).




**Fig. 48.1 Darier disease.** Truncal involvement with a predilection for seborrheic areas **(A–D)**. Keratotic papules can vary from red **(A, B)** to brown **(C, D)** in color and may become confluent. **E** Severe intertriginous involvement. *A, C, Courtesy, Julie V. Schaffer, MD; B, D, Courtesy, YDRSC; E, Courtesy, Daniel Hohl, MD.*

- Exacerbating factors include friction, heat, sweat, bacterial colonization, application of adhesive tape; complications the same as for Darier disease (see above).
- Histopathologic features – acantholysis of the majority of the epidermis.
- **DDx:** intertrigo, irritant contact dermatitis, cutaneous candidiasis, pemphigus vegetans, Darier disease.
- **Rx:**
  - General measures: lightweight clothing, antimicrobial cleansers
  - For symptomatic disease: intermittent topical/intralesional CS, other topicals including calcineurin inhibitors, botulinum toxin type A to decrease sweat production, oral low-dose naltrexone
  - As-needed basis: topical and oral antibiotics and antifungals, destructive modalities (e.g. surgical excision, laser treatment) for refractory lesions

For further information see Ch. 59 from *Dermatology, Fourth Edition*.

**For additional online figures visit www.expertconsult.com**

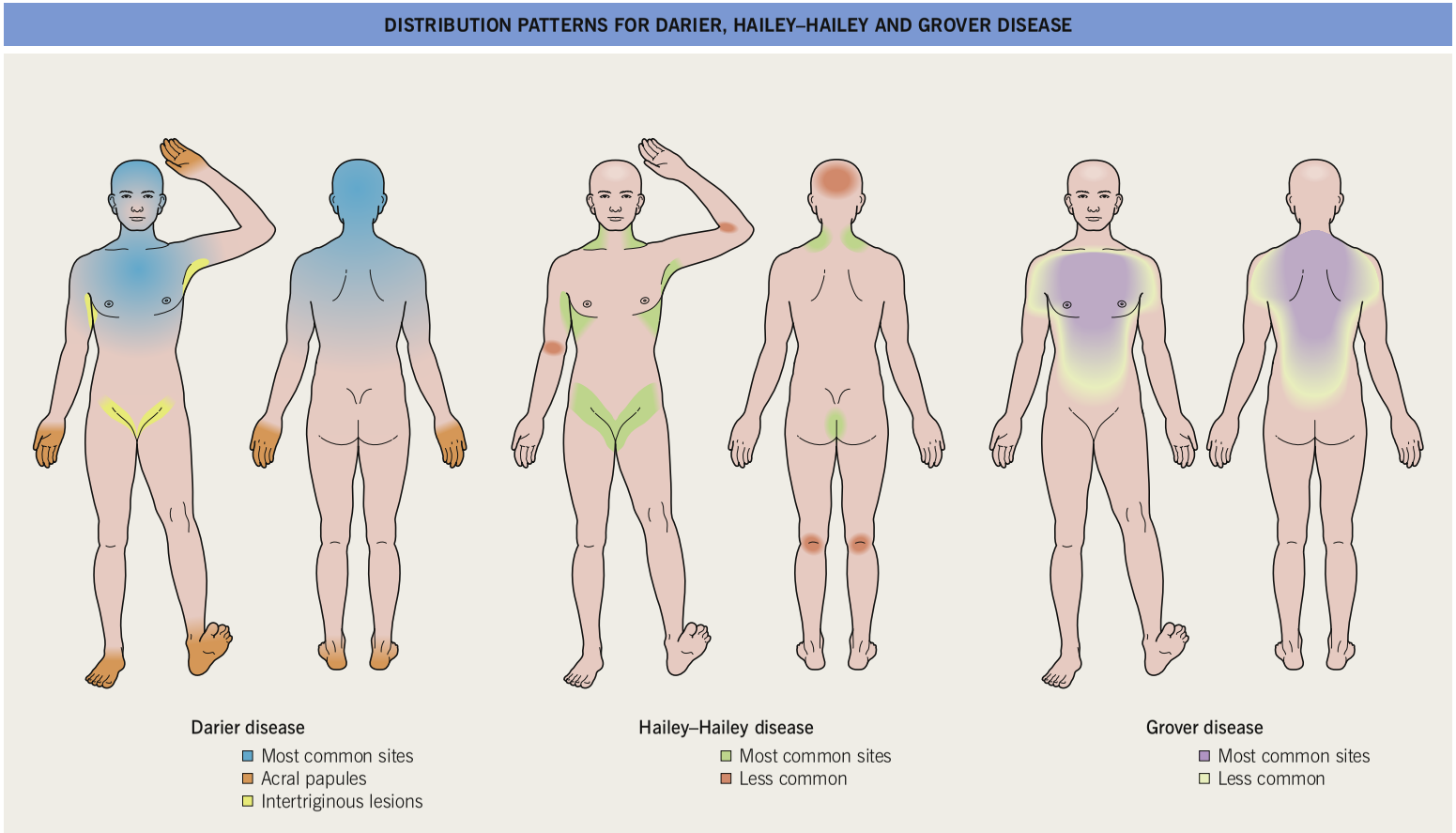


**Fig. 48.2 Distribution patterns for Darier, Hailey–Hailey, and Grover disease.**

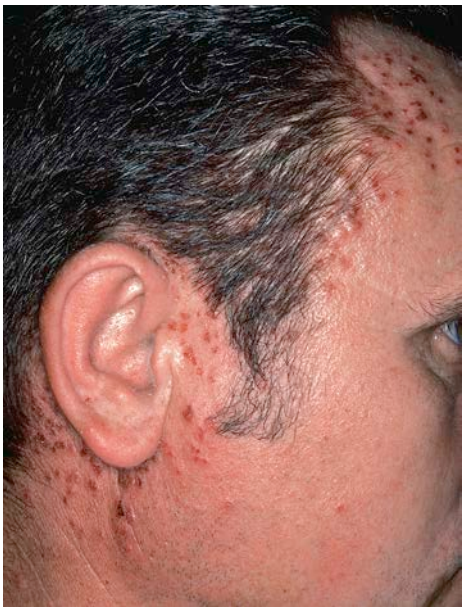

**Fig. 48.3 Darier disease.** Crusted papules at the hairline on the face and in the posterior auricular area. *Courtesy, Daniel Hohl, MD.*



**Fig. 48.4 Darier disease.** Observed most commonly in individuals with darkly pigmented skin, a guttate leukoderma may be seen in patients with Darier disease, including the segmental form. *Courtesy, Julie V. Schaffer, MD.*



**Fig. 48.5 Darier disease.** Multiple flat-topped papules on the dorsal aspect of the hand. *Courtesy, Daniel Hohl, MD.*







**Fig. 48.6 Palmar involvement in Darier disease. A** Both keratotic papules and keratin-filled depressions are seen. **B** Less commonly, a thick, spiked focal keratoderma is observed. *A, Courtesy, Kalman Watsky, MD; B, Courtesy, Julie V. Schaffer, MD.*



**Fig. 48.7 Darier disease.** Alternating longitudinal red and white streaks as well as notching of the free edge of the nail plate. *Courtesy, Antonella Tosti, MD.*



**Fig. 48.8 Oral mucosal Darier disease.** Whitish papules on the palate. *Courtesy, Daniel Hohl, MD.*



**Fig. 48.9 Darier disease with superimposed HSV infection (Kaposi varicelliform eruption).** Multiple hemorrhagic crusts of a similar size are seen. *Courtesy, YDRSC.*







**Fig. 48.11 Hailey–Hailey disease. A** Erythematous, eroded plaque in the axilla. Note the intact flaccid vesicles at 2 and 7 o'clock. **B** Chronic submammary lesion with erosions in a worm-eaten pattern. *Courtesy, YDRSC.*



**Fig. 48.10 Acrokeratosis verruciformis of Hopf.** Involvement of the dorsal aspect of the foot with flat-topped papules. *Courtesy, YDRSC.*



**Fig. 48.12 Hailey–Hailey disease.** Circinate plaques on the back with erosions and crusting in the active borders. *Courtesy, Louis A. Fragola, Jr., MD.*



**eFig. 48.1 Darier disease.** Extensive facial involvement leading to ectropion. *Courtesy, Daniel Hohl, MD.*



**eFig. 48.2 Type 1 segmental Darier disease.** Note the distribution of the papules along the lines of Blaschko. *Courtesy, YDRSC.*

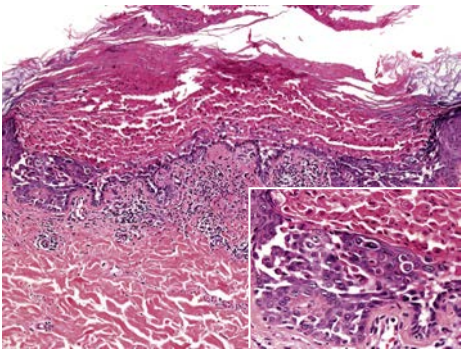

**eFig. 48.3 Histopathology of Darier disease.** Hyperkeratosis, grains and corp ronds (inset) are seen in addition to acantholysis leading to suprabasilar clefting. *Courtesy, Lorenzo Cerroni, MD.*

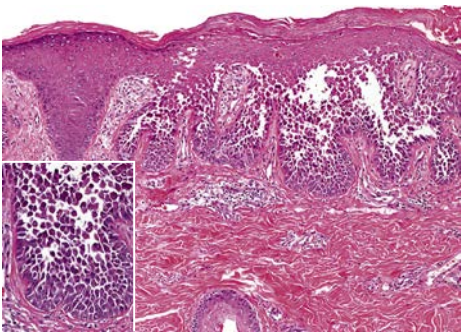

**eFig. 48.4 Histopathology of Hailey–Hailey disease.** Focal crusting and acantholysis beginning in the suprabasilar area and extending throughout the epidermis. The latter has been likened to a "dilapidated brick wall". *Courtesy, Lorenzo Cerroni, MD.*

# Primary Immunodeficiencies

# 49

- Heterogeneous group of disorders characterized by immune system defects that result in increased susceptibility to various infections, often with additional manifestations such as autoimmunity, allergy, and risk of malignancy.
- The genetic basis has been determined for >200 primary immunodeficiencies.
- Many immunodeficiency syndromes present with dermatologic findings that can facilitate early diagnosis (Table 49.1; Figs 49.1–49.9); these features may be divided into three categories:
  - Recurrent, severe, atypical or recalcitrant mucocutaneous infections, most often with *Staphylococcus aureus*, *Candida* spp., and human papillomaviruses
  - Patterns of cutaneous inflammation that are shared by several immunodeficiencies, e.g. eczematous dermatitis, non-infectious granulomas, lupus erythematosus-like lesions, small vessel vasculitis, and ulcers
  - More specific skin findings suggestive of particular disorders, e.g. oculocutaneous telangiectasias in ataxia–telangiectasia and maternofetal GVHD in severe combined immunodeficiencies (SCID)
- In addition to extracutaneous infections with unusual organisms and increased frequency (e.g. pneumonia ≥2 times or otitis media ≥4 times yearly) or severity, signs of immunodeficiency in children may include failure to thrive, chronic diarrhea, lymphadenopathy (or lack of expected lymph nodes), and hepatosplenomegaly.




**Fig. 49.1 Ataxia–telangiectasia.**
**A** Characteristic linear telangiectasias on the medial and lateral bulbar conjunctivae. Punctate and smaller linear telangiectasias are also present on this girl's eyelids. **B** Extensive telangiectasias on the neck of a young woman. **C** Persistent granulomatous plaques on the leg of a child. These lesions often ulcerate and are difficult to manage. *A, Courtesy, Edward Cowen, MD; B, C, Courtesy, Amy Paller, MD.*

| CUTANEOUS FINDINGS IN PRIMARY IMMUNODEFICIENCY (ID) DISORDERS | | | | | | | | | | |
|---|---|---|---|---|---|---|---|---|---|---|
| **Disorder** | ***S. aureus* infections*** | **CMC** | **Warts**** | **Eczematous dermatitis** | **Granulomas***** | **LE** | **SVV** | **Ulcers (PG-like)** | **Additional mucocutaneous findings** | **Other major clinical features** |
| Ataxia–telangiectasia (Fig. 49.1) | + | | | + (facial) | + (often ulcerates) | | | | Oculocutaneous telangiectasias (onset age 3–6 y; favor ears, cheeks), CALMs, progeric changes | Cerebellar ataxia (onset age 1–2 y), sinopulmonary infections, leukemia/lymphoma, sensitivity to IR |
| Chédiak–Higashi syndrome (DDx includes Griscelli syndrome type 2; see Ch. 54) | + | | | | | | | + | Pigmentary dilution, hyper- or dyspigmentation in sun-exposed sites, silvery hair, gingivitis | Bleeding diathesis, lymphoproliferative "accelerated phase", neurologic degeneration |
| Chronic granulomatous disease (XR>AR) (Fig. 49.2) | ++ | + | | + | ++ (nodular, necrotic) | + | | + | Sweet syndrome, oral ulcers; DLE in female carriers | LAN (often suppurative), HSM, internal granulomas, pneumonias |
| CMC syndromes (Figs 49.3 & 49.4) | | ++ | | | (++) (candidal) | | | | See text | See text |
| Complement deficiencies | + | + | | | | ++ | + | + | See Table 49.3 | See Table 49.3 |
| DiGeorge (22q11.2 deletion) syndrome | | + | | + | + | | | | Erythroderma | Thymic hypoplasia, ↓ $Ca^{+2}$ due to hypoparathyroidism, congenital heart defects, craniofacial anomalies |
| Hyper-IgE syndromes (Figs 49.5 & 49.6) | ++ | + | + (AR) | ++ | | | | | See text | See text |

| Immunoglobulin deficiencies | | | | | | | | | | |
|---|---|---|---|---|---|---|---|---|---|---|
| • Agamma-globulinemia (XR>AR) | + | | | + | + | | | | Dermatomyositis-like (due to echovirus); ecthyma gangrenosum | Bacterial and viral infections (e.g. lungs, GI) |
| • Hyper-IgM syndromes | + | | + | | + | + | | + | Oral & anogenital ulcers | Infections (e.g. lungs, GI), autoimmunity |
| • Common variable ID (CVID) (Fig. 49.7) | + | + | + | + | ++ | + | + | + | Dermatophyte infections, vitiligo, alopecia areata | Variable infections (e.g. lungs, GI), autoimmunity (e.g. cytopenias), granulomas |
| • IgA deficiency† | + | + | | + | | + | + | + | Vitiligo, lipodystrophy | Similar to CVID but milder |
| Idiopathic $CD4^+$ lymphocytopenia (<300/$mm^3$ or <20%) | | + | ++ | | | + | | | HSV infections, non-tuberculous mycobacterioses | Cryptococcal meningitis, lymphoma; *HIV infection excluded* |
| Leukocyte adhesion deficiency (Fig. 49.8) | ++ (necrotic, little pus) | | | | | | | ++ | Poor wound healing, delayed umbilical stump separation, gingivitis | Pneumonias > severe bacterial or fungal infections |
| Severe combined ID (SCID) | + | + | + | + | +*** | | | | GVHD, erythroderma, Omenn syndrome‡ | Severe infections, diarrhea, failure to thrive |
| Wiskott–Aldrich syndrome (XR) (Fig. 49.9) | ++ | | | ++ | + | | + | | Petechiae, ecchymoses | Platelet dysfunction, sinopulmonary infections, autoimmunity, atopy, lymphoma |

*Including abscesses and superficial pyoderma.*
***Extensive warts are also a characteristic finding in warts, hypergammaglobulinemia, infections and myelokathexis (WHIM) syndrome.*
****Non-infectious unless otherwise noted; extensive granulomas (including destructive mid facial lesions) are associated with hypomorphic RAG1 or RAG2 mutations.*
*†Prevalence of ~1:500, with clinical manifestations in only ~15% of affected individuals; profound IgA deficiency is occasionally associated with reactions to blood products containing IgA.*
*‡Neonatal onset of erythrodermic eczematous dermatitis, alopecia, lymphadenopathy, hepatosplenomegaly, and peripheral eosinophilia.*
*+, occasional finding.*
*++, common finding.*

**Table 49.1 Cutaneous findings in primary immunodeficiency (ID) disorders.** Infectious conditions are in darker blue shading and non-infectious conditions in lighter blue shading. AR, autosomal recessive; CALMs, café-au-lait macules; CMC, chronic mucocutaneous candidiasis; DLE, discoid lupus erythematosus; HSM, hepatosplenomegaly; IR, ionizing radiation; LAN, lymphadenopathy; PG, pyoderma gangrenosum; SVV, small vessel vasculitis; XR, X-linked recessive (affects primarily boys/men).

• The primary feature of some immunodeficiency disorders is lymphoproliferation due to immune dysregulation (e.g. familial hemophagocytic lymphohistiocytosis, X-linked and autoimmune lymphoproliferative syndromes), whereas others involve predisposition to a specific type of infection, such as severe mycobacterial infections with defects in the IL-12/interferon-γ axis.



**Fig. 49.2 Chronic granulomatous disease.** Lupus erythematosus-like annular plaques and papules on the infraorbital cheek. *Courtesy, Edward Cowen, MD.*

• Initial laboratory evaluation for patients suspected to have an immunodeficiency is outlined in Table 49.2.

## Chronic Mucocutaneous Candidiasis (CMC)

• Heterogeneous group of conditions characterized by recurrent and severe infections of the skin, nails, and mucous membranes with *Candida albicans*, together with variable autoimmunity and susceptibility to other infections (see Table 49.1).

• These disorders share an underlying impairment in Th17 responses, e.g. due to autoantibodies neutralizing Th17 cytokines in APECED (see below) and mutations in the genes encoding IL-17F, the IL-17 receptor A or C, or STAT1 (*s*ignal *t*ransducer and *a*ctivator of *t*ranscription *1*) in other forms of CMC.

• Clinical manifestations include recalcitrant oral thrush, dystrophic nails, and granulomatous plaques with scale-crust favoring the scalp, face, and skin folds (see Figs 49.3 and 49.4).

• The *a*utoimmune *p*oly*e*ndocrinopathy–*c*andidiasis–*e*ctodermal *d*ystrophy syndrome (APECED) is caused by mutations (usually







**Fig. 49.3 Chronic mucocutaneous candidiasis due to increased STAT1 signaling. A** Recalcitrant thrush on the tongue of a 6-year-old child. **B** Extensive tinea corporis with coalescing annular and polycyclic plaques on the legs. *A, Courtesy, Julie V. Schaffer, MD; B, Courtesy, Edward Cowen, MD.*










**Fig. 49.4 Chronic mucocutaneous candidiasis (CMC). A** Non-syndromic CMC presenting as crusted granulomatous plaques on the palm. **B** Non-syndromic CMC presenting as marked onychodystrophy with significant paronychial swelling and erythema. **C** Recurrent cutaneous candidiasis in an infant with DiGeorge syndrome. Note the erythema, pustules, and scale-crust near the site of an intravenous line on the arm. *A, Courtesy, YDRSC; B, Courtesy, Amy Paller, MD; C, Courtesy, Julie V. Schaffer, MD.*

with autosomal recessive inheritance) in the *a*uto*i*mmune *re*gulator gene (*AIRE*), which result in failure to delete autoreactive T cells in the thymus; patients present with a variety of autoimmune disorders (e.g. hypoparathyroidism, hypoadrenocorticism, alopecia areata) in addition to CMC.

- The most common form of CMC is autosomal dominant due to an activating *STAT1* mutation; additional manifestations can include autoimmunity, predisposition to other infections (e.g. viral, invasive fungal), and aneurysms (see Fig. 49.3).

## Complement Disorders

- Clinical manifestations of various complement deficiencies are presented in Table 49.3.

## Hyperimmunoglobulin E Syndromes (HIESs)

- HIESs feature eczematous dermatitis, recurrent staphylococcal skin (including "cold" abscesses and impetigo) and respiratory tract infections, mucocutaneous candidiasis, and markedly elevated serum IgE levels (usually > 2000 IU/ml) (see Fig. 49.6A).
- *Classic HIES* has autosomal dominant inheritance and is caused by mutations in the *STAT3* gene, which encodes a signaling protein that promotes production of cytokines (e.g. IL-6, IL-10, IL-17, IL-22) important to fighting infections at epithelial surfaces and controlling inflammation.
  - Usually presents in the first month of life with a non-infectious papulopustular eruption on the face, scalp, and diaper area



**Fig. 49.5 Autosomal dominant hyper-immunoglobulin E syndrome (AD-HIES).** Coarse facial features that developed progressively over time in an affected woman. Note the prominent follicular ostia, doughy skin, and broad nasal bridge. *Courtesy, Edward Cowen, MD.*

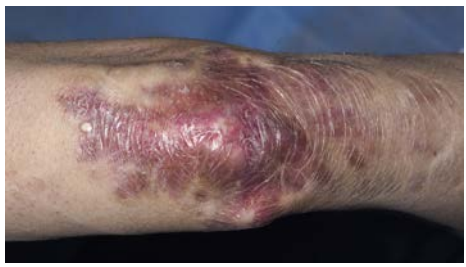

**Fig. 49.7 Persistent granulomatous plaques in a patient with common variable immunodeficiency (CVID).** *Courtesy, Edward Cowen, MD.*



**Fig. 49.8 Leukocyte adhesion deficiency type I.** This 7-year-old boy was scratched by his sister, resulting in a large gaping wound that healed poorly. *Reprinted with permission from Schachner L, Hansen R (Eds.). Pediatric Dermatology, 4th edn. London: Mosby, 2011.*




**Fig. 49.6 Autosomal recessive hyper-immunoglobulin E syndrome (AR-HIES) due to *DOCK8* deficiency. A** Eczematous dermatitis with prurigo nodularis lesions. **B** Extensive molluscum contagiosum. **C** Numerous coalescing facial warts. *A, B, Courtesy, Edward Cowen, MD; C, Julie V. Schaffer, MD.*



**Fig. 49.9 Wiskott–Aldrich syndrome.** This young boy presented with widespread, severe atopic dermatitis. Following successful treatment with hematopoietic stem cell transplantation, his dermatitis virtually cleared. *Reprinted with permission from Schachner L, Hansen R (Eds.). Pediatric Dermatology, 4th edn. London: Mosby, 2011.*

  - Other findings include progressive facial coarsening with pitted scarring (see Fig. 49.5), retention of primary teeth, a high-arched palate, osteopenia with minimal-trauma fractures, scoliosis, pneumatocele formation, and increased risk of B-cell lymphomas
  - Absent Th17 cells
- An *autosomal recessive form of HIES (AR-HIES)* can be caused by mutations in the *d*edicator *o*f *cyto*kinesis 8 (*DOCK8*) gene.
  - Characterized by severe viral (e.g. warts, molluscum contagiosum, HSV, VZV; see Fig. 49.6B, C) and opportunistic infections, other atopic manifestations, CNS vasculitis, and increased

| INITIAL LABORATORY EVALUATION FOR A PATIENT SUSPECTED TO HAVE A PRIMARY IMMUNODEFICIENCY (ID) | | |
|---|---|---|
| **Test** | **Potential finding** | **Examples of disorders identified** |
| Complete blood count with differential, platelet count, and examination of smear | • Giant granules within neutrophils, ± neutropenia | • Chédiak–Higashi syndrome |
| | • Neutrophilia | • Leukocyte adhesion deficiency |
| | • Small platelets, thrombocytopenia, eosinophilia | • Wiskott–Aldrich syndrome |
| | • Marked eosinophilia | • Hyper-IgE syndromes<br>• Omenn syndrome |
| Quantitative immunoglobulins | • All Ig ↓ | • Agammaglobulinemia |
| | • IgA ↓, IgG ↓, ± IgM ↓ | • Common variable ID |
| | • IgA ↓ or IgM ↓ | • IgA or IgM deficiency |
| | • IgM ↑, other Ig ↓ | • Hyper-IgM syndrome |
| | • IgA ↓, IgE ↓, $IgG_{2,4}$ ↓ | • Ataxia telangiectasia |
| | • IgE ↑↑ | • Hyper-IgE syndromes |
| | • IgM ↓, ± IgG ↓, IgA ↑, IgE ↑ | • Wiskott–Aldrich syndrome |
| Total hemolytic complement (CH50) | • Marked ↓ | • Various complement deficiencies |
| Nitroblue tetrazolium (NBT) reduction assay | • <10% of normal NBT reduction | • Chronic granulomatous disease |
| T- and B-cell analysis by flow cytometry | • Lack of T cells ± B cells | • Severe combined ID |
| Hair shaft examination (if silvery hair color) | • Small, regular melanin clumps | • Chédiak–Higashi syndrome |
| | • Large, irregular melanin clumps | • Griscelli syndrome |

**Table 49.2 Initial laboratory evaluation for a patient suspected to have a primary immunodeficiency (ID).** Antibody titers to previously administered vaccines can also be assessed.

| COMPLEMENT DISORDERS | | |
|---|---|---|
| **Complement component(s)** | **Susceptibility to infectious agents** | **Autoimmune/inflammatory disorders** |
| **Classical pathway** | | |
| C1q/r/s, C4, C2* | **Encapsulated bacteria** (especially *Streptococcus pneumoniae*) > *Candida* (C1q) | • **SLE**: risk with deficiency of C1q (~90%) > C4 > C1r/s > C2 (~20%)<br>– C1q/r/s or C4 deficiency: often childhood onset (F = M); photosensitivity, renal disease<br>– C2 deficiency: usually adult onset (median age ~30 years; ~8 F:1 M); photosensitivity, SCLE > DLE, oral ulcers<br>– ANA may be – or low-titer; anti-Ro/SSA usually +<br>• Uncommon associations include dermatomyositis, Henoch–Schönlein purpura, urticaria, and atrophoderma |
| C1 inhibitor | | Hereditary angioedema (see Ch. 14) |
| **Lectin pathway** | | |
| Mannose-binding lectin (MBL)§ | Encapsulated bacteria, especially *N. meningitides* | • SLE, dermatomyositis |
| **C3 and alternative pathway** | | |
| C3, factor H, factor I | **Encapsulated bacteria** (severe infections for C3) | • SLE, vasculitis, partial lipodystrophy (C3), glomerulonephritis, atypical HUS<br>• "Leiner phenotype" (C3): erythroderma, failure to thrive, chronic diarrhea, recurrent infections |
| Properdin¶, factor D | ***Neisseria* spp.** (fulminant infections) | |
| **Membrane attack complex** | | |
| C5, C6, C7, C8, C9† | ***Neisseria* spp.** (recurrent infections) | • SLE (rarely); "Leiner phenotype" (C5) |

**C2 deficiency is the most common homozygous complement disorder.*
*§Very low penetrance, usually in young children and immunocompromised individuals.*
*¶X-linked recessive, so occurs primarily in male patients.*
*†Prevalence of ~1:1000 in Japan; milder than other etiologies.*

**Table 49.3 Complement disorders.** Unless otherwise specified, refers to homozygous/biallelic deficiencies. DLE, discoid lupus erythematosus; F, female; HUS, hemolytic–uremic syndrome; M, male; SCLE, subacute cutaneous lupus erythematosus.

risk of mucocutaneous SCC as well as lymphoma
– Decreased $CD4^+$ T cells and low IgM levels

• **DDx:** atopic dermatitis; Wiskott–Aldrich, Netherton, Omenn, and IPEX (*i*mmune dysregulation, *p*olyendocrinopathy, *e*nteropathy, *X*-linked) syndromes.

For further information see Ch. 60 from *Dermatology, Fourth Edition*.


For additional online figures and tables visit www.expertconsult.com




**eFig. 49.1 Ataxia–telangiectasia.** Linear telangiectasias on the bulbar conjunctivae. *A, Courtesy, Jean L. Bolognia, MD; B, Courtesy, Edward Cowen, MD.*



**eFig. 49.2 Chédiak–Higashi syndrome.** Light microscopic examination of hair shows small, regularly spaced clumps of melanin in patients with Chédiak–Higashi syndrome. *Courtesy, Amy Paller, MD.*




**eFig. 49.3 Chronic granulomatous disease.** **A** Lupus erythematosus-like annular plaques on the neck. **B** Pyoderma gangrenosum-like ulcers at an ostomy stoma site. *Courtesy, Edward Cowen, MD.*



**eFig. 49.4 Autosomal dominant hyper-immunoglobulin E syndrome (AD-HIES).** Several erythematous, slightly purulent "cold" abscesses are apparent on the forehead and scalp of this infant. *Courtesy, Amy Paller, MD.*




**eFig. 49.5 Autosomal recessive hyperimmunoglobulin E syndrome (AR-HIES) due to DOCK8 deficiency. A** Widespread eczematous dermatitis. **B** Eczematous dermatitis admixed with molluscum contagiosum. **C** Numerous coalescing warts on the hands. *A, B Courtesy, Edward Cowen, MD; C, Courtesy, Julie V. Schaffer, MD.*



**eFig. 49.6 Painful oral ulceration in a patient with hyperimmunoglobulinemia M syndrome.** *Reprinted with permission from Schachner L, Hansen R, eds. Pediatric Dermatology, 4th edn. London: Mosby, 2011.*



**eFig. 49.7 Extensive, recalcitrant perianal warts in a child with WHIM syndrome.** *Courtesy, Edward Cowen, MD.*

| FREQUENCY OF SIGNS AND SYMPTOMS IN PATIENTS WITH CHRONIC GRANULOMATOUS DISEASE | |
|---|---|
| **Symptom** | **Approximate % of patients** |
| Lymphadenopathy | 90 |
| Hepatosplenomegaly | 85 |
| Pneumonia | 80 |
| Underweight | 75 |
| Short stature | 50 |
| Persistent diarrhea and/or abdominal pain | 40 |
| Hepatic/perihepatic abscess | 35 |
| Pleuritis/empyema | 35 |
| Septicemia or meningitis | 35 |
| Osteomyelitis | 25 |
| Conjunctivitis and/or chorioretinitis | 25 |
| Facial periorificial dermatitis | 20 |
| Perianal abscess | 15 |
| Lung abscess | 15 |
| Ulcerative stomatitis | 15 |
| Peritonitis | 10 |
| Onset by age 1 year | 65 |
| Onset with lymphadenitis | 25 |

**eTable 49.1 Frequency of signs and symptoms in patients with chronic granulomatous disease.**

| DIAGNOSTIC GUIDELINES FOR HYPERIMMUNOGLOBULIN E SYNDROME (AD-HIES) DUE TO *STAT3* MUTATIONS | | | | | | | |
|---|---|---|---|---|---|---|---|
| **Clinical finding** | **Points** | | | | | | **Multiplication factor** |
| | **0** | **2** | **4** | **5** | **6** | **8** | |
| Pneumonias (X-ray proven, total #) | none | 1 | 2 | – | 3 | >3 | 2.5 |
| Newborn papulo-pustular eruption (during first 3 weeks of life) | absent | – | present | – | – | – | 2.1 |
| Pathologic bone fractures | none | – | 1–2 | – | – | >2 | 3.3 |
| Characteristic facies | absent | mild | – | present | – | – | 3.3 |
| High-arched palate | absent | present | – | – | – | – | 2.5 |
| **Possible AD-HIES:** IgE >1000 IU/ml *plus* weighted score of >30<br>**Probable AD-HIES**: As above plus lack of Th17 cells by peripheral blood flow cytometry *or* a family history of definitive AD-HIES<br>**Definitive AD-HIES:** As above plus a dominant-negative heterozygous mutation in *STAT3* | | | | | | | |

**eTable 49.2 Diagnostic guidelines for autosomal dominant hyperimmunoglobulin E syndrome (AD-HIES) due to *STAT3* mutations.**

# Neurofibromatosis and Tuberous Sclerosis Complex

# 50

- Neurofibromatosis (NF) and tuberous sclerosis complex (TSC) are neurocutaneous disorders (phacomatoses) characterized by skin lesions as well as neoplasms of the central and peripheral nervous systems.
- Cutaneous manifestations (especially pigmentary findings) are often the first clinical signs of NF type 1 (NF1) and TSC.
- Both disorders have autosomal dominant inheritance, although ~30–50% of patients have unaffected parents and harbor new, spontaneous mutations.
- Education of patients/parents about the condition, attention to psychosocial concerns, and genetic counseling represent important components of care.

## Neurofibromatosis Type 1

- Incidence of approximately 1 in 3000 births.
- The *NF1* tumor suppressor gene encodes the neurofibromin protein, which negatively regulates the RAS-mitogen-activated protein kinase (MAPK) pathway that promotes cell survival and proliferation.
- Patients with NF1 have a constitutive (germline) *NF1* mutation plus a somatic "second hit" mutation inactivating the other copy of the gene in affected tissues, e.g. Schwann cells in neurofibromas and melanocytes in café-au-lait macules (CALMs).
- The major clinical features of NF1 are outlined in Table 50.1 and depicted in Figs 50.1–50.5; Fig. 50.6 shows the time course of their development.
- Revised diagnostic criteria for NF1 (Table 50.2) developed by an international consensus group were published in 2021.
- An approach to infants or young children with ≥6 CALMs is presented in Fig. 50.7.
- Comprehensive *NF1* gene analysis with ≥95% sensitivity is available; this can help to establish the diagnosis in atypical presentations or young children not yet meeting criteria.
- **DDx:** other disorders that can manifest with multiple CALMs are summarized in Table 50.3.
- Management of NF1 requires a multidisciplinary approach (Table 50.4). Selumetinib, a MEK inhibitor, is FDA-approved for the treatment of symptomatic plexiform neurofibromas.

## Tuberous Sclerosis Complex (TSC)

- Incidence of approximately 1 in 10,000 births.
- Hamartomatous disorder caused by mutations in either the *TSC1* or *TSC2* gene; both encode proteins (hamartin and tuberin, respectively) that negatively regulate the *m*ammalian *t*arget *o*f *r*apamycin (mTOR) pathway that promotes cell growth.
- *TSC2* mutations are associated with more severe disease and are threefold more common than *TSC1* mutations in TSC patients overall.
- Fig. 50.9 shows the time course for the development of cutaneous findings in TS.
- Hypomelanotic macules may be very subtle or inapparent in individuals with lightly pigmented skin, and a Wood's light can help to identify them.
- The hypomelanotic macules in TS patients vary in number (few to >100) and size (<1 to >10 cm); their shapes are polygonal more often than resembling an "ash leaf" – rounded at one end, tapered at the other (Fig. 50.10A).
  - **DDx:** nevus depigmentosus is a common (1–5% of healthy children) cause of one or two hypopigmented macule(s) or patch(es); Fig. 50.11 presents an approach to infants/young children with ≥3 hypomelanotic macules

| MAJOR CLINICAL FEATURES OF NEUROFIBROMATOSIS TYPE 1 (NF1) |
|---|
| **Cutaneous findings** |
| • Café-au-lait macules (CALMs) (>90%; often evident within first year of life)<br>– Tan to dark brown, uniformly pigmented macules/patches with regular borders (Fig. 50.1A–C)<br>– Most patients have ≥6 by early childhood<br>• Axillary and/or inguinal freckling (Crowe sign) (~80%; usually present by 4–6 years of age)<br>– 1- to 3-mm brown macules, more akin to lentigines than ephelides<br>– Favor intertriginous sites (Fig. 50.1B) and the neck, but may be widespread (Fig. 50.1C,D)<br>• *Cutaneous* neurofibromas (70–90%; typically begin to appear around puberty)<br>– Skin-colored to pink-tan, soft papulonodules that invaginate with gentle pressure ("button-hole" sign); dome-shaped, pedunculated, or barely elevated (early lesions) (Figs 50.2 and 50.3)<br>– Range from a few millimeters to several centimeters in diameter and <10 to >1000 in number<br>• *Plexiform* neurofibromas (PNF) (25%; congenital origin, enlarge during first 4–5 years of life)<br>– Deeper nodules or masses resembling a "bag of worms" upon palpation (Fig. 50.4)<br>– May have overlying hyperpigmentation (Fig. 50.4A) ± hypertrichosis and associated soft tissue overgrowth<br>• Nevus anemicus (30–50%; congenital), a pale area with irregular outline favoring the chest and more apparent after rubbing the skin<br>• Juvenile xanthogranuloma (JXG) (~15–30%; typically develops in first 2–3 years of life)<br>– Pink (early) to yellow-brown papule/nodule (see Ch. 76); may be associated with additional increased risk of JML in NF1 patients (who already have a higher risk of JML)<br>• Glomus tumors of the fingers and toes (see Ch. 94) |
| **Ocular lesions** |
| • Lisch nodules (iris hamartomas) (>90% by 20 years of age; begin to appear at ~3 years of age)<br>– 1- to 2-mm yellow-brown papules, best seen on slit-lamp examination (Fig. 50.5)<br>• Choroidal abnormalities (~80% of adults, 60-70% of children)<br>– Nodules detected by optical coherence tomography/near infrared reflectance imaging |
| **Skeletal anomalies** |
| • *Cranial*: macrocephaly (20–50%), hypertelorism (25%), sphenoid wing dysplasia (<5%)<br>• *Spinal*: scoliosis (5–10%)<br>• *Limbs*: cortical thinning ± pseudoarthrosis (2%; e.g. tibial bowing) |
| **Extracutaneous tumors** |
| • Optic glioma (10–15%; childhood) (± precocious puberty), other CNS tumors (~5%)<br>• Malignant peripheral nerve sheath tumor (3–15%, peak in young adults), usually arising from a PNF<br>– Rapid growth, increased firmness, or persistent pain in established PNF; new neurologic deficit<br>• Other, e.g. pheochromocytoma (1%), JML, GIST, rhabdomyosarcoma (especially GU), breast cancer |
| **Neurologic manifestations** |
| • Unidentified bright objects (UBO) on MRI (50–75%)<br>• Learning difficulties (30–50%), ADD, intellectual impairment (severe in <5%), seizures (~5%) |
| **Cardiovascular manifestations** |
| • Hypertension (~30%): essential > from renal artery stenosis (~2%) or pheochromocytoma (1%)<br>• Pulmonic stenosis (~1%), cerebrovascular anomalies (2–5%) |

**Table 50.1 Major clinical features of neurofibromatosis type 1 (NF1).** ADD, attention deficit disorder; GIST, gastrointestinal stromal tumors; GU, genitourinary; JML, juvenile myelomonocytic leukemia.

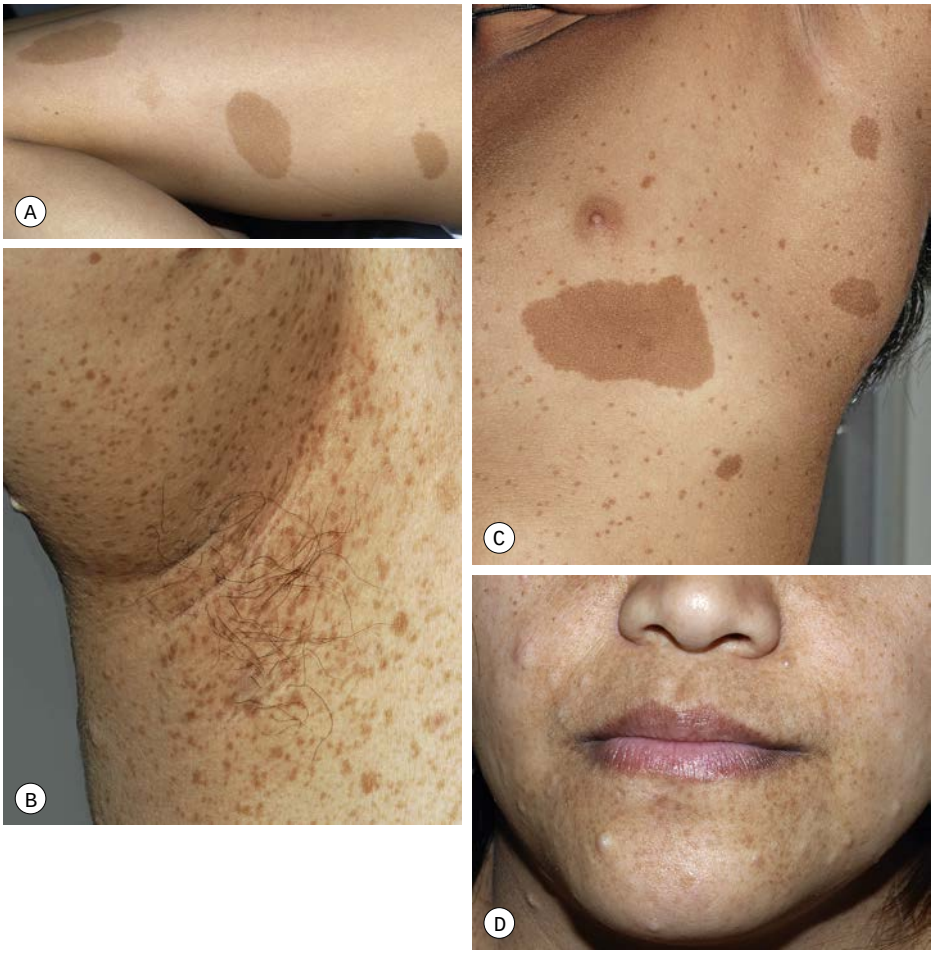


**Fig. 50.1 Café-au-lait macules and "freckling".** Oval-shaped, light- to medium-brown patches with regular borders and uniform pigmentation **(A–C).** Numerous 1- to 3-mm lentigines are most commonly found in the axilla (Crowe sign) **(B)** but can also develop in other sites such as the chest (**C**) and perioral region **(D)**. *Courtesy, Julie V. Schaffer, MD.*




**Fig. 50.2 Multiple cutaneous neurofibromas.** Soft, skin-colored to pinkish tan, dome-shaped or polypoid, well-demarcated papules and nodules of various sizes **(A, B)** in patients with NF1. Neurofibromas may be superimposed on café-au-lait macules and lentigines **(B)**. *A, Courtesy, Julie V. Schaffer, MD; B, Courtesy, Hensin Tsao, MD, and Su Luo, MD.*

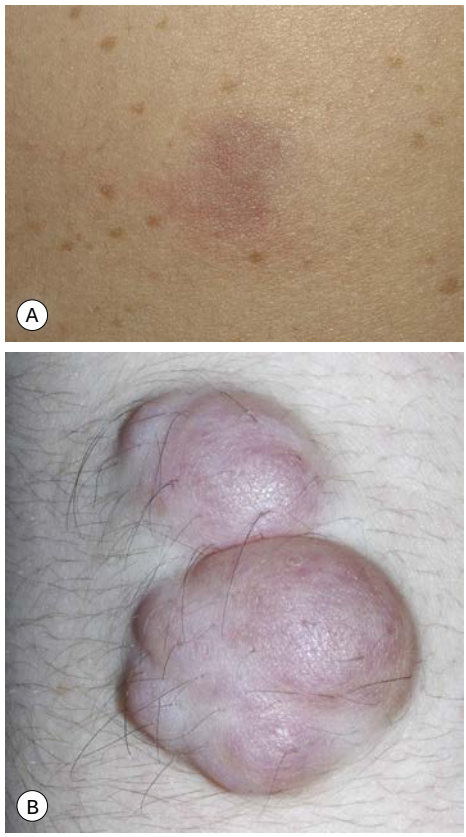


**Fig. 50.3 Spectrum of cutaneous neurofibromas.** Lesions range from subtle blue-red macules **(A)** to exophytic nodules with associated hypertrichosis **(B)**. *Courtesy, Julie V. Schaffer, MD.*

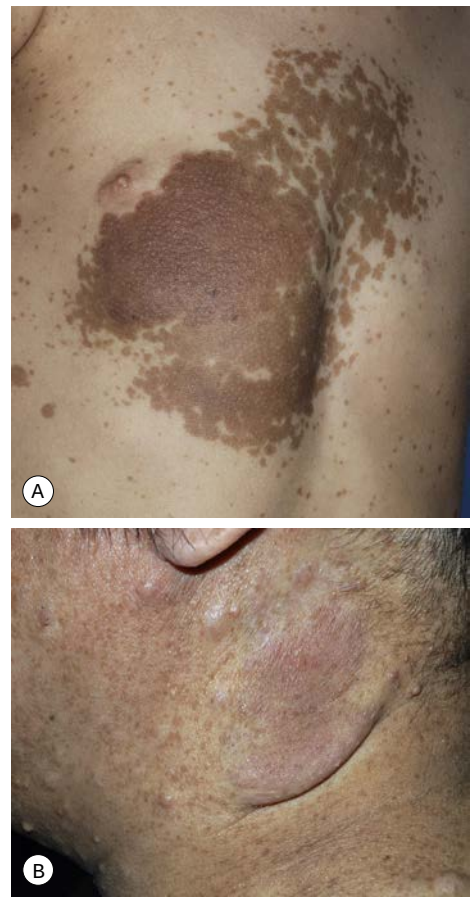


**Fig. 50.4 Plexiform neurofibromas. A** A hyperpigmented plaque that may be misdiagnosed as a congenital melanocytic nevus or (if not palpated) a café-au-lait macule. Note the widespread "freckling" on the trunk. **B** A poorly circumscribed, sagging pink mass. *Courtesy, Julie V. Schaffer, MD.*

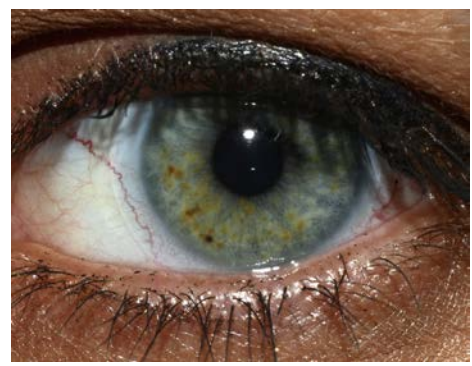

**Fig. 50.5 Lisch nodules.** Multiple yellow-brown papules of the iris. Although best seen using a slit lamp, Lisch nodules may also be evident on clinical examination in patients with lightly pigmented eyes. *Courtesy, Julie V. Schaffer, MD.*

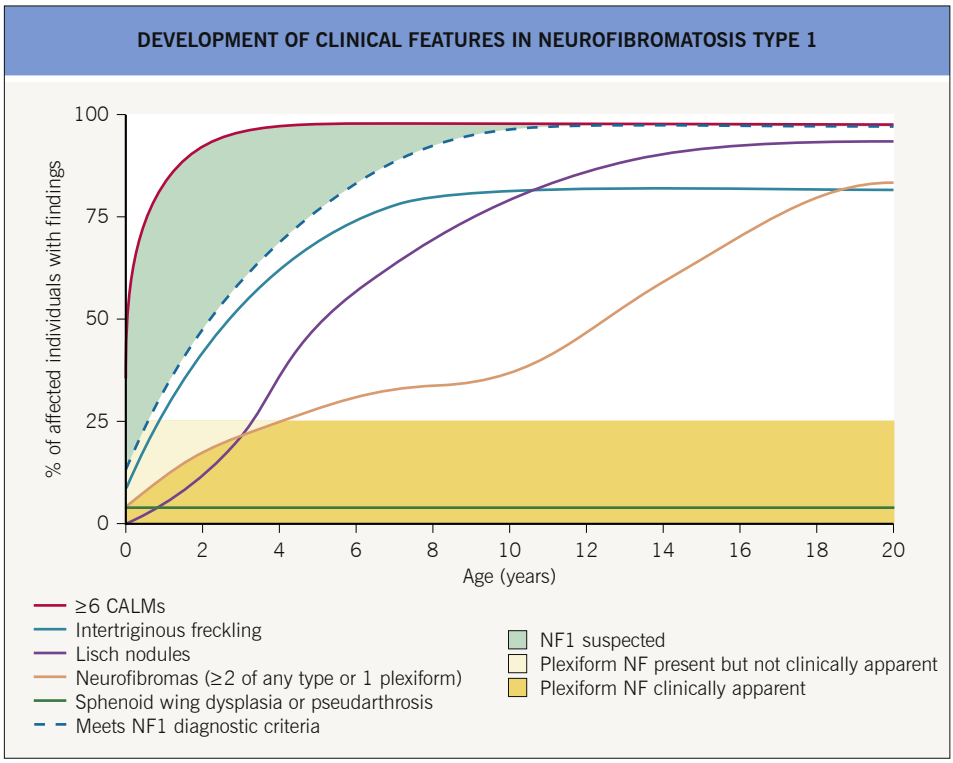


**Fig. 50.6 Development of clinical features in neurofibromatosis type 1.** The time course of major diagnostic lesions that develop in NF1. During the first few years of life, a child may have only café-au-lait macules. *Adapted from DeBella K, Szudek J, Friedman JM. Use of the National Institutes of Health criteria for diagnosis of neurofibromatosis 1 in children. Pediatrics 2000;105:608–614.*

- Numerous small, confetti-like hypopigmented macules (especially on the extremities) represent a relatively specific finding for TS (Fig. 50.10B).
- Angiofibromas (formerly known as "adenoma sebaceum") are smooth, dome-shaped, pink to red-brown papules (Fig. 50.12); they favor the central face and sometimes coalesce to form plaques.
  - **DDx:** one or two angiofibromas (fibrous papules) can occur in the general population, and multiple facial angiofibromas can develop in multiple endocrine neoplasia type 1 (MEN1) and Birt–Hogg–Dubé syndrome (see Ch. 91)
- Variants of angiofibromas include cephalic fibrous plaques (e.g. on forehead or other facial sites) (see Fig. 50.12), ungual fibromas (Koenen tumors; toes > fingers) (Fig. 50.13), and molluscum pendulum (resembling large skin tags) in flexural sites.
- Shagreen patches are collagenomas with a predilection for the lower back; they present as skin-colored, hyperpigmented or (less often) hypopigmented plaques with an uneven, pigskin-like surface (Fig. 50.14).
- Infantile spasms affect ~70% of TS patients, typically beginning at 3–6 months of age; the spectrum of *T*SC-*a*ssociated *n*europsychiatric *d*isorders (TAND) can also include intellectual impairment, autism, attention deficit disorder, and psychiatric conditions.
- Additional extracutaneous manifestations and diagnostic criteria are listed in Table 50.5.

| REVISED DIAGNOSTIC CRITERIA FOR NEUROFIBROMATOSIS TYPE 1 (NF1) AND MOSAIC NF1 |
|---|
| **Diagnostic criteria for NF1** |
| Requires **two or more** of the following in an individual ***without a parent diagnosed with NF1*** and **one or more** of the following in an individual ***with a parent diagnosed with NF1***:<br>• Six or more café-au-lait macules >5 mm in prepubertal individuals and >15 mm in post-pubertal individuals*<br>• "Freckling" in the axillary or inguinal region*<br>• Two or more neurofibromas of any type *or* one plexiform neurofibroma<br>• Optic pathway glioma<br>• Two or more Lisch nodules (iris hamartomas) or two or more choroidal abnormalities<br>• A distinctive osseous lesion such as sphenoid dysplasia, anterolateral bowing of the tibia, or pseudoarthrosis of a long bone<br>• A heterozygous pathogenic *NF1* variant with a variant allele fraction of 50% in apparently normal tissue (e.g. white blood cells) |
| **Diagnostic criteria for mosaic NF1** |
| Requires any of the following in an individual ***without a parent diagnosed with NF1*:**<br>• A heterozygous pathogenic *NF1* variant with a variant allele fraction of significantly <50% in apparently normal tissue (e.g. white blood cells) **AND** one of the other NF1 criteria above<br>• An identical heterozygous pathogenic *NF1* variant in two anatomically independent affected tissues, in the absence of a pathogenic *NF1* variant in unaffected tissue<br>• A clearly segmental distribution of café-au-lait macules or cutaneous neurofibromas **AND** *either* another NF1 criterion** *or* offspring diagnosed with NF1<br>• One of the *clinical* NF1 criteria above *other than* café-au-lait macules **AND** offspring diagnosed with NF1 |
| **If only café-au-lait macules and freckling are present, at least one should be bilateral; the diagnosis is most likely NF1 but may rarely be another condition such as Legius syndrome.*<br>***If only café-au-lait macules and freckling are present, the diagnosis is most likely mosaic NF1 but may rarely be mosaic Legius syndrome or constitutional mismatch repair deficiency syndrome (see Table 50.3).* |

**Table 50.2 2021 revised diagnostic criteria for neurofibromatosis type 1 (NF1) and mosaic NF1.** *Adapted from Legius E, Messiaen L, Wolkenstein P, et al. Revised diagnostic criteria for neurofibromatosis type 1 and Legius syndrome: an international consensus recommendation. Genet Med 2021;23:1506-13.*

- Recommendations for evaluation and management are presented in Table 50.6.
- **Rx:** systemic administration of mTOR inhibitors (rapamycin [sirolimus], everolimus) for astrocytomas, renal angiomyolipomas, and pulmonary lymphangioleiomyomas; topical rapamycin (0.1–1%), lasers (pulsed dye or ablative), and electrosurgery to treat angiofibromas; sun protection to potentially prevent development of angiofibromas.

For further information see Ch. 61 From *Dermatology, Fourth Edition*.

**For additional online figures visit www.expertconsult.com**

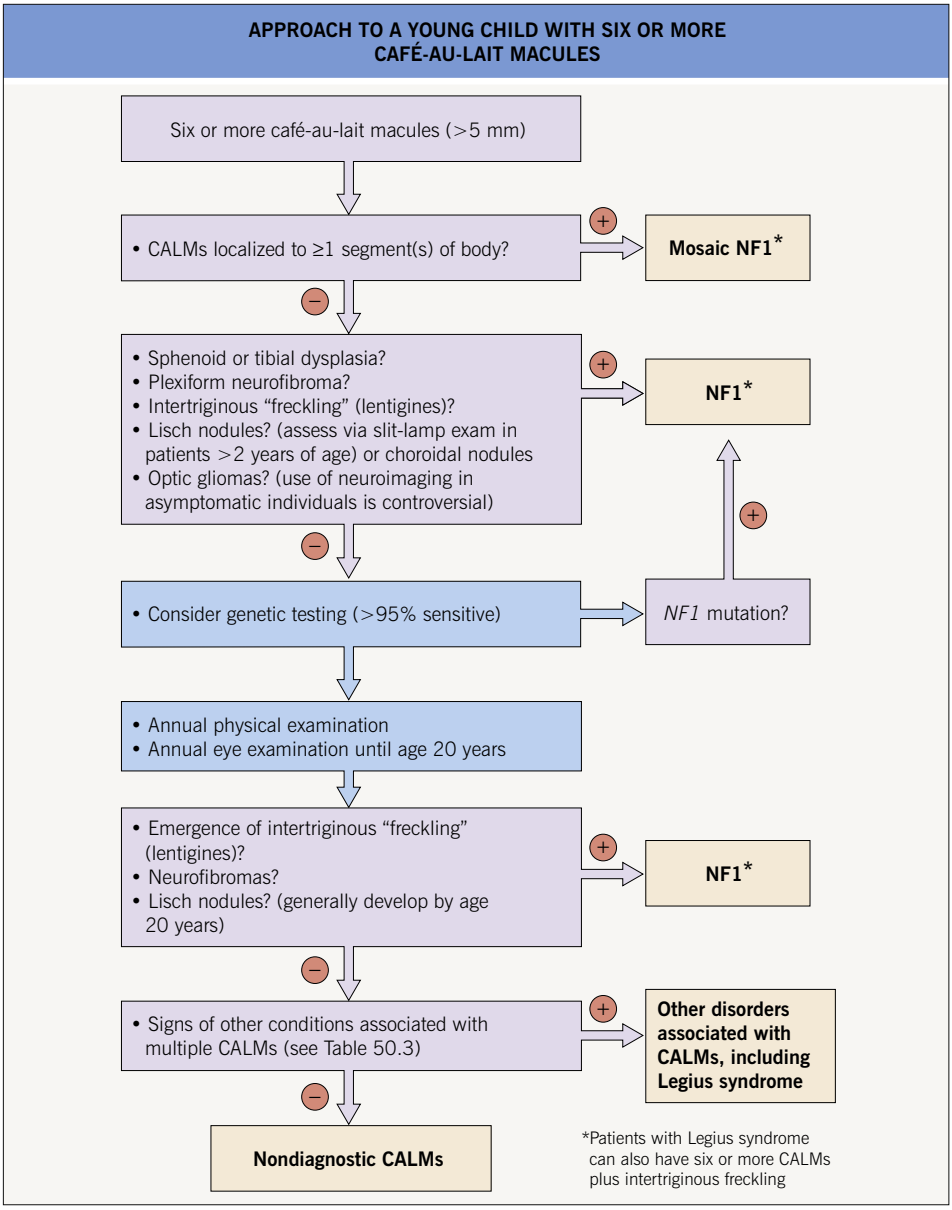


**Fig. 50.7 Approach to a young child with six or more café-au-lait macules (CALMs).** More than half of these patients will eventually be diagnosed with NF1 or, less often, another CALM-associated syndrome (see Table 50.3). The latter should be considered if other signs of NF1 do not develop.

| OTHER DISORDERS ASSOCIATED WITH MULTIPLE CAFÉ-AU-LAIT MACULES (CALMs) | |
|---|---|
| **Disorder** | **Additional features** |
| **Mosaic conditions** | |
| Mosaic (segmental) NF1 (see Table 50.2)† | CALMs ± "freckling" in a segmental distribution (e.g. block-like) (Fig. 50.8A); can also have neurofibromas (Fig. 50.8B); post-zygotic *NF1* mutations – if in gonads, could potentially pass on generalized NF1 to offspring |
| McCune–Albright syndrome | CALMs often block-like or in broad bands along the lines of Blaschko with midline demarcation and irregular ("coast of Maine") borders; polyostotic fibrous dysplasia; endocrine hyperfunction (e.g. precocious puberty); activating *GNAS1* mutations (encodes $G_s\alpha$) in affected tissues |
| "Pigmentary mosaicism" due to chromosomal anomalies | CALMs often have irregular borders; may be segmental or follow the lines of Blaschko (see Ch. 51) |
| **Other RASopathies (characterized by increased MAPK signaling)** | |
| Legius syndrome | AD; ≥6 CALMs in >80% ± intertriginous "freckling" (~50%); *lacks* neurofibromas, Lisch nodules, and optic gliomas; often macrocephaly, learning disabilities; loss-of-function *SPRED1* mutations |
| Noonan syndrome* | AD; lymphedema, webbed neck; KP (atrophicans); nevi; short stature, characteristic facies, developmental delay; cardiac defects, especially pulmonic stenosis; activating mutations in *PTPN11* > *SOS1*, *RAF1, RIT1* > *KRAS*, *NRAS, MAP2K1*; Noonan-like: *SHOC12* (loose anagen hair), *CBL* (JML) |
| Noonan syndrome with multiple lentigines (LEOPARD syndrome) | Called "café noir" macules due to dark color; *l*entigines, electrocardiogram abnormalities, *o*cular hypertelorism, *p*ulmonary stenosis, *a*bnormalities of genitalia, *r*etardation of growth, *d*eafness; *PTPN11* mutations |
| **Disorders characterized by genomic instability** | |
| Constitutional mismatch repair deficiency syndrome | AR; multiple CALMs, axillary freckling, neurofibromas, CNS gliomas (similar to NF1); also other malignancies (e.g. hematologic, colorectal) |
| Fanconi anemia* (see Ch. 55), Bloom syndrome* (see Ch. 73), ataxia–telangiectasia* (see Ch. 49) | |
| **Other tumor predisposition syndromes** | |
| Neurofibromatosis type 2* | AD; cutaneous and bilateral vestibular schwannomas; meningiomas, spinal tumors; *NF2* gene |
| Tuberous sclerosis* | See text |
| PTEN hamartoma tumor syndrome*, MEN1*, and MEN2B* (see Ch. 52) | |
| **Disorders of pigmentation** | |
| Piebaldism (CALMs in leukodermic and uninvolved skin; see Ch. 54), familial progressive hyper- and hypopigmentation (see Ch. 55) | |

†*DDx may include a large speckled lentiginous nevus (nevus spilus) or partial unilateral lentiginosis (see Ch. 92).*
**Multiple CALMs in small minority of affected individuals.*

**Table 50.3 Other disorders associated with multiple café-au-lait macules (CALMs).** Of note, approximately 30% of the general population has at least one CALM. AD, autosomal dominant; AR, autosomal recessive; JML, juvenile myelomonocytic leukemia; KP, keratosis pilaris; MAPK, mitogen-activated protein kinase; NF1, neurofibromatosis type 1.

| EVALUATION AND MANAGEMENT OF NEUROFIBROMATOSIS 1 (NF1) PATIENTS |
|---|
| **At time of diagnosis and annually** |
| Dermatologic examination (especially if a plexiform neurofibroma [PNF] is present)<br>• Surgical consultation if painful or disfiguring neurofibromas<br>• PET/CT if rapid growth, increased firmness, or persistent pain in an established PNF |
| Neurologic examination<br>• MRI and/or other studies (e.g. PET/CT if related to a PNF) if neurologic signs/symptoms* |
| Cardiac assessment (*at initial diagnosis*) and measurement of blood pressure<br>• Renal arteriography and 24-hour urine collection for catecholamines and metanephrines if hypertension |
| **At the time of diagnosis and annually, depending on the age of the patient** |
| Evaluation for scoliosis and other bony defects (e.g. tibial bowing) (*annually only in children/adolescents*)<br>Neurodevelopmental/behavioral evaluation (*annually only in children/adolescents*) |
| Ophthalmologic examination with visual assessment (*prior to 8 years of age*)<br>• Orbital/brain MRI if signs/symptoms of optic glioma (e.g. visual compromise, proptosis)<br>Assessment for precocious pubertal development (*prior to ~8 years of age*)<br>Measurement of head circumference (*in young children*) |
| Screening for breast cancer with clinical examination + mammography ± MRI (*in women, beginning by age 30 years*) |
| **The role of neuroimaging in asymptomatic patients is controversial.* |

**Table 50.4 Evaluation and management of neurofibromatosis 1 (NF1) patients.** PET/CT, positron emission tomography/computed tomography.




**Fig. 50.8 Mosaic neurofibromatosis. A** Multiple small café-au-lait macules and "freckling" limited to the left side of the trunk and groin, with slight extension past the midline. **B** A cluster of soft, pink to pink-brown papules limited to the thigh. There were no associated café-au-lait macules. *A, Courtesy, Antonio Torrelo, MD; B, Courtesy, Jean L. Bolognia, MD.*

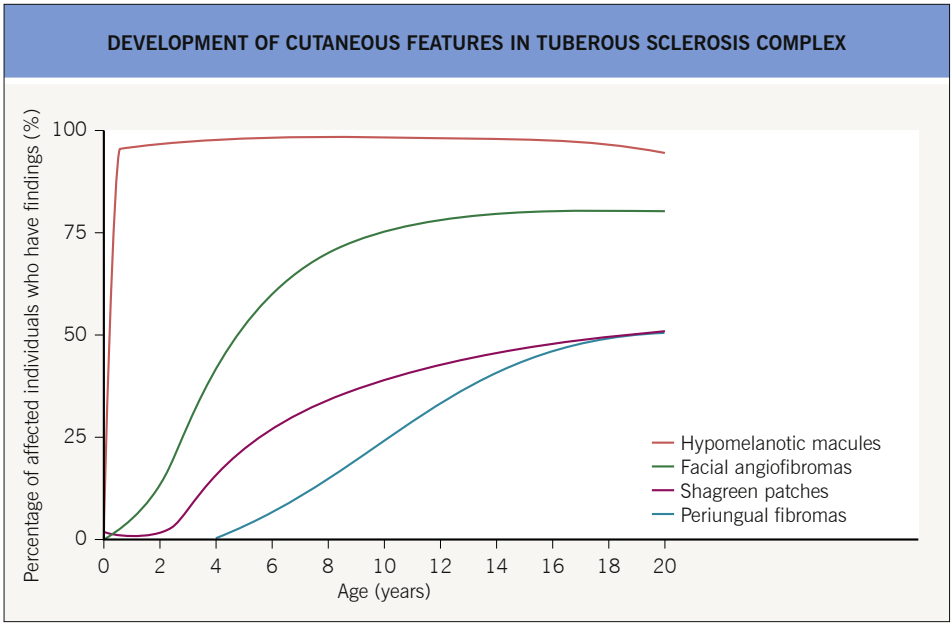


**Fig. 50.9 Development of cutaneous features in tuberous sclerosis complex.** Hypomelanotic macules are usually the only cutaneous finding at birth.




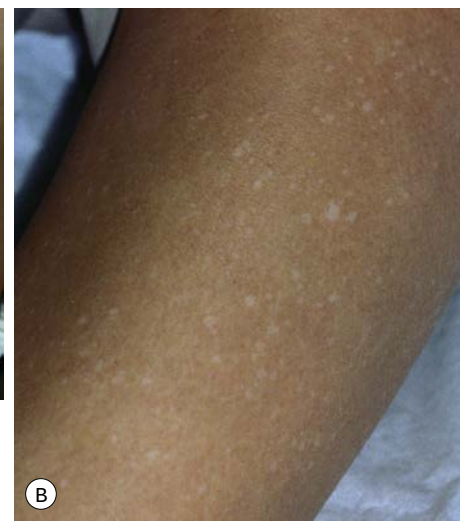


**Fig. 50.10 Hypopigmentation in tuberous sclerosis complex. A** Ash leaf macules. **B** "Confetti" macules of guttate leukoderma. *A, Courtesy, Julie V. Schaffer, MD; B, Courtesy, Jean L. Bolognia, MD.*

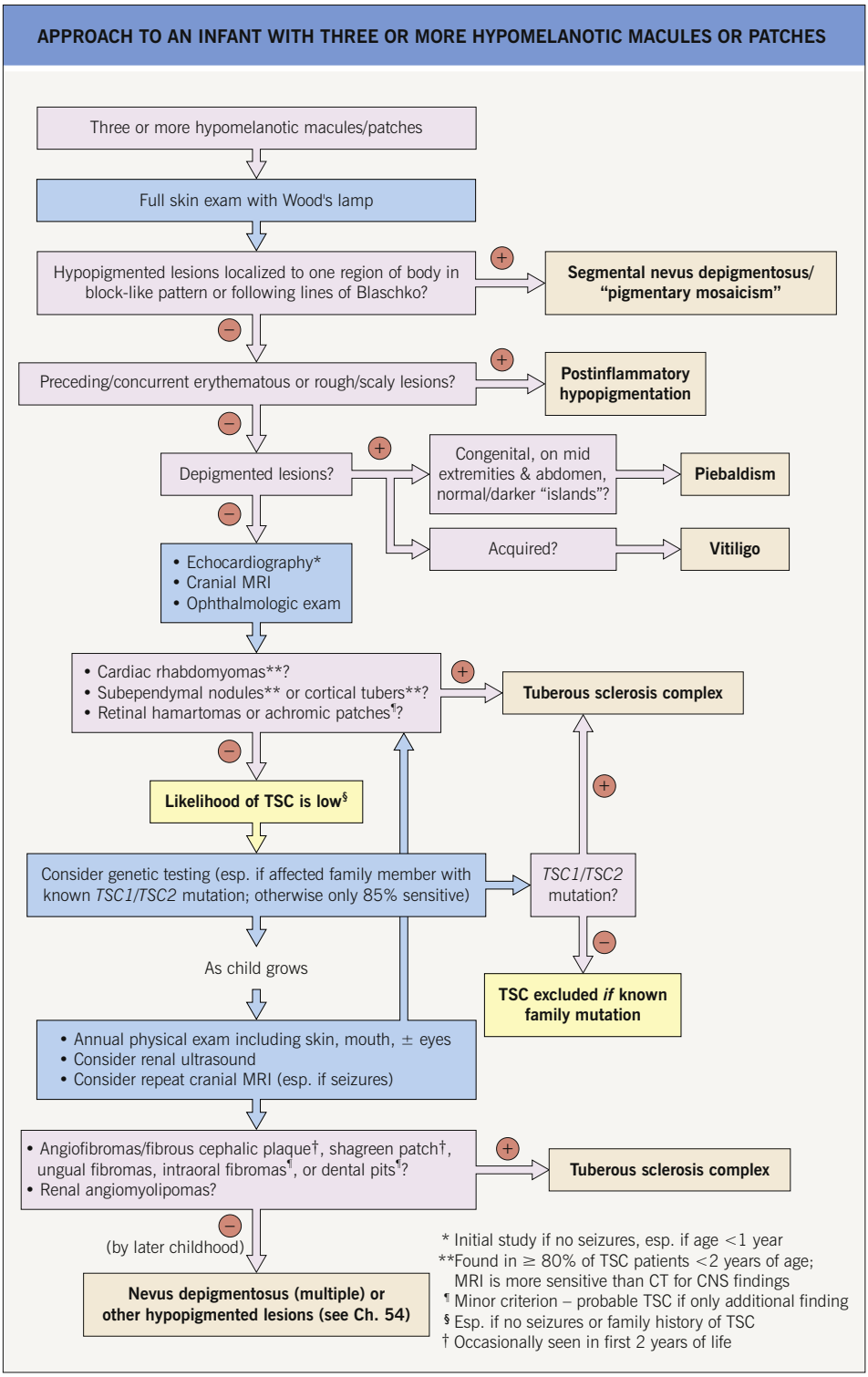


**Fig. 50.11 Approach to an infant with three or more hypomelanotic macules or patches.** A child with fewer than three macules and no family history of tuberous sclerosis complex (TSC) has an extremely low likelihood of having this disease.



**Fig. 50.12 Facial angiofibromas.** Multiple small, pink-tan, dome-shaped papules on the cheeks and nose of a young boy. Note the brown fibrous plaque on the lower right cheek. Early angiofibromas are sometimes confused with acne, but taking photos at two points in time will show that individual lesions are persistent. Sun protection may help to prevent the development of angiofibromas in patients with tuberous sclerosis complex, as UV-induced DNA damage has been implicated in the development of these lesions. *Courtesy, Julie V. Schaffer, MD.*



**Fig. 50.13 Ungual fibromas of tuberous sclerosis complex.** Multiple fibromas of the toes arising in a periungual location. Note the associated longitudinal grooves. *Courtesy, Julie V. Schaffer, MD.*



**Fig. 50.14 Shagreen patch (collagenoma) in tuberous sclerosis complex.** These plaques can be hyperpigmented or hypopigmented relative to the patient's background skin. The surface is said to resemble leather or pigskin. *Courtesy, Julie V. Schaffer, MD.*

| 2012 REVISED DIAGNOSTIC CRITERIA FOR TUBEROUS SCLEROSIS COMPLEX (TSC) | | |
|---|---|---|
| **Major features** | | |
| Hypomelanotic macules (≥3, diameter ≥5 mm)<br>Facial angiofibromas (≥3) or fibrous cephalic plaque<br>Ungual fibromas (≥2)<br>Shagreen patch | | |
| Multiple retinal hamartomas<br>Cortical dysplasias (including tubers and cerebral white matter radial migration lines)<br>Subependymal nodules<br>Subependymal giant cell astrocytoma<br>Cardiac rhabdomyoma<br>Lymphangioleiomyomatosis<br>Angiomyolipomas (≥2; renal >> other organs, e.g. liver) | | |
| **Minor features** | | |
| "Confetti" skin lesions | | |
| Dental enamel pits (≥3)<br>Intraoral fibromas (≥2)<br>Retinal achromic patch<br>Multiple renal cysts<br>Non-renal hamartomas | | |
| **Definite *clinical* diagnosis**<br>• Either two major features* *or* one major feature plus ≥2 minor features<br>**Possible *clinical* diagnosis**<br>• Either one major feature or ≥2 minor features<br>**Definite *genetic* diagnosis**†<br>• Identification of a pathogenic mutation in either *TSC1* or *TSC2* in DNA from the blood or normal tissue | | |
| Key: | *Cutaneous* | *Extracutaneous* |

**With the exception of lymphangioleiomyomatosis + angiomyolipomas.*
*†Genetic testing is recommended when the diagnosis of TSC is suspected but cannot be clinically confirmed, as well as to assist in genetic counseling and family planning; 10–15% of patients who meet clinical diagnostic criteria for TSC have no pathogenic mutation identified by conventional genetic testing.*

**Table 50.5 2012 revised diagnostic criteria for tuberous sclerosis complex.**

| EVALUATION AND MANAGEMENT OF TUBEROUS SCLEROSIS COMPLEX (TSC) PATIENTS |
|---|
| **Evaluation for TSC-associated neuropsychiatric disorder (TAND)**: at diagnosis and then annual screening, with comprehensive evaluation at ages 0–3, 3–6, 6–9, 12–16, and 18–25 years |
| **Ophthalmologic examination**: at diagnosis |
| **Brain MRI with and without gadolinium***: at diagnosis and every 1–3 years until age 25 |
| **Electroencephalogram (EEG)**: at diagnosis |
| **Electrocardiogram (ECG)**†: at diagnosis and every 3–5 years; **echocardiography**: at diagnosis if <3 years of age |
| **Abdominal MRI** (favored over CT or ultrasound) to detect angiomyolipomas and renal cysts: at diagnosis and every 1–3 years |
| **Assess blood pressure and determine GFR**: at diagnosis and at least annually |
| **High-resolution chest CT and PFTs** to assess for lymphangioleiomyomatosis: in adult women at diagnosis and then CT every 5–10 years |
| **Dental examination**: at diagnosis and every 6 months, with panoramic radiographs by age 7 years |
| **Dermatologic examination**: at diagnosis and annually |
| **Genetic testing/counseling**: offer to patients of reproductive age |
| **Findings may correlate with seizure activity and cognitive deficits; assess for enlarging lesions suggestive of giant cell astrocytomas (most common during childhood).*<br>*†Arrhythmias are more common in patients with TSC than the general population.* |

**Table 50.6 Evaluation and management of tuberous sclerosis complex (TSC) patients.** More frequent evaluation may be required for patients with symptoms and/or abnormal findings. GFR, glomerular filtration rate; PFTs, pulmonary function tests.



**eFig. 50.1 Café-au-lait macules and "freckling".** Oval-shaped, light-to medium-brown patches with regular borders and uniform pigmentation. Numerous lentigines are most commonly found in the axilla (Crowe sign). *Courtesy, Julie V. Schaffer, MD.*

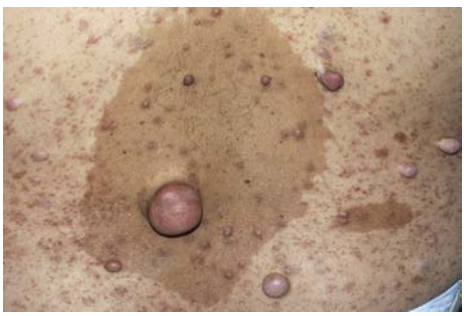

**eFig. 50.2 Multiple cutaneous neurofibromas.** Soft, skin-colored to pinkish tan, dome-shaped or polypoid, well-demarcated papules and nodules of various sizes in a patient with NF1. Neurofibromas may be superimposed on café-au-lait macules and lentigines. *Courtesy, Julie V. Schaffer, MD.*







**eFig. 50.3 Plexiform neurofibromas in patients with neurofibromatosis type 1.** **A** This sharply demarcated reddish-brown plaque had a "bag of worms" texture upon palpation. **B** This hyperpigmented plaque may be misdiagnosed as a café-au-lait macule if not palpated. *A, Courtesy, Julie V. Schaffer, MD; B, Courtesy, Antonio Torrelo, MD.*

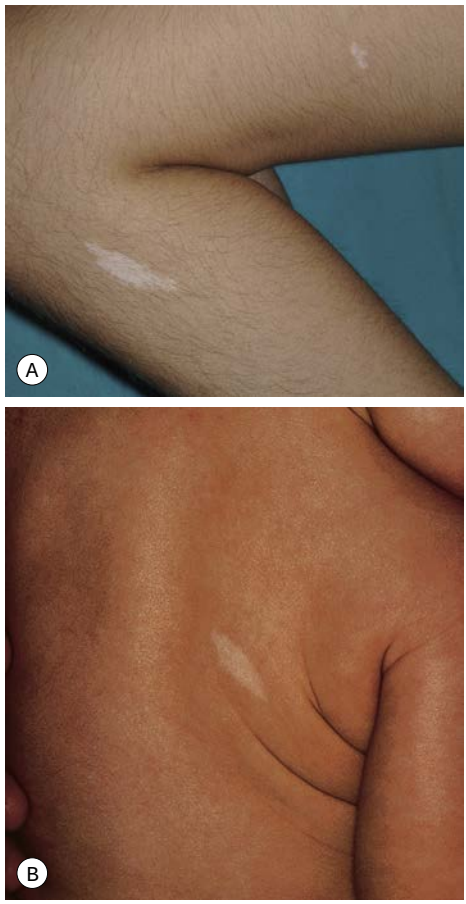


**eFig. 50.4 Ash leaf macules in tuberous sclerosis complex.** *A, Courtesy Ángela Hernández-Martín, MD; B, Courtesy, YDRSC.*




**eFig. 50.5 Facial angiofibromas and fibrous plaque in tuberous sclerosis complex. A** Multiple dome-shaped, pink-tan papules on the cheeks and nose of an adolescent. **B** Fibrous plaque on the forehead, which represents the most common location. **C** Multiple small dome-shaped papules as well as a larger fibrous plaque on the cheek. *A, Courtesy, Julie V. Schaffer, MD; B, Courtesy, Ángela Hernández-Martín, MD; C, Courtesy, YDRSC.*







**eFig. 50.6 Collagenoma variants in tuberous sclerosis complex. A** Shagreen patches are actually plaques, which can be hyperpigmented. The surface is said to resemble leather or pigskin. **B** The "folliculocystic and collagen hamartoma" features comedones and keratin-filled cysts as well as collagen deposition. *A, Courtesy, YDRSC; B, Courtesy, Antonio Torrelo, MD.*



**eFig. 50.7 Ungual fibromas of tuberous sclerosis complex.** Multiple fibromas of the toes arising in a periungual location. *Courtesy, YDRSC.*

# 51 Mosaic Skin Conditions

• A mosaic organism is composed of ≥2 genetically distinct cell populations derived from a homogeneous zygote.
  – *Genomic mosaicism* results from alteration in the DNA sequence, affecting genes or chromosomes
  – *Functional (epigenetic) mosaicism* results from changes in gene expression (but not the DNA sequence) that are passed on during cellular replication; an important example is *lyonization* in female embryos, where random inactivation of one of the two X chromosomes occurs in each cell during early development
• Clinical findings in mosaic skin conditions depend not only on the underlying genetic alteration but also on: (1) the timing of its origin, with earlier onset generally leading to more widespread involvement; and (2) the types of cells or tissues affected (cutaneous ± extracutaneous).
  – For example, mosaicism for an activating *HRAS* mutation can produce the combination of a nevus sebaceus (keratinocytes affected), speckled lentiginous nevus (melanocytes affected), and occasionally CNS abnormalities (nerve cells affected) in patients with phakomatosis pigmentokeratotica
• The accessibility of the skin allows visualization of mosaic patterns.
  – The *lines of Blaschko* are streaks and swirls that represent pathways of epidermal cell (e.g. keratinocyte) migration during embryonic development (Fig. 51.1)
  – Segmental (e.g. block-like) patterns can also reflect cutaneous mosaicism involving melanocytes, mesodermal cells, or nerve cells
• Types of cutaneous lesions that can follow the lines of Blaschko or have a block-like/segmental pattern are outlined in Tables 51.1 and 51.2, respectively (Fig. 51.2).
• In *chimerism*, different cell populations reflect a genetically heterogeneous zygote, e.g. from fusion of two zygotes or fertilization of one egg by two sperm; this may manifest with a checkerboard, linear, or irregular pattern of pigmentary variation.

## Epidermal Nevi and "Epidermal Nevus Syndromes"

• Epidermal nevi (see Ch. 89) present as streaks and swirls of thickened (e.g. verrucous, hyperkeratotic, or velvety) skin along the lines of Blaschko, usually with hyperpigmentation and sometimes with adnexal involvement (e.g. in a nevus sebaceus or nevus comedonicus) (Fig. 51.3).
• The heterogeneous genetic etiologies and potential systemic associations ("epidermal nevus syndromes") of various types of epidermal nevi are presented in Table 51.3 (Fig. 51.4).

## Mosaicism in Autosomal Dominant Skin Conditions

• When evaluating a patient with skin lesions in a mosaic pattern, it can be helpful to consider whether the findings would resemble an autosomal dominant genodermatosis if present in a more generalized distribution.
• Type 1, type 2, and revertant forms of mosaicism occurring in autosomal dominant skin disorders are summarized in Fig. 51.5.
• Some dominant mutations in autosomal genes are only observed in a mosaic state, as they would not be compatible with life if present in all the cells of the body; examples

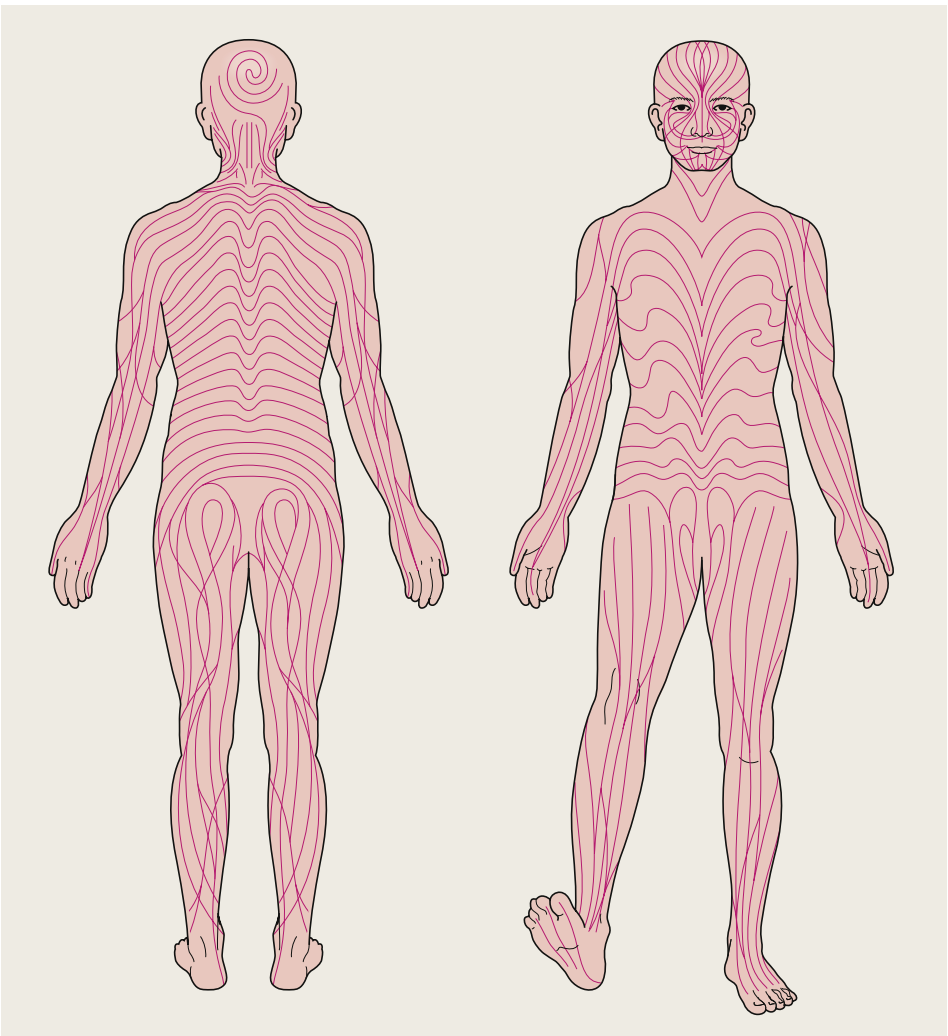


**Fig. 51.1 Lines of Blaschko.** Note the S-shape of lines on the abdomen, the V-shape on the central back, perpendicular lines on the face, and swirls on the posterior scalp.

include Proteus, Schimmelpenning (nevus sebaceus), and McCune–Albright syndromes (see Tables 50.3 and 51.3).

## Mosaicism in X-Linked Conditions

- In X-linked disorders, functional mosaicism due to lyonization occurs in female patients and carriers.
- *X-linked dominant* conditions are typically lethal in male embryos and are therefore seen almost exclusively in a mosaic pattern in female patients with a heterozygous mutation; male patients occasionally survive due to underlying mosaicism, e.g. in the setting of Klinefelter syndrome (47,XXY karyotype) or a postzygotic mutation.
- In conditions traditionally referred to as *X-linked recessive*, male patients have generalized disease and female patients or "carriers" are affected to a variable (usually lesser) degree, often in a mosaic pattern; an example is hypohidrosis and hyperpigmentation following the lines of Blaschko in female "carriers" of X-linked hypohidrotic ectodermal dysplasia (Fig. 51.6A).

| SKIN FINDINGS THAT CAN OCCUR ALONG THE LINES OF BLASCHKO | |
|---|---|
| **Inflammation** | |
| **Examples** | **Clinical clues** |
| Lichen striatus (Fig. 51.2A) | • Pink to hypopigmented flat-topped papules; common in children (see Ch. 9) |
| Linear lichen planus (Fig. 51.2B) | • Violaceous flat-topped papules with Wickham striae; often in adults |
| "Blaschkitis" | • Pruritic erythematous papulovesicles in multiple streaks on the trunk; usually develops in adults and often recurs |
| Inflammatory linear verrucous epidermal nevus (ILVEN) (Fig. 51.2C) | • Scaly, erythematous psoriasiform plaques with prominent pruritus and lack of response to therapy; onset usually by childhood |
| Linear psoriasis (Fig. 51.2D) | • Psoriasiform plaques, often responding to therapy and associated with psoriasis elsewhere |
| *Other conditions resembling lichen planus*: linear GVHD, lupus erythematosus > dermatomyositis, drug eruptions<br>*Other conditions with a keratotic and/or vesiculobullous component*:<br>• Variable onset: linear Darier (Fig. 51.2E) and Hailey–Hailey (Fig. 51.2F) diseases<br>• Early onset: linear porokeratosis (see Fig. 89.8D), PEODDN, IP* stages 1–2 (see Figs 28.10 and 51.7A), epidermolytic epidermal nevus*, Conradi–Hünermann–Happle syndrome* (see Fig. 46.13) | |
| **Verrucous lesions** – e.g. epidermal/sebaceous nevi (Table 51.3; see Fig. 51.3), IP stage 2 (see Fig. 51.7B) | |
| **Spines/comedones** – e.g. nevus comedonicus (Table 51.3; see Fig. 51.3G), PEODDN (favors palms/soles), linear lichen planopilaris (later onset; see Fig. 9.5H) | |
| **Hypopigmentation** (see Table 54.3) | |
| **Hyperpigmentation** (see Table 55.4) | |
| **Hairlessness** – e.g. X-linked hypohidrotic ectodermal dysplasia (female "carriers"; Fig. 51.6A), Goltz syndrome, IP stage 4 (Fig. 51.7C) | |
| **Atrophy** – e.g. linear lichen sclerosus (epidermal wrinkling), linear atrophoderma of Moulin (hyperpigmented and depressed; Fig. 51.6B), Goltz syndrome (Fig. 51.8A,B), IP stage 4, Conradi–Hünermann–Happle syndrome (follicular atrophoderma) | |
| **Papulonodular lesions**** – e.g. adnexal neoplasms (e.g. trichoepitheliomas), BCCs, basaloid follicular hamartomas | |
| **Inflammatory manifestations occur primarily during infancy.*<br>***In addition to conditions with inflammatory or verrucous papulonodules noted above.* | |

**Table 51.1 Skin findings that can occur along the lines of Blaschko.** IP, incontinentia pigmenti; PEODDN, porokeratotic eccrine ostial and dermal duct nevus.

| SKIN FINDINGS THAT CAN HAVE A SEGMENTAL PATTERN THAT REFLECTS MOSAICISM |
|---|
| **Hypopigmentation** – e.g. nevus depigmentosus, segmental vitiligo (see Ch. 54) |
| **Hyperpigmention** ± **hypertrichosis** – e.g. CALM, Becker melanosis (nevus)/smooth muscle hamartoma (see Table 50.3 and Ch. 55) |
| **Hypertrichosis** – e.g. X-linked congenital generalized hypertrichosis (female "carriers") |
| **Vascular lesions** – e.g. port wine stain,† CMTC, unilateral nevoid telangiectasia, venous malformation,* plaque-type glomuvenous malformation,** segmental infantile hemangioma (see Ch. 85) |
| **Papulonodular lesions** – e.g. segmental leiomyomas** or neurofibromas** |
| *†Associated with mosaic activating mutations in the GNAQ gene encoding the Q-class G protein α-subunit; mutations in this gene have also been associated with dermal melanocytosis, which occurs as "twin spots" with port wine stains in phakomatosis pigmentovascularis.*<br>**Type 1 segmental manifestation of an autosomal dominant disorder (Fig. 51.5).*<br>***Type 2 segmental manifestation of an autosomal dominant disorder (Fig. 51.5).* |

**Table 51.2 Skin findings that can have a segmental pattern that reflects mosaicism.** CALM, café-au-lait macule; CMTC, cutis marmorata telangiectatica congenita.




**Fig. 51.2 Inflammatory lesions along the lines of Blaschko.** **A** Lichen striatus on the leg presenting as linear streaks composed of multiple pink papules with variable scale. **B** Linear lichen planus presenting as a band of coalescing violaceous papules and plaques with Wickham striae on an extremity. Note the postinflammatory hyperpigmentation proximally. **C** Inflammatory linear verrucous epidermal nevus (ILVEN) featuring persistent, extremely pruritic, scaly psoriasiform plaques. **D** Linear psoriasis with erythema and scale that responded to treatment with a high-potency topical CS. Small scattered psoriasiform lesions are also present. **E** Linear Darier disease presenting with keratotic papules in an adult, representing type 1 mosaicism (see Fig. 51.5A). *A, Courtesy, Tetsuo Shiohara, MD, and Yoshiko Mizukawa, MD; B, Courtesy, Joyce Rico, MD; C, E, Courtesy, YDRSC; D, Courtesy, Celia Moss, MD.* *Continued*




**Fig. 51.2** *Continued* **Inflammatory lesions along the lines of Blaschko. F** Linear Hailey–Hailey disease presenting with recurrent blistering and erosions in a young girl, representing type 2 mosaicism with earlier and more severe involvement in the affected region due to a "second hit" mutation (see Fig. 51.5B). *F, Courtesy, Julie V. Schaffer, MD.*










**Fig. 51.3 Epidermal nevi (EN). A** Non-epidermolytic EN presenting as S-shaped hyperpigmented papillomatous streaks on the abdomen with sharp midline demarcation. **B** Non-epidermolytic EN in a V-shaped pattern on the mid back. **C** Non-epidermolytic EN with hyperpigmented keratotic streaks accentuated in skin folds. **D** Epidermolytic EN with shedding of scale and associated hypopigmentation. *A, C, Courtesy, Julie V. Schaffer, MD; B, D, Courtesy, YDRSC.* *Continued*




**Fig. 51.3** *Continued* **Epidermal nevi (EN). E** Non-epidermolytic EN due to a *FGFR3* mutation, representing a mosaic counterpart of the acanthosis nigricans in thanatophoric dysplasia, an autosomal dominant neuroskeletal syndrome. This explains the flexural accentuation of the epidermal nevus. **F** Extensive non-epidermal EN presenting as hypopigmented streaks with variable adherent scale. **G** Nevus comedonicus with inflammatory papulonodules as well as comedones in an adolescent. The lesion initially presented as a congenital hypopigmented streak. *E, Courtesy, Celia Moss, MD; F, G, Courtesy, Julie V. Schaffer, MD.*

## Incontinentia Pigmenti (IP)

- X-linked dominant disorder caused by mutations in the *N*F-κB *e*ssential *mo*dulator (*NEMO; IKBKG*) gene, which encodes a protein that protects against TNF-α-induced apoptosis; male patients with milder *NEMO* mutations may present with hypohidrotic ectodermal dysplasia with immune deficiency (see Table 52.5).
- IP has four stages, which may be absent or overlapping, of cutaneous findings that follow the lines of Blaschko (with the exception of stage 4) (Fig. 51.7; see Fig. 28.10):
  - *Vesicular* streaks favoring the extremities and scalp in neonates, often associated with peripheral blood leukocytosis and eosinophilia; may recur during childhood febrile illnesses
  - *Verrucous* linear plaques favoring the extremities in infants; acral keratotic nodules sometimes develop after puberty
  - *Hyperpigmented* grayish-brown streaks and swirls favoring the trunk and intertriginous areas from infancy through adolescence
  - *Hypopigmented/atrophic* "Chinese character"-like bands lacking hair and sweat glands, favoring the calves in adolescents and adults
- Other manifestations can include alopecia (often at the vertex in a swirled pattern), missing or conical teeth, CNS abnormalities (e.g. seizures, developmental delay), and retinal vascular anomalies that require monitoring with ophthalmologic examinations during infancy.

## Goltz Syndrome (Focal Dermal Hypoplasia)

- X-linked dominant condition caused by mutations in the *PORCN* gene, which encodes a protein that regulates Wnt signaling.
- Skin lesions following the lines of Blaschko are characterized by vermiculate dermal

| EPIDERMAL NEVI: SELECTED VARIANTS AND POTENTIAL SYNDROMIC ASSOCIATIONS | | | |
|---|---|---|---|
| **Type of epidermal nevus (EN)** | **Gene** | **Generalized conditions caused by constitutional mutations*** | **Potential syndromic associations with the EN** |
| Epidermolytic verrucous EN | *KRT1, KRT10* | Epidermolytic ichthyosis, PPK *(KRT1)* | None |
| Non-epidermolytic verrucous EN | Mosaic RASopathies (also nevus sebaceus [see below] and woolly hair nevi) | | |
| | *HRAS* > *NRAS* > *KRAS, BRAF* | Costello, Noonan, and cardio-facio-cutaneous syndromes (see Table 50.3) | Cutaneous skeletal hypophosphatemic syndrome (CSHS); phakomatosis pigmentokeratotica with speckled lentiginous nevus |
| | Mosaic FiGRopathies (also nevus sebaceous and acneiform nevi; see below) | | |
| | *FGFR3*§ > *FGFR2* | Thanatophoric dysplasia, SADDAN, Beare–Stevenson cutis gyrata | Asymmetric craniofacial malformations, intellectual disability |
| | Mosaic AKTopathies (see Ch. 85) | | |
| | *PIK3CA*§ | Cowden syndrome variant (rare) | Asymmetric overgrowth, lipomatosis, vascular anomalies, digital anomalies, macrocephaly; cerebriform connective tissue nevi of palms/soles (Proteus) |
| | *AKT1* | Not reported | |
| | *PTEN* | PTEN hamartoma (e.g. Cowden) syndrome | |
| Nevus sebaceus | *HRAS* > *KRAS*; rarely *FGFR2* | See above | Schimmelpenning syndrome (CNS, ocular, skeletal); CSHS (see above) |
| Munro acne nevus (hypopigmented background skin) | *FGFR2* | Apert syndrome | Digital anomalies, intellectual disability |
| Nevus comedonicus | *NEK9* | Skeletal dysplasia (with biallelic mutations) | Digital anomalies, scoliosis |
| Porokeratotic adnexal ostial nevus¶ | *GJB2* | Keratitis–ichthyosis–deafness (KID) syndrome | |
| Inflammatory linear verrucous epidermal nevus (ILVEN) | *GJA1* ?*NSHDL* | Erythrokeratodermia variabilis et progressiva<br>? CHILD syndrome (mosaic) | Distal limb reductions |

**Could potentially occur in the offspring of an epidermal nevus patient who has gonadal as well as cutaneous mosaicism.*
*§Somatic activating mutations are also found in seborrheic keratoses, dermatosis papulosa nigra, stucco keratoses, and solar lentigines; the PIK3CA-related overgrowth spectrum includes Klippel–Trenaunay syndrome, megalencephaly–capillary malformation, and CLOVES (see Ch. 85).*
*¶Includes porokeratotic eccrine ostial and dermal duct nevus (PEODDN) and other spiny hyperkeratotic EN. Mosaic RAS mutations found in epidermal nevi are often (but not always) different from those in generalized conditions, suggesting that the former represent more severe, lethal mutations rescued by mosaicism.*

**Table 51.3 Epidermal nevi: selected variants and potential syndromic associations.** CHILD, congenital hemidysplasia with ichthyosiform erythroderma/nevus and limb defects; FGF, fibroblast growth factor; GJA1/B2, gap junction α1/β2; KRT, keratin; PPK, palmoplantar keratoderma; SADDAN, severe achondroplasia with developmental delay and acanthosis nigricans.

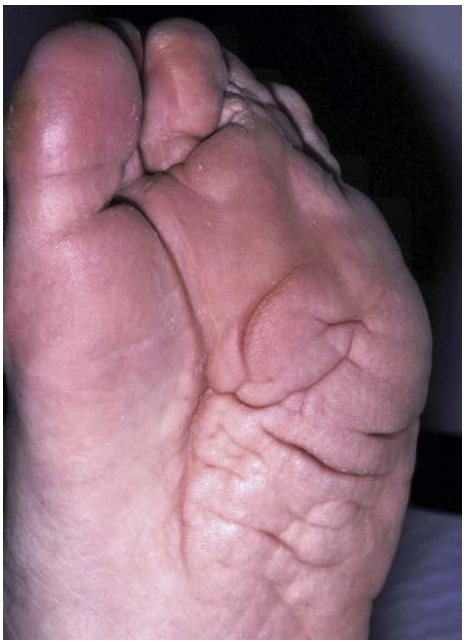

**Fig. 51.4 Plantar cerebriform connective tissue nevus in a man with Proteus syndrome.** *Courtesy, Odie Enjolras, MD.*

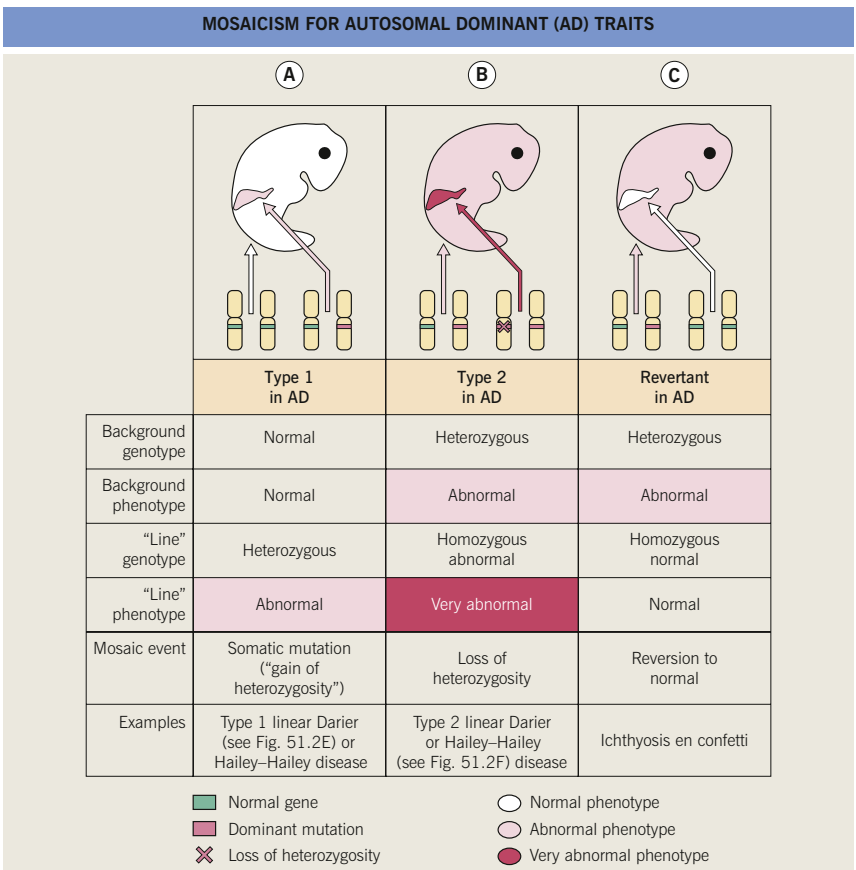


**Fig. 51.5 Mosaicism for autosomal dominant (AD) traits. A** *See next page for figure legend.*

**Fig. 51.5 Mosaicism for autosomal dominant (AD) traits. A** *Type 1 mosaicism* features a linear distribution of the skin lesions that characterize an AD genodermatosis in the absence of involvement elsewhere on the body. This results from a postzygotic heterozygous mutation in the underlying gene that is only present in the affected region. **B** *Type 2 mosaicism* presents with a more severe linear lesion superimposed on the background of a generalized AD genodermatosis. This reflects a constitutional (in all the cells of the body) heterozygous mutation plus a "second hit" in the other allele of the gene within the more severely affected region. **C** In *revertant mosaicism*, an area of normal-appearing skin occurs in the background of a generalized AD genodermatosis due to a reversion ("back" mutation) to normal or another correction of the underlying heterozygous mutation in that region. Of note, mosaicism can also occur in autosomal recessive conditions, with revertant mosaicism potentially leading to a spared area (e.g. in epidermolysis bullosa).




**Fig. 51.6 Hyperpigmentation along the lines of Blaschko. A** In this 2-year-old female "carrier" of X-linked hypohidrotic ectodermal dysplasia, the skin within the hyperpigmented streaks and swirls is extremely smooth. Starch-iodine testing on the back disclosed a patchy distribution of active sweat glands. The patient also had whorled areas of sparse hair on the posterior scalp and several cone-shaped teeth. **B** Linear atrophoderma of Moulin presenting as streaks of hyperpigmented depressions with "cliff-drop" borders. The morphology resembles atrophoderma of Pasini and Pierini. *A, B, Courtesy, Julie V. Schaffer, MD.*




**Fig. 51.7 Incontinentia pigmenti. A** Stage 1 with streaks of erythema and vesicles in a neonate. **B** Stages 2 (verrucous) and 3 (hyperpigmented). Note the keratotic lesions on the toes. The scalloped edges of the hyperpigmented streaks reflect growth of normal keratinocytes into areas of apoptosis. **C** Stage 4 (atrophic and hypopigmented). Note the absence of hairs within the streaks on the calf. *A, Courtesy, Robert Silverman, MD; B, Courtesy, Julie V. Schaffer, MD; C, Courtesy, USCDRSC.*

phy, outpouchings of fat, telangiectasias, and hypo- > hyperpigmentation (Fig. 51.8).

• Additional features include periorificial raspberry-like papillomas, dystrophic nails, sparse hair, abnormal teeth, split hand/foot ("lobster claw") malformations, ocular abnormalities (e.g. microphthalmia), and the radiographic finding of osteopathia striata in long bones.

### X-Linked Dominant Ichthyosiform Conditions

• Examples include *c*ongenital *h*emidysplasia with *i*chthyosiform nevus and *l*imb *d*efects (CHILD) and Conradi–Hünermann–Happle syndromes (see Table 46.2).

### Mosaic Manifestations of Acquired Skin Conditions

• Multifactorial skin disorders with environmental as well as genetic components occasionally occur along the lines of Blaschko or in a segmental distribution, presumably reflecting mosaicism for a "susceptibility" mutation; as a result, such conditions often develop in older children or adults following an environmental trigger, and they are sometimes superimposed on a pre-existing mosaic lesion (e.g. psoriasis within an epidermal nevus).

• Other examples include linear lichen planus, linear GVHD, and segmental vitiligo (see Fig. 51.2B, D).

For further information see Ch. 62 from *Dermatology, Fourth Edition*.

**For additional online figures visit www.expertconsult.com**







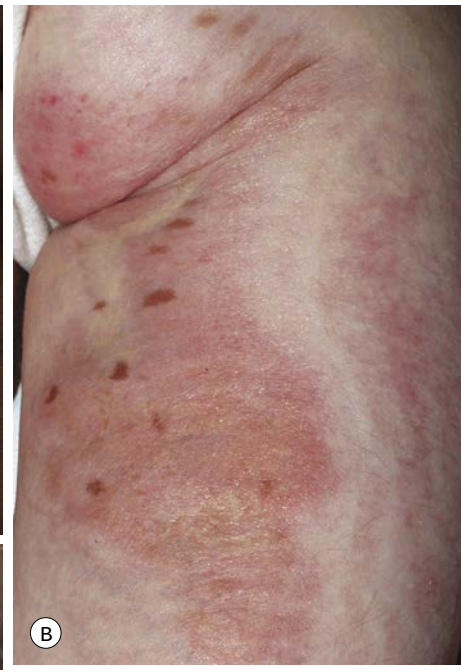


**Fig. 51.8 Goltz syndrome. A** Hypopigmented streaks of vermiculate atrophy. **B** Bands of telangiectatic erythema, dermal atrophy with fat "herniation," and hyperpigmented macules on the posterior thigh. **C** Raspberry-like papules on the lower lip. Similar lesions can occur in the anogenital region and may be confused with warts. *A–C, Courtesy, Julie V. Schaffer, MD.*



**eFig. 51.1 Linear psoriasis.** The pink, scaly plaques responded to topical corticosteroid therapy. *Courtesy, Julie V. Schaffer, MD.*

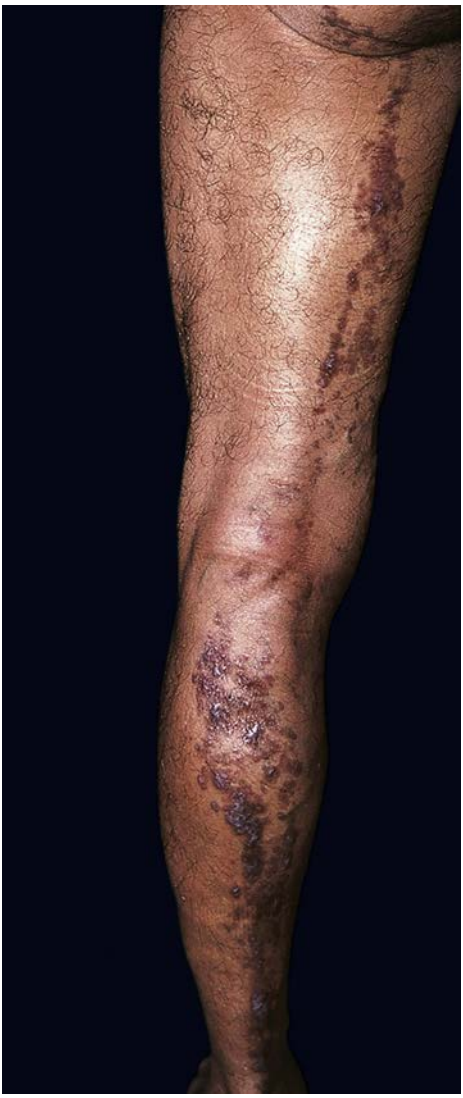

**eFig. 51.2 Linear lichen planus.** More active lesions are seen on the calf, while postinflammatory hyperpigmentation predominates on the thigh. *Courtesy, Anthony J. Mancini, MD.*




**eFig. 51.3 Epidermal nevi. A** Extensive involvement on the trunk and arm. The lesions on the neck are more verrucous. **B, C** Accentuation in the groin. **D** Extensive hypopigmented streaks with variable scale, which is accentuated in the popliteal fossae. *A, Courtesy, YDRSC; B–D, Courtesy, Julie V. Schaffer, MD.*







**eFig. 51.4 Woolly hair and epidermal nevi due to a mosaic *HRAS* mutation in a young girl. A** Focal areas of curly hair with a woolly texture amid a background of straight hair. **B** A thin tan epidermal nevus with subtle elevation that is more evident with side lighting. *Courtesy, Julie V. Schaffer, MD.*

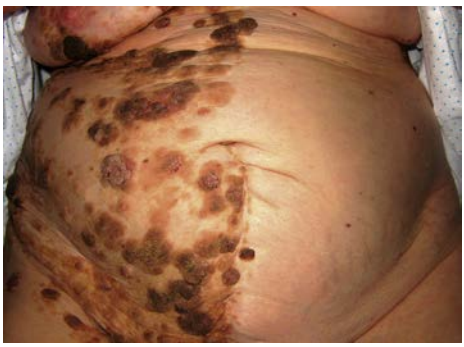

**eFig. 51.5 Unilateral seborrheic keratoses in bands following the lines of Blaschko.** Seborrheic keratoses often have a somatic activating mutation in *FGFR3* or *PIK3CA*. *Courtesy, Luis Requena, MD.*

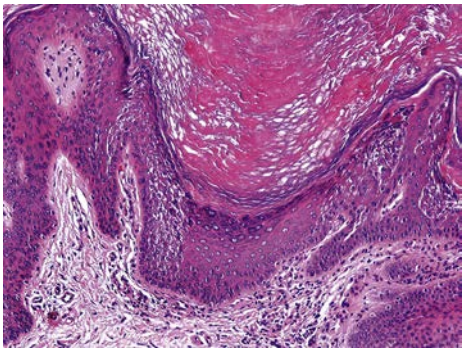

**eFig. 51.6 Histopathologic features of epidermolytic verrucous epidermal nevus.** Histopathology shows verrucous epidermal hyperplasia with prominent compact hyperkeratosis associated with granular and vacuolar degeneration of keratinocytes in the spinous and granular layers (epidermolytic hyperkeratosis). *Courtesy, Luis Requena, MD.*



**eFig. 51.7 SOLAMEN – *s*egmental *o*vergrowth, *l*ipomatosis, *a*rteriovenous *m*alformation, and *e*pidermal *n*evus – syndrome.** Epidermal nevus, vascular malformations, and localized fatty infiltration on the thigh. *Courtesy, Celia Moss, MD.*



**eFig. 51.8 Linear atrophoderma of Moulin.**
*Courtesy, Julie V. Schaffer, MD.*




**eFig. 51.9 Incontinentia pigmenti. A, B** Stage 1 presenting as vesicular and crusted lesions. **C** Stages 2 and 3 with hyperpigmented and hyperkeratotic lesions. **D** Stage 3 with residual involvement in the axilla of a young girl. **E** Histologically, numerous eosinophils are present within the dermis and epidermis (inset). *A, Courtesy, Helen T Shin, MD; B, Courtesy, Andrea Zaenglein, MD; C, D Courtesy, Julie V. Schaffer, MD; E, Courtesy, Lorenzo Cerroni, MD.*

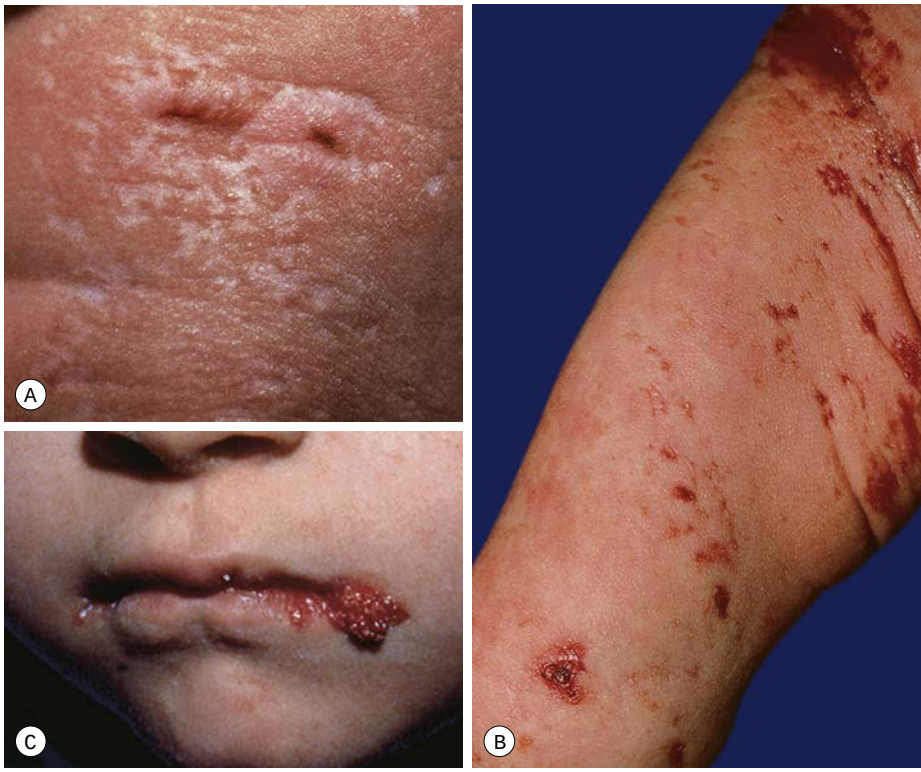


**eFig. 51.10 Goltz syndrome (focal dermal hypoplasia). A** Hypopigmented streaks of vermiculate atrophy and fat herniation. **B** Streaks of telangiectasias plus erosions on the leg. **C** Several erythematous, raspberry-like papules on the lips. The most prominent lesion is at the angle of the mouth. Similar lesions can occur in the anogenital region and may be confused with warts. *A, B, Courtesy, YDRSC; C, Courtesy, Celia Moss, MD.*

# Other Genodermatoses 52

This chapter discusses genetic skin diseases that are not covered in other chapters, including conditions featuring extracutaneous tumorigenesis, enzyme deficiencies, premature aging, and ectodermal dysplasia.

## Disorders Featuring Extracutaneous Tumorigenesis

### Cowden Syndrome and Other Forms of PTEN Hamartoma Tumor Syndrome

- Spectrum of autosomal dominant multisystem disorders that feature characteristic skin findings (Fig. 52.1), macrocephaly, hamartomatous overgrowth of a variety of tissues, and a predisposition to certain cancers (Table 52.1).
- Due to mutations in the phosphatase and tensin homolog tumor suppressor gene (*PTEN*), which negatively regulates the AKT/mammalian target of rapamycin (mTOR) pathway of increased cellular growth and survival.

### Multiple Endocrine Neoplasia Syndromes

- Group of autosomal dominant disorders associated with neoplasia or hyperplasia in two or more endocrine organs, often presenting with mucocutaneous findings that serve as clues to the diagnosis (Table 52.2; Fig. 52.2).

### Muir–Torre Syndrome (MTS)

- Subtype of hereditary nonpolyposis colorectal cancer (Lynch) syndrome characterized by sebaceous neoplasms (e.g. sebaceous adenoma, sebaceoma, sebaceous carcinoma; Fig. 52.3, see Table 91.2) and keratoacanthomas (± sebaceous differentiation) as well as internal malignancies (Table 52.3).
- Caused by heterozygous constitutional mutations in a DNA mismatch repair gene, e.g. *MSH2* (70–90% of patients), *MLH1*, and *MSH6*.

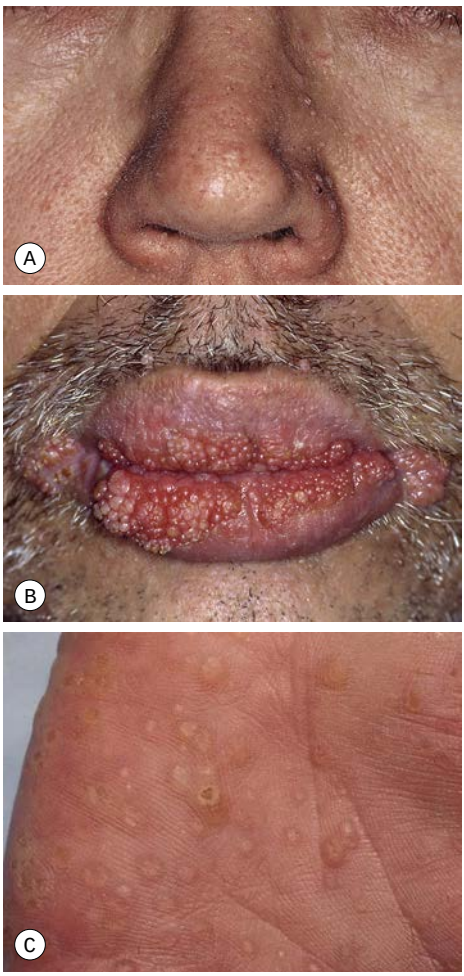


**Fig. 52.1 Cowden syndrome. A** Multiple skin-colored papules on the face, especially the nose, some of which are verrucous. **B** Coalescing papules with a cobblestone-like appearance on the vermilion lips. **C** Multiple palmar keratoses, many with a glassy appearance or depression centrally. *A, Courtesy, Kalman Watsky, MD; B, Courtesy, Jean L. Bolognia, MD; C, Courtesy, Joyce Rico, MD.*

| MAJOR CLINICAL MANIFESTATIONS OF PTEN HAMARTOMA TUMOR SYNDROME | | |
|---|---|---|
| | **Onset at birth or in childhood – *classic features of BRR*** | **Onset in adolescence or adulthood – *classic features of Cowden syndrome*** |
| Mucocutaneous | • Pigmented genital macules (penis > vulva)<br>• Lipomas<br>• Vascular anomalies*<br>• Epidermal nevi<br>• Café-au-lait macules<br>• Neuromas (acrofacial, mucosal) | • Multiple facial tricholemmomas (Fig. 52.1A; see Ch. 91) and other verrucous papules (especially periorificial and on ears)<br>• Multiple oral papillomas (lips, tongue) (Fig. 52.1B)<br>• Acral/palmoplantar keratoses (Fig. 52.1C)<br>• Sclerotic fibromas<br>• Multiple acrochordons, acanthosis nigricans |
| Extracutaneous | • Macrocephaly, intracranial developmental venous anomalies<br>• High-arched palate, adenoid facies<br>• Scoliosis/kyphosis, pectus excavatum<br>• GI: ganglioneuromas, hamartomatous polyps<br>• CNS: developmental delay, autism | • Breast: fibrocystic disease, fibroadenomas, carcinoma (25–50% of women, mean age = 40 years; occasionally in men)<br>• Thyroid: goiter, adenomas, carcinoma (10–15% of patients; often follicular)<br>• GU: testicular lipomatosis, ovarian cysts, uterine leiomyomas, endometrial carcinoma (5–10% of women), renal cell carcinoma<br>• GI: colon carcinoma<br>• CNS: Lhermitte–Duclos disease† |

**Typically with fast-flow channels, intramuscular involvement, and ectopic fat; may have capillary, venous, and/or lymphatic components and associated soft tissue/bony overgrowth.*
*†Hamartomatous dysplastic gangliocytoma of the cerebellum.*

**Table 52.1 Major clinical manifestations of PTEN hamartoma tumor syndrome.** This categorization reflects general tendencies, as the age of onset or recognition of these findings can vary. Criteria for PTEN gene testing and guidelines for surveillance in patients suspected to have Cowden syndrome are available at http://www.nccn.org/professionals/physician_gls/PDF/genetics_screening.pdf. BRR, Bannayan–Riley–Ruvalcaba syndrome.

• Cutaneous findings develop at a mean age of ~55 years, presenting as yellow to pink papulonodules on the face (the usual site of sebaceous neoplasms outside of MTS) or trunk > extremities.

## Gardner Syndrome

• Variant of familial adenomatous polyposis syndrome with prominent extraintestinal involvement as well as premalignant GI polyps (typically by age 20 years) and colorectal carcinoma (usually by age 40 years); caused by heterozygous mutations in the adenomatous polyposis coli gene (*APC*).
• Epidermoid cysts often develop during childhood; pilomatricomas, fibromas, desmoid tumors (e.g. within abdominal scars), lipomas, and jaw osteomas are additional manifestations.
• *C*ongenital *h*ypertrophy of the *r*etinal *p*igment *e*pithelium (CHRPE) is an early sign.

## Birt–Hogg–Dubé Syndrome

• Autosomal dominant genodermatosis caused by mutations in the folliculin gene (*FLCN*).
• Onset during early adulthood of multiple fibrofolliculomas > trichodiscomas, presenting as small whitish papules on the face, ears, and neck (see Figs 91.4 and 91.16); also flexural acrochordons.

| CLASSIC MULTIPLE ENDOCRINE NEOPLASIA (MEN) SYNDROMES | | | |
|---|---|---|---|
| **MEN type** | **Gene** | **Major extracutaneous features** | **Cutaneous features** |
| 1 (Wermer) | *MEN1* (*MENIN*) | • **Pituitary** neoplasia (e.g. prolactinoma)<br>• **Parathyroid** hyperplasia/adenoma<br>• **Pancreatic** islet cell hyperplasia/adenoma/carcinoma | • Multiple facial angiofibromas<br>• Collagenomas (Fig. 52.2A), lipomas<br>• Multiple gingival papules<br>• Guttate hypopigmented macules |
| 2A (Sipple) | *RET* (especially codon 634) | • **Parathyroid** hyperplasia/adenoma<br>• **Thyroid** medullary carcinoma<br>• **Adrenal** pheochromocytomas | • Pruritus/notalgia paresthetica → macular or lichen amyloidosis on the upper back (often with childhood onset) |
| 2B (multiple mucosal neuroma syndrome) | *RET* (especially codon 918) | • **Thyroid** medullary carcinoma<br>• **Adrenal** pheochromocytoma<br>• **GI ganglioneuromatosis**<br>• Marfanoid habitus | • Multiple mucosal neuromas (especially on eyelid margins/conjunctiva, lips, tongue; Fig. 52.2B); rarely neuromas of perinasal skin |

**Table 52.2 Classic multiple endocrine neoplasia (MEN) syndromes.**

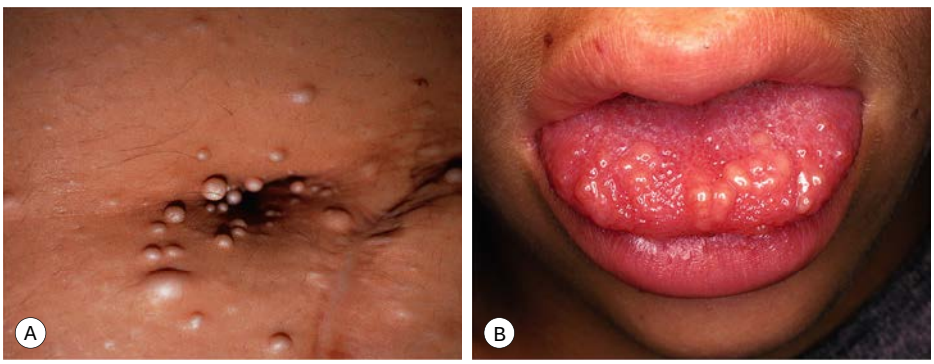


**Fig. 52.2 Mucocutaneous findings in multiple endocrine neoplasia (MEN). A** Multiple collagenomas in a patient with MEN type 1. **B** Enlarged nodular lips and multiple mucosal neuromas on the lateral and distal tongue in a patient with MEN type 2B. *A, Courtesy, Susan Bayliss, MD; B, Courtesy, YDRSC.*

• Increased risk of spontaneous pneumothoraces and renal cell carcinoma (especially oncocytic and chromophobe subtypes).

### Reed Syndrome (Hereditary Leiomyomatosis and Renal Cell Cancer Syndrome)

• Discussed in Chapter 95.

## Enzyme Deficiency Disorders

### Alkaptonuria

• Rare autosomal recessive disorder due to homogentisic acid oxidase deficiency.
• Urine that darkens on standing and brown-black cerumen represent early findings.
• Blue-gray discoloration of the axillary skin, ear (Fig. 52.4), and sclera typically ap-

pears during early adulthood, when arthritis and valvular heart disease often develop.



**Fig. 52.3 Muir–Torre syndrome with multiple sebaceous neoplasms.** *Courtesy, Dan Ring, MD.*

## Fabry Disease

- X-linked lysosomal storage disorder due to α-galactosidase A deficiency, which leads to glycosphingolipid accumulation within endothelial cells and results in progressive renal, coronary, and cerebrovascular insufficiency.
- Female heterozygotes have variable clinical manifestations, often with later onset than those in affected men.
- *Angiokeratoma corporis diffusum* presents as punctate dark red macules and papules clustered between the umbilicus and knees ("bathing trunk" distribution) (Fig. 52.5); serves as an early sign of Fabry disease, typically developing in childhood or adolescence along with paresthesias of the extremities, hypohidrosis, and whorled corneal opacities.

| RISK ASSESSMENT FOR MUIR–TORRE SYNDROME (MTS) | |
|---|---|
| **Higher likelihood of MTS** | **Lower likelihood of MTS** |
| **Clinicopathologic characteristics of skin lesions** | |
| • ≥2 sebaceous neoplasms **[2]**<br>• Located outside of the head and neck region<br>• Sebaceous neoplasm with high specificity for MTS, e.g. a cystic lesion or seboacanthoma | • Single sebaceous neoplasm<br>• Located in photodamaged facial skin<br>• Sebaceous hyperplasia |
| **Characteristics of patient and family history** | |
| • Age <60 years **[1]**<br>• Personal history of colorectal cancer* and/or other Lynch syndrome-related malignancies (e.g. small bowel, gastric, endometrial, bladder, ureteral, renal, biliary, pancreatic, glioblastoma) **[1]**, especially if more than one<br>• Colorectal cancer and/or other Lynch syndrome-related malignancies in family member(s) **[1]**, especially if before 50 years of age and in first-degree relative(s) | • Elderly patient with no history of a Lynch syndrome-related malignancy<br>• No family members with colorectal cancer/other Lynch syndrome-related malignancies |
| **Additional analysis of sebaceous neoplasms** | |
| • Loss of MSH2, MLH1, MLH6, and/or PMS2 expression shown by immunohistochemical staining‡<br>• Evidence of MSI in lesional tissue (more specific)§ | • Expression of MLH1, MSH2, MSH6, and PMS2 shown by immunohistochemical staining<br>• No evidence of MSI in lesional tissue§ |

**Especially if MSI-high histology – presence of tumor-infiltrating lymphocytes, Crohn disease-like lymphocytic reaction, medullary growth pattern, or signet ring/mucinous differentiation.*
*‡MSH2 and MSH6 proteins form a heterodimer, so lack of one can lead to the absence of the other; likewise, PMS2 is unstable without a functional MLH1 protein.*
*§Testing can be performed on paraffin-embedded tissue; diagnostic yield may be higher for colonic neoplasms.*

**Table 52.3 Risk assessment for Muir–Torre syndrome (MTS).** A clinical score of ≥2 based on the sum of the applicable numbers in [ ] has a sensitivity of nearly 100% and a specificity of ~80% for predicting a germline mutation in a mismatch repair gene. MSI, microsatellite instability.

- Fig. 52.6 compares the clinical features of Fabry disease and *fucosidosis*, one of several other lysosomal storage disorders associated with angiokeratomas.
- **Rx:** intravenous α-galactosidase A replacement therapy; migalastat, an oral pharmacologic chaperone that stabilizes mutant forms of α-galactosidase, is an alternative in patients with suitable mutations.



**Fig. 52.4 Blue-gray discoloration of the pinna in a woman with alkaptonuria.** *Courtesy, Julie V. Schaffer, MD.*

### Phenylketonuria

- Autosomal recessive disorder due to phenylalanine hydroxylase deficiency.
- Cutaneous findings can include diffuse pigmentary dilution (skin, hair, eyes), eczematous dermatitis, sclerodermatous skin changes favoring the proximal extremities (Fig. 52.7), and sweat with a musty odor; pigmentary banding of the hair can occur as a reflection of nonadherence to the diet.
- Newborn screening allows prevention of intellectual disability and skin changes through early nutritional intervention (e.g. a phenylalanine-restricted diet).

### Mitochondrial Disorders

- This heterogeneous group of conditions can present with a wide variety of cutaneous manifestations (Table 52.4) as well as neuromuscular and visceral dysfunction.

## Premature Aging Disorders

Inherited photosensitivity disorders (see Ch. 73) and Kindler syndrome (see Ch. 26) may also have features of premature aging.

### Hutchinson–Gilford Progeria Syndrome

- Accelerated aging due to heterozygous mutations in the *LMNA* gene; the mutant lamin A protein ("progerin") remains farnesylated and disrupts nuclear scaffolding.
- Onset during infancy of growth failure, facial findings (e.g. frontal bossing, protruding

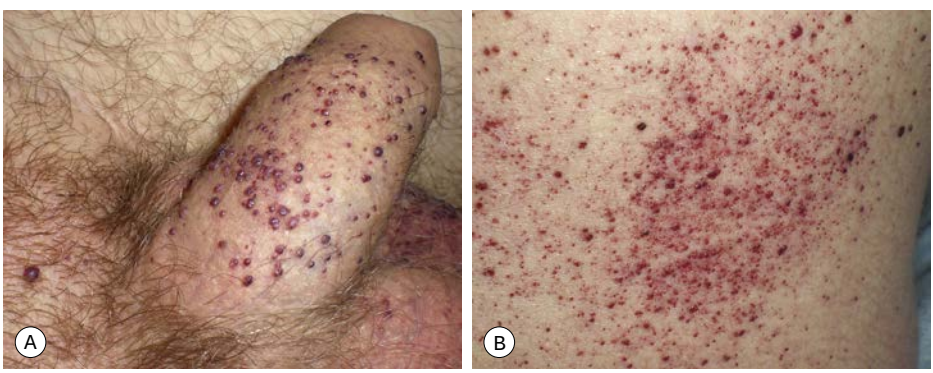


**Fig. 52.5 Angiokeratomas of Fabry disease.** Multiple dark red to red-brown macules and papules located: (**A**) on the penis, an uncommon site for angiokeratomas in the general population, as well as on the scrotum; and (**B**) on the lower trunk within a "bathing trunk" distribution. *Courtesy, Paula Luna, MD.*

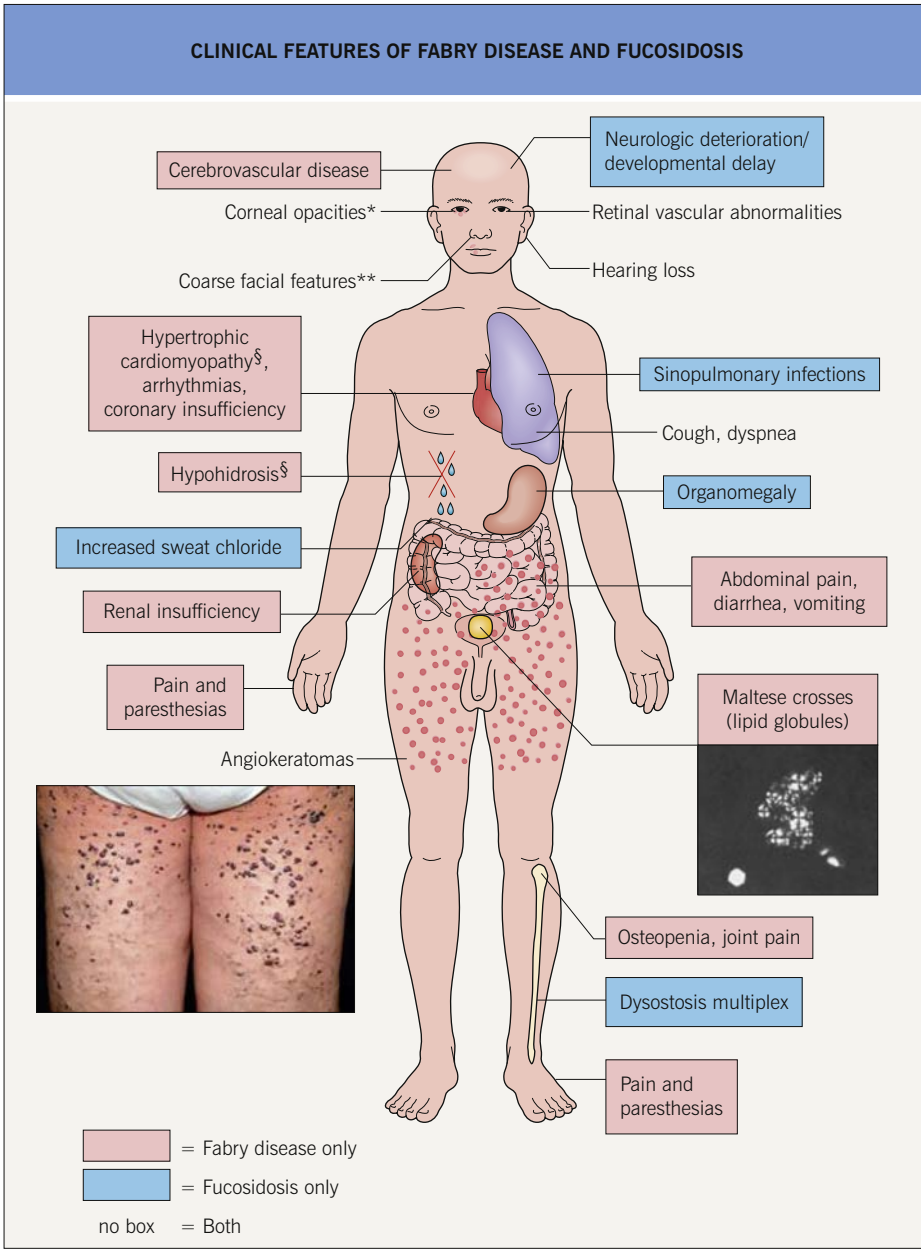


**Fig. 52.6 Clinical features of Fabry disease and fucosidosis.** Angiokeratomas are also seen in other metabolic disorders, including galactosialidosis, GM1 gangliosidosis, Kanzaki disease, β-mannosidosis, sialidosis, and aspartylglucosaminuria. *Also lenticular in Fabry disease. **Milder in Fabry disease. §Occasionally observed in fucosidosis. *Angiokeratomas of Fabry disease, courtesy, Luis Requena, MD; photomicrograph of urinary sediment demonstrating Maltese crosses (via polarization), courtesy, Robert J. Desnick, MD, PhD.*

eyes, prominent veins), decreased subcutaneous fat, and cutaneous manifestations such as thin dry skin, acral wrinkling, mottled hyperpigmentation, sclerodermoid changes (especially on the lower trunk and thighs), and alopecia.

- Progressive atherosclerosis results in a median life span of 14 years.

| CUTANEOUS MANIFESTATIONS OF MITOCHONDRIAL RESPIRATORY CHAIN DISORDERS |
|---|
| • Alopecia<br>• Hair shaft abnormalities – trichoschisis, pili torti, longitudinal grooving, trichorrhexis nodosa<br>• Hypertrichosis<br>• Absent or excessive sweating<br>• Pigmentary abnormalities – mottled or reticulated pigmentation<br>• Palmoplantar keratoderma (linked with deafness)<br>• Hypoplastic nails<br>• Lipomas<br>• Acrocyanosis |

**Table 52.4 Cutaneous manifestations of mitochondrial respiratory chain disorders.**



**Fig. 52.7 Phenylketonuria (PKU).** Infant with PKU and sclerodermoid skin changes. *Courtesy, New York Medical College.*

• **Rx:** inhibitors of farnesylation (e.g. lonafarnib) may be of benefit.

### Werner Syndrome

• Autosomal recessive disorder characterized by premature aging beginning in the second decade of life; caused by mutations in the *RECQL2* gene, which encodes a DNA helicase.

• Cutaneous findings include atrophy, mottled hyperpigmentation, sclerodermoid changes, keratoses and ulcers over pressure points (especially acrally), and premature graying of hair.

• Short stature, characteristic facies (e.g. thin with beaked nose), atherosclerosis, osteoporosis, diabetes mellitus, and an increased risk of sarcomas are additional features; median survival ~50 years.

## Ectodermal Dysplasias

• Large, heterogeneous group of genetic disorders characterized by abnormalities in ≥2 major ectodermal structures: the hair, sweat glands, nails, and teeth. Other ectodermal structures, e.g. sebaceous or mucous glands, may also be affected.

• Major features of several classic forms of ectodermal dysplasia are presented in Table 52.5 and Figs 52.8–52.11.

For further information see Ch. 63 from *Dermatology, Fourth Edition*.

**For additional online figures and tables visit www.expertconsult.com**

| SELECTED ECTODERMAL DYSPLASIA (ED) SYNDROMES | | | | | | |
|---|---|---|---|---|---|---|
| **Syndrome** | **Inheritance (gene)** | **Scalp hair** | **Sweating** | **Nails** | **Teeth** | **Other features** |
| Hypohidrotic ED (Figs 52.8 and 52.9) | XLR (*EDA*)* > AD, AR (*EDAR* > *EDARADD*) | Sparse–absent; often lightly pigmented in childhood | ↓↓, often leads to hyperpyrexia | Normal | Hypodontia, conical | • Frontal bossing, saddle nose, everted lips, periorbital wrinkling/hyperpigmentation, sebaceous hyperplasia<br>• ± Collodion-like membrane at birth; eczema later<br>• Frequent respiratory tract infections, thick cerumen |
| Hypohidrotic ED-immune deficiency | XLR (*NEMO*)** > AD (*NFKBIA*) | Sparse | ↓ | Normal | Hypodontia, conical | • Intertrigo, seborrheic-like dermatitis, erythroderma<br>• Colitis; recurrent infections (pyogenic, opportunistic); ↑ IgM, IgA; ↓ IgG<br>• Rare osteopetrosis, lymphedema |
| Hidrotic ED (Clouston syndrome) (Fig. 52.10) | AD (*GJB6*), most common in French Canadians | Wiry/brittle, variable alopecia | Normal | White in infants→ thickened with distal separation | Normal | • Diffuse PPK, "pebbled" skin on dorsal digits with EFSA<br>• Blepharitis, conjunctivitis |
| WNT10A-associated ED† | AR > AD (*WNT10A*) | Thin, sparse | ± ↓ | Dystrophic or absent | Hypodontia | • Facial telangiectasias, reticulated erythema, atrophy<br>• PPK with ESFA, xerosis |
| AEC (Hay–Wells) syndrome‡ (Fig. 52.11) | AD (*p63,* SAM domain) | Wiry/coarse, lightly pigmented, patchy alopecia | ± ↓ | Thickened > absent | Hypodontia, often conical | • Neonatal erythroderma with peeling skin/erosions<br>• Erosive scalp dermatitis<br>• Ankyloblepharon<br>• Cleft palate ± lip; GER<br>• ± Syndactyly |
| EEC syndrome | AD (*p63,* DNA-binding domain) | Coarse, lightly pigmented, ± sparse | Usually normal | Transverse ridges, pitting | Hypodontia, premature loss | • PPK, xerosis<br>• Cleft palate + lip<br>• Ectrodactyly > syndactyly |

**Variable phenotype with mosaic pattern (e.g. hypohidrosis and hyperpigmentation along the lines of Blaschko lines) in female "carriers" of XLR form.*
***Female carriers may have mild features of incontinentia pigmenti (see Ch. 51).*
*†Includes odonto-onycho-dermal dysplasia and Schöpf–Schulz–Passarge syndrome, which also features eyelid hidrocystomas.*
*‡Rapp–Hodgkin syndrome is now included in the AEC spectrum.*

**Table 52.5 Selected ectodermal dysplasia (ED) syndromes.** AD, autosomal dominant; AEC, ankyloblepharon–ED–clefting; AR, autosomal recessive; EDA, ectodysplasin A; EDAR, EDA receptor; EDARADD, EDAR-associated death domain; EEC, ED–ectrodactyly–clefting; ESFA, eccrine syringofibroadenomatosis; GER, gastroesophageal reflux; GJB6, gap junction β6 (encodes connexin 30); NEMO, NF-κB essential modulator; NFKBIA, NF-κB inhibitor-α; PPK, palmoplantar keratoderma; XLR, X-linked recessive.

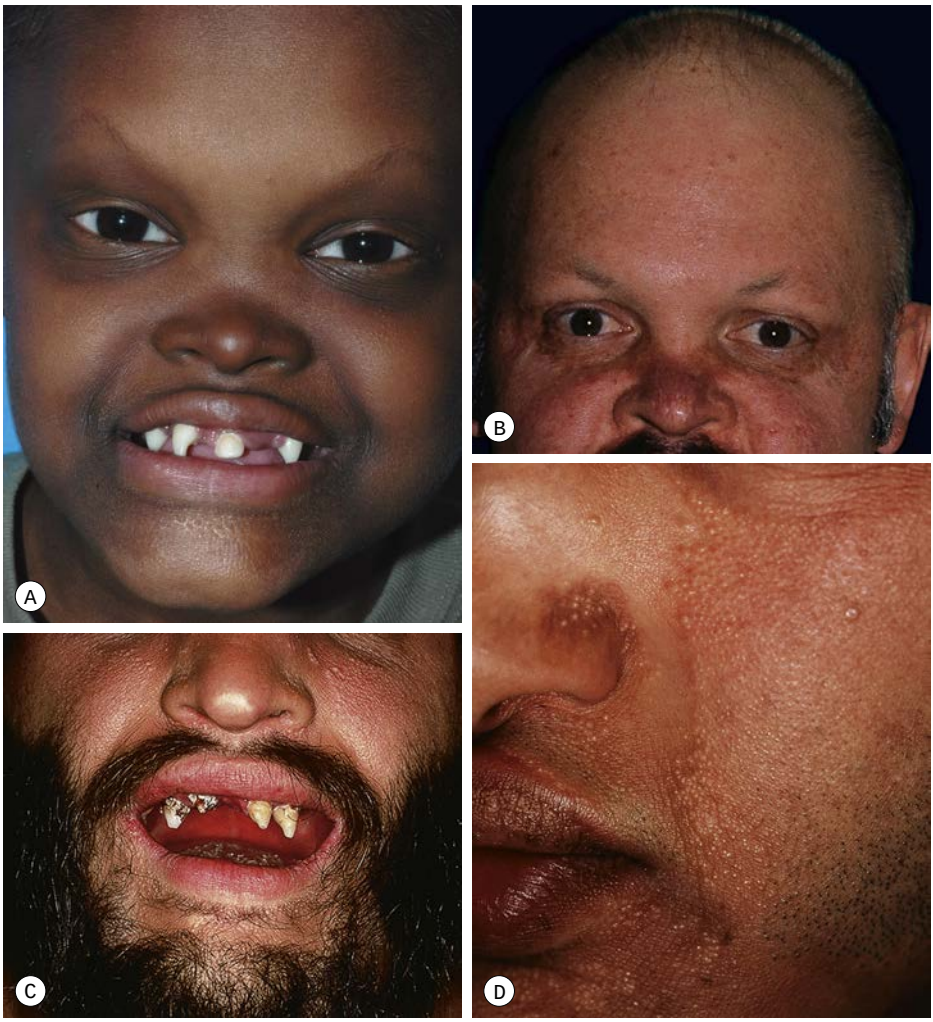


**Fig. 52.8 Male patients with hypohidrotic ectodermal dysplasia.** Note the flat nasal bridge, depressed nasal tip, sparse hair (scalp, eyebrows, eyelashes), peg-shaped teeth, full lips, and sebaceous hyperplasia. Also note the normal secondary hair in adults. *A, Courtesy, Julie V. Schaffer, MD; B, D, Courtesy, Mary Williams, MD; C, Courtesy, YDRSC.*

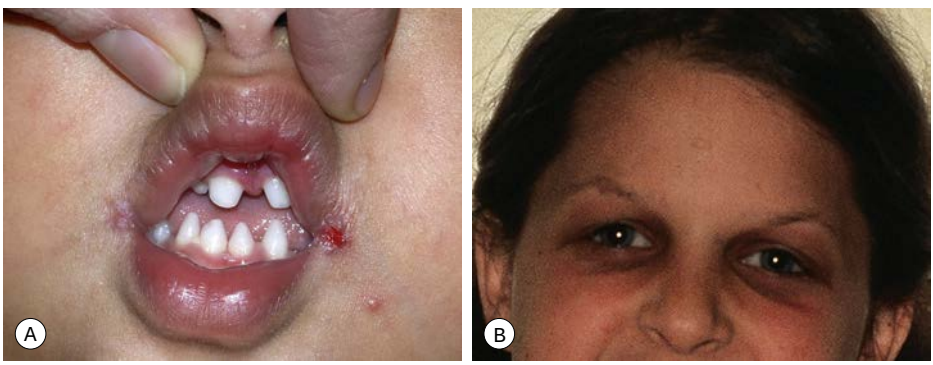


**Fig. 52.9 Female patients with X-linked hypohidrotic ectodermal dysplasia. A** Full lips, peg-shaped teeth, and hypodontia. **B** Periorbital hyperpigmentation. *A, Courtesy, Julie V. Schaffer, MD. Continued*




**Fig. 52.9** *Continued* **Female patients with X-linked hypohidrotic ectodermal dysplasia.** **C** Sebaceous hyperplasia.



**Fig. 52.10 Hidrotic ectodermal dysplasia (Clouston syndrome).** Note the thickened, shortened nails with distal separation and the tiny papules in a regular distribution on the dorsal fingertips. *Courtesy, Virginia Sybert, MD, and Alanna Bree, MD.*




**Fig. 52.11 Ankyloblepharon–ectodermal dysplasia–clefting syndrome.** **A** Extensive erosions in an infant who succumbed to sepsis. **B** Chronic erosive scalp dermatitis with thick scale-crust and alopecia. **C** Strands of tissue between the eyelids (ankyloblepharon filiforme adnatum). **D** Digital abnormalities (including syndactyly) and nail dystrophy. *A, C, D, Courtesy, Virginia Sybert, MD, and Alanna Bree, MD; B, Courtesy, Julie V. Schaffer, MD.*



**eFig. 52.1 Congenital hypertrophy of the retinal pigment epithelium.** *Courtesy, L. Tychsen, MD.*

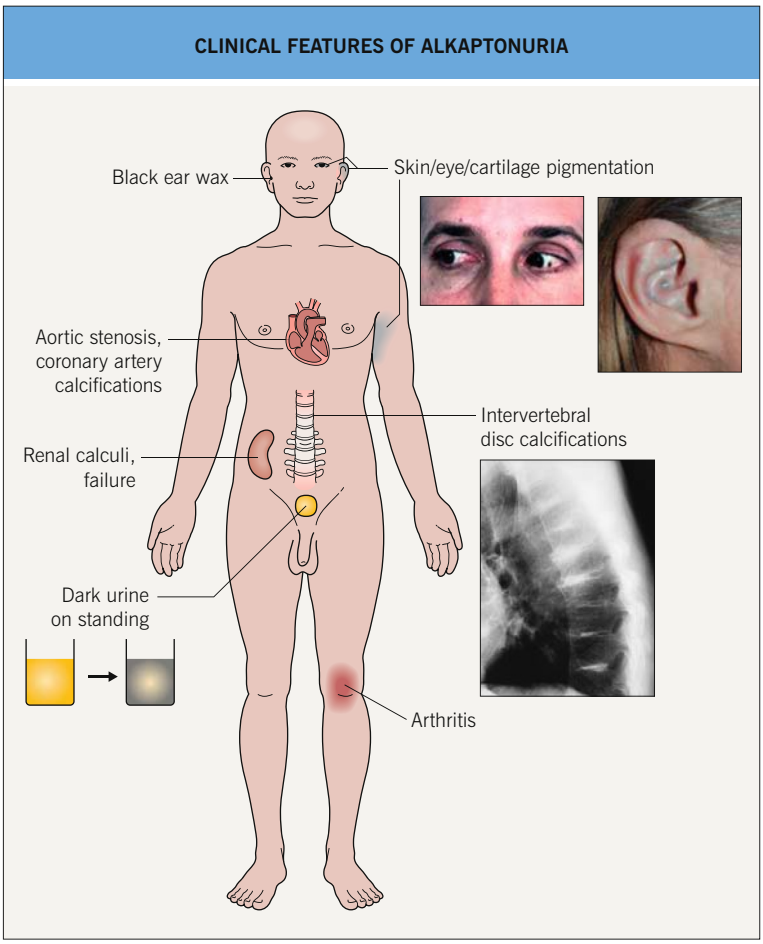


**eFig. 52.2 Clinical features of alkaptonuria.** *Eyes, courtesy, William Gohl, MD, PhD; ear, courtesy, Julie V. Schaffer, MD; radiograph, courtesy, Jean L. Bolognia, MD.*



A L G r a w a n y



**eFig. 52.3 Angiokeratomas of Fabry disease.** Multiple dark red to red-brown macules and papules on the lower trunk within a "bathing trunk" distribution. *Courtesy, Edward Cowen, MD.*

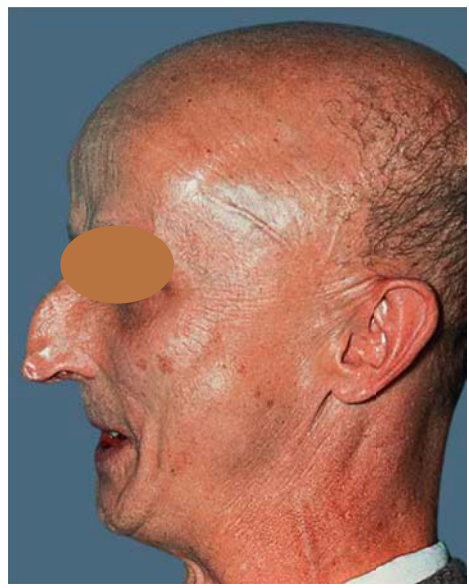

**eFig. 52.4 Werner syndrome.** Characteristic features include a beaked nose, tautness of the skin, prominent veins, and micrognathia. *Courtesy, Ronald P. Rapini, MD.*



**eFig. 52.5 Witkop tooth and nail syndrome.** Small primary teeth, some conical, in a 7-year-old boy. Radiographs showed an absence of nearly all of the secondary teeth. *Courtesy, Julie V. Schaffer, MD.*



**eFig. 52.6 Ankyloblepharon–ectodermal dysplasia–clefting syndrome.** Chronic erosive scalp dermatitis with thick scale-crust and alopecia. *Courtesy, Jean L. Bolognia, MD.*




**eFig. 52.7 Ectodermal dysplasia–ectrodactyly–clefting syndrome.** Note the characteristic split-hand (**A**) and split-foot (**B**) deformities in these three siblings.

| SCREENING RECOMMENDATIONS FOR PATIENTS WITH PTEN HAMARTOMA TUMOR SYNDROME |
|---|
| • Yearly comprehensive physical examination, including skin, thyroid and breast, beginning at 18 years of age (or 5 years before the youngest age of cancer diagnosis in the family); in women, twice-yearly breast examinations beginning at age 25 years in addition to monthly self-examinations<br>• Yearly thyroid ultrasound<br>• Colonoscopy beginning at age 35 years (or earlier if symptomatic or a family history of colon cancer before age 40 years); repeat at least every 5 years<br>• In women, annual mammogram and breast MRI beginning at age 30–35 years (or 5–10 years before the youngest breast cancer diagnosis in the patient's family)<br>• Consider: (1) Prophylactic mastectomies on an individual basis; (2) annual random endometrial biopsies and/or endometrial ultrasound beginning at age 30–35 years; and (3) renal ultrasound every 1–2 years beginning at age 40 years |

**eTable 52.1 Screening recommendations for patients with PTEN hamartoma tumor syndrome.**

| REVISED CLINICAL DIAGNOSTIC CRITERIA FOR PTEN HAMARTOMA TUMOR SYNDROME (2013) |
|---|
| **Major criteria** |
| Multiple mucocutaneous lesions (any of the following):<br>• Tricholemmomas (≥3, at least 1 biopsy-proven)<br>• Acral keratoses (≥3 papules or palmoplantar pits)<br>• Mucocutaneous neuromas (≥3)<br>• Oral papillomas, particularly on tongue & gingiva (≥3, biopsy-proven, or dermatologist-diagnosed)<br>Pigmented macules on the glans penis<br>Macrocephaly (>97$^{th}$ %ile; 58 cm in adult women, 60 cm in adult men)<br>Lhermitte–Duclos disease (LDD; in an adult)<br>Breast cancer<br>Endometrial cancer (epithelial)<br>Thyroid cancer (follicular)<br>Gastrointestinal (GI) hamartomas, including ganglioneuromas, but not hyperplastic polyps (≥3) |
| **Minor criteria** |
| Vascular anomalies, including multiple intracranial developmental venous anomalies<br>Lipomas (≥3)<br>Testicular lipomatosis<br>Autism spectrum disorder<br>Intellectual disability (IQ ≤75)<br>Renal cell carcinoma<br>Colon cancer<br>Esophageal glycogenic acanthosis<br>Thyroid cancer (papillary or follicular variant of papillary)<br>Thyroid structural lesions (e.g. adenoma, multinodular goiter) |
| **Operational diagnosis in an individual:**<br>3 major criteria including macrocephaly, LDD, or GI hamartomas –or–<br>2 major criteria + 3 minor criteria<br>**Operational diagnosis when a family member meets diagnostic criteria or has a PTEN mutation:**<br>2 major criteria –or– 1 major + 2 minor criteria –or– 3 minor criteria |

**eTable 52.2 Revised clinical diagnostic criteria for PTEN hamartoma tumor syndrome (2013).**

| SURVEILLANCE GUIDELINES FOR PATIENTS WITH LYNCH SYNDROME, INCLUDING MUIR–TORRE SYNDROME | | |
|---|---|---|
| **Test** | **When to begin** | **Frequency** |
| Comprehensive physical examination, including the skin, and neurologic assessment | Age 20–25 years | Yearly |
| **Colonoscopy** | Age 20–25 years<br>If diagnosed in a family member before age 25 years, 2–5 years prior to the earliest colon cancer in the family | Every 1–2 years |
| Pelvic examination, endometrial biopsy, and transvaginal ultrasound* | Age 30–35 years* | Yearly |
| Esophagogastroduodenoscopy with biopsy of the gastric antrum and treatment of *H. pylori* infection when found | Age 30–35 years | Every 2–3 years, based on individual risk factors |
| Urinalysis ± cytological examination | Age 25–30 years | Yearly |

**Hysterectomy and bilateral salpingo-oophorectomy are recommended when childbearing is completed or at age 40 years.*

**eTable 52.3 Surveillance guidelines for patients with Lynch syndrome, including Muir–Torre syndrome.** Colonoscopy (in bold) is the only strong recommendation in these guidelines. Routine breast and prostate screening beyond that advised for the general population is not currently recommended. Based on the National Comprehensive Cancer Network guidelines (http://www.nccn.org/professionals/physician_gls/PDF/genetics_screening.pdf) and Giardiello FM, Allen JI, Axilbund JE, et al. Guidelines on genetic evaluation and management of Lynch syndrome: a consensus statement by the US Multi-Society Task Force on Colorectal Cancer. Dis Colon Rectum 2014;57:1025–48.

| NUCLEAR ENVELOPATHIES | |
|---|---|
| **Primary feature and associated diseases** | **Inheritance** |
| **Laminopathies – due to mutations in the *LMNA* gene which encodes the lamin A and C proteins of the nuclear membrane lamina*** | |
| ***Premature aging and/or cutaneous sclerosis*** | |
| Hutchinson–Gilford progeria syndrome (classic and atypical) | AD |
| Restrictive dermopathy† | AD > AR |
| "Atypical Werner syndrome" | AD |
| Other progeroid laminopathies | AD > AR |
| ***Skeletal dysplasia and/or arthropathy*** | |
| Mandibuloacral dysplasia† | AR |
| Arthropathy, tendinous calcinosis and progeroid features | AR |
| ***Lipodystrophy*** | |
| Dunnigan familial partial lipodystrophy | AD |
| Generalized lipodystrophy with pubertal onset‡ | AD |
| ***Muscular dystrophy*** | |
| Emery–Dreifuss muscular dystrophy | AD > AR |
| Limb-girdle muscular dystrophy type 1B | AD |
| Early-onset myopathy with progeroid features | AD |
| ***Cardiomyopathy*** | |
| Dilated cardiomyopathy type 1A | AD |
| "Heart–hand syndrome" | AD |
| ***Neuropathy*** | |
| Charcot–Marie–Tooth type 2B1 | AR |
| **Cutaneous disorders with inner nuclear membrane dysfunction – due to mutations in the *LEMD3* gene, whose protein product associates with lamin A** | |
| ***Cutaneous sclerosis and/or skeletal dysplasia*** | |
| Buschke–Ollendorff syndrome | AD |
| Osteopoikilosis | AD |
| Melorheostosis | Type 2 segmental§ |

**Heterozygous mutations in the LMNB2 gene, which encodes the lamin B2 protein of the nuclear membrane lamina, can cause "acquired" partial lipodystrophy (Barraquer–Simons syndrome).*
*†Can also result from recessive mutations in the ZMPSTE24 gene, which encodes a zinc metalloproteinase involved in the processing of prelamin A into mature lamin A; mandibuloacral dysplasia often presents with progeroid features and lipodystrophy.*
*‡Overlaps with atypical Werner syndrome; numerous whitish, fibrotic papules on a background of diffuse hyperpigmentation have been described in some patients.*
*§Germline heterozygous mutation (resulting in Buschke–Ollendorff syndrome or osteopoikilosis) with a presumed second hit in area of melorheostosis.*

**eTable 52.4 Nuclear envelopathies.** A heterogeneous group of genetic disorders that share the common findings of cutaneous fibrosis and bone dysplasia. AD, autosomal dominant; AR, autosomal recessive.

# Developmental Anomalies 53

Developmental anomalies are a diverse group of congenital disorders that result from faulty *in utero* morphogenesis. When they affect the skin, developmental anomalies can range in severity from isolated minor physical findings to potentially life-threatening conditions or cutaneous signs of significant extracutaneous defects.

## Midline Lesions of the Nose or Scalp

- A midline mass or pit on the nose or scalp due to a dermoid cyst, cephalocele, nasal glioma, or other heterotopic brain/meningeal tissue (Fig. 53.1) may have a deeper component with intracranial extension.
- These lesions are typically apparent at birth or during early childhood.
- *Hair collar sign*: a peripheral ring of long, dark hair often surrounds ectopic neural tissue or membranous aplasia cutis congenita (ACC) on the scalp (Figs 53.2 and 53.3); the latter is thought to represent a forme fruste of a neural tube defect.
- **DDx:** outlined in Table 53.1 for nasal masses; epidermoid cysts, tricholemmal cysts, and granuloma annulare for scalp lesions (especially in older children).
- **Rx:** avoid biopsy or aspiration, which could lead to a CNS infection (e.g. meningitis); MRI and/or CT is required to assess extent prior to surgical intervention, which should include exploration to exclude intracranial extension and repair of any bony/dural defects.

## Dermoid Cysts

- Result from sequestration of ectodermal tissue along embryonic fusion planes.
- Recognized at birth or when they enlarge or become inflamed during infancy or childhood.
- Firm, noncompressible, skin-colored to pink subcutaneous nodules that often reach a size of 1–4 cm in diameter; some have a sinus ostium, which may be heralded by protruding hairs.
- Most often located around the eyes, especially the lateral eyebrow region (Fig. 53.4); midline lesions on the nose, scalp, or back may have intracranial extension.
- **Rx:** surgical excision, following imaging if midline.

## Cephaloceles

- Neural tube defect characterized by congenital herniation of brain + meninges (*encephalocele*) or meninges (*cranial meningocele*) through a skull defect (see Fig. 53.3).
- Midline or paramedian location at the occiput or vertex > nasal region.
- Soft, compressible, pulsatile mass, often with a bluish color; covered with normal skin or a glistening membrane.
- Clues to the diagnosis include transillumination and transient expansion with crying or the Valsalva maneuver; nasal lesions may present with cerebrospinal fluid (CSF) rhinorrhea or a broad nasal bridge.
- **Rx:** MRI followed by neurosurgical repair.

## Nasal Gliomas, Other Heterotopic Brain Tissue, and Rudimentary Meningoceles

- A *nasal glioma* is a congenital mass of heterotopic brain tissue (HBT) at the nasal root/glabella > intranasally; the skin overlying this firm, noncompressible nodule tends to be red with prominent telangiectasias (mimicking an infantile hemangioma) (Fig. 53.5).

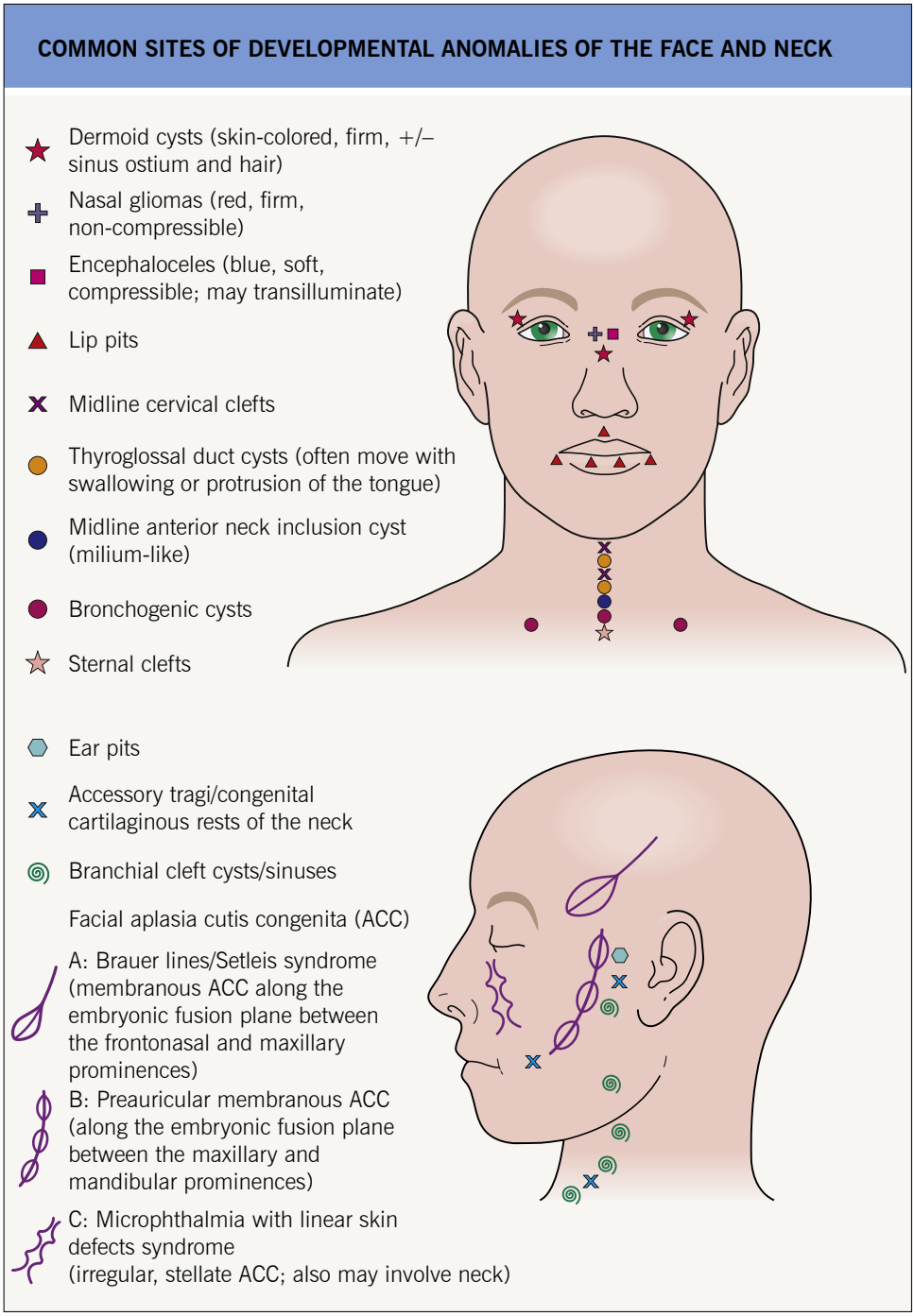


**Fig. 53.1 Common sites of developmental anomalies of the face and neck.** *Courtesy, Julie V. Schaffer, MD.*

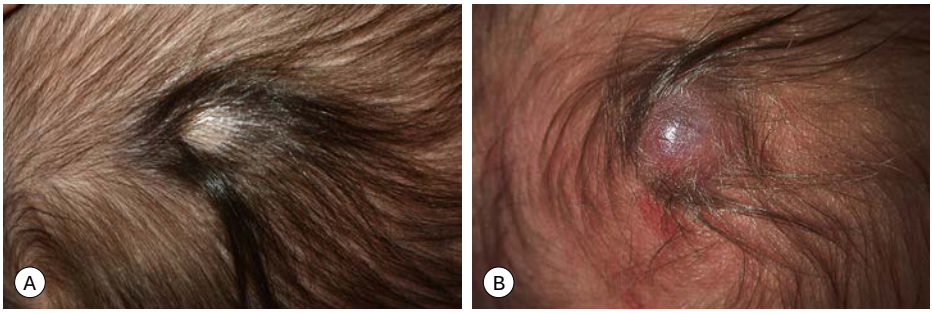


**Fig. 53.2 Membranous aplasia cutis congenita.** Note the hair collar sign **(A, B)** and the bullous appearance **(B)**. *A, Courtesy, Julie V. Schaffer, MD; B, Courtesy, YDRSC.*

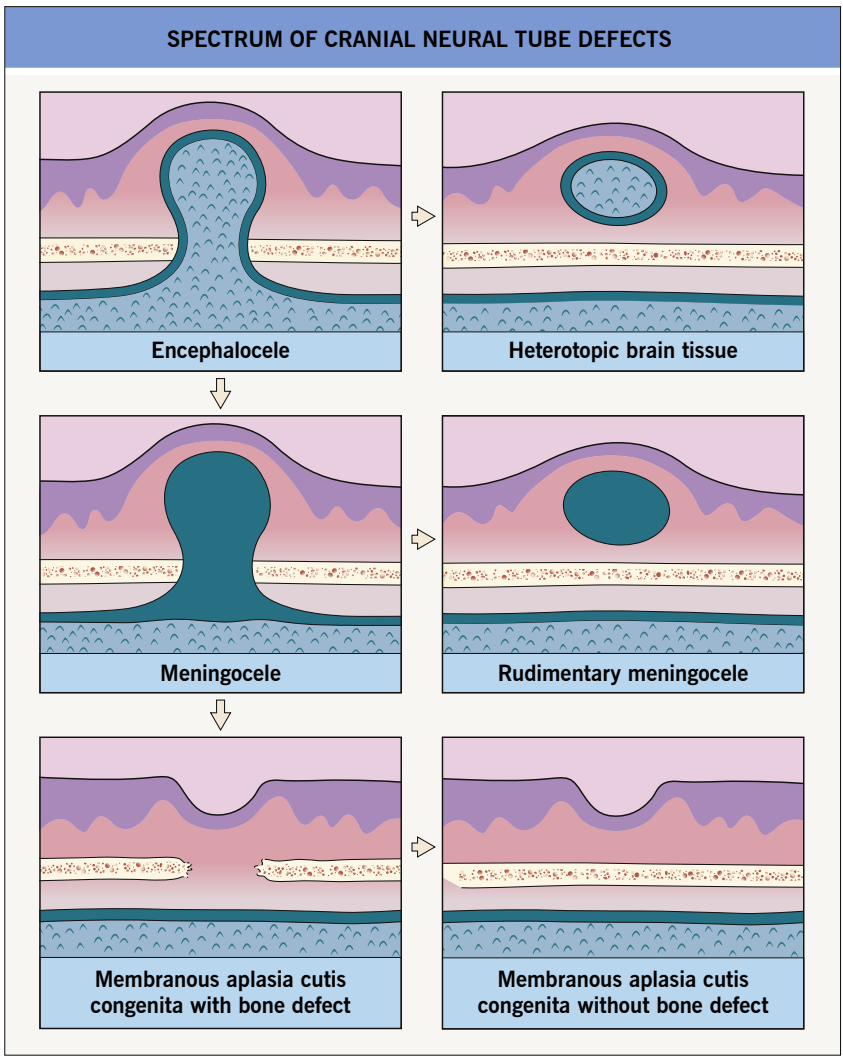


**Fig. 53.3 Spectrum of cranial neural tube defects.**

| DIFFERENTIAL DIAGNOSIS OF NASAL MASSES PRESENTING AT BIRTH OR DURING INFANCY |
|---|
| **Cysts and developmental defects** |
| **Midline lesions (see Fig. 53.1)** |
| • Dermoid cyst, nasal glioma, cephalocele |
| **Other lesions** |
| • Vascular malformation (e.g. lymphatic, venous; see Ch. 85)<br>• Epidermoid cyst (see Ch. 90), pilomatricoma (see Ch. 91), nasolacrimal duct cyst |
| **Benign neoplasms and hamartomas** |
| • Infantile hemangioma (see Ch. 85), neurofibroma (see Ch. 95)<br>• Hamartomas (e.g. chondromesenchymal, lipomatous), teratoma* |
| **Malignant neoplasms** |
| • Rhabdomyosarcoma > fibrosarcoma, neuroblastoma |
| **May also be malignant.* |

**Table 53.1 Differential diagnosis of nasal masses presenting at birth or during infancy.**



**Fig. 53.4 Dermoid cyst.** This dermoid cyst presented in an infant as a firm subcutaneous nodule superior to the right lateral eyebrow. *Courtesy, Julie V. Schaffer, MD.*



**Fig. 53.5 Nasal glioma.** A mass was noted on prenatal ultrasound, and this reddish, slightly pedunculated, rubbery nodule was evident at birth. *Courtesy, Mary Chang, MD.*

- Other HBT and rudimentary meningoceles typically present as a solid or cystic subcutaneous nodule on the midline scalp, often with a blue-red hue, overlying alopecia and a surrounding hair collar (see above); a rudimentary meningocele may have a bullous appearance and can also be located over the spine.
- May have a vestigial fibrous stalk extending into the intracranial space, but lack a connection with the intracranial leptomeninges or CSF (see Fig. 53.3).
- **Rx:** MRI followed by surgical excision.

## Midline Cervical, Sternal, and Supraumbilical Clefts

- A *midline cervical cleft* is a vertical band of atrophic skin on the mid anterior neck, often with a sinus tract inferiorly and a protuberance overlying a fibrous cord superiorly; surgical correction is needed to prevent neck contracture.
- A *sternal cleft* or *supraumbilical raphe* presents with a band of atrophic (Fig. 53.6), scarred or ulcerated skin; may occur in the setting of PHACE(S) syndrome (*p*osterior fossa malformations; *h*emangiomas; *a*rterial, *c*ardiac, and *e*ye anomalies; *s*ternal cleft/supraumbilical raphe; see Ch. 85).

## Midline Lesions Overlying the Spine

- Midline cutaneous lesions serve as a valuable marker for "occult" spinal dysraphism

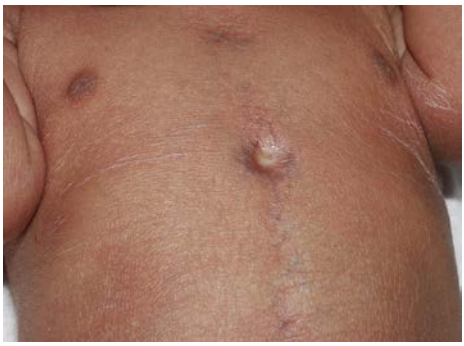

**Fig. 53.6 Sternal cleft.** Note the atrophic skin overlying the defect and prominent veins in the midline chest. Generalized desquamation is also evident in this 1-day-old post-term neonate. She did not develop an infantile hemangioma and had no cardiac defects or other features of PHACE(S) syndrome. *Courtesy, Julie V. Schaffer, MD.*

and are present in ~80% of affected individuals (most of whom have >1 type of skin lesion), compared to <3% of the general population; shallow coccygeal dimples and deep gluteal clefts, which are considered as normal variants, occur in an additional 4% of infants.

- Skin lesions associated with spinal dysraphism are presented in Table 53.2 and Fig. 53.7.
- **Rx:** Fig. 53.8 outlines an approach to patients with skin signs of spinal dysraphism.

## Aplasia Cutis Congenita (Congenital Absence of Skin)

- ACC is a physical finding: areas of skin (localized or widespread) that are absent or scarred at birth.
- Possible causes of ACC include genetic factors, vascular compromise, trauma, teratogens, and intrauterine infections.
- The morphology and distribution of the skin defects (Figs 53.9 and 53.10) and the presence or absence of associated abnormalities represent clues to the etiology of ACC (Table 53.3).
- The most common form is *membranous ACC*, which favors the scalp (especially the vertex) and presents as a sharply marginated, round to oval defect that is covered by a thin translucent membrane and often surrounded by a hair collar (see Fig. 53.2 and above); may have a bullous appearance in neonates, evolving into an atrophic scar.
- An autosomal dominant form of scalp ACC presents with hypertrophic scarring. Another ACC morphology is stellate or angulated ulcerations, which may result from vascular abnormalities and/or intrauterine ischemic events (see Table 53.3).
- **DDx:** obstetric trauma, rudimentary meningocele (especially if bullous).
- Imaging is recommended for irregular and membranous lesions on the scalp, in particular those that are large and/or deep, to assess for underlying skull defects and vascular anomalies.
- **Rx:** topical antibiotic ointment until re-epithelialization occurs; early surgical repair of large, deep stellate scalp lesions to prevent life-threatening hemorrhage, thrombosis, or meningitis.

## Congenital Lip and Ear Pits

- *Commissural lip pits*: most common form of lip pits (1–2% of newborns), found bilaterally at angles of mouth (Fig. 53.11A); usually isolated, occasionally associated with branchio-otic syndrome (preauricular pits, deafness).
- *Lower lip pits*: typically bilateral at apex of conical elevation (Fig. 53.11C); isolated > associated with Van der Woude (cleft lip/palate, hypodontia) or popliteal pterygium syndrome.
- *Upper lip pits*: along philtrum or paramedian (Fig. 53.11B); isolated > associated findings (e.g. hypertelorism) or branchio-oculo-facial syndrome (see below).
- *Ear pits*: affect 0.5–1% of newborns, presenting as an invagination (Fig. 53.11D) > cystic nodule in the upper preauricular area (unilateral > bilateral); usually isolated (± autosomal dominant inheritance), occasionally associated with hearing impairment or malformation syndromes (e.g. branchio-oto-(±)renal syndrome, hemifacial microsomia).

## Accessory Tragi (Preauricular Tags)

- Congenital anomalies of the first branchial arch that are found in ~5 per 1000 newborns.
- Soft or firm (due to a cartilaginous core) skin-colored papules or nodules covered by vellus hairs.

| SKIN LESIONS OF THE SPINAL AXIS ASSOCIATED WITH DYSRAPHISM | |
|---|---|
| **Lesion** | **Features** |
| Hypertrichosis | A V-shaped patch of long, coarse or silky hair (see Fig. 53.7B,C); "faun tail" |
| Lipomas | Soft subcutaneous mass, asymmetric buttocks, curved gluteal cleft (see Fig. 53.7A); most common sign of spinal dysraphism |
| Dimples | Above the gluteal cleft or >2.5 cm from the anal verge in neonates (see Fig. 53.7A,D); >0.5 cm in size or deep* |
| Dermal sinuses | Hair may be present at the ostium* |
| Acrochordons | May be associated with a dimple or dermal sinus |
| Pseudotails | Caudal protrusion due to prolonged vertebrae or hamartomatous elements, e.g. adipose tissue or cartilage (see Fig. 53.7A,D) |
| True tails | Persistent vestigial appendage with a central core of mature adipose tissue, muscle, blood vessels, and nerves<br>May be capable of spontaneous or reflex motion |
| Infantile hemangiomas | Usually superficial with a segmental pattern (see Fig. 53.7D) and often ulcerated; represents a component of LUMBAR syndrome |
| Telangiectasias | May represent an early, minimal/arrested growth or regressed infantile hemangioma |
| Vascular malformations** | Capillary malformations are typically found together with other skin lesions<br>Cobb syndrome: spinal arteriovenous malformation associated with segmental skin lesions mimicking a CM or angiokeratomas |
| Aplasia cutis congenita (ACC) | Ulcer, scar, or atrophic skin |
| Connective tissue nevus | Typically found together with other skin lesions |
| Hypo/depigmentation | May represent a nevus depigmentosus (typically found together with other skin lesions) or the residua of ACC |
| Hyperpigmentation | Typically found together with other skin lesions |
| Congenital melanocytic nevi | Spinal dysraphism has been reported in patients with neurocutaneous melanosis |
| Subcutaneous masses | May represent (lipomyelo)meningoceles or teratomas |

**Due to a potential risk of meningitis, these lesions should not be probed.*
***The common occipital nevus simplex ("stork bite") and lumbosacral capillary stains in the setting of additional nevus simplex lesions on the head/neck (but no other lumbosacral skin lesions) are generally not considered to be signs of spinal dysraphism.*

**Table 53.2 Skin lesions of the spinal axis associated with dysraphism.** The presence of two or more types of lesions increases the risk of a spinal anomaly. LUMBAR, lumbosacral hemangiomas and lipomas, urogenital anomalies and ulceration, myelopathy, bony deformities, anorectal and arterial malformations, renal anomalies.

- Located in preauricular area > mandibular cheek or anterolateral neck (*congenital cartilaginous rests of the neck* or *"wattles"*) (Fig. 53.12).
- Usually an isolated finding; occasionally associated with hearing impairment or malformation syndromes (e.g. hemifacial microsomia).
- **Rx:** assessment of hearing; excision, with care to remove any cartilaginous component.

## Branchial Cleft Cysts, Sinuses, and Fistulae

- Located on the neck along the anterior border of the sternocleidomastoid muscle or in the mandibular or preauricular region (see Fig. 53.1).
- *Branchial cleft cysts* lack a primary cutaneous opening and typically present in older children and adults when they become infected or inflamed.




**Fig. 53.7 Skin findings associated with spinal dysraphism. A** Midline deep sacral dimple located above the gluteal cleft in association with a small pseudotail. In contrast, a shallow dimple within the gluteal cleft is a common finding and not a sign of spinal dysraphism. **B** Circumscribed midline hypertrichosis overlying the lower thoracic spine in a patient with occult dysraphism. The patient periodically clips the distal ends. **C** V-shaped patch of long, coarse hair on the mid back in a boy born with a large thoracic myelomeningocele. Severe scoliosis remains after multiple surgeries. **D** This infant with segmental infantile hemangiomas, a dimple, a pseudotail, and a deviated gluteal cleft had an underlying lipomyelomeningocele. *A, Courtesy, Seth Orlow, MD; B, Courtesy, Jean L. Bolognia, MD; C, Courtesy, Julie V. Schaffer, MD; D, Courtesy, Richard Antaya, MD.*

• *Branchial cleft sinuses/fistulae* usually have a sinus ostium with mucus discharge that is evident at birth or during the first few years of life.

• Usually an isolated anomaly, but occasionally associated with branchio-oto-(±) renal and branchio-oculo-facial (with eroded/"hemangiomatous" overlying skin) syndromes.

• **Rx:** surgical excision after delineation of extent with MRI or fistulography (via CT or intraoperatively).

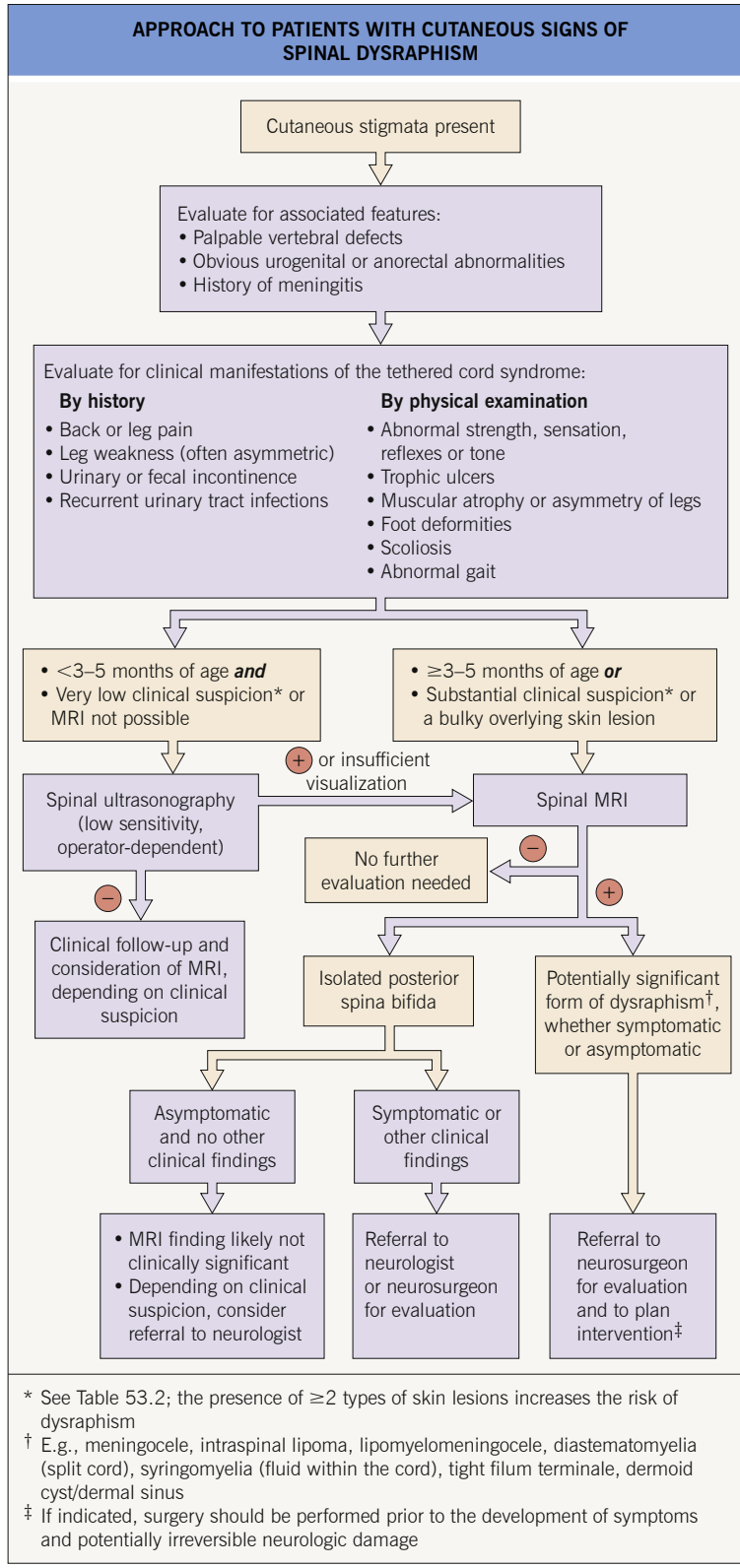


**Fig. 53.8 Approach to patients with cutaneous signs of spinal dysraphism.**
*Courtesy, Julie V. Schaffer, MD.*

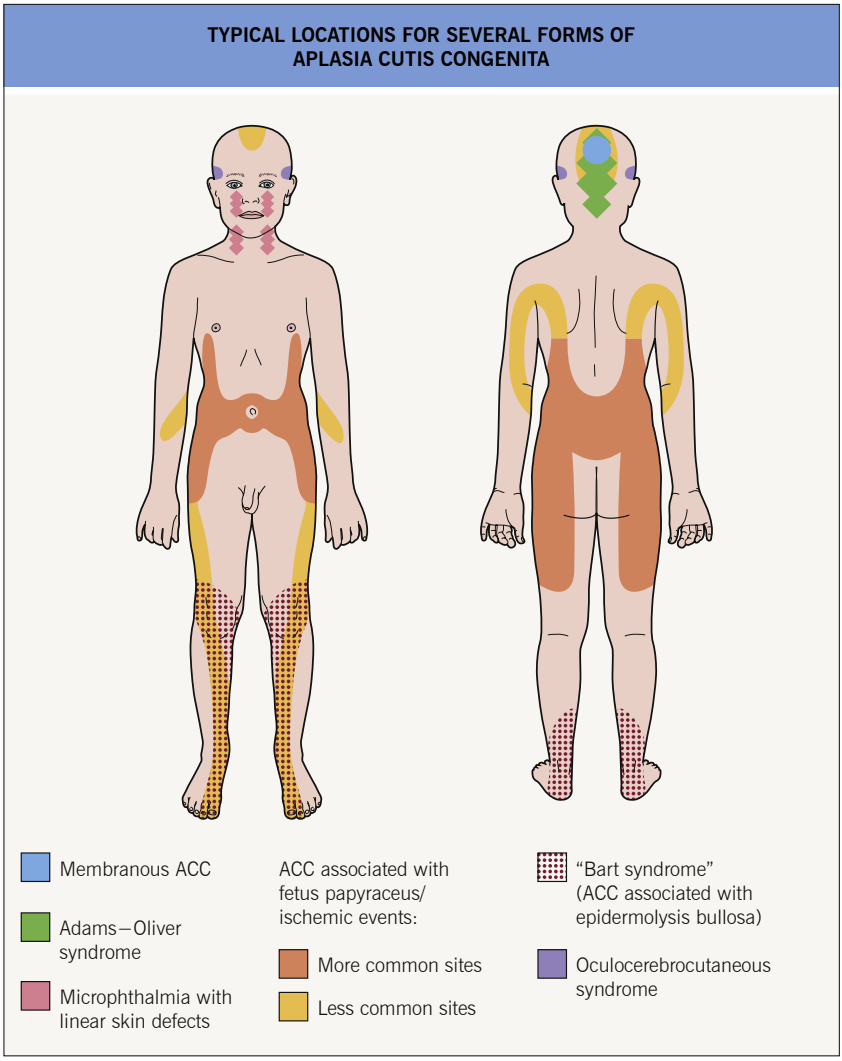


**Fig. 53.9 Typical locations for several forms of aplasia cutis congenita (ACC).** See Fig. 53.1 for Brauer lines/Setleis syndrome and preauricular membranous ACC. *Courtesy, Julie V. Schaffer, MD.*

## Thyroglossal Duct Cysts and Bronchogenic Cysts (See Fig. 53.1)

- *Thyroglossal duct cysts* present in children and young adults as a nodule on the mid anterior neck that moves with swallowing.
- *Cutaneous bronchogenic cysts* typically appear as a congenital papule or nodule, most often in the suprasternal notch or surrounding areas; mucus discharge is sometimes noted.
- **Rx:** surgical excision.

## Omphalomesenteric Duct Cysts and Urachal Cysts

- Defective closure of the omphalomesenteric duct, the embryonic connection between the midgut and yolk sac, can result in an umbilical-enteric fistula, umbilical sinus or *omphalomesenteric duct cyst*, which typically presents as an umbilical polyp (Fig. 53.13).
- A patent urachus, which connects the fetal bladder to the umbilicus, results in leakage of urine from the umbilicus; in contrast, a *urachal*

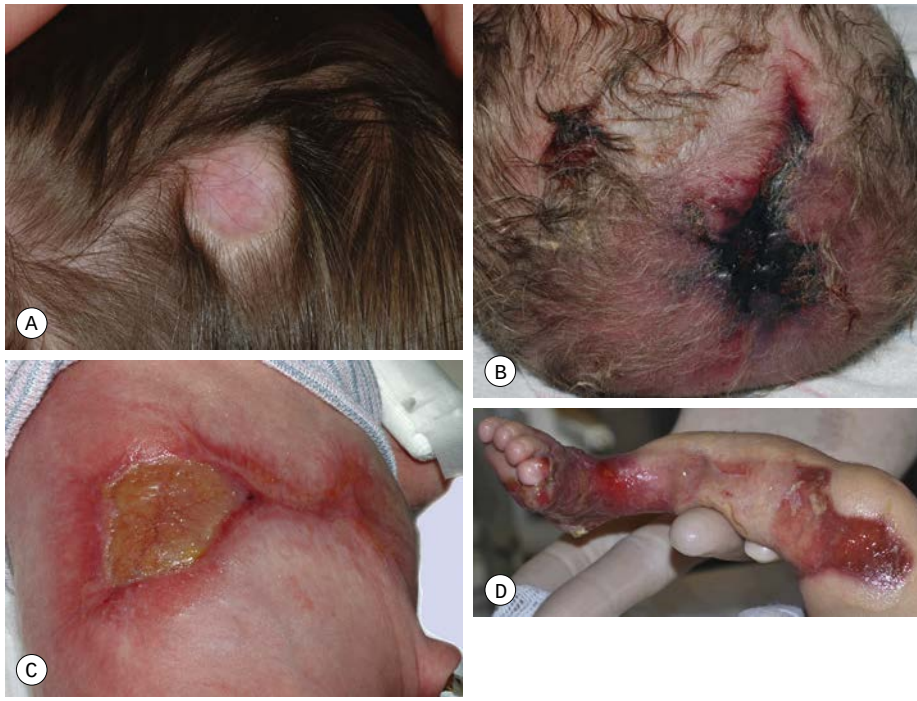


**Fig. 53.10 Aplasia cutis congenita (ACC).** **A** This hairless, round, scarred plaque on the scalp of a 6-month-old was present at birth. **B** Stellate ACC on the midline scalp of a neonate with mosaic trisomy 13. This hemorrhagic lesion was associated with an underlying skull defect and cerebrovascular anomalies. **C** Stellate ACC on the lateral trunk of a neonate born of an initial sextuplet gestation for which fetal reduction was performed. The lesions had a bilateral, symmetric distribution. **D** ACC on the leg in a neonate with epidermolysis bullosa. *A, Courtesy, Anthony J. Mancini, MD; B, C, Courtesy, Julie V. Schaffer, MD; D, Courtesy, Emily Berger MD.*

**CLASSIFICATION SCHEME FOR APLASIA CUTIS CONGENITA (ACC)**

| Group | Inheritance | Location, features, and associated abnormalities |
|---|---|---|
| 1. Isolated scalp ACC (see Figs 53.2 and 53.10A) | Sporadic > AD | • Favors vertex: membranous with hair collar |
| | Often AD | • Favors vertex: irregular hypertrophic scars |
| 2. Scalp ACC associated with Adams–Oliver syndrome (limb reductions, CMTC) | AD > AR | • Large, irregular lesions on midline scalp<br>• Frequent skull defect and dilated scalp veins |
| 3. Scalp ACC associated with epidermal, sebaceous, and/or large congenital melanocytic nevi | Sporadic | • Scalp, often unilateral and membranous<br>• ± Ipsilateral ophthalmologic or CNS abnormalities |
| 4. ACC overlying embryologic malformations | Variable | • Scalp with hair collar (heterotopic brain/meningeal tissue)<br>• Lumbosacral (spinal dysraphism)<br>• Anterior trunk (sternal defect, omphalocele) |
| 5. ACC associated with fetus papyraceus* (see Fig. 53.10C), placental infarct, or other ischemic events | Sporadic | • Scalp, chest, flanks, axillae, extremities<br>• Multiple, symmetric<br>• Stellate/angulated morphology |



**Table 53.3 Classification scheme for aplasia cutis congenita (ACC).** *Continued*

| CLASSIFICATION SCHEME FOR APLASIA CUTIS CONGENITA (ACC) | | |
|---|---|---|
| **Group** | **Inheritance** | **Location, features, and associated abnormalities** |
| 6. ACC associated with epidermolysis bullosa (simplex, junctional, or dystrophic; see Ch. 26 and Fig. 53.10D) | AD or AR | • Lower extremities ("Bart syndrome") or widespread |
| 7. ACC localized to extremities without blistering | Variable | • Pretibial areas, extensor forearms (± radial dysplasia), dorsal hands/feet |
| 8. ACC caused by teratogens (e.g. methimazole), maternal conditions (e.g. antiphospholipid syndrome), or intrauterine infections (e.g. varicella, HSV) | Not inherited | • Scalp with drugs<br>• Any site with congenital infections |
| 9. ACC associated with malformation syndromes | Variable | • Favors scalp, e.g. in trisomy 13 (see Fig. 53.10B), 4p- syndrome, and Goltz syndrome |

**Due to second trimester death of a co-twin/triplet.*

**Table 53.3** *Continued* **Classification scheme for aplasia cutis congenita (ACC).** CMTC, cutis marmorata telangiectatica congenita.

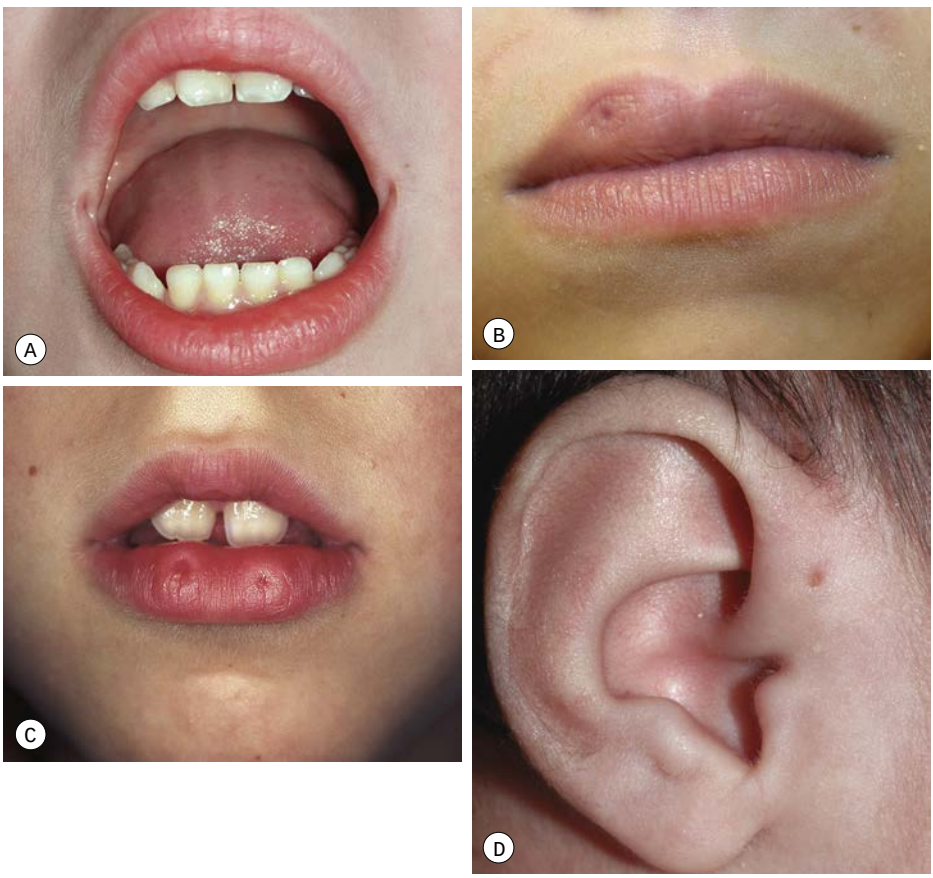


**Fig. 53.11 Lip and ear pits. A** Bilateral commissural lip pits. **B** Unilateral right-sided upper lip pit. **C** Bilateral paramedian lower lip pits, each located on the apex of a conical elevation. **D** Ear pit. In all of these patients, the pits represented an isolated finding. *A, B, Courtesy, Richard Antaya, MD; C, Courtesy, NYUDSC; D, Courtesy, Julie V. Schaffer, MD.*

*cyst* typically presents with an umbilical mass, often in the setting of a secondary infection.
- **DDx:** umbilical granuloma (persistent granulation tissue after cord separation).
- **Rx:** excision after radiographic studies to determine extent.

## Rudimentary Supernumerary Digits (Rudimentary Polydactyly)

- Found in 0.5–1:1000 white newborns and 5–10:1000 black newborns.
- Soft-tissue duplications without a skeletal component, usually arising from the ulnar side of the fifth finger (postaxial location) (Fig. 53.14).
- Range from small, fleshy or wart-like papules to pedunculated nodules that may contain cartilage or a vestigial nail; frequently bilateral.
- Typically an isolated finding, often with an autosomal dominant inheritance pattern.
- **Rx:** surgical excision; removal via ligation with suture material increases risk of infection and often leaves a residual papule that becomes a painful neuroma.

## Supernumerary Nipples and Other Accessory Mammary Tissue

- Present in 2–5% of the population, representing remnants of the embryonic "milk lines" (Fig. 53.15A).
- Equally prevalent in men and women, but often become more prominent at puberty or during pregnancy in female patients.
- Found on the inframammary chest > axilla, vulva, or upper medial thigh.
- Small, soft, pink or brown papules, with or without a surrounding areola (Fig. 53.15B, C); ectopic glandular breast tissue is occasionally present (± a nipple/areola), especially in the axilla or vulva.
- Usually an isolated finding; controversial potential association with malformations of the kidneys or urinary tract, and occasionally seen together with a Becker's nevus or malformation syndrome.
- **Rx:** excision if symptomatic or cosmetically undesirable; accessory mammary tissue can develop the same disorders as normal breasts and requires periodic breast cancer screening.

## Amniotic Band Sequence and Disorganization Syndrome

- Various congenital anomalies of the limbs, head, body wall, and viscera with asymmetric, seemingly haphazard distribution patterns.
- Characterized by fibrous bands that form constriction rings and lead to amputations of limbs/digits.
- Extrinsic (entanglement in torn amnion) and intrinsic (endogenous "disorganization syndrome") hypotheses for its pathogenesis; latter is favored by the presence of duplicated structures and internal malformations.
- **Rx:** surgical release of constriction bands.

For further information see Ch. 64 from *Dermatology, Fourth Edition*.

**For additional online figures visit www.expertconsult.com**

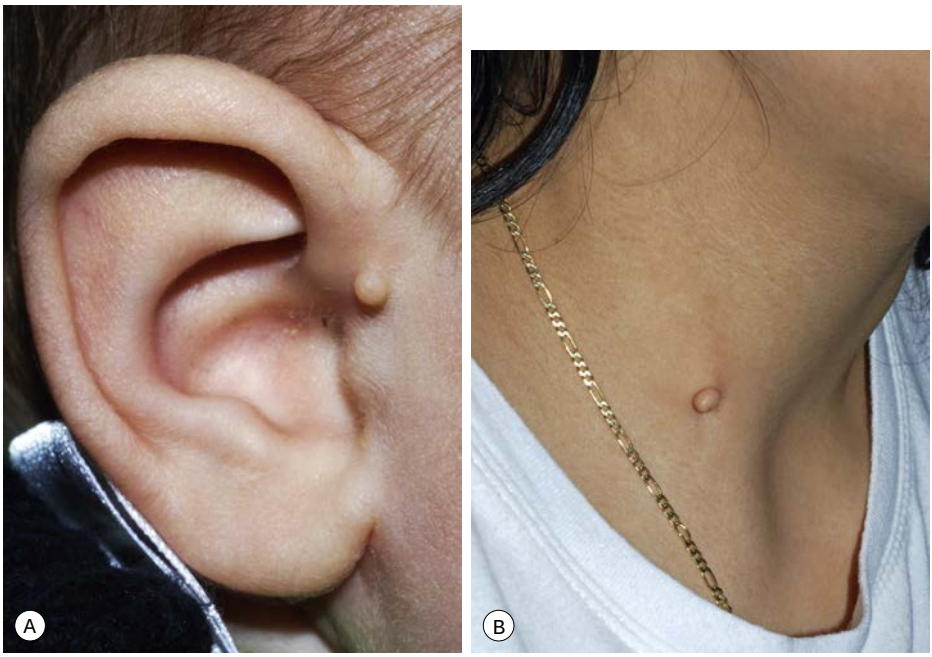


**Fig. 53.12 Accessory tragi. A** Typical small preauricular papule. **B** Congenital cartilaginous rest on the neck, which is considered to represent a cervical subtype of accessory tragus. *Courtesy, Julie V. Schaffer, MD.*



**Fig. 53.13 Omphalomesenteric duct cyst.** The pink papule in the umbilicus of this infant showed gastrointestinal epithelium histologically. *Courtesy, Mary S. Stone, MD.*



**Fig. 53.14 Bilateral rudimentary supernumerary digits.** The ulnar side of the fifth digit is the most common location (referred to as postaxial). *Courtesy, YDRSC.*

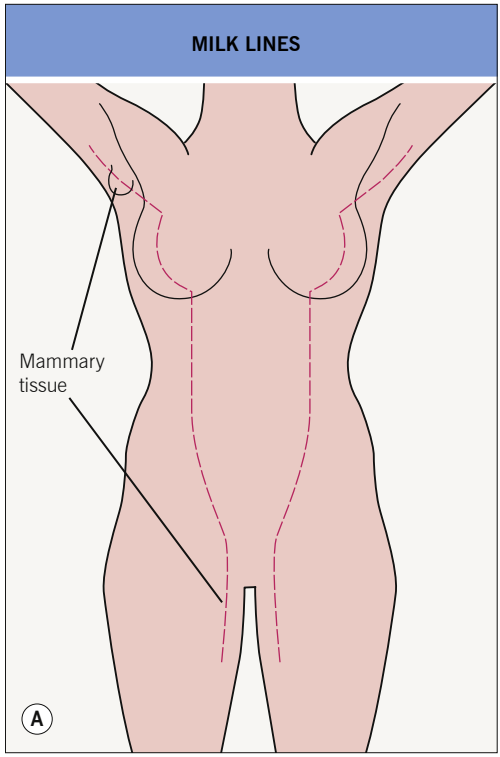


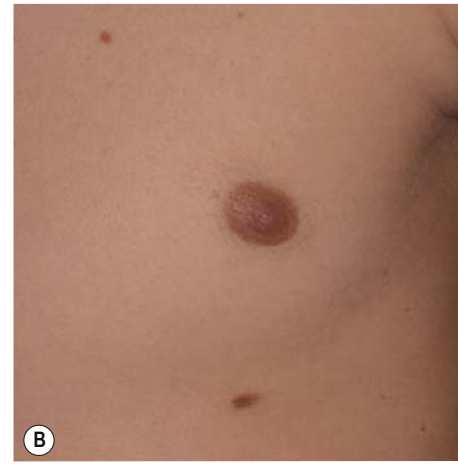





**Fig. 53.15 Supernumerary nipples. A** Supernumerary nipples and other forms of accessory mammary tissue represent focal remnants of the embryologic mammary ridges ("milk lines") that extend from the anterior axillary fold to the upper medial thigh bilaterally. **B** Brown papule that might be mistaken for a melanocytic nevus. **C** Nipple with a surrounding areola. *A, B, Courtesy, Julie V. Schaffer, MD; C, Courtesy, Jean L. Bolognia, MD.*

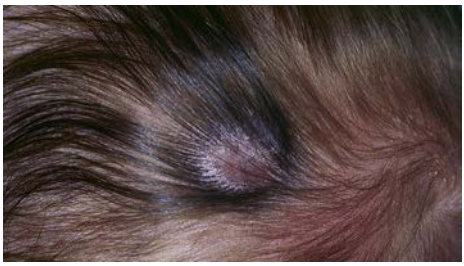

**eFig. 53.1 Hair collar sign.** Membranous aplasia cutis congenita with a hair collar and an associated capillary malformation. *Courtesy, Kalman Watsky, MD.*



**eFig. 53.2 Membranous aplasia cutis congenita.** This was associated with a large defect of the underlying skull in a patient with Goltz syndrome. *Courtesy, Julie V. Schaffer, MD.*

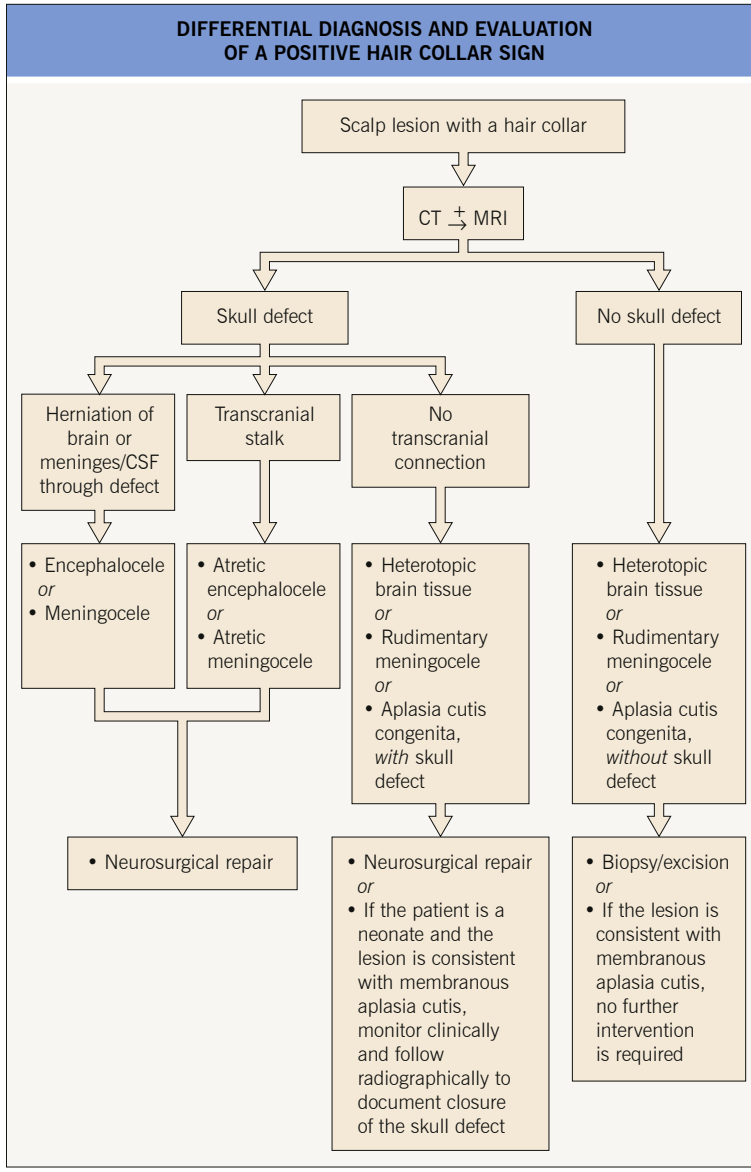


**eFig. 53.3 Differential diagnosis and evaluation of a positive hair collar sign.** In general, CT is the most accurate method of detecting skull defects. However, if a bony defect is detected by CT, a follow-up evaluation by MRI may be indicated to better determine whether there is extension of soft tissue transcranially.



**eFig. 53.4 Sinus pericranii.** This venous malformation involving the midline forehead and communicating with an intracranial dermal sinus was evident at birth. Fluctuations in fullness occurred with crying. *Courtesy, Susan Psaila, MD.*



**eFig. 53.5 Dermoid cyst on the scalp.**
*Courtesy, Julie V. Schaffer, MD.*



**eFig. 53.6 Facial aplasia cutis congenita.** Atrophic cutaneous defect extending from the lateral eyebrow to the anterior hairline in a patient with Setleis syndrome. Note the upward-slanting eyebrows and "leonine" facial appearance.
*Courtesy, Seth Orlow, MD, PhD.*

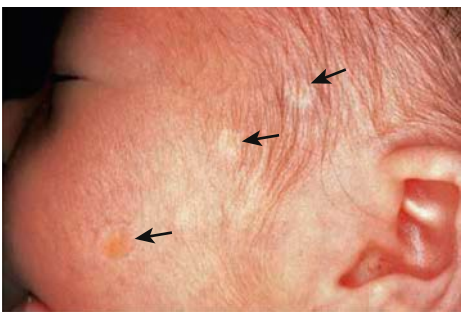

**eFig. 53.7 Preauricular skin defects.** Multiple discrete, round, atrophic skin defects in an infant, extending from the hairline toward the angle of the mouth in a linear arrangement (arrows).
*Courtesy, Jean L. Bolognia, MD.*

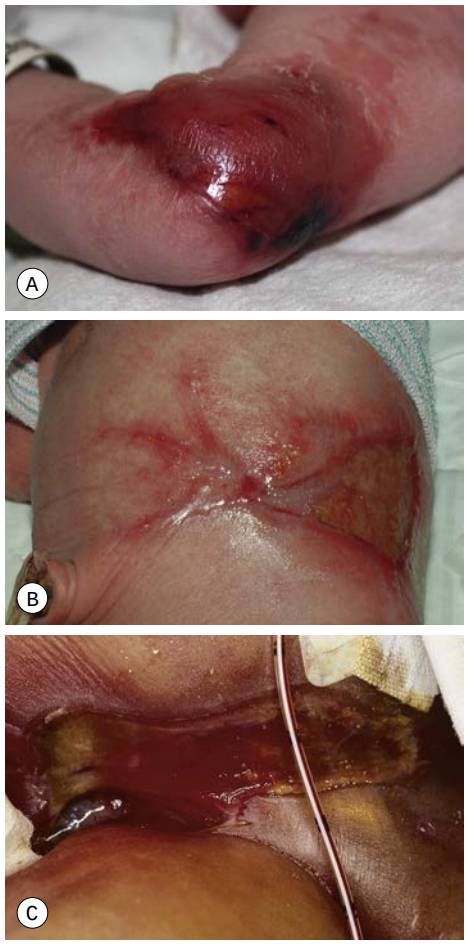


**eFig. 53.8 Aplasia cutis congenita (ACC).** **A** ACC associated with fetus papyraceus due to the second-trimester death of a co-twin. **B** Stellate ACC on the lateral trunk of a neonate born of an initial sextuplet gestation for which fetal reduction was performed. The lesions had a bilateral, symmetric distribution. **C** ACC resulting from congenital varicella. Note the sharply demarcated, deep ulcer on the lower abdominal wall. *A, Courtesy, Richard Antaya, MD; B, Courtesy, Julie V. Schaffer, MD; C, Courtesy, YDRSC.*



**eFig. 53.9 Accessory tragi.** Multiple skin-colored papulonodules on the mandibular cheek as well as in a preauricular location. *Courtesy, YDRSC.*



**eFig. 53.10 Supernumerary nipple with surrounding areola.** *Courtesy, Julie V. Schaffer, MD.*

# Vitiligo and Other Disorders of Hypopigmentation

# 54

## Introduction/Definitions

- **Leukoderma** and **hypopigmentation**: areas of skin are lighter in color than uninvolved skin, due primarily to a decrease in melanin; decreased blood supply to the skin (e.g. nevus anemicus) can be another cause of leukoderma.
- **Hypomelanosis**: an absence or reduction of melanin in the skin that may be due to any one or a combination of the following:
  1. A decrease in the number of melanocytes (e.g. vitiligo).
  2. A decrease in melanin synthesis by a normal number of melanocytes (e.g. albinism).
  3. A decrease in the transfer of melanin to keratinocytes (e.g. postinflammatory hypopigmentation).
- **Amelanosis**: total absence of melanin in the skin.
- **Depigmentation**: usually implies a total loss of skin color (e.g. as in vitiligo).
- **Pigmentary dilution**: a generalized lightening of the skin, hair, and eyes (e.g. oculocutaneous albinism); sites of melanin production include the epidermis, hair follicles, pigmented retinal epithelium, and uveal tract.
- **Poliosis**: a lock of scalp hair, eyebrows, or eyelashes that is white in color.
- **Canities**: generalized depigmentation of scalp hair.
- **Wood's lamp examination**: the greater the loss of epidermal pigmentation, the more marked the contrast with uninvolved skin on Wood's lamp examination (see Table 2.1 and Fig. 61.10B).
- All disorders of hypopigmentation are more easily observed in darkly pigmented individuals or after a suntan.

## Approach to Disorders of Hypopigmentation

- Assess the following parameters:
  1. Age of onset (e.g. birth/infancy vs. childhood vs. adulthood).
  2. Presence or absence of preceding inflammation.
  3. Distribution pattern (see below) and anatomic location.
  4. Degree of pigment loss.
- The distribution patterns can be divided into *circumscribed* (e.g. vitiligo), *diffuse* (e.g. albinism), *linear*, or *guttate* (e.g. idiopathic guttate hypomelanosis).
- An approach to leukoderma is outlined in Fig. 54.1.

## Vitiligo

- An acquired disease, due to autoimmune destruction of melanocytes, that is characterized by circumscribed, amelanotic macules or patches of the skin and mucous membranes (Fig. 54.2); hairs within involved areas may be depigmented or pigmented; the uveal tract and retinal pigmented epithelium can also be affected.
- Two major subtypes of vitiligo: *generalized* (most common) and *localized* (Fig. 54.3).
- A polygenic disorder, i.e. involving multiple susceptibility genes, plus environmental factors (mostly unknown).
- There is an increased incidence of other autoimmune disorders (e.g. thyroid disease > Addison disease, pernicious anemia, SLE, rheumatoid arthritis, type I diabetes mellitus) in individuals with vitiligo as well as in family members; associated autoimmune skin disorders include halo melanocytic nevi, alopecia areata, and lichen sclerosus.

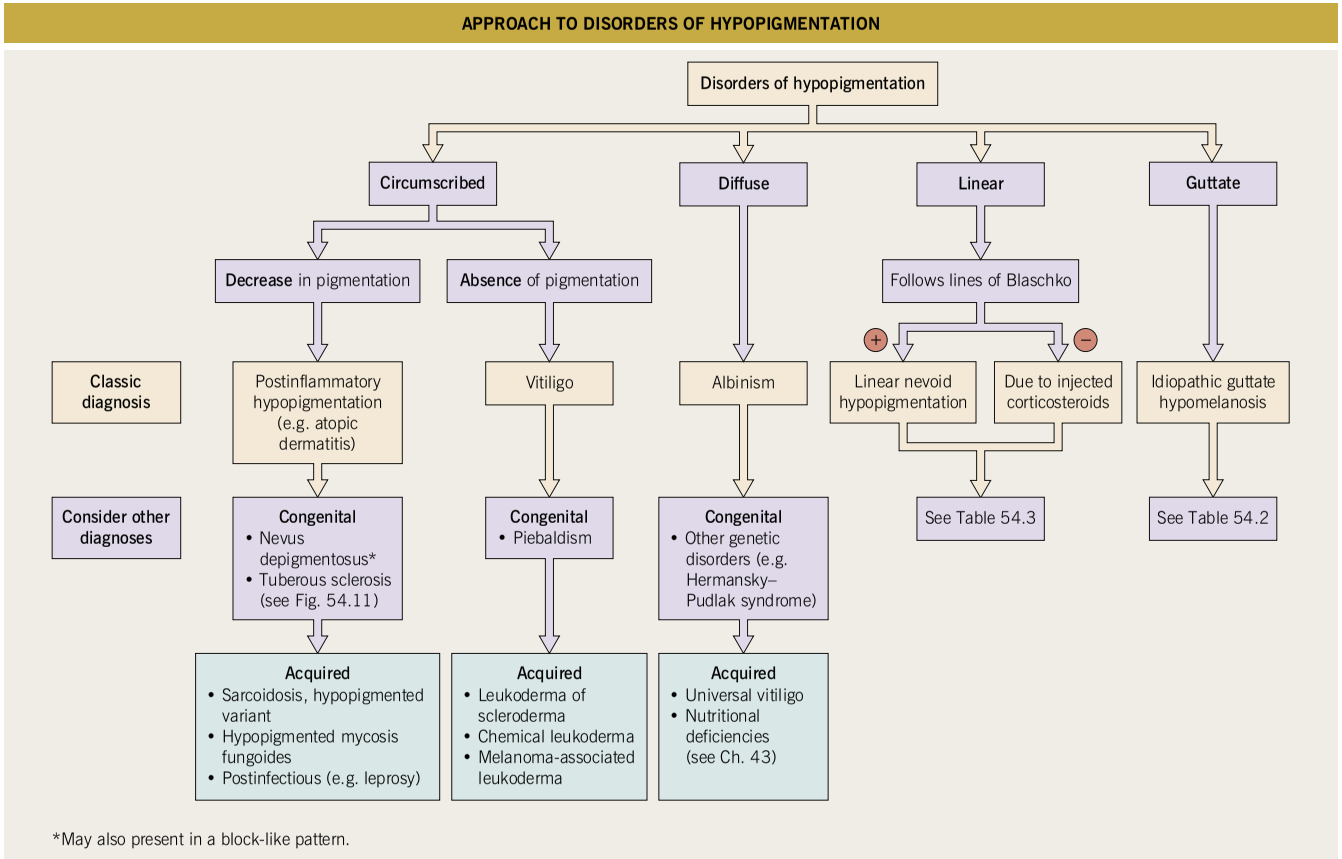


**Fig. 54.1 Approach to disorders of hypopigmentation.**




**Fig. 54.2 Vitiligo. A** Complete loss of pigment on the penis and scrotum. Note the lack of any secondary changes. **B** Depigmentation of the volar wrists as well as the palmar surfaces; easily recognizable in darkly pigmented individuals. *A, Courtesy, Lorenzo Cerroni, MD; B, Courtesy, Jean L. Bolognia, MD.*

- ***Generalized vitiligo.***
  - Includes acrofacial, vulgaris, and universal variants (see Fig. 54.3); occasionally an inflammatory edge is seen (Fig. 54.4)
  - Affects ~1% of the population worldwide; males = females; onset in ~50% before age 20 years; onset after age 50 years is unusual and prompts widening of the **DDx** (see below)
  - The typical lesion is an asymptomatic, amelanotic macule or patch that is milk or chalk-white in color; early on the pigment loss may not be complete; margins are fairly discrete and convex
  - Course is unpredictable, but often progressive
- ***Segmental vitiligo.***
  - Usually begins in childhood; typically presents in a unilateral, segmental pattern that respects the midline, most often with an initial rapidly progressive phase followed by stabilization within ~1–2 years (Fig. 54.5)
  - **DDx:** nevus depigmentosus (decreased but not total absence of pigment)
- **DDx** of depigmented lesion(s).
  - **In a child:** if 1–2 isolated circular or oval macules, stage 3 halo nevus; piebaldism, Waardenburg syndrome (see below)
  - **In an adult:** chemical leukoderma, melanoma-associated leukoderma, leukoderma of scleroderma, Vogt–Koyanagi–Harada syndrome, onchocerciasis, and postinflammatory *de*pigmentation (see below)
  - With the exception of onchocerciasis, or in areas of sclerosis or inflammation, a biopsy is not particularly helpful
- **Vitiligo and ocular disease.**
  - Uveitis is the most significant ocular abnormality; asymptomatic depigmented areas of the ocular fundus can also be seen
  - Uveitis is a major component of the *Vogt–Koyanagi–Harada syndrome*, in which patients also develop aseptic meningitis, otic involvement (e.g. dysacousia), poliosis, and vitiligo, especially of the head and neck region
  - *Alezzandrini syndrome* is a rare disorder characterized by unilateral facial vitiligo, poliosis, and ipsilateral ocular involvement
- **Rx:** primarily directed at halting the progression of disease and at repigmentation (Fig. 54.6); there is some evidence that earlier initiation of treatment is more effective.

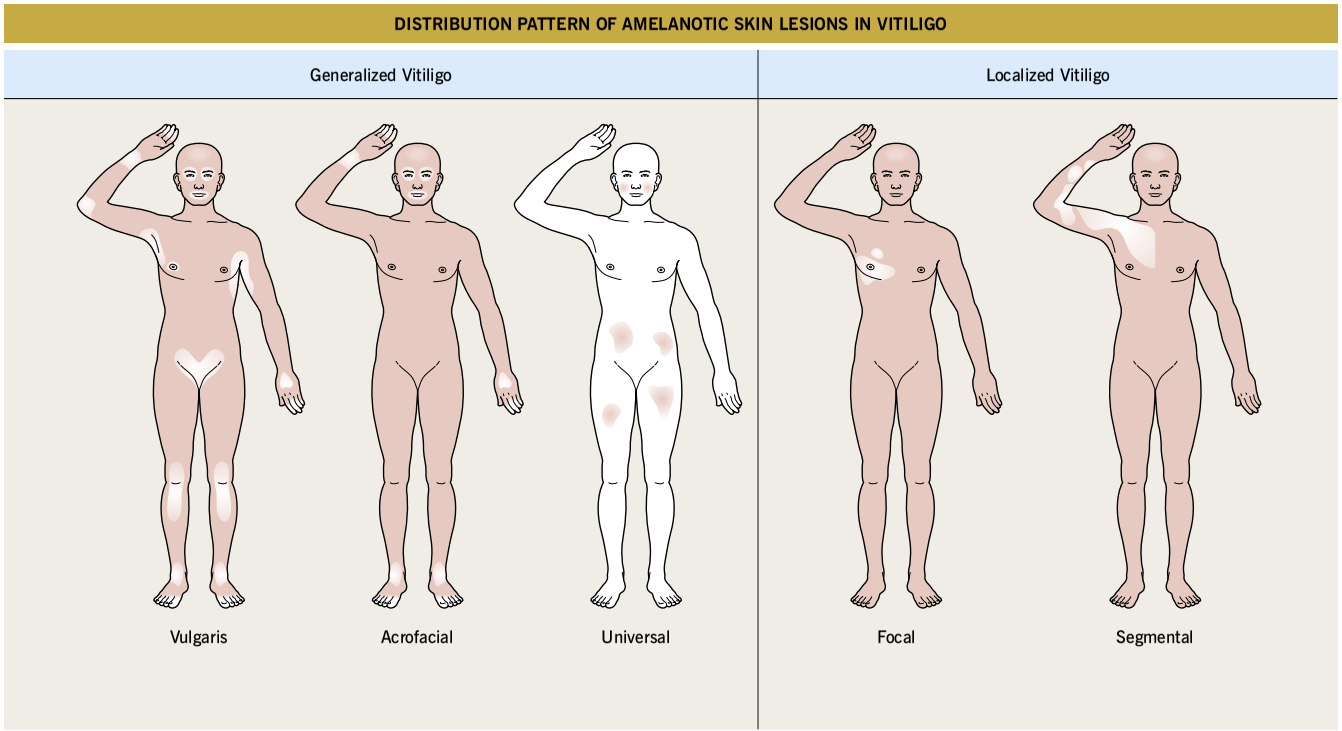


**Fig. 54.3 Distribution of amelanotic skin lesions in vitiligo.** Vitiligo is clinically divided into two broad categories: *generalized* and *localized*. The three distribution patterns in *generalized* vitiligo include *vulgaris*, *acrofacial*, and *universal*. In *focal* vitiligo, the amelanotic macules or patches are limited to one or only a few areas, but not necessarily in a segmental pattern, as in *segmental* vitiligo, which is also unilateral and respects the midline. *Adapted with permission from Le Poole C, Boissy RE. Vitiligo. Semin Cutan Med Surg 1997;16:3–14.*

– The choice of treatment depends upon the extent, location and activity of the vitiligo, as well as the patient's age, skin type, and motivation for treatment
– Treatment of progressive disease more difficult than stable disease
– Repigmentation usually appears in a perifollicular pattern (Fig. 54.7) and/or from the periphery of lesions; vitiligo in areas with hair (e.g. face, neck, mid extremities) is typically more responsive to treatment compared to distal digits and lips, which lack hair
– 10–20% monobenzyl ether of hydroquinone (MBEH) is sometimes used as depigmentation therapy for widespread or treatment-resistant vitiligo, but it can be permanent and lead to loss of pigment in areas distant to the sites of application



**Fig. 54.4 Inflammatory vitiligo.** An erythematous inflammatory border is evident. Such lesions are sometimes misdiagnosed as tinea corporis. *Courtesy, Thierry Passeron, MD.*

## Hereditary Hypomelanosis

### Oculocutaneous Albinism (OCA)

•A group of genetic disorders characterized by pigmentary dilution due to a partial or total absence of melanin within the skin, hair follicles, and eyes; the number of melanocytes is normal.
• Estimated frequency is 1:20,000, but may be 1:1500 in areas of Africa.
• Multiple types of OCA (Table 54.1) exist; nearly always inherited in an autosomal recessive manner; OCA1 and OCA2 constitute ~90% of all cases of OCA.
• The ocular manifestations are due to a decrease of melanin within eye structures (e.g. photophobia, reduced visual acuity) or the misrouting of optic nerve fibers during development (e.g. strabismus, nystagmus, lack of stereoscopic vision).
• Early ophthalmologic consultation and strict photoprotection are mandatory; the development of aggressive SCCs (Fig. 54.8A) is a significant cause of morbidity and mortality.

### Disorders of Melanocyte Development

#### PIEBALDISM

• A rare autosomal dominant congenital disorder resulting primarily from mutations

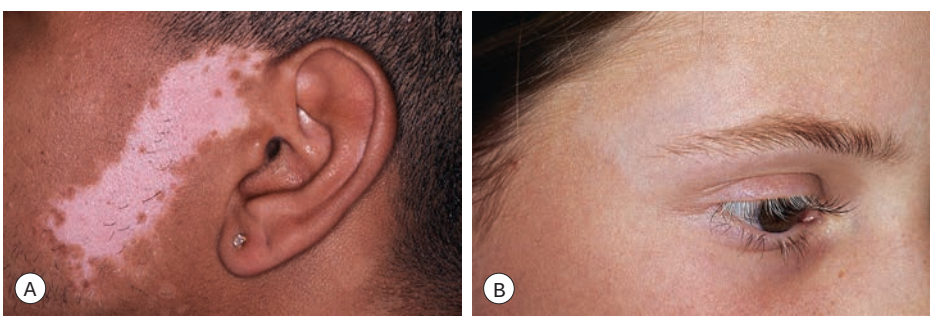


**Fig. 54.5 Segmental vitiligo. A** Unilateral band of depigmentation on the face, the most common location for segmental vitiligo. Note the pigmented and depigmented hairs within the affected area. **B** Under normal light, vitiligo can be subtle in lightly pigmented individuals. The clue to the diagnosis is the poliosis of the eyelashes. *A, Courtesy, Kalman Watsky MD; B, Courtesy, Jean L. Bolognia, MD.*

**TREATMENT OPTIONS FOR VITILIGO**

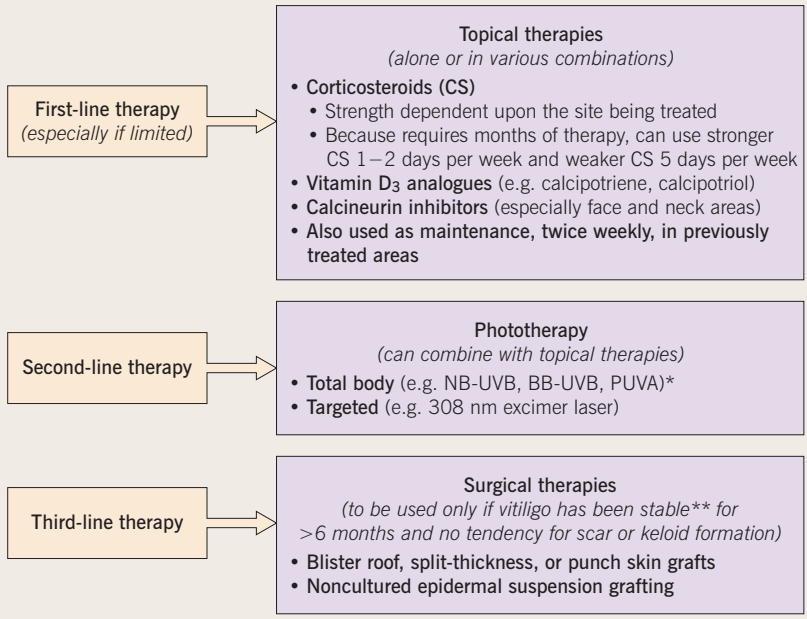


*Can be considered as first-line therapy for more extensive disease, rapidly progressive disease, or cosmetically sensitive areas

**Unstable disease is characterized by koebnerization, confetti-like lesions, and inflammatory or trichrome vitiligo

**Fig. 54.6 Treatment options for vitiligo.** Treatment of vitiligo is directed at halting the progression of disease and at repigmentation of patient-desired areas. Some clinicians may use oral or IM CS in the short term to help stabilize aggressive or rapidly progressive disease, in conjunction with other modalities. Camouflage can be offered to all patients for temporary (e.g. makeup, self-tanners) or more permanent (e.g. tattoos) cosmetic relief. Referral to a support group (e.g. Vitiligo Support International [vitiligosupport.org]) may also be helpful. 10–20% monobenzyl ether of hydroquinone (MBEH) is sometimes used (see text). Non-FDA-approved systemic therapies include an alpha-melanocyte-stimulating hormone analogue (afamelanotide) and JAK inhibitors, in combination with NB-UVB.




**Fig. 54.7 Perifollicular repigmentation.** Vitiligo on the elbow **(A)** and segmental vitiligo on the back **(B)** responding to PUVA and narrowband UVB therapy, respectively, with repigmentation in a prominent perifollicular pattern as well as from the periphery. The areas of repigmentation are darker in color than the uninvolved skin in **(A)**. *A, Courtesy, Jean L. Bolognia, MD; B, Courtesy, Julie V. Schaffer, MD.*

| CLASSIFICATION OF OCULOCUTANEOUS ALBINISM (OCA) | |
|---|---|
| **Type (gene mutation)** | **Clinical features** |
| OCA1A (*TYR*) *absent* tyrosinase activity | • **At birth:** white hair, milk-white skin, blue-gray eyes, pink nevi<br>• No increase in pigmentation over time, except for the denaturing (yellow color) of hair<br>• Most severe ocular abnormalities (see text) |
| OCA1B (*TYR*) *reduced* tyrosinase activity | • **At birth:** similar to OCA1A<br>• Majority acquire some pigmentation of hair and skin during first two decades of life<br>• Ocular abnormalities less severe than in OCA1A |
| OCA2 *(OCA2)* | • **At birth:** more pigmentation compared to OCA1A<br>• Over time, pigmented nevi may develop and large, stellate lentigines appear in photodistributed sites (Fig. 54.8B) |
| OCA3 *(TYRP1)* | • Red-bronze skin, ginger-red hair, blue or brown irides |
| OCA4 *(SLC45A2)* | • Similar clinical presentation as OCA2, with variability in pigmentation |

**Table 54.1 Classification of oculocutaneous albinism (OCA).** Three additional, less common OCA subtypes include OCA5, OCA6, OCA7. SLC45A2, solute carrier family 45 member 2; TYR, tyrosinase; TYRP1, tyrosinase-related protein-1.

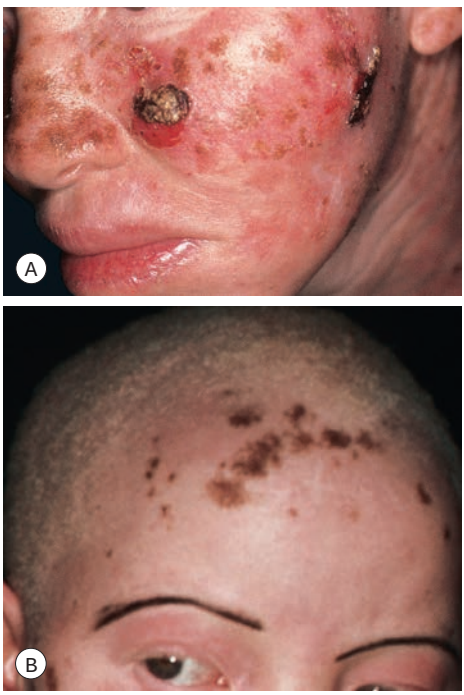


**Fig. 54.8 Oculocutaneous albinism type 2 (OCA2). A** African patient with obvious squamous cell carcinomas on the cheek as well as multiple pigmented lentigines. **B** African patient with hypopigmented hair and large pigmented lentigines. *Courtesy, James Nordlund, MD.*

in the *KIT* proto-oncogene, causing abnormal melanocyte development.

- Presents at birth with poliosis of the mid frontal scalp and stable circumscribed areas of amelanosis in a characteristic distribution pattern, favoring the anterior trunk, mid extremities, and central forehead (Fig. 54.9).
- Areas of amelanosis contain normally pigmented and hyperpigmented macules and patches within them (see Fig. 54.9); the latter can be seen in uninvolved skin.
- **Rx:** amenable to autologous skin grafting given its stability.

### WAARDENBURG SYNDROME (WS)

- A rare autosomal dominant or recessive disorder characterized by:
  - Skin lesions resembling piebaldism, including the white forelock
  - Congenital deafness (10–40%)
  - Partial or total heterochromia iridis
  - Medial eyebrow hyperplasia (synophrys)
  - Broad nasal root
  - Dystopia canthorum (increase in the distance between the inner canthi with normal interpupillary distance)
- Four clinical subtypes have been described:
  - WS1: classic form
  - WS2: lacks dystopia canthorum (Fig. 54.10)




**Fig. 54.9 Piebaldism. A** White forelock (poliosis) and characteristic triangular amelanotic patch on the mid-forehead. **B** Mother and son with the characteristic involvement of the mid-extremities. Note the normally pigmented macules within the leukoderma. *A, Courtesy, Julie V. Schaffer, MD; B, Courtesy, Jean L. Bolognia, MD.*



**Fig. 54.10 Waardenburg syndrome type 2.** Heterochromia irides in the absence of dystopia canthorum. The white forelock is seen in the upper left corner. *Courtesy, Daniel Albert, MD.*

- WS3: associated limb abnormalities
- WS4: associated with Hirschsprung disease

## Disorders of Melanosome Biogenesis

- Because biosynthesis of lysosome-related organelles, e.g. platelet-dense granules and lytic granules of cytotoxic lymphocytes and natural killer cells, are also affected, patients can have a bleeding diathesis and immunodeficiency.

### HERMANSKY–PUDLAK SYNDROME (HPS)

- Autosomal recessive inheritance; eight subtypes; HPS1 and HPS3 are the most common subtypes seen in Puerto Ricans.
- Characterized by variable pigmentary dilution of skin, hair, and eyes, depending on ethnicity; ocular manifestations of OCA; bleeding tendency; normal platelet count with a prolonged bleeding time.
- Depending on HPS subtype, may develop fatal pulmonary fibrosis and/or granulomatous colitis; average life span is 30–50 years.
- No specific treatment other than platelet transfusions prior to surgery.

### CHÉDIAK–HIGASHI SYNDROME (CHS)

- Characterized by silvery hair, OCA skin and ocular findings, bleeding diathesis, progressive neurologic dysfunction, and infections due to severe immunodeficiency.
- Giant lysosomes within neutrophils seen on peripheral blood smear.
- Death is often in childhood secondary to infection, bleeding, or an accelerated lymphoma-like phase.
- **Rx:** hematopoietic stem cell transplant.

## Disorders of Melanosome Transport and/or Transfer to Keratinocytes

- Consequences of this disrupted transport are pigmentary dilution and silvery hair (which contains melanin clumps in the hair shafts).

### GRISCELLI SYNDROME (GS)

- Autosomal recessive; three subtypes, based on sites of expression of three mutated genes; all characterized by silvery hair and pigmentary dilution; patients can also have neurologic

impairment (GS1) or immune abnormalities and hemophagocytic syndrome (GS2).

## Other

### TUBEROUS SCLEROSIS COMPLEX (TSC) (See Ch. 50)

- Hypomelanotic macules are often the first sign of TSC.
- These hypomelanotic macules are typically multiple in number; polygonal is the most common shape, followed by lance-ovate or "ash leaf" (Fig. 54.11); less often, the macules are "thumbprint"-like, guttate/confetti, or segmental (see Fig. 54.11; Table 54.2); lesions favor the trunk or extremities.



**Fig. 54.11 Tuberous sclerosis complex (TSC).** Two types of hypomelanotic macules, lance-ovate (ash leaf) and confetti (idiopathic guttate hypomelanosis-like). *Courtesy, David Strobel, MD.*

## Hypopigmentation in Mosaic Patterns

- Several patterns of hypopigmentation can result from a mosaic "clone" of skin cells with decreased potential for pigment production ("pigmentary mosaicism").
- Hypopigmented areas may be apparent at birth or become evident during childhood, especially in patients with fair skin.

### LINEAR NEVOID HYPOPIGMENTATION

- Localized or widespread streaks and swirls of hypopigmentation that follow the lines of Blaschko, which represent pathways of epidermal cell migration during embryogenesis (Fig. 54.12; see Fig. 51.1).
- ~10–20% of affected individuals have associated extracutaneous abnormalities, most often affecting the CNS (e.g. seizures, developmental delay), eyes, or musculoskeletal system; more severe involvement is usually

| DIFFERENTIAL DIAGNOSIS OF GUTTATE LEUKODERMA |
|---|
| Idiopathic guttate hypomelanosis (see Fig. 54.23) |
| Pityriasis lichenoides chronica (see Fig. 7.3E) |
| Lichen sclerosus (see Fig. 54.17) |
| Confetti-like lesions of tuberous sclerosis (see Fig. 50.10B) |
| Tinea versicolor (especially on the face of children; see Fig. 54.18B) |
| Pityriasis alba (favors the cheeks of children) |
| Achromic verrucae planae* |
| Frictional lichenoid dermatosis* |
| Clear cell papulosis* |
| Vitiligo ponctué |
| Darier disease (usually admixed with keratotic lesions; see Fig. 48.4) |
| Xeroderma pigmentosum |
| In association with chromosomal abnormalities |
| Following PUVA therapy (leukoderma punctata, disseminated hypopigmented keratoses*) |

**Table 54.2 Differential diagnosis of guttate leukoderma.** Guttate hypopigmentation may also be seen in the setting of dyschromatoses (see Ch. 55). *Adapted from Bolognia JL, Shapiro PE. Albinism and other disorders of hypopigmentation. In Arndt KA, et al. (Eds.). Cutaneous Medicine and Surgery. Philadelphia: Saunders, 1995.*

apparent in infancy and evaluation is directed by clinical findings.

- The term *hypomelanosis of Ito* has been used in studies focusing on linear nevoid hypopigmentation associated with systemic manifestations, and it should be reserved for this subset of patients.
- **DDx:** outlined in Table 54.3 (Fig. 54.13).

### NEVUS DEPIGMENTOSUS

- Present in ~1:50 children, generally as an isolated finding.



**Fig. 54.12 Linear nevoid hypopigmentation.** Hypopigmented streaks with various widths along the lines of Blaschko on the posterior lower extremities. *Courtesy, Antonio Torrelo, MD.*

- Lesions are typically hypopigmented, not depigmented as implied by the name.
- *Classic form*: ovoid or irregular hypopigmented patch, often breaking up into smaller macules at its periphery (Fig. 54.14).
- *Segmental form* (hypopigmented variant of *"segmental pigmentation disorder"*): block-like hypopigmented patch with midline demarcation and less distinct lateral borders.

### PHYLLOID HYPOMELANOSIS

- Leaf-shaped and oblong hypopigmented macules and patches in an arrangement resembling a floral ornament, usually in the setting of mosaic trisomy 13 and associated with CNS abnormalities.

## Postinflammatory Hypomelanoses

- Inflammatory skin conditions can potentially result in postinflammatory *hypo*pigmentation or *hyper*pigmentation or both (see Ch. 55).
- Postinflammatory hypopigmentation is a very common skin disorder that follows a wide variety of dermatoses, most commonly atopic dermatitis, seborrheic dermatitis, and psoriasis,

| DISORDERS WITH LINEAR HYPOPIGMENTATION |
|---|
| **Lesions usually follow lines of Blaschko** |
| Linear nevoid hypopigmentation*/hypomelanosis of Ito (see Fig. 54.12)<br>Lichen striatus (see Ch. 9 and Fig. 54.15D)<br>Focal dermal hypoplasia (Goltz syndrome; see Fig. 51.8A)<br>Menkes kinky hair disease (female carrier; see Ch. 43)<br>Conradi–Hünermann–Happle syndrome (see Ch. 46)<br>Epidermal nevus<br>In association with Munro acne nevus (see Fig. 51.3G)<br>Linear lichen sclerosus (see Ch. 36)<br>Guttate macules in linear keratosis follicularis and linear basaloid follicular hamartoma |
| **Lesions may follow lines of Blaschko** |
| Segmental vitiligo (see Fig. 54.5)<br>Segmental ash leaf spot<br>Fourth stage of incontinentia pigmenti (see Fig. 54.13) |
| **Lesions do not follow lines of Blaschko** |
| Linear hypopigmentation secondary to intralesional corticosteroids (see Fig. 54.22A)<br>Pigmentary demarcation lines, type C (see Ch. 55) |
| **Block-like hypopigmentation (segmental pigmentation disorder) represents another pattern of "pigmentary mosaicism" and may coexist with linear lesions; previous terms include "systematized" nevus depigmentosus with a linear configuration.* |

**Table 54.3 Disorders with linear hypopigmentation.** *Adapted from Bolognia JL, Shapiro PE. Albinism and other disorders of hypopigmentation. In Arndt KA, et al. (Eds.). Cutaneous Medicine and Surgery. Philadelphia: Saunders, 1995.*

as well as pityriasis lichenoides chronica, lichen striatus, and lichen sclerosus (Fig. 54.15).

- It typically coexists or co-localizes with the inflammatory lesions, but occasionally only hypopigmented lesions are seen; the size, shape, and distribution pattern often provide clues to the underlying inflammatory dermatosis and the clinician can imagine the lesions being pink, red or red-brown.
- Most commonly there is a decrease in pigmentation; rarely there is an absence (e.g. severe atopic dermatitis).
- Histopathologic examination is often nonspecific, but in certain diseases (e.g. sarcoidosis and hypopigmented mycosis fungoides) can be diagnostic.
- **Rx** of underlying dermatosis is followed by gradual resolution.

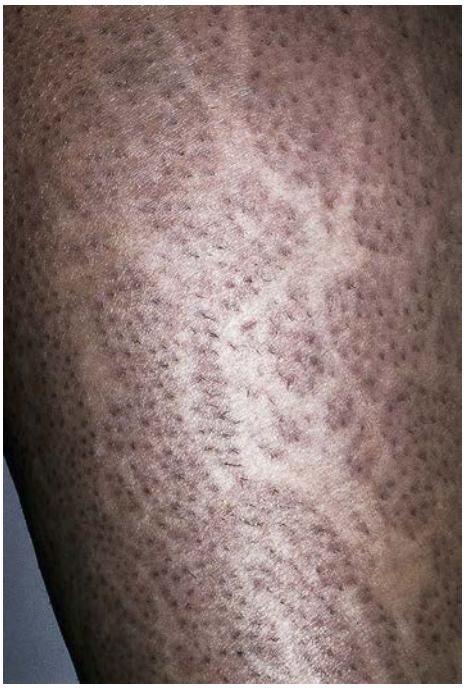

**Fig. 54.13 Stage 4 of incontinentia pigmenti.** Note the absence of hairs within the irregular streaks on the calf. *Courtesy, USCDRSC.*



**Fig. 54.14 Nevus depigmentosus.** Hypomelanotic patch with a decrease, but not absence, of pigmentation. *Courtesy, YDRSC.*

## Pityriasis Alba (See Ch. 10)

- A very common, asymptomatic disorder seen primarily during childhood and adolescence.
- One to several slightly scaly, hypopigmented macules and patches are seen, typically on the cheeks; the lesions are usually ill-defined and occasionally there is associated mild erythema.
- The hypomelanosis often becomes more apparent during the summer months; emollients, sunscreens, or low-strength topical CS (e.g. hydrocortisone 2.5%) may be helpful.
- **DDx:** tinea versicolor, early vitiligo, and postinflammatory hypopigmentation from seborrheic dermatitis or atopic dermatitis.

## Sarcoidosis

- Sarcoidosis occurs more commonly in African-Americans, and the hypopigmented variant of cutaneous sarcoidosis may go undiagnosed; this form has no associated prognostic significance and may spontaneously repigment.
- Hypopigmented papules, plaques, or sometimes nodules are seen; range in size from 1 to several cm.
- Histopathology reveals noncaseating granulomas.

## Hypopigmented Mycosis Fungoides (MF) (See Ch. 98)

- A variant of early stage MF that is most commonly observed in darkly pigmented individuals (see Fig. 54.15E); seen in adults, as well as children and adolescents.
- Atrophy can be observed within the hypopigmented patches.
- Histopathology reveals typical features of MF.
- **DDx:** hypopigmented parapsoriasis, pityriasis lichenoides chronica (PLC).

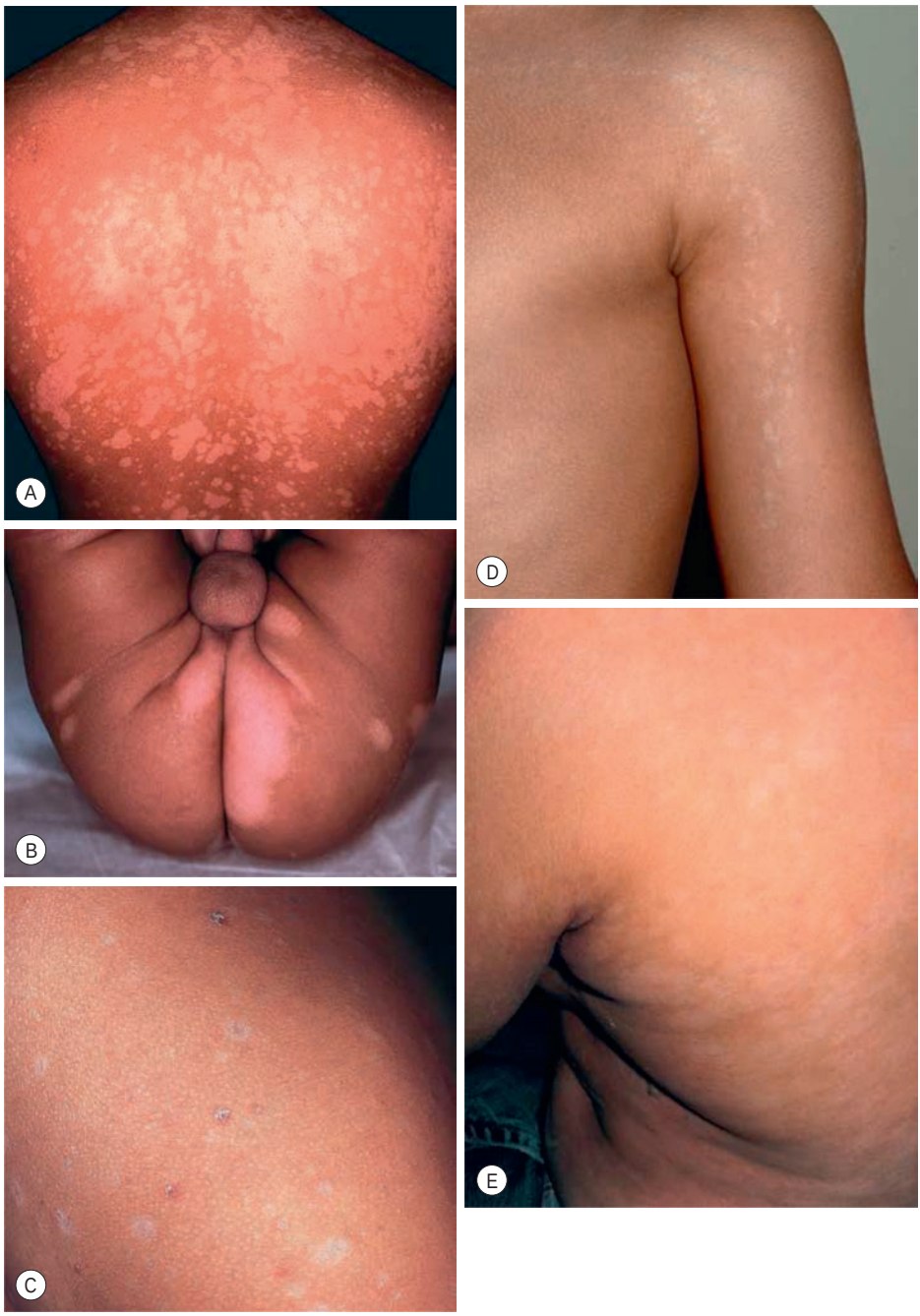


**Fig. 54.15 Postinflammatory hypomelanosis.** Hypopigmentation secondary to psoriasis **(A),** seborrheic dermatitis in an infant **(B),** pityriasis lichenoides chronica **(C)**, lichen striatus (note the flat-topped papules) **(D),** and hypopigmented mycosis fungoides **(E)**. *Continued*




**Fig. 54.15** *Continued* **Postinflammatory hypomelanosis.** Complete pigment loss in patients with severe atopic dermatitis **(F)**, discoid lupus erythematosus **(G)**, and neonatal lupus erythematosus **(H)**. *A, E–G, Courtesy, YDRSC; B, Courtesy, Jean L. Bolognia, MD; C, Courtesy, SUNYSBDRSC; D, H, Courtesy, Julie V. Schaffer, MD.*

### Cutaneous Lupus Erythematosus (LE) (See Ch. 33)

- In discoid LE (DLE), hypomelanosis is often seen centrally within well-developed lesions and the lesions also have cutaneous atrophy, scarring, erythema (if active) and a hyperpigmented rim; pigmentary changes tend to be persistent (see Fig. 54.15G).
- In subacute cutaneous LE (SCLE), hypomelanosis typically occurs within the center of annular lesions and is usually reversible.

### Systemic Sclerosis (SSc) (See Ch. 35)

- Patients with SSc can develop several pigmentary abnormalities, including diffuse hypermelanosis with photoaccentuation, mixed hyper- and hypopigmentation in areas of chronic sclerosis, and a characteristic leukoderma in both sclerotic and nonsclerotic skin (Fig. 54.16).
- This leukoderma of systemic sclerosis presents as circumscribed areas of depigmentation but with perifollicular and supravenous retention of pigment (see Fig. 54.16).
- This peculiar leukoderma is rather specific for SSc as it occasionally occurs in two other clinical settings, an overlap syndrome (that includes SSc) and scleromyxedema.
- Although clinically similar to the perifollicular repigmentation seen in treatment-responsive vitiligo, it is different in that in vitiligo the perifollicular macules represent *new* pigmentation, whereas in SSc the macules represent *old* or retained pigmentation.

### Lichen Sclerosus (LS) (See Ch. 36)

- Genital and extragenital lesions of LS are often hypopigmented, but in addition display cutaneous atrophy, follicular plugging (extragenital), and purpura (genital).
- Occasionally extragenital LS presents as guttate leukoderma (Fig. 54.17; see Table 54.2).



**Fig. 54.16 Leukoderma of systemic sclerosis (scleroderma).** Uniform retention of perifollicular pigment within areas of leukoderma. Hyperpigmentation is also seen overlying a superficial vein. *Courtesy, YDRSC.*

## Infectious and Parasitic Hypomelanosis

### Tinea (Pityriasis) Versicolor (See Ch. 64)

- A very common superficial cutaneous mycosis caused by *Malassezia* spp.; although there is usually minimal inflammation, this infection can lead to either hyper- or hypopigmentation.
- Typically presents symmetrically on the upper trunk and shoulders or flexural areas (e.g. groin and inframammary) as round to oval macules or thin papules that coalesce into patches or thin plaques; the lesions vary in color from pink to light tan to brown, hence the term *versicolor* (Fig. 54.18).
- Lesions often coalesce and when untreated, there is usually a subtle overlying fine scale that is more readily apparent upon scratching or stretching the skin.
- Diagnosis is easily confirmed by KOH examination of the associated scale.



**Fig. 54.17 Guttate lichen sclerosus involving the areolae.** *Courtesy, YDRSC.*

- Hypomelanosis without any scaling may remain for months after treatment.

### Leprosy (See Ch. 62)

- *Tuberculoid leprosy* (Fig. 54.19): fewer larger hypopigmented patches with discrete, often raised, borders; favor posterolateral aspects of extremities, back, buttocks, face; associated anhidrosis, alopecia, and loss of sensation.
- *Borderline leprosy*: occasionally, ill-defined hypomelanotic macules are seen.
- *Indeterminate leprosy*: erythematous to hypomelanotic macules asymmetrically distributed on exposed sites; normal hair.
- *Lepromatous leprosy*: hypomelanotic macules may be the earliest manifestation; often small, multiple, subtle, and ill-defined; favor the face, extremities, and buttocks; minimal or no anhidrosis or loss of sensation.

### Treponematoses (See Chs 61 and 69)

- Non-venereal treponematoses (e.g. pinta, yaws, bejel) and venereal syphilis may be associated with hypomelanosis, especially during their untreated phase.

### Onchocerciasis (River Blindness) (See Ch. 70)

- A filarial infestation that predominantly affects cutaneous and ocular tissues and is caused by the transmission of *Onchocerca volvulus* from the bite of a black fly in tropical areas of Africa > Central and South America.

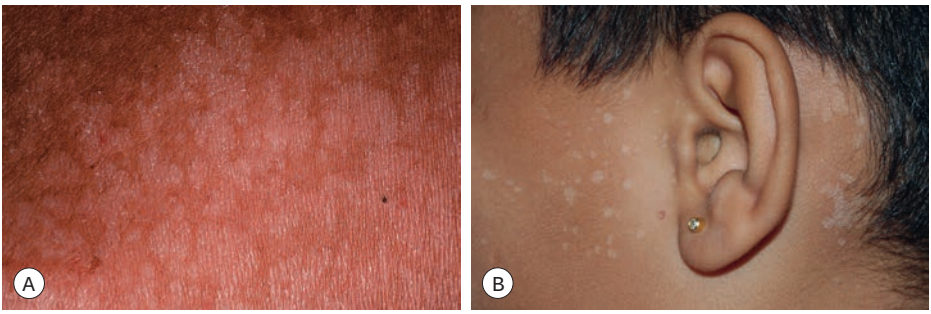


**Fig. 54.18 Tinea (pityriasis) versicolor. A** Hypopigmented variant with obvious scale. **B** Guttate hypopigmented lesions on the cheek; note the classic scaly lesions in the posterior auricular area. *A, Courtesy, YDRSC; B, Courtesy, Julie V. Schaffer, MD.*



**Fig. 54.19 Tuberculoid leprosy.** Large thin hypopigmented plaque on the elbow with a raised light pink border. *Courtesy, YDRSC.*



**Fig. 54.20 Onchocerciasis (leopard skin).** Depigmentation of the shin with follicular repigmentation or retention of perifollicular pigment, a common site for the associated leukoderma. Clinically resembles repigmenting vitiligo or the leukoderma of scleroderma. *Courtesy, Jean-Paul Ortonne, MD.*

- A later cutaneous finding is leukoderma of the shins with follicular pigmentation, resembling leopard skin (Fig. 54.20).
- **DDx:** atopic dermatitis with postinflammatory depigmentation, or atopic dermatitis plus vitiligo with Koebner phenomenon.

### Other

- Hypopigmentation may also result from cutaneous bacterial or viral infections, e.g. herpes zoster.

## Melanoma-Associated Leukoderma (See Ch. 93)

- Vitiligo-like depigmentation can occur in patients with cutaneous or ocular melanoma, either spontaneously or in the setting of immunotherapy (e.g. ipilimumab, pembrolizumab, nivolumab).
- Thought to result from an immune reaction directed against shared antigens on normal and malignant melanocytes (Fig. 54.21).
- Whereas the spontaneous form points to the need for re-staging, the treatment-associated form can portend a better prognosis.

## Chemical Leukoderma

- Contact with a number of chemical agents can lead to hypomelanosis of the skin and hair (Fig. 54.22).
- Depigmenting compounds have chemical structures that are similar to melanin precursors; they include catechols, phenols, or quinones (e.g. hydroquinone [HQ] or monobenzyl ether of HQ [MBEH]).
- HQ induces a reversible hypopigmentation, whereas MBEH depigmentation is often permanent and occurs not only at the site of application but also at distant sites.
- Topical and injected CS can also lead to hypopigmentation (see Fig. 54.22).

## Miscellaneous

### Idiopathic Guttate Hypomelanosis (IGH)

- A very common disorder that increases in incidence with age; occurs in all races and skin types (Fig. 54.23).
- Typically presents as multiple, asymptomatic, small (guttate), well-circumscribed white macules on the extensor forearms and shins; the surface is smooth, often with accentuation of the skin markings.
- **DDx:** other guttate leukodermas (see Table 54.2).



**Fig. 54.21 Melanoma-associated leukoderma.** Vitiligo-like leukoderma associated with ipilimumab, an anti-cytotoxic T-lymphocyte-associated antigen-4 (CTLA-4) antibody, administered for metastatic melanoma. *Courtesy, Jean L. Bolognia, MD.*

### Progressive Macular Hypomelanosis of the Trunk (PMH)

- Characterized by asymptomatic, poorly defined, small, round to oval, non-scaly, hypopigmented macules and patches, primarily on the trunk and proximal upper extremities, often with confluence of lesions (Fig. 54.24).
- A less common variant is seen in Afro-Caribbean females as larger patches.
- **DDx:** previously treated tinea versicolor.

## Hair Hypomelanosis

- Circumscribed (poliosis) versus generalized (canities).
- Graying of hair, either localized or generalized, is characterized by an admixture of normally pigmented, hypomelanotic and amelanotic hairs.
- Whitening of hair is the endpoint of graying of hair, and both are due to defective maintenance of melanocyte stem cells.
- Premature graying of the hair has been associated with a number of genetic disorders (e.g. Werner syndrome, piebaldism) as well as vitiligo.
- Diffuse hypomelanosis of hair has been associated with both hereditary (e.g. Fanconi syndrome) and acquired causes (e.g. tyrosine kinase inhibitors, antimalarials).

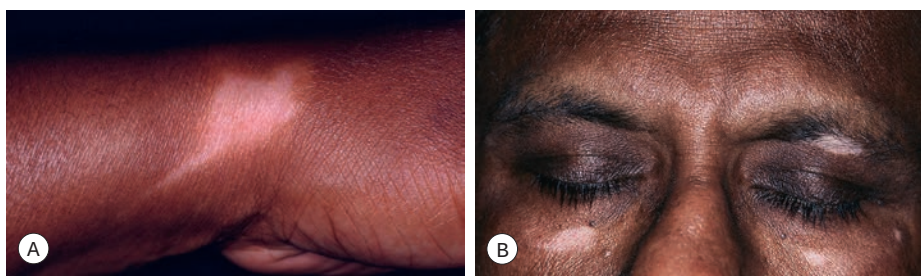


**Fig. 54.22 Chemical leukoderma. A** Hypopigmentation due to injection of corticosteroids into the anatomic snuff box. The outline is both stellate and linear. Typically appears several weeks to months after the injection. In most cases repigmentation occurs within one year after stopping the injections. **B** Depigmentation developed at sites of contact with rubber swimming goggles. *A, Courtesy, YDRSC; B, Courtesy, Kalman Watsky, MD.*

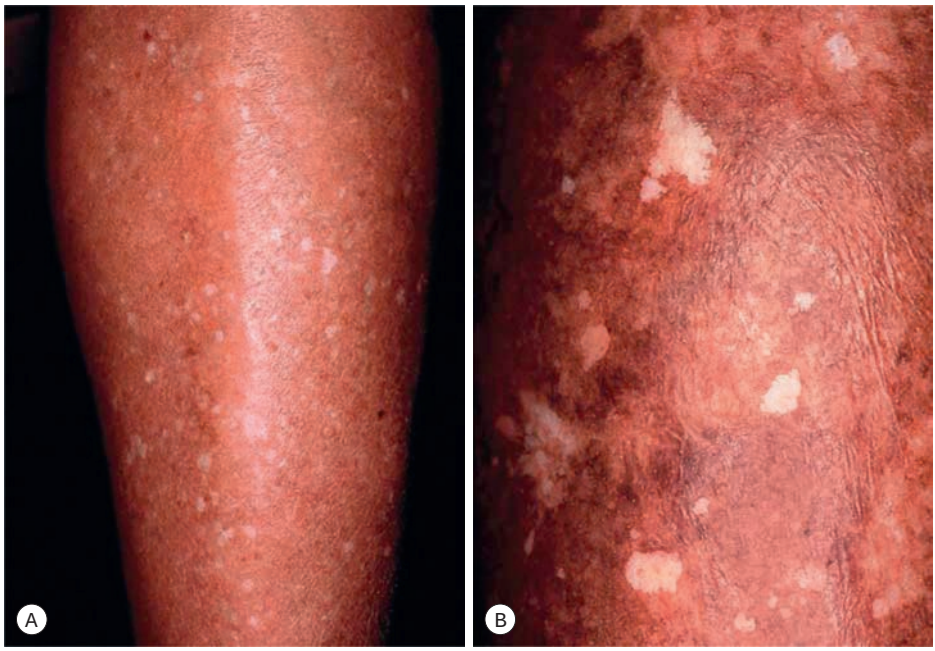


**Fig. 54.23 Idiopathic guttate hypomelanosis. A** Typical 1- to 5-mm macules on the shin. **B** Occasionally there is an admixture of larger lesions. *Courtesy, YDRSC.*



**Fig. 54.24 Progressive macular hypomelanosis.** Note the coalescence of the non-scaly hypopigmented macules on the center of the back. *Courtesy, Jean-Paul Ortonne, MD.*

For further information see Chs 65 and 66 from *Dermatology, Fourth Edition*.

**For additional online figures and tables visit www.expertconsult.com**



**eFig. 54.1 Vitiligo.** Complete loss of pigment of the glans penis. Note the lack of any secondary changes. *Courtesy, Jean L. Bolognia, MD.*



**eFig. 54.2 Inflammatory vitiligo.** There is a figurate outline to the inflammatory border, which is sometimes misdiagnosed as tinea corporis. *Courtesy, Jean-Paul Ortonne, MD.*




**eFig. 54.3 Piebaldism. A** White forelock (poliosis) and characteristic triangular amelanotic patch on the mid-forehead. **B** Characteristic involvement of the mid extremities. **C** Amelanotic patch on the upper calf. In all of these examples, note the normally pigmented and hyperpigmented macules of varying sizes within the leukoderma, especially at the periphery. *A, Courtesy, Diane Davidson, MD; B, C, Courtesy, Julie V. Schaffer, MD.*



**eFig. 54.4 Linear nevoid hypopigmentation.** Note the S-shaped pattern of the hypopigmented streaks along the lines of Blaschko. *Courtesy, YDRSC.*










**eFig. 54.5 Postinflammatory hypopigmentation. A,B** Hypopigmentation secondary to lichen striatus. Note the subtle flat-topped papules (**A**) and the hypopigmented band along the lines of Blaschko on the trunk (**B**). **C** Postinflammatory hypopigmentation in a child with atopic dermatitis. *A, Courtesy, YDRSC; B, Courtesy, Thierry Passeron, MD; C, Courtesy, Antonio Torrelo, MD.*




**eFig. 54.6 Guttate leukoderma. A** Disseminated hypopigmented keratoses presenting as >200 guttate, minimally elevated hypopigmented papules. The lesions developed after several months of PUVA therapy. Histopathologically, there was no evidence of verruca plana. **B** Clear cell papulosis presenting as multiple, hypopigmented, barely elevated, small flat-topped papules and macules in the suprapubic area and on the abdomen along the "milk lines" in a 2-year-old boy. Histopathologically, these lesions are characterized by large clear cells in the lower epidermis that have a pattern of immunohistochemical staining similar to clear cells of Toker and extramammary Paget disease. **C** Guttate hypopigmentation in sun-exposed areas on the extensor aspect of the arm in a 3-year-old Hispanic boy with xeroderma pigmentosum. Note the sparing of the proximal upper arm, which is normally covered by a T-shirt. *A, Courtesy, Jean L. Bolognia, MD; B, C, Courtesy, Julie V. Schaffer, MD.*



**eFig. 54.7 Chemical leukoderma.** Hypopigmentation due to injection of corticosteroids into the anatomic snuff box. The outline is both stellate and linear. Typically appears several weeks to months after the injection. In most cases repigmentation occurs within one year after stopping the injections. *Courtesy, YDRSC.*

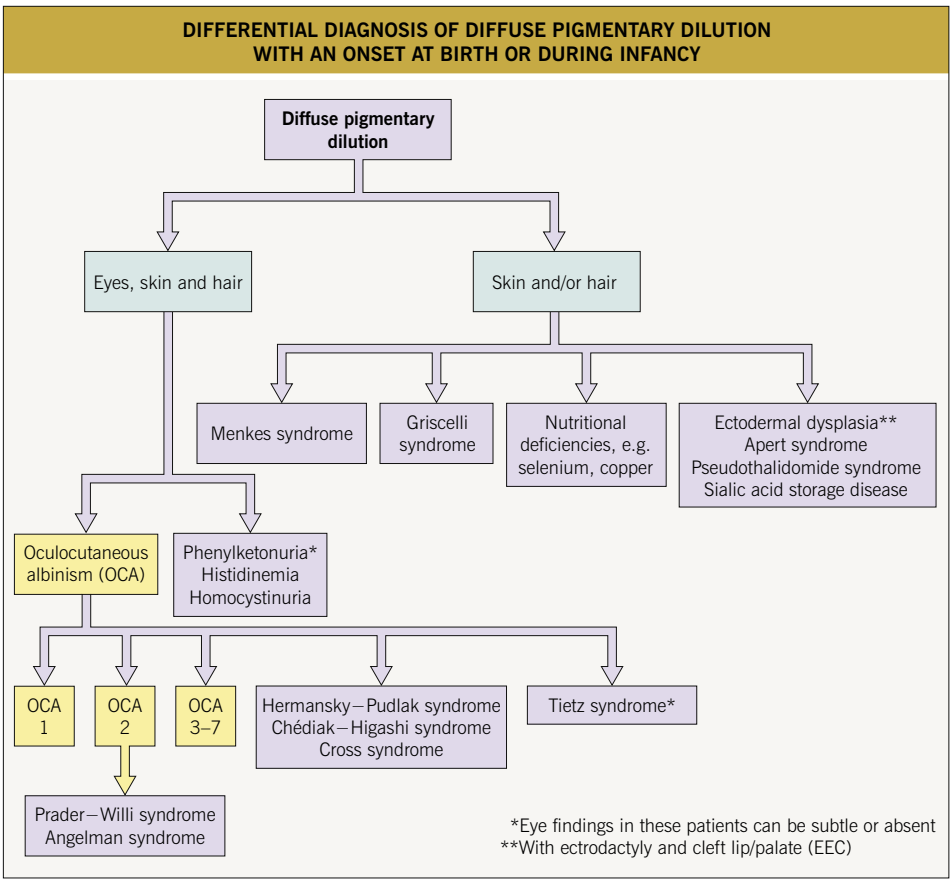


**eFig. 54.8 Differential diagnosis of diffuse pigmentary dilution with onset at birth or during infancy.** Patients with Griscelli syndrome and Chédiak–Higashi syndrome (CHS) have silvery hair and those with CHS can have an admixture of hyper- and hypopigmentation in chronically sun-exposed skin. Additional rare causes of diffuse pigmentary dilution include deficiency of the endosomal adaptor p14 and biallelic *KIT* mutations. *Adapted from Bolognia JL. A clinical approach to leukoderma. Int J Dermatol. 1999:38:568–72.*

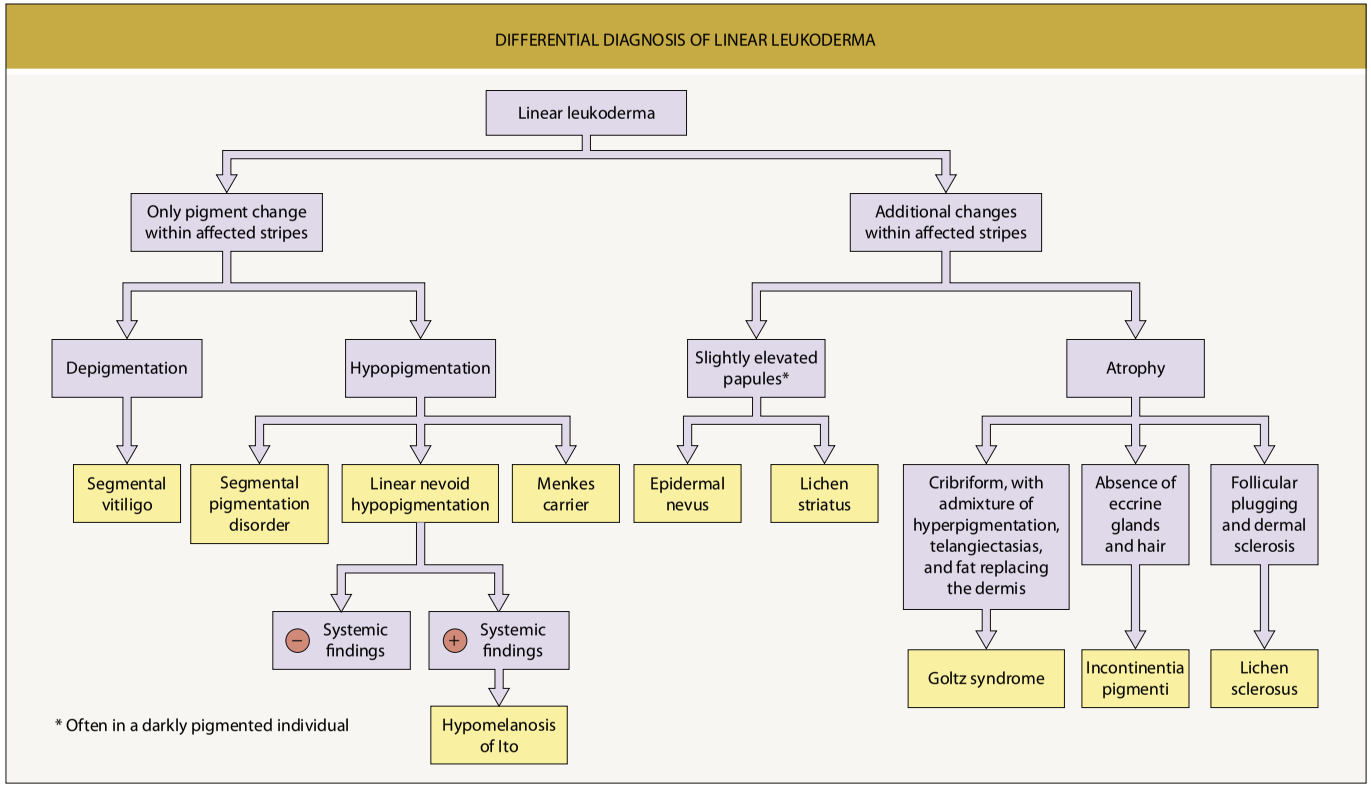


**eFig. 54.9 Differential diagnosis of linear leukoderma.**

| DIFFERENTIAL DIAGNOSIS OF CIRCUMSCRIBED SCALP POLIOSIS |
|---|
| **Inflammatory, autoimmune, or traumatic** |
| • Vitiligo<br>• Halo nevus<br>• Alopecia areata (primarily initial cycle of growth)<br>• Postinflammatory (e.g. discoid lupus, blepharitis [eyelashes])<br>• Postinfectious (e.g. zoster)<br>• Post-traumatic<br>• Vogt–Koyanagi–Harada syndrome<br>• Alezzandrini syndrome<br>• Melanoma-associated leukoderma (spontaneous or following immunotherapy) |
| **Inherited** |
| • Tuberous sclerosis complex*<br>• Piebaldism (midline frontal)<br>• Waardenburg syndrome (primarily midline frontal)<br>• Isolated white forelock†<br>• Isolated occipital white lock (X-linked recessive)<br>• White forelock with osteopathia striata (autosomal or X-linked dominant)<br>• White forelock with multiple malformations (autosomal or X-linked recessive)<br>• Neurofibromatosis type 1 – overlying a neurofibroma<br>• Prolidase deficiency and Marfan syndrome (single case reports) |
| **Nevoid** |
| • Angora hair nevus<br>• Associated with Munro acne nevus<br>• Scalp heterochromia secondary to mosaicism* |
| **Pharmacologic agents** |
| • Imiquimod<br>• Latanoprost (eyelash poliosis)<br>• Tyrosine kinase inhibitors (e.g. eyelash poliosis with cetuximab) |
| **Idiopathic** |
| **May be lighter than surrounding hair rather than white (e.g. blond streaks in a patient with brown hair).*<br>*†Separate entity vs possible forme fruste of piebaldism.* |

**eTable 54.1 Differential diagnosis of circumscribed scalp poliosis.** *Adapted from Bolognia JL, Shapiro PE. Albinism and other disorders of hypopigmentation. In Arndt KA, et al. (Eds.). Cutaneous Medicine and Surgery. Philadelphia: Saunders, 1995.*

# 55 Disorders of Hyperpigmentation

## Definitions

- **Hyperpigmentation**: a term used to describe disorders characterized by darkening of the skin; encompasses hypermelanosis.
- **Hypermelanosis**: a more specific term that denotes an increase in the melanin content of the skin; typically due to an increase in melanin production but occasionally from an increase in the density of active melanocytes.
- **Discoloration**: a term used to describe an abnormal color of the skin; may be due to deposition of substances such as drugs, drug complexes (e.g. with melanin or iron), or heavy metals within the dermis.
- **Dyschromatosis**: a disorder characterized by the presence of both hypo- and hyperpigmentation.
- **Pigment incontinence**: the presence of melanin within dermal macrophages (melanophages); the source of the melanin is the epidermis, and this typically results from inflammation at the dermal–epidermal junction.
- **Epidermal pigmentation**: denotes increased melanin within the epidermis, which typically leads to a light brown to dark brown color.
- **Dermal pigmentation**: denotes increased melanin in the dermis, primarily within melanophages; characteristically presents as a gray-blue to gray-brown color.

## Approach to Disorders of Hyperpigmentation

- Disorders of hyperpigmentation usually result from an increase in melanin production and occasionally from an increase in the density of active melanocytes.
- The clinical approach to these disorders is simplified by dividing them into four patterns, namely *circumscribed*, *diffuse*, *linear*, and *reticulated* (Fig. 55.1).
- The most common clinical pattern is *circumscribed*; observation of the sites of involvement, shape, configuration, and size can provide clues to the diagnosis.
- The dyschromatoses are discussed separately.

### Circumscribed Hyperpigmentation

- The three major entities in this category are postinflammatory hyperpigmentation, melasma, and drug-induced hyperpigmentation.

#### POSTINFLAMMATORY HYPERPIGMENTATION

- Represents an acquired excess of melanin pigment following cutaneous inflammation (e.g. acne, psoriasis) or injury (e.g. burns or friction).
- Depending on the disorder, postinflammatory hypopigmentation may also occur and is discussed in Chapter 54.
- Can occur anywhere on the body, including the mucosae or nail unit; increased pigmentation is localized to areas of inflammation and becomes more apparent once the associated erythema resolves (likened to "a shadow left behind").
- The preceding inflammation may be obvious, transient, or subclinical (Table 55.1; Fig. 55.2).
- The hyperpigmented macules and patches can range in color from light brown to dark brown (epidermal melanin) or gray-blue to gray-brown (dermal melanin).
- In general, postinflammatory epidermal pigmentation eventually resolves as long as the underlying disorder is treated effectively, but this may take months or even years; postinflammatory dermal pigmentation can be persistent.

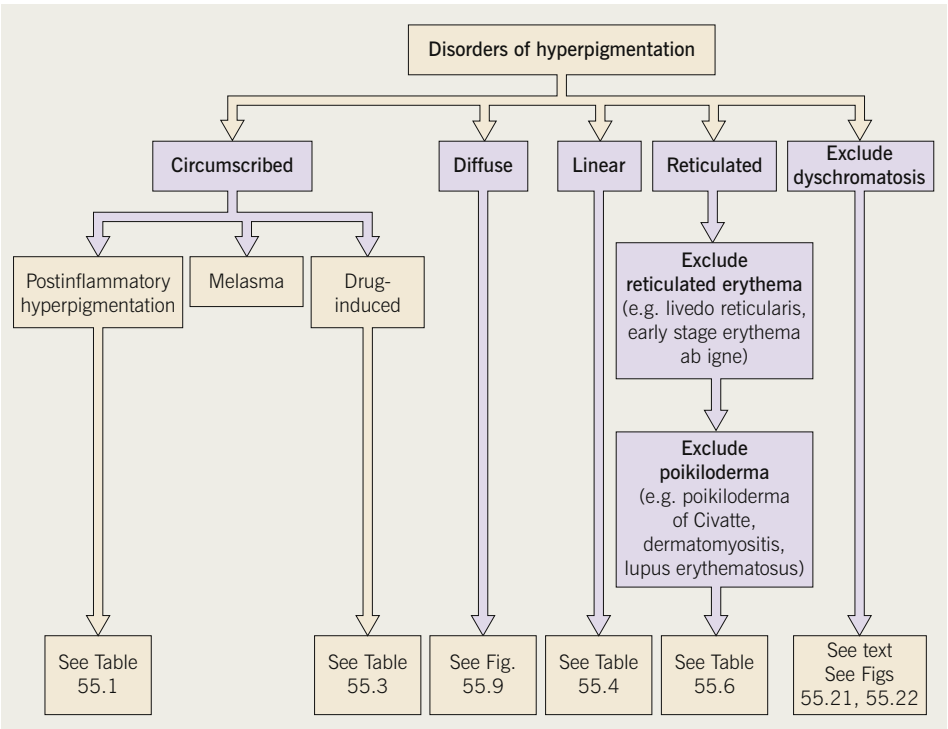


**Fig. 55.1 Approach to disorders of hyperpigmentation.**

- May also be exacerbated by UVR exposure, and photoprotection is an important part of treatment.
- **DDx:** see Table 55.1; occasionally a skin biopsy will assist in establishing the diagnosis.
- Causes of postinflammatory hyperpigmentation that often present without obvious prior inflammation include the following:
  - Primary (localized) cutaneous amyloidosis (see Ch. 39 and Figs 39.6 and 39.7)
  - Erythema dyschromicum perstans (EDP or ashy dermatosis) (see Ch. 9 and Figs 9.10 and 55.3A)
  - Lichen planus pigmentosus (LPP) (see Ch. 9, Table 9.1, and Figs 9.5G and 55.3B)
  - ***Mastocytosis*** (see Ch. 96 and Fig. 96.4)
  - ***Tinea (pityriasis) versicolor*** (see Chs 54 and 64 and Fig. 64.1)
  - ***Atrophoderma of Pasini and Pierini*** (see Ch. 82)
    - There is some debate as to whether this represents a distinct entity or is an end-stage (i.e. "burned-out" stage) of morphea
    - Typically seen in young healthy adults as several 3- to 6-cm, oval, hyperpigmented, minimally depressed patches on the posterior trunk
    - Lacks an inflammatory phase
    - **Rx:** In addition to treating the underlying inflammatory disorder and photoprotection, the following topical agents may be used: hydroquinone 2–4%; a combination of hydroquinone, tretinoin, and a low-strength CS; azelaic acid 15%; α-hydroxy acids (e.g. glycolic acid)

### MELASMA

- A very common, acquired disorder characterized by symmetric, hyperpigmented patches with irregular borders, resulting from an increase in epidermal and/or dermal melanin; favors the face (see below) > mid-upper chest and extensor forearms.

| DISORDERS ASSOCIATED WITH POSTINFLAMMATORY HYPERPIGMENTATION | |
|---|---|
| **Inflammatory disease** | **Clinical clues** |
| **Common** | |
| Acne vulgaris | Head/neck region, upper trunk; <1 cm; perifollicular |
| Atopic dermatitis | Atopic diathesis; face and extensor extremities in infants, then later flexural involvement; excoriations; atopic pleats; xerosis; lichenification; transverse nasal crease ("allergic salute") |
| Lichen simplex chronicus | Common locations: posterior neck, ankle, scrotum |
| Transient neonatal pustular melanosis (Fig. 55.2D) | Black newborns; pustules may precede pigmentation |
| Impetigo | Favors face; most common in children |
| Insect bites (Fig. 55.2A) | Favor exposed areas; usually <1 cm; lower extremities common with flea bites; clustered and sometimes linear patterns ("breakfast–lunch–dinner") |
| Linear trauma | Often a preceding history of trauma or injury; may have an angular or irregular shape or configuration |
| **Less common** | |
| Irritant and allergic contact and photocontact dermatitis (Fig. 55.2E) | Sites determined by etiologic agent and form of exposure; phytophotodermatitis leads to irregularly shaped or linear hyperpigmentation in sun-exposed areas |
| Pityriasis rosea | Favors trunk and proximal extremities; lesions follow skin cleavage lines; oval-shaped |
| Psoriasis (Fig. 55.2B) | Scalp/nail involvement; knees/elbows most common sites |
| Polymorphic light eruption | Extensor upper extremities, mid upper chest, face; seasonal (e.g. spring or early summer) |
| Discoid lupus erythematosus | Face and conchal bowls, with follicular plugging in latter site; oral lesions; in scarred lesions, central hypopigmentation with rim of hyperpigmentation |
| Lichen planus (LP) (Fig. 55.3B) | Wrists, shins, and presacral area in classic LP; face, neck and intertriginous sites in LP pigmentosus; nail/oral involvement |
| Erythema dyschromicum perstans* (EDP; ashy dermatosis) (Fig. 55.3A) | Neck, proximal upper extremities, trunk; round or oval in shape with gray-brown to blue-gray color; long axis can follow skin cleavage lines (similar to pityriasis rosea); less commonly observed in fair-skinned individuals |
| Idiopathic eruptive macular pigmentation* | Trunk, proximal extremities, neck, face; round or oval in shape with gray-brown to blue-gray color; barely elevated plaques with a subtle velvety texture; affects primarily children and adolescents; lasting months to years |
| Fixed drug eruption (Fig. 55.2C) | Circular; favors perioral, acral, and genital sites; recurrence at same site(s) with repeated exposure |
| Morbilliform drug eruption | Widespread; usually discrete lesions; history of drug exposure |
| Viral exanthem | Widespread; usually discrete lesions; history of associated symptoms |
| Morphea | Trunk or extremities; large-sized except in guttate variant; may be linear; induration and later dermal atrophy |
| Atrophoderma of Pasini and Pierini | Trunk; large-sized; depressed with "cliff sign" at periphery; no induration |
| Neurotic (psychogenic) excoriation, acne excoriée | Favors face, scalp, extensor surface of arms, upper back (reachable areas); linear or angular shapes; multiple stages of evolution, from erosions/ulcerations to scars |

**Typically no preceding inflammatory phase evident clinically or histopathologically.*

**Table 55.1 Disorders associated with postinflammatory hyperpigmentation.** Disorders in the blue rows are characterized by inflammation at the dermal-epidermal junction. Such inflammation can lead to dermal melanin within melanophages (pigment incontinence), which can be resistant to treatment and take longer to resolve. Most disorders result in epidermal hyperpigmentation and eventually resolve if the underlying disorder is treated effectively. *Adapted from Bolognia JL. Disorders of hypopigmentation and hyperpigmentation. In: Harper J, Oranje A, Prose N (Eds.), Textbook of Pediatric Dermatology, 2nd edn. Oxford: Blackwell Science, 2006;997–1040.*

- Seen primarily in women; increased prevalence in individuals with skin phototypes III–IV.
- Pathogenesis is thought to be related to hyperfunctional melanocytes that are stimulated by exacerbating factors, such as sun exposure and hormones (e.g. pregnancy, oral contraceptives).
- Three classic clinical patterns based on distribution: centrofacial (most common), malar, and mandibular (Fig. 55.4).
- Classically, melasma was also classified based on findings from Wood's lamp examination: lesions that enhance imply an increase in epidermal melanin and lesions that do not enhance imply an increase in dermal melanin; however, mixed epidermal and dermal melasma patterns are common.
- In northern latitudes, lesions tend to fade during the winter months; melasma tends to be more persistent in darkly pigmented individuals.
- **DDx:** postinflammatory hyperpigmentation, drug-induced (e.g. minocycline, amiodarone), acquired bilateral nevus of Ota-like macules (especially in Asian women), actinic lichen planus, pigmented contact dermatitis, exogenous ochronosis due to the application of hydroquinone-containing bleaching agents (Fig. 55.5), erythromelanosis faciei.
- These other disorders are distinguished from melasma based on historical aspects (e.g. drug ingestion, application of topical medications or cosmetics, previous inflammation), color (e.g. clusters of nevus of Ota-like macules are typically blue-gray in color), distribution pattern, histopathologic features, and primary lesions, if present.
- Treatment options are outlined in Table 55.2; typically, epidermal hyperpigmentation responds best to treatment.

#### DRUG-INDUCED CIRCUMSCRIBED HYPERPIGMENTATION AND DISCOLORATION

- A wide range of medications and chemicals can cause hyperpigmentation or discoloration in circumscribed, diffuse, and even linear patterns; longitudinal or horizontal melanonychia may also be present.
- The most common culprits of drug-induced circumscribed hyperpigmentation and discoloration are minocycline and the antimalarials (Table 55.3; Figs 55.5–55.8).
- The pathogenesis involves varying mechanisms, from increased melanin production to deposition of drug complexes or heavy metals within the dermis.
- The hyperpigmentation or discoloration typically resolves upon discontinuation of the offending drug, but the course may be prolonged.

### Diffuse Hyperpigmentation

- Diffuse hyperpigmentation has multiple causes, including drug-induced, metabolic and endocrine abnormalities, nutritional deficiencies, exposure to heavy metals, and inherited syndromes.
- May be accentuated in sun-exposed sites.
- An approach to the patient with diffuse hyperpigmentation is presented in Fig. 55.9.

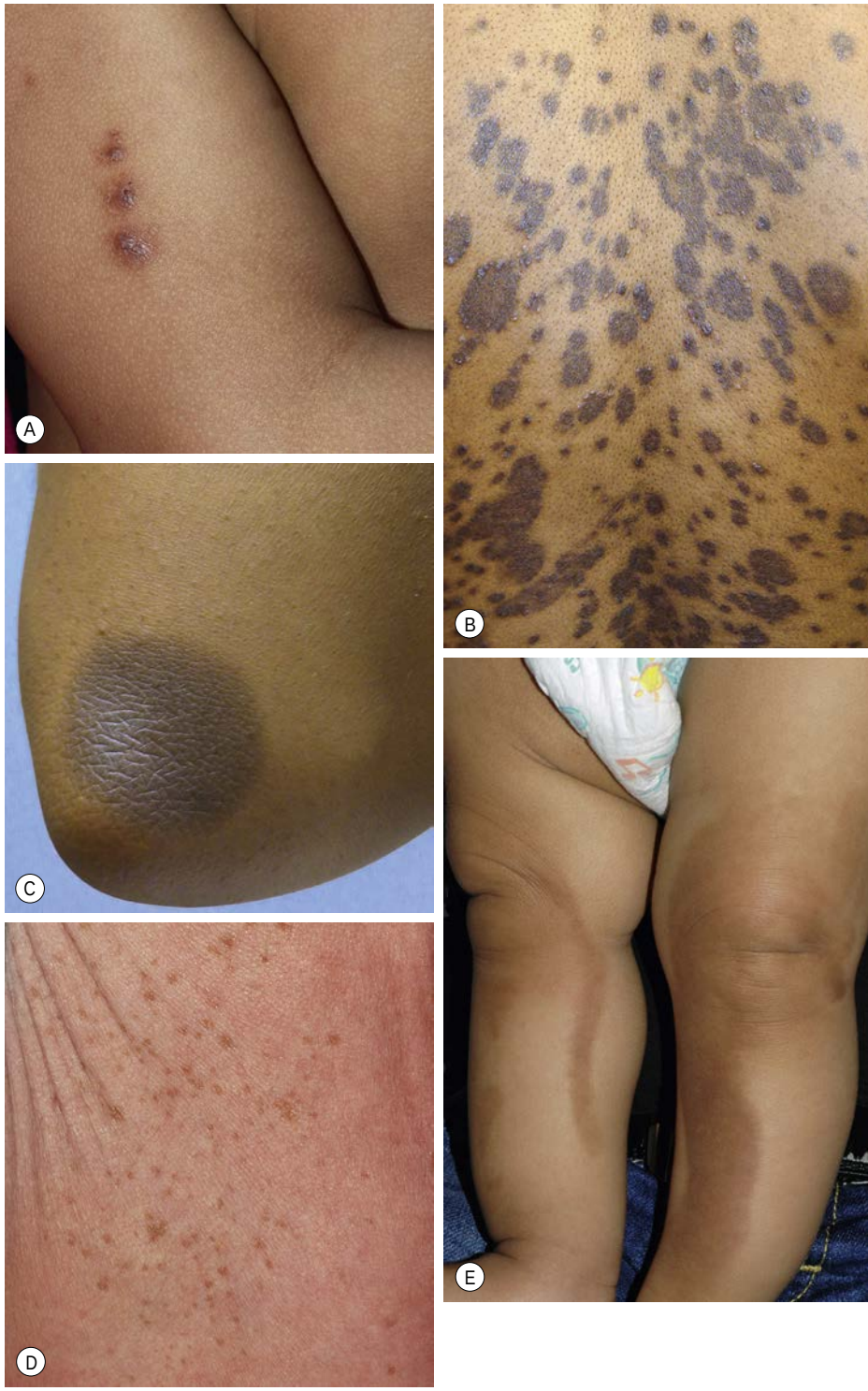


**Fig. 55.2 Epidermal postinflammatory hyperpigmentation.** The lesions were caused by insect bite reactions **(A)**, psoriasis **(B)**, a fixed drug eruption induced by trimethoprim–sulfamethoxazole **(C)**, and transient neonatal pustular melanosis **(D)**. Note the residual inflammation and "breakfast–lunch–dinner" configuration in **(A)**. **E** Linear epidermal postinflammatory hyperpigmentation due to phytophotodermatitis, which requires contact with a plant (e.g. lime) containing a photosensitizing chemical followed by UVR exposure. *A, D, E, Courtesy, Julie V. Schaffer, MD; B, C, Courtesy, Justin Finch, MD.*




**Fig. 55.3 Dermal postinflammatory hyperpigmentation. A** Erythema dyschromicum perstans (EDP or ashy dermatosis). Multiple gray-brown macules and patches on the abdomen. The "ashy" color is characteristic. **B** Lichen planus pigmentosus. Multiple coalescing brown to gray-brown macules in the axilla of a middle-aged woman. *A, Courtesy, NYUDSC; B, Courtesy, YDRSC.*

## Linear Hyperpigmentation

- Linear hyperpigmentation, like linear hypopigmentation (see Ch. 54), can result from multiple etiologies; one of the initial steps is determining if the lesions do or do not follow the lines of Blaschko (see Ch. 51).
- The differential diagnosis of linear hyperpigmentation is presented in Table 55.4 (Figs 55.10–55.16).

### HYPERPIGMENTATION ALONG THE LINES OF BLASCHKO AND IN OTHER MOSAIC PATTERNS

- Hyperpigmentation can follow the lines of Blaschko or have other mosaic patterns (e.g. block-like [see Ch. 51]).
- Hyperpigmented streaks along the lines of Blaschko has been termed ***"linear and whorled nevoid hypermelanosis" (LWNH)*** or linear nevoid hyperpigmentation, and they reflect pigmentary mosaicism (see Fig. 55.10).
- In a minority of patients, LWNH is associated with systemic abnormalities (e.g. CNS, musculoskeletal, or ocular); hyperpigmented streaks usually appear in infancy.
- Patients presenting with hypo- or hyperpigmented streaks along the lines of Blaschko can be approached in a similar fashion, with a physical examination and further evaluation (e.g. genetic) directed by clinical findings.
- Hyperpigmentation can also occur in a block-like configuration, also referred to as ***segmental pigmentation disorder*** (see Fig. 55.11); the **DDx** includes Becker melanosis (nevus) and segmental CALM, either isolated or syndromic (e.g. McCune–Albright syndrome [see Table 50.3]); in the latter, the CALM may be more geographic in configuration.

### LINEAR HYPERPIGMENTATION THAT IS NOT ALONG THE LINES OF BLASCHKO

- ***Pigmentary demarcation lines*** (see Fig. 55.14)
  - In humans, the dorsal skin surfaces are relatively hyperpigmented, compared to the ventral surfaces
  - In patients with darker pigmentation, visible lines of demarcation between dorsal and ventral surfaces are more apparent
  - These demarcation lines are present from infancy and persist throughout life; they are most prevalent on the anterolateral upper arm and posteromedial thigh (see Fig. 55.15)
  - Several forms of pigmentary demarcation lines exist and are presented in Table 55.5 and Fig. 55.14
- ***Flagellate pigmentation from bleomycin***
  - Occurs in ~10–20% of patients treated with systemic bleomycin
  - The pigmentation appears to be dose dependent but the pathogenesis is not well understood
  - Presents as linear hyperpigmented streaks on the chest, back, and occasionally extremities (see Fig. 55.16); typically in a configuration that suggests a relationship to scratching, but attempts to reproduce lesions by scratching have in general been unsuccessful; an erythematous phase, which is typically pink in light-skinned individuals, can precede the hyperpigmentation




**Fig. 55.4 Various forms of melasma and melasma-like hyperpigmentation.** **A** Malar variant. **B** Mild centrofacial type with sparing of the philtrum. **C** Extension of the hyperpigmentation onto the mandible. **D** Involvement of the extensor forearm; note the same irregular outline as seen on the face. **E** Melasma-like appearance in a patient with previous acute cutaneous lupus erythematosus.
*A, B, Courtesy, NYUDSC; C–E, Courtesy, Jean L. Bolognia, MD.*

| SELECTED TREATMENT OPTIONS FOR MELASMA |
|---|
| **Recommendations for all patients** |
| • Avoidance of sun exposure and tanning beds<br>• Daily use of broad-spectrum sunscreen (ideally SPF ≥30 with physical blocker such as zinc oxide or titanium dioxide)<br>• Sun-protective hats and clothing<br>• Camouflage makeup<br>• Discontinue oral contraceptives, if possible |
| **Active/intense treatment options*,**** |
| **First-line topical therapies** |
| • Triple combination of HQ + retinoid + CS† at bedtime<br>• 4% HQ daily, typically at bedtime<br>• Azelaic acid (15–20%) |
| **Adjunctive topical therapy** |
| • L-ascorbic acid (10–15%)<br>• Kojic acid (1–4%)<br>• Tranexamic acid (2–5%) |
| **Second-line therapies** |
| • Glycolic (typically start at 30% and increase as tolerated) or salicyclic acid (20–30%) peels every 4–6 weeks |
| **Third-line therapies‡** |
| • Laser (e.g. fractional) and intense pulsed light therapy (IPL) |
| **Long-term maintenance recommendations** |
| • Daily sunscreen and sun protective measures (see above)<br>• Topical retinoid<br>• Topical α-hydroxy acid (e.g. glycolic acid cream)<br>• Other topicals (e.g. L-ascorbic acid [10–15%], azelaic acid [15–20%], kojic acid [1–4%], tranexamic acid [2–5%]) |
| **Results from topical treatments may take up to 6 months to appreciate; depending on the patient, HQ and combination HQ + retinoid + CS are typically used daily for 2–4 months and then decreased in frequency to 1–2 times per week; prolonged daily use can result in side effects such as perioral dermatitis, telangiectasias, atrophy (CS) and ochronosis (HQ; see Fig. 55.5).*<br>***While topical HQ can cause an allergic contact dermatitis, all topical agents may cause an irritant contact dermatitis, which can result in worsening of the dyspigmentation; if this is a concern, a small, non-facial site test can be performed prior to widespread facial application.*<br>*†Typically a Class 5–7 topical CS is used (see Appendix).*<br>*‡Potential risk of post-procedural dyspigmentation; a site test should be performed prior to widespread facial laser or light therapy.* |

**Table 55.2 Selected treatment options for melasma.** HQ, hydroquinone.

  - The hyperpigmentation is usually reversible once the bleomycin is discontinued, but it may take 3–4 months to fade
  - Other skin findings can include circumscribed hyperpigmentation overlying the small joints of the hands as well as sclerodermoid changes
- ***Flagellate mushroom dermatitis***
  - Occurs after eating large amounts of raw or partially cooked shiitake mushrooms
  - A second form occurs in persons who cultivate shiitake mushrooms
  - Presents initially with pruritic papules and vesicles that develop on the face, scalp, trunk, and proximal extremities; scratching of these lesions then leads to long, flagellate streaks composed of petechiae or papules, followed finally by linear patterns of discoloration (due to hemosiderin) or postinflammatory hyperpigmentation

### LINEAR HYPERPIGMENTATION THAT MAY OR MAY NOT BE ALONG THE LINES OF BLASCHKO

- ***Linear postinflammatory hyperpigmentation***
  - More common in individuals with darkly pigmented skin
  - Occurs after linear trauma (e.g. burn, abrasion, dermatitis artefacta) and along

| DRUGS AND CHEMICALS ASSOCIATED WITH CIRCUMSCRIBED HYPERPIGMENTATION OR DISCOLORATION | |
|---|---|
| **Drug or chemical** | **Clinical features** |
| **Chemotherapeutic agents** | |
| Mechlorethamine (nitrogen mustard) | • Hyperpigmentation at sites of topical application |
| Bleomycin (intravenous or intralesional) | See text |
| Anthracyclines (e.g. daunorubicin, doxorubicin) | • Hyperpigmentation of sun-exposed areas<br>• Hyperpigmentation overlying the small joints of the hand and involving the palms (especially the creases), soles, and oral mucosa (buccal, tongue)<br>• Transverse brown-black melanonychia |
| 5-Fluorouracil | • Hyperpigmentation in sun-exposed areas (~5% of patients treated systemically; often follows an erythematous photosensitivity reaction)<br>• Hyperpigmentation of skin overlying veins in which the drug was infused<br>• Other sites include the dorsal aspects of the hands, palms/soles, and radiation ports<br>• Transverse or diffuse melanonychia; lunular pigmentation |
| **Antimalarials** | |
| Chloroquine, hydroxychloroquine, quinacrine | • Gray to blue-black discoloration, usually pretibial, with (hydroxy) chloroquine; face, hard palate, sclerae, and subungual areas may be involved<br>• Diffuse yellow to yellow-brown discoloration with quinacrine<br>• Discoloration affects up to 25% of patients |
| **Heavy metals** | |
| Arsenic (see Ch. 74) | • Areas of bronze hyperpigmentation ± superimposed "raindrops" of lightly pigmented skin; favors axillae, groin, palms, soles, nipples, and pressure points (see Fig. 74.7A) |
| Bismuth | • Generalized blue-gray discoloration of the face, neck, and dorsal hands<br>• Oral mucosa and gingivae may be involved |
| Gold (chrysiasis) | • Permanent blue-gray discoloration in sun-exposed areas, mostly around the eyes |
| Iron | • Permanent brown discoloration at injection sites or in areas of application of ferric subsulfate (Monsel's) solution as a hemostatic agent<br>• Dermal hemosiderin deposits (due to lysis of extravasated red blood cells and release of their iron stores) are commonly observed in the setting of venous hypertension, in pigmented purpuric dermatoses, at sites of previous solar purpura, and as a side effect of sclerotherapy of superficial veins |
| Lead | • "Lead line" in gingival margin<br>• Nail discoloration |
| Mercury | • Slate-gray discoloration, particularly in skin folds |

**Table 55.3 Drugs and chemicals associated with circumscribed hyperpigmentation or discoloration.** *Continued*

| DRUGS AND CHEMICALS ASSOCIATED WITH CIRCUMSCRIBED HYPERPIGMENTATION OR DISCOLORATION | |
|---|---|
| **Drug or chemical** | **Clinical features** |
| Silver (argyria) | • Sites of topical application (e.g. of silver sulfadiazine to burns or ulcers)<br>• Diffuse slate-gray discoloration, increased in sun-exposed areas; occurs in settings of occupational exposure, alternative medications, or systemic absorption from use of silver sulfadiazine on extensive burns/wounds<br>• The nail unit (diffuse or localized to the lunulae) and sclerae may also be affected |
| **Hormones** | |
| Oral contraceptives, hormone replacement therapy | • Melasma; increased pigmentation of nipples and nevi |
| **Miscellaneous compounds** | |
| Amiodarone | • Slate-gray to violaceous discoloration of sun-exposed skin, especially the face (less common than erythema from photosensitivity)<br>• Fair-skinned patients after long-term, continuous therapy; usually fades over months to years after discontinuation of the drug, but may persist |
| Azidothymidine (zidovudine, AZT) | • Longitudinal > transverse and diffuse melanonychia (up to 10% of patients); blue lunulae<br>• Mucocutaneous hyperpigmentation (e.g. widespread diffuse, acral, oral macules); most common in patients with darkly pigmented skin, and may be accentuated in areas of friction or sun exposure |
| Clofazimine | • Violet-brown to blue-gray discoloration, especially lesional skin (Fig. 55.7)<br>• Diffuse red to red-brown discoloration of skin, conjunctivae |
| Diltiazem | • Slate-gray to gray-brown discoloration of sun-exposed skin in patients with skin phototypes IV–VI (see Fig. 73.12); perifollicular accentuation and a reticular pattern may be observed |
| Hydroquinone | See text and Fig. 55.5 |
| Minocycline | • *Type I:* blue-black discoloration in sites of inflammation and scars, including those due to acne (Fig. 55.8C)<br>• *Type II:* blue-gray macules/patches (1 mm–10 cm in size) within previously normal skin, most often on the shins (Fig. 55.8A,B); sometimes misdiagnosed as ecchymoses<br>• *Type III:* diffuse "muddy brown" pigmentation that is most prominent in sun-exposed areas<br>• Blue-black discoloration may also involve nails, sclerae, oral mucosa, bones, thyroid, and teeth |
| Psychotropic drugs (e.g. chlorpromazine, amitriptyline) | • Slate-gray discoloration in sun-exposed areas |

**Table 55.3** *Continued* **Drugs and chemicals associated with circumscribed hyperpigmentation or discoloration.** Additional drugs include busulfan (causes more diffuse hyperpigmentation), hydroxyurea (hyperpigmentation over pressure points and mucosal [see Fig. 55.6], melanonychia), methotrexate (sun-exposed sites), imatinib (localized or diffuse, may involve nails and mucosa). Diffuse hyperpigmentation and discoloration is discussed in Fig. 55.9.



**Fig. 55.5 Exogenous ochronosis secondary to topical hydroquinone.** This cause of progressive darkening is seen more commonly in Africa. *Courtesy, Regional Dermatology Training Centre, Moshi, Tanzania.*



**Fig. 55.6 Hydroxyurea-induced hyperpigmentation of the oral mucosa.** Circumscribed hyperpigmented macules on the dorsal tongue. *Courtesy, Brian Horvath, MD.*

veins (e.g. phlebitis, intravenous drug abuse, systemic sclerosis); also follows linear inflammatory dermatoses, most often allergic contact dermatitis due to plants (e.g. poison ivy/oak dermatitis) or phytophotodermatitis, which requires both plant exposure and UVR (see Fig. 55.2E)

- Occasionally, postinflammatory hyperpigmentation may follow the lines of Blaschko due to the configuration of the antecedent inflammatory dermatosis (e.g. linear lichen planus, Blaschkitis)



**Fig. 55.7** Blue-violet discoloration of previous leprosy lesions in a patient treated with clofazimine. *Courtesy, Anne Burdick, MD.*

### Reticulated Hyperpigmentation

- Disorders characterized by true reticulated macular hyperpigmentation are unusual and are primarily rare genodermatoses (Table 55.6; Figs 55.17–55.20).
- It is more common to encounter disorders where the reticulated hyperpigmentation represents just one of several components; as an example, confluent and reticulated papillomatosis (CARP) of Gougerot and Carteaud also has papillomatosis and slight hyperkeratosis (see Fig. 55.17).
- In addition, it is necessary to exclude cutaneous disorders characterized by reticulated erythema (e.g. livedo reticularis) or poikiloderma (e.g. poikiloderma of Civatte).
- Reticulated hyperpigmentation can also correspond to the pattern of the venous plexus (e.g. later stage of erythema ab igne); the clinical clue is a wider spacing than in genodermatoses.

## Dyschromatoses

- The dyschromatoses are characterized by the presence of both hypo- and hyperpigmentation; often at least one component of the dyspigmentation is guttate in configuration.
- These disorders can be divided into three groups:
  - *Genetic* (e.g. dyschromatosis symmetrica hereditaria [Fig. 55.21] and dyschromatosis universalis hereditaria [Fig. 55.22])

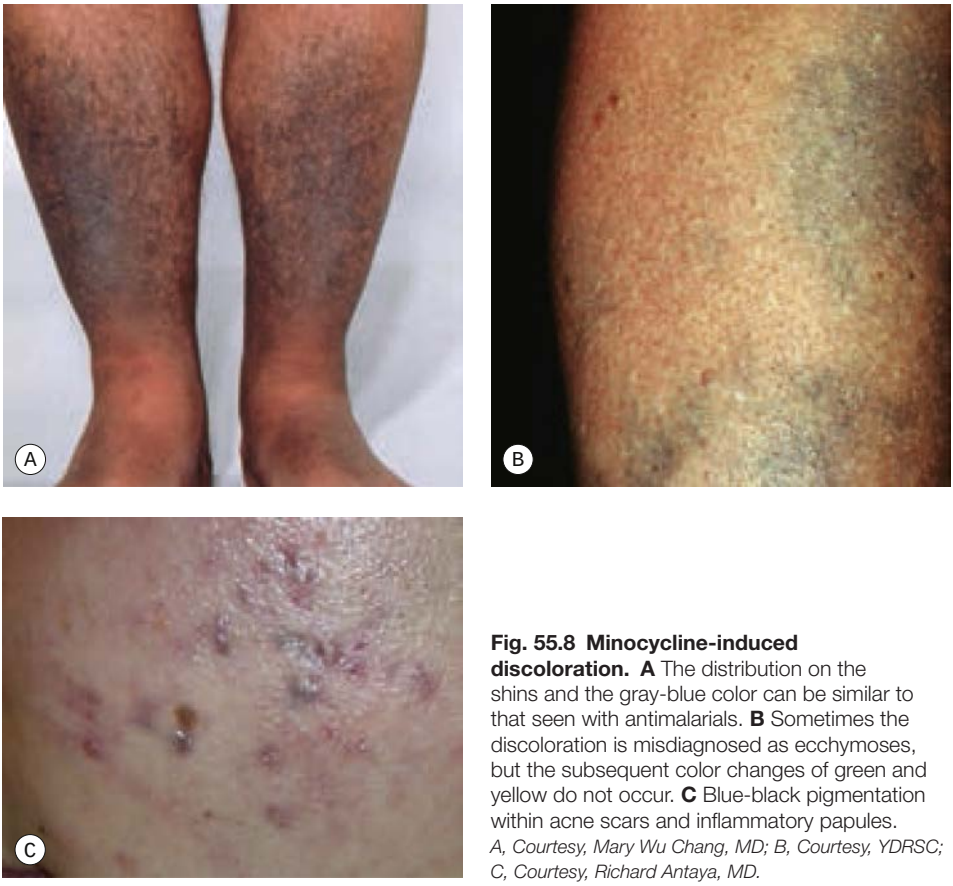

**Fig. 55.8 Minocycline-induced discoloration. A** The distribution on the shins and the gray-blue color can be similar to that seen with antimalarials. **B** Sometimes the discoloration is misdiagnosed as ecchymoses, but the subsequent color changes of green and yellow do not occur. **C** Blue-black pigmentation within acne scars and inflammatory papules. *A, Courtesy, Mary Wu Chang, MD; B, Courtesy, YDRSC; C, Courtesy, Richard Antaya, MD.*

  - *Exposure-induced* (e.g. arsenic [see Fig. 74.7A], monobenzyl ether of hydroquinone [MBEH], diphenylcyclopropenone [DPCP], betel leaf)
  - *Infection-related* (e.g. secondary syphilis, pinta [see Ch. 61])
- There is also a variant of cutaneous amyloidosis that is dyschromic.

For further information see Ch. 67 from *Dermatology, Fourth Edition*.

**For additional online figures and tables visit www.expertconsult.com**

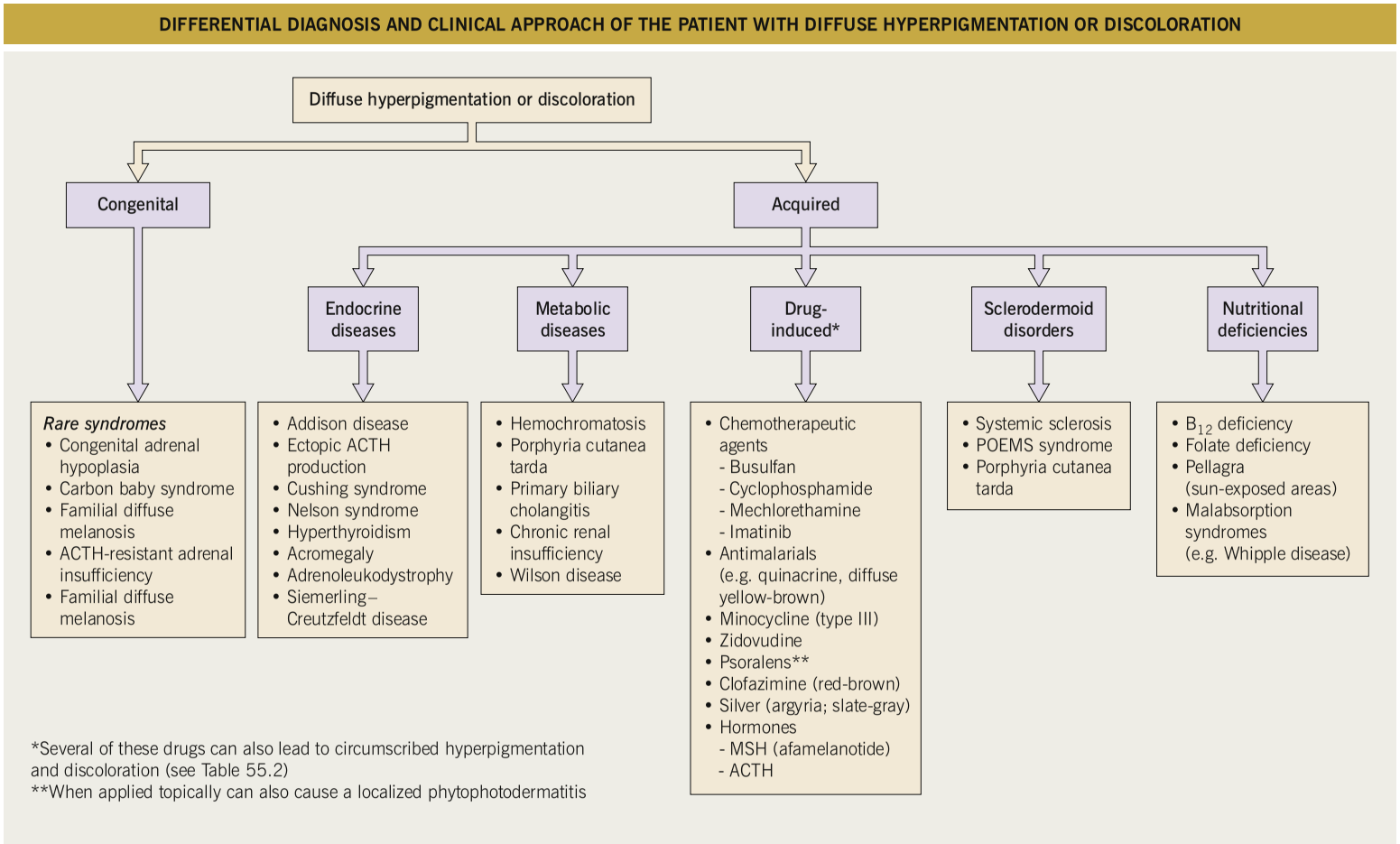


**Fig. 55.9 Differential diagnosis and clinical approach of the patient with diffuse hyperpigmentation or discoloration.** ACTH, adrenocorticotropic hormone; MSH, melanocyte stimulating hormone; POEMS, *p*olyneuropathy, *o*rganomegaly, *e*ndocrinopathy, *m*onoclonal gammopathy, and skin changes.

| DISORDERS WITH LINEAR HYPERPIGMENTATION |
|---|
| **Follows the lines of Blaschko** |
| *Inherited/early onset* |
| Linear and whorled nevoid hypermelanosis ("pigmentary mosaicism"*; see Fig. 55.10) |
| Early or subtle epidermal nevus |
| Third stage of incontinentia pigmenti** (see Fig. 55.12) |
| X-linked reticulate pigmentary disorder** |
| Focal dermal hypoplasia** (Goltz syndrome; hyperpigmented macules within linear streaks, along with cribriform dermal atrophy, fat "herniation", hypopigmentation, and/or telangiectasias) |
| X-linked hypohidrotic ectodermal dysplasia** |
| Conradi–Hünermann–Happle syndrome** |
| Café-au-lait macules of McCune–Albright syndrome (more often broad bands or block-like) |
| Chimerism (more often block-like or ill-defined pattern) |
| *Acquired/often later onset* |
| Linear lichen planus, lichen planus pigmentosus, erythema dyschromicum perstans, or fixed drug eruption |
| Linear atrophoderma of Moulin (see Fig. 55.13), possibly linear morphea |
| Postinflammatory hyperpigmentation due to Blaschkitis |
| Linear biphasic cutaneous amyloidosis‡ |
| **Does *not* follow the lines of Blaschko** |
| Pigmentary dermarcation lines (see Figs 55.14 and 55.15, Table 55.5) |
| Linea nigra (Fig. 22.7B) |
| Phytophotodermatitis (see Fig. 55.2E) |
| Sock- or mitten-line hyperpigmentation |
| Flagellate hyperpigmentation – e.g. from bleomycin (see Fig. 55.16), shiitake mushroom dermatitis, dermatomyositis, persistent plaques of Still disease |
| Serpentine supravenous hyperpigmentation, e.g. from phlebitis, intravenous drug use, systemic sclerosis |
| Additional causes of linear postinflammatory hyperpigmentation – excoriations, trauma/abuse, burns, allergic contact dermatitis (especially to plants), koebnerized lesions (e.g. psoriasis, lichen planus), coining |

**Pigmentary mosaicism can also present with hyperpigmentation in a block-like pattern, referred to as segmental pigmentation disorder (see Fig. 55.11).*
***Primarily in female patients, due to functional mosaicism (via lyonization) in these X-linked disorders; occasionally in male patients with somatic mosaicism or Klinefelter syndrome.*
*‡Single case.*

**Table 55.4 Disorders with linear hyperpigmentation.**



**Fig. 55.10 Linear and whorled nevoid hypermelanosis (LWNH) on the trunk.** This young African-American girl had developmental delay. Note the distribution along the lines of Blaschko. *Courtesy, Julie V. Schaffer, MD.*



**Fig. 55.11 Segmental pigmentation disorder.** Unilateral block-like hyperpigmentation on the chest, abdomen and upper arm of an infant. Note the midline demarcation inferiorly. *Courtesy, Julie V. Schaffer, MD.*



**Fig. 55.12 Stage 3 incontinentia pigmenti in a 2-year-old child.** Note the characteristic gray-brown color, and the distribution along the lines of Blaschko. *Courtesy, Julie V. Schaffer, MD.*



**Fig. 55.13 Linear hyperpigmentation due to atrophoderma of Moulin.** Note the subtle depression of the lesions. *Courtesy, Antonio Torrelo, MD.*

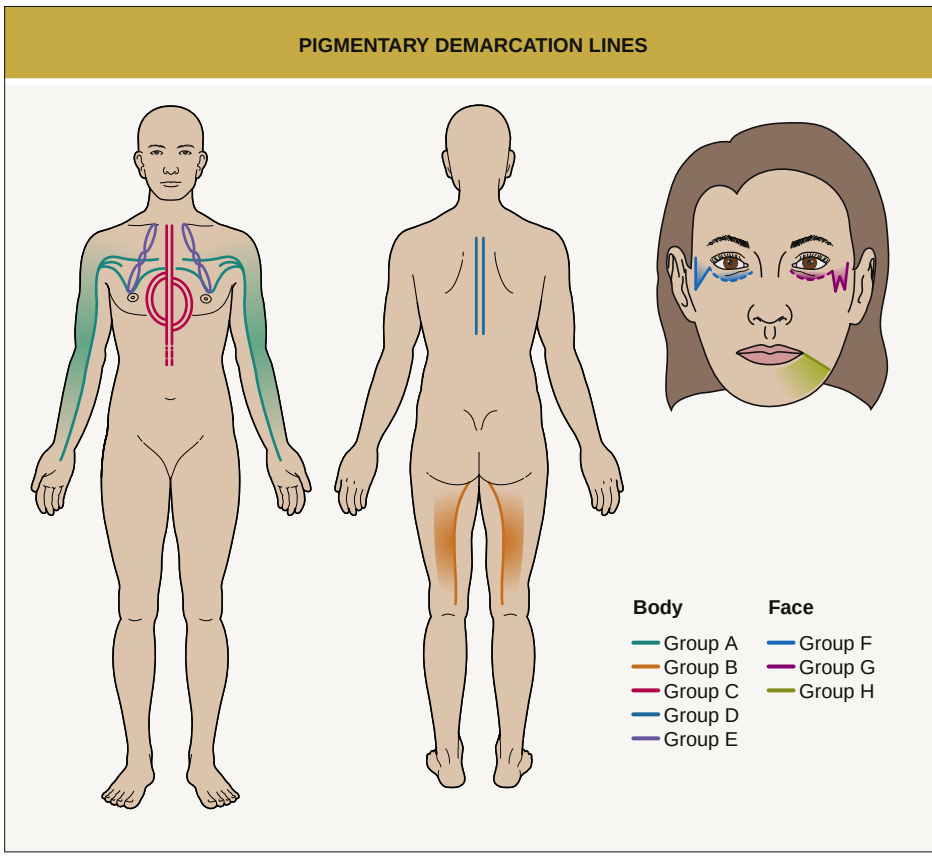


**Fig. 55.14 Pigmentary demarcation lines.**

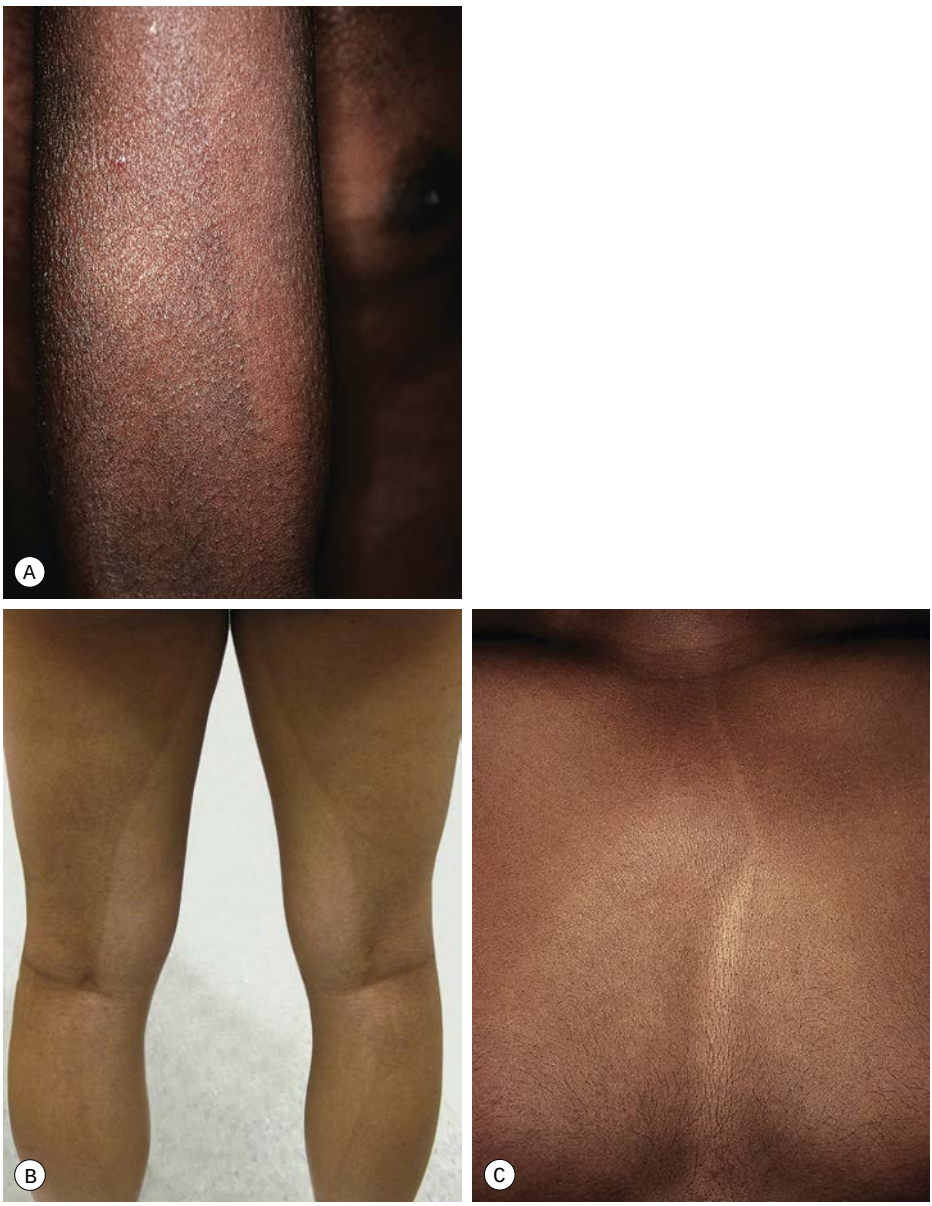


**Fig. 55.15 Pigmentary demarcation lines (PDLs). A** The most common PDL (Type A) is on the upper arm, with relative hypopigmentation on the ventral surface. **B** Type B PDLs on the posterior thighs, with relative hypopigmentation medially. **C** Type C PDL (composed of parallel lines) may be confused with linear nevoid hypopigmentation. *A, C, Courtesy, Jean L. Bolognia, MD; B, Courtesy, Justin Finch, MD.*

| PIGMENTARY DEMARCATION LINES: FIVE MAJOR TYPES (A-E) AND PROPOSED FACIAL TYPES (F-H) | |
|---|---|
| **Type** | **Description** |
| A | A vertical line along the anterolateral portion of the upper arm that may extend into the pectoral region (most commonly observed type; see Fig. 55.15A ) |
| B | A curved line on the posteromedial thigh that extends from the perineum to the popliteal fossa and occasionally to the ankle (see Fig. 55.15B) |
| C | A vertical or curved hypopigmented band on the mid chest that results from two parallel pigmentary demarcation lines (see Fig. 55.15C) |
| D | A vertical line in a pre- or paraspinal location |
| E | Bilateral chest markings (hypopigmented macules and patches) in a zone that runs from the mid third of the clavicle to the periareolar skin |
| F&G | "V"- or "W"-shaped lines between the lateral temple and malar prominence; a curved line may extend medially in the infraorbital area |
| H | A diagonal line from the angle of the mouth to the lateral aspect of the chin |

**Table 55.5 Pigmentary demarcation lines: five major types (A–E) and proposed facial types (F–H).** Also see Fig. 55.14.



**Fig. 55.16 Flagellate pigmentation.** This young man had received bleomycin as a treatment for his lymphoma. Note the linear excoriations. *Courtesy, David E. Cohen, MD, MPH.*

| DISORDERS CHARACTERIZED BY RETICULATED HYPERPIGMENTATION | |
|---|---|
| **Disorder** | **Key features** |
| **Reticulated hyperpigmentation with additional cutaneous features** | |
| **Confluent and reticulated papillomatosis (CARP) of Gougerot and Carteaud** (Fig. 55.17) | • Elevated, favors neck and upper trunk; treated with minocycline<br>• Often appears during adolescence |
| **Erythema ab igne** (later stage) (Fig. 74.3) | • Widely spaced net that corresponds to vascular pattern<br>• Due to heat injury, including from heating pads (back) or laptop computer batteries (anterior thighs) |
| Atopic dirty neck | • Anterolateral neck<br>• Favors children |
| Epidermolysis bullosa simplex (EBS) herpetiformis (Dowling–Meara) and EBS with mottled pigmentation* | • "Mottled" appearance; AD, due to *KRT 5/14* mutations<br>• Onset during early childhood |
| Prurigo pigmentosa | • Typically young Asian (primarily Japanese) women<br>• Favors the back, neck, and chest<br>• Recurrent crops of pruritic papulovesicles that resolve with a reticulated pattern of hyperpigmentation |
| **True reticulated macular hyperpigmentation – onset in infancy or early childhood** | |
| X-linked reticulate pigmentary disorder | • XLR, due to *POLA1* mutations<br>• *Males* present with generalized reticulated pigmentation, neonatal colitis, recurrent pneumonia, hypohidrosis, photophobia, ± amyloid deposits in adults<br>• *Female carriers* present with hyperpigmented streaks along lines of Blaschko |
| Dyskeratosis congenita* (Fig. 55.18) | • XLR form more common than AD and AR forms<br>• ~50% due to mutations in the *TERT*, *TERC*, *DKC1*, or *TINF2* genes<br>• Pterygium, leukoplakia, pancytopenia, mucosal squamous cell carcinoma, leukemia |
| Fanconi anemia* | • AR, with at least 11 complementation groups; rarely XLR<br>• More diffuse hyperpigmentation, radial ray bony defects, pancytopenia, leukemia |
| Dermatopathia pigmentosa reticularis (Fig. 55.19) | • AD; due to *KRT14* mutations<br>• Persistent hyperpigmentation, alopecia, nail dystrophy; absent dermatoglyphics in some patients |
| Naegeli–Franceschetti–Jadassohn syndrome | • AD; due to *KRT14* mutations<br>• Fading hyperpigmentation, hypohidrosis, dental anomalies, palmoplantar hyperkeratosis, reduced/missing dermatoglyphics, nail dystrophy |
| **True reticulated macular hyperpigmentation – onset in adolescence or adulthood** | |
| Dowling–Degos disease (DDD) (Fig. 55.20) | • AD; due to mutations in *KRT5, POFUT1,* and *POGLUT1*<br>• Reticulated hyperpigmentation of major flexures, comedones on the back and neck, pitted facial scars |
| Galli–Galli disease | • Acantholytic variant of DDD |
| Haber syndrome | • Rosacea-like facial eruption plus the clinical features of DDD |
| Pigmentatio reticularis faciei et colli | • Possible variant of DDD<br>• Hyperpigmentation of the face and neck plus multiple epidermoid cysts |
| Reticulate acropigmentation of Kitamura | • AD; due to *ADAM10* mutations<br>• Atrophic, acral lentigo-like lesions, palmoplantar and dorsal phalangeal pitting |

*Also dyschromatosis.

**Table 55.6 Disorders characterized by reticulated hyperpigmentation. The two most common disorders are in bold.** Additional disorders include Mendes da Costa disease*, Cantu syndrome, reticulate genital hyperpigmentation associated with localized vitiligo*, and mitochondrial disorders. AD, autosomal dominant; *ADAM10, a d*isintegrin *a*nd *m*etalloproteinase *10*; AR, autosomal recessive; *KRT5/14,* keratin 5 or 14; *POFUT1,* protein O-fucosyltransferase 1; *POGLUT1,* protein O-glucosyltransferase 1; *POLA1,* DNA polymerase-α 1, catalytic subunit; XLR, X-linked recessive.

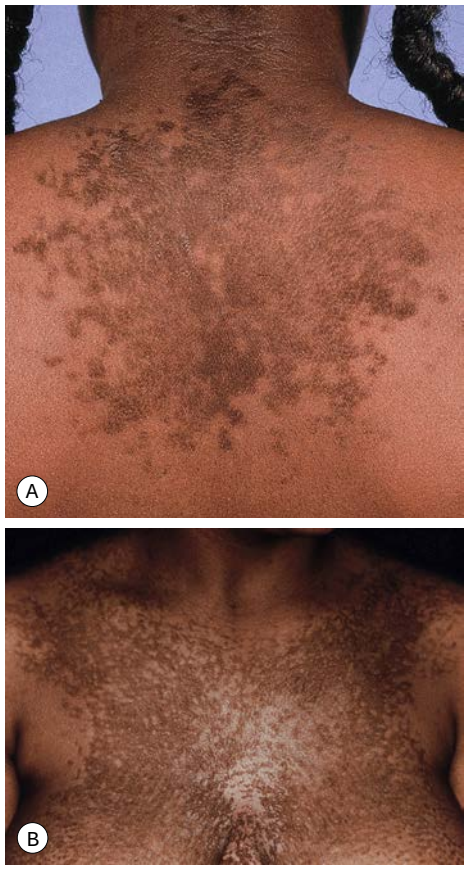


**Fig. 55.17 Confluent and reticulated papillomatosis of Gougerot and Carteaud. A** On the neck and back of a teenage girl. **B** On the chest of an older woman. *A, Courtesy, Seth Orlow, MD, PhD; B, Courtesy, YDRSC.*




**Fig. 55.18 Dyskeratosis congenita. A** Reticulated hyperpigmentation on the chest and neck of a teenage boy. **B** More pronounced reticulated and confluent hyperpigmentation on the shoulder and axilla. **C** Longitudinal ridging, splitting, and early pterygium formation in another teenage boy. *A, Courtesy, Seth Orlow, MD, PhD; B, Courtesy, Eugene Mirrer, MD; C, Courtesy, Anthony Mancini, MD.*



**Fig. 55.19 Dermatopathia pigmentosa reticularis.** Persistent hyperpigmentation in a reticulated pattern extending from the lower abdomen to the thigh in a young man. *Courtesy, Julie V. Schaffer, MD.*



**Fig. 55.21 Dyschromatosis symmetrica hereditaria.** An autosomal dominant disorder characterized by mutations in *ADAR* (*DSRAD)* (encodes an adenosine deaminase) and mixed hypo- and hyperpigmentation on the distal hands and feet. Note that the hands are more involved than the forearms. *Courtesy, Peter Ehrnstrom, MD.*



**Fig. 55.20 Dowling–Degos disease.** Hyperpigmented macules forming a reticulated pattern in the axilla. *Courtesy, Thomas Schwarz, MD.*

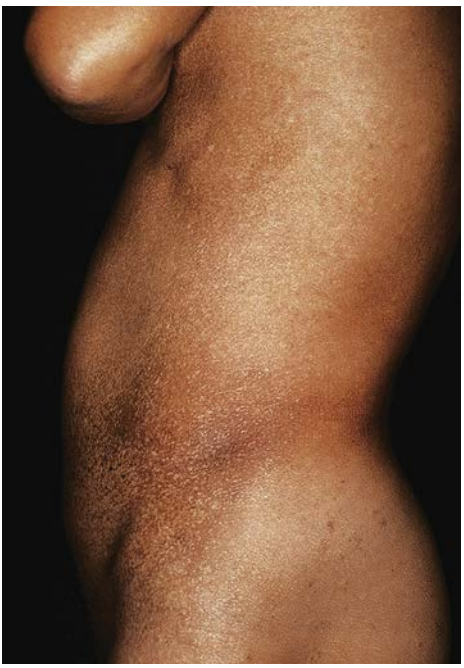

**Fig. 55.22 Dyschromatosis universalis hereditaria.** Widespread distribution of both hypo- and hyperpigmented macules. *With permission from Urabe K, Hori Y. Dyschromatosis. Semin Cutan Med Surg 1997;16:81–5.*










**eFig. 55.1 Postinflammatory hyperpigmentation (PIH).** The lesions were caused by pemphigus foliaceus (**A**) and phytophotodermatitis (**B, C**), which requires contact with a plant (e.g. lime) containing a photosensitizing chemical followed by UVR exposure. The desquamation is at the site of a previous bulla in **B**. In **C** the hyperpigmented streaks developed on the arms of this mother and her toddler son following contact with citrus juice on a sunny day. *A, Courtesy, Julie V. Schaffer, MD; B, Courtesy, USCDRSC; C, Courtesy, Mary Wu Chang, MD.*

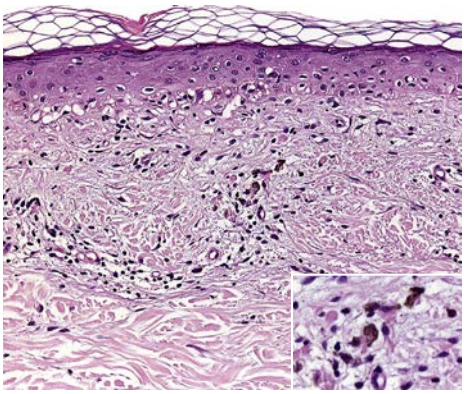

**eFig. 55.2 Histopathology of erythema dyschromicum perstans (ashy dermatosis).** Vacuolar degeneration of the basal layer, a sparse perivascular lymphocytic infiltrate, and prominent dermal melanophages (see inset). *Courtesy, Lorenzo Cerroni, MD.*

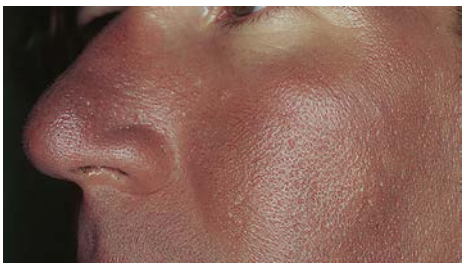

**eFig. 55.3 Gray-violet discoloration of the face due to amiodarone.** Note the sparing of the lower eyelid. *Courtesy, Jean L. Bolognia, MD.*



**eFig. 55.4 Argyria.** Diffuse slate-gray discoloration of the palms. *Courtesy, Mary Beth Cole, MD.*



**eFig. 55.5 Linear hyperpigmentation due to atrophoderma of Moulin.** Note the subtle depression of the lesions. *Courtesy, Jean L. Bolognia, MD.*



**eFig. 55.6 Dermatitis artefacta resulting in linear postinflammatory hyperpigmentation of the forehead.** The lesions were due to excoriations. *Courtesy, Mary Wu Chang, MD.*

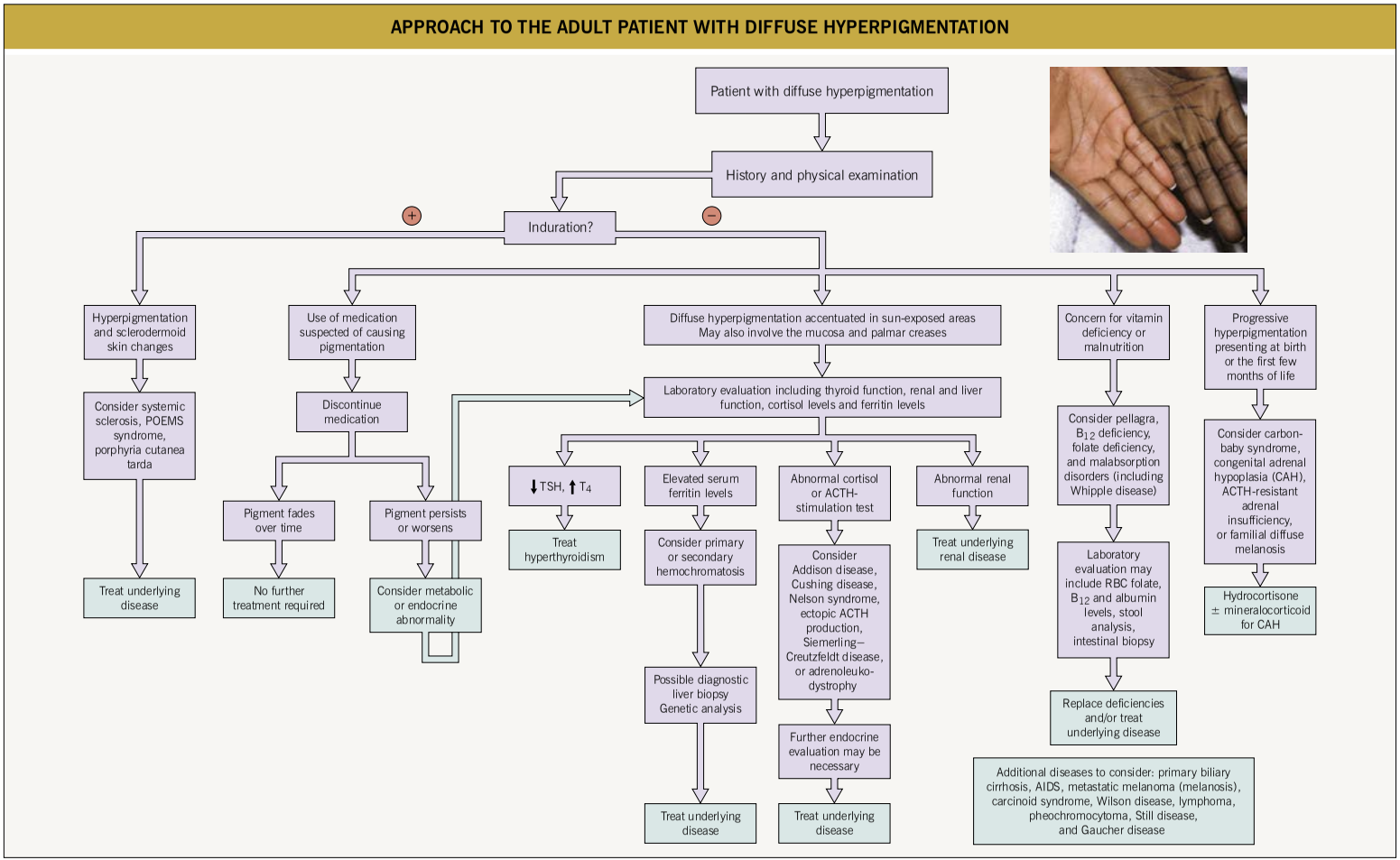


**eFig. 55.7 Approach to the adult patient with diffuse hyperpigmentation.** The palm on the right hand of the inset photograph shows diffuse hyperpigmentation in a patient with POEMS syndrome (*p*olyneuropathy, *o*rganomegaly, *e*ndocrinopathy, *m*onoclonal gammopathy, and *s*kin lesions). ACTH, adrenocorticotrophic hormone; T4, thyroxine. *Courtesy, Mary Wu Chang, MD.*

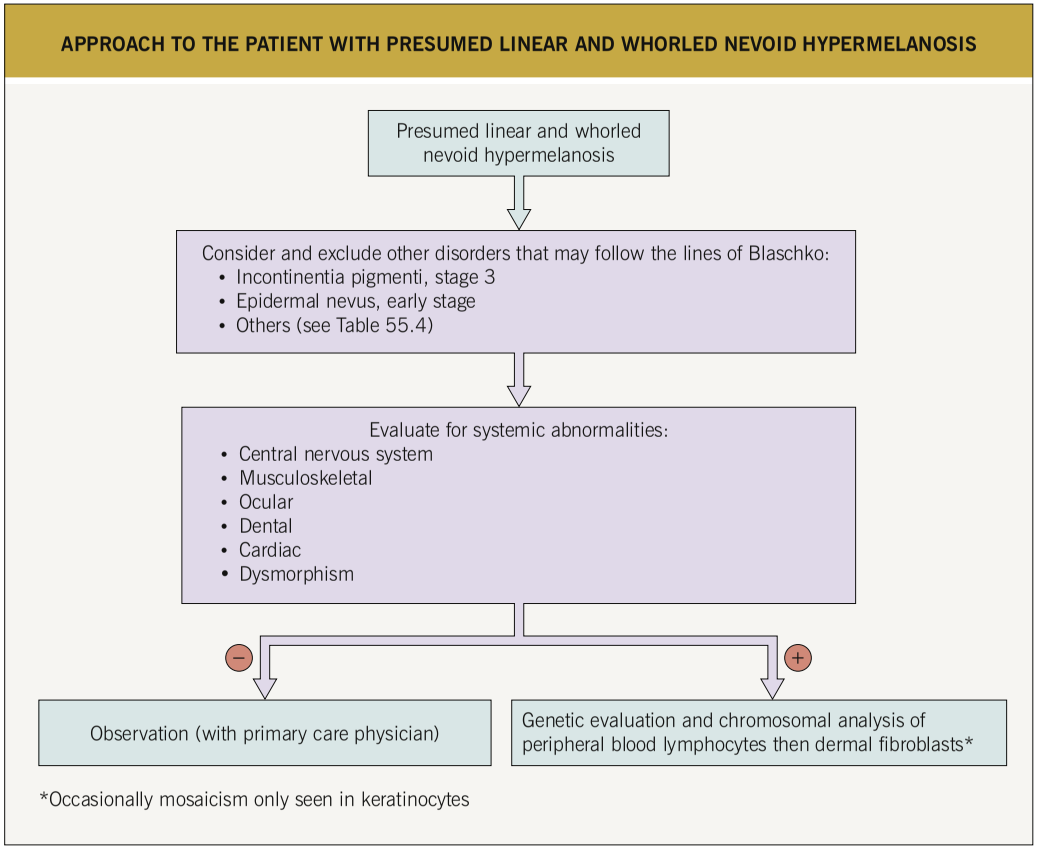


**eFig. 55.8 Approach to the patient with presumed linear and whorled nevoid hypermelanosis.** In general, the initial evaluation is clinical, with additional studies only as indicated based on abnormalities that are evident. Genetic abnormalities are currently detected primarily at the chromosomal (not gene) level; decisions regarding performance of conventional chromosomal analysis and/or array comparative genomic hybridization are made on a case-by-case basis. *Courtesy, Mary Wu Chang, MD.*

| DIFFERENTIAL DIAGNOSIS OF MELASMA | |
|---|---|
| **Disorder** | **Key differences from melasma/comments** |
| **Drug-induced hyperpigmentation or discoloration** | • History of medication use (e.g. doxycycline, amiodarone)<br>• Hyperpigmentation less patterned and less irregular in outline; may involve tip of nose<br>• Discrete oval or round shape of fixed drug eruption rarely confused with melasma<br>• May follow phototoxic drug reaction<br>• Oral contraceptives and phenytoin may exacerbate melasma |
| **Postinflammatory hyperpigmentation**, e.g. due to cutaneous lupus erythematosus, photosensitivity reactions, contact dermatitis (e.g. irritant contact dermatitis to hydroquinone or tretinoin), or other forms of dermatitis | • History of inflammatory phase with erythema, scale, and possible pruritus or burning<br>• Primary lesions – may be admixed or elsewhere on body |
| **Pigmented contact dermatitis (Riehl melanosis)** | • Favors sites of application of contactants, especially cosmetics<br>• May be reticulated<br>• Brown-grey color due to dermal melanin deposits<br>• Histologic features: vacuolar degeneration of basal layer and lichenoid infiltrate in early lesions |
| **Acquired bilateral nevus of Ota-like macules (Hori nevus)** | • Asian women, usually during the fourth or fifth decade of life<br>• Multiple brown-gray to brown-blue macules, primarily in the malar region<br>• Less common sites: lateral forehead, temples, upper eyelids, nasal root or alae<br>• Lack of ocular or mucosal involvement<br>• Histologic features: pigment-producing dermal melanocytes |
| Actinic lichen planus | • Fine scale overlying violaceous lesions if inflammatory phase still present<br>• Histologic features: hydropic degeneration of basal layer, lichenoid infiltrate |
| Lichen planus pigmentosus | • Often begins on the temples/in the preauricular area and involves the neck<br>• Coexistent classic lichen planus (~20% of patients)<br>• Histologic features: vacuolar degeneration of basal layer; variable lichenoid infiltrate and epidermal atrophy |
| Erythema dyschromicum perstans | • Inflammatory phase with rim of erythema occasionally seen<br>• Lesions slate-gray to blue-brown<br>• Distribution includes sun-protected areas |
| Exogenous ochronosis | • History of hydroquinone application to areas of hyperpigmentation followed by progressive darkening<br>• Superimposed small pigmented papules may also be seen<br>• Histologic features: banana-shaped, yellow-brown deposits in the dermis |

**eTable 55.1 Differential diagnosis of melasma.** *Continued*

| DIFFERENTIAL DIAGNOSIS OF MELASMA | |
|---|---|
| **Disorder** | **Key differences from melasma/comments** |
| Cutaneous mercury deposits | • History of use of mercury-containing soaps or creams<br>• Dermatitis often present<br>• Histologic features: brown-black granules free in dermis, in association with elastic fibers and within macrophages |
| Erythromelanosis follicularis faciei et colli | • Red-brown patches on lateral cheeks and neck<br>• Superimposed tiny pale follicular papules |
| Poikiloderma of Civatte | • Presence of atrophy and telangiectasias<br>• Favors lateral and inferior aspects of anterior neck; sparing of perifollicular skin and submental region |
| Acanthosis nigricans | • Velvety plaques in the hollow of the cheek and preauricular areas |

**eTable 55.1** *Continued* **Differential diagnosis of melasma.** Most common diagnoses are in bold. *Courtesy, Mary Wu Chang, MD.*

# 56 Alopecias

- In a normal scalp, 90–95% of hairs are in anagen phase, 5–10% in telogen phase (Fig. 56.1).
- About 50–100 hairs normally shed daily.
- Alopecias can be categorized as diffuse vs circumscribed, patterned vs non-patterned, and non-scarring vs scarring loss (Fig. 56.2).

## Non-Scarring Alopecias

### Male and Female Pattern Hair Loss (Androgenetic Alopecia)

- 80% of Caucasian men are affected by age 70 years.
- Women are less likely than men to have a family history of the disorder.
- Related to hormonal effects of dihydrotestosterone (DHT), converted from testosterone by 5-alpha reductase.
- Sensitivity of scalp hair to androgen hormones causes gradual miniaturization of hairs on the frontal/midline/vertex regions of men and the midline and crown of women (Fig. 56.3).
- In women, the frontal hairline is spared (except in the setting of virilization) and a Christmas tree pattern of widening of the hair part may be seen.
- May first become clinically apparent with superimposed telogen effluvium >> alopecia areata, especially in women.
- Should exclude hyperandrogenism (e.g. ovarian or adrenal source) in younger women or in women with signs of virilization (see Ch. 57).
- **Rx:** topical minoxidil 2% or 5% solution (BID) or foam (daily) for both genders; finasteride or dutasteride (inhibits 5-alpha reductase) in men; spironolactone in women; hair transplantation (using occipital hair as the source).

### Telogen Effluvium

- Sometimes a definable precipitating event ~3 months prior precedes diffuse shedding, leading to a reduced density of hair on the entire scalp and occasionally other areas of body hair (Table 56.1).

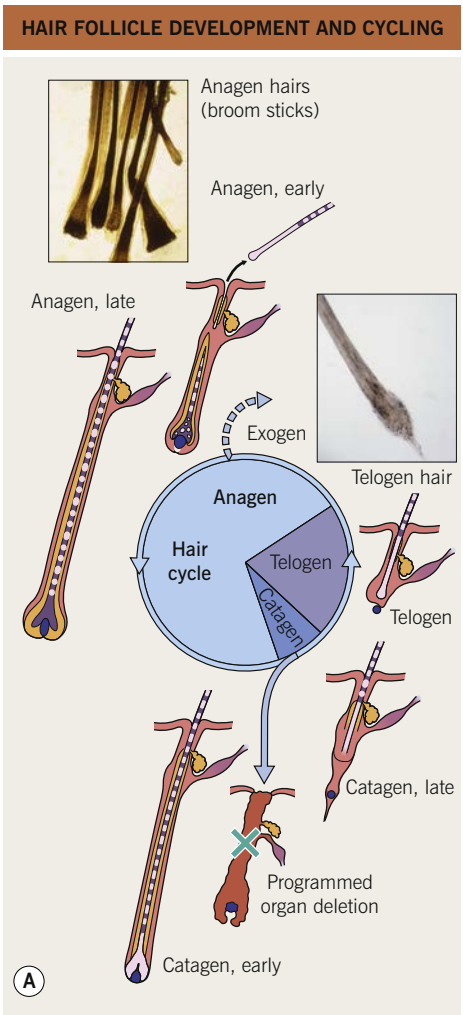


**Fig. 56.1 General concepts. A** Hair follicle development and cycling. *Courtesy, Ralf Paus, MD; Anagen hairs, Courtesy, Maria K. Hordinsky, MD; Telogen hair, Courtesy, Leonard C. Sperling, MD.*
*Continued*

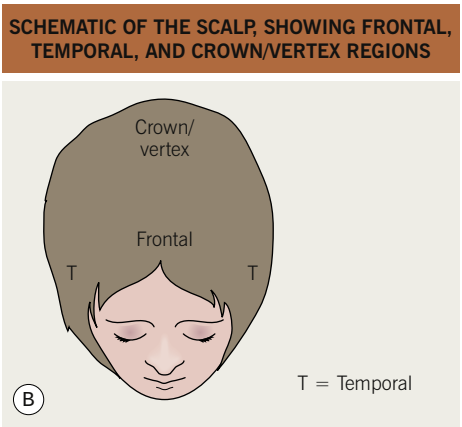


**Fig. 56.1** *Continued* **General concepts. B** Schematic of the scalp, showing frontal, temporal, and crown/vertex regions.

- Shed hairs are predominantly telogen hairs (Fig. 56.1).
- Generally complete hair regrowth occurs after months to years.
- Some women have chronic telogen effluvium without a definable cause.
- **Rx:** discontinue any potentially offending drugs, exclude thyroid abnormality and etiologies listed in Table 56.1.

## Alopecia Areata

- Autoimmune disease with increased T-cells present in the hair matrix.
- Associated with atopy and other autoimmune diseases (e.g. autoimmune thyroid disease, vitiligo, inflammatory bowel disease, autoimmune polyendocrinopathy syndrome type 1).
- Average lifetime risk for developing this disease is 1–2%.
- Circular to oval areas of alopecia that may progress to total scalp hair loss (alopecia totalis) or total body hair loss (alopecia universalis) (Fig. 56.4).
- May see exclamation point hairs at borders (Fig. 56.4).
- Positive pull test (easily extractable telogen hairs at periphery of oval areas of loss) correlates with active disease.
- Ophiasis pattern is a band-like pattern of loss along the temporal/occipital scalp (Fig. 56.4) that may be less responsive to therapy.
- When there is a single, long-standing lesion in the temporal region, the possibility of temporal triangular alopecia should be considered.
- Associated nail findings = nail pitting, trachyonychia >> brittle nails, onycholysis, koilonychia, onychomadesis (see Ch. 58).
- **Rx:** *for regrowth of hair* – high-potency topical or intralesional CS (e.g. 5 mg/ml); topical irritants (e.g. anthralin or tazarotene), topical immunotherapy (e.g. squaric acid dibutyl ester), topical minoxidil 5%; in rapidly progressive disease, occasionally oral CS are given for a limited trial period (e.g. pulsed therapy over 2–3 months); for severe disease, JAK/STAT pathway inhibitors.

## Trichotillomania

- Self-induced twirling, pulling, and/or breaking of hair.
- May be related to a psychologic disorder or stress.
- Plucking of scalp hair results in patchy >> diffuse alopecia, sometimes in a wave-like pattern or centrifugally; hairs tend to be of different lengths (see Fig. 5.5).
- Occiput often spared.
- In difficult cases, can distinguish from alopecia areata by shaving a defined area of involvement and observing for regrowth.
- **Rx:** counseling and treat any underlying psychiatric illness (see Ch. 5).

## Postoperative (Pressure-Induced Alopecia)

- Most commonly secondary to a long surgical procedure.
- Generally alopecia seen on occiput as a solitary, oval patch.
- Usually hair regrows completely.

## Drug-Induced Alopecia

- Chemotherapeutic agents (e.g. cyclophosphamide, doxorubicin, paclitaxel, etoposide) are common causes of anagen effluvium (see Table 17.8).
- Anagen effluvium can also be secondary to exposure to metals, e.g. arsenic, gold.
- Telogen effluvium can be drug-induced (see Table 56.1).

## Secondary Syphilis

- Patchy, "moth-eaten" alopecia in 7% of patients with secondary syphilis.
- Telogen effluvium has also been described.

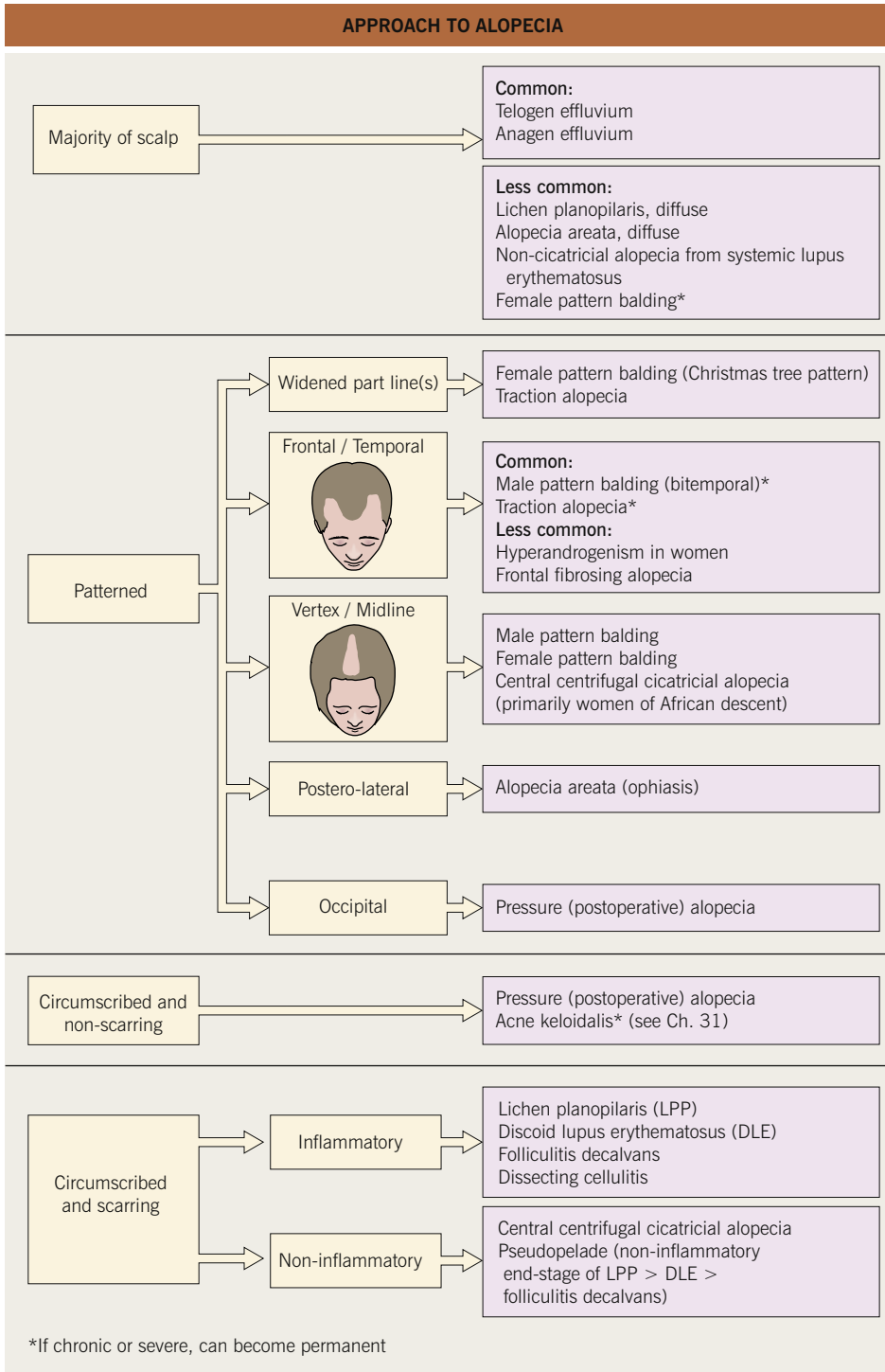


**Fig. 56.2 Approach to alopecia.**




**Fig. 56.3 Androgenetic alopecia.** Widening of the central part line in early disease (**A**) with further widening and translucency of hairs along the border in more severe disease (**B**). Rarely, hair loss is extensive in advanced disease (**C**). *Courtesy, Rodney D. Sinclair, MD.*

| CAUSES OF TELOGEN EFFLUVIUM |
|---|
| • Shedding of the newborn (physiologic) |
| • Postpartum (physiologic) |
| • Chronic telogen effluvium (no attributable cause or illness) |
| • Postfebrile (extremely high fevers, e.g. malaria) |
| • Severe infection |
| • Severe chronic illness (e.g. HIV disease, systemic lupus erythematosus) |
| • Severe, prolonged psychological stress |
| • Postsurgical (implies major surgical procedure) |
| • Hypothyroidism and other endocrinopathies (e.g. hyperparathyroidism) |
| • Crash or liquid protein diets; starvation/malnutrition |
| • Drugs |
| – Retinoids (acitretin, isotretinoin) |
| – Discontinuation of birth control pills |
| – Anticoagulants (especially heparin) |
| – Antidepressants |
| – Lithium |
| – Antithyroid (propylthiouracil, methimazole) |
| – Anticonvulsants (e.g. phenytoin, valproic acid, carbamazepine) |
| – Interferon-α-2b |
| – Heavy metals |
| – β-blockers (e.g. propranolol) |

**Table 56.1 Causes of telogen effluvium.** Some authors also propose vitamin $B_{12}$ or iron deficiency as causes.

### Psoriatic Alopecia

- Areas of hair loss that in some patients are associated with shedding of thick psoriatic plaques.
- Most commonly non-scarring.

## Scarring (Cicatricial) Alopecias

- Classically defined as loss of hair follicles with scarring (e.g. lupus erythematosus, lichen planopilaris) *or* an alopecia in which hair does not grow back (e.g. chronic, long-standing traction alopecia).
- Non-scarring alopecias that may eventually result in permanent hair loss include male and female pattern hair loss > alopecia areata.
- In *secondary* scarring alopecia, the hair is destroyed nonspecifically, i.e. secondary to burns, radiation dermatitis, cutaneous malignancy (see Ch. 100), sarcoidosis, morphea, necrobiosis lipoidica, infections (e.g. severe kerion), mucous membrane (cicatricial) pemphigoid.

### Central Centrifugal Cicatricial Alopecia (CCCA)

- Most commonly observed in black women.
- May be related to the use of chemical hair relaxers or thermal relaxers (e.g. flat iron).
- Slowly progressive; centered on the crown/vertex and midline (Fig. 56.5).
- Symptoms may be mild or absent.




**Fig. 56.4 Alopecia areata. A** Circular area of alopecia in a child. **B** Exclamation point hair with the distal end broader than the proximal end. **C** Total alopecia of scalp, eyebrows, and eyelashes in a patient with alopecia universalis. **D** Ophiasis with a band-like pattern of hair loss along the periphery of the temporal and occipital scalp. **E** Alopecia areata with just beard involvement. **F** Typical yellow dots seen dermoscopically in alopecia areata. *A, D, Courtesy, YDRSC; B, Courtesy, Julie V. Shaffer, MD; C, Courtesy, Leonard C. Sperling, MD; E, Courtesy, Maria K. Hordinsky, MD; F, Courtesy, Iris Zalaudek, MD.*

• Occasionally patients have secondary changes, especially crusting or pustules.
• **Rx:** mild disease – oral tetracycline plus potent topical CS; severe disease – oral rifampin plus oral clindamycin; occasionally intralesional CS if an inflammatory component is present.

## Lichen Planopilaris

• Women > men, more common in Caucasians.
• 30% may have associated lichen planus involving the skin (see Table 9.1), mucous membranes, or nails (see Chs 9 and 58).
• Usually several foci of alopecia with loss of follicles and scarring centrally (may be clinically subtle); peripheral follicles having a central, keratotic plug and a rim of inflammation (pink to violet in color) (Fig. 56.6).
• Centered on the crown/vertex or midline.

### Frontal Fibrosing Alopecia

- Predominantly affecting the frontal hairline and eyebrows ("frontal fibrosing alopecia") (Fig. 56.7), or rarely a diffuse pattern. Lonely hairs and absence of solar lentigines may be present.

### Graham Little Syndrome

- Scalp alopecia, alopecia of axillary/pubic areas, and grouped spinous follicular papules on trunk/extremities.
- **Rx:** topical or intralesional CS, oral doxycycline, oral antimalarials (e.g. hydroxychloroquine), oral retinoids, oral mycophenolate mofetil (if severe).

### Discoid Lupus Erythematosus (DLE)

- A type of chronic cutaneous lupus erythematosus.
- More common in adult women, especially black women.
- Minority of patients fulfill the criteria for systemic lupus erythematosus (see Ch. 33), but patients need to be evaluated at the time of diagnosis of DLE and followed longitudinally.
- Circular lesions of erythema, atrophy, dilated/plugged follicles, and scale as well as alopecia.
- As lesions age, central hypopigmentation and peripheral hyperpigmentation may appear, along with scarring (Fig. 56.8).
- May see similar-appearing lesions elsewhere (especially face and ears).
- **Rx:** discussed in Chapter 33.

### Acne Keloidalis

- Favors young black men (see Ch. 31).
- Occipital scalp most common site, but sometimes involves the crown/vertex.
- Smooth, firm papules > pustules.
- Initial lesions resolve with alopecia and/or protuberant papules.
- Coalescence of lesions leads to alopecia.
- **Rx:** intralesional CS, oral antibiotics, excision (see Table 31.6).

### Dissecting Cellulitis

- May be associated with "follicular occlusion tetrad," which includes this entity,

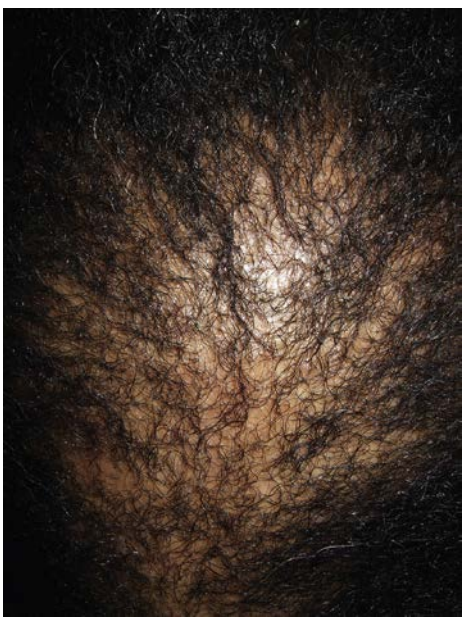

**Fig. 56.5 Central centrifugal cicatricial alopecia in an African-American woman.** Alopecia is most prominent on the crown/vertex and the midline. *Courtesy, Leonard C. Sperling, MD.*

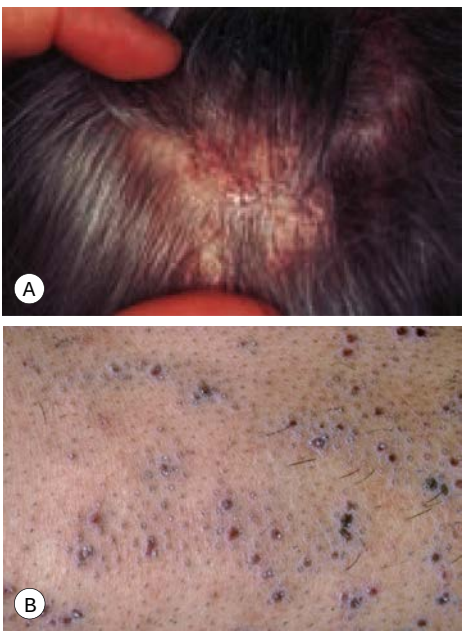


**Fig. 56.6 Lichen planopilaris. A** Perifollicular erythema in association with scale. **B** Multiple clusters of follicular keratotic plugs on the leg admixed with small violaceous papules, some of which are folliculocentric. *A, Courtesy, Jean L. Bolognia, MD; B, Courtesy, NYUDSC.*



**Fig. 56.7 Frontal fibrosing alopecia.** Progressive hair loss along the frontotemporal hairline. Note eyebrow hair loss as well as the presence of isolated "lonely" hairs on the upper forehead. *Courtesy, Leonard C. Sperling, MD, and Rodney D. Sinclair, MD.*

hidradenitis suppurativa, acne conglobata, and pilonidal cyst/sinus.

- Affects young adult men, especially black men.
- Multiple, firm scalp nodules over crown/vertex/occiput that become boggy and fluctuant with purulent discharge; often interconnecting.
- Sometimes little pain.
- **Rx:** intralesional CS, antibiotics based on cultures, incision and drainage, excision.

### Folliculitis Decalvans

- Inflammatory scarring alopecia with perifollicular papules and pustules.
- **Rx:** dapsone, oral antibiotics (e.g. tetracycline or doxycycline for anti-inflammatory effects; combination of rifampin and clindamycin).

### Pseudopelade (of Brocq)

- Considered by most to be the end-stage, burned-out phase of different scarring alopecias (Fig. 56.9), especially lichen planopilaris.

### Traction Alopecia (Late-Stage)

- Occurs after years of hair styling that causes traction.
- Generally seen in black women on the bitemporal/frontal scalp line (Fig. 56.10).



**Fig. 56.8 Discoid lupus erythematosus.** Coalescing areas of alopecia in which there is obvious erythema. Central hypopigmentation is accompanied by peripheral hyperpigmentation. *Courtesy, Leonard C. Sperling, MD, and Rodney D. Sinclair, MD.*



**Fig. 56.9 Pseudopelade (end-stage scarring alopecia).** Irregularly shaped areas of scarring alopecia along the midline. *Courtesy, Kalman Watsky, MD.*

## Hair Shaft Abnormalities

- Four main categories: (1) *fractures* (trichorrhexis nodosa and invaginata, trichoschisis); (2) *irregularities* (monilethrix); (3) *twisting* (pili torti, woolly hair, trichonodosis); and (4) *extraneous matter* (Fig. 56.11).

• Can also divide into *increased breakage* (bubble hair, monilethrix, pili torti, trichorrhexis invaginata and nodosa, trichothiodystrophy) and *no increased breakage* (loose anagen, pili annulati, spun-glass hair, woolly hair).
• Trichorrhexis nodosa – common hair shaft abnormality that leads to increased breakage; hair shaft fractured with the appearance of two brushes pushing against each other; seen with hair straightening.
• Loose anagen hair syndrome – common cause of sparse, short hair especially in young children, with improvement over time; anagen hairs are poorly anchored and therefore easily shed or pulled, but breakage is not increased.



**Fig. 56.10 Traction alopecia.** Favors frontotemporal area in African-American women and is due to traumatic types of hair styling. *Courtesy, Leonard C. Sperling, MD.*

## Trichoscopy (Fig. 56.12)

For further information see Ch. 69 from *Dermatology, Fourth Edition*.

**For additional online figures visit www.expertconsult.com**




**Fig. 56.11 Schematic drawings and microscopic appearance of hair shaft abnormalities.** **A** Trichorrhexis nodosa. **B** Trichorrhexis invaginata. **C** Monilethrix. **D** Trichoschisis (due to trichothiodystrophy). **E** Trichothiodystrophy (polarization; in comparison to normal hair shaft). **F** Bubble hair. **G** Pili torti (scanning electron microscopy [EM]). **H** Pili annulati. **I** Trichonodosis. **J** Pili trianguli et canaliculi ("spun glass hair"). **K** Trichoptilosis. Some of the hair shaft abnormalities are seen in genetic syndromes (e.g. trichorrhexis invaginata in Netherton syndrome, trichoschisis in trichothiodystrophy). *A, B, Courtesy, Maria K. Hordinsky, MD; C–E, G, H, J, K, Courtesy, YDRSC; F, Courtesy, Jean L. Bolognia, MD.*

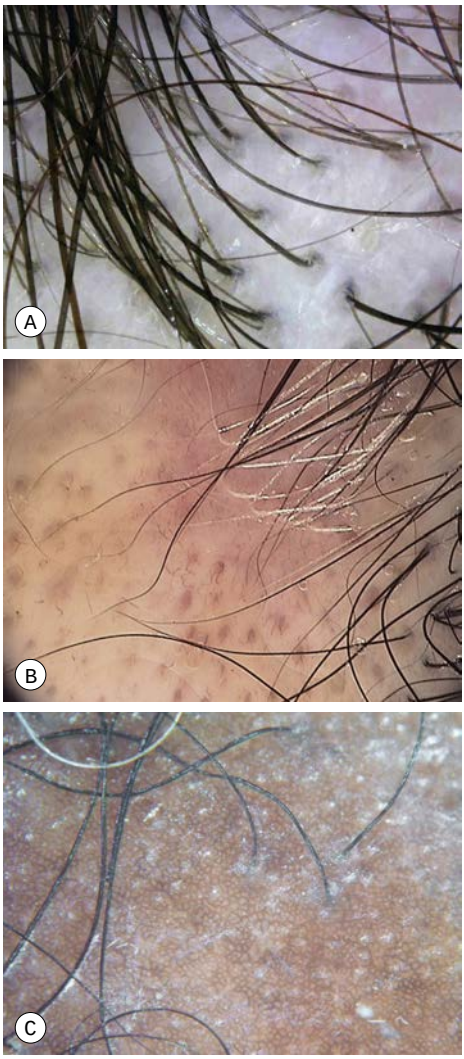


**Fig. 56.12 Trichoscopy. A** Androgenetic alopecia: a diversity of hair shaft diameters affects >20% of the hairs. Brown halos around hair shafts (peripilar sign) is a subtle clue. **B** Discoid lupus erythematosus (DLE): follicular red dots are a characteristic sign and they correspond histopathologically to dilated vessels, extravasated erythrocytes, and keratin plugs. **C** Lichen planopilaris: discrete white dots due to loss of melanin over scarred fibrotic tracts and perifollicular fibrosis. The fibrosis in DLE is more diffuse. Trichoscopic findings in alopecia areata are shown in Fig. 56.4F. *A, Courtesy, Leonard C. Sperling, MD, and Rodney D. Sinclair, MD; B, C, Courtesy, Antonella Tosti, MD.*



**eFig. 56.1 Central centrifugal cicatricial alopecia in an African-American woman.** Alopecia is most prominent on the crown and/or vertex.



**eFig. 56.2 Lichen planopilaris.** Later stage showing scarring with loss of follicular openings and less erythema. *Courtesy, NYUDSC.*



**eFig. 56.3 Frontal fibrosing alopecia.** Progressive hair loss along the anterior hairline. Note the "lonely" hairs. *Courtesy, Kalman Watsky, MD.*



**eFig. 56.4 Late-stage chronic lupus erythematosus.** Burnt-out discoid lesions of lupus erythematosus mimicking Brocq's alopecia.



**eFig. 56.5 Dissecting cellulitis of the scalp and acne keloidalis in an African-American man.** *Courtesy, YDRSC.*



**eFig. 56.7 Temporal triangular alopecia.** The tip of the "lancet" points superiorly. Occasionally, the lesion is located outside the temporal region, as seen here.

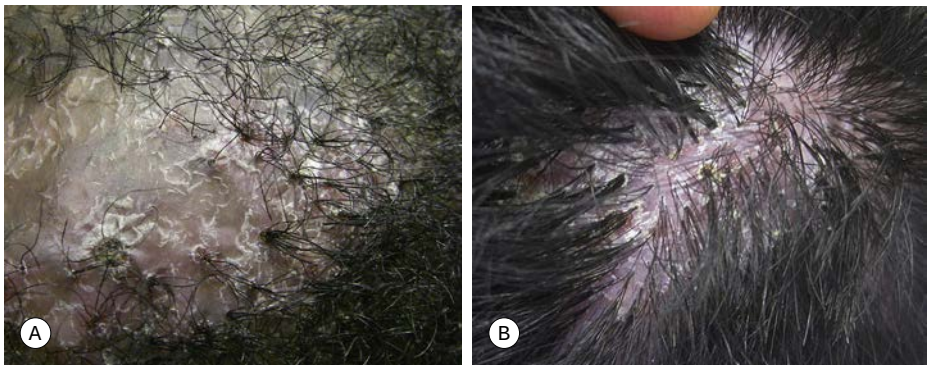


**eFig. 56.6 "Tufted folliculitis."** Note the multiple hairs arising from a single follicular orifice within the area of scarring alopecia. *A, Courtesy, Kalman Watsky, MD; B, Courtesy, Damon McClain, MD.*

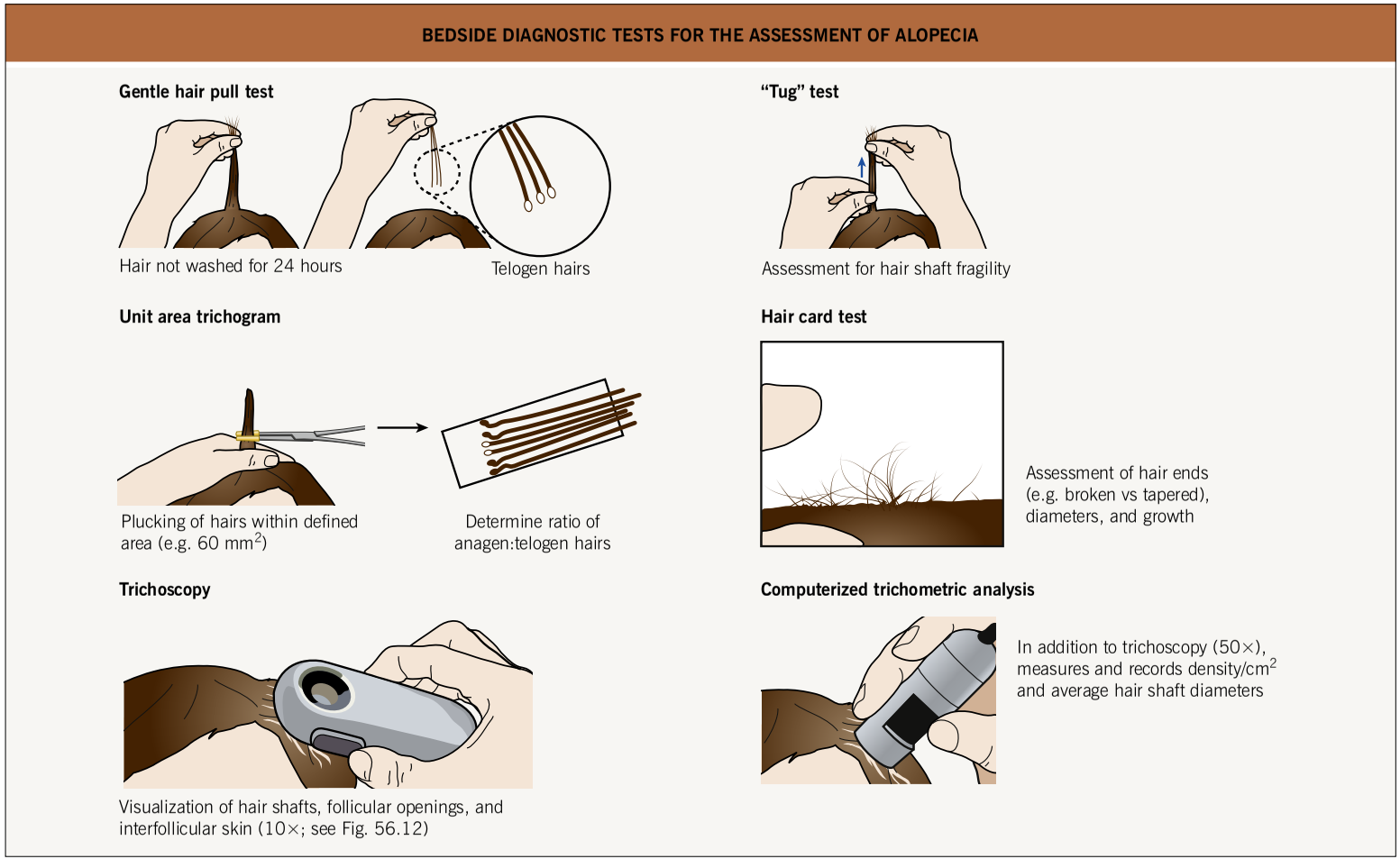


**eFig. 56.8 Bedside diagnostic tests for the assessment of alopecia.** Additional investigations include fungal culture, Wood's lamp examination, scalp biopsy, hair shaft analysis, and blood tests.

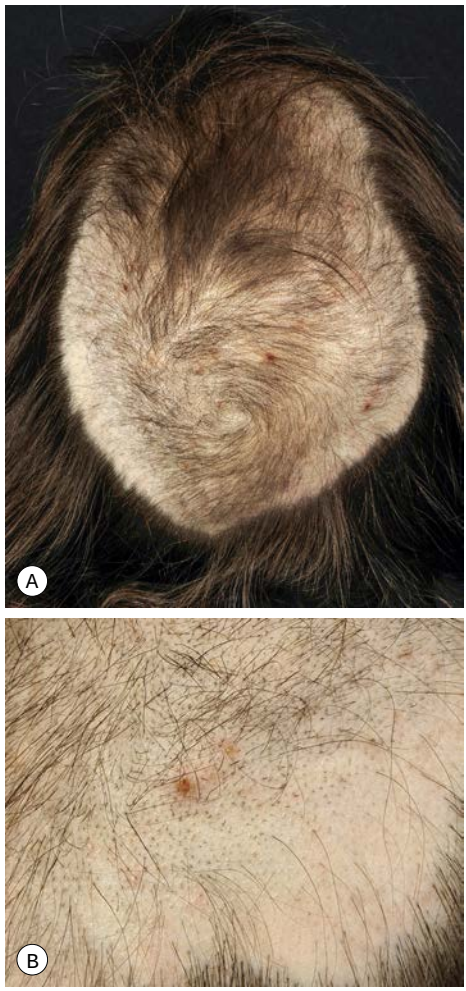


**eFig. 56.9 Trichotillomania. A** Large area of alopecia with a sharp border and hairs that are different lengths. **B** There are broken hairs, crusted erosions, and a few pustules in addition to hairs of different lengths.



**eFig. 56.10 Temporal triangular alopecia.** The tip of the "lancet" points superiorly. *Courtesy, Jean L. Bolognia.*

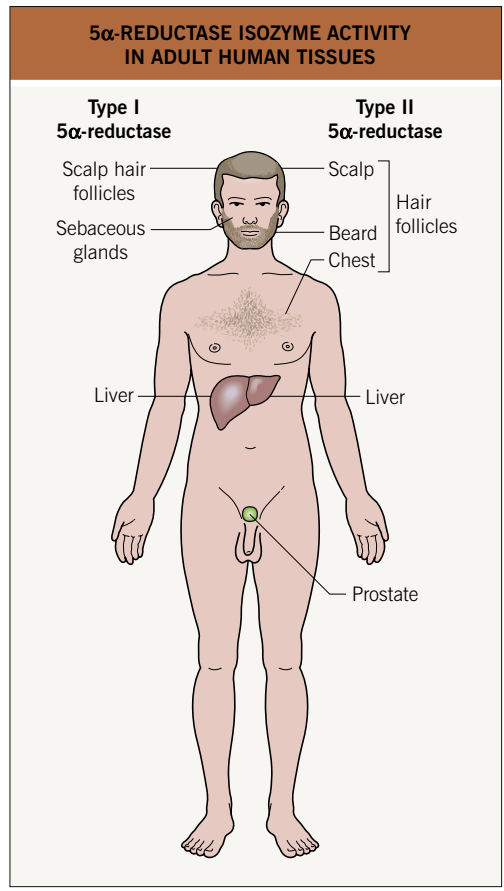


**eFig. 56.11 5α-reductase isoenzyme activity in adult human tissues.** Type III 5α-reductase is found throughout the epidermis and dermis, but its functional role has not yet been elucidated.



**eFig. 56.12 Dissecting cellulitis of the scalp in an African-American man.** The areas of alopecia vary in shape, from oval to linear. Interconnecting boggy and fluctuant nodules are accompanied by pustular drainage from sinuses and scarring. *Courtesy, Joseph English, MD.*



**eFig. 56.13 Monilethrix.** Hypotrichosis due to breakage of fragile hairs. Note the small perifollicular papules with scale.



**eFig. 56.14 Woolly hair nevus.** Circumscribed area where scalp hair is wavier and has a woolly appearance. *Courtesy, YDRSC.*

# 57 Hypertrichosis and Hirsutism

## Definitions

- **Hypertrichosis**: excessive hair growth on any area of the body, beyond what is normally expected for a patient's demographic group.
- **Hirsutism**: excessive terminal hair growth in women or children in a pattern typically seen in adult men.
- **Lanugo hair**: long fine hair that is grown *in utero*, covers the fetus, and is normally shed either *in utero* or during the first few weeks of life.
- **Vellus hair**: short, non- or lightly pigmented hair that covers most areas of the body; occasionally so fine as to not be appreciated clinically.
- **Terminal hair**: thick pigmented hair that is typical of the scalp and androgen-dependent areas, such as the axillae and pubic region in both sexes, as well as the beard, trunk, and limbs in adult males.
- **Hyperandrogenism**: elevated serum levels of testosterone, DHEAS, and/or androstenedione; cutaneous findings include hirsutism, severe or treatment-resistant acne, androgenetic alopecia, and seborrhea.
- **Virilization**: in women, clinical features of hyperandrogenism plus clitoromegaly, deepened voice, increased muscle mass, breast atrophy, and increased libido.
- **Depilation**: removal of a portion of the hair at some point along its shaft.
- **Epilation**: removal of the entire hair shaft.

## Hypertrichosis

- Can be classified based on the **distribution** (generalized vs. localized), **age of onset** (congenital or early onset vs. acquired), and **type of hair** (lanugo vs. vellus vs. terminal).
- Three mechanisms of hypertrichosis are generally recognized:
  1. Conversion of vellus to terminal hair (e.g. localized hypertrichosis in an area of chronic rubbing or scratching).
  2. Changes in the hair growth cycle (e.g. intranasal and ear hairs in older males due to prolongation of anagen phase).
  3. Increase in hair follicle density beyond what is normal for a given site (e.g. congenital melanocytic nevus).
- **Rx:** treat underlying condition, if possible, otherwise see Table 57.2.
- Shaving of hairs does not increase the thickness or pigmentation of the hairs, contrary to common belief.

### Generalized Hypertrichosis

- The presence of lanugo hair, excess vellus hair, or terminal hair on most of the body.
- An approach to a patient with *generalized hypertrichosis* is presented in Fig. 57.1.
- In young girls, constitutional prepubertal hypertrichosis is the most common form of generalized hypertrichosis.

### Localized Hypertrichosis

- Most often involves a switch from vellus to terminal hair in sites that normally do not have terminal hairs.
- ***Congenital localized hypertrichosis*** is usually related to an underlying hamartoma or occurs at a specific anatomic site (Table 57.1; Figs 57.2–57.5).
- ***Acquired localized hypertrichosis*** most often develops after repeated trauma, friction, irritation, or inflammation (see Table 57.1; Figs 57.6–57.7).

Downloaded for Novin lib (novinlibrary@yahoo.com) at United Arab Emirates University from ClinicalKey.com by Elsevier on March 26, 2022. For personal use only. No other uses without permission. Copyright ©2022. Elsevier Inc. All rights reserved.

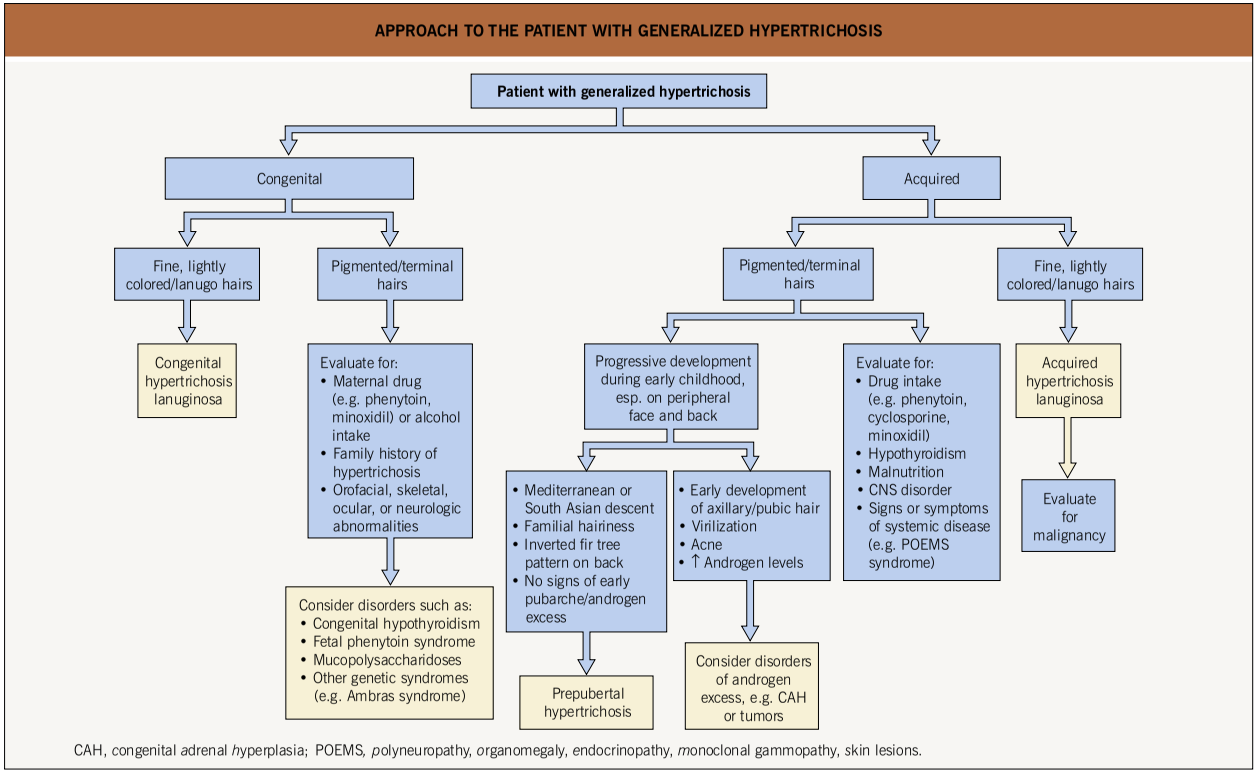


**Fig. 57.1 Approach to the patient with generalized hypertrichosis.** Acquired hypertrichosis lanuginosa occasionally may involve only the face.

| CLASSIFICATION AND KEY FEATURES OF SELECTED DISORDERS OF LOCALIZED HYPERTRICHOSIS | |
|---|---|
| **Condition** | **Key features** |
| **Congenital localized hypertrichosis** | |
| Congenital melanocytic nevus | • Hyperpigmented and usually elevated (see Ch. 92) |
| Plexiform neurofibroma | • Palpable component and often hyperpigmented (see Ch. 50) |
| Nevoid hypertrichosis (Fig. 57.2) | • Circumscribed area of terminal hair growth<br>• *Primary*: skin normally pigmented; no underlying hamartoma<br>• *Secondary*: can be associated with lipodystrophy, hemihypertrophy, scoliosis, and abnormalities of underlying vasculature |
| Smooth muscle hamartoma | • Exists on a clinical spectrum with Becker melanosis (nevus) (see Ch. 95) |
| Becker melanosis (nevus) (Fig. 57.3) | • Hamartoma characterized by macular hyperpigmentation with irregular borders; often on the upper lateral trunk; onset in first decade of life<br>• Hypertrichosis (variable) usually appears in second decade, correlating with puberty<br>• Males > females<br>• Occasionally associated with asymmetry of the extremities and hyper- or hypoplasia of the affected areas |
| Spinal hypertrichosis (see Ch. 53) | • Tufts of terminal hairs along the dorsal midline<br>• May signify underlying *spinal dysraphism* |
| Hair collar sign (see Ch. 53) | • Peripheral ring of hypertrichosis surrounding membranous aplasia cutis or ectopic neural tissue in the scalp<br>• MRI can detect underlying skull defect; do *not* biopsy |
| Anterior cervical hypertrichosis (see Fig. 57.5) | • Tuft of terminal hair above laryngeal prominence<br>• Isolated > associated with a neuropathy or intellectual disability |
| Hypertrichosis cubiti (hairy elbow syndrome) (Fig. 57.4) | • Symmetric excessive hair growth on the elbow region<br>• Occasionally associated with short stature |
| Facial hypertrichosis | • Genetic syndromes (e.g. Cornelia de Lange syndrome) |
| **Acquired localized hypertrichosis** | |
| Due to repeated trauma, friction, inflammation, or irritation (Fig. 57.6) | • Hair within the affected area becomes longer and thicker<br>• Typical scenarios: repeated scratching or LSC; fractured limb or orthopedic casts and splints; sack carriers |
| Chemical-induced | • Exposure to iodine or topical agents (e.g. minoxidil, tacrolimus, CS) |
| Facial hypertrichosis | • May be due to familial predisposition, PCT (see Fig. 41.3), systemic medications (e.g. CSA) or topical medications (e.g. minoxidil), malnutrition |
| Hypertrichosis singularis | • One long “wild” hair |
| Trichomegaly of eyelashes (Fig. 57.7) | • May be due to topical ophthalmic medications (e.g. bimatoprost), systemic medications (e.g. EGFR inhibitors, tacrolimus, CSA, topiramate), HIV infection, malnutrition |
| Systemic disease | • Complex regional pain syndrome (hypertrichosis in affected area)<br>• Juvenile dermatomyositis (hypertrichosis in infrapatellar region)<br>• Pretibial myxedema (anterior shins)<br>• In association with cutaneous sclerosis (e.g. H syndrome, linear melorheostosis) |

**Table 57.1 Classification and key features of selected disorders of localized hypertrichosis.**
CSA, cyclosporine; LSC, lichen simplex chronicus; PCT, porphyria cutanea tarda.



**Fig. 57.2 Nevoid hypertrichosis in the scalp of a young boy.** There was no underlying melanocytic nevus or hyperpigmentation. *Courtesy, Jean L. Bolognia, MD.*



**Fig. 57.3 Becker melanosis (nevus) on the mid back in a young man.** In addition to hyperpigmentation, there is marked hypertrichosis. The degree of hypertrichosis can vary. When it is marked, as in this patient, the clinical differential diagnosis includes congenital melanocytic nevus, especially when there is an underlying smooth muscle hamartoma. *Courtesy, Francisco M. Camacho Martinez, MD.*

## Hirsutism

- Affects ~5–10% of females of reproductive age; can also affect postmenopausal women.
- Due to hyperandrogenism (exogenous or endogenous) or increased sensitivity of the hair follicle to normal androgen levels and is the most commonly used clinical criterion of androgen excess.



**Fig. 57.4 Hypertrichosis cubiti.** Multiple terminal hairs on both elbows in a child. *Courtesy, Francisco M. Camacho Martinez, MD.*



**Fig. 57.5 Anterior cervical hypertrichosis.** *Courtesy, Harvey Lui, MD.*



**Fig. 57.6 Acquired localized hypertrichosis.** Hypertrichosis, hyperpigmentation, and epidermal hyperplasia at the site of friction. Some authors refer to this as "frictional asymmetric darkening of the extensor surfaces", when there is primarily hyperpigmentation. *Courtesy, YDRSC.*

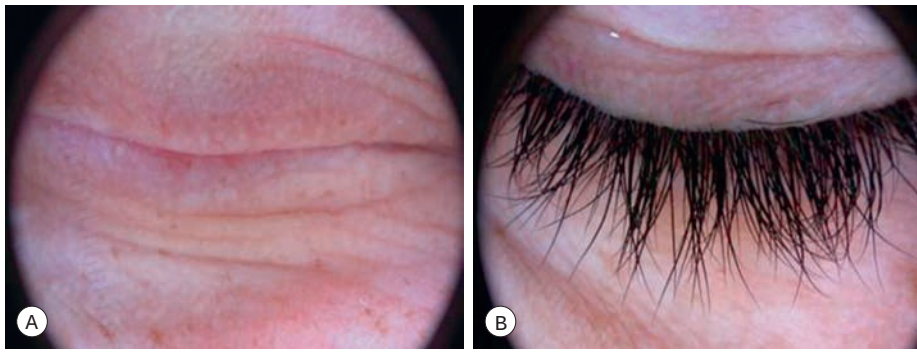


**Fig. 57.7 Treatment of eyelash alopecia in a patient with alopecia universalis. A** Prior to treatment. **B** Following daily application of topical latanoprost ophthalmic 0.005% solution for 6 months, there was regrowth of eyelashes. *Courtesy, Francisco M. Camacho Martinez, MD.*

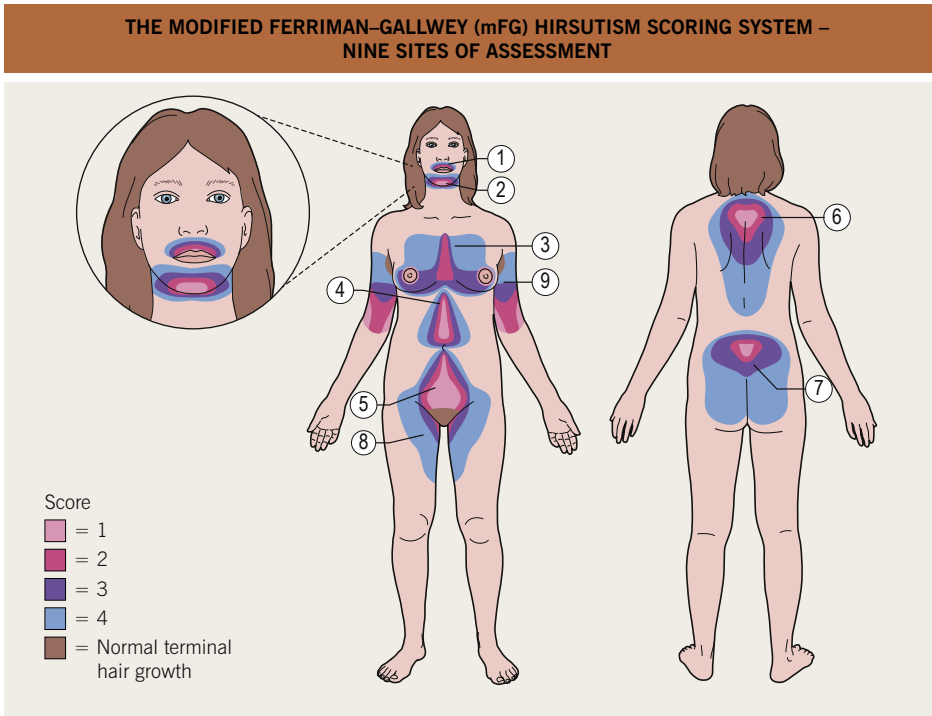


**Fig. 57.8 The modified Ferriman–Gallwey (mFG) hirsutism scoring system.** In this system, nine body areas are evaluated for the amount of terminal hair growth. A score of "0" (no hair) up to "4" (frankly virile) is given to each of the nine areas and these are added together to compute a hormonal hirsutism score (mFG score). Total scores that define hirsutism in women of reproductive age are as follows: US and UK black or white women, ≥8; Mediterranean, Hispanic and Middle Eastern women, ≥9 to 10; South American women, ≥6; and Asian women, a range of ≥2 for Han Chinese women to ≥7 for Southern Chinese women.

- Quantified using the modified Ferriman–Gallwey (mFG) method (Fig. 57.8).
- Etiologies of hyperandrogenism and hirsutism in *premenopausal* females include:
  - *Most common*: polycystic ovary syndrome (PCOS), idiopathic (end-organ sensitivity; Fig. 57.9)
  - *Less common*: nonclassic congenital adrenal hyperplasia (NC-CAH), ovarian hyperthecosis, tumoral
  - *Must exclude*: pregnancy; drugs (e.g. androgens, anabolic steroids, valproic acid, supplements)

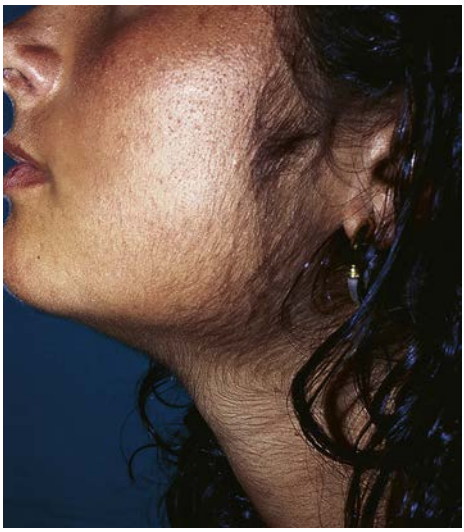

**Fig. 57.9 Facial hirsutism in a young female.** This can be due to hyperandrogenism or end-organ sensitivity. *Courtesy, Francisco M. Camacho Martinez, MD.*

- Etiology in *postmenopausal* women (new onset) is most likely ovarian hyperthecosis or tumoral hirsutism.
- Suggested algorithms for the evaluation of hirsutism and for hyperandrogenism are shown in Figs 57.10 and 57.11, respectively.

## Polycystic Ovary Syndrome (PCOS)

- Diagnosed by the presence of ≥2 of the following criteria *and* the exclusion of other possible etiologies (see Fig. 57.11):
  1. Oligo- or anovulation (<8 menses/year or cycles >35 days).
  2. Clinical and/or biochemical signs of hyperandrogenism (Fig. 57.12).
  3. Polycystic ovaries (pelvic [preferably trans-vaginal] ultrasound).
- Luteinizing hormone (LH): follicle-stimulating hormone (FSH) ratio is >3 in ~95% of cases
- Occurs only during the reproductive years, and although the majority of patients are obese, some are of normal weight.
- Other associated findings may include acanthosis nigricans and insulin resistance; patients are at increased risk for the metabolic syndrome (see Table 45.11), infertility, obstructive sleep apnea, endometrial carcinoma, depression and anxiety.
- **Rx** of hirsutism: hormonal agents (Table 57.3) as well as general hair removal methods (see Table 57.2).

## Idiopathic Hirsutism

- Usually characterized by mild hirsutism, regular ovulation, and normal testosterone levels.
- Diagnosis of exclusion.

## Nonclassic Congenital Adrenal Hyperplasia (NC-CAH)

- Autosomal recessive disorder due to partial deficiency in 21-hydroxylase activity (mutations in *CYP21A2*), leading to increased 17-hydroxyprogesterone (17-OHP) levels.
- More prevalent in Ashkenazi Jews, Hispanics, and Slavics.
- Usually presents in the peripubertal and young adult years with hirsutism, menstrual irregularities, infertility, androgenetic alopecia, and acne.
- Initial testing includes measuring an early morning 17-OHP level during the follicular phase of menstrual cycle; if equivocal, a high-dose ACTH stimulation test and/or genotyping for *CYP21A2* can be performed.
- **Rx** of hirsutism: overlaps with that of PCOS, but may also include systemic CS (see Tables 57.2 and 57.3).

## Ovarian Hyperthecosis

- Occurs in both premenopausal and postmenopausal females.
- Due to the differentiation of ovarian interstitial cells into steroidogenically active luteinized stromal cells, resulting in greater production of androgens.
- Clinical features are similar to those of PCOS but with more pronounced and long-standing hirsutism, an increased likelihood of virilization (Fig. 57.13), and the occurrence postmenopausally.
- Testosterone levels are often quite elevated (>200 ng/dl); DHEAS can be normal or increased (see Fig. 57.11).
- Compared to tumoral hirsutism, a slower onset of symptoms and more gradual worsening over years.
- Increased risk of insulin resistance, type 2 diabetes, and endometrial carcinoma.

## Tumoral Hirsutism

- Can be caused by a variety of benign or malignant ovarian or adrenal androgen-secreting tumors.
- Typically presents with either sudden onset or rapid progression of hirsutism and other clinical features of hyperandrogenism; virilization more likely.

Downloaded for Novin lib (novinlibrary@yahoo.com) at United Arab Emirates University from ClinicalKey.com by Elsevier on March 26, 2022. For personal use only. No other uses without permission. Copyright ©2022. Elsevier Inc. All rights reserved.

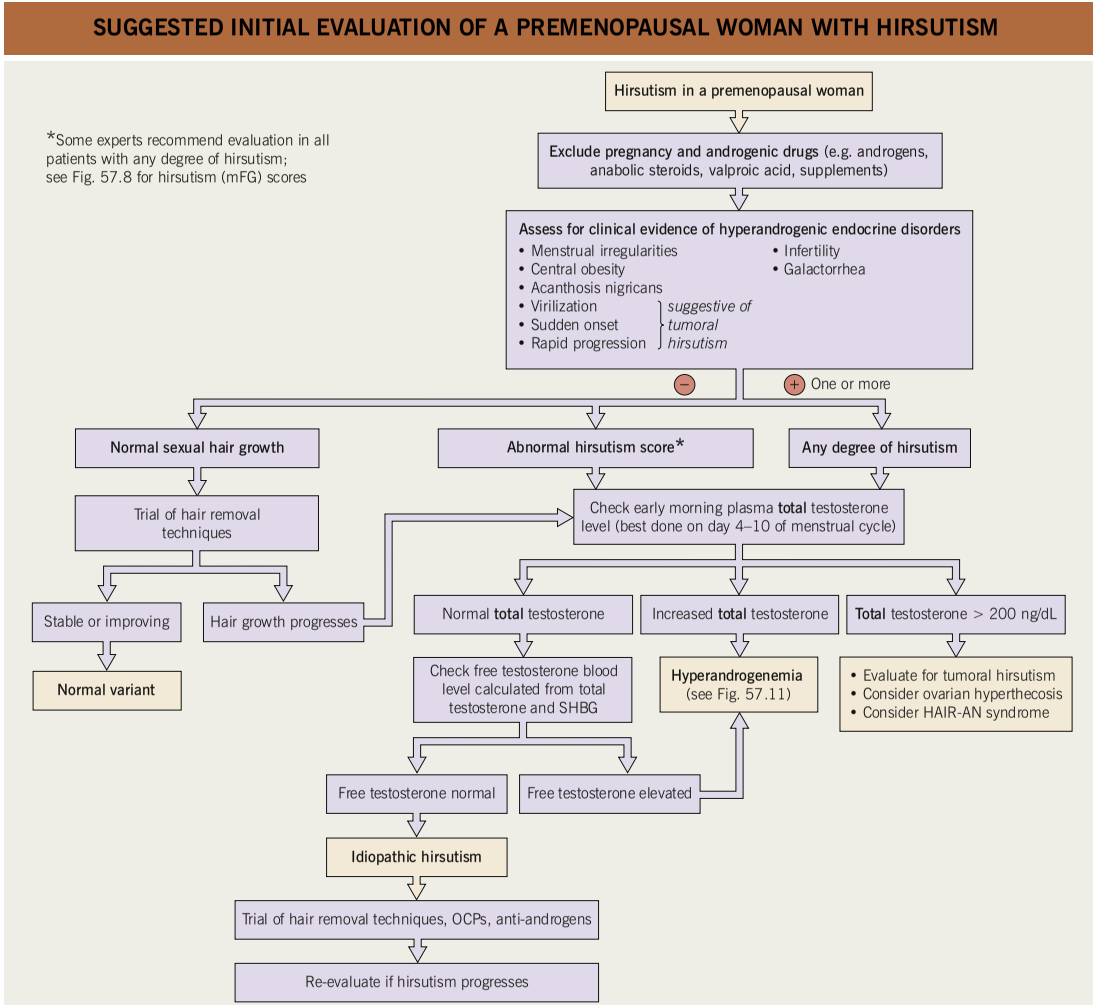


**Fig. 57.10 Suggested initial evaluation of a premenopausal female with hirsutism.** HAIR-AN, *h*yper*a*ndrogenism, *i*nsulin *r*esistance, *a*canthosis *n*igricans syndrome; mFG, modified Ferriman–Gallwey score (see Fig. 57.8); OCP, oral contraceptive pills; SHBG, steroid hormone binding globulin.

Downloaded for Novin lib (novinlibrary@yahoo.com) at United Arab Emirates University from ClinicalKey.com by Elsevier on March 26, 2022. For personal use only. No other uses without permission. Copyright ©2022. Elsevier Inc. All rights reserved.

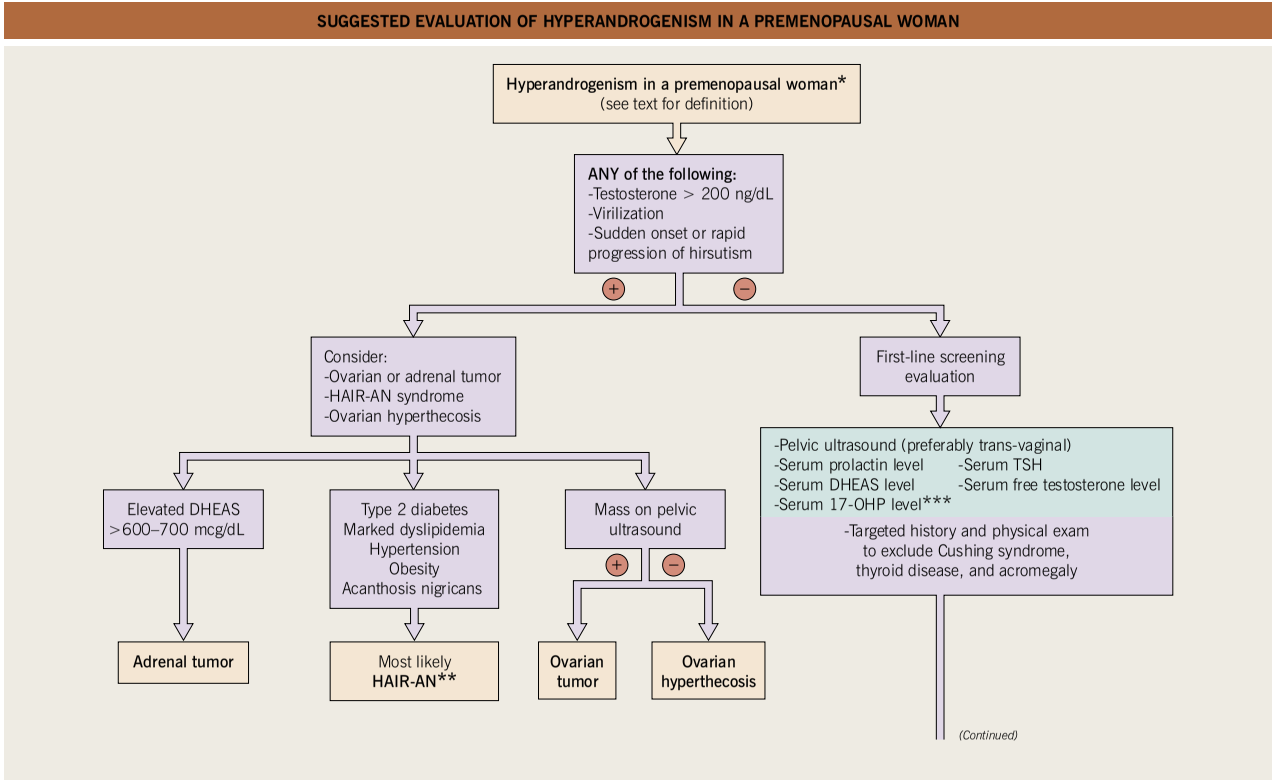


**Fig. 57.11 Suggested evaluation of hyperandrogenism in a premenopausal woman.** *Continued*

Downloaded for Novin lib (novinlibrary@yahoo.com) at United Arab Emirates University from ClinicalKey.com by Elsevier on March 26, 2022. For personal use only. No other uses without permission. Copyright ©2022. Elsevier Inc. All rights reserved.

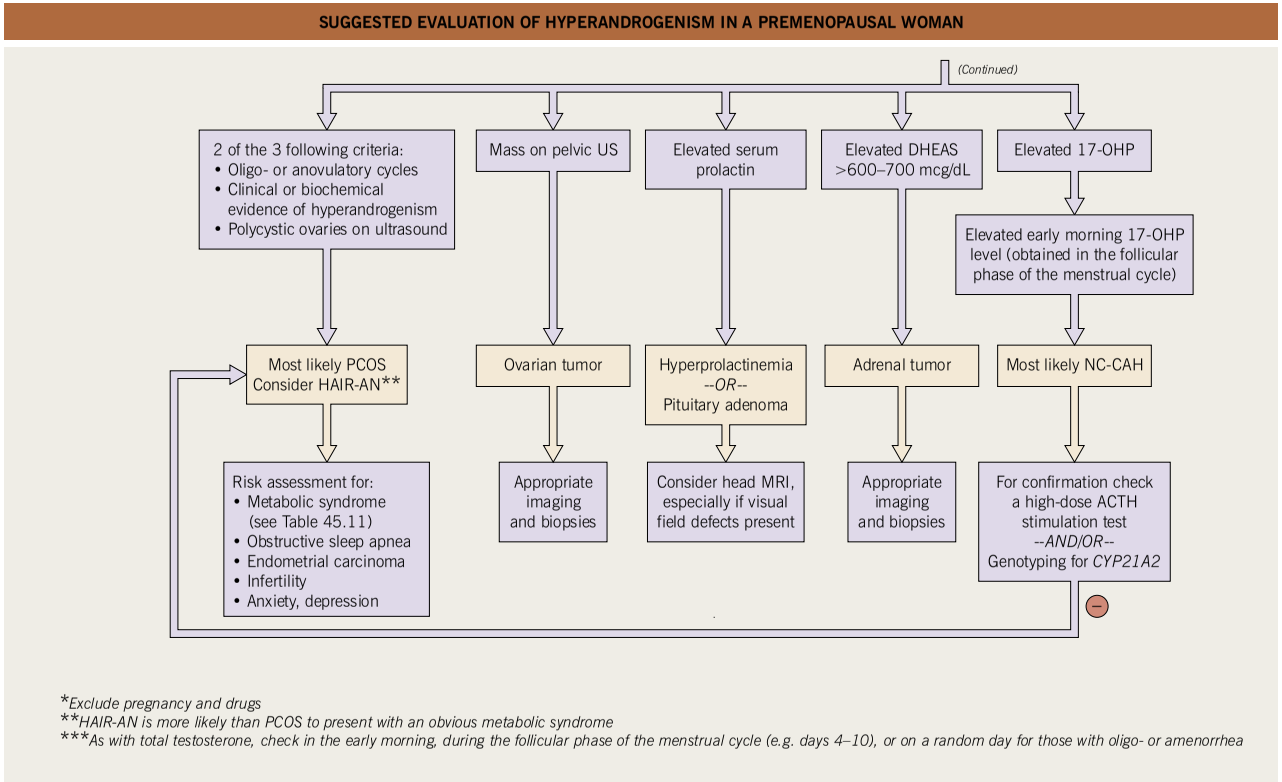


**Fig. 57.11** *Continued* **Suggested evaluation of hyperandrogenism in a premenopausal woman.** 17-OHP, 17-hydroxyprogesterone; ACTH, adrenocorticotropic hormone; HAIR-AN, *h*yper*a*ndrogenism, *i*nsulin *r*esistance, and *a*canthosis *n*igricans; NC-CAH, nonclassic congenital adrenal hyperplasia; PCOS, polycystic ovarian syndrome.



**Fig. 57.12 Hirsutism in a young woman with polycystic ovarian syndrome (PCOS).** Modified Ferriman–Gallwey (mFG) score of 9 based on three sites: chest, upper abdomen, and lower abdomen. *Courtesy, NYUDSC.*



**Fig. 57.13 Facial hirsutism (mFG score 4) due to ovarian hyperthecosis.** *Courtesy, Robert Hartman, MD.*

- Diagnostic clues are extremely elevated levels of testosterone (>200 ng/dl, seen in ovarian and adrenal tumors) or DHEAS (>600–700 mcg/dl, seen in adrenal tumors).
- If suspected, an appropriate imaging study is recommended (e.g. CT scan, MRI, and/or ultrasound).

## HAIR-AN Syndrome

- *H*yper*a*ndrogenism, *i*nsulin *r*esistance, and *a*canthosis *n*igricans syndrome.

| TREATMENT OPTIONS FOR HYPERTRICHOSIS AND UNWANTED HAIR | | |
|---|---|---|
| **Camouflage** | **Hair removal techniques** | **Retardation of hair growth** |
| • Make-up<br>• Lightening of hair color with commercial bleach or 6–12% hydrogen peroxide | **Depletion**<br>***Chemical***<br>1. Barium sulfate creams*<br>2. Calcium thioglycolate creams<br>***Mechanical***<br>1. Hair trimming<br>2. Shaving<br>**Epilation**<br>• Tweezing<br>• Waxing<br>• Threading<br>• Sugaring<br>• Electrolysis**<br>• Thermolysis**<br>• Lasers or other light sources** (e.g. Nd:YAG, diode, alexandrite, IPL) | • Eflornithine hydrochloride cream (best used in conjunction with other hair removal techniques) |

**More effective than calcium thioglycolate but more irritating and odiferous.*
***These epilatory methods are operator-dependent and have the potential for permanent hair removal results.*

**Table 57.2 Treatment options for hypertrichosis and unwanted hair.** Epilation technique results typically last longer than those of depilation. Chemical depilatories work by dissolving hair shafts, specifically by breaking disulfide bonds. IPL, intense pulsed light.

- Marked insulin resistance leads to secondary increased insulin levels and resultant increased ovarian androgen production.
- More likely than PCOS to have overt type 2 diabetes, hypertension, and cardiovascular disease.
- Marked hyperandrogenism and often frank virilization; total testosterone levels are often markedly increased.
- Evaluation involves excluding an androgen-secreting tumor and PCOS.

## Hirsutism Associated with Other Endocrine Abnormalities

- Cushing syndrome, hyperprolactinemia, pituitary adenoma, acromegaly, and thyroid dysfunction may present with hirsutism and other signs of hyperandrogenism, but typically manifest with other distinguishing and diagnostic features specific to the underlying disease (see Ch. 45).

**TREATMENT OF HIRSUTISM AND HYPERANDROGENISM – SYSTEMIC AGENTS AND CLINICAL SCENARIOS**

**Systemic agents**

**Oral contraceptives (OCPs)***
- All OCPs appear to be equally effective for treating hirsutism
- If relatively higher risk for venous thromboembolism (e.g. obesity or age > 39 years), then choose an OCP with the lowest effective dose of ethinyl estradiol (usually 20 mcg) and a low-risk progestin (e.g. norethindrone, levonorgestrel, norgestimate)

**Antiandrogens*****
- Spironolactone 100–200 mg/day (usually given in divided doses, twice daily)
- CPA (cyproterone acetate); given on days 5–15 of menstrual cycle)**
- Finasteride > flutamide (not recommended because of potential hepatotoxicity)

**GnRH agonists** (risk of severe estrogen deficiency)

**Insulin-lowering agents** (e.g. metformin > thiazolidinediones; improves metabolic syndrome and reproductive function but not hirsutism as a single agent)

**Glucocorticoids** (e.g. low-dose hydrocortisone [children], prednisone or dexamethasone [adolescents and adults]; *restricted to second-line treatment of women with NC-CAH or for those seeking ovulation induction*)

| Clinical scenarios and recommended treatment† | | |
|---|---|---|
| Premenopausal female | **First-line**: OCP<br>**Second-line**: OCP + spironolactone or CPA** | **Severe or refractory:** Finasteride or GnRH agonist; plus an OCP if premenopausal |
| Postmenopausal female | **First-line**: Spironolactone or CPA** | |
| NC-CAH | **First-line:** OCP ± spironolactone or CPA**<br>**Second-line or if seeking ovulation induction:** Glucocorticoids | |

*Should avoid in females who smoke or who have risk factors for hypercoagulability and thrombosis.
**CPA is not available in the United States.
***Requires concomitant reliable contraceptive method because of the risk of feminization of the male fetus.
†A waiting period of 6 months is recommended after initiating a treatment and before adding or changing medications.

**Table 57.3 Treatment of hirsutism and hyperandrogenism – systemic agents and clinical scenarios.** For hirsute women with obesity, including those with polycystic ovary syndrome, lifestyle changes are also recommended. GnRH, gonadotropin releasing hormone; NC-CAH, nonclassic congenital adrenal hyperplasia.

For further information see Ch. 70 from *Dermatology, Fourth Edition*.

**For additional online figures and tables visit www.expertconsult.com**



ALGrawany



**eFig. 57.1 Universal hypertrichosis.** Some authors view as simply exaggerated normal hairiness that may be familial. *Courtesy, Francisco M. Camacho Martinez, MD.*

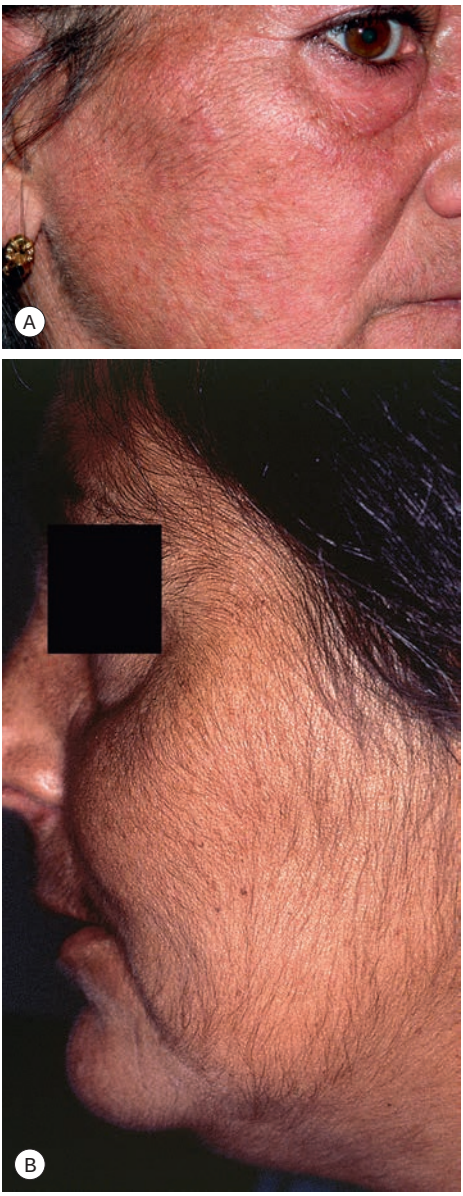


**eFig. 57.2 Facial hypertrichosis due to porphyria cutanea tarda (A, B).** *A, Courtesy, Luis Requena, MD; B, Courtesy, YDRSC.*



**eFig. 57.3 Hypertrichosis in association with Becker melanosis (nevus).** *Courtesy, Jean L. Bolognia, MD.*



**eFig. 57.4 Acquired hypertrichosis lanuginosa.** *Courtesy, Jeffrey P. Callen, MD.*



**eFig. 57.5 Unilateral trichomegaly.** Bimatoprost ophthalmic solution (0.03%) was applied to one eye to treat glaucoma. *Courtesy, Jean L. Bolognia, MD.*

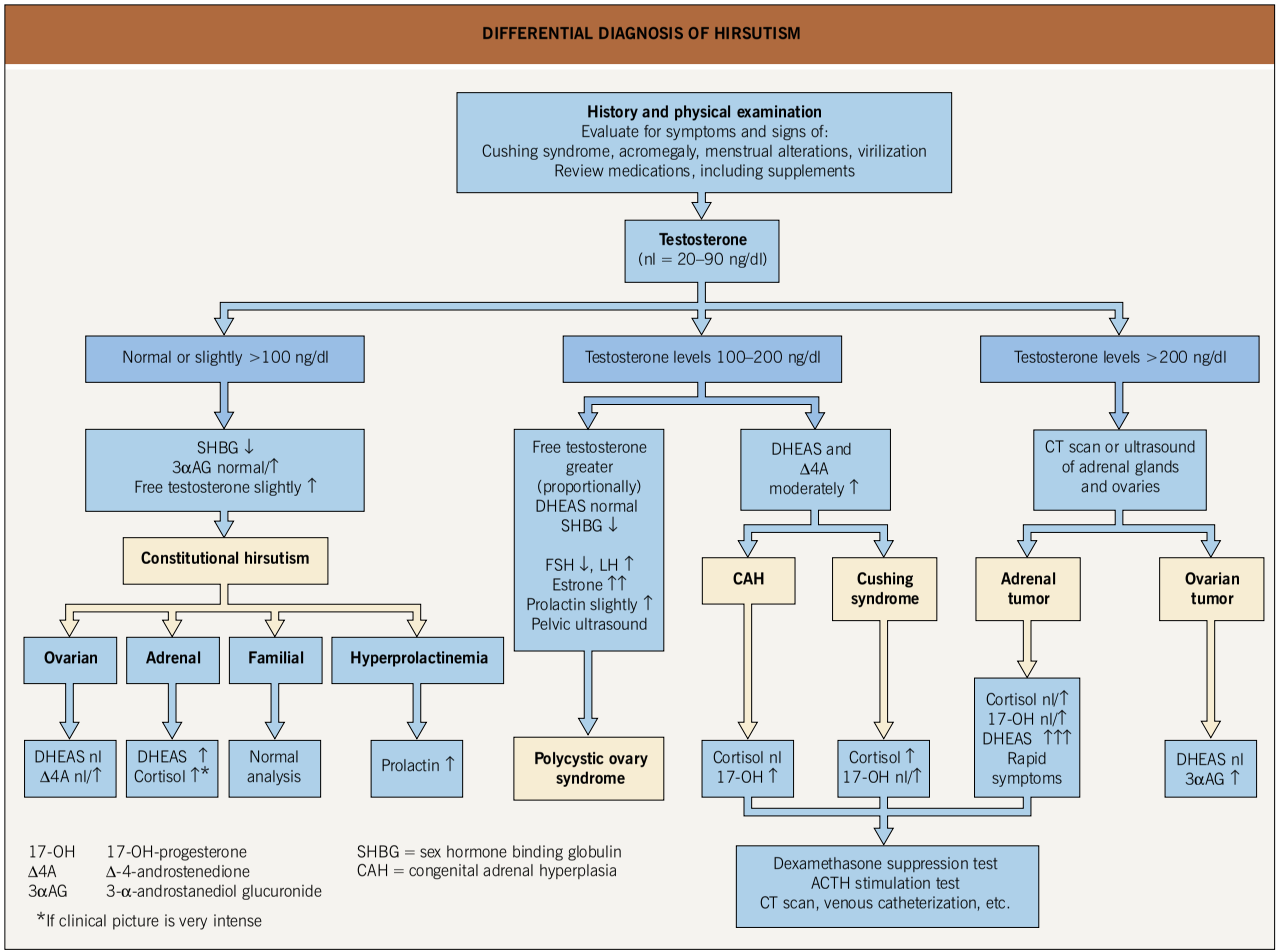


**eFig. 57.6 Differential diagnosis of hirsutism.** The optimum time to assess circulating follicle-stimulating hormone (FSH) and luteinizing hormone (LH) levels is 3–5 days after onset of menses. Δ-4-androstenedione is produced by both the ovaries and the adrenals and represents the major androgen produced by the ovary.

Downloaded for Novin lib (novinlibrary@yahoo.com) at United Arab Emirates University from ClinicalKey.com by Elsevier on March 26, 2022. For personal use only. No other uses without permission. Copyright ©2022. Elsevier Inc. All rights reserved.



**eFig. 57.7 Central hirsutism (mFG score 3 for the lower abdomen) in a woman with adrenal SAHA (*s*eborrhea, *a*cne, *h*irsutism and *a*lopecia) syndrome.** *Courtesy, Francisco M. Camacho Martínez, MD.*

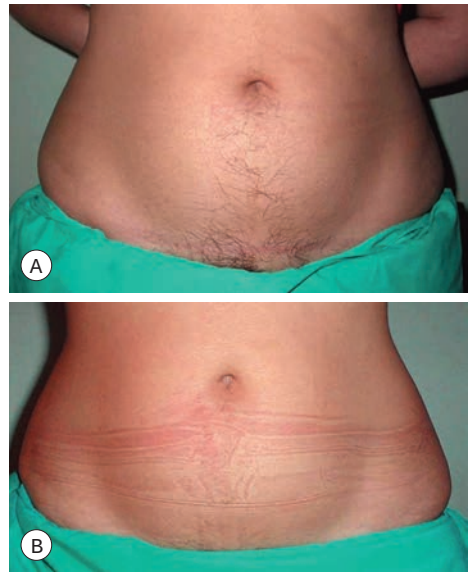


**eFig. 57.8 Adrenal SAHA (*s*eborrhea, *a*cne, *h*irsutism and *a*lopecia) syndrome.** Before (**A**) and after (**B**) finasteride treatment (2.5 mg daily) for one year.

| HYPERTRICHOSIS DUE TO DRUGS | |
|---|---|
| **Antibiotics** | |
| • Streptomycin | |
| **Anti-inflammatory drugs** | |
| • Benoxaprofen | • Corticosteroids |
| **Vasodilators** | |
| • Diazoxide<br>• **Minoxidil** | • Prostaglandin E1 |
| **Diuretics** | |
| • Acetazolamide | |
| **Anticonvulsants** | |
| • **Phenytoin** | |
| **Immunosuppressives** | |
| • **Cyclosporine** | • Mycophenolate mofetil |
| **Psoralens** | |
| • Methoxypsoralen | • Trimethylpsoralen |
| **Antiseptic agents** | |
| • Hexachlorobenzene | |
| **Chelators** | |
| • Penicillamine | |
| **Other** | |
| • Interferon-α<br>• Fenoterol | • EGFR inhibitors (e.g. cetuximab, panitumumab, erlotinib, gefitinib) |
| *Most common drugs are in **bold**.* | |

**eTable 57.1 Hypertrichosis due to drugs.**

# Nail Disorders 58

- The nail matrix, which is the growth area, has proximal and distal components (Fig. 58.1).
  - The proximal nail matrix forms the top (surface) of the nail plate
  - The distal nail matrix forms the underside of the nail plate; therefore, biopsies of the distal matrix are less likely to produce a deformity of the surface of the nail plate
- Fingernails grow ~1–3 mm per month and are replaced every 6 months.
- Toenails grow ~0.5–1 mm per month and are replaced every 12 months.
- Therefore, nail plate abnormalities such as Beau's lines that are due to insults to the nail matrix can be dated by their distance from the cuticle.
- **Rx** of common nail disorders is given in Table 58.1.

| TREATMENT OF COMMON NAIL DISORDERS | |
|---|---|
| **Disorder** | **Treatment** |
| Psoriasis | Systemic treatment of psoriasis may be helpful<br>Topical vitamin D analogues or tazarotene<br>Injection of CS into nail matrix or nail bed<br>Topical CS under occlusion |
| Lichen planus | Injection of CS into nail matrix |
| Beau's lines<br>Onychomadesis | Await spontaneous resolution |
| Paronychia, acute | Incision and drainage (may have occurred spontaneously)<br>If mild, topical mupirocin or retapamulin<br>Oral antibiotics (directed against *Staphylococcus aureus*) |
| Paronychia, chronic | Avoid trauma to cuticle<br>Strict avoidance of irritants<br>Topical CS for 2–3 weeks |
| Onycholysis* | Keep nails short, reduce trauma and friction to nail<br>Strict avoidance of irritants<br>Can consider topical antifungal solution<br>If due to psoriasis, see above |
| Green nails* | 1% acetic acid solution soaks<br>Topical antibiotic (e.g. gentamycin, tobramycin, or ciprofloxacin ophthalmic solution) |
| Onychorrhexis | Topical 20% urea, 12% lactic acid, or retinoids; nail hardener; and/or biotin (2.5 mg PO daily) |
| Ingrown toenails | Correct predisposing factors (e.g. change to a larger toebox)<br>Trim nail properly (straight across)<br>Elevate lateral border of nail with piece of gauze, cotton, or dental floss<br>Warm soaks<br>If severe, matrixectomy (partial or total) |

**Cut back portions of detached nail plate.*

**Table 58.1 Treatment of common nail disorders.**

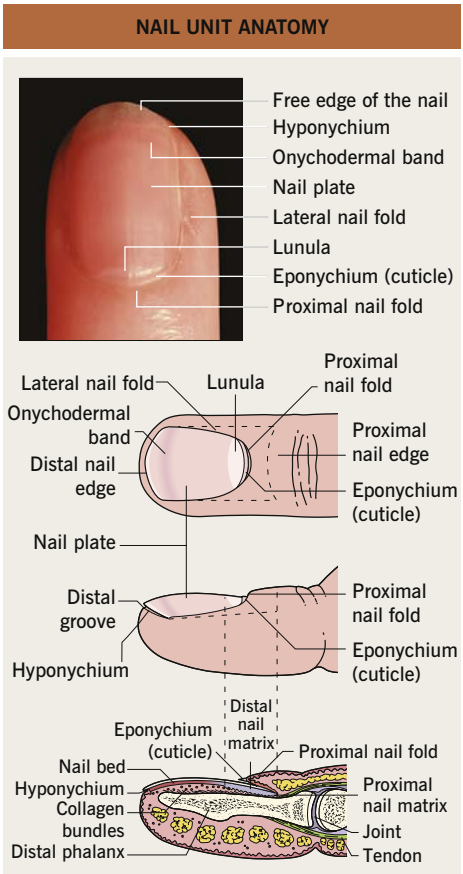


**Fig. 58.1 Nail unit anatomy.**

## Common Nail Findings

### Ingrown Toenails (Onychocryptosis)

- Painful inflammation of lateral fold with growth of granulation tissue.
- Usually due to horizontal overcurvature of the nail plate with aging; most commonly involves the great toes.
- Overgrowth of granulation tissue from systemic medications, e.g. systemic retinoids, can embed the lateral nail plate.
- **Rx:** see Table 58.1.

### Longitudinal Melanonychia



- Longitudinal brown-to-black band.
- Multiple bands common in darker skin types (physiologic); also can be due to trauma (Table 58.2).
- Single band may be a sign of nail melanoma (Table 58.3; Fig. 58.2).
- When melanoma is suspected, the nail matrix must be biopsied (see Fig. 58.1).

| CAUSES OF LONGITUDINAL MELANONYCHIA | |
|---|---|
| Melanocyte activation | Racial |
| | Trauma<br>• Manicures<br>• Nail biting/onychotillomania<br>• Frictional, primarily in toenails |
| | Drugs<br>• Cancer chemotherapeutic agents, e.g. doxorubicin, 5-fluorouracil<br>• Zidovudine (AZT)<br>• Psoralens |
| | Pregnancy |
| | Laugier–Hunziker syndrome/Peutz–Jegher syndrome |
| | Addison disease |
| | HIV infection |
| | Postinflammatory<br>• Lichen planus<br>• Pustular psoriasis<br>• Onychomycosis (*T. rubrum* and *Scytalidium* spp.)<br>• Chronic radiodermatitis |
| Non-melanocytic tumors and proliferations | Bowen disease<br>Verrucae<br>Basal cell carcinoma<br>Subungual keratosis<br>Myxoid cyst |
| Melanocyte hyperplasia | |
| Nail matrix nevus | |
| Nail matrix melanoma | |

**Table 58.2 Causes of longitudinal melanonychia.**

| ABCDEF RULE FOR CLINICAL SUSPICION OF NAIL MELANOMA | |
|---|---|
| A | • Age (peak incidence – 5th to 7th decades of life)<br>• African-Americans, Asians, and Native Americans (of all nail melanoma cases)<br>• Asymmetry |
| B | • Brown to black<br>• Breadth (3 mm or wider)<br>• Borders (variegated, blurred) |
| C | • Change in the nail band (color/size)<br>• Lack of change in the nail morphology despite presumed adequate treatment |
| D | • Digit most commonly involved (thumb and big toe) |
| E | • Extension of the pigment into the proximal and/or lateral nail fold (Hutchinson's sign) |
| F | • Family or personal history of melanoma |

**Table 58.3 ABCDEF rule for clinical suspicion of nail melanoma.** *Adapted from Levit EK, et al. The ABC rule for clinical detection of subungual melanoma. J Am Acad Dermatol 2000;42:269–74; Benati E, et al. Clinical and dermoscopic clues to differentiate pigmented nail bands: an International Dermoscopy Society study. J Eur Acad Dermatol Venereol 2017;31:732–6; Ohn J, et al. Assessment of a predictive scoring model for dermoscopy of subungual melanoma in situ. JAMA Dermatol 2018;154:890–6.*



**Fig. 58.2 Melanoma *in situ* of the nail.** Darkly pigmented band in the nail bed and matrix. *Courtesy, Frank O. Nestle, MD.*

## Onycholysis

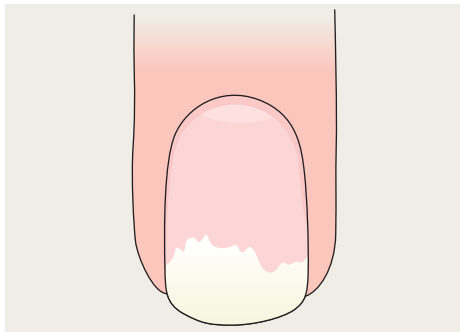



- Distal nail plate detachment, causing nail to look white to yellow-white (Fig. 58.3).
- Additional exogenous pigments beneath the nail plate (e.g. pyocyanin from *Pseudomonas*) may cause yellow to green-black coloration.
- Chronic exposure to water and irritants (e.g. soaps) is a common cause of fingernail onycholysis whereas onycholysis of the great toe is often due to biomechanical forces.
- Associated with psoriasis (see Fig. 6.14), onychomycosis, hyperthyroidism, and medications (Table 58.4).

## Onychomycosis

- See Chapter 64.

## Onychorrhexis

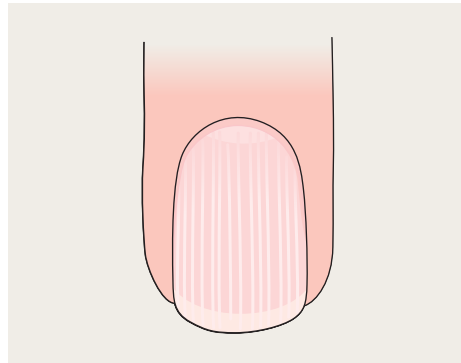

- Thinning and longitudinal ridging.
- May develop fissuring or notching.
- Less pronounced than trachyonychia.
- Sometimes secondary to trauma but more commonly an age-related phenomenon.

## Onychoschizia

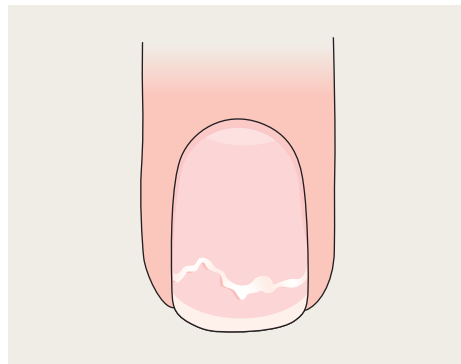

- Lamellar splitting of distal nail into multiple layers.
- Associated with the use of soap and irritants.
- Normal finding with aging.

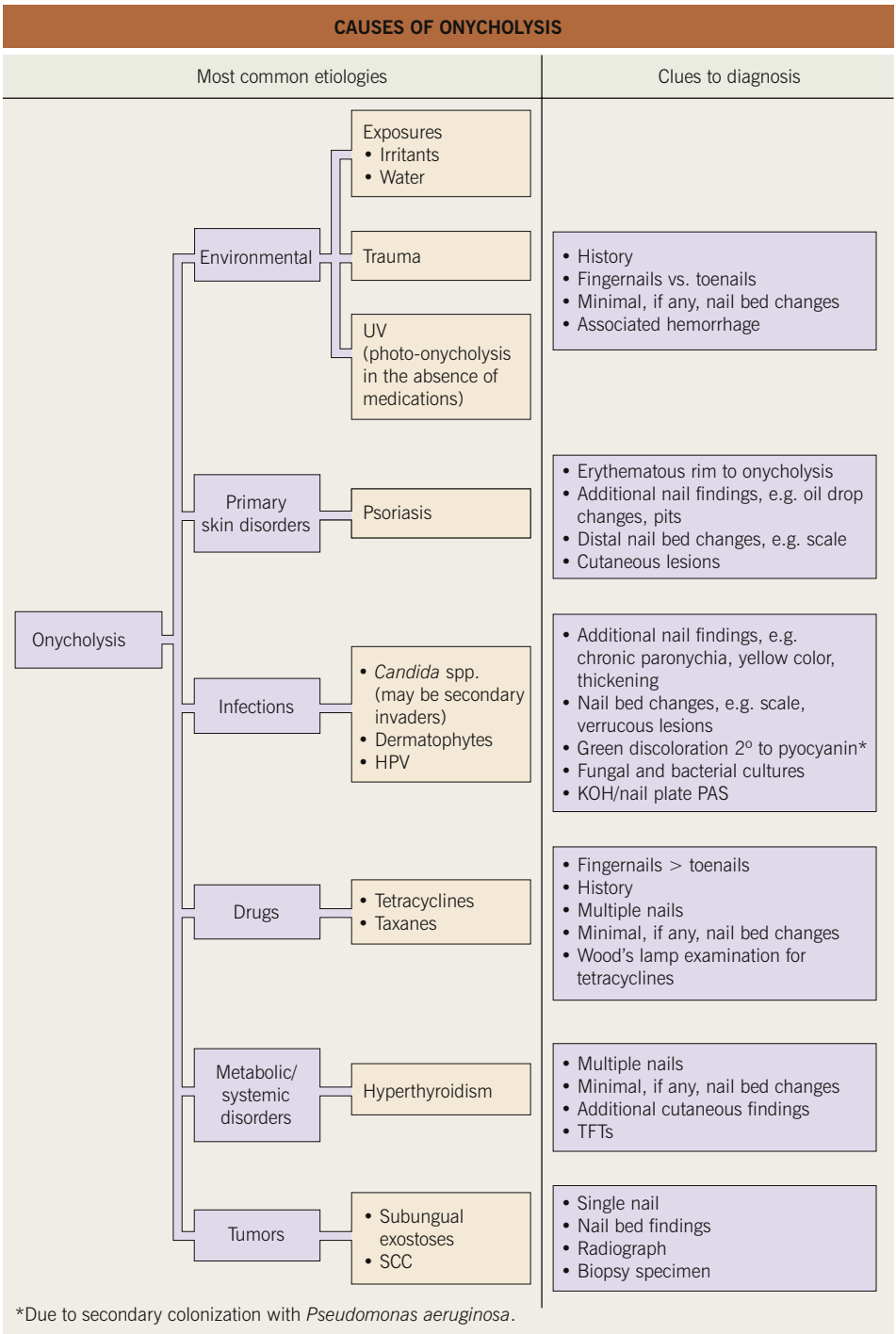


**Fig. 58.3 Causes of onycholysis.** TFTs, thyroid function tests.

| DRUG-INDUCED NAIL ABNORMALITIES | |
|---|---|
| **Nail abnormality** | **Responsible agents** |
| Beau's lines and onychomadesis | Chemotherapeutic agents |
| Onycholysis/photo-onycholysis (see Fig. 58.3) | Chemotherapeutic agents, in particular taxanes<br>Tetracyclines<br>Psoralens<br>NSAIDs |
| Melanonychia | Chemotherapeutic agents<br>Psoralens<br>Zidovudine (AZT) |
| Paronychia and periungual pyogenic granulomas (see Fig. 58.6) | Retinoids<br>Antiretroviral drugs (e.g. indinavir, efavirenz, lamivudine)<br>Epidermal growth factor receptor (EGFR) inhibitors (e.g. cetuximab, panitumumab)<br>Methotrexate<br>Capecitabine<br>Sirolimus |
| True leukonychia | Chemotherapeutic agents |
| Nail thinning and brittleness | Chemotherapeutic agents<br>Retinoids |
| Apparent leukonychia (e.g. Muehrcke's nails) | Chemotherapeutic agents, in particular polychemotherapy including anthracyclines, vincristine |

**Table 58.4 Drug-induced nail abnormalities.**

## Paronychia, Acute



- Swollen nail fold with erythema and pain, sometimes with pustular drainage.
- Caused by bacteria, especially staphylococci.
- Recurrent episodes may be caused by herpes simplex virus infection (herpetic whitlow).

## Paronychia, Chronic

- Chronic proximal nail fold inflammation with loss of cuticle (natural sealant).
- Exacerbated by exposure to water and irritants or overaggressive nail grooming.
- May have secondary *Candida* colonization.

## Subungual Hematoma

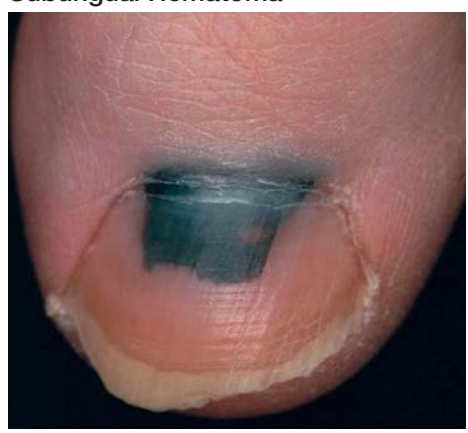

- Purple-red to black color beneath nail plate due to hemorrhage.
- Moves distally with nail growth; if more recent onset, a band of normal nail plate can be seen by pushing back the cuticle.
- Secondary to trauma.

### True Leukonychia

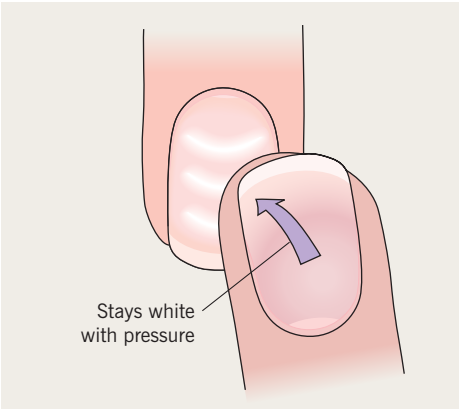


- White discoloration of nail that persists when pressure is applied.
- Punctate form, which is due to trauma, is the most common form.
- Less often, a linear or diffuse pattern is seen.
- Linear bands may be transverse (e.g. Mee's lines, trauma) or longitudinal (e.g. Darier disease).
- Diffuse variant may be inherited and occasionally associated with hearing loss.
- **DDx**: superficial white onychomycosis and apparent leukonychia.

## Less Common Nail Findings

### Beau's Lines

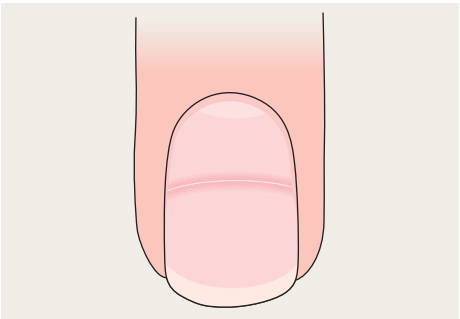



- Transverse depressions in the nail plate.
- Often secondary to trauma, especially when limited to a single digit.
- Consider systemic insult (e.g. high fever, chemotherapy) if multiple nails involved.

### Dorsal Pterygium

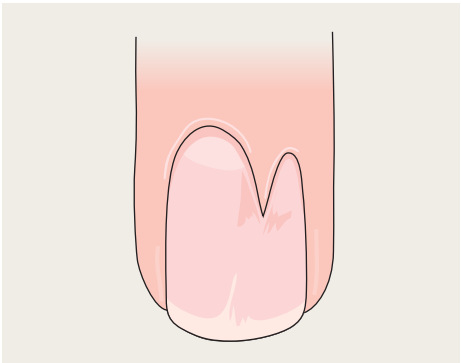

- Triangular extension of the proximal nail fold into the nail bed.
- Local loss of nail plate.
- Most commonly associated with lichen planus (see below); also seen in other disorders (e.g. dyskeratosis congenita).

### Green Nail



- Blue-green to green-black discoloration secondary to pyocyanin produced by *Pseudomonas aeruginosa*.
- Usually in association with onycholysis (creates a favorable moist environment).

### Malalignment

- Lateral deviation of nail plate, often bilateral and congenital.
- Most commonly 1st toe(s).
- May result in ingrown toenails and nail thickening.

## Median Nail Dystrophy (Tic Deformity)







- Multiple transverse grooves with central longitudinal depression that resemble a washboard **(A)**.
- Primarily thumbnail(s).
- Due to manipulation of skin overlying matrix.
- **DDx**: primarily median canaliform dystrophy of Heller which presents as a central longitudinal split with an inverted fir tree pattern **(B)**.

## Onychogryphosis



- Curling of nail plate leads to ram's horn appearance.
- Most commonly nail(s) of 1st toe(s).
- Affects elderly patients.

## Onychomadesis (Nail Shedding)

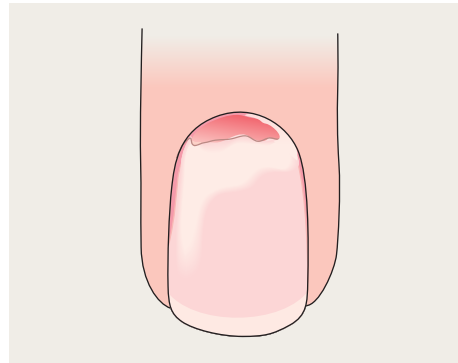



- Proximal detachment of nail plate.
- When single digit, often due to trauma.
- Consider systemic cause (e.g. post-viral, high fever, chemotherapy, post-erythroderma) if multiple nails involved; coxsackie infections are a common cause in children.

## Subungual Exostosis





- Associated with onycholysis and tender subungual nodule.
- Diagnosis confirmed by X-ray.

## Splinter Hemorrhages

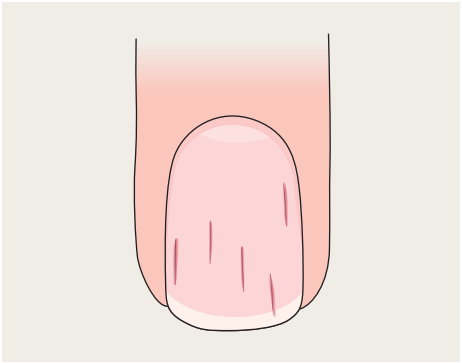

- Thin, longitudinal, dark-red subungual lines.
- Usually secondary to trauma.
- Can be seen in patients with psoriasis or endocarditis.
- Pattern reflects the longitudinal orientation of dermal blood vessels within the nail bed.

## Trachyonychia

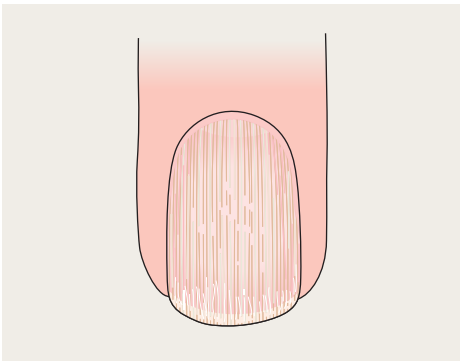



- Rough, "sandpaper" nails, often thin.
- Associated with alopecia areata or lichen planus >> psoriasis.

- May affect most or all nails, especially in children; often termed "20-nail dystrophy."
- **DDx:** onychorrhexis which is a common entity due to longitudinal ridging secondary to aging.

## The Nail in Dermatologic Diseases

### Alopecia Areata

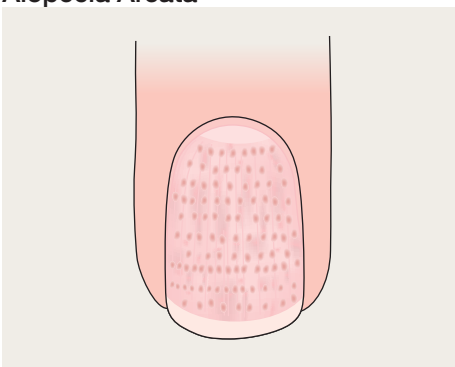

- Pitting, e.g. punctate depressions in nail plate, in a geometric or "scotch-plaid" pattern.
- Compared to psoriasis, pits are smaller and more numerous.
- Additional manifestations include trachyonychia > leukonychia or onychomadesis.

### Darier Disease

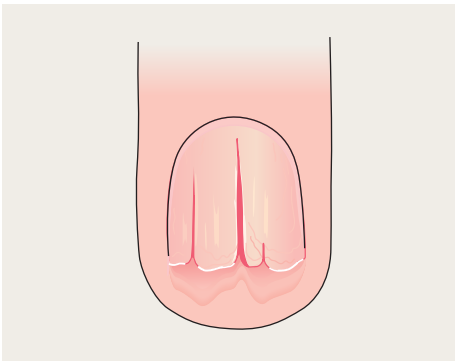



- Alternating longitudinal red and white streaks (i.e. longitudinal erythronychia and leukonychia).
- Distal fissuring (notches).

### Lichen Planus (see Ch. 9)

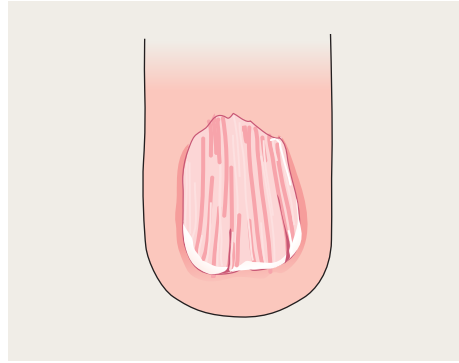



- Thinning of nail plate and atrophy, especially laterally.
- Additional clues include dorsal pterygium and trachyonychia (see above).

### Psoriasis (see Ch. 6)





- Nail changes are often associated with arthritis and enthesitis.
- Pitting, punctate depressions in the nail plate, irregular in size and distribution.
- Oil drop changes which appear as irregular area of yellow-orange discoloration.
- Additional manifestations include yellowing, thickening and crumbling of the nail plate, onycholysis, subungual debris, splinter hemorrhages, paronychia, and rarely pustules (see next section).
- **DDx:** onychomycosis.

### Pustular Psoriasis

- Pustules can form under the nail plate.
- May have lesions of psoriasis on the tips of the digits.

## The Nail in Systemic Diseases

Examples, in addition to those below, are in Table 58.5.

### Apparent Leukonychia

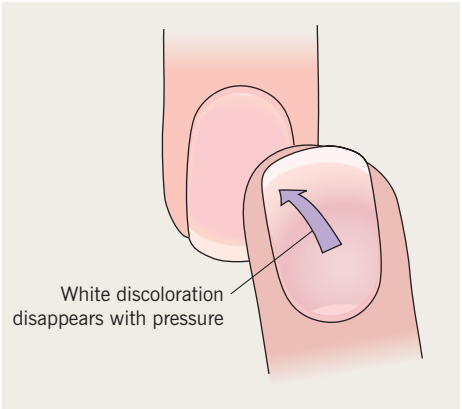




- Nail plate appears white due to alterations in nail bed (e.g. edema).
- Secondary to drugs or systemic disease (e.g. hypoalbuminemia leads to Muehrcke's lines).
- *Terry's nails*: only distal several millimeters of nail plate unaffected; associated with liver disease.
- *Lindsay's nails*: proximal half of nail is white and distal nail is red; associated with renal disease.

| EXAMPLES OF NAIL CHANGES IN SYSTEMIC DISEASES AND GENODERMATOSES | |
|---|---|
| **Nail finding** | **Systemic or genetic disease** |
| Onycholysis | Hyperthyroidism |
| Splinter hemorrhages | Endocarditis |
| Beau's lines/onychomadesis | High fever<br>Viral infection, e.g. coxsackie |
| Various, e.g. characteristic thickening ("door-wedge"), atrophy, partial to complete loss of nails, pterygium | Genodermatoses, e.g. pachyonychia congenita, hidrotic ectodermal dysplasia (see Fig. 52.10), dominant dystrophic epidermolysis bullosa, dyskeratosis congenita |

**Table 58.5 Examples of nail changes in systemic diseases and genodermatoses.** Additional entities are discussed in more detail in the text.

## Koilonychia

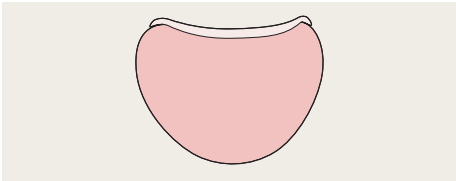

- Spoon-shaped nails.
- Associated with iron deficiency in adults but physiologic in children.

## Clubbing

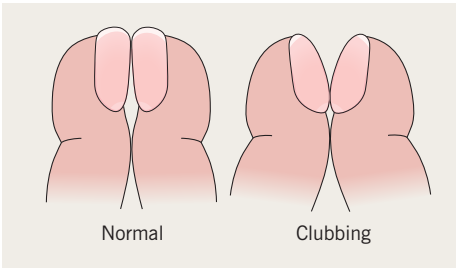




- Bulbous digits with watch-glass nails (>180° angle between proximal nail fold and nail).
- Most commonly seen in thyroid acropachy and in association with cardiovascular and bronchopulmonary disorders (e.g. interstitial lung disease).

## Nail Patella Syndrome

- Hypoplasia of fingernails, greatest on the thumb, least on the fifth digit, triangular lunulae.
- Absent or hypoplastic patella; associated renal disease in up to 40%.

## Proximal Nail Fold (Cuticular) Telangiectasias

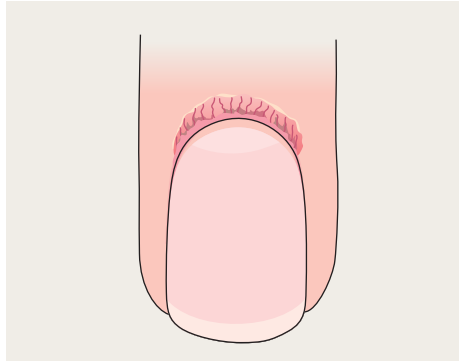



- Capillary prominence ± cuticular hemorrhages.
- Associated with lupus erythematosus and hereditary hemorrhagic telangiectasia.
- Also associated with dermatomyositis and systemic sclerosis, with a slightly different appearance of capillary dropout alternating with dilated capillary loops (see below).
- In dermatomyositis, ragged cuticles may also be present.
- In systemic sclerosis, ventral pterygium (loss of distal subungual space) may be seen.

## Yellow Nail Syndrome

- Yellow coloration of all or most fingernails > toenails (see Fig. 45.1C).
- Loss of cuticle, onychomadesis, overcurvature of nail plate.
- Associated with lymphedema and bronchopulmonary disease.



**Fig. 58.4 Periungual fibroma producing a longitudinal groove due to matrix compression.** *Courtesy, Antonella Tosti, MD.*



**Fig. 58.5 Myxoid cyst.** The longitudinal nail groove is a result of the compression of the nail matrix by the cyst (arrow). *Courtesy, Antonella Tosti, MD.*

## Tumors

• Various cysts, hyperplasias, and tumors may be seen on the distal digits, including fibromas (Fig. 58.4), myxoid cysts (Fig. 58.5, see Fig. 90.10), pyogenic granuloma (Fig. 58.6), glomus tumor (associated with paroxysmal pain) (see Ch. 94), Bowen disease (Fig. 58.7), keratoacanthoma (symptoms include pain, rapid growth), melanoma (signs include longitudinal melanonychia [see Fig. 58.2], Hutchinson's sign = pigmentation of proximal cuticle).



**Fig. 58.6 Multiple periungual pyogenic granulomas in a patient taking indinavir.** Similar lesions can be seen in patients receiving systemic retinoids or epidermal growth factor receptor inhibitors. *Courtesy, Antonella Tosti, MD.*



**Fig. 58.7 Bowen disease.** The lateral portion of the nail plate is absent. The nail bed shows hyperkeratosis with scaling and fissuring of the epithelium. *Courtesy, Antonella Tosti, MD.*

*Additional figure details: onycholysis due to psoriasis; onychomadesis after an episode of acute paronychia; apparent leukonychia represents Muehrcke's lines; multiple Beau's lines were due to repeated cycles of systemic chemotherapy; proximal nail-fold telangiectasias and ragged cuticles due to dermatomyositis.*

*Additional courtesies: Antonella Tosti, Julie V. Schaffer, and Jean L. Bolognia.*

For further information see Ch. 71 from *Dermatology, Fourth Edition*.




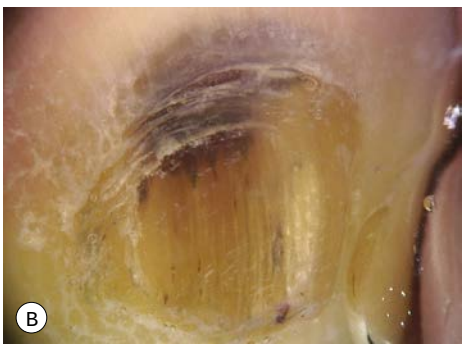


**eFig. 58.1 Subungual hematoma. A** Dark purple-black discoloration of the lateral portion of the proximal nail fold and nail plate of the fifth toe. **B** Dermoscopy shows small red longitudinal splinter hemorrhages and dark purple pigmentation under the proximal nail fold and nail plate due to accumulated blood, with a typical fringed distal edge.







**eFig. 58.2 Traumatic onycholysis of the nail of the first toe. A** Clinical appearance. **B** By dermoscopy, the proximal margin of the nail plate detachment has a linear shape.



**eFig. 58.3 Clubbing in a patient with pachydermoperiostosis (primary hypertrophic osteoarthropathy).** *Courtesy, Dr D. Timaná and Dr J. Valverde, Hospital Docente de Trujillo.*



**eFig. 58.4 Amelanotic melanoma.** Note the diffuse nail destruction and ulceration.



**eFig. 58.5 Onychomadesis of the fingernails following hand-foot-and-mouth disease due to coxsackievirus A6 infection.** *Courtesy, Julie V. Schaffer, MD.*



**eFig. 58.6 Longitudinal melanonychia due to a congenital melanocytic nevus of the nail matrix.** The pigmentation involves approximately 75% of the nail plate and the color varies from light brown to black. *Courtesy, Antonella Tosti, MD.*

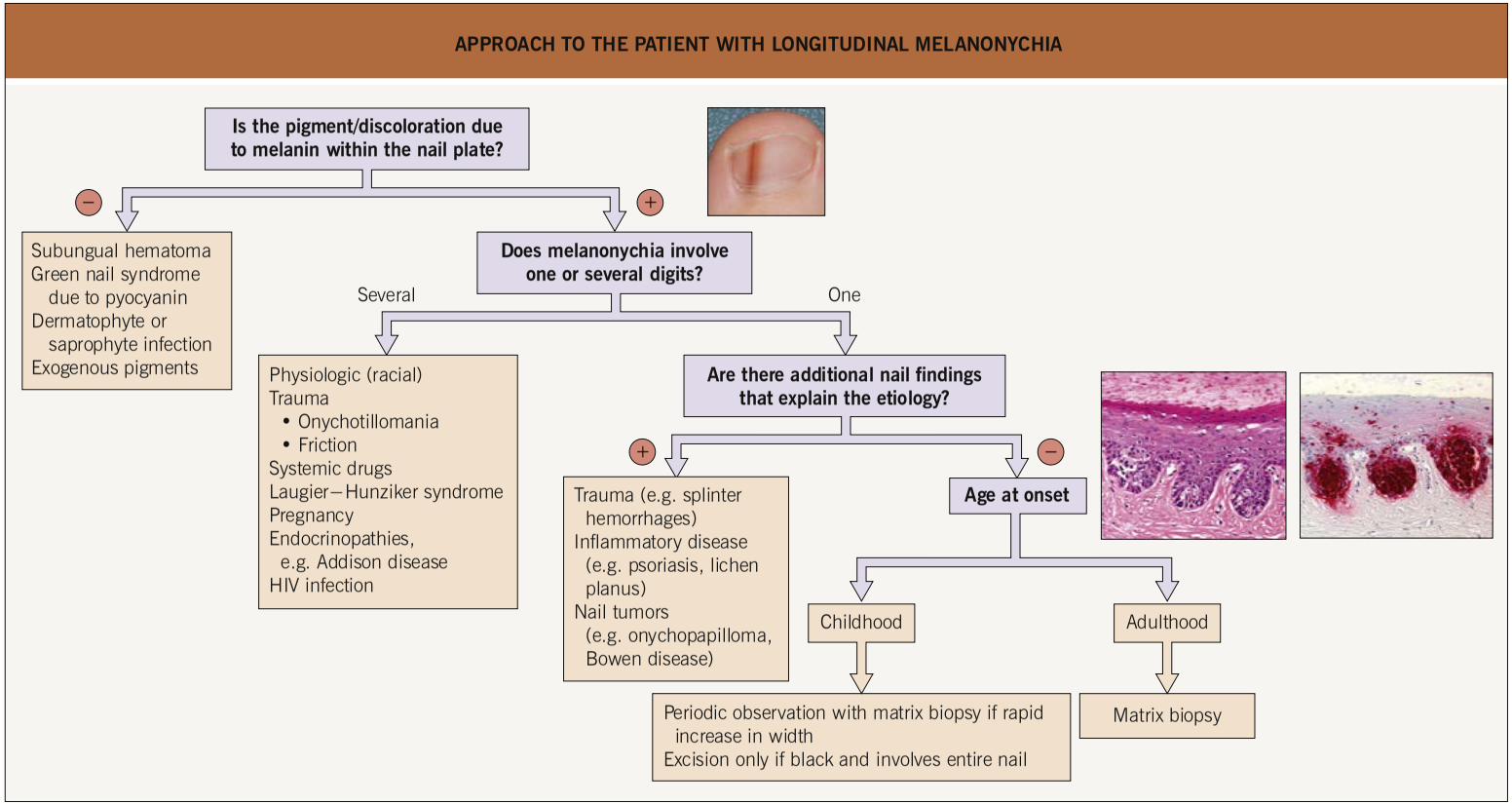


**eFig. 58.7 Approach to the patient with longitudinal melanonychia.** See Table 58.2 for a more extensive list of etiologies.



**eFig. 58.8 Congenital malalignment of the great toenails.** The longitudinal axis of the nail plate is deviated laterally. Note the Beau's lines and initial lateral ingrowing of the nail plate. *Courtesy, Antonella Tosti, MD.*



**eFig. 58.9 Nail hypoplasia in nail–patella syndrome.** There is hypoplasia of the nails of the first and second digits. This gradient of severity of nail involvement is characteristic. *Courtesy, Antonella Tosti, MD.*



**eFig. 58.10 Darier disease.** Alternating longitudinal red and white streaks with wedge-shaped subungual hyperkeratosis, V-shaped notching of the distal margin, and fissuring. *Courtesy, Antonella Tosti, MD.*



**eFig. 58.11 Nail psoriasis.** The nails show "oil drop" changes (salmon patches) and onycholysis with an erythematous border. *Courtesy, Antonella Tosti, MD.*



**eFig. 58.12 Acrodermatitis continua of Hallopeau.** Recurrent pustular eruption of the nail bed and distal finger. *Courtesy, Antonella Tosti, MD.*



**eFig. 58.13 Nail lichen planus.** Note the nail thinning, atrophy, and dorsal pterygium. The index finger has an "angel's wings" deformity. *Courtesy, Antonella Tosti, MD.*



**eFig. 58.14 Muehrcke's nails in a patient undergoing chemotherapy.** There are multiple parallel transverse white bands that will fade with pressure (apparent leukonychia). Note the associated melanonychia. *Courtesy, Antonella Tosti, MD.*



**eFig. 58.15 Yellow nail syndrome.** Note the overcurvature of the nail, both transversely and longitudinally, and loss of the cuticle, in addition to the yellow discoloration.



**eFig. 58.16 Onychotillomania in a patient with depression.** In four of the nails, the nail plate is damaged or absent. The hemorrhagic crusts on the nail bed and proximal nail fold serve as a clue to the diagnosis. *Courtesy, Antonella Tosti, MD.*



**eFig. 58.17 Onychomatricoma.** The nail is thickened and overcurved with longitudinal yellow streaks. The distal border shows several holes. *Courtesy, Antonella Tosti, MD.*



**eFig. 58.18 Onychopapilloma.** Longitudinal erythronychia and leukonychia with focal hemorrhage and a subtle distal notch. The subungual tumor is best appreciated by viewing the nail *en face* at its distal free edge (inset). *Courtesy, Harvey Lui, MD.*



**eFig. 58.19 Amelanotic melanoma.** Note the diffuse nail destruction and ulceration as well as swelling of the proximal nail fold. The tumor can resemble granulation tissue. *Courtesy, Lorenzo Cerroni, MD.*

| NAIL CHANGES ASSOCIATED WITH A MANICURE OR PEDICURE | |
|---|---|
| **Nail abnormality** | **Etiology** |
| Beau's lines | Matrix damage from cuticle removal |
| True leukonychia (transverse) | Matrix damage from cuticle removal |
| Nail brittleness (onychorrhexis, onychoschizia) | Nail varnish solvents; electric drills |
| Nail brittleness (superficial granulation) | Prolonged nail polish wearing |
| Distal onycholysis ("roller coaster") | Mechanical (nail tools utilized to clean the nail plate free edge) |
| Diffuse onycholysis | Mechanical (artificial nails acting as a lever)<br>Chemical (acrylic nails) |
| Discoloration (yellow/orange) | Nail varnishes |
| Acute paronychia | Periungual cuts from sharp instruments |
| Chronic paronychia | Contact allergy |
| Periungual pyogenic granulomas | Constant cuticle removal |
| Periungual warts | Periungual wounds<br>Mechanical trauma to the cuticle |

**eTable 58.1 Nail changes associated with a manicure or pedicure.** *Courtesy, Antonella Tosti and Bianca Maria Piraccini.*

# 59 Oral Diseases

- In addition to common benign lesions such as bite fibromas and mucoceles, oral findings can represent clues to the diagnosis of skin disorders (e.g. lichen planus, early pemphigus vulgaris) or cutaneous signs of systemic disease (Table 59.1). Table 59.2 provides an overview of topical care for oral inflammatory conditions.
- Oral manifestations of infectious diseases (e.g. candidiasis, viral enanthems, findings associated with HIV infection) are covered in the chapters focused on these conditions.

## Common Oral Mucosal Findings

### Fordyce Granules

- "Free" sebaceous glands (i.e. not associated with hair follicles) evident in as many as 75% of adults (Fig. 59.1).
- Multiple 1- to 2-mm yellowish papules on the vermilion lips (upper > lower) and oral mucosa (especially buccal).

### Geographic Tongue (Migratory Glossitis)

- Incidental finding on the dorsum of the tongue in ~2–3% of the population; may occasionally be associated with psoriasis, especially pustular variants.
- Well-demarcated areas of erythema and atrophy of the filiform papillae, surrounded by a whitish, hyperkeratotic serpiginous border (Fig. 59.2); lesions tend to migrate over time, may affect other oral sites, and are occasionally associated with a burning sensation.

### Scrotal (Fissured) Tongue

- Asymptomatic finding that is occasionally associated with conditions such as granulomatous cheilitis (see below) and Down syndrome.
- Multiple grooves or furrows are present on the dorsal tongue, especially centrally (Fig. 59.3).

### Hairy Tongue (Black Hairy Tongue)

- Reflects accumulation of keratin on the dorsum of the tongue; contributing factors may include poor oral hygiene, smoking, and a soft diet.
- Confluence of hairlike projections, which represent elongated papillae, with yellowish to brown-black discoloration (Fig. 59.4); may have exogenous staining from food, tobacco, or chromogenic bacteria (especially following antibiotic therapy); some patients report an unpleasant odor or taste.
- **DDx:** pigmented papillae of the tongue (in individuals with darkly pigmented skin).
- **Rx:** scraping or brushing the tongue.

### Leukoedema

- Normal variant that is more often evident in smokers and individuals with darkly pigmented skin.
- Grayish-white, opalescent, sometimes "moth-eaten" appearance of the buccal > labial mucosa (Fig. 59.5); typically becomes less evident upon stretching.

### Median Rhomboid Glossitis (Central Papillary Atrophy)

- Found in ~1% of adults, usually associated with local candidiasis.
- Well-demarcated diamond- or oval-shaped area of erythema and atrophy on the dorsum of the tongue (Fig. 59.6).
- **Rx:** clotrimazole troches or oral fluconazole (for dosage, see Table 64.5).

## Periodontal and Dental Conditions with Dermatologic Relevance

### Desquamative Gingivitis

- Clinical finding that can occur in several immune-mediated vesicular and erosive disorders (Fig. 59.7); favors women over 40 years of age.

| SYSTEMIC DISEASES WITH ORAL MANIFESTATIONS | |
|---|---|
| **Disorder** | **Oral findings** |
| Primary systemic amyloidosis (see Ch. 39) | • Macroglossia, often with scalloped edges (due to dental impressions) or hemorrhagic papulonodules (see Fig. 39.3); xerostomia |
| Nutritional deficiencies (see Ch. 43) | • Atrophic glossitis (see text), stomatitis<br>• *Scurvy*: gingival enlargement, hemorrhage and erosions (see Fig. 43.7B) |
| Inflammatory bowel disease | • *Crohn disease*: oral cobblestoning and ulcers (aphthous or linear; see Fig. 59.16), angular cheilitis, orofacial granulomatosis (see text)<br>• *Pyostomatitis vegetans* (ulcerative colitis > Crohn): oral pustules and erosions in a "snail track-like" arrangement |
| Behçet disease (see Ch. 21) | • Aphthae (see text) |
| Sarcoidosis (see Ch. 78) | • Orofacial granulomatosis (see text), xerostomia, salivary gland enlargement |
| Sjögren syndrome (see Ch. 37) | • Xerostomia |
| Granulomatosis with polyangiitis (see Ch. 19) | • Gingival hemorrhage with a friable micropapular surface ("strawberry gums"; see Fig. 59.17) |
| Leukemia | • Hemorrhage due to thrombocytopenia, infections (viral, fungal, bacterial), gingival enlargement due to leukemic infiltration (especially in [myelo]monocytic forms) |
| Genodermatoses | • *Tuberous sclerosis complex*: oral fibromas, dental enamel pits<br>• *Cowden syndrome*: oral papillomas favoring lips and tongue (see Fig. 45.3C and 52.1B)<br>• *Multiple endocrine neoplasia type 2B*: mucosal neuromas – papulonodules favoring lips and anterior tongue (see Fig. 52.2B)<br>• *Darier disease*: whitish papules and rugose plaques favoring palate and gingivae (see Fig. 48.8)<br>• *Lipoid proteinosis*: diffuse infiltration or cobblestoned papules favoring lips and tongue/frenulum, xerostomia (see Fig. 40.4B)<br>• *Chronic mucocutaneous candidiasis* (see Fig. 49.3A)<br>• *Classic hyper-IgE syndrome*: retention of primary teeth, candidiasis<br>• *Ectodermal dysplasias*: hypodontia, cone-shaped teeth<br>• *Basal cell nevus syndrome*: odontogenic keratocysts of mandible > maxilla<br>• *Gardner syndrome*: osteomas of maxilla and mandible<br>• Peutz–Jeghers syndrome: brown macules on lips and oral mucosa (see Fig. 45.3B) |

**Table 59.1 Systemic diseases with oral manifestations.**

• Diffuse gingival erythema with varying degrees of sloughing and erosion; frequently painful.
• Because desquamative gingivitis is often a manifestation of mucous membrane (cicatricial) pemphigoid and other autoimmune bullous disorders, evaluation should include routine histology plus direct and indirect immunofluorescence studies (see Ch. 23).
• **Rx:** treatment of underlying condition plus meticulous oral hygiene.

## Gingival Enlargement (Hyperplasia, Overgrowth)

• Systemic medications and other causes of gingival enlargement are listed in Table 59.3.
• Drug-related gingival enlargement typically develops during the first year of

| TOPICAL CARE FOR ORAL INFLAMMATORY CONDITIONS |
|---|
| **Oral hygiene** |
| Soft toothbrush<br>Water pick, soft-tipped gum pick, or waxed tape-type dental floss to remove plaque<br>Non-alcohol-based mouthwash<br>Avoid trauma, e.g. sharp/rough dental restorations/appliances or biting cheeks |
| **Topical anesthetics for erosions/ulcers** |
| 2% viscous lidocaine (to surface of ulcers or as swish & spit)<br>"Magic mouthwash" with equal parts of: (1) 2% viscous lidocaine; (2) diphenhydramine 12.5 mg/5 ml; (3) magnesium and aluminum hydroxide plus sucralfate (Maalox®); consider adding dexamethasone elixir and/or nystatin suspension<br>Dyclonine lozenges (e.g. Sucrets®)<br>Benzocaine gel or lozenges |
| **Topical anti-inflammatory medications** |
| Corticosteroids, e.g. clobetasol 0.05% gel/ointment, fluocinonide 0.05% gel/ointment, triamcinolone 0.1% paste BID<br>Dexamethasone elixir 0.5 mg/5 ml, swish and spit 5 ml BID–TID (leaving in mouth for 5 minutes)*<br>Corticosteroid inhaler BID<br>Tacrolimus 0.1% ointment BID<br>Tacrolimus 1 mg capsule dissolved in 0.5–1 L of water, swish and spit 5 ml BID (leaving in mouth for ≥2 minutes)* |
| **Prevention of secondary infection**** |
| Clotrimazole 10 mg troches 4 times/day<br>Nystatin suspension (400,000–6000,000 units), swish and swallow 4 times/day<br>Chlorhexidine 0.12% oral rinse, swish and spit BID<br>Dilute hydrogen peroxide (one part 3% solution, 2 parts water), swish and spit BID |
| **Especially for patients with more widespread involvement.*<br>***Consider for patients with extensive oral erosion/ulceration, especially if using topical or systemic immunosuppressive agents.* |

**Table 59.2 Topical care for oral inflammatory conditions.**



**Fig. 59.1 Fordyce granules.** Multiple yellowish 1- to 2-mm papules on the vermilion portion of the upper lip, representing "free" sebaceous glands. *Courtesy, Carl M. Allen, MD, and Charles Camisa, MD.*

administration and is first evident in the interdental papillae.

## Dental Sinus

- Occurs in the setting of a chronic periapical abscess in a carious tooth.



**Fig. 59.2 Geographic tongue.** A florid example, demonstrating well-delineated areas of erythema partially surrounded by white serpiginous borders. *Courtesy, Carl M. Allen, MD, and Charles Camisa, MD.*

- *Intraoral ("parulis")*: soft, nontender, erythematous papule on the alveolar process in the region of the affected tooth.
- *Cutaneous*: erythematous papule, often with an umbilicated or ulcerated center; found on the chin or submandibular region (mandibular teeth) > the cheek or upper lip (maxillary teeth) (Fig. 59.8).



**Fig. 59.3 Fissured tongue.** Numerous asymptomatic furrows and grooves on the dorsal tongue. *Courtesy, Carl M. Allen, MD, and Charles Camisa, MD.*



**Fig. 59.4 Hairy tongue.** The dorsum of the tongue exhibits marked accumulation of keratin and brown discoloration. *Courtesy, Carl M. Allen, MD, and Charles Camisa, MD.*



**Fig. 59.5 Leukoedema.** Diffuse grayish-white and wrinkled appearance of the buccal mucosa. These findings disappear when the cheek is stretched. *Courtesy, Carl M. Allen, MD, and Charles Camisa, MD.*

## Sequelae of Trauma or Toxic Insults

### Fibroma (Bite Fibroma)

- Results from reactive connective tissue hyperplasia in response to local trauma.
- Smooth pink papulonodule; most often located on the labial mucosa, especially of the lateral lower lip, or along the "bite line" of the buccal mucosa.
- **Rx:** if bothersome, excision with histologic evaluation to exclude a neoplastic condition.



**Fig. 59.6 Median rhomboid glossitis.** On the dorsum of the tongue (anterior to the circumvallate papillae), there is a well-demarcated, smooth area with loss of the filiform papillae. *Courtesy, NYUDSC.*

### Morsicatio Buccarum (Chronic Cheek Chewing)

- Characteristic mucosal changes related to habitual chewing or biting.
- Shaggy white mucosa, usually bilaterally in the buccal region along the "bite line" (Fig. 59.9).

### Mucocele

- Translucent to bluish papule due to disruption of a minor salivary gland duct, most often located on the lower mucosal lip (Fig. 59.10; see Ch. 90).

### Chemotherapy- and Radiation Therapy-Induced Mucositis

- Results from cytotoxic effects on the oral epithelium, especially in the setting of neutropenia; typically develops 4–7 days after administration of chemotherapy and ≥2 weeks after beginning radiation therapy.

## DIFFERENTIAL DIAGNOSIS OF DESQUAMATIVE GINGIVITIS





**Differential diagnosis of desquamative gingivitis***

| Lichen planus (LP)<br>Lichenoid drug reaction<br>Lupus erythematosus (LE)<br>GVHD | Autoimmune bullous disorder – mucous membrane (cicatricial) pemphigoid, pemphigus vulgaris, paraneoplastic pemphigus<br>> EBA, BP, LABD | Erythema multiforme, fixed drug eruption | Chronic ulcerative stomatitis | Contact dermatitis, allergic or irritant | Lichenoid contact stomatitis, lichenoid foreign body gingivitis |
|---|---|---|---|---|---|
| • Lacy white plaques (e.g. Wickham striae) of oral &/or other mucosae<br>• Correct clinical setting for LE or GVHD<br>• Appropriate medication history | • Erosions, ulcers & occasionally vesicles/ bullae of oral &/or other mucosae<br>• Ragged ulcers → pemphigus; smooth but irregular ulcers → mucous membrane pemphigoid | • Erosions, ulcers & occasionally vesicles/ bullae of oral &/or other mucosae**<br>• Recurrent episodes | • Clinically, resembles oral erosive LP, but asymmetric distribution of lesions & striae less sharply defined | • Need to look for unusual causes (e.g. nail polish in nail biters, sucking on metal objects) | • Lesions may result from exposure to cinnamon flavoring in food, beverage, and oral hygiene products; embedded particles from dentifrices and dental restorative materials in foreign body gingivitis |

*Some entities may have cutaneous lesions.
**Erythema multiforme is more likely to affect other mucosal sites (e.g. genital, ocular).

**Fig. 59.7 Differential diagnosis of desquamative gingivitis.** If the gingivae are painful, hemorrhagic, and necrotic with punched-out interdental papillae, then necrotizing ulcerative gingivitis (trench mouth) should also be considered. BP, bullous pemphigoid; EBA, epidermolysis bullosa acquisita; LABD, linear IgA bullous dermatosis. *Courtesy, Carl M. Allen, MD, and Charles Camisa, MD.*



**CAUSES OF GINGIVAL ENLARGEMENT (HYPERPLASIA, HYPERTROPHY)**



| Systemic medications |
|---|
| • Phenytoin (~50%) > other anticonvulsants<br>• Cyclosporine (~25%)*<br>• Nifedipine (~25%) > other calcium channel blockers<br>• Others – e.g. amphetamines, estrogens |
| **Other etiologies** |
| • Poor oral hygiene**, periodontal disease<br>• Hormone-related – pregnancy, acromegaly<br>• Orofacial granulomatosis (see text)<br>• Granulomatosis with polyangiitis (friable "strawberry" gums)<br>• Scurvy<br>• Genetic disorders – e.g. tuberous sclerosis complex, Cowden syndrome, hereditary gingival fibromatosis<br>• Malignancies – e.g. leukemia, Kaposi sarcoma<br>• Deposition – e.g. primary systemic amyloidosis |

*Consider substitution with oral tacrolimus.
**Often contributes to gingival enlargement related to drugs and other factors.

**Table 59.3 Causes of gingival enlargement (hyperplasia, hypertrophy).** *Insert images, courtesy, YDRSC.*

• Multiple erosions and/or ulcerations favor the gingivae, lateral tongue, and buccal mucosa; self-limited.
• **DDx:** herpetic or candidal infections (may be concomitant).
• **Rx:** topical anesthetics, analgesics, maintenance of oral hygiene; palifermin (recombinant human keratinocyte growth factor) can reduce severity but produces whitish discoloration of the dorsum of the tongue due to hyperkeratosis.

## Cheilitis

• The differential diagnosis of cheilitis and clues to determining the etiology are outlined in Fig. 13.5; granulomatous cheilitis is discussed below.
• *Cheilitis glandularis*, seen primarily in men with actinic cheilitis and/or lip irritation, is characterized by tiny red macules on the lower labial mucosa at sites of inflamed salivary ducts.

## Other Inflammatory Conditions

### Aphthae (Aphthous Stomatitis; Canker Sores)

• Common condition characterized by recurrent oral ulcers, with a peak prevalence during the second and third decades of life; outbreaks may be triggered by trauma, psychological stress, or hormonal fluctuations.
• *Minor aphthae* (most frequent form): painful, round to ovoid, shallow ulcers that are usually <5 mm in diameter; feature a yellowish-white to gray pseudomembranous base, well-defined border, and prominent erythematous rim (Fig. 59.11); favor the buccal or labial mucosa and typically heal in 1–2 weeks without scarring.
• *Major aphthae*: larger (>1 cm), deeper ulcers that persist for up to 6 weeks; occasionally affect keratinized mucosa (e.g. dorsum of tongue, hard palate, attached gingiva) as well as non-keratinized mucosa, may heal with scarring, and are more common in HIV-infected individuals.




**Fig. 59.8 Cutaneous sinuses of dental origin. A, B** Extraoral drainage of sinuses originating from periapical dental abscesses within the mandible. These sinuses channel through the overlying skin. They may be mistaken for a pyogenic granuloma, cutaneous infection, or neoplasm. *A, Courtesy, Judit Stenn, MD; B, Courtesy, Carl M. Allen, MD, and Charles Camisa, MD.*



**Fig. 59.9 Cheek chewing (morsicatio buccarum).** Repetitive nibbling of the superficial layers of the epithelium resulted in these changes. Note that the characteristic shaggy, white lesion approximates the area where the upper and lower teeth meet. *Courtesy, Carl M. Allen, MD, and Charles Camisa, MD.*



**Fig. 59.10 Mucocele.** Soft nodule with bluish hue in a typical location: lower lateral labial mucosa. *Courtesy, Carl M. Allen, MD, and Charles Camisa, MD.*

- *Herpetiform aphthae*: simultaneous development of numerous small lesions that tend to coalesce; tends to favor non-keratinized mucosa, unlike recurrent oral HSV, which favors keratinized mucosa.
- *Complex aphthosis*: frequent outbreaks of multiple (≥3) oral aphthae, or recurrent genital as well as oral aphthae, in the absence of Behçet disease (see Ch. 21).
- Recurrent aphthae can occur in the setting of systemic disorders such as inflammatory bowel disease, SLE, Behçet disease, cyclic neutropenia, and PFAPA (*p*eriodic *f*ever, *a*phthous stomatitis, *p*haryngitis and *a*denitis) syndrome (see Table 59.1).
- **DDx:** in addition to associated systemic conditions, may include HSV infection, trauma, and the disorders listed in Fig. 59.7.
- **Rx:** superpotent topical CS gel, CS inhaler, topical analgesics (see Table 59.2); if severe or frequent recurrences: colchicine, dapsone, thalidomide (the latter is especially helpful for major aphthae).



**Fig. 59.11 Recurrent aphthous stomatitis.** Shallow, creamy-white ulceration surrounded by an intensely red halo and located on non-keratinized mucosa, representing a classic presentation. *Courtesy, Carl M. Allen, MD, and Charles Camisa, MD.*



**Fig. 59.12 Orofacial granulomatosis.** Note the swelling of the lips (lower > upper) and angular cheilitis in this 10-year-old boy with Crohn disease. *Courtesy, Julie V. Schaffer, MD.*

### Granulomatous Cheilitis and Other Forms of Orofacial Granulomatosis

- The term *orofacial granulomatosis* refers to non-infectious, non-necrotizing granulomatous inflammation of the lips, face, and/or oral cavity; this term includes isolated granulomatous cheilitis as well as manifestations of Crohn disease and sarcoidosis (see Table 59.1); usually develops during the second or third decade of life.
- *Granulomatous cheilitis* presents as diffuse swelling of the lip(s) (lower > upper or both) that can initially be intermittent (raising the possibility of angioedema) but is eventually persistent (Fig. 59.12); patients may have oral cobblestoning, recurrent aphthae, and gingival enlargement. The less frequent association with a scrotal tongue and/or facial nerve palsy is referred to as *Melkersson–Rosenthal syndrome.*
- **Rx:** intralesional CS, topical calcineurin inhibitors, dapsone, tetracyclines (given for several months), thalidomide, or TNF inhibitors (for severe disease); patients should be evaluated for Crohn disease and sarcoidosis.

### Contact Stomatitis

- Irritant or allergic contact stomatitis can result from a variety of foods, food additives, materials used in dentistry, chewing on metal objects, and propylene glycol from vaping; in particular, cinnamon flavoring and dental amalgam ("silver" fillings) can lead to a lichenoid mucositis histologically.
- Shaggy white or erythematous areas, most often on the buccal mucosa or lateral tongue; lacy white streaks (resembling lichen planus) or erosions may be seen (Fig. 59.13).
- **Rx:** evaluation with patch testing and avoidance of offending agents, sometimes requiring replacement of amalgam with other materials.

### Nicotine Stomatitis

- Presents as gray-white discoloration of the palate, often with umbilicated papules that represent inflamed salivary ducts (Fig. 59.14).

### Atrophic Glossitis

- Manifestation of candidiasis and several nutritional deficiencies, e.g. vitamin $B_{12}$ (pernicious anemia), folate, iron, niacin (pellagra), and riboflavin (see Ch. 43).
- Presents with a smooth, "beefy red" tongue (Fig. 59.15); involvement may initially be patchy but is eventually diffuse and may be associated with a burning sensation or sore mouth.

## Oral Signs of Systemic Disease

- Systemic diseases that can present with oral findings are listed in Table 59.1 (Figs 59.16 and 59.17).



**Fig. 59.13 Contact stomatitis from artificial cinnamon flavoring.** Use of artificial cinnamon-flavored gum caused this shaggy, white keratotic lesion of the buccal mucosa. *Courtesy, Carl M. Allen, MD, and Charles Camisa, MD.*



**Fig. 59.16 Crohn disease.** Linear ulceration of the mandibular vestibule is the classic oral manifestation of this disease. *Courtesy, Carl M. Allen, MD, and Charles Camisa, MD.*



**Fig. 59.14 Nicotine stomatitis.** Gray-white palatal mucosa with numerous umbilicated papules representing inflamed palatal salivary glands. *Courtesy, Carl M. Allen, MD, and Charles Camisa, MD.*



**Fig. 59.17 Granulomatosis with polyangiitis – strawberry gums.** The affected areas of the gingiva are red-purple, micropapular, and friable, with a resemblance to ripe strawberries. *Courtesy, Carl M. Allen, MD, and Charles Camisa, MD.*



**Fig. 59.15 Atrophic glossitis due to pernicious anemia plus candidiasis.** Erythematous, atrophic tongue as a manifestation of pernicious anemia with a superimposed candidal infection. *Courtesy, Carl M. Allen, MD, and Charles Camisa, MD.*

## Premalignant and Malignant Conditions

### Leukoplakia and Erythroplakia

- *Leukoplakia* refers to a white patch or plaque on the oral mucosa that cannot be clinicopathologically characterized as a specific disease process; typically occurs in middle-aged and older adults (men > women), especially those who use tobacco ± alcohol, and is regarded as a premalignant condition for SCC.
  - Often a homogeneous white patch or plaque, but may be non-homogeneous and "speckled" (e.g. white flecks on a red base); usually has sharply demarcated borders (Fig. 59.18)



**Fig. 59.18 Leukoplakia.** Sharply demarcated, white plaque involving the ventral surface of the tongue and floor of the mouth. *Courtesy, Carl M. Allen, MD, and Charles Camisa, MD.*



**Fig. 59.19 Squamous cell carcinoma.** Ulcerated, indurated, exophytic mass involving the right lateral border of the tongue, a typical presentation and site for this tumor. *Courtesy, Carl M. Allen, MD, and Charles Camisa, MD.*

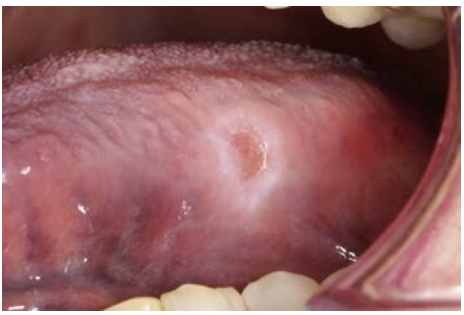

**Fig. 59.20 Traumatic ulcer.** This lesion on the lateral tongue demonstrates a yellow fibrinous base with a white hyperkeratotic border. Compare this to the oral SCC depicted in Fig. 59.19, which presented as an ulcerated, indurated mass. *Courtesy, Carl M. Allen, MD, and Charles Camisa, MD.*

- Similarly, *erythroplakia* is defined as a red intraoral patch or slightly elevated, velvety plaque that cannot be diagnosed as a particular disease; biopsies usually show more severe epithelial dysplasia than leukoplakia.
- Often affects the buccal mucosa, lower inner lip, floor of the mouth, and lateral or ventral tongue.
- The degree of histologic epithelial dysplasia influences the risk of transformation to SCC; non-homogeneous leukoplakia, erythroplakia, and lesions located on the floor of the mouth or lateral/ventral tongue also have higher malignant potential.
- **DDx** of leukoplakia: may include SCC, lichen planus, candidiasis, morsicatio buccarum (see above), and nicotine or contact stomatitis.
- After elimination of possible causative factors (e.g. tobacco use, candidiasis, irritation/trauma) for 2–6 weeks, persistent lesions should be biopsied.
- **Rx:** for leukoplakia with moderate to severe dysplasia or in high-risk sites and for erythroplakia – excision, cryosurgery, or laser ablation; all patients need longitudinal evaluation and should avoid carcinogenic habits.
- *Proliferative verrucous leukoplakia*, which tends to occur in women without traditional risk factors, is characterized by multifocal red and white patches that eventually develop a verrucous surface; difficult to treat and associated with high risk of transformation to SCC.

## Squamous Cell Carcinoma

- Most common malignancy of the oral cavity, favoring middle-aged and older men; risk factors include tobacco and alcohol use, HPV infection (see Ch. 66), and betel nut chewing.
- May present as an ulcer, exophytic mass, or area of induration; most often on the lateral or ventral tongue and floor of the mouth (Fig. 59.19).
- **DDx:** leukoplakia, traumatic ulcer (Fig. 59.20), salivary gland tumor, amelanotic melanoma.
- **Rx:** combinations of surgery, radiation therapy (especially if HPV-associated), and chemotherapy.
- *Verrucous carcinoma* (*oral florid papillomatosis*) is a low-grade variant of SCC that presents as slowly growing, exophytic papillomatous masses that favor the buccal mucosa and gingiva; **Rx:** excision, traditionally

avoiding radiation therapy due to a possible association with anaplastic transformation.

## Melanoma

- Uncommon oral malignancy that favors middle-aged and older men; often diagnosed at a locally advanced stage.
- Pigmented (with findings similar to cutaneous melanoma; see Ch. 93) > amelanotic, with a predilection for the hard palate and maxillary gingivae.
- **DDx:** for pigmented lesions – foreign body tattoo (Fig. 59.21), blue nevus, oral melanotic macule, physiologic pigmentation.



**Fig. 59.21 Amalgam tattoo.** Foreign body tattoos are the most common cause of acquired oral pigmentation, and most of them are due to implantation of dental amalgam. In this patient, the amalgam was used to seal the apices of endodontically treated teeth, resulting in tattooing of the maxillary vestibule. *Courtesy, Carl M. Allen, MD, and Charles Camisa, MD.*

For further information see Ch. 72 from *Dermatology, Fourth Edition*.

**For additional online figures and tables visit www.expertconsult.com**

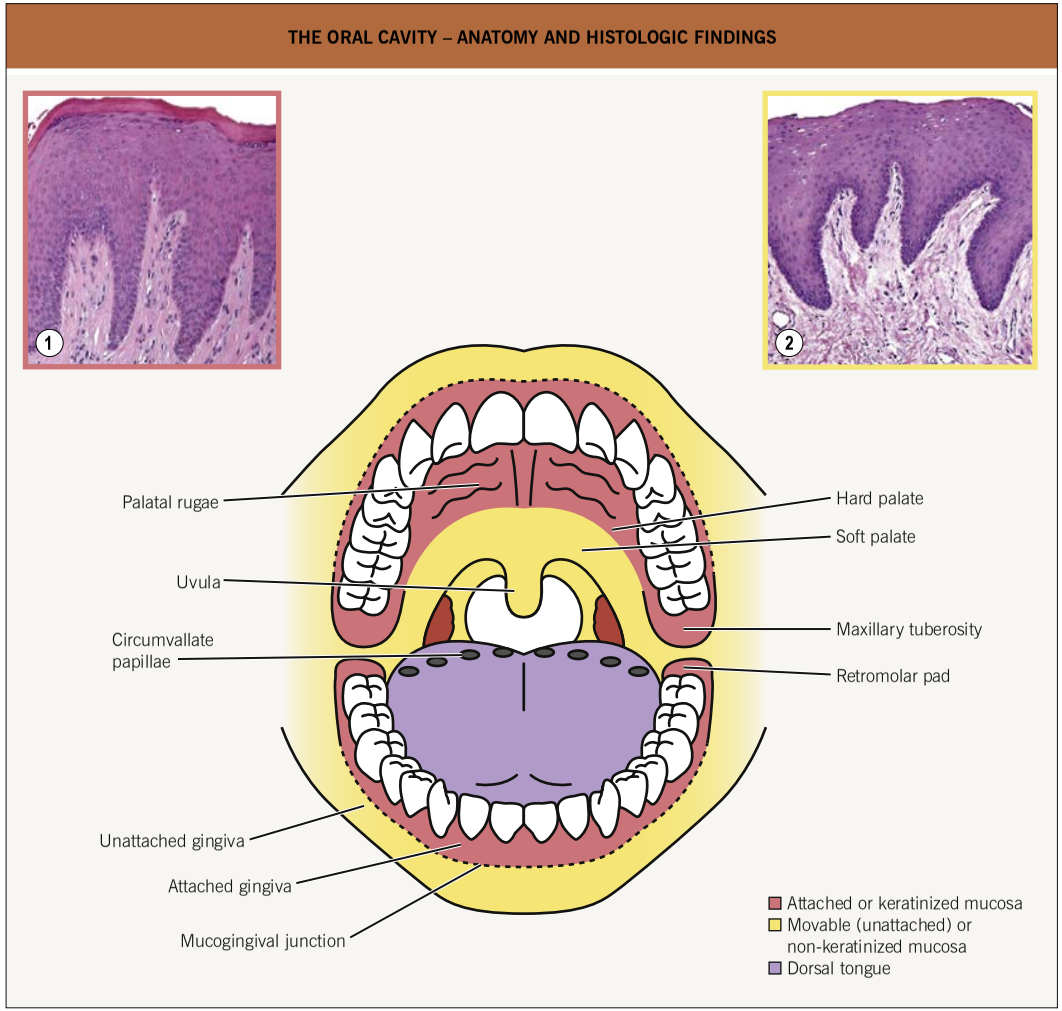


**eFig. 59.1 The oral cavity – anatomy and histologic findings.** Pink represents attached mucosa, yellow represents movable mucosa, and purple the dorsal tongue. Inset 1: Histologic features of the palate with prominent rete ridge formation, a granular layer, and orthohyperkeratosis; the attached gingiva has similar findings. Inset 2: Histologic features of the buccal mucosa with less pronounced rete ridges, minimal parakeratosis, and no orthokeratosis; the soft palate, labial mucosa, ventral tongue and floor of the mouth exhibit similar features. *Inset 2, courtesy, YDRSC.*



**eFig. 59.2 Fordyce granules.** Multiple yellowish 1- to 2-mm papules on the buccal mucosa. *Courtesy, Carl M. Allen, MD and Charles Camisa, MD.*

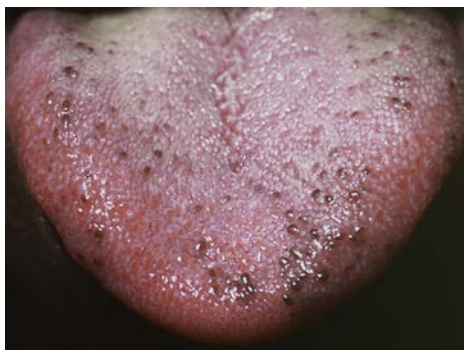

**eFig. 59.3 Pigmented papillae of the tongue.** Uniformly spaced tiny brown papules, representing normal fungiform papillae, on the tip and lateral aspects of the tongue can be seen in darkly pigmented individuals. They lie amongst the more numerous keratotic projections that are normal filiform papillae. *Courtesy, Carl M. Allen, MD and Charles Camisa, MD.*



**eFig. 59.4 Desquamative gingivitis.** *Courtesy, Luis Requena, MD.*



**eFig. 59.5 Maxillary cutaneous sinus of dental origin.** The erythematous papule may be mistaken for a pyogenic granuloma or neoplasm. *Courtesy, Carl M. Allen, MD and Charles Camisa, MD.*



**eFig. 59.6 Cheilitis glandularis.** Erythematous macules on the mucosal lower lip at sites of inflamed salivary gland ducts. There is also evidence of actinic cheilitis. *Courtesy, Carl M. Allen, MD, and Charles Camisa, MD.*

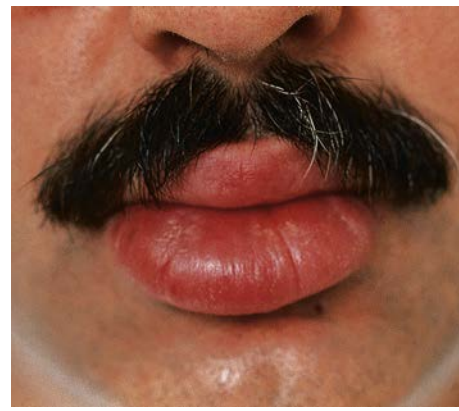

**eFig. 59.7 Cheilitis granulomatosa.** Slightly asymmetric swelling, predominantly of the lower lip. A biopsy specimen demonstrated non-caseating granulomas. Patients are sometimes misdiagnosed as having angioedema. *Courtesy, Carl M. Allen, MD, and Charles Camisa, MD.*

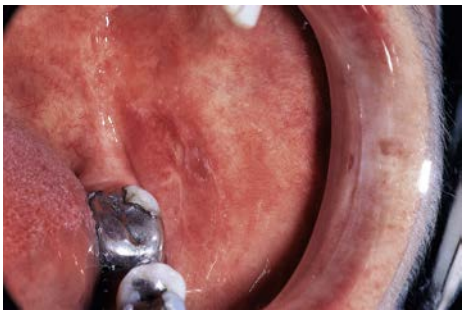

**eFig. 59.8 Lichenoid stomatitis secondary to amalgam hypersensitivity.** Superficial erosions with radiating white striae are localized to the buccal mucosa adjacent to a large amalgam restoration. Of note, lichenoid amalgam reactions generally develop on movable mucosa in direct contact with surfaces of adjacent amalgam fillings (e.g. buccal mucosa, ventrolateral tongue). *Courtesy, Carl M. Allen, MD, and Charles Camisa, MD.*



**eFig. 59.9 Squamous cell carcinoma.** Ulcerated leukoplakia on the ventrolateral aspect of the tongue. *Courtesy, Carl M. Allen, MD, and Charles Camisa, MD.*







**eFig. 59.10 Macroglossia in primary systemic amyloidosis. A** Note the dental impressions on the tongue. **B** Purpuric and translucent papulonodules on the tongue. *A, Courtesy, YDRSC; B, Courtesy, Dennis Cooper, MD.*



**eFig. 59.11 Scurvy.** Hemorrhage beneath the buccal mucosa. *Courtesy, YDRSC.*



**eFig. 59.12 Scurvy.** Gingival hypertrophy and infection, with loosened teeth. *Courtesy, Jeffrey Callen, MD.*



**eFig. 59.13 Gingival cobblestoning in Cowden syndrome.** *Courtesy, Jeffrey Callen, MD.*



**eFig. 59.14 Cowden syndrome.** Coalescing papules with a cobblestone-like appearance on the vermilion lips. *Courtesy, Jean L. Bolognia, MD.*



**eFig. 59.15 Oral mucosal Darier disease.** Whitish papules on the palate. *Courtesy, Daniel Hohl, MD.*



**eFig. 59.16 Lipoid proteinosis.** Firm tongue with numerous tiny papules on the dorsal surface. *Courtesy, Julie V. Schaffer, MD.*



**eFig. 59.17 Chronic mucocutaneous candidiasis due to increased STAT1 signaling.** Recalcitrant thrush on the tongue of a 6-year-old child. *Courtesy, Julie V. Schaffer, MD.*



**eFig. 59.18 Brown macules on the lip in Peutz–Jeghers syndrome.** *Courtesy, Jeffrey Callen, MD.*

| POTENTIAL CAUSES OF CONTACT STOMATITIS OR CHEILITIS |
|---|
| Allergic |
| • Flavorings: cinnamon, mint, menthol, vanillin<br>• Dental metals: mercury, gold, nickel, palladium, copper, silver, cobalt, chromium, beryllium, tin, zinc<br>• Dental adhesives: acrylate compounds, eugenol (combined with zinc oxide)<br>• Topical anesthetics: benzocaine<br>• Essential oils: clove, lemon, orange |
| Irritant |
| • Aspirin<br>• Dental chemicals: eugenol, peroxides, phenol, sodium hypochlorite<br>• Chlorhexidine mouth rinse<br>• Silver nitrate stick<br>• Sodium lauryl sulfate and sodium pyrophosphate (in toothpaste) |

**eTable 59.1 Potential causes of contact stomatitis or cheilitis.**

| THE DIFFERENTIAL DIAGNOSIS OF INTRAORAL TUMORS AND TUMOR-LIKE LESIONS |
|---|
| **Developmental lesions** |
| • Congenital inclusion cysts<br>  – Bohn nodules (alveolar ridge)<br>  – Epstein pearls (palate)<br>• Torus palatinus, torus mandibularis<br>• Lingual thyroid<br>• Dermoid cyst<br>• Enteric duplication cyst<br>• Nasoalveolar (nasolabial) cyst<br>• Lymphoepithelial cyst<br>• Lymphatic/vascular malformation |
| **Reactive/inflammatory conditions** |
| • Mucocele<br>• Fibroma*<br>• Oral melanoacanthoma<br>• Eosinophilic ulcer<br>• Pyogenic granuloma<br>• Peripheral giant cell granuloma<br>• Necrotizing sialometaplasia<br>• Nodular fasciitis |
| **Benign salivary gland neoplasms** |
| • Pleomorphic adenoma<br>• Monomorphic adenoma<br>• Papillary cystadenoma |
| **Other benign neoplasms** |
| • Squamous papilloma<br>• Infantile hemangioma<br>• Angiomyoma<br>• Myofibroma, hemangiopericytoma<br>• Granular cell tumor†<br>• Neurofibroma<br>• Schwannoma<br>• Palisaded encapsulated neuroma<br>• Melanotic neuroectodermal tumor of infancy<br>• Ameloblastoma<br>• Lipoma |
| **Malignant salivary gland neoplasms** |
| • Adenoid cystic carcinoma<br>• Mucoepidermoid carcinoma<br>• Adenocarcinoma |
| **Other malignant neoplasms** |
| • Squamous cell carcinoma<br>• Melanoma<br>• Lymphoma<br>• Kaposi sarcoma<br>• Plasmacytoma<br>• Rhabdomyosarcoma<br>• Osteosarcoma<br>• Fibrosarcoma<br>• Liposarcoma |
| **Ossification may occur.*<br>*†A congenital epulis represents a granular cell tumor of the alveolar ridge.* |

**eTable 59.2 The differential diagnosis of intraoral tumors and tumor-like lesions.**

| DRUGS ASSOCIATED WITH ORAL MUCOSAL PIGMENTATION |
|---|
| • Busulfan |
| • Chloroquine |
| • Chlorpromazine |
| • Clofazimine |
| • Cyclophosphamide |
| • Doxorubicin |
| • Estrogen |
| • 5-Fluorouracil |
| • Hydroxychloroquine |
| • Imatinib mesylate |
| • Ketoconazole |
| • Minocycline |
| • Phenolphthalein |
| • Quinacrine |
| • Quinidine |
| • Tetracycline |
| • Zidovudine (AZT) |

**eTable 59.3 Drugs associated with oral mucosal pigmentation.**

# Anogenital Diseases

# 60

## Introduction

- The anatomy (Fig. 60.1), normal cutaneous findings, and benign lesions of the anogenital area (Table 60.1) should be appreciated before addressing diseases in this area.
- A number of systemic diseases affect the anogenital area (Table 60.2).
- Cutaneous disorders of the anogenital area may be more difficult to diagnose than those involving other cutaneous sites, as typical features may not be present.
- A number of dermatologic conditions affect the anogenital region, including inflammatory (Table 60.3; Figs 60.2–60.6), bullous (Table 60.4; Fig. 60.7), infectious (Table 60.5; see Ch. 69), and premalignant and malignant conditions (Table 60.6; Figs 60.8–60.11).
- Pain and pruritus can be the presenting symptoms in a wide variety of anogenital diseases (Figs 60.12 and 60.13).
- Patients with anogenital disease should use soap substitutes and bland emollient ointments; irritants and potential allergens (e.g. flushable moist wipes, previous topical medications) should be avoided.
- Ointments are preferred over creams in this area because of less irritation and burning with application, as well as providing a better barrier to urine and feces.
- The anogenital region is an area of occlusion and more prone to adverse side effects from and increased absorption of topical agents (e.g. CS).
- High-potency topical CS are generally avoided because of the increased risk for atrophy and striae, but they are used with confidence in certain situations (e.g. lichen sclerosus, erosive lichen planus) for periods of up to 12 weeks once to twice yearly.
- Because of increased moisture, warmth, and occlusion, anogenital diseases have an increased risk of superimposed bacterial and fungal infections.
- Diseases that result in scarring of the anogenital region (e.g. lichen sclerosus, erosive lichen planus) carry an increased long-term risk of developing invasive SCC.

## Intraepithelial Neoplasia

- The term *intraepithelial neoplasia* (*IN*) refers to a change within the anogenital epithelium that is premalignant, and as such has the potential to become an invasive SCC.
- IN has replaced older synonymous terms, such as genital Bowen disease, erythroplasia of Queyrat, and genital SCC *in situ*; use of the term leukoplakia with atypia is also not recommended.
- IN is further subdivided based on location: vulvar IN (VIN), penile IN (PIN), perianal IN (PaIN), and anal IN (AIN) (see Table 60.6), as well as the degree of atypia: 1, mild; 2, moderate; 3, severe.
- VIN is now classified as either *usual type* VIN associated with HPV infection (typically HPV types 16 and 18) or *differentiated type* VIN that can arise in the setting of lichen sclerosus or lichen planus.
- Recently recommended terminology that can replace or qualify IN: high-grade and low-grade squamous intraepithelial lesion.
- Bowenoid papulosis (BP) is a distinct clinical variant of IN that occurs in a younger (more sexually active) age group, is caused by the human papillomavirus (HPV subtypes 16 and 18), has a better prognosis, and sometimes spontaneously regresses (see Ch. 66).

## Condyloma Acuminata

- See Ch. 66.

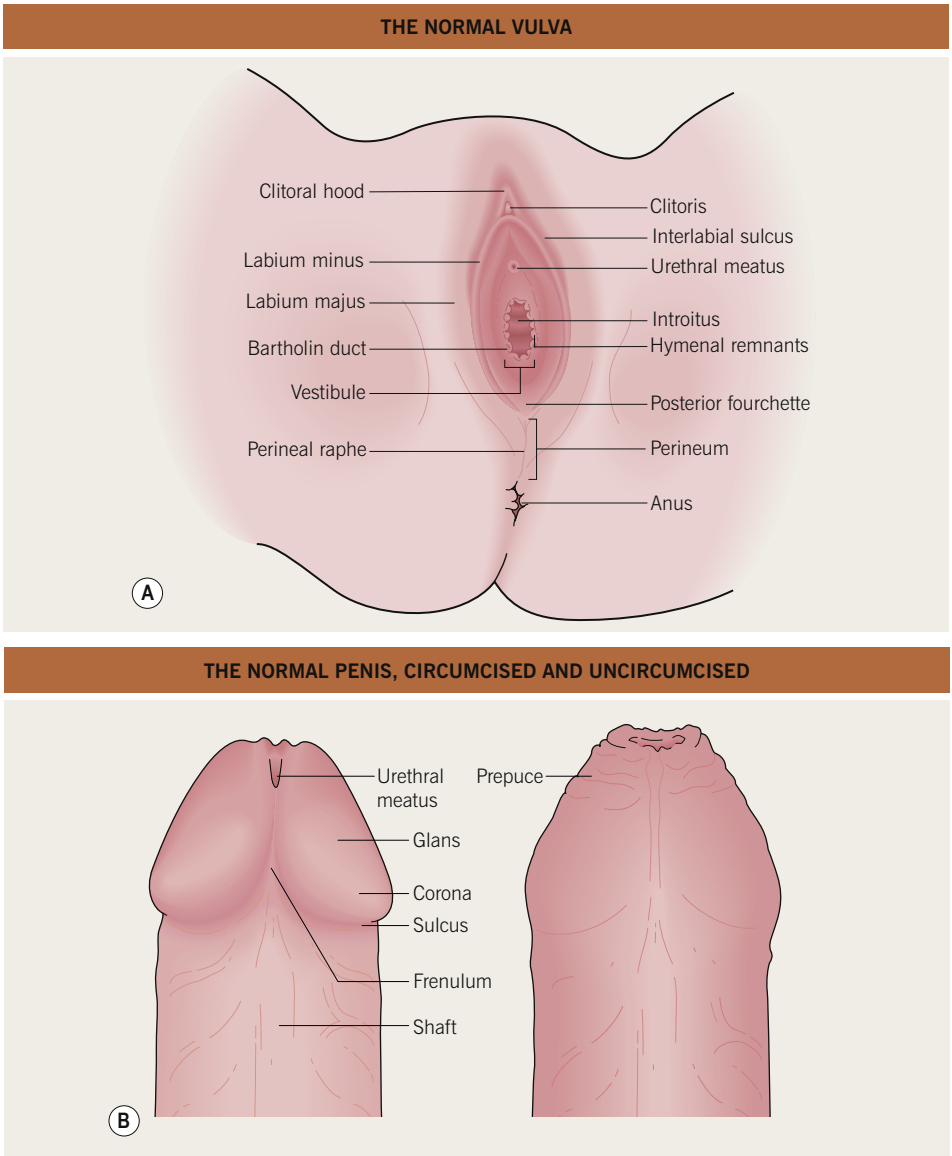


**Fig. 60.1 Genital anatomy. A** The normal vulva. **B** The normal penis, circumcised and uncircumcised.

## Dysesthetic Genital Pain Syndromes

- Includes several regional pain syndromes in which clinical appearance of the involved anogenital region is normal despite the patient's experience of debilitating pain (Fig. 60.14); associated depression is common.
- *Localized vulvodynia* (vestibulodynia) occurs in young, sexually active females and is characterized by superficial dyspareunia and tenderness upon localized pressure within the vulvar vestibule.
- *Generalized* (dysesthetic) *vulvodynia/scrotodynia* is characterized by persistent burning pain that involves the entire vulva, scrotum, or penis, and may extend down the thighs.

| NORMAL FINDINGS AND BENIGN LESIONS OF THE ANOGENITAL REGION | |
|---|---|
| **Common** | **Less common** |
| Epidermoid cysts | Fox–Fordyce disease |
| Open comedones | Syringomas |
| Pearly penile papules (see Fig. 95.7) | Idiopathic calcinosis of the scrotum |
| Vestibular papillomatosis | Urethral caruncle |
| Angiokeratomas (see Fig. 94.11) | Hidradenoma papilliferum |
| Seborrheic keratoses and acrochordons | |
| Melanocytic nevi and genital lentigines (see Fig. 92.2) | |
| Free sebaceous glands | |

**Table 60.1 Normal findings and benign lesions of the anogenital region.** Papules in the anogenital region can also result from HPV infection, in particular condylomata acuminata and common warts (see Ch. 66).

**SYSTEMIC DISEASES THAT MAY PRESENT IN THE ANOGENITAL REGION**

- Inflammatory bowel disease, especially Crohn disease (see Ch. 45)
- Nutritional dermatoses, e.g. acrodermatitis enteropathica, necrolytic migratory erythema, cystic fibrosis (see Ch. 43)
- Langerhans cell histiocytosis (see Ch. 76)
- Kawasaki disease (see Ch. 3)
- Behçet disease – ulcers (see Ch. 45)
- Infections (nonvenereal), e.g. recurrent toxin-mediated perineal erythema, Fournier gangrene
- Infections (venereal) (see Ch. 69)
- Drug reactions (see Chs 16 & 17), e.g. EM major, SJS, TEN; fixed drug eruption; toxic erythema of chemotherapy
- Neutrophilic dermatoses, e.g. Sweet syndrome (see Ch. 21)

**Table 60.2 Systemic diseases that may present in the anogenital region.** EM, erythema multiforme; SJS, Stevens–Johnson syndrome; TEN, toxic epidermal necrolysis.



**Fig. 60.2 Vulvar dermatitis.** Lichenification is prominent. The underlying diagnosis was atopic dermatitis. *Courtesy, Susan M. Cooper, MD, and Fenella Wojnarowska, MD.*



**Fig. 60.3 Psoriasis of the penile shaft.** Well-demarcated erythematous plaque with slight scale. Similar lesions can be seen in patients with reactive arthritis (formerly Reiter disease). *Courtesy, Jean L. Bolognia, MD.*

| INFLAMMATORY DISORDERS WITH ANOGENITAL FEATURES | | |
|---|---|---|
| **Inflammatory disorder** | **Anogenital features** | **Rx** |
| **Anogenital dermatitis** | • Female > male<br>• Varied presentations, from mild erythema to significant lichenification (Fig. 60.2)<br>• Unremitting itch/scratch cycle<br>**Female:** perianal, labia majora, mons pubis<br>**Male:** crura and scrotum | • Examine entire body for clues to etiology (e.g. seborrheic or atopic dermatitis)<br>• Eliminate irritants/allergens<br>• Break itch/scratch cycle with potent topical CS for several weeks and then taper<br>• Oral antihistamines may help control pruritus<br>• Consider patch testing |
| **Psoriasis (including inverse psoriasis)** (See Ch. 6) | • Perianal and intergluteal cleft fissuring; erythematous, smooth, well-demarcated plaques<br>**Female:** labia majora and mons pubis<br>**Male**: glans and shaft of penis (Fig. 60.3) | **Mild–moderate**<br>• Moderate potency topical CS for 2–3 weeks with taper to less potent topical CS plus antifungal<br>• Topical calcineurin inhibitors and vitamin D analogues (may sting)<br>**Severe** (see Ch. 6) |
| **Lichen sclerosus (LS)** | See Fig. 60.4 and Ch. 36 | See Ch. 36 |
| **Lichen planus (LP)** (see Ch. 9) | • Intense pruritus common in all forms | **First-line**<br>• Superpotent topical CS<br>• For vaginal disease, CS foams, enemas, suppositories or ointments (± dilators)<br>**Second-line**<br>• Longer-term maintenance with superpotent topical CS or combined moderately potent CS/ antifungal/antibacterial preparations<br>• Topical calcineurin inhibitors<br>• Intralesional CS (hypertrophic)<br>• Systemic antimalarials (e.g. hydroxychloroquine)<br>• Systemic immunosuppressants (e.g. weekly methotrexate, mycophenolate mofetil)<br>• Systemic antibiotics (e.g. minocycline ± nicotinamide)<br>• Surgery to lyse adhesions |
| **1. Classic** | • Violaceous flat-topped papules and plaques; lacy white streaks<br>**Female:** mons pubis and labia<br>**Male:** glans and shaft of penis; often annular (Fig. 60.5A) | |
| **2. Erosive** | • Female > male<br>• Erosions surrounded by white lacy pattern; prominent scarring/ adhesions (Fig. 60.5B)<br>• Desquamative vaginitis with discharge; significant pain and dyspareunia<br>• Usually severe oral involvement/ desquamative gingivitis<br>• Increased risk for SCC | |
| **3. Hypertrophic** | • Hyperkeratotic white plaques on the vulva or shaft of penis (Fig. 60.5C)<br>• Increased risk for SCC | |
| **Zoon balanitis/vulvitis (plasma cell balanitis/vulvitis)** | • Male (uncircumcised) > female<br>• Pruritus and pain<br>**Male:** glans penis (Fig. 60.6)<br>• Erythematous discrete moist plaques with speckled appearance and orange hue<br>• Involvement of adjacent surfaces produce “kissing lesions”<br>**Female:** similar lesions involving vulva | • Circumcision curative<br>• Topical CS if symptoms |

**Table 60.3 Inflammatory disorders with anogenital features.** Porokeratosis ptychotropica is a rare disorder and can mimic anogenital dermatitis or inverse psoriasis. The DDx of these disorders includes the other entities listed in this table; consider infections, either primary or superimposed (see Table 60.5); less commonly bullous disorders (see Table 60.4); if nonhealing consider malignancy, most commonly SCC (see Table 60.6).




**Fig. 60.4 Lichen sclerosus (LS).** Typical involvement of the vulva demonstrating marked architectural change with the loss of the labia minora and midline fusion **(A)** and purpura **(B).** Perianal LS **(C)** and involvement of the penis **(D)** with an erythematous and white plaque on the glans. *A,C Courtesy, Susan M. Cooper, MD, and Fenella Wojnarowska, MD; B, Courtesy, Kalman Watsky, MD; D, Courtesy, Luis Requena, MD*.

- *Cyclical vulvovaginitis* is a recurrent vulvovaginitis, with or without a typical candidal discharge, that most often occurs premenstrually and is associated with superficial dyspareunia; often responds to prolonged course of oral antifungals.
- *Anodynia* is an anal/perianal regional pain syndrome in males and females that shares many features of the previously described entities.
- **Rx:** individualized and may include topical local anesthetics, oral tricyclic antidepressants, oral gabapentin, referral to a neurologist or specialized pain clinic (to exclude underlying neurologic disorder; see Ch. 4), acupuncture, or biofeedback.

For further information see Ch. 73 from *Dermatology, Fourth Edition*.

**For additional online figures visit www.expertconsult.com**

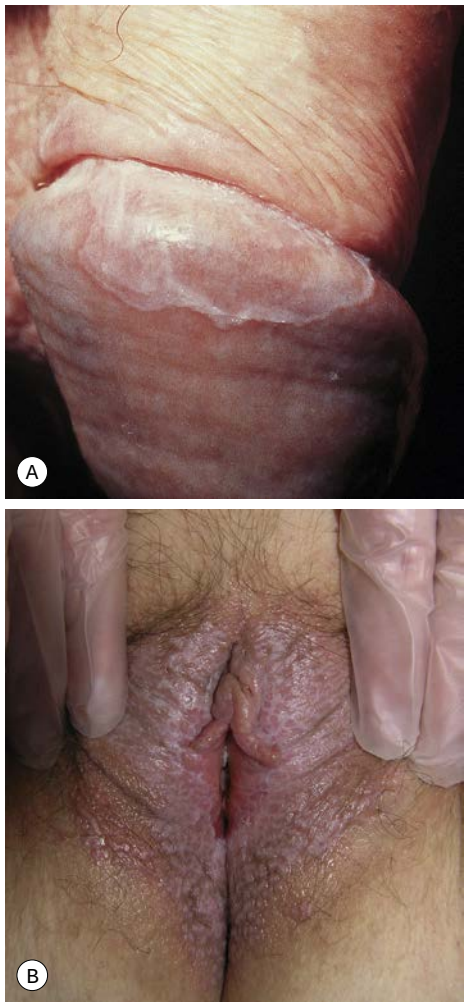





**Fig. 60.5 Anogenital lichen planus. A** Involvement of the penis with an annular band on the glans, a typical finding. **B** Erosive lichen planus of the vulva with fissures and an extensive white lacy pattern. **C** This patient with extensive hypertrophic lichen planus of the vulva and perineum had developed an invasive SCC. *A, Courtesy, R. Turner, MD; B, Courtesy, Susan M. Cooper, MD, and Fenella Wojnarowska, MD; C, Courtesy Karynne O. Duncan, MD.*



**Fig. 60.6 Zoon balanitis.** There are moist "kissing lesions" on adjacent surfaces of the glans and prepuce. *Courtesy, Susan M. Cooper, MD, and Fenella Wojnarowska, MD.*

| SELECTED BULLOUS DISORDERS WITH ANOGENITAL FEATURES | | |
|---|---|---|
| **Bullous disorder** | **Anogenital features** | **Rx** |
| **Hailey–Hailey disease** | See Ch. 48 | See Ch. 48 |
| **Bullous pemphigoid (BP)** (See Ch. 24) | • Mostly affects the elderly, but a localized vulvar variant is occasionally seen in children<br>• A vegetans form favors flexural sites<br>• Less likely than PV to involve mucosal sites | **Mild**<br>• Potent topical/intralesional CS<br>**Severe**<br>• Systemic CS<br>• Other systemic immunosuppressants<br>• Methotrexate (BP)<br>• Dapsone, cyclophosphamide (MMP)<br>• Dapsone or sulfapyridine (LABD)<br>• Mycophenolate mofetil, azathioprine (PV) |
| **Mucous membrane (cicatricial) pemphigoid (MMP)** (See Ch. 24) | • External genitalia and anus<br>**Early**: erosions, ulcerations, blisters (Fig. 60.7)<br>• Pain, pruritus, dysuria<br>**Late**: scarring prominent with related disability<br>• Phimosis, narrowing of vaginal introitus, anal stricture | |
| **Pemphigus vulgaris (PV)** (See Ch. 23) | • Vagina, labia, anus, penis<br>• Widespread erosions; vegetative and papillomatous nodulo-plaques may develop (pemphigus vegetans) | See Ch. 23 |

**Table 60.4 Selected bullous disorders with anogenital features.** Acquired autoimmune bullous diseases are clinically difficult to differentiate from one another and require biopsies for H&E and DIF, as well as serum for IIF and/or ELISA. MMP can be clinically indistinguishable from erosive lichen planus in the anogenital area. The DDx (especially of PV) may include other causes of erosions (Table 60.7). Other blistering disorders, including LABD (linear IgA bullous dermatosis), epidermolysis bullosa acquisita (EBA), and paraneoplastic pemphigus can occur in the genital area (see Chs 23 and 24). DIF, direct immunofluorescence; IIF, indirect immunofluorescence.



**Fig. 60.7 Mucous membrane pemphigoid of the vulva.** Ulcerations and scarring of the perianal area and perineum. Positive direct immunofluorescence with linear deposition of immunoreactants distinguished this from erosive lichen planus. *Courtesy, Susan M. Cooper, MD, and Fenella Wojnarowska, MD.*

| INFECTIOUS (NONVENEREAL) DISORDERS WITH ANOGENITAL FEATURES | | | |
|---|---|---|---|
| **Infectious (nonvenereal) disorder** | **Anogenital features** | **Dx and DDx** | **Rx** |
| **Candidiasis**<br>(See Ch. 64 and Figs 13.2 and 13.4) | • Favors the perianal area and inguinal crease, with sheet-like erythema, fissuring, erosions, and satellite pustules<br>**Female**<br>• Vulvar erythema, small fissures<br>• Severe pruritus<br>• Creamy-white vaginal discharge<br>**Male**<br>• Uncircumcised > circumcised<br>• Balanitis or balanoposthitis<br>• In the inguinal/scrotal folds, see erythema and focal white areas | • Many anogenital diseases may be misdiagnosed as a "yeast" infection or develop superimposed candidiasis<br>• Confirm by microscopy (KOH preparation) and/or culture<br>• If pustules, consider impetigo | • Address precipitating factors (e.g. diabetes mellitus, systemic antibiotics)<br>**Mild**<br>• Topical antifungal/anti-yeast agents<br>• Vaginal anti-yeast suppositories<br>• Single, oral dose of fluconazole 150 mg (vaginal candidiasis)<br>**Severe**<br>• Fluconazole 50–100 mg daily for 14 days<br>**Recurrent (>3 episodes/year)**<br>• Treat sexual partners<br>• Oral fluconazole 150 mg weekly for 6 months<br>• Clotrimazole vaginal 500 mg tablets weekly for 6 months<br>• Oral itraconazole 200 mg, twice a day, once per month, for 6 months |
| **Dermatophytosis (tinea cruris)**<br>(See Ch. 64 and Fig. 13.2) | • Chronic, slowly advancing, scaly, erythematous patches and thin plaques; ± pustules<br>• Favors the groin (but scrotum often spared) with extension onto upper, medial thighs; medial buttocks<br>• Tinea pedis and toenail onychomycosis often present | • Confirm with microscopy (KOH preparation) | **Mild**<br>• Topical antifungals<br>**Severe**<br>• Oral terbinafine 250 mg daily for 2 weeks |
| **Erythrasma**<br>(See Ch. 61 and Fig. 13.2) | • Well-defined, pink to red-brown, pigmented patches or thin plaques with fine diffuse scale and wrinkling<br>• Favors flexural areas, such as groin and intergluteal cleft<br>• Caused by *Corynebacterium minutissimum* | • Wood's lamp examination (coral pink fluorescence) | **Mild**<br>• Antibacterial soaps<br>• Topical 10–20% aluminum chloride<br>• Topical 2% clindamycin, erythromycin<br>**Severe**<br>• Oral erythromycin for 5 days |

**Table 60.5 Infectious (nonvenereal) disorders with anogenital features.** *Continued*

| INFECTIOUS (NONVENEREAL) DISORDERS WITH ANOGENITAL FEATURES | | | |
|---|---|---|---|
| **Infectious (nonvenereal) disorder** | **Anogenital features** | **Dx and DDx** | **Rx** |
| **Perianal and vulvovaginal streptococcal infection** (See Ch. 61 and Fig. 13.4) | • Children >> adults<br>• Sharply demarcated, bright perianal erythema, extending 2–3 cm around the anal verge<br>• Painful defecation or urination<br>• Blood-streaked stools<br>• Irritation or pruritus<br>• Caused by group A β-hemolytic *Streptococcus*<br>• May also involve the neck and inguinal regions, especially in children (streptococcal intertrigo)<br>• May be preceded or accompanied by pharyngitis | • Diagnosis made with bacterial culture or rapid strep test of involved site<br>• Also consider: candidiasis, irritant contact dermatitis, pinworm infection, child abuse, and early Kawasaki disease (if inguinal)<br>• May trigger guttate psoriasis | • Oral cephalosporin, penicillin or erythromycin for 10–14 days<br>• Follow with re-culture to exclude recurrence |

**Table 60.5** *Continued* **Infectious (nonvenereal) disorders with anogenital features.** Condylomata acuminata and venereal diseases are covered in Chapters 66 and 69, respectively. The DDx of these disorders includes the other entities listed in this table; they may be confused with the disorders listed in Tables 60.2 and 60.3 as well as superimposed upon them; topical medications can also lead to a superimposed contact dermatitis.

| PREMALIGNANT AND MALIGNANT DISORDERS WITH ANOGENITAL FEATURES | | | |
|---|---|---|---|
| **Premalignant and malignant disorders** | **Anogenital features** | **Other** | **Rx** |
| **Premalignant lesions** | | | |
| • Vulvar intraepithelial neoplasia (VIN)<br>• Penile intraepithelial neoplasia (PIN)<br>• Perianal intraepithelial neoplasia (PaIN)<br>• Anal intraepithelial neoplasia (AIN) | Varied presentations<br>• Erythematous or pigmented, well-demarcated plaque (genital Bowen disease variant)<br>• Verrucous white-gray plaque<br>• Erosions<br>• Nonhealing ulcer<br>• Erythematous, shiny, velvety patch or plaque (erythroplasia of Queyrat variant) (Fig. 60.8) | Several etiologies/ predisposing factors<br>• Oncogenic HPV (e.g. subtypes 16, 18, 31, 33)<br>• Inflammatory, scarring conditions (e.g. lichen sclerosus, erosive lichen planus)<br>• Uncircumcised male<br>• Immunosuppression<br>• HIV infection | • In conjunction with gynecologic or urologic oncologist<br>• Long-term evaluation necessary, including anal and cervical cytology<br>• Examine sexual partners<br>• Varies from topical agents (e.g. imiquimod, 5-fluorouracil) to surgical excision, including Mohs surgery<br>• Prevention: HPV vaccination |
| • Bowenoid papulosis | See Fig. 60.9 and Ch. 66 | See Ch. 66 | See Ch. 66 |
| **Malignant lesions** | | | |
| • Invasive SCC | Varied presentations<br>• Nonhealing ulcer or fissure<br>• Erythematous plaque with heaped-up edges (Fig. 60.10)<br>• Verrucous plaque<br>• Nodule | • Most common anogenital tumor, but overall rare<br>• Etiologies are similar to those listed for premalignant lesions | • Consult with gynecologic or urologic oncologist<br>• First-line: surgical excision, including Mohs surgery<br>• Second-line: XRT |
| • Extramammary Paget disease | • Slowly expanding erythematous plaque with demarcation between normal and involved skin; erosions and scale present (Fig. 60.11)<br>• Favors vulva and perianal regions<br>• Pruritus, burning, or asymptomatic | • Rare intraepithelial adenocarcinoma<br>• More common in older females and Japanese males<br>• May be primary or secondary to an underlying malignancy<br>• Associated underlying visceral malignancy in 10–20%<br>• Associated underlying adnexal adenocarcinoma in <5% | • Initial and periodic systemic evaluations for internal malignancy are necessary<br>• Surgical excision vs. Mohs surgery<br>• Combination therapy, e.g. topicals (see above), XRT, photodynamic therapy |

**Table 60.6 Premalignant and malignant disorders with anogenital features.** Multiple biopsies may be necessary to make a diagnosis. The DDx of these disorders includes the other entities listed in this table and Table 60.2, as well as seborrheic keratosis, condylomata acuminata, NMSC, and amelanotic melanoma.



**Fig. 60.8 Penile intraepithelial neoplasia (PIN).** Persistent erythema not responding to topical steroids. *Courtesy, R. Turner, MD.*







**Fig. 60.9 Bowenoid papulosis variant of intraepithelial neoplasia. A** Multiple red-brown to brown papules on the shaft of the penis. **B** Coalescence of red-brown to brown papules on the upper inner thigh. *A, Courtesy, YDRSC; B, Courtesy, Robert Hartman, MD.*







**Fig. 60.10 Invasive squamous cell carcinoma. A** Erythematous plaque on the foreskin in this patient with psoriasis who had received PUVA therapy without genital protection. **B** Erythematous, indurated plaque in another patient with non-HPV-related perianal SCC. *A, Courtesy, Susan M. Cooper, MD, and Fenella Wojnarowska, MD; B, Courtesy, Karynne O. Duncan, MD.*

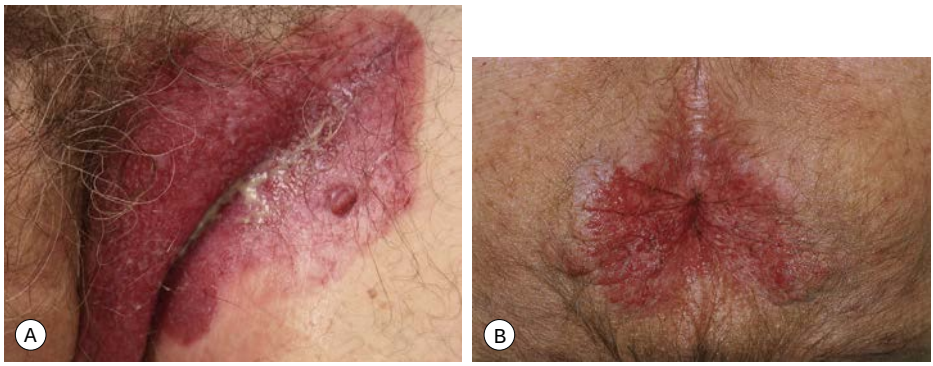


**Fig. 60.11 Extramammary Paget disease. A** Eroded erythematous plaque with exudate, especially in the inguinal crease. The patient refused any further evaluation and had never undergone colonoscopy or cystoscopy. **B** Well-demarcated perianal plaque with both erosions and scale, giving rise to a "strawberries and cream" appearance. *A, Courtesy, Kathryn Schwarzenberger, MD, and Jeffrey P. Callen, MD; B, Courtesy, Kalman Watsky, MD.*

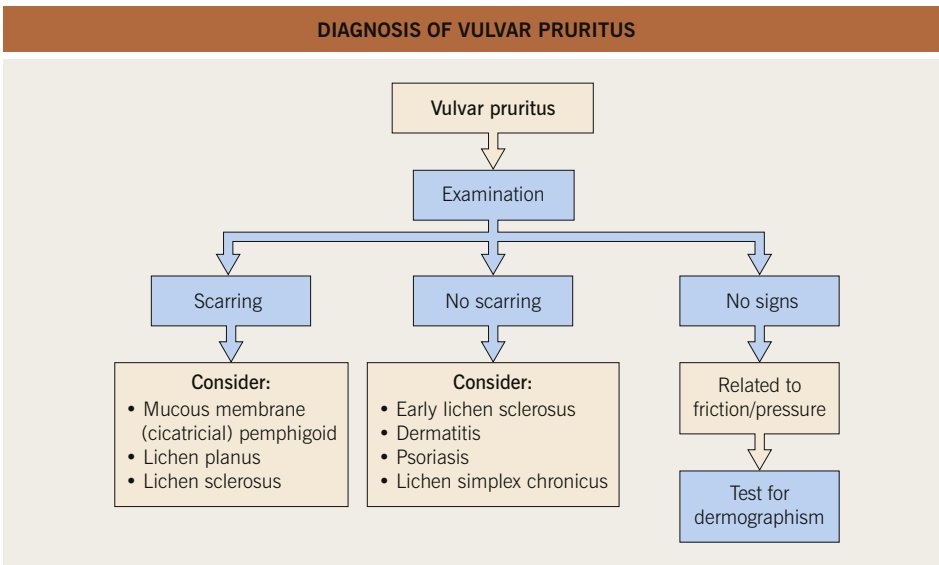


**Fig. 60.12 Diagnosis of vulvar pruritus.** *Courtesy, Susan M. Cooper, MD, and Fenella Wojnarowska, MD.*

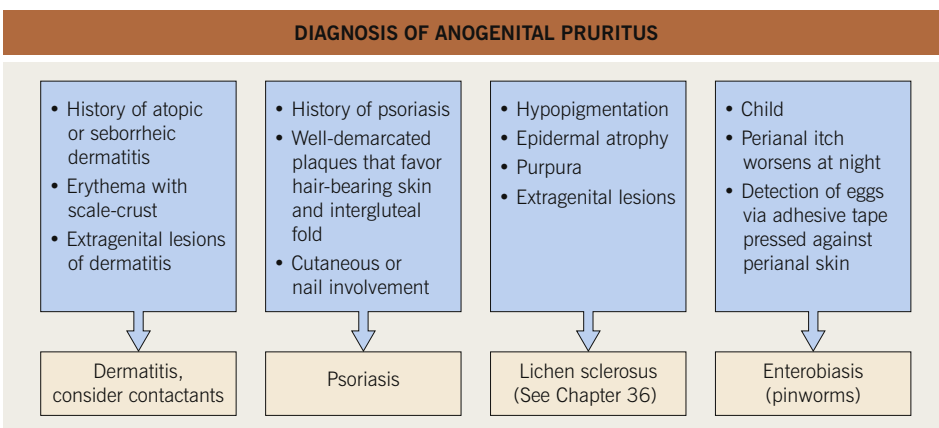


**Fig. 60.13 Diagnosis of anogenital pruritus.** Histologic evaluation may be required to confirm the clinical diagnosis (e.g. lichen sclerosus) or to exclude more unusual etiologies (e.g. extramammary Paget disease). Systemic contact dermatitis reactions in this region may also be very pruritic. *Courtesy, Susan M. Cooper, MD, and Fenella Wojnarowska, MD.*

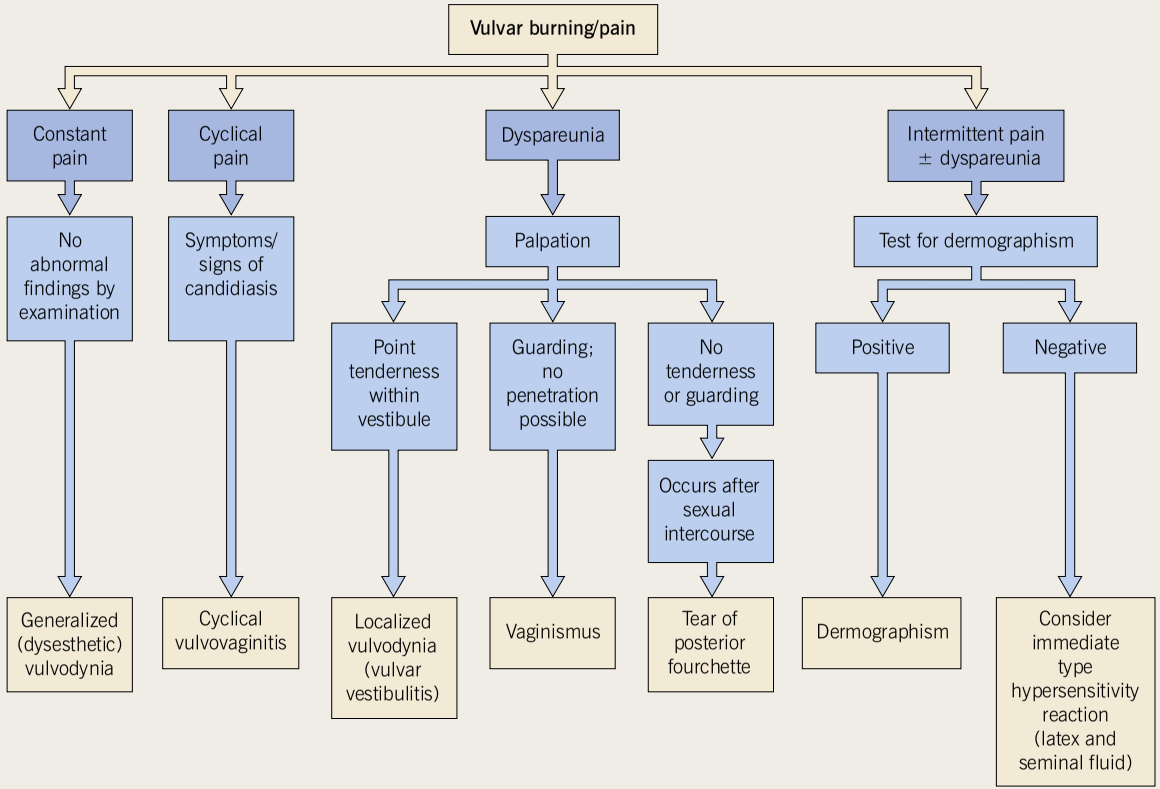


**Fig. 60.14 Diagnosis of vulvar burning/pain in the setting of a normal-appearing vulva.** *Courtesy, Susan M. Cooper, MD, and Fenella Wojnarowska, MD.*

| CAUSES OF GENITAL EROSIONS AND ULCERATIONS |
|---|
| • Lichen sclerosus (see Fig. 36.9B)<br>• Erosive lichen planus (see Fig. 60.5B)<br>• Genital aphthae/aphthosis* |
| • Infection<br>– Candidiasis (see Figs 13.2 and 13.4)<br>– Impetigo (*Staphylococcus*/*Streptococcus*)<br>– Herpes simplex viral infection (see Figs 67.2E and 67.6D) or herpes zoster<br>– Primary syphilis, chancroid<br>– Epstein–Barr virus (EBV; Fig. 60.15)**,†, cytomegalovirus†, *Mycoplasma*†<br>– Tuberculosis |
| • Squamous cell carcinoma and other malignancies<br>• Intraepithelial neoplasia |
| • Zoon plasma cell balanitis/vulvitis (see Fig. 60.6) |
| • Acquired bullous diseases<br>– Pemphigus vulgaris<br>– Bullous pemphigoid<br>– Mucous membrane (cicatricial) pemphigoid (see Fig. 60.7)<br>– Linear IgA bullous dermatosis<br>– Epidermolysis bullosa acquisita<br>– Erythema multiforme, Stevens–Johnson syndrome (see Fig. 16.7B)<br>– Fixed drug eruption (see Fig. 17.10B)<br>• Inherited bullous disease<br>– Hailey–Hailey disease (see Fig. 13.2)<br>– Epidermolysis bullosa |
| • Complex aphthosis due to Behçet disease or inflammatory bowel disease<br>• Crohn disease (see Fig. 13.2)<br>• Extramammary Paget disease (see Fig. 60.11)<br>• Langerhans cell histiocytosis (see Fig. 76.1)<br>• Necrolytic migratory erythema, acrodermatitis enteropathica (see Fig. 43.9)<br>• Papular acantholytic dyskeratosis<br>• Toxic erythema of chemotherapy (see Fig. 17.15A) |
| **Includes reactive non-sexually related acute genital ulcers, which can be triggered by a variety of viral and bacterial infections.*<br>***Diagnosed via EBV IgM antibodies or PCR; favors female children and adolescents.*<br>†*Cause/trigger of reactive non-sexually related acute genital ulcers.* |

**Table 60.7 Causes of genital erosions and ulcerations.**



**Fig. 60.15 Reactive non-sexually related acute genital ulcers associated with primary Epstein–Barr virus (EBV) infection.** Extreme pain with urination required placement of a Foley catheter in this 13-year-old girl. EBV-related genital ulcers are often misdiagnosed as a genital herpes simplex viral infection. *Courtesy, Julie V. Schaffer, MD.*

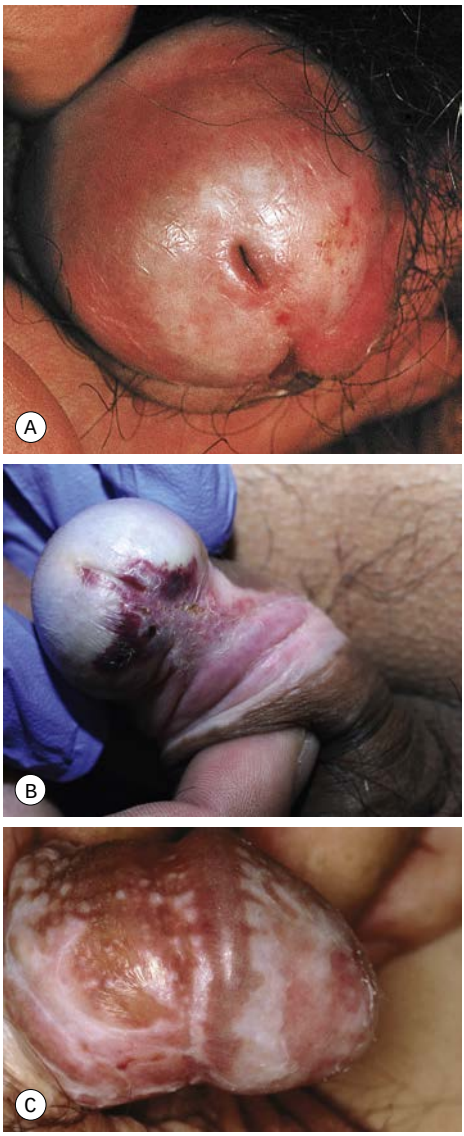


**eFig. 60.1 Lichen sclerosus (LS) of the glans penis.** Erythematous and hypopigmented plaque on the glans **(A)** and hypopigmentation and purpura as well as scarring and inflammation with extension onto the shaft of the penis **(B)**. **C** Note the ivory color, erosion, and scarring.
*A, Courtesy, Ronald P. Rapini, MD; B, Courtesy, Kalman Watsky, MD; C, Courtesy, USCDRSC.*

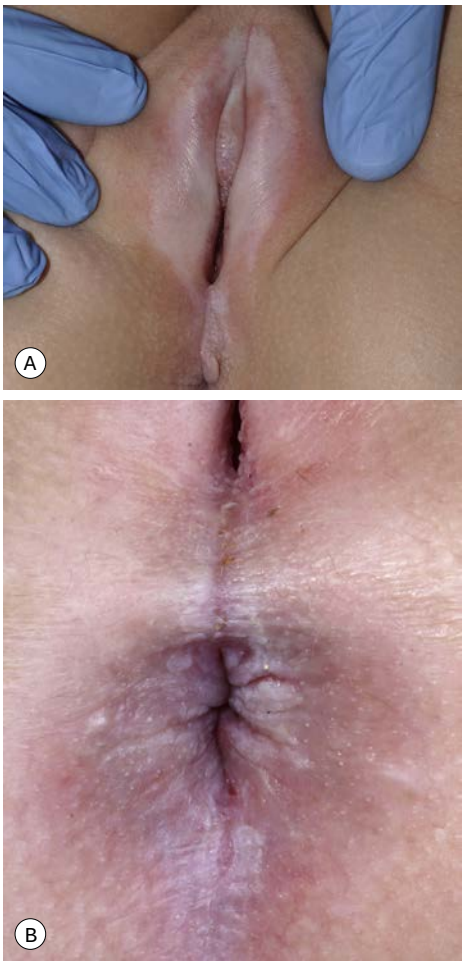


**eFig. 60.2 Anogenital lichen sclerosus.** **A** Characteristic vulvar, perineal and perianal involvement in a child. Symmetric ivory-colored plaques with a thin pink peripheral rim are seen; a perianal pyramidal protrusion is also present. **B** Perianal lichen sclerosus in which the hypopigmented plaques are accompanied by a linear erosion (skin tear) at 6 o'clock and central fissuring of the perineum. *Courtesy, Martin Rocken, MD.*

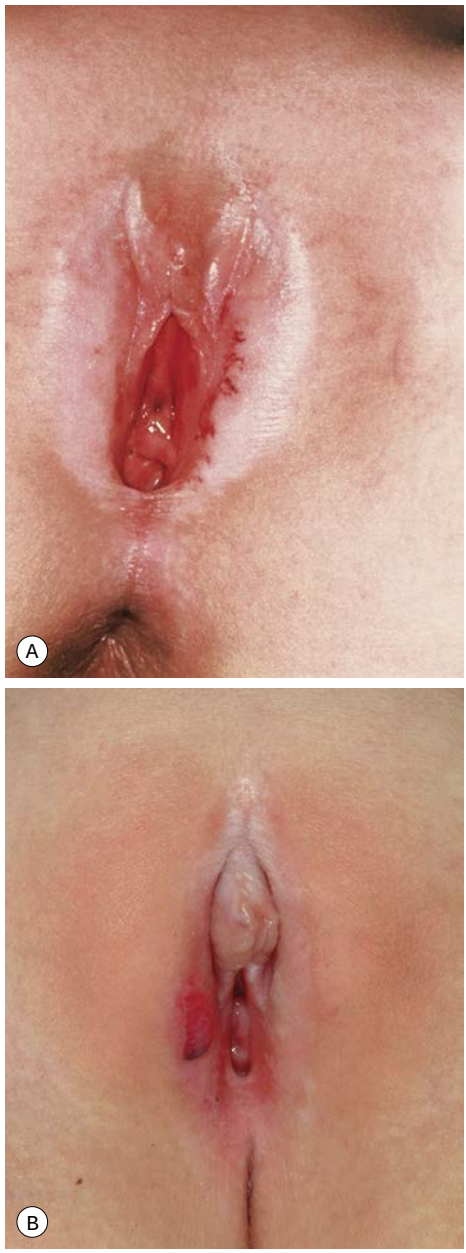


**eFig. 60.3 Genital lichen sclerosus involving the vulva of a young female. A** Centrally, there is erythema with superficial erosion and purpura. More peripherally, white plaques with a wrinkled surface are seen. Note fissuring of the perineum. **B** Genital lichen sclerosus may also have associated purpura or hemorrhagic bullae. *A, Courtesy, Martin Rocken, MD, and Kamran Ghoreschi, MD; B, Courtesy, Julie V. Schaffer, MD.*




**eFig. 60.4 Ultrapotent topical corticosteroids in the treatment of lichen sclerosus in a 12-year-old girl.** Before **(A)** and after **(B)** topical application of clobetasol propionate 0.05% cream daily for 5 months. *Courtesy, Martin Rocken, MD, and Kamran Ghoreschi, MD.*



**eFig. 60.5 Psoriasis involving the glans penis and distal finger.** Thin pink plaques are seen with scale and erosions. *Courtesy, Kalman Walsky, MD.*




**eFig. 60.6 Extramammary Paget disease.** **A** Erythematous plaque with hydrated scale at the base of the scrotum. **B** Photomicrograph demonstrating pagetoid cells within the epidermis, both as single cells and in nests. *A, Courtesy, YDRSC; B, Courtesy, Lorenzo Cerroni, MD.*



**eFig. 60.7 Vulvar ulcers associated with primary EBV infection.** EBV-related genital ulcers, which are most common in adolescent girls, are often misdiagnosed as genital herpes simplex infection and in some patients represent a variant of aphthosis. *Courtesy, YDRSC.*

# Bacterial Diseases 61

The skin is normally colonized by hundreds of species of bacteria as part of the cutaneous microbiota (flora). These organisms help prevent skin infection by competing with pathogenic microorganisms.

Skin infection with bacteria may be a primary problem (e.g. impetigo) or a complication of another skin disease (e.g. atopic dermatitis) and may lead to multisystem dysfunction (e.g. toxic shock syndrome). Nomenclature of these diseases often reflects the site and the depth of infection – that is, from the stratum corneum to the subcutaneous tissue (Fig. 61.1) – as well as the suspected causative organism.

## Gram-Positive Cocci

### Staphylococcal and Streptococcal Skin Infections

Streptococcal infections may be complicated by acute post-streptococcal glomerulonephritis; this occurs in <1% of patients in high-income countries, but it remains a significant problem in low-income countries.

#### IMPETIGO

- Major organisms are *Staphylococcus aureus* and *Streptococcus pyogenes* (group A streptococci [GAS]).
- A very common, highly contagious bacterial infection. Occurs most commonly on the face or extremities of children, in particular around the nose and mouth (Fig. 61.2A). Usually the skin is eroded with overlying "honey-colored" crusts, but there is a bullous variant (Fig. 61.2B) that is often seen in the major body folds, e.g. axillae.
- The bullous variant is due to *S. aureus* and can be explained by local release of an exfoliative toxin that binds to desmoglein 1 and leads to dissolution (i.e. acantholysis) of the upper epidermis (see Ch. 23).
- Risk factors for infection: nasal carriage of *S. aureus* and breaks in the epidermal barrier, e.g. atopic dermatitis, arthropod bites, trauma, scabies.
- **DDx** of eroded lesions: insect bites, dermatitis (e.g. nummular, atopic), herpes simplex viral infection, prurigo simplex.
- **DDx** of bullae: bullous insect bites, thermal burns, herpes simplex viral infection, acute contact dermatitis, and occasionally autoimmune bullous dermatoses.
- **Rx:** local wound care (including soap), removal of crusts by soaking; for mild cases, topical mupirocin, retapamulin, ozenoxacin, or fusidic acid; for moderate to severe infections, oral antibiotics, the choice of which is dependent on prevalence of methicillin-resistant *S. aureus* (MRSA) in the local community (Table 61.1).

#### ECTHYMA

- Most commonly secondary to *Streptococcus pyogenes*.
- Ulceration with hemorrhagic crust that extends into the superficial dermis, i.e. is deeper than impetigo (Fig. 61.3); can heal with scarring.
- Often on the lower extremities, and risk factors include an edematous limb, arthropod bites, and a pre-existing ulceration.
- **DDx:** ulcers secondary to vasculitis or other etiology (e.g. cutaneous diphtheria; see Fig. 86.1); not to be confused with ecthyma gangrenosum which is due to septic emboli (see below).
- **Rx:** see Table 61.1.

#### BACTERIAL FOLLICULITIS

- *Staphylococcus aureus* is the most common cause, followed by Gram-negative bacteria; the latter can occur in patients with acne vulgaris on long-term antibiotic therapy; see Chapter 31 for *Pseudomonas* folliculitis.

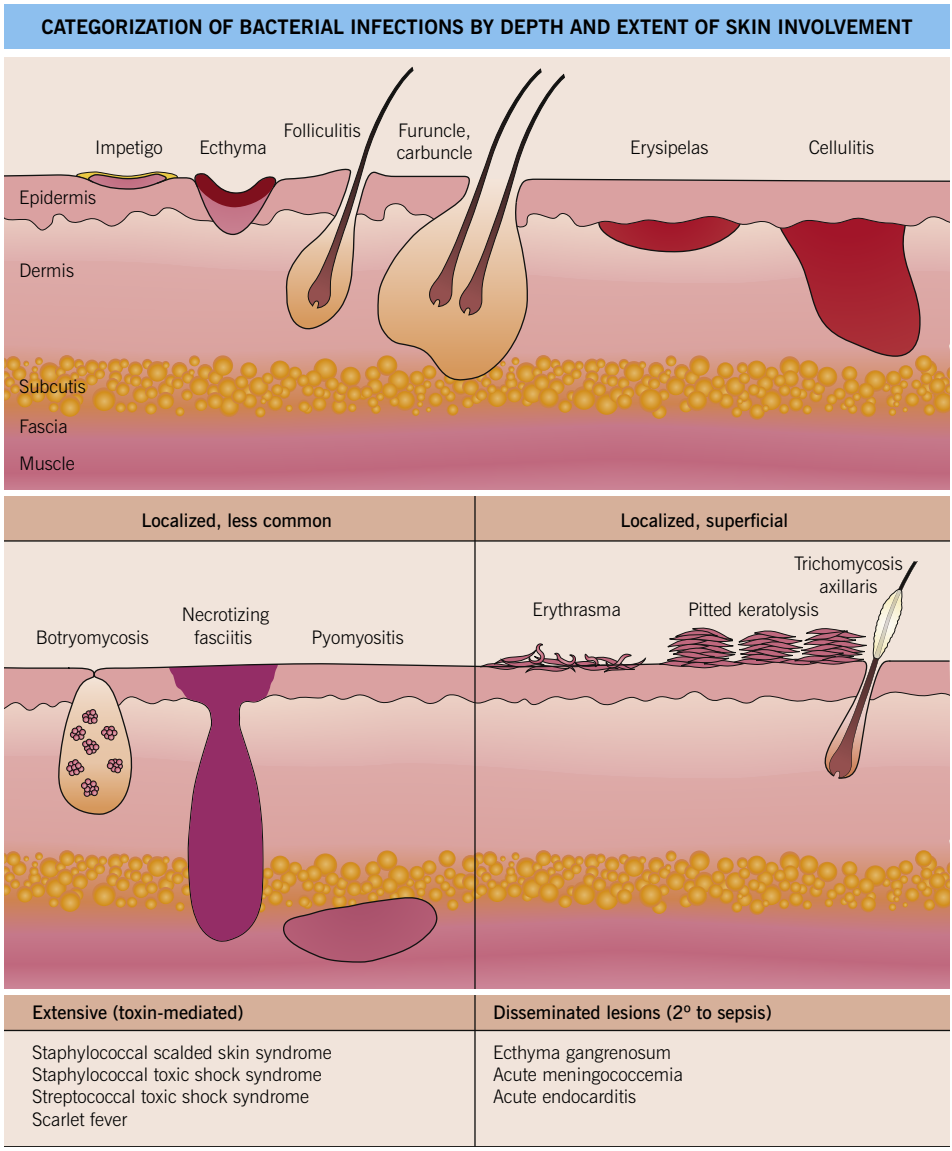


**Fig. 61.1 Categorization of bacterial infections by depth and extent of skin involvement.** More common, localized infections are depicted first; these infections are often secondary to *Staphylococcus aureus* or group A streptococci. *Adapted from "Common bacterial infections of the skin," American Academy of Dermatology.*

- Usually superficial, but occasionally deep, infection centered on hair follicles (see Fig. 61.1).
  - Superficial – 1- to 4-mm pustules on an erythematous base (see Fig. 31.2); centrally, a hair shaft may be noted
  - Deep – also referred to as sycosis – tender, erythematous papulonodules, often with a central pustule
- Commonly in the beard area, on the upper trunk, or on the buttocks and thighs; shaving can be an exacerbating factor.
- **DDx:** culture-negative (normal flora) folliculitis, acne vulgaris, folliculitis due to fungi (e.g. *Pityrosporum*), viruses (e.g. herpes simplex virus) or *Demodex* (Fig. 31.1); rosacea, chloracne, and pseudofolliculitis barbae.

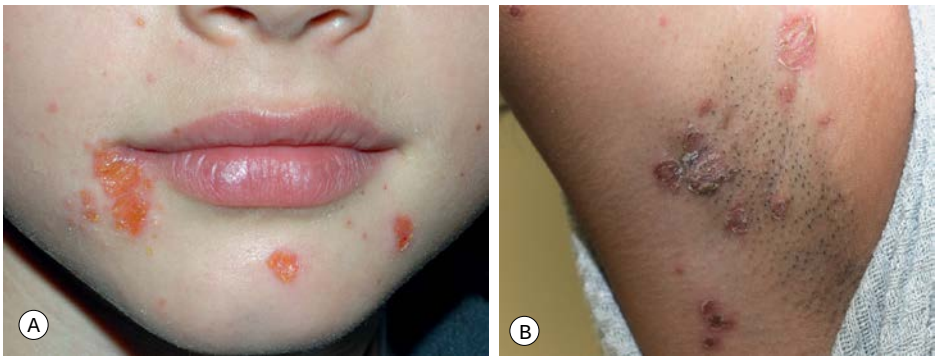


**Fig. 61.2 Staphylococcal impetigo. A** Honey-colored crusts on the chin and cheeks of a child with impetigo. **B** Superficial round to oval erosions with central thin crusting and a peripheral collarette due to bullous impetigo in the axilla. *A, Courtesy, Julie V. Schaffer, MD; B, Courtesy, Kalman Watsky, MD.*

• **Rx:** for superficial form – antibacterial washes (e.g. benzoyl peroxide, chlorhexidine) or topical gels (e.g. combination clindamycin /benzoyl peroxide); widespread staphylococcal folliculitis – oral antibiotics (see Table 61.1).

### ABSCESSES, FURUNCLES, AND CARBUNCLES

• Abscesses are localized collections of pus. By definition, a furuncle is an abscess involving a hair follicle; involvement of multiple, adjacent follicles is termed a carbuncle (see Fig. 61.1).
• Most common organism is *S. aureus*, and this is the most frequent presentation for community-acquired MRSA (CA-MRSA).
• Clinically, furuncles appear as firm, tender, red nodules; carbuncles begin similarly but become larger in size and can develop multiple draining sinus tracts.
• Common locations for furuncles are the face, neck, axillae, buttocks, perineum, and thighs. Carbuncles often favor the trunk and thighs and heal with scarring.
• **DDx:** ruptured epidermoid cyst, hidradenitis suppurativa, and cystic acne.
• **Rx:** fluctuant lesions should be incised and drained. Administration of systemic antibiotics (see Table 61.1 for **Rx** options) reduces recurrence, even for small, isolated lesions and are indicated for: (1) furuncles around the nose, in the external auditory canal, or in other locations where drainage is difficult; (2) severe or extensive disease (e.g. multiple sites); (3) lesions with surrounding cellulitis/phlebitis or associated with signs or symptoms of systemic illness; (4) lesions not responding to local care; and (5) patients with concerning comorbidities or immunosuppression.

### ERYSIPELAS

• Most commonly due to *Streptococcus pyogenes*.
• Represents infection of the superficial dermis along with significant lymphatic involvement; often on the face and neck or the leg.
• Presents as a well-defined area of hot, indurated, bright erythema that is painful and tender (Fig. 61.4); occasionally, there may be superimposed pustules, vesicles, bullae, or areas of hemorrhagic necrosis.
• Favors the young, debilitated, elderly, and limbs with edema or lymphedema.
• **DDx:** cellulitis, irritant contact dermatitis, early necrotizing fasciitis or herpes zoster, erysipeloid breast cancer, erysipeloid, Sweet syndrome, and if it involves the ear, chondritis.
• **Rx:** 10- to 14-day course of penicillin if due to *Streptococcus pyogenes*, with route depending on the severity and risk factors.

### STREPTOCOCCAL INTERTRIGO, PERIANAL AND VULVOVAGINAL STREPTOCOCCAL INFECTION

• Sharply demarcated, bright red erythema, especially in young children (see Fig. 61.4 and Table 60.5).

| EMPIRIC TREATMENT OF CUTANEOUS STAPHYLOCOCCAL AND STREPTOCOCCAL INFECTIONS IN ADULTS | | |
|---|---|---|
| **Organism/situation** | | **Suggested antibiotics** |
| Streptococci | Confirmed | • Amoxicillin 500 mg PO TID<br>• Penicillin VK 500 mg PO four times a day |
| | Empiric treatment to cover both streptococci and staphylococci | • First-generation cephalosporin (see below)<br>• Dicloxacillin 500 mg PO four times a day<br>• Nafcillin or oxacillin 1–2 gm IV four times a day, if severe |
| Suspected MSSA (e.g. impetigo requiring systemic treatment or non-purulent cellulitis) or streptococci | | • First-generation cephalosporin, e.g. cephalexin 250–500 mg PO three or four times a day<br>• Dicloxacillin 250–500 mg PO four times a day<br>• Amoxicillin-clavulanate 875/125 mg PO BID |
| Suspected CA-MRSA (e.g. furuncles/abscesses, purulent cellulitis, or infections that failed to respond to MSSA treatment)<br>• Risk factors include participation in contact sports, other close interpersonal contact (e.g. military personnel), injection drug use | | • Doxycycline 100 mg PO two times a day*<br>• Trimethoprim-sulfamethoxazole 1 or 2 double-strength tablets PO twice a day*<br>• Clindamycin 300–450 mg PO four times a day<br>• Linezolid, tedizolid, delafloxacin |
| Suspected hospital-acquired MRSA (HA-MRSA)<br>• Risk factors include recent contact with hospitals or health care facilities such as nursing homes or dialysis units | | • See Suspected CA-MRSA |
| Penicillin-allergic patients | | • Clindamycin (see above)<br>• Clarithromycin 250 mg PO two times a day |
| Additional special considerations | | • Furuncle/abscess: incision and drainage (without packing) is a key component of successful Rx<br>• If recurrent infections, address carrier state:<br>– Mupirocin 2% nasal ointment twice a day for 5 days<br>– Mupirocin 2% cream to major body folds, e.g. axillae, groin, inframammary, as well as umbilicus<br>– Wash body with chlorhexidine, bathe in dilute Clorox® (see Fig. 10.12A) once or twice a week, or use spray bottle with dilute Clorox®<br>• Address fomites including sports equipment<br>• Consider close human contacts or pets as source of infection |

**Does not provide coverage of group A streptococci; if coverage of the latter is desired, a β-lactam is also prescribed.*

**Table 61.1 Empiric treatment of cutaneous staphylococcal and streptococcal infections in adults.** Treatment duration is usually 5–10 days, depending on the severity and clinical response. Initial choice of antibiotic is dependent on known resistance patterns in a given community. The contents of pustules or exudate (e.g. underlying a crust) should be sent for culture and sensitivities prior to beginning therapy. Quinolones and macrolides are not optimal for treatment of community-acquired methicillin-resistant *Staphylococcus aureus* (CA-MRSA) because resistance is common and may develop rapidly. MSSA, methicillin-sensitive *Staphylococcus aureus*.



**Fig. 61.3 Ecthyma.** Ulceration with hemorrhagic crust due to infection with group A streptococci. *Courtesy, Karynne O. Duncan, MD.*

- **DDx:** outlined in Fig. 13.4 and Table 60.5.
- **Rx:** 7- to 10-day course of a first-generation cephalosporin (see Table 61.1) or penicillin.

### CELLULITIS

- Most commonly due to *Streptococcus pyogenes* or *S. aureus*; in diabetics and immunocompromised hosts, other organisms (e.g. Gram-negative bacilli) may be the cause.
- In children, *Haemophilus influenzae* can be a cause of cellulitis, but its incidence has decreased since introduction of the *H. influenzae* vaccine.
- Infection of the deep dermis and sometimes the subcutaneous fat (see Fig. 61.1).
- Skin rubor (redness), calor (warmth), dolor (pain), and tumor (swelling) are present; more ill-defined borders than erysipelas and may have skip areas; can become bullous or necrotic (Figs 61.5 and 75.9).

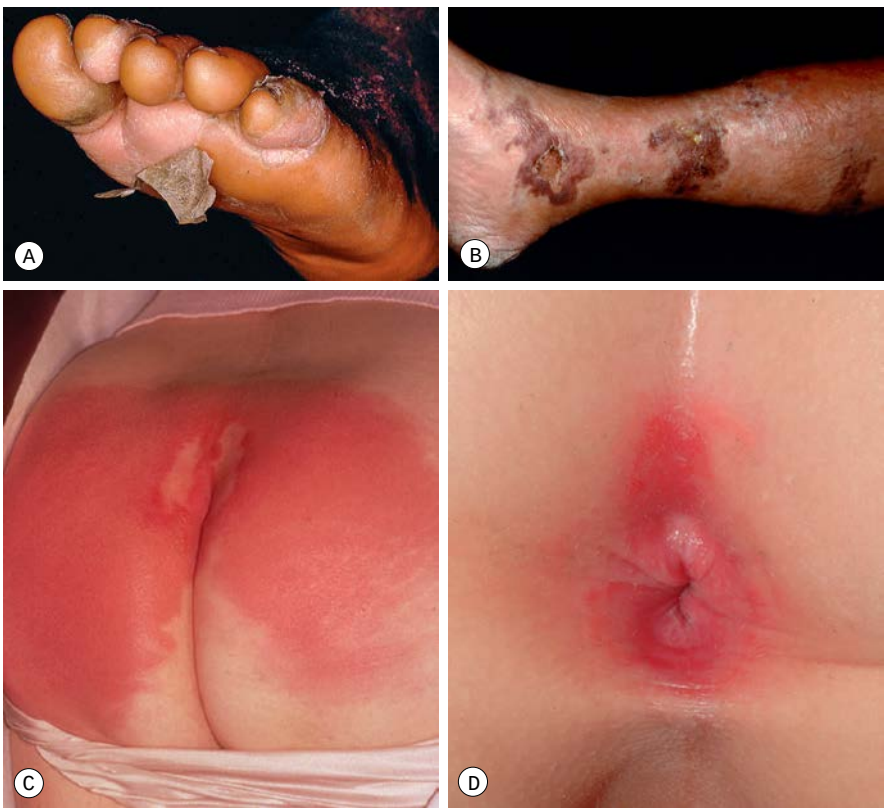


**Fig. 61.4 Cutaneous manifestations of streptococcal infections.** Prominent desquamation of the feet (**A**) following scarlet fever. Multiple areas of necrotic crusting and focal purulence due to streptococcal cellulitis (**B**). Sharply demarcated erythema of the buttocks (**C**) in erysipelas. Bright red erythema extending from the anal verge in a young boy with streptococcal perianal disease (**D**). *A, Courtesy, Eugene Mirrer, MD; B, YDRSC; C, Courtesy, Mary Stone, MD; D, Courtesy, Julie V. Schaffer, MD.*

• Systemic symptoms include fever, chills, and malaise; CBC usually shows leukocytosis and bandemia.
• Risk factors for cellulitis of the lower extremity include previous DVT, previous cellulitis with lymphangitis, chronic edema, and tinea pedis (especially in patients who have undergone saphenous venectomy).
• **DDx:** on the lower extremity, lipodermatosclerosis and stasis dermatitis (see Fig. 11.5); elsewhere, erysipelas and the early stage of necrotizing fasciitis, as well as causes of pseudocellulitis (Table 61.2).
• **Rx:** see Table 61.1.



**Fig. 61.5 Bullous cellulitis.** Edema and confluent bullae. *Courtesy, YDRSC.*

### BLISTERING DISTAL DACTYLITIS

• Secondary to GAS > *S. aureus.*
• Localized infection of the volar fat pad of a finger or, less often, a toe; occurs most commonly in children.
• Initially erythema and swelling of the skin, followed by development of one or more vesicles or bullae.
• **DDx:** herpetic whitlow, burn, acute paronychia, bullous impetigo, frictional bulla.
• **Rx:** drainage of blisters and systemic antibiotics (see Table 61.1).

### BOTRYOMYCOSIS

• Most commonly caused by *S. aureus*, followed by *Pseudomonas* spp.
• Cutaneous and subcutaneous nodules that may have superimposed pustules, purulent discharge, or become ulcerative or verrucous; often in immunosuppressed hosts.

**CAUSES OF "PSEUDOCELLULITIS"**

**Infections and bites**
- Arthropod bite reactions (e.g. insect, spider)
- Erythema migrans
- Herpes zoster
- Toxin-mediated erythema (e.g. recurrent toxin-mediated perineal erythema)

**Neutrophilic dermatoses**
- Sweet syndrome, neutrophilic panniculitis
- Familial Mediterranean fever, other periodic fever syndromes

**Drug reactions**
- Fixed drug eruptions (especially non-pigmenting)
- Vaccine/injection site reactions
- Toxic erythema of chemotherapy (e.g. due to gemcitabine), neutrophilic eccrine hidradenitis*

**Other inflammatory disorders**
- Allergic contact dermatitis (including airborne and dermal)
- Phytophotodermatitis
- Well syndrome
- Panniculitis, e.g. lipodermatosclerosis, erythema nodosum
- Thrombophlebitis
- Angioedema
- Interstitial granulomatous dermatitis, inflammatory granuloma annulare
- Inflammatory morphea

**Metabolic disorders**
- Gout

**Malignancy**
- Erysipeloid skin metastases (especially breast carcinoma)

**Occasionally develops prior to onset of leukemia or due to infection.*

**Table 61.2 Causes of "pseudocellulitis."**

- Grains, representing macroscopic colonies of bacteria, are seen in biopsy specimens as well as the pustular discharge; grains are also seen in eumycotic and actinomycotic mycetoma (see Ch. 64) and actinomycosis (see below).
- Often develops at sites of trauma.
- **DDx:** ruptured epidermoid cyst, abscess, actinomycotic or eumycotic mycetoma, actinomycosis, and atypical mycobacterial or dimorphic fungal infection.
- **Rx:** surgical excision with debridement and/or antibiotic therapy based on pathogenic organism.

### NECROTIZING FASCIITIS

- Usually represents polymicrobial infection with both anaerobes and aerobes; ~10% secondary to GAS; other organisms include community-acquired MRSA.
- Rapidly progressive necrosis of subcutaneous fat and fascia that leads to undermining and ulceration; may have a foul discharge and not bleed on incision.
- Risk factors include older age, diabetes mellitus, alcoholism, peripheral vascular disease, and immunosuppression.
- Initially may resemble cellulitis, but associated pain is often out of proportion to the clinical findings and may extend beyond the area of apparent involvement; additional clues include tense edema, blisters, crepitus, and a mottled violaceous or pale gray color reflecting impending necrosis (Figs 61.6 and 75.10).



**Fig. 61.6 Necrotizing fasciitis.** Tense, woody edema of the forearm with purple-gray areas of necrosis and bullae with watery discharge. Intravenous drug use was a predisposing factor. *Courtesy, Luis Requena, MD.*

- Diagnosis requires a high index of suspicion; when anogenital, it is referred to as Fournier gangrene.
- Patients may have fever, chills, malaise, and leukocytosis.
- Dx: outlined in Fig. 61.7.
- **DDx:** cellulitis, trauma with hematoma, pyomyositis, clostridial myonecrosis, phlebitis.
- **Rx:** surgical debridement is the mainstay of therapy; broad-spectrum IV antibiotics.

### PYOMYOSITIS

- Primary bacterial infection of skeletal muscle, most commonly with *S. aureus* (see Fig. 61.1); associated with immunosuppression, including HIV infection.

### STAPHYLOCOCCAL SCALDED SKIN SYNDROME (SSSS)

- Secondary to *S. aureus*, phage group II strains, which produce exfoliative toxins that bind to desmoglein 1 and lead to dissolution (i.e. acantholysis) of the upper epidermis.
- More commonly seen in infants and children; occasionally, adults with chronic renal insufficiency can develop SSSS.
- Prodrome of malaise, fever, irritability, sore throat, and tender skin; purulent rhinorrhea or conjunctivitis may be present because the initial site of staphylococcal infection is usually extracutaneous.
- Tender erythema on the face and in intertriginous zones that generalizes to the remainder of the body over 1 or 2 days; due to the split in the upper epidermis, the skin becomes "wrinkled" and then sloughs over 3–5 days, leading to denuded areas; on the face, radial fissures with scale-crust develop around the mouth and eyes (Fig. 61.8; see Fig. 3.9).
- **DDx:** sunburn, drug reaction, Kawasaki disease (erythema often first appears in the groin), Stevens–Johnson syndrome/toxic epidermal necrolysis (SJS/TEN; usually affects older children and adults, has mucosal involvement, and nearly always drug-induced).
- **Rx:** hospitalization and IV anti-staphylococcal antibiotics (see Table 61.1).

### TOXIC SHOCK SYNDROME (OTHER THAN STREPTOCOCCAL) (TSS)

- Secondary to *Staphylococcus aureus*, which produces an exotoxin, toxic shock syndrome toxin-1.

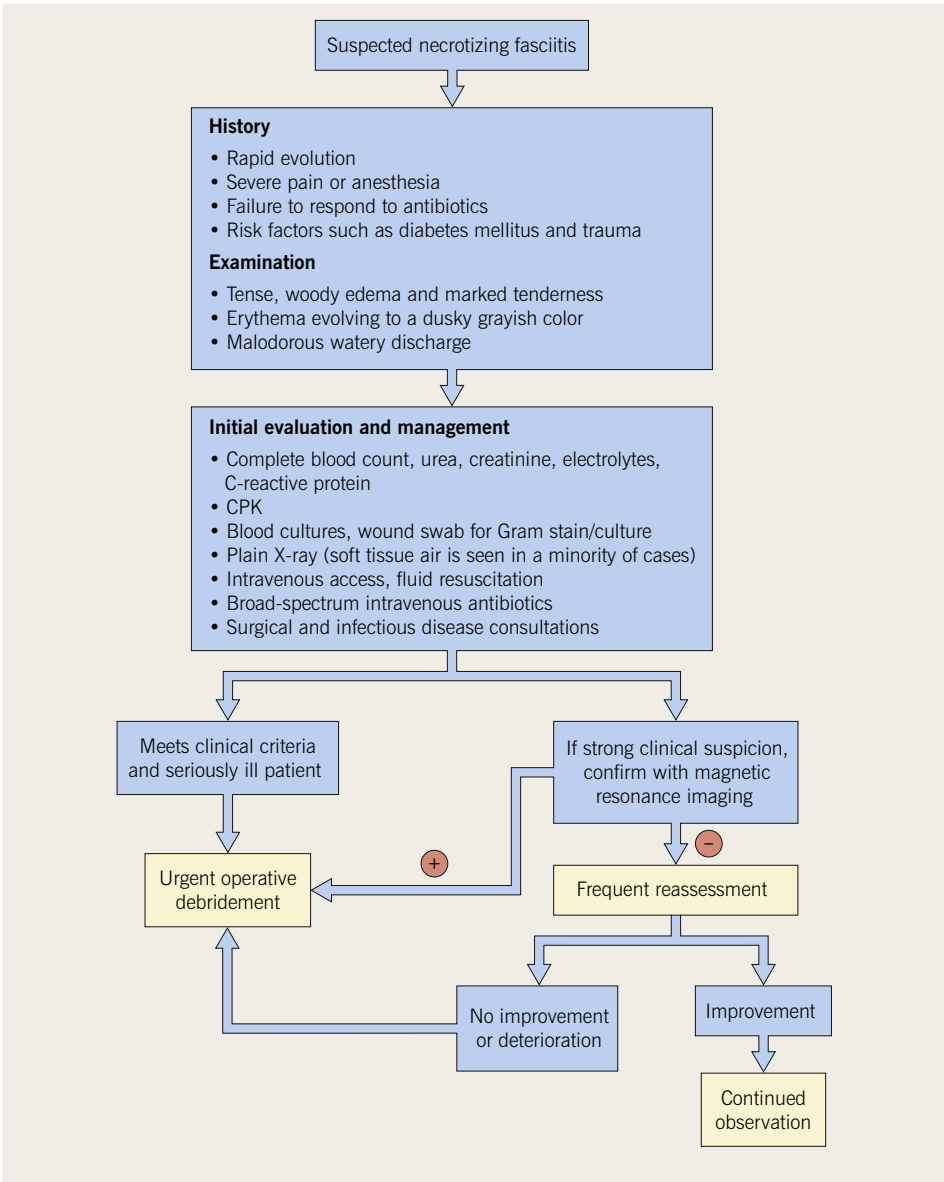


**Fig. 61.7 Algorithm for assessment and treatment of suspected necrotizing fasciitis.** CPK, creatine phosphokinase.

- Case definition of staphylococcal TSS is outlined in Table 61.3.
- Historically associated with menstruation and tampon use, but nowadays with surgical packing, meshes, and cutaneous infections (e.g. abscesses).
- Sudden onset of high fever, myalgias, vomiting, diarrhea, headache, and pharyngitis; hypotension is a key finding.
- Clinically, scarlatiniform changes initially appear on the trunk and then spread centrifugally; erythema and edema of the palms and



**Fig. 61.8 Staphylococcal scalded skin syndrome.** Extensive involvement on the neck with a wrinkled appearance of the erythematous skin in addition to peeling and multiple erosions. *Courtesy, Julie V. Schaffer, MD.*

soles can be followed by desquamation 1–3 weeks later.
- Mucous membrane findings: erythema, strawberry tongue, hyperemia of the conjunctivae (Fig. 61.9).
- **DDx:** streptococcal TSS, drug reaction plus hypotension from sepsis; in children, Kawasaki disease and scarlet fever.
- **Rx:** hospitalization and IV antibiotics (see Table 61.1).

#### STREPTOCOCCAL TOXIC SHOCK SYNDROME (STREPTOCOCCAL TSS)
- Secondary to GAS (especially M types 1 and 3), which produce exotoxins A and/or B.
- Case definition of streptococcal TSS is outlined in Table 61.3.
- Most common site of the associated streptococcal infection is the skin, e.g. cellulitis or necrotizing fasciitis.
- **Rx:** hospitalization and IV antibiotics (see Table 61.1).

#### SCARLET FEVER
- Secondary to GAS, which produce erythrogenic toxins types A, B, and C.
- Seen in children (ages 1–10 years), usually following streptococcal tonsillitis or pharyngitis.
- Sore throat, headache, malaise, chills, anorexia, nausea, and high fevers precede erythema of the neck, chest, and axillae that becomes generalized over 4–6 hours.
- The erythema blanches with pressure and is studded with tiny papules ("sunburn with goose pimples"); the cheeks are also flushed with circumoral pallor.
- Pastia lines (linear petechial streaks) are seen in major body folds, e.g. axillary, inguinal, antecubital.
- Desquamation of distal digits occurs after 7–10 days.
- Postinfectious sequelae include acute glomerulonephritis and rheumatic fever.
- **DDx** of palmoplantar desquamation: Kawasaki disease, TSS, and any preceding infection (including viral) with a high fever.
- **DDx** of exanthem: drug eruption, viral exanthem, early SSSS; a scarlatiniform eruption is also seen in TSS and Kawasaki disease.
- **Rx:** 10- to 14-day course of penicillin or amoxicillin.

#### BACTEREMIA/SEPTICEMIA
- Septic emboli can present as petechiae and purpura that may develop central pustules or hemorrhagic bullae; subcutaneous abscesses can also be seen.
- Endocarditis can be acute or subacute and caused by organisms including *S. aureus* and *Streptococcus* spp., respectively; cutaneous signs of endocarditis include splinter hemorrhages (see Ch. 58), Osler nodes, and Janeway lesions (see Table 18.2).

## Gram-Positive Bacilli

### Clostridial Skin Infections
- *Clostridia* spp. are Gram-positive bacilli that live on dead organic matter and can cause anaerobic cellulitis or myonecrosis (gas gangrene); they account for half of the normal skin microbiota.
- Anaerobic cellulitis.
  - Risk factors: trauma, diabetes mellitus, peripheral vascular disease, and injection drug use
  - Generally due to *Clostridium perfringens* > other anaerobic bacteria (e.g.

| CASE DEFINITIONS FOR THE TOXIC SHOCK SYNDROMES |
|---|
| **Toxic shock syndrome (other than streptococcal)** |
| • Fever: temperature >102°F (or >38.9°C)<br>• Rash: diffuse macular erythroderma<br>• Desquamation: 1–2 weeks after the onset of illness (especially palms and soles)<br>• Hypotension: systolic blood pressure <90 mmHg for adults (<5th percentile for children)<br>• Involvement of three or more of the following organ systems:<br>– Gastrointestinal<br>– Muscular<br>– Central nervous<br>– Renal<br>– Hepatic<br>– Mucous membranes (erythema)<br>– Hematologic (platelets <100,000/mm$^3$)<br>• Negative results for the following tests (if done):<br>– Blood and cerebrospinal fluid cultures (blood culture may be positive for *Staphylococcus aureus*)<br>– Serologic tests for Rocky Mountain spotted fever, leptospirosis, measles |
| **Streptococcal toxic shock syndrome** |
| • Isolation of group A streptococci from a normally sterile site* (e.g. blood, cerebrospinal fluid, tissue biopsy, surgical wound)<br>*or*<br>• Isolation of group A streptococci from a nonsterile site† (e.g. throat, sputum, vagina, superficial skin lesion)<br>*and*<br>• Hypotension: systolic blood pressure <90 mmHg for adults (<5th percentile for children)<br>*and*<br>• Two or more of the following signs:<br>– Renal impairment<br>– Coagulopathy (platelets ≤100,000/mm$^3$ or disseminated intravascular coagulation)<br>– Liver impairment<br>– Acute respiratory distress syndrome<br>– Generalized erythematous macular rash ± desquamation<br>– Soft tissue necrosis (e.g. necrotizing fasciitis, myositis, gangrene) |
| **Defined as a definite case.*<br>*†Defined as a probable case, excluding any other possible etiology.* |

**Table 61.3 Case definitions for the toxic shock syndromes.** See https://ndc.services.cdc.gov/case-definitions/toxic-shock-syndrome-2011/ and https://ndc.services.cdc.gov/case-definitions/streptococcal-toxic-shock-syndrome-2010/ for details on the current case definitions.

*Bacteroides*); incubation period >3 days with a rapid course

– Minimal visible skin changes; signs include crepitus and a thin, dark gray-brown, foul-smelling ("dirty dishwater") exudate; pain often absent or mild without symptoms of toxemia (e.g. tachycardia)

• Myonecrosis, in contrast to anaerobic cellulitis, has a shorter incubation period with a very rapid course; overlying skin has a dark yellow to bronze discoloration, sometimes with bullae or necrosis, and severe swelling; toxemia (e.g. hypotension) is generally present.

• **Rx:** early surgical debridement and empirical antibiotics (e.g. clindamycin plus a third-generation cephalosporin) until culture and sensitivities obtained.

## *Corynebacterium* (and *Kytococcus*) Skin Infections

### ERYTHRASMA

• Superficial, localized infection due to *Corynebacterium minutissimum*.

• Three major clinical variants:

– Interdigital – the most common variant, characterized by chronic maceration with fissuring or scaling; needs to be distinguished from interdigital tinea pedis

– Intertriginous – thin red-brown plaques in the axillae and groin/upper inner thigh that may be misdiagnosed as tinea cruris (see Table 60.5; Fig. 61.10)

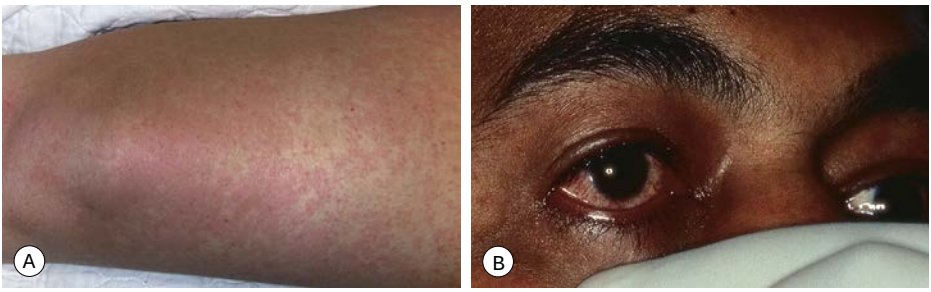


**Fig. 61.9 Toxic shock syndrome due to *Staphylococcus aureus* infection. A** Blotchy erythema is evident on the thigh. **B** Hyperemia of the conjunctiva is seen. *Courtesy, YDRSC.*

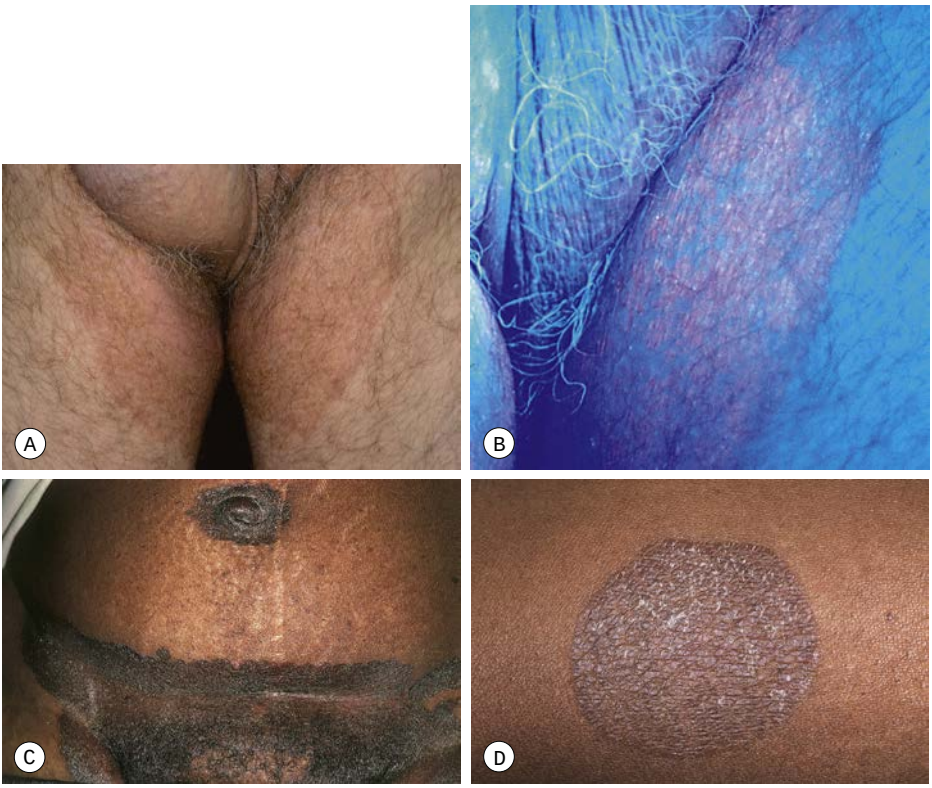


**Fig. 61.10 Erythrasma. A** Pink to brown scaly patches on the upper inner thighs. **B** Coral-red fluorescence upon illumination with a Wood's lamp. **C** Hyperpigmented plaques in the inguinal and periumbilical areas (intertriginous zones). **D** Well-demarcated, scaly, hyperpigmented plaque of disciform erythrasma. *A, B, Courtesy, Louis A. Fragola, Jr., MD; C, D, Courtesy, NYUDSC.*

  - "Disciform" – often on the trunk and diabetes mellitus is a risk factor (Fig. 61.10D)

• Bright, coral-red fluorescence with Wood's lamp examination (see Figs 61.10B and 13.2).

• **Rx:** topical clindamycin or erythromycin; prevent moisture accumulation with topical aluminum chloride 6–20% (axillae).

### PITTED KERATOLYSIS

• Secondary to *Kytococcus sedentarius* (*Micrococcus sedentarius*) and *Corynebacterium* spp.

• Hyperhidrosis, prolonged occlusion, and increased surface pH are contributing factors; the latter plus bacterial infection lead to 1- to



**Fig. 61.11 Pitted keratolysis of the plantar surface of the foot.** Multiple craters with decreased stratum corneum that favor pressure points on the plantar surface. *Courtesy, Kalman Watsky, MD.*



**Fig. 61.12 Trichomycosis axillaris.** Cylindrical sheaths and beading of the axillary hairs. A yellow color is seen most commonly. *Courtesy, YDRSC.*

3-mm crater-like depressions in the stratum corneum that may coalesce, with involvement of soles >> palms (Fig. 61.11).

- Often accompanied by a distinctive malodor.
- **Rx:** topical clindamycin or erythromycin; decrease eccrine sweat production with topical aluminum chloride 20%.

#### TRICHOMYCOSIS AXILLARIS

- Common disorder that may be clinically subtle; often accompanied by malodor.
- Hair shafts are ensheathed with adherent yellow > red or black concretions composed of organisms (Fig. 61.12); most common in the axillae and a cause of chromhidrosis (see Ch. 32).
- **DDx:** other causes of nodules on hair shafts (see Fig. 64.3).

**CUTANEOUS ANTHRAX – CLINICAL CHARACTERISTICS**

- Incubation period averages 7 days (range 1–12 days)
- A purpuric macule or papule develops in an exposed area (e.g. forearm, neck, chest, finger); the papule may resemble an insect bite and can be pruritic
- Within 48 hours of the lesion's appearance, a vesicle (1–3 mm) forms with surrounding non-pitting edema
- The central vesicle ulcerates and small vesicles may form around the ulcer
- The lesion becomes hemorrhagic and depressed, and a *painless*, black, necrotic eschar forms centrally with an increase in the surrounding erythema and edema
- The eschar dries, loosens, and sloughs over the next 1–2 weeks, with no permanent scar

**Table 61.4 Cutaneous anthrax – clinical characteristics.** *Adapted from Carucci JA, McGovern TW, Norton SA,* et al. *Cutaneous anthrax management algorithm. J. Am. Acad. Dermatol. 2002;47:766–769.*

- **Rx:** shaving of hair; topical antimicrobials (e.g. benzoyl peroxide, erythromycin) can help prevent recurrence.

## Other Gram-Positive Skin Infections

#### ANTHRAX

- *Bacillus anthracis* causes inhalational, gastrointestinal, and cutaneous disease.
- Occurs most commonly in farmers and ranchers exposed to animals such as sheep, cows, horses, and goats; also secondary to exposure to hides from these animals (e.g. skins used for drums).
- Emerged as an agent of biological terrorism.
- Clinical characteristics of cutaneous disease are outlined in Table 61.4.
- **Rx** for cutaneous disease: fluoroquinolone (e.g. ciprofloxacin 500 mg PO twice daily) for 7–10 days or 60 days if also risk of inhalational disease.
- Prevention: vaccine (e.g. raxibacumab) for high-risk populations (e.g. military).

#### ERYSIPELOID

- Due to *Erysipelothrix rhusiopathiae*.
- Variants:
  - Localized cellulitis – infection due to traumatic inoculation; seen in individuals



**Fig. 61.13 Erysipeloid.** Erythema and edema with vesicle formation on the hand and fifth digit. *Courtesy, NYUDSC.*



**Fig. 61.14 Acute meningococcemia.** Purpura with irregular outline and central gunmetal gray color. *Courtesy, Kalman Watsky, MD.*

who prepare fish and meat; the hand is a frequent site of involvement and the color is characteristically red-violet (Fig. 61.13)

– Generalized – uncommon form; multiple pink plaques, usually in the setting of immunosuppression, with associated fever and arthralgias; blood cultures are generally negative

• **DDx** of localized form: cellulitis due to more common infectious agents (see above), atypical mycobacterial infection, early *Vibrio* infection.

• **Rx** for localized form: penicillin 500 mg PO four times a day for 7–10 days.

## Gram-Negative Cocci

### ACUTE MENINGOCOCCEMIA

• Systemic infection due to *Neisseria meningitides*.

• Primarily seen in young children (6 months to 1 year of age) and young adults in close quarters (e.g. dormitories, barracks).

• In most individuals, infection results in an asymptomatic carrier state.

• In acute meningococcemia, one-third to one-half of patients have skin lesions due to septic emboli, initially subtle petechiae that evolve into irregularly shaped purpura with a central gunmetal gray color that reflects necrosis (Fig. 61.14); Gram-negative cocci may be seen on Gram staining of lesional tissue.

• The septic lesions are to be distinguished from those due to disseminated intravascular coagulation (see Table 18.1).

• Additional systemic manifestations include fever, chills, hypotension, meningoencephalitis, pneumonia, pericarditis, and myocarditis.

• **Rx:** IV penicillin or ceftriaxone; vaccination is important for prevention.

### CHRONIC MENINGOCOCCEMIA

• An indolent infection due to *Neisseria meningitides*.

• Recurrent episodes of fever, chills, night sweats, and arthralgias; skin lesions are polymorphous, e.g. pink macules and papules, nodules, petechiae/purpura; the skin lesions represent small vessel vasculitis without visible organisms by light microscopy, but PCR may be used to detect organisms.

• **Rx** as for acute meningococcemia; close contacts should be treated as well.

### GONORRHEA & DISSEMINATED GONOCOCCAL INFECTION

See Chapter 69.

## Gram-Negative Bacilli

### Pseudomonal Infections

Green nail syndrome is discussed in Chapter 58.

### GRAM-NEGATIVE TOE-WEB INFECTION

• Although *Pseudomonas aeruginosa* is the most common cause, other Gram-negative bacilli can be implicated (e.g. *Escherichia coli*, *Proteus mirabilis*).

• Risk factors are pre-existing tinea pedis and occlusion (e.g. tight-fitting shoes).

• Symptoms of burning and pain; signs include a malodorous exudate with a



**Fig. 61.15 Severe superficial infection of the skin with *Pseudomonas*.** Note the macerated border, the erosions, and the moth-eaten appearance of the skin. Often represents secondary infection superimposed on interdigital tinea pedis. *Courtesy, Kalman Watsky, MD.*

blue-green tinge, a grape-juice odor, and a moth-eaten appearance of skin due to maceration and erosions (Fig. 61.15).

- In severe cases, there can be cellulitis.

### OTITIS EXTERNA ("SWIMMER'S EAR")

- Swollen auditory ear canal with greenish purulent discharge.
- Extreme pain with manipulation of the pinna.
- **Rx:** antimicrobial drops (e.g. ofloxacin) with or without an ear wick, oral analgesics (e.g. NSAIDs).

### PSEUDOMONAL FOLLICULITIS (HOT TUB FOLLICULITIS)

See Table 31.2.

### *PSEUDOMONAS* HOT-FOOT SYNDROME

- Develops acutely on the soles of children and adolescents who are otherwise healthy after swimming in water with high concentrations of *Pseudomonas aeruginosa*.
- Painful and tender, red-purple, 1- or 2-cm nodules appear on the weight-bearing aspects of the feet (Fig. 61.16).
- Self-limiting and **DDx** is primarily idiopathic palmoplantar hidradenitis (Ch. 32).



**Fig. 61.16 *Pseudomonas* hot-foot syndrome.** Tender erythematous nodules on the heel. *Courtesy, Justin J. Green, MD.*



**Fig. 61.17 Ecthyma gangrenosum.** Embolic lesion of *Pseudomonas aeruginosa* on the chest. Note the necrotic center and inflammatory border. *Courtesy, YDRSC.*

### CELLULITIS

- Clinical features are similar to those of cellulitis due to *S. aureus* (see above); can occur on the lower extremity in the setting of Gram-negative toe-web infection or on the external ear postoperatively.
- Sometimes, it can be difficult to distinguish soft tissue infection from colonization with *Pseudomonas*, particularly in chronic ulcers.

### ECTHYMA GANGRENOSUM

- A sign of bacteremia or septicemia.
- Most commonly due to Gram-negative bacilli, including *Pseudomonas*, but can also be due to opportunistic fungi; primarily seen in immunocompromised hosts, especially those with prolonged neutropenia.
- A red-purple macule or patch that develops central necrosis; sometimes the necrosis is preceded by a hemorrhagic bulla; the number can vary from one to a dozen or more (Fig. 61.17).

• The most common location for ecthyma gangrenosum due to *Pseudomonas* is the groin.
• To establish the diagnosis, culture of tissue, obtained via sterile biopsy technique (see Fig. 2.10), is performed in combination with histopathology.

#### TREATMENT OF PSEUDOMONAL INFECTIONS

• For superficial infection (e.g. Gram-negative toe-web infection): 5% acetic acid soaks followed by application of a topical antibiotic (e.g. gentamicin, silver sulfadiazine); if minimal improvement or severe, oral fluoroquinolone.
• For severe or systemic infections: piperacillin/tazobactam or doripenem if penicillin-allergic; may be combined with an aminoglycoside antibiotic.

### Diseases Caused by *Bartonella* Species

See Table 61.5.

### Other Gram-Negative Skin Infections with Fever and Skin Findings

See Table 61.6, Table 61.7.

### Spirochetes

#### LYME DISEASE

See Chapter 15.

#### SYPHILIS

See Chapter 69.

#### OTHER TREPONEMAL DISEASES

• Like syphilis, other treponemal diseases may have primary, secondary, and tertiary stages.
• Endemic syphilis.
  – Due to *Treponema pallidum endemicum*
  – Seen most commonly in Africa, the Arabian peninsula, and Southeast Asia
  – Children younger than the age of 15 years are most often affected
  – Primary lesion often missed
  – Secondary stage: macerated patches on lips, tongue, and pharynx; angular stomatitis; condyloma lata; generalized lymphadenopathy
  – Tertiary stage: gummas that can lead to destruction of the palate and nasal septum
• Pinta.
  – Due to *T. carateum*
  – Seen primarily in Central and South America
  – Primary stage: minute macules or papules with erythematous haloes, most commonly on the lower extremities, that develop into infiltrated plaques over several months
  – Secondary stage: smaller, variably pigmented (red, blue, black, or hypopigmented), scaly macules and papules that may coalesce; clustered near the initial primary lesion or generalized
  – Tertiary stage: symmetric, depigmented, vitiligo-like lesions that are atrophic or keratotic
• Yaws.
  – Due to *T. pallidum pertenue*
  – Seen in warm, humid, tropical climates
  – Children younger than the age of 15 years are most often affected
  – Primary: erythematous, infiltrated, painful papule, usually on the extremities; enlarges to become up to 5 cm in diameter and ulcerates; heals spontaneously over 3–6 months
  – Secondary: smaller lesions adjacent to orifices or adjacent to site of initial primary lesion (Fig. 61.18)
  – Tertiary: destructive skin lesions, palmoplantar thickening that can lead to difficulty with ambulation, chronic osteitis (sabre tibia)

### Filamentous Bacteria

#### ACTINOMYCOSIS

• Most commonly due to *Actinomyces israelii.*
• Three major sites of involvement – cervical, pulmonary, and gastrointestinal.
• Skin involvement is most common with the cervical variant and is sometimes referred to as "lumpy jaw" due to irregular subcutaneous nodules; the latter can drain and the exudate contains grains (Fig. 61.19).
• **Rx:** penicillin.

#### ACTINOMYCOTIC MYCETOMA

• Most commonly due to *Nocardia* as well as *Actinomadura madurae*, *Actinomadura pelletieri*, and *Streptomyces somaliensis*; organisms are found in soil and on plant material (Table 61.8).

| MAJOR HUMAN DISEASES CAUSED BY *BARTONELLA* SPECIES | | | | |
|---|---|---|---|---|
| **Species** | **Disease** | **Vector** | **Epidemiology** | **Clinical features** |
| *B. henselae* | Cat-scratch disease | Cat flea (*Ctenocephalides felis*)* | Young people, <18 years of age | • Lymphadenopathy<br>• Systemic symptoms (e.g. fever, malaise) |
| | Bacillary angiomatosis | | Immunocompromised patients | • Bright red papules that can resemble pyogenic granulomas; lichenoid papules/plaques; subcutaneous nodules<br>• Hepatic involvement (peliosis) |
| *B. bacilliformis* | Bartonellosis (Carrion disease, Oroya fever, verruga peruana) | Sand fly (*Lutzomyia verrucarum*) | Peru, Ecuador, and southwestern Colombia | • Oroya fever – fever, hemolytic anemia, secondary bacterial infections, e.g. *Salmonella*<br>• Verruga peruana – erythematous patches with overlying bright red papules and nodules |
| *B. quintana* | Trench fever/"urban" trench fever | Human body louse (*Pediculus humanus corporis*) | Originally seen in World War I troops; today, associated with homelessness and poor hygiene | Relapsing fever |
| | Bacillary angiomatosis | | See above | See above |

*More commonly by a cat scratch or bite.

**Table 61.5 Major human diseases caused by *Bartonella* species.** Treatment must be tailored to the particular presentation; commonly employed antibiotics include azithromycin, erythromycin, doxycycline, and/or rifampin. Therapy may be administered for up to 3 months.

| SELECTED GRAM-NEGATIVE INFECTIONS THAT PRESENT WITH NONSPECIFIC SYSTEMIC SYMPTOMS (E.G. FEVER) AND SKIN FINDINGS | | | | |
|---|---|---|---|---|
| **Infection** | **Common organism(s)** | **Transmission/other factors** | **Unique/characteristic findings** | **Skin findings** |
| Infection with *Vibrio vulnificus* | *Vibrio vulnificus* | Raw seafood or exposure of cutaneous wounds to infected sea water, primarily in warmer climates; patients at risk are middle-aged men with chronic liver disease or diabetes | | Hemorrhagic bullae with cellulitis |
| Tularemia | *Francisella tularensis* | Infected rabbits; deerfly or tick (e.g. *Amblyomma americanum*) as vector | May show sporotrichoid pattern | Ulcers, lymphadenopathy |
| Glanders | *Burkholderia mallei* | Direct contact with infected animals (horses, mules, donkeys) | Sporotrichoid (lymphocutaneous) pattern | Nodule, pustule, or vesicle surrounded by erythema |
| Plague | *Yersinia pestis* | Contaminated food, water, or raw milk; fleas can be the vector | Bubonic form can have a sporotrichoid pattern | • Bubonic form due to inoculation: wound becomes a pustule or ulcer with painful regional lymphadenopathy<br>• Septicemic form: emboli present as vesicles, carbuncles, petechiae, or purpura |
| Melioidosis | *Burkholderia pseudomallei* | Contact with contaminated soil or water; ingestion or inhalation; sexual intercourse; fleas can be the vector | | Abscesses, granulomatous lesions, purpura, pustules, urticaria, ecthyma gangrenosum |

**Table 61.6 Selected Gram-negative infections that present with nonspecific systemic symptoms (e.g. fever) and skin findings.** *Continued*

| SELECTED GRAM-NEGATIVE INFECTIONS THAT PRESENT WITH NONSPECIFIC SYSTEMIC SYMPTOMS (E.G. FEVER) AND SKIN FINDINGS | | | | |
|---|---|---|---|---|
| **Infection** | **Common organism(s)** | **Transmission/other factors** | **Unique/characteristic findings** | **Skin findings** |
| Rat-bite fever (Haverhill fever) | *Streptobacillus moniliformis* | Close contact with infected rodents or contaminated food, water, or raw milk (Haverhill fever) | Migratory polyarthritis in 50% of patients that mimics rheumatoid arthritis | Acral palmoplantar eruption of macules, papules, petechiae, vesicles, pustules, with secondary crusts |
| Brucellosis | *Brucella abortus* | Consumption of unpasteurized milk products | Malodorous perspiration | • Erythema nodosum<br>• Vasculitis |
| Typhoid fever | *Salmonella typhi* | Contact with infected persons | Rose spots | • Rose spots – 2–8 mm pink, blanching papules, often in clusters of 5–15 on the anterior trunk<br>• Erythema multiforme, Sweet syndrome, hemorrhagic bullae, pustules |
| Malacoplakia (malakoplakia) | *Escherichia coli* (less commonly *Pseudomonas* or other bacteria) | Immunocompromised hosts | Michaelis–Gutmann bodies: intracytoplasmic concretions within large histiocytes | Most commonly perianal abscesses or ulcers |
| Rhinoscleroma | *Klebsiella rhinoscleromatis* | Endemic to Central Europe, India, Egypt, other countries (e.g. Indonesia) | Intracellular bacteria within large histiocytes (Mikulicz cells) | Rhinitis that progresses to granulomatous nodules and scarring of nose and upper respiratory tract |

**Table 61.6** *Continued* **Selected Gram-negative infections that present with nonspecific systemic symptoms (e.g. fever) and skin findings.**



**Fig. 61.18 Cutaneous yaws on the knee of an adolescent from Indonesia.** *Courtesy, Peter Ehrnstrom, MD*.



**Fig. 61.19 Cervicofacial actinomycosis or "lumpy jaw" with soft tissue swelling and draining ulcerated nodules.** The discharge contained sulfur granules, a term used when the grains are yellow in color. *Courtesy, M. Joyce Rico, MD.*

| RISK FACTORS FOR *VIBRIO VULNIFICUS* INFECTION |
|---|
| **Acquisition of infection** |
| **Cutaneous exposure to contaminated seawater and/or shellfish** |
| • Exposure to warm coastal salt water (April–October in temperate climates)<br>• Handling shellfish<br>• New injury to the skin or a pre-existing wound predisposes to a primary cutaneous infection, which can lead to cellulitis, necrotizing fasciitis, and/or septicemia in susceptible hosts (see below) |
| **Consumption of contaminated raw/undercooked seafood** |
| • Classically raw oysters, but also found in clams, crabs, and other shellfish<br>• Leads to an acute gastrointestinal illness in immunocompetent individuals and septicemia in susceptible hosts (see below) |
| **Underlying medical conditions that predispose to severe infections** |
| **Liver disease** |
| • Hemochromatosis or iron overload in the setting of thalassemia<br>– *V. vulnificus* is ferrophilic and requires higher levels of iron than other pathogens<br>– Patients have decreased hepcidin antibacterial activity<br>• Alcoholic cirrhosis or chronic hepatitis |
| **Diabetes mellitus** |
| • Peripheral neuropathy predisposes to cutaneous wounds that serve as a portal of entry |
| **Gastrointestinal disease** |
| • Peptic ulcer disease<br>– Antacid use may lead to increased survival of *V. vulnificus*<br>• Gastrointestinal surgery |
| **Immunosuppression** |
| • HIV infection<br>• Leukemia or lymphoma<br>• Treatment with corticosteroids, chemotherapy, and other immunosuppressive agents |
| **Chronic kidney disease** |

**Table 61.7 Risk factors for *Vibrio vulnificus* infection.** Infections are most common in men >40 years of age.

| FOUR MAJOR CLINICAL FORMS OF CUTANEOUS NOCARDIOSIS | |
|---|---|
| **Primary** | |
| Actinomycotic mycetoma | • Half of all cases of actinomycotic mycetoma are due to *Nocardia* species*<br>• Traumatic inoculation causes a painless nodule that enlarges, suppurates, and drains via sinus tracts<br>• Purulent discharge contains grains<br>• The foot is the usual site of involvement<br>• May involve underlying muscle and bone |
| Lymphocutaneous | • Occurs days to weeks after trauma<br>• Appears as a persistent crusted pustule or abscess, often resistant to shorter courses of antibiotics<br>• Ascending lymphatic streaks, a sporotrichoid pattern of papulonodules, and tender palpable lymph nodes may be seen |
| Superficial cutaneous | • Traumatic implantation of foreign objects (including soil and gravel) into the skin<br>• The diagnosis is based on a high index of suspicion, lack of response to routine antibiotic treatment, and laboratory results |
| **Secondary** | |
| Pulmonary/ systemic | • Subcutaneous abscesses of the chest wall<br>• Pustules, nodules, cutaneous fistulae<br>• Almost universally fatal if left untreated<br>• Most commonly caused by *Nocardia asteroides* |

**In Mexico and Central and South America,* N. brasiliensis *is the etiologic agent of 90% of actinomycotic mycetomas, whereas in the United States, most mycetomas are caused by true fungi.*

**Table 61.8 Four major clinical forms of cutaneous nocardiosis. Rx:** sulfonamides are the drugs of choice for primary cutaneous nocardiosis, with minocycline being an alternative for sulfonamide-allergic patients. Duration of treatment is at least 6–12 weeks for localized disease in immunocompetent hosts. Surgical excision may be required for deep abscesses.

• **DDx:** distinguishing this entity from eumycotic mycetoma requires culture of grains or tissue; prior to the return of tissue or grain culture results, a presumptive diagnosis can be made based on the diameter of the filaments or hyphae composing the grains in biopsy specimens.

NOCARDIOSIS

See Table 61.8.

For further information see Ch. 74 from *Dermatology, Fourth Edition*.

**For additional online figures and tables visit www.expertconsult.com**

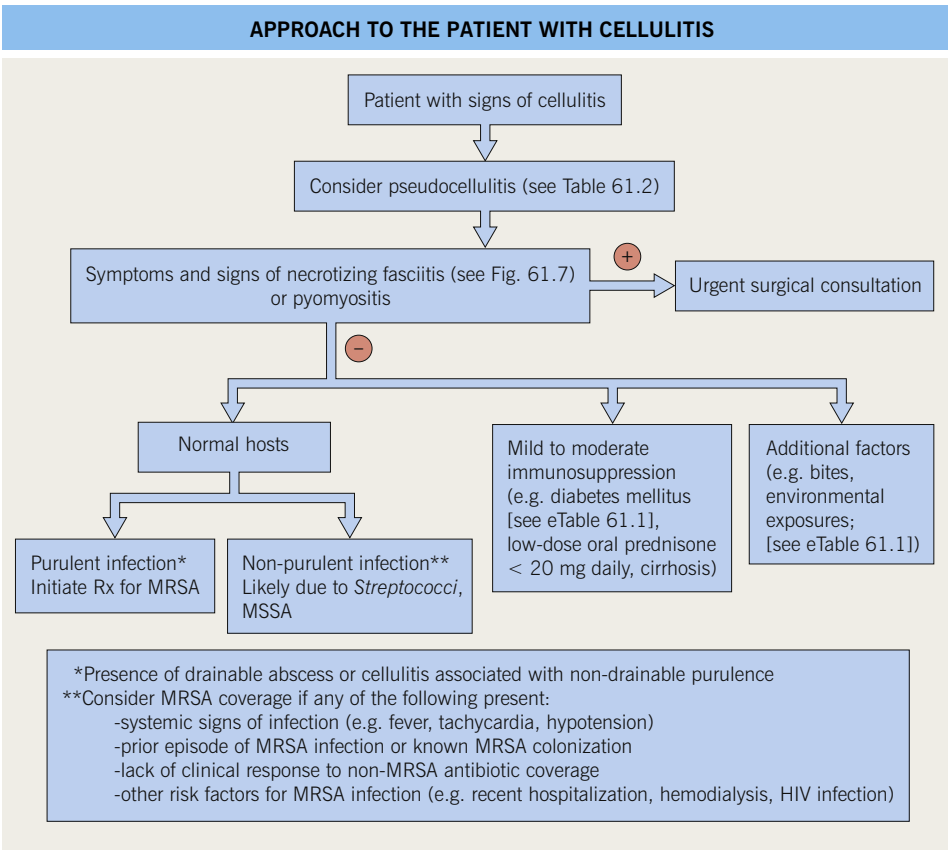


**eFig. 61.1 Approach to the patient with cellulitis.**

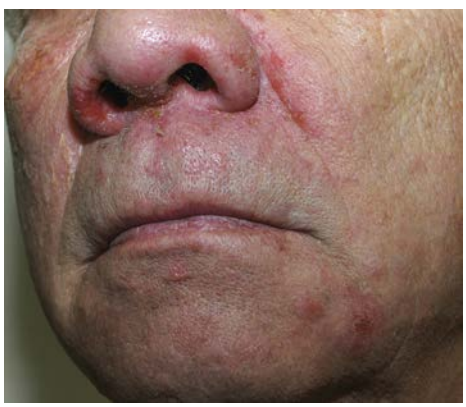

**eFig. 61.2 Staphylococcal impetigo.** Multiple small superficial erosions with crusting around the nares and on the chin in association with folliculitis in an adult. *Courtesy, Kalman Watsky, MD.*

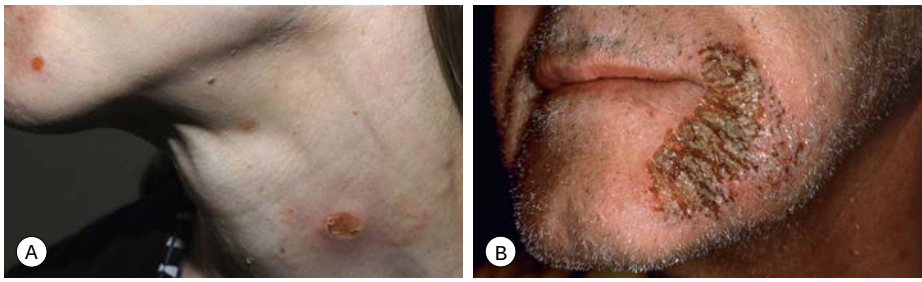


**eFig. 61.3 Staphylococcal impetigo. A** Small erosions with slight crusting on the neck and chin. **B** Thick scale-crust on the cheek. *A, Courtesy, Kalman Watsky, MD; B, Courtesy, YDRSC.*

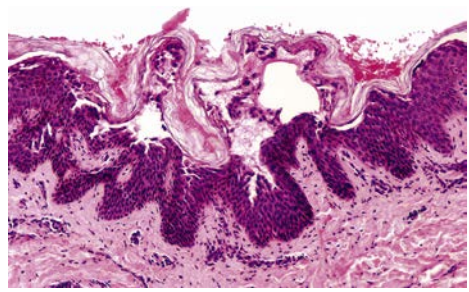

**eFig. 61.4 Histopathology of staphylococcal scalded skin syndrome.** Note the zone of cleavage at the stratum granulosum. *Courtesy, Luis Requena, MD.*



**eFig. 61.5 Desquamation of the hand following scarlet fever.** *Courtesy, Eugene Mirrer, MD.*




**eFig. 61.6 Furuncles secondary to methicillin-resistant *Staphylococcus aureus*.** Fluctuant erythematous nodules with a central pustule on the ankle (**A**) and finger (**B**). *A, Courtesy, Julie V. Schaffer, MD; B, Courtesy, Frank Samarin, MD.*



**eFig. 61.7 Ecthyma.** Ulceration with hemorrhagic crust on the wrist due to infection with group A streptococci. *Courtesy, Kalman Watsky, MD.*



**eFig. 61.8 Staphylococcal scalded skin syndrome.** Diffuse erythema with an early superficial erosion in the antecubital fossa. *Courtesy, Julie V. Schaffer, MD.*



**eFig. 61.9 Cutaneous streptococcal infections.** Sharply demarcated erythema on the upper arm and chest. *Courtesy, Lorenzo Cerroni, MD*

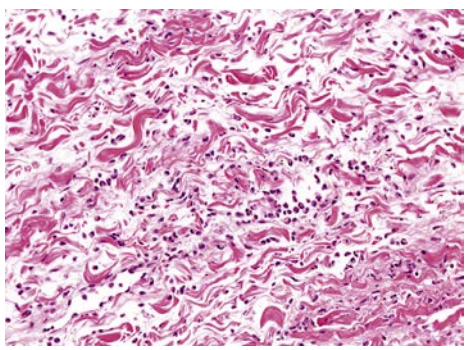

**eFig. 61.10 Histopathology of cellulitis.** Dermal edema and a neutrophilic infiltrate are evident. *Courtesy, Lorenzo Cerroni, MD.*



**eFig. 61.11 Erythema migrans as "pseudocellulitis."** Expanding erythematous plaque on the neck that could be mistaken for cellulitis. *Courtesy, YDRSC.*



**eFig. 61.12 Palmar lesions due to staphylococcal endocarditis.** *Courtesy, YDRSC.*



**eFig. 61.13 Pitted keratolysis of the plantar surface of the foot.** Multiple small craters with decreased stratum corneum that favor pressure points on the plantar surface. *Courtesy, Kalman Watsky, MD.*



**eFig. 61.14 Ecthyma diphthericum.** Punched-out ulcer with a black eschar on the upper lip. *Courtesy, Joyce Rico, MD.*



**eFig. 61.15 Green nail syndrome.** Blue-green discoloration of the nail due to pyocyanin produced by *Pseudomonas aeruginosa*. Note the associated onycholysis. *Courtesy, Julie V. Schaffer, MD.*



**eFig. 61.16 Bacillary angiomatosis.** Bright red nodule and papule on the forehead. *Courtesy, NYUDSC.*



**eFig. 61.17 Hemorrhagic bullae of the leg secondary to *Vibrio vulnificus* infection.** *Courtesy, USCDRSC.*



**eFig. 61.18 Acrodermatitis chronica atrophicans.** The acral skin is atrophic, shiny, and wrinkled, with prominent superficial veins. *Courtesy, YDRSC.*



**eFig. 61.19 Chronic meningococcemia.** Multiple erythematous crusted papules and nodules on the arm. *Courtesy, YDRSC.*



**eFig. 61.20 Erythema migrans.** Expanding erythematous plaque with central vesiculation. *Courtesy, Oscar Colegio, MD.*



**eFig. 61.21 Staphylococcal impetigo.** Superficial bullae and dry erosion on the nose due to bullous impetigo. *Courtesy, YDRSC.*



**eFig. 61.22 Erysipelas.** Sharply demarcated erythema of the face, most clearly demarcated on the forehead. *Courtesy, Kalman Watsky, MD.*



**eFig. 61.23 Bullous cellulitis.** Extensive soft tissue infection of the lower extremity due to group A streptococcal infection. *Courtesy, YDRSC.*



**eFig. 61.24 Necrotizing fasciitis.** Necrosis of the subcutaneous fat and fascia of the inner aspect of the upper arm in an elderly patient with diabetes mellitus. Note the watery discharge.
*Courtesy, Jean L. Bolognia, MD.*

**BACTERIAL CELLULITIS – ADDITIONAL FACTORS THAT INFLUENCE ASSOCIATED PATHOGENS**

| Additional factors | | | Associated pathogens |
|---|---|---|---|
| Underlying disorders | Diabetes mellitus | | *Staphylococcus aureus*<br>Group B streptococci<br>Anaerobes (e.g. *Clostridium*)<br>Gram-negative bacilli |
| | Cirrhosis | | *Campylobacter fetus*<br>Coliforms (e.g. Enterobacteriaceae)<br>*Vibrio vulnificus*<br>*Capnocytophaga canimorsus* |
| | Neutropenia | | *Pseudomonas aeruginosa* |
| | Intravenous drug abuse (see Table 75.2, Figs 75.9 and 75.10) | | MRSA<br>Group A streptococci |
| Bites (see Ch. 72) | Human | | *Eikenella corrodens*<br>Viridans group streptococci |
| | Dog* | | *Pasteurella multocida*<br>*Capnocytophaga canimorsus* |
| | Cat* | | *Pasteurella multocida* |
| | Rat (see Table 61.6) | | *Streptobacillus moniliformis* |
| Environmental exposures | Hot tub (see Table 31.2 and Fig. 31.3) | | *Pseudomonas aeruginosa*<br>Atypical mycobacteria |
| | Laceration | Freshwater | *Aeromonas hydrophilia* |
| | | Brackish water (see Table 61.6) | *Vibrio* species |
| | | Fish tank (see Fig. 62.17) | *Mycobacterium marinum* |
| | | Fish handling (Fig. 61.13) | *Erysipelothrix rhusiopathiae* |
| | | Motorcycle accident | *Nocardia* species |
| | Penetrating foot wound | | *Pseudomonas aeruginosa* |

**In addition to streptococci and staphylococci.*

**eTable 61.1 Bacterial cellulitis – additional factors that influence associated pathogens.**

# Mycobacterial Diseases

# 62

## Key Points

- Mycobacteria are the etiologic agents of three major types of infection:
  - Leprosy – *Mycobacterium leprae*
  - Tuberculosis – *Mycobacterium tuberculosis*
  - Atypical or nontuberculous infections – e.g. *Mycobacterium marinum, Mycobacterium chelonae* (Tables 62.1 and 62.2)

## Leprosy

- Slowly progressive disease characterized by granuloma formation in nerves and the skin.
- Affects all ages, but bimodal peak distribution – ages 10–15 years and 30–60 years.
- Currently, the highest reported prevalence is in the South Sudan (Fig. 62.1), with high incidence in Brazil, India, and Indonesia.
- Spread of leprosy is dependent on: (1) a contagious person (predominantly through nasal/oral droplets); (2) a susceptible person; and (3) close/intimate contact.
- Incubation period averages 4–10 years.
- Degree of immunity is reflected in clinical findings (Table 62.3; Figs 62.2–62.4) and histopathologic features; the latter range from macrophages containing numerous bacilli (globi) in lepromatous leprosy to granulomas without organisms in tuberculoid leprosy.
- Nerves are often affected, particularly ones close to the surface of the skin (Fig. 62.5); sensations of pain, temperature, and/or touch should be evaluated within skin lesions.
- Sequelae of leprosy can be disfiguring (Figs 62.6 and 62.7).

**MYCOBACTERIA THAT CAUSE CUTANEOUS DISEASE**

| Group and pigment | Rate of growth | Examples of pathogens |
|---|---|---|
| Slow growers | | |
| Photochromogens* | 2–3 weeks | *M. kansasii, M. marinum, M. simiae* |
| Scotochromogens† | 2–3 weeks | *M. scrofulaceum, M. szulgai, M. gordonae, M. xenopi* |
| Nonchromogens‡ | 2–3 weeks | *M. tuberculosis, M. avium, M. intracellulare, M. chimaera, M. ulcerans, M. haemophilum, M. bovis*§ |
| Rapid growers | 3–5 days | Examples include *M. fortuitum, M. chelonae, M. abscessus*** |
| Noncultured (to date) | | *M. leprae* |

**Capable of yellow pigment formation upon exposure to light.*
*†Capable of yellow pigment production without light exposure.*
*‡Incapable of pigment production.*
*§Including bacillus Calmette–Guérin.*
***Including M. abscessus subsp. massiliense and M. abscessus subsp. bolletii.*

**Table 62.1 Mycobacteria that cause cutaneous disease.** Modified classification of Runyon from: *Hautmann G, Lotti T. Atypical mycobacterial infections of the skin. Dermatol Clin 1994;12:657–68; Yates VM, Rook GAW. Mycobacterial infections. In: Burns T, Breathnach S, Cox N, Griffiths C (eds). Rook's Textbook of Dermatology, 7th edn. London: Blackwell Science, 2004;28.1–39; Neves RG, Pradinaud R. Micobacterioses atípicas. In: Neves RG, Talhari S (eds). Dermatologia Tropical. Rio de Janeiro: Medsi, 1995:283–90.*

| IMPORTANT FEATURES OF ATYPICAL MYCOBACTERIA | | |
|---|---|---|
| **Mycobacteria** | **Clinical features** | **Clinical setting** |
| *M. marinum* | • See text | Found in the environment |
| *M. fortuitum,*<br>*M. chelonae,*<br>*M. abscessus* | • Infected tattoos and post-pedicure lower extremity furuncles<br>• Infected surgical sites | Can occur in immuno-competent hosts |
| *M. ulcerans* | • Often infects children<br>• Can form large ulcers<br>• May require surgical Rx as responds poorly to antibiotic therapy | |
| *M. avium intracellulare*<br>*M. kansasii* | • Skin lesions rare | Found in the environment |
| *M. scrofulaceum* | • Classically causes lymphadenopathy | Often develops in immunocompromised hosts |

**Table 62.2 Important features of atypical mycobacteria.** Disseminated skin lesions are an HIV-defining criterion, most commonly due to *M. avium intracellulare* or *M. kansasii*.

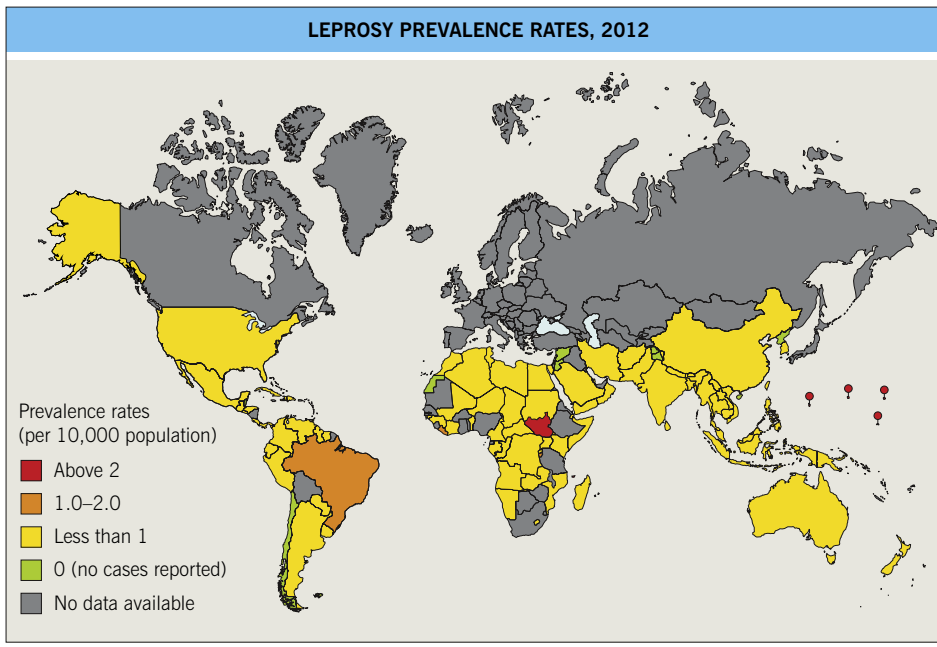


**Fig. 62.1 Leprosy prevalence rates, 2012.** The World Health Organization (WHO) has achieved its goal of a prevalence rate of less than 1 case per 10,000 persons in all but a few countries. *From World Health Organization,* https://www.who.int/lep/situation/Leprosy_PR_2011.pdf?ua=1.

| CLASSIFICATION OF LEPROSY: RIDLEY–JOPLING AND OPERATIONAL | | | | |
|---|---|---|---|---|
| **Operational** | **Multibacillary, >5 skin lesions** | | **Paucibacillary, 1–5 skin lesions** | |
| Ridley–Jopling* | Lepromatous leprosy (LL) | Borderline leprosy (BL) | Tuberculoid leprosy (TT) | Indeterminate (I) |
| Clinical findings |  |  |  | |
| Cellular immunity | Least (Th2 $CD4^+$ T-cell response) → | | ← Greatest (Th1 $CD4^+$ T-cell response) | |
| Type of lesions | Macules, papules, and plaques and sometimes diffuse infiltration of the skin | Macules, papules, and plaques with variable induration | Infiltrated thin plaques with raised edges, often hypopigmented | Macules, often hypopigmented |
| Distribution | Symmetric; favors face, buttocks, lower extremities | Tendency to symmetry | Localized, asymmetric | Variable |
| Definition | Vague, difficult to distinguish normal versus affected skin | Less well-defined borders | Well-defined, sharp borders | Not always defined |
| Sensation | Not affected | Diminished | Absent | Impaired |
| Bacilli in skin lesions | ← | | | Usually none detected |

**Disease states intermediate between LL and TT include borderline LL, mid-borderline leprosy, borderline TT, and indeterminate.*

**Table 62.3 Classification of leprosy: Ridley–Jopling and operational.** Adapted from A Guide to Leprosy Control, 2nd ed. Geneva: World Health Organization, 1988;27–8.



**Fig. 62.2 Tuberculoid leprosy.** Large annular lesion on the cheek with a red-brown color and rim of hypopigmentation. *Courtesy, Marcia Ramos-e-Silva, MD.*

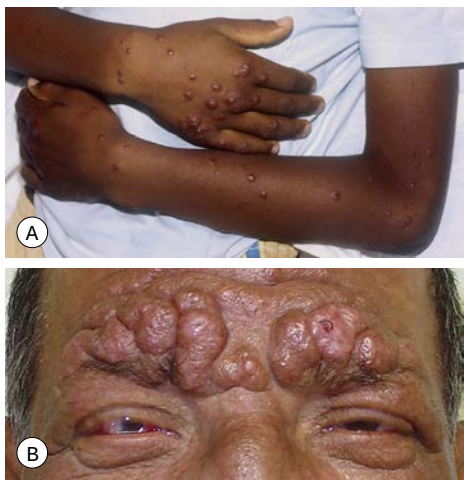


**Fig. 62.3 Lepromatous leprosy. A** Numerous erythematous papules and nodules on the forearms and hands. **B** Infiltrated nodules coalescing on the forehead with leonine facies and madarosis. Note the ocular involvement. *Courtesy, Marcia Ramos-e-Silva, MD.*

- Reactive states that can involve the skin may develop, especially following institution of antimicrobial treatment.
  - Type 1 (reversal reaction) – acute inflammation of cutaneous lesions (Fig. 62.8A) and nerves; appears rapidly due to a change in the immunologic state of the patient; in the case of upgrading, subclinical lesions can become clinically apparent



**Fig. 62.4 Borderline leprosy.** Erythematous, arcuate lesions with ill-defined outer borders and well-demarcated inner borders. *Courtesy, Marcia Ramos-e-Silva, MD.*

  - Type 2 (vasculitis) – formation of immune complexes in the setting of an excessive humoral immune reaction, leading to the appearance of cutaneous lesions, particularly erythema nodosum leprosum (Fig. 62.8B)
- **DDx:** outlined in Table 62.4.
- **Rx** for adults: multibacillary leprosy – rifampin 600 mg PO once a month, dapsone 100 mg PO daily, and clofazimine 300 mg PO once a month plus 50 mg PO daily for 12 months; paucibacillary leprosy – rifampin 600 mg PO once a month and dapsone 100 mg PO daily for 6 months; single lesion – one-time dose of rifampin 600 mg, ofloxacin 400 mg, and minocycline 100 mg; prednisone for type 1 (reversal) reactions; thalidomide for type 2 reactions. Second-line antimicrobials include moxifloxacin, clarithromycin, and rifapentine.

## Cutaneous Tuberculosis (TB)

- Cutaneous lesions reflect mode of exposure and the degree of immunity.
- Exogenous exposure (inoculation).
  - Tuberculous chancre – seen in previously uninfected persons; 2–4 weeks after inoculation, a painless, firm, red-brown

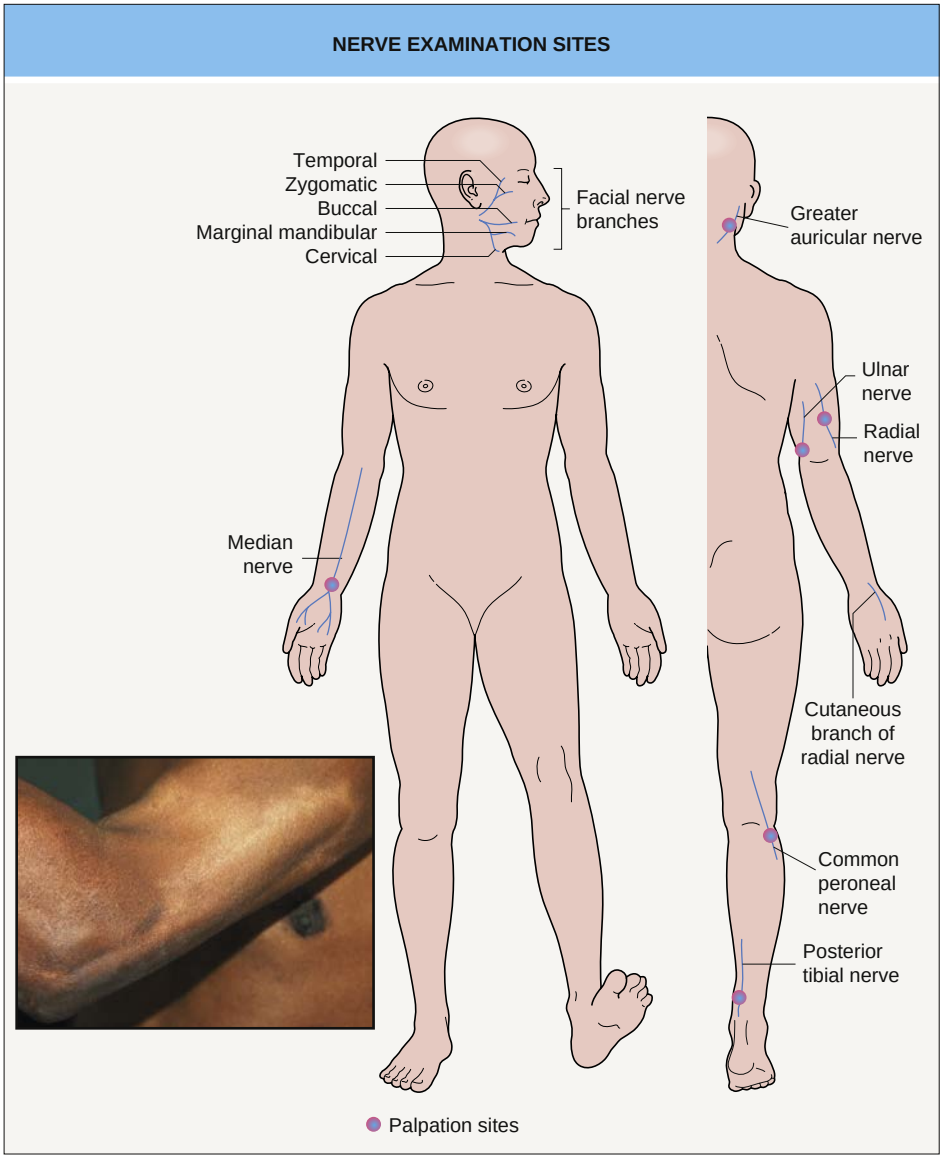


**Fig. 62.5 Nerve examination sites.**

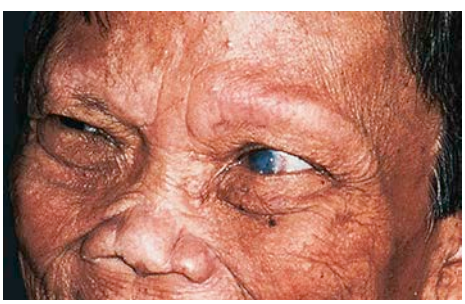

**Fig. 62.6 Sequelae of leprosy.** The patient has madarosis, a saddle nose, and blindness in the left eye. *Courtesy, Evangeline Handog, MD.*

papulonodule appears that ulcerates centrally; generally heals within 3–12 months
  - TB verrucosa cutis – secondary to inoculation in persons with moderate to high immunity to *M. tuberculosis*; asymptomatic, wart-like papule that gradually enlarges (Fig. 62.9); may heal spontaneously after several years
- Endogenous spread of infection.
  - Some degree of cellular immunity (TST/PPD [tuberculin skin test] usually positive)

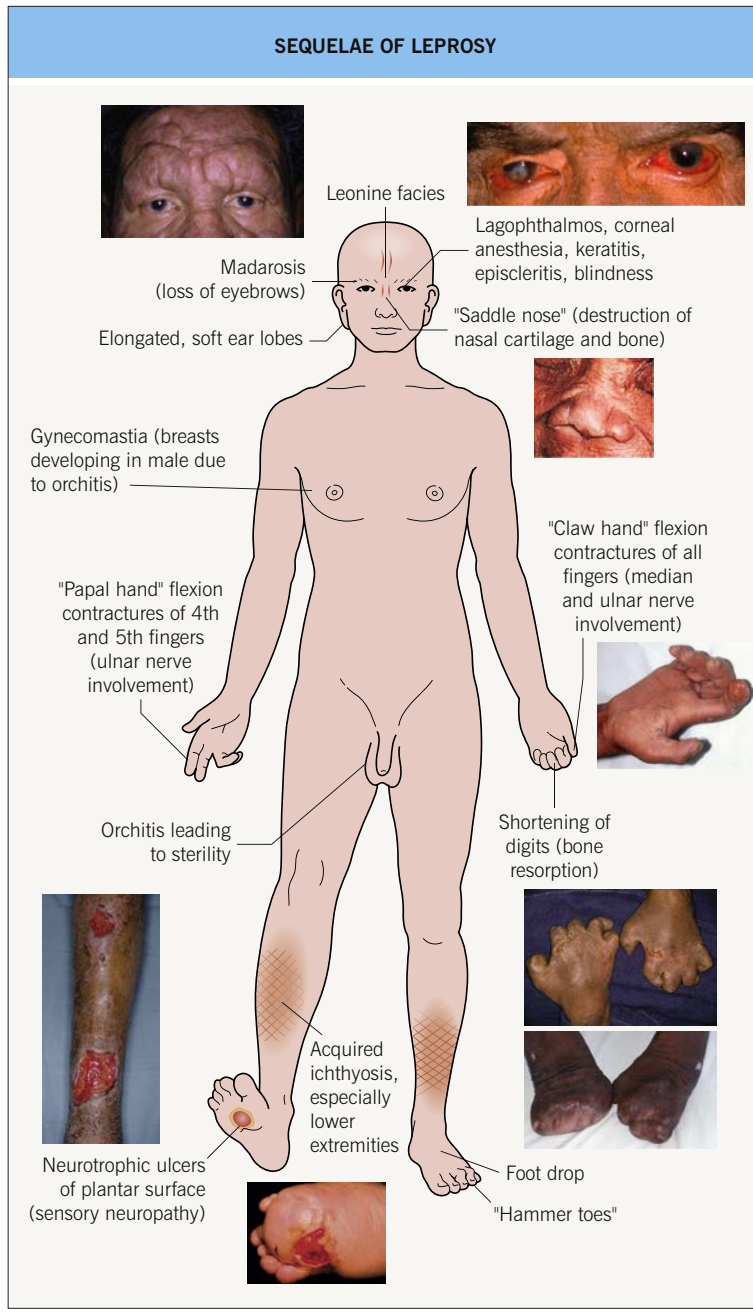


**Fig. 62.7 Sequelae of leprosy.** *Insets, Courtesy, Louis A. Fragola, Jr., MD, and Joyce Rico, MD.*

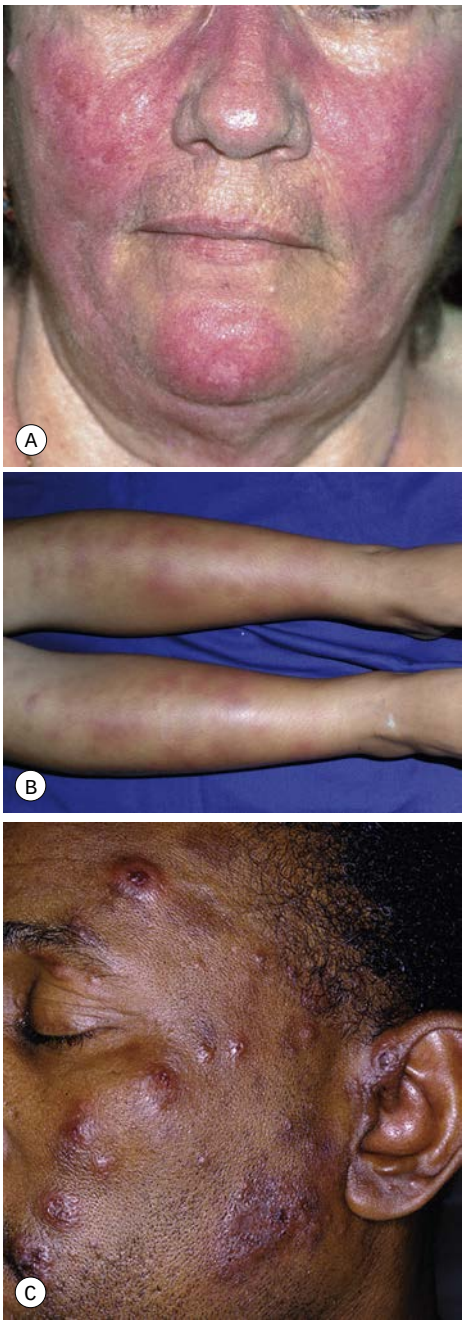


**Fig. 62.8 Leprosy reactions. A** Type 1 "upgrading" reaction with lupus erythematosus-like facial involvement in a "butterfly" distribution with marked inflammation. **B** Erythema nodosum leprosum, a type 2 reaction, presenting with erythematous nodules on the legs. **C** Type 2 reaction presenting with red facial papulonodules due to immune complex-mediated small vessel vasculitis in a patient with lepromatous leprosy. *A,B, Courtesy, Marcia Ramos-e-Silva, MD; C, Courtesy, Louis A. Fragola, Jr., MD.*

- Scrofuloderma – firm, subcutaneous nodules that become fluctuant; may ulcerate or drain via sinus tracts that heal as tethered scars; represents spread of infection from underlying disease (e.g. in bones and lymph nodes, often cervical; Fig. 62.10).
- Lupus vulgaris – typically a red-brown plaque that can expand with central scar formation (Fig. 62.11); as with other granulomatous skin diseases such as sarcoidosis, pressure (diascopy) results in a yellow-brown color; represents direct extension or hematogenous/lymphatic spread of infection.
  - Impaired cellular immunity (TST/PPD usually negative)
- Orificial TB – autoinoculation of skin or mucosa adjacent to an orifice draining an active tuberculous infection (Fig. 62.12); occurs in patients with advanced internal TB.
- Miliary TB – small erythematous papules that develop central crusting and may resemble a viral exanthem or pityriasis lichenoides et varioliformis acuta (PLEVA); secondary to hematogenous spread from a primary lung focus.
- Tuberculous gumma – firm subcutaneous nodule or fluctuant swelling that often ulcerates; seen in the setting of hematogenous dissemination.
- Tuberculids (cutaneous immune reactions to *M. tuberculosis*).
  - Papulonecrotic tuberculid – widely distributed, dusky red papules or papulopustules, sometimes with central crusts; favors the extremities and may resemble PLEVA (Fig. 62.13)
  - Lichen scrofulosorum – small pink to yellow-brown perifollicular papules with scale, often in clusters on the trunk
  - Erythema induratum, a form of panniculitis – subcutaneous nodules that may ulcerate; favors the posterior calves (see Ch. 83)
- Confirmation of diagnosis: tuberculin skin test (TST/PPD) or IFN-γ release assays (e.g. QuantiFERON-TB Gold [In-Tube]) or testing of tissue with polymerase chain reaction for *M. tuberculosis* DNA; advantages and disadvantages of the first two tests are outlined in Table 62.5.
- **Rx:** pending sensitivities, an example of an initial multidrug regimen includes rifampin, isoniazid, pyrazinamide, and ethambutol.

| DIFFERENTIAL DIAGNOSIS OF LEPROSY | | |
|---|---|---|
| Hypopigmented lesions |  | • Mycosis fungoides, including the hypopigmented variant<br>• Sarcoidosis, but hypopigmented variant is usually more papulonodular<br>• Postinflammatory hypopigmentation |
| Circinate (annular) plaques |  | • Mycosis fungoides and other forms of cutaneous lymphoma<br>• Sarcoidosis<br>• Psoriasis<br>• Interstitial granulomatous dermatitis<br>• Granuloma annulare<br>• Tinea corporis |
| Infiltrated plaques/nodules |  | • Lymphoma<br>• Sarcoidosis<br>• Other infections (dimorphic fungal, tuberculous)<br>• For DDx of leonine facies, see Table 38.1 |
| Neurologic findings | | • Peripheral neuropathy due to other disorders (e.g. diabetes mellitus, vasculitis) |
| Deforming acral features |  | • Systemic sclerosis<br>• Tabes dorsalis<br>• Dupuytren contracture |
| Type 1 reaction |  | • Acute lupus erythematosus<br>• Cellulitis<br>• Drug reactions<br>• Misdiagnosed as worsening of disease as subclinical lesions may become apparent |
| Type 2 reaction |  | • Sweet syndrome<br>• Medium-vessel vasculitis<br>• Panniculitides, e.g. erythema nodosum*<br>• Infections, including other mycobacterial, bacterial, dimorphic fungal, and other opportunistic fungal |

**Lesions favor the shins and are longer-lived than erythema nodosum leprosum lesions, which are widespread, appear in crops and then resolve relatively rapidly.*

**Table 62.4 Differential diagnosis of leprosy.**

## Atypical Mycobacteria

- Found in the natural environment (water, wet soil, vegetation, cold-blooded animals [e.g. fish], dairy products, human feces).
- Skin infections most commonly arise via traumatic inoculation; other routes include surgical or cosmetic procedures (e.g. liposuction, tattooing) and exposure to contaminated water (e.g. soaking distal lower extremities prior to pedicure; see Table 62.2).
- Clinically, pustules, plaques, or nodules develop that may become keratotic or centrally ulcerated.
- A sporotrichoid or lymphocutaneous pattern (linear arrangement of lesions along draining lymphatics) may be seen (Figs 62.14–62.16).



**Fig. 62.9 Tuberculosis verrucosa cutis.** A wart-like papule at the site of exogenous inoculation in a patient with immunity against *M. tuberculosis*. *Courtesy, YDRSC.*



**Fig. 62.10 Scrofuloderma.** Plaques and nodules with central ulceration as well as resultant scarring with retraction. *Courtesy, YDRSC.*



**Fig. 62.12 Orificial tuberculosis.** A non-healing ulcer of the nasal mucosa. *Courtesy, Louis A. Fragola, Jr., MD.*

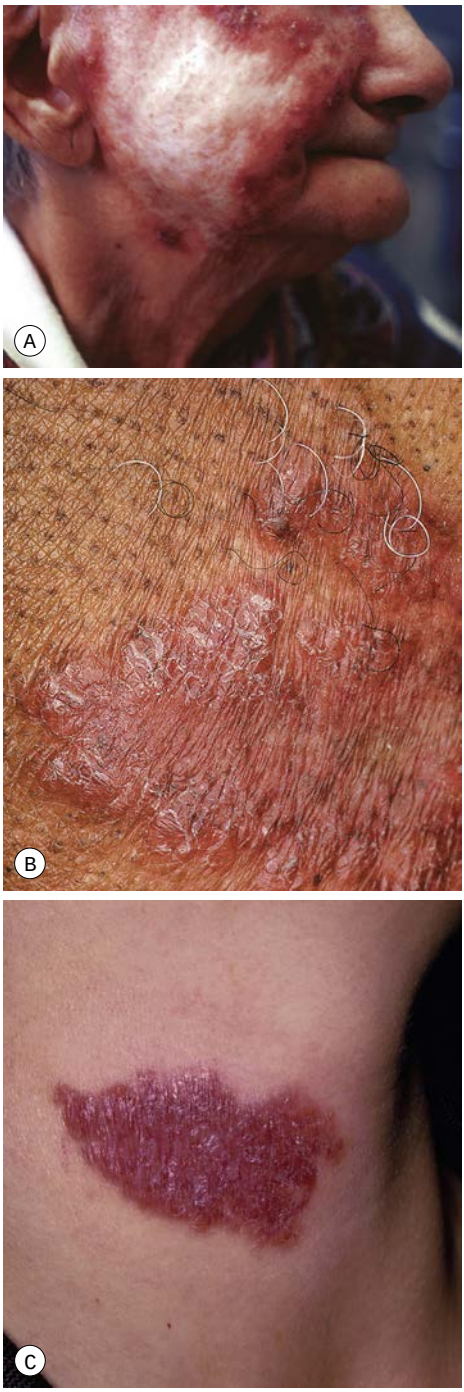


**Fig. 62.11 Lupus vulgaris. A** Annular granulomatous plaque with central scarring. **B** Two dull red-brown plaques with papular borders, scale and central clearing. **C** Violet-brown plaque on the neck. *A, Courtesy, Marcia Ramos-e-Silva, MD; B, Courtesy, YDRSC; C, Courtesy, Eugene Mirrer, MD.*



**Fig. 62.13 Papulonecrotic tuberculid.** Erythematous papules and papulopustules on the heel. *Courtesy, YDRSC.*



**Fig. 62.14 Suppurative lymphadenitis due to *Mycobacterium fortuitum* infection.** The inoculation chancre was on the foot. *From Azulay RD, Neves RG, Estrella RR, et al. Complexo primario cutaneoganglionar por Mycobacterium fortuitum. AMB Rev Assoc Med Bras. 1974;20:177–81. Courtesy, Rubem Azulay, MD.*

**ADVANTAGES AND DISADVANTAGES OF IFN-γ RELEASE ASSAYS AND TUBERCULIN SKIN TESTING**

| | Tuberculin skin test | IFN-γ release assays |
|---|---|---|
| Advantages | Does not require a laboratory<br>Relatively low cost | Requires a single patient visit<br>Results can be available within 24 hours<br>Prior BCG vaccination does not cause a false-positive result<br>Does not boost responses measured by subsequent tests |
| Disadvantages | Requires two patient visits<br>Results not available for 48 hours<br>Prior BCG vaccination can cause a false-positive result<br>May boost responses in subsequent tests<br>Infections with non-tuberculous mycobacteria may lead to a false-positive result | Requires laboratory processing within 16 hours (for QuantiFERON®-TB Gold [In-Tube]) or 8 hours (for T-SPOT®.TB; time limit of 30 hours if use T-cell Xtend®)<br>Relatively high cost<br>Infections with some non-tuberculous mycobacteria (e.g. *M. kansasii*, *M. szulgai*, and *M. marinum*) may lead to a false-positive result |
| Situations where preferable | Children <5 years of age | Patient groups that historically have low rates of returning for a second visit (e.g. homeless persons, drug users)<br>Individuals who have received BCG |

**Table 62.5 Advantages and disadvantages of interferon-γ (IFN-γ) release assays and tuberculin skin testing.** Both types of tests may be negative in patients with early active tuberculosis. Indeterminate IFN-γ release assay results due to failure of the internal positive control (i.e. a "low mitogen" response) are more common in immunocompromised individuals and young children. Indeterminate results due to inappropriately high IFN-γ levels in the negative control ("high nil") can also occur. Testing with a second method after an initial negative test may be useful when the risk of infection/progression is high or when there is clinical suspicion of active tuberculosis. The QuantiFERON®-TB Gold (In-Tube) test directly measures IFN-γ levels, whereas the T-SPOT®.TB test determines the number of IFN-γ-producing T cells; both use a peripheral blood sample. BCG, bacille Calmette–Guérin.



**Fig. 62.15 Complication of injection of methanol extraction residue (MER) of bacille Calmette–Guérin (BCG), an attenuated strain of *Mycobacterium bovis.*** Nodules, some of which have ulcerated, are arranged in a linear "lymphatic" pattern in a patient with a high-risk extremity melanoma who had received an injection of MER of BCG as adjuvant immunotherapy. *Courtesy, YDRSC.*



**Fig. 62.16 *Mycobacterium avium* complex cellulitis in a patient on chronic CS for rheumatoid arthritis.** Note the sporotrichoid (lymphocutaneous) pattern of the coalescing nodules with abscess formation. *Courtesy, YDRSC.*

- Disseminated infection can occur in immunocompromised hosts.
- *Mycobacterium marinum* infection is seen most frequently in the United States.
  - Found in aquatic environments, including fish tanks and swimming pools
  - Bluish-red inflammatory nodule or pustule that may ulcerate; over time, can develop additional lesions in a sporotrichoid pattern (Fig. 62.17)
- **DDx:** other infections with sporotrichoid spread (e.g. sporotrichosis, nocardiosis) (see Table 64.7).
- **Rx:** pending sensitivities, empiric treatment of infection with *M. marinum* is clarithromycin, and additional antibiotics include minocycline and rifampin; localized infection with *M. ulcerans* or *M. scrofulaceum* can be excised; more disseminated disease usually requires a multidrug regimen for at least 3–6 months.

For further information see Ch. 75 from *Dermatology, Fourth Edition*.

**For additional online figures and tables visit www.expertconsult.com**




**Fig. 62.17 *Mycobacterium marinum* infections.** A range of presentations, including an erythematous plaque with scale-crust at the inoculation site on the lateral hand (**A**), a sporotrichoid pattern with the inoculation site on the distal third finger (**B**), and disseminated necrotic lesions on the face of an immunocompromised patient (**C**). *Courtesy, YDRSC.*



**eFig. 62.1 Site of a BCG vaccination.** Enlarging granulomatous plaque (BCGitis). *Courtesy, YDRSC.*



**eFig. 62.2 *Mycobacterium chelonae* infection.** This immunosuppressed patient presented with an area of warmth and mild erythema on the ankle. *Courtesy, YDRSC.*

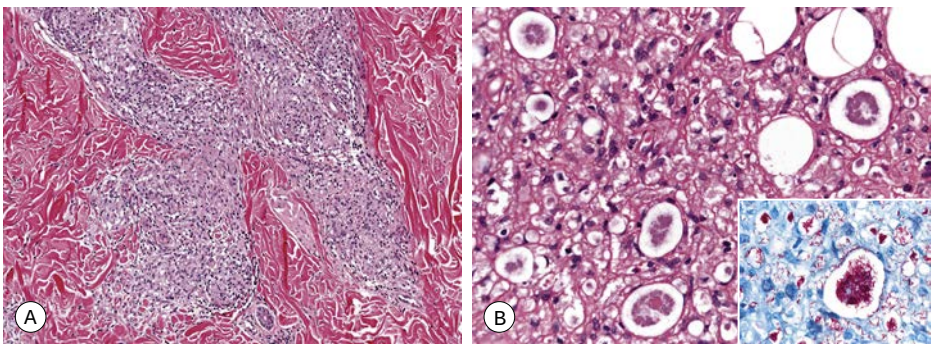


**eFig. 62.3 Tuberculoid and lepromatous leprosy.** Granulomatous nodular infiltrate within the dermis with nerve involvement; organisms are generally not detected (**A**). Diffuse dermal infiltrate of foamy histiocytes; note the globi which represent clumping of mycobacteria (**B**). Fite stain highlighting the numerous bacilli as well as globi (inset). *Courtesy, Lorenzo Cerroni, MD.*

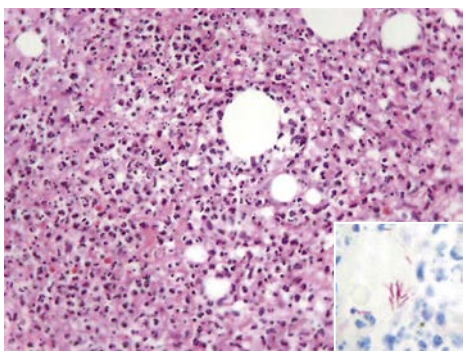

**eFig. 62.4 Mixed diffuse inflammatory infiltrate with granuloma formation.** Curved acid-fast bacilli are seen with Fite staining (inset).

| MULTIDRUG THERAPY/WHO SCHEME FOR THE TREATMENT OF LEPROSY | | | | | | |
|---|---|---|---|---|---|---|
| | **Rifampin** | **Clofazimine** | **Dapsone** | **Ofloxacin** | **Minocycline** | **Therapy duration** |
| MB (>5 lesions*) | 600 mg once monthly | 300 mg once monthly and 50 mg daily | 100 mg daily | – | – | 12 blister packs over 12 to 18 months |
| PB (2–5 lesions*) | 600 mg once monthly | – | 100 mg daily | – | – | 6 blister packs over 6 to 9 months |
| PB (single lesion*) | 600 mg × 1 | – | – | 400 mg × 1 | 100 mg × 1 | Single dose |
| **Dose adjustments for children** | | | | | | |
| 10 to 14 years of age, MB† | 450 mg once monthly | 150 mg once monthly and 50 mg every other day | 50 mg daily | – | – | 12 blister packs over 12 to 18 months |
| <10 years of age, MB† | 300 mg once monthly | 100 mg once monthly and 50 mg twice weekly | 25 mg daily | – | – | 12 blister packs over 12 to 18 months |
| 5 to 14 years of age, single lesion PB | 300 mg × 1 | – | – | 200 mg × 1 | 50 mg × 1 | Single dose |

**WHO classification for endemic areas when no facilities for performing bacilloscopy are available.*
*†For PB disease (2–5 lesions), clofazimine is not required and the duration of therapy is 6 to 9 months.*

**eTable 62.1 Multidrug therapy/WHO scheme for the treatment of leprosy.** These recommendations are those currently standardized by the WHO (www.who.int/lep/mdt/regimens/en/). MB, multibacillary; PB, paucibacillary.



ALGrawany

| TREATMENT OF NON-TUBERCULOUS ("ATYPICAL") MYCOBACTERIAL INFECTIONS | | |
|---|---|---|
| **Agent** | **Local** | **Systemic medications: alone or combined** |
| *M. ulcerans* | For ulcers, surgical excision; local heat (40°C); hyperbaric oxygen | Rifampin plus streptomycin, clarithromycin, and/or a quinolone (e.g. moxifloxacin, ciprofloxacin) for at least 4–8 weeks* |
| *M. marinum* | | Clarithromycin, minocycline > doxycycline†, rifampin, ethambutol, trimethoprim–sulfamethoxazole; two agents for serious infections (e.g. clarithromycin + rifampin or ethambutol) |
| *M. kansasii* | | Isoniazid (or clarithromycin) + rifampin + ethambutol ± pyridoxine; other options (depending on susceptibilities) include azithromycin, moxifloxacin, streptomycin and sulfamethoxazole |
| *M. fortuitum* | Surgical excision | Ciprofloxacin, ofloxacin, clarithromycin‡, trimethoprim–sulfamethoxazole, minocycline, doxycycline; at least two agents for serious infections |
| *M. chelonae* | Surgical excision | Clarithromycin; for severe infections, combine clarithromycin with linezolid, imipenem, tobramycin, amikacin, doxycycline and/or ciprofloxacin (often resistant to latter two agents) |
| *M. abscessus* | Surgical excision | Clarithromycin or azithromycin + (for serious infections) amikacin, cefoxitin or imipenem |
| *M. avium* complex | | Clarithromycin or azithromycin + ethambutol ± rifampin or rifabutin |
| *M. haemophilum* | Surgical excision | Clarithromycin + rifampin ± ciprofloxacin or amikacin |
| *M. scrofulaceum* | Surgical excision | Isoniazid + rifampin, clarithromycin |

**WHO recommends 8 weeks of rifampin plus streptomycin.*
*†Resistance to tetracyclines has been reported.*
*‡Often have inducible resistance to macrolides.*

**eTable 62.2 Treatment of non-tuberculous ("atypical") mycobacterial infections.** Therapy for 3 to 6 months or more is often required. If clinical suspicion is high for a non-tuberculous mycobacterial infection, empiric treatment with clarithromycin can be considered while waiting for culture and sensitivity results.

# Rickettsial Diseases 63

Rickettsial infections often have cutaneous manifestations that can vary from nonspecific maculopapular eruptions to an eschar at the site of inoculation (by the vector) to petechiae and retiform purpura (Table 63.1). These Gram-negative bacteria reside within an arthropod – tick, flea, mite, or louse – during a portion of their life cycle and are transmitted to humans while feeding, either via saliva or via feces (Table 63.2). As a result, rickettsial diseases exhibit both seasonality and geographic diversity.

*Rickettsia* and *Orientia* spp. target endothelial cells of multiple organs, including the skin, whereas *Ehrlichia*, *Anaplasma*, and *Coxiella* spp. target monocytes or neutrophils, neutrophils, and macrophages, respectively.

## Rocky Mountain Spotted Fever (RMSF)

- Due to transmission of *Rickettsia rickettsia* by the bite of a tick, most commonly *Dermacentor* spp. (Fig. 63.1); the incubation period is 2–14 days (mean, 7 days) following the bite.
- Highest incidence in the south Atlantic and south central states (Fig. 63.2), not the Rocky Mountain states, with peak incidence from late spring to the end of summer (tick season).
- Begins as a subtle cutaneous eruption with pink to erythematous macules then papules, initially in acral sites (e.g. wrists, ankles); over time central petechiae develop and lesions become more widespread (Figs 63.3–63.6).
- In the majority of patients, the skin findings are preceded by a fever (for 3–5 days), myalgias, and severe headache; some patients also develop nausea and vomiting and a change in mental status; if not treated appropriately, acute renal failure, hypotension, and coma can ensue, with a mortality rate of up to 25%.
- Dx: biopsy of petechial papule or eschar followed by PCR and/or immunohistochemistry (Table 63.3); serologic results are not helpful in the acute setting.
- **DDx:** viral exanthem (e.g. enterovirus, EBV, measles, parvovirus B19, dengue virus; see Fig. 68.1), other rickettsial spotted fevers (similar eruption but more likely to have an inoculation eschar; see Table 63.1), typhus (several forms), ehrlichiosis, morbilliform drug reaction; when severe and purpuric, meningococcemia, other thrombotic vasculopathies, vasculitis, hemorrhagic fevers.
- **Rx:** begun empirically; doxycycline or tetracycline represents first-line therapy, even in children (Table 63.4).

## Typhus – Epidemic and Endemic (Murine)

- While the vector differs for epidemic (human body louse) versus endemic (flea) typhus, spread of the infection involves deposition of feces onto the skin followed by scratching into the skin, rubbing into mucous membranes, or inhalation.
- The eruption often begins in the axillae and then becomes more widespread, with relative sparing of the face; individual lesions are similar to those seen in RMSF.
- **DDx** and **Rx:** see section on RMSF.

## Rickettsialpox

- Most often occurs in urban areas.
- Within 48 hours, a papulovesicle (then eschar) develops at the site of the bite of the mouse mite (Fig. 63.7A); fever, myalgias, and headache appear 1–2 weeks later followed soon thereafter by a cutaneous eruption.
- The eruption has a widespread distribution that includes the face, but the number of lesions is usually limited, i.e. ~20–40;

| DERMATOLOGIC MANIFESTATIONS OF RICKETTSIAL INFECTIONS | | | | |
|---|---|---|---|---|
| **Disease** | **Rash incidence (%)** | **Appearance of rash after onset of illness** | **Characteristics** | **Eschar (%)** |
| Rocky Mountain spotted fever, Brazilian spotted fever | 90 | 3–5 days | Early macules, later papules; petechiae in 50% of cases; retiform purpura in severe disease | <1 |
| Rickettsialpox | 100 | 2–3 days | Early macules and papules; later papulo-vesicles and crusts | 90 |
| *Rickettsia parkeri* rickettsiosis | 80 | 2–4 days | Macules, papules, often vesicles | 100 |
| Boutonneuse fever and related conditions | 95 | 3–5 days | Early macules, later papules | 50 |
| North Asian tick typhus and related conditions | 100 | 4–5 days | Macules and papules | 75 |
| Queensland tick typhus | 90 | 2–6 days | Macules, papules, and vesicles | 75 |
| Flinders Island spotted fever | 85 | A few days | Early macules and papules, later (in some patients) petechiae | 50 |
| Japanese spotted fever | 100 | A few days | Early macules, later (in some patients) petechiae | 90 |
| Flea-borne spotted fever | 80 | A few days | Macules and papules; occasionally pustules | 15–20 |
| African tick bite fever | 50 | 2–5 days | Generally relatively few lesions; macules, often vesicles | 90, often multiple |
| *R. aeschlimannii* infection | 50 | Not known | Macules, papules | 100 |
| Tick-borne lymphadenopathy | 5 | Not reported | Macules, papules | 100 |
| Epidemic louse-borne typhus | 50–100 | 4–5 days | Early macules, later papules; petechiae | None |
| Brill–Zinsser disease | 50 | 4–6 days | Macules, papules | None |
| Flying squirrel typhus | 65 | 2–8 days | Macules, papules | None |
| Murine (endemic) typhus | 80 | 5 days | Early macules, later papules | None |
| Scrub typhus | 50 | 4–6 days | Early macules, later papules | 60–90 |
| Human monocytic ehrlichiosis | 40 | Median, 5 days | Macules, papules, occasionally petechiae | None |
| *Ehrlichia muris*-like agent ehrlichiosis | 10 | Not reported | Not reported | None |
| Anaplasmosis (human granulocytic anaplasmosis) | ≤5 | Not reported | Erythematous eruption on neck/chest; petechiae or purpura | None |
| Q fever | Rare | Associated with chronic infection | Macules, papules, palpable purpura; rarely erythema nodosum | None |

**Table 63.1 Dermatologic manifestations of rickettsial infections.** Skin findings have not been described in patients with *Ehrlichia ewingii* ehrlichiosis. *Courtesy, David H. Walker, MD.*

| EPIDEMIOLOGY OF RICKETTSIAL INFECTIONS | | | |
|---|---|---|---|
| **Agent** | **Disease** | **Transmission** | **Geographic distribution** |
| *Rickettsia rickettsii* | Rocky Mountain spotted fever, Brazilian spotted fever | **Bite of tick:** | |
| | | *Dermacentor variabilis* (Fig. 63.1) | Eastern two-thirds and Pacific Coast of US |
| | | *D. andersoni* | Rocky Mountain states |
| | | *Rhipicephalus sanguineus* | Southwestern US; northern Mexico; Brazil |
| | | *Amblyomma cajennense, A. aureolatum, A. imitator, A. sculptum* | Mexico; Central and South America |
| *Rickettsia akari* | Rickettsialpox | **Bite of mouse mite:** | |
| | | *Liponyssoides sanguineus* | North America; Eurasia |
| *Rickettsia parkeri* | *Rickettsia parkeri* rickettsiosis (maculatum disease, American tick bite fever) | **Bite of tick**: | |
| | | *Amblyomma maculatum, A. americanum* | North America |
| | | *A. triste* | South America |
| *Rickettsia conorii* (4 subspecies) | Boutonneuse fever (Mediterranean spotted fever), Indian and Israeli tick typhus, Astrakhan spotted fever | **Bite of tick:** | |
| | | *Rhipicephalus sanguineus* | Southern Europe; Africa; western and southern Asia |
| | | *Rh. pumilio* | Southern Russia |
| *Rickettsia sibirica* | North Asian and Siberian tick typhus, lymphangitis-associated rickettsiosis | **Bite of tick:** | |
| | | *Dermacentor nuttallii*, *D. silvarum*, *Haemaphysalis concinna*, *Hyalomma asiaticum*, other species | Eurasia and Africa |
| *Rickettsia australis* | Queensland tick typhus | **Bite of tick**: | |
| | | *Ixodes holocyclus* | Eastern Australia |
| *Rickettsia honei* | Flinders Island spotted fever | **Bite of tick**: | |
| | | *Bothriocroton hydrosauri*, other species | Australia and Nepal (Flinders Island is located between Tasmania and mainland Australia) |
| *Rickettsia japonica* | Japanese spotted fever | **Bite of tick**: | |
| | | Vector status not established for ticks that carry the agent (*Haemaphysalis flava, H. longicornis, Ixodes ovatus, Dermacentor taiwanensis*) | Japan; eastern Asia |

**Table 63.2 Epidemiology of rickettsial infections.** *Continued*

| EPIDEMIOLOGY OF RICKETTSIAL INFECTIONS | | | |
|---|---|---|---|
| **Agent** | **Disease** | **Transmission** | **Geographic distribution** |
| *Rickettsia felis* | Flea-borne spotted fever | **By flea**: | |
| | | e.g. *Ctenocephalides felis* | Worldwide |
| *Rickettsia africae* | African tick bite fever | **Bite of tick**: | |
| | | *Amblyomma hebraeum* | Southern Africa |
| | | *A. variegatum* | Central, eastern, and western Africa; Caribbean islands |
| *Rickettsia aeschlimannii* | *Rickettsia aeschlimannii* disease | **Bite of tick**: | |
| | | *Hyalomma marginatum* | Africa |
| *Rickettsia slovaca, R. raoultii,* or *Candidatus Rickettsia rioja* | Tick-borne lymphadenopathy, *Dermacentor*-borne necrosis and lymphadenopathy (DEBONEL) | **Bite of tick** (usually on the scalp): | |
| | | *Dermacentor marginatus*, *D. reticularis* | Europe |
| *Rickettsia prowazekii* | Epidemic louse-borne typhus | **Feces of human body louse** (*Pediculus humanus* var. *corporis*) | South America; Africa; Eurasia |
| | Brill–Zinsser disease | **None (recrudescence of latent infection)** | |
| | Flying squirrel typhus | **Contact with flying squirrel** (*Glaucomys volans*) and its fleas and lice | North America |
| *Rickettsia typhi* | Murine (endemic) typhus | **Feces of fleas:** *Xenopsylla cheopis* *Ctenocephalides felis* | Worldwide North America |
| *Orientia tsutsugamushi* | Scrub typhus | **Bite of larval trombiculid mites:** | |
| | | *Leptotrombidium deliense*, *L. fletcheri*, *L. scutellare*, *L. arenicola* | Southern and eastern Asia; islands of the southwestern Pacific and Indian Oceans; northern Australia |
| | | e.g. *L. pallidum* | Japan; Korea; Russian Far East |
| | | e.g. *L. scutellare* | China; Malaysia |
| | | e.g. *L. deliense, L. fletcheri, L. arenicola* | Tropical regions |
| *Ehrlichia chaffeensis* | Human monocytic ehrlichiosis | **Bite of tick**: | |
| | | *Amblyomma americanum* (Fig. 63.1), *Dermacentor variabilis* | Southeastern and south central US |

**Table 63.2** *Continued* **Epidemiology of rickettsial infections.**

| EPIDEMIOLOGY OF RICKETTSIAL INFECTIONS | | | |
|---|---|---|---|
| **Agent** | **Disease** | **Transmission** | **Geographic distribution** |
| *Ehrlichia muris*-like (EML) agent | EML agent ehrlichiosis | **Bite of tick:** | |
| | | *Ixodes scapularis* | Upper midwestern US |
| *Ehrlichia ewingii* | *Ehrlichia ewingii* ehrlichiosis | **Bite of tick**: | |
| | | *Amblyomma americanum* | Southeastern and south central US |
| *Anaplasma phagocytophilum* | Human granulocytic anaplasmosis | **Bite of tick**: | |
| | | *Ixodes scapularis* (Fig. 63.1) | Northern US |
| | | *I. pacificus* | Far western US |
| | | *I. ricinus, I. persulcatus* | Eurasia |
| *Coxiella burnetii* | Q fever | **Aerosol** of infected products of parturition of ruminants (e.g. sheep, cattle, goats), cats, and other animals* | Worldwide |

*Less common means of transmission include ingestion of contaminated dairy products and tick bites (e.g. Dermacentor spp.).

**Table 63.2** *Continued* **Epidemiology of rickettsial infections.** Additional tick-borne infections include Pacific Coast tick fever (*Rickettsia philipii,* type strain "Rickettsia 364D"), Far Eastern spotted fever (*Rickettsia heilongjiangenesis*), *Rickettsia massiliae* rickettsiosis, and *Candidatus Neoehrlichia mikurensis* infection. *Courtesy, David H. Walker, MD.*

the individual macules and papules develop central vesicles and hemorrhagic crusts (Fig. 63.7B).

- **DDx:** varicella and disseminated zoster, other vesicular viral exanthems (e.g. Coxsackie), pityriasis lichenoides et varioliformis acuta (PLEVA), bullous insect bite reactions, scabies.
- **Rx:** tetracycline or doxycycline (dosages in Table 63.4).

## Ehrlichiosis

- The primary vector for ehrlichiosis is the lone star tick *Amblyomma americanum* (Figs 63.1 and 63.8), with the white-tailed deer serving as a major reservoir.
- In addition to fever, headache, and myalgias, patients with human monocytic ehrlichiosis (HME) can develop meningoencephalitis and acute respiratory distress syndrome, with overwhelming disease in immunocompromised hosts.
- Mucocutaneous lesions appear an average of 5 days into the illness of HME and vary from a widespread morbilliform eruption to petechiae favoring the palms and soles to vesicular; occasionally palpable purpura due to small vessel vasculitis can occur.
- Dx: PCR of blood, with intracytoplasmic macrocolonies of bacteria sometimes noted in peripheral blood smears.
- **DDx:** see sections on RMSF and rickettsialpox (if vesicular).
- **Rx:** see Table 63.4.

## Anaplasmosis (Human Granulocytic Anaplasmosis)

- Cutaneous manifestations are rare (<5% of patients), but patients may have concurrent signs and symptoms of Lyme borreliosis and/or babesiosis because all three infections are transmitted by *Ixodes* ticks, e.g. *I. scapularis* in the northeastern United States (see Fig. 63.8).
- The illness is usually not as severe as HME and patients may have peripheral neuropathy.
- **Rx:** see Table 63.4.

For further information see Ch. 76 from *Dermatology, Fourth Edition*.

**For additional online figures visit www.expertconsult.com**

**COMPARISON OF *IXODES SCAPULARIS*, *AMBLYOMMA AMERICANUM*, AND *DERMACENTOR VARIABILIS*, BY LIFE STAGE**

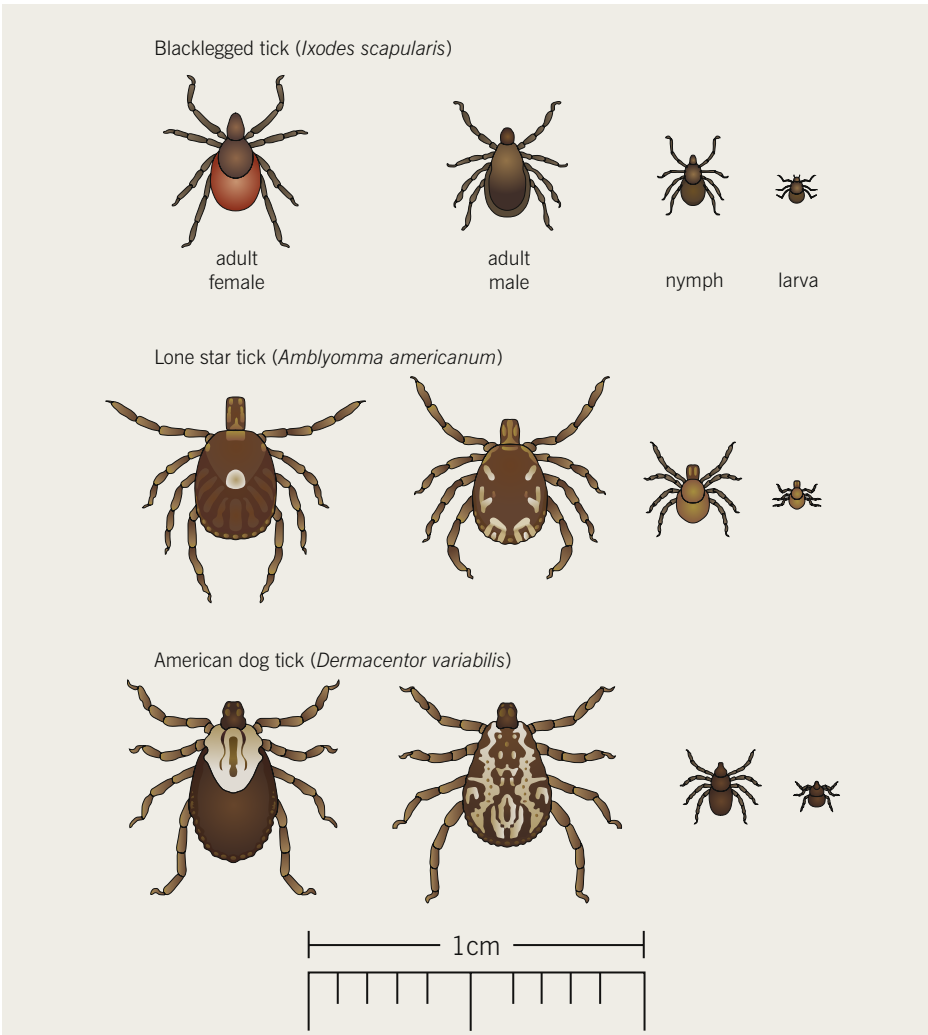


**Fig. 63.1 Comparison of *Ixodes scapularis* (blacklegged tick), *Amblyomma americanum* (lone star tick), and *Dermacentor variabilis* (American dog tick), by life stage.** *From Chapman, A. S., et al. MMWR Recomm Rep 2006;55:1–27.*

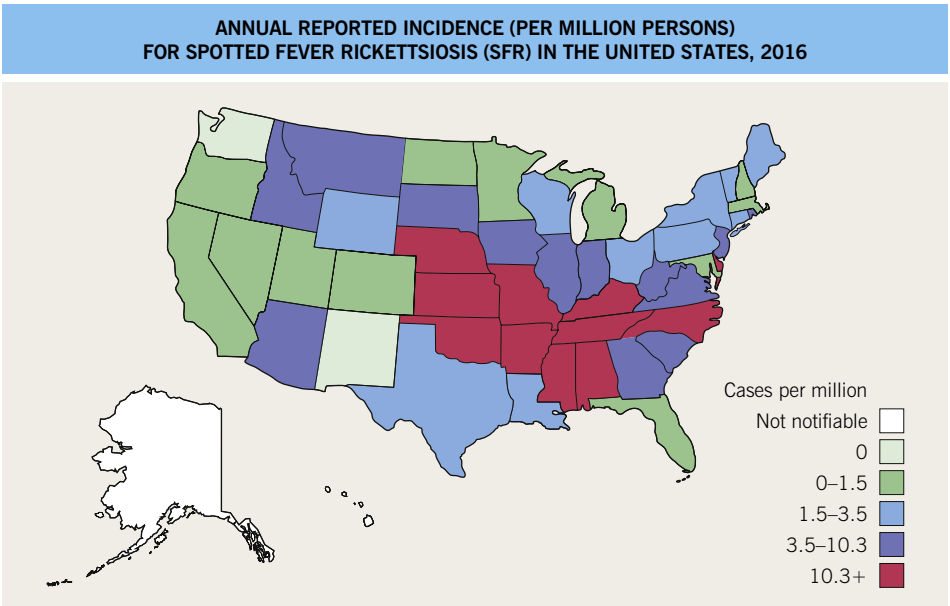


**Fig. 63.2 Annual reported incidence (per million persons) for spotted fever rickettsiosis (SFR) in the United States, 2016.** As of 2010, cases of RMSF are reported under the category of SFR, along with *Rickettsia parkeri* rickettsiosis, Pacific Coast tick fever, and rickettsialpox. *From* www.cdc.gov/rmsf/stats/#reportsurv.



**Fig. 63.3 Rocky Mountain spotted fever.** The cutaneous lesions often first appear on the ankles and wrists. These are nonblanching due to hemorrhage within the skin. *Courtesy, Philippe Berbis, MD.*



**Fig. 63.4 Rocky Mountain spotted fever.** Petechiae on the palms and soles often develop relatively later in the disease course. *Courtesy, Ronald Rapini, MD.*



**Fig. 63.5 Rocky Mountain spotted fever.** Petechiae are present within erythematous papules and plaques on the buttocks. Some of the lesions have a retiform pattern. *Courtesy, YDRSC.*



**Fig. 63.6 Rocky Mountain spotted fever.** Retiform purpura on the distal lower extremity in a patient with more severe disease. *Courtesy, YDRSC.*




**Fig. 63.7 Rickettsialpox. A** Eschar at the site of the mite bite. **B** Scattered papules with central hemorrhagic crusts. *A, B, Courtesy, NYUDSC.*

| EVALUATION OF SUSPECTED CUTANEOUS LESION(S) OF A SPOTTED FEVER, INCLUDING RMSF, VIA REAL-TIME PCR |
|---|
| • Contact the state health department to assist (required if utilizing the CDC) |
| • 4- to 5-mm skin biopsy of a fresh but developed lesion (e.g. in the case of a spotted fever, a maculopapular lesion with pinpoint hemorrhage) that includes the center of the lesion |
| • Appropriate treatment for <24 hours does not appear to alter sensitivity |
| • Appropriate treatment for ≥72 hours often results in a negative test |
| • Fresh, non-frozen tissue preferred with placement of skin biopsy inside sterile urine container on gauze moistened with sterile saline (transport overnight with cold packs) (see Fig. 2.10B) |
| • PCR can be done on frozen tissue (transport overnight with dry ice) |

**Table 63.3 Evaluation of suspected cutaneous lesion(s) of a spotted fever, including Rocky Mountain spotted fever (RMSF), via real-time PCR.** These recommendations are those of the Centers for Disease Control and Prevention (CDC) (https://www.cdc.gov/ncezid/dvbd/pdf/Collection-Submission-Skin-Biopsy-Specimens-Rickettsial-Disease.pdf). Cell culture isolation from fresh tissue can also be done.

| TREATMENT OF RICKETTSIAL DISEASES | | | | |
|---|---|---|---|---|
| | **Medication** | **Adult dose** | **Pediatric dose** | **Treatment duration** |
| • First choice for virtually all rickettsial infections in both children and adults* | Doxycycline | 100 mg PO or IV twice daily | 2.2 mg/kg (max. 100 mg) PO or IV twice daily | Until ≥3 days after defervescence, for a minimum total course of 5–7 days† |
| • Alternative for non-life-threatening rickettsial infections in pregnant women | Chloramphenicol‡ | 500 mg IV every 6 hours | Not recommended | Until ≥3 days after defervescence, for a minimum total course of 5–7 days† |
| • Alternative for non-life-threatening HME or HGA in pregnant women<br>• Alternative for resistant scrub typhus | Rifampin | 300 mg PO twice daily | 10 mg/kg (max. 300 mg) twice daily | Until ≥3 days after defervescence, for a minimum total course of 7–10 days |
| • First choice for scrub typhus in pregnant women and potentially in children<br>• Alternative for mild rickettsioses (e.g. early boutonneuse fever) during pregnancy or in children | Azithromycin§ | 500 mg PO daily | 10 mg/kg PO daily | 3 days |

**With the exception of infections in pregnant women, although doxycycline administration during pregnancy can be considered in life-threatening situations when the suspicion of RMSF or other severe rickettsioses is high; other tetracyclines are also effective for rickettsial infections.*
*†Recommended by the CDC; others recommend a 10-day course.*
*‡May be associated with gray baby syndrome when administered late in the third trimester of pregnancy.*
*§Clarithromycin may also be considered.*

**Table 63.4 Treatment of rickettsial diseases.** Empiric treatment with an appropriate agent should be initiated immediately when a diagnosis of Rocky Mountain spotted fever (RMSF), human monocytic ehrlichiosis (HME), human granulocytic anaplasmosis (HGA), or another potentially severe rickettsiosis is suspected clinically.

**APPROXIMATE DISTRIBUTION IN THE US OF VECTOR TICK SPECIES FOR HUMAN MONOCYTOTROPIC EHRLICHIOSIS, HUMAN GRANULOCYTIC ANAPLASMOSIS, *RICKETTSIA PARKERI* RICKETTSIOSIS, AND LYME BORRELIOSIS**

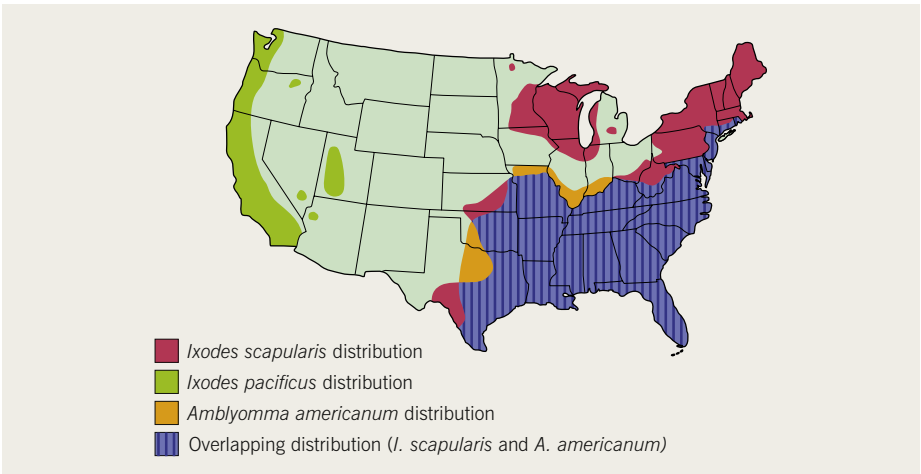


**Fig. 63.8 Approximate distribution in the United States of vector tick species for human monocytic ehrlichiosis, human granulocytic anaplasmosis, *Rickettsia parkeri* rickettsiosis, and Lyme borreliosis.** It has been postulated that *Amblyomma maculatum*, which is classically found primarily along the Atlantic and Gulf coasts, has a range as broad as that of *Amblyomma americanum*. *From Chapman, A. S., et al. MMWR Recomm Rep 2006;55:1–27.*



**eFig. 63.1 African tick bite fever.** Eschar at the tick bite site. *Courtesy, David H. Walker.*

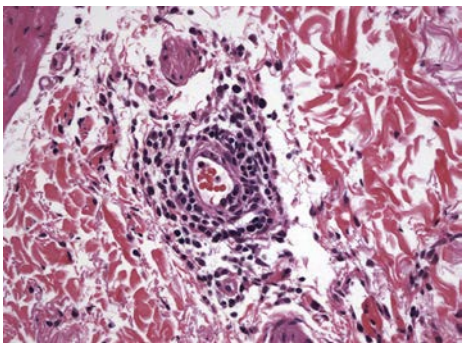

**eFig. 63.2 Rocky Mountain spotted fever – histopathologic findings.** Typical lymphohistiocytic vasculitis involving a dermal blood vessel. *Courtesy, James W. Patterson, MD.*

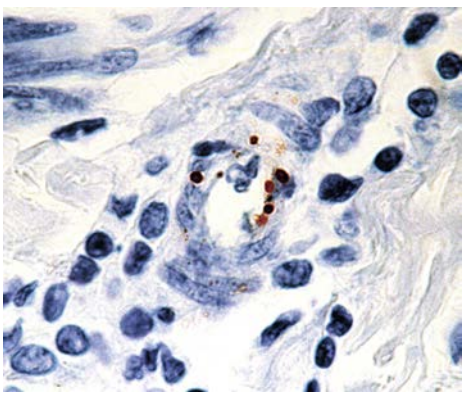

**eFig. 63.3 Immunohistochemical detection of spotted fever rickettsiae.** Organisms within the endothelium of a dermal blood vessel are highlighted by brown staining. This staining can be performed on fresh or formalin-fixed tissue.

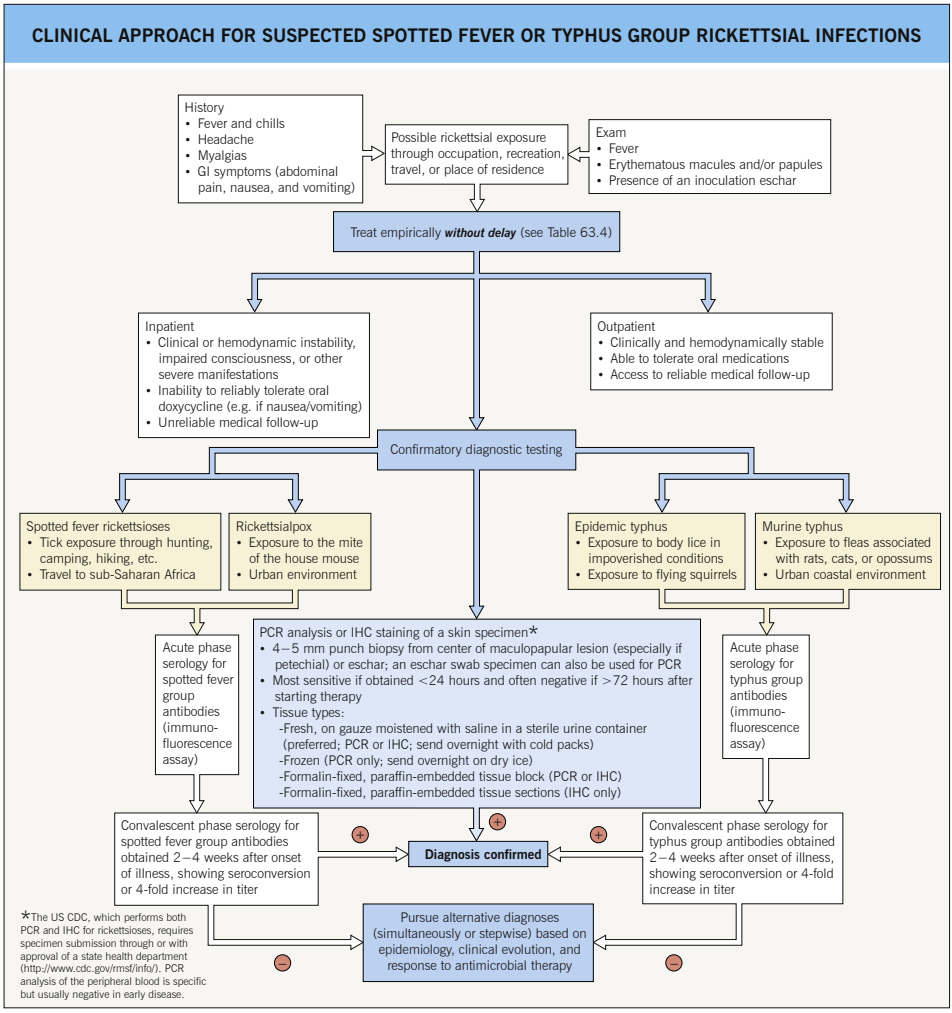


**eFig. 63.4 Clinical approach for suspected spotted fever or typhus group rickettsial infections.** IHC, immunohistochemical.

# 64 Fungal Diseases

## Key Points

- Cutaneous fungal diseases can be broadly divided into two groups:
  - Superficial – limited to the stratum corneum, hair, and/or nails
  - Deep – dermal and/or subcutaneous
- Superficial fungal infections can be further subdivided into:
  - Non-inflammatory – most commonly tinea versicolor, but includes tinea nigra and piedra
  - Inflammatory – primarily infections due to dermatophytes (*Trichophyton*, *Microsporum*, *Epidermophyton*; e.g. tinea corporis, tinea cruris) or *Candida* spp. (e.g. cutaneous candidiasis of the groin)
- Deep fungal infections are often secondary to implantation (e.g. sporotrichosis, chromo(blasto) mycosis, eumycetoma) or hematogenous spread of an underlying systemic infection (e.g. cryptococcosis, coccidioidomycosis).
- Opportunistic pathogens (e.g. *Aspergillus*, *Mucor*) can lead to systemic infection in immunosuppressed hosts.

## Superficial Fungal Infections

### Tinea (Pityriasis) Versicolor

- Secondary to transformation of *Malassezia* spp., especially *M. furfur*, from the yeast form to the hyphal form (see Fig. 2.1A).
- *Malassezia* spp. are part of the normal flora.
- Multiple, brown (hyperpigmented), tan (hypopigmented), or pink, oval to round macules, patches, or thin plaques; there is often coalescence of lesions centrally with scattered lesions at the periphery.
- Associated scale may be subtle but becomes more obvious with gentle scratching or stretching of the skin.
- Most commonly develops on the upper trunk and shoulders, but can also involve flexural sites such as the antecubital fossae, submammary folds, and groin (Fig. 64.1); in children more frequently than adults, there can also be facial involvement.

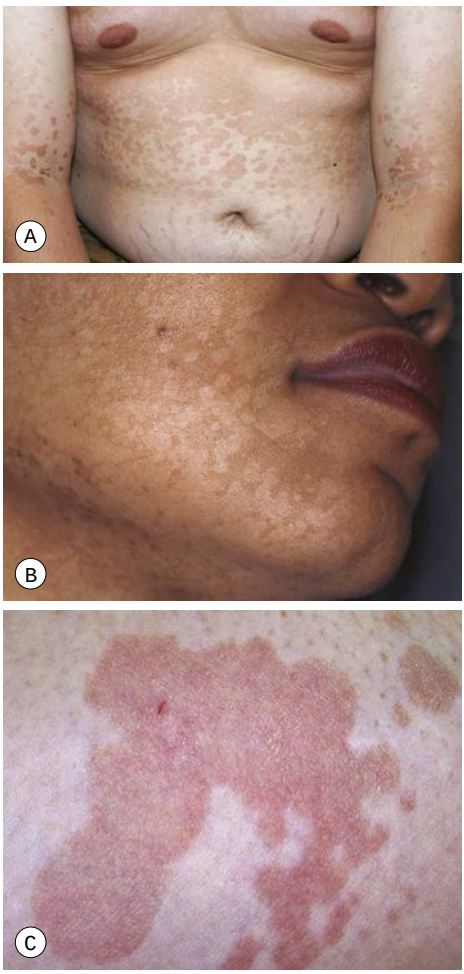


**Fig. 64.1 Tinea (pityriasis) versicolor.** **A** Hyperpigmented variant. **B** Hypopigmented variant on the face. **C** Coalescing pink lesions with fine scale. *A, B, Courtesy, Kalman Watsky, MD; C, Courtesy, Boni E. Elewski, MD and Roderick J. Hay, MD.*

| TREATMENT OF TINEA (PITYRIASIS) VERSICOLOR | |
|---|---|
| Initial therapy (often combination) | **Topical**<br>• Application of antifungal shampoo for 10 minutes to 1 hour weekly to twice weekly for 2–4 weeks<br>• Selenium sulfide shampoo, 1% (OTC) or 2.5%<br>• Ketoconazole shampoo, 1% (OTC) or 2%<br>• Imidazoles, e.g. ketoconazole 2% cream daily to BID × 2 weeks<br>• Apply several hand-widths beyond clinically visible lesions |
| | **Oral**<br>• Fluconazole 200–400 mg PO once weekly × 2–3 doses |
| Maintenance therapy (tinea versicolor commonly recurs) | **Examples of topical regimens**<br>• Treat previously affected sites with topical imidazole daily for 2 weeks prior to anticipated sun exposure (temperate climates)<br>• Apply antifungal shampoo (see above) 1–2 times every month (tropical climates) |

**Table 64.1 Treatment of tinea (pityriasis) versicolor.**

• Often first noticed in the summer, and a suntan accentuates the hypopigmented variant.
• **DDx:** postinflammatory hypopigmentation and idiopathic macular hypomelanosis (if hypopigmented); confluent and reticulated papillomatosis of Gougerot and Carteaud (if hyperpigmented; see Ch. 89).
• **Rx:** outlined in Table 64.1.
• Following appropriate **Rx**, the associated hypopigmentation may persist for months until there is repigmentation or fading of the suntan.

## Tinea Nigra, Black Piedra, and White Piedra

• Typically seen in tropical areas.
• Tinea nigra:
  – Most commonly due to infection with *Hortaea werneckii*, a pigmented fungus found in soil
  – Brown, sharply marginated macule or patch; most commonly on the palms (Fig. 64.2)
  – **Rx:** keratolytic agents (e.g. salicylic acid 6% cream) and topical antifungals (e.g. terbinafine 1% cream)
• Black piedra and white piedra are characterized by the formation of nodules on hair shafts (Table 64.2; Fig. 64.3).

## Dermatophytoses (Tinea Infections)

• The names of dermatophyte infections consist of the word "tinea" followed by the Latin name for the involved body site; examples are tinea pedis (foot) and tinea cruris (groin) (Fig. 64.4).



**Fig. 64.2 Tinea nigra.** Single, sharply demarcated brown macule on the finger. *Courtesy, Frank Samarin, MD.*

• Due to fungi of three genera – *Trichophyton*, *Microsporum*, and *Epidermophyton* – that invade only keratinized tissue (stratum corneum, hair, and nails):
  – With the exception of tinea capitis, *Trichophyton rubrum* and *T. mentagrophytes* are the most common pathogens
  – *Trichophyton mentagrophytes* (previously *T. mentagrophytes* var. *mentagrophytes*) is acquired from animals (zoophilic); *T. interdigitale*

(previously *T. mentagrophytes* var. *interdigitale* [anthropophilic]) is spread human-to-human

- Transmission occurs via close contact with infected humans or domestic animals, occupational or recreational exposure (e.g. locker rooms), and contact with contaminated clothing, furniture, or brushes; the latter inanimate objects serve as fomites.
- More commonly seen in adults, with the exception of tinea capitis, which occurs more often in children.
- The classic presentation is an erythematous, annular lesion with an active, scaly border; superficial pustules may also be present (Fig. 64.5).
- Occasionally, vesicles may develop, especially in tinea pedis or manuum due to *T. mentagrophytes*.
- Dx: KOH ± fungal culture of skin scrapings (see Fig. 2.1) as well as hairs and nails, in the case of tinea capitis and tinea unguium, respectively.
- Important variants:
  - *Tinea incognito* refers to atypical clinical presentations, often due to inappropriate treatment with potent topical CS or combination topical therapies that contain CS; lesions may lack scale or be minimally inflamed (Fig. 64.6)
  - *Majocchi granuloma* is characterized by erythematous papules or pustules within an area of tinea corporis; the papules represent sites of hair shaft invasion, usually due to *T. rubrum*; often seen in women with tinea pedis who shave their legs or in immunosuppressed patients (see Fig. 31.4A; Fig. 64.7)

### EXAMPLES OF SPECIFIC TYPES OF DERMATOPHYTOSES

- Tinea pedis (Fig. 64.8; **DDx**, see Table 13.1):
  - Most commonly due to *T. rubrum* or *T. interdigitale* and *T. mentagrophytes* > *Epidermophyton floccosum*
  - Four major types: (1) interdigital – erythema, scaling, and maceration in the web spaces, especially the two lateral web spaces, which have the most occlusion; can be accompanied by fissures as well as superimposed bacterial infection; (2) moccasin – diffuse scaling and erythema that extends onto the lateral aspect of the feet;

**COMPARISON OF BLACK AND WHITE PIEDRA**

| | White piedra | Black piedra |
|---|---|---|
| Nodule color | White (occasionally red, green, or light brown) | Brown to black |
| Nodule firmness | Soft | Hard |
| Nodule adherence to the hair shaft | Loose | Firm |
| Typical anatomic location | Face, axillae, and pubic region (occasionally scalp) | Scalp and face (occasionally pubic region) |
| Favored climate | Tropical | Tropical |
| Causative organism | *Trichosporon beigelii* | *Piedraia hortae* |
| KOH examination of "crush prep" of cut hair shafts | Non-dematiaceous hyphae with blastoconidia and arthroconidia (see Fig. 2.17A) | Dematiaceous hyphae with asci and ascospores (sexual reproduction) |
| Culture on Sabouraud's agar | Moist, cream-colored, yeast-like colonies* | Slow-growing, dark green to dark brown-black colonies |
| Treatment | Clip affected hairs, wash affected hairs with antifungal shampoo | Clip affected hairs, wash affected hairs with antifungal shampoo |

**Growth inhibited by cycloheximide.*

**Table 64.2 Comparison of black and white piedra.** *From Elewski B. The superficial mycoses, the dermatophytoses, and select dermatomycosis. In: Elewski BE, editor. Cutaneous Fungal Infections. Massachusetts: Blackwell Science; 1998.*




**Fig. 64.3 Causes of nodules on hair shafts.** *A inset, From Bonifaz, A. Tinea versicolor, tinea nigra, white piedra, and black piedra. Clinics in Dermatology, 2010-03-01, Volume 28, Issue 2, pp. 140–5, Copyright © 2010 Elsevier Inc. ISSN: 0738-081X. Fig. 11; D inset, Courtesy, YDRSC.*

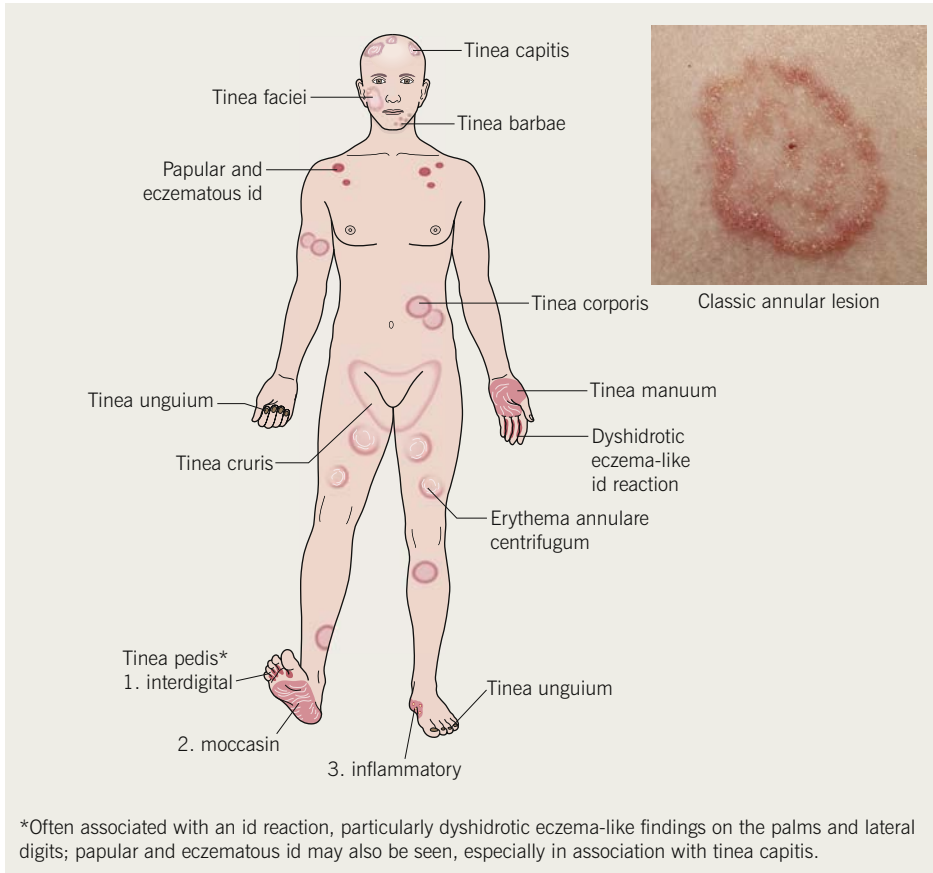


**Fig. 64.4 Dermatophyte infections of the skin and potential associated reactions.** Erythema annulare centrifugum is a reaction pattern that can be idiopathic or associated with tinea infections (see Ch. 15).

(3) in inflammatory (vesicular) – vesicles and bullae, especially on the medial aspect of the plantar surface; and (4) ulcerative, which is often an exacerbation of interdigital tinea pedis, especially in immunocompromised and diabetic patients. Secondary bacterial (e.g. pseudomonal) infection is common (see Fig. 61.15)
  - Consider use of oral antifungal medications if the tinea pedis fails to respond to topical agents or is severe (Table 64.3)
- Tinea unguium (Fig. 64.9):
  - Dx: KOH preparation and/or fungal culture of nail plate and subungual scale, PAS-staining of nail clippings
  - Of note, *onychomycosis* is a more general term that includes nail infections due to dermatophytes, *Candida* spp., and saprophytes (up to 10% of toenail infections; Table 64.4)
- Tinea cruris (Fig. 64.10; **DDx**, see Fig. 13.2):
  - Favors the upper inner thighs and can extend to the lower abdomen and buttocks; usually spares the scrotum, unlike candidiasis; associated with tinea pedis
  - Most commonly due to *T. rubrum* > *Epidermophyton floccosum* > *T. mentagrophytes*
- Tinea manuum (Fig. 64.11; **DDx**, see Fig. 13.1):
  - Often due to same dermatophyte as associated tinea pedis
  - Can be unilateral ("one hand, two feet syndrome"; see Fig. 64.8A)

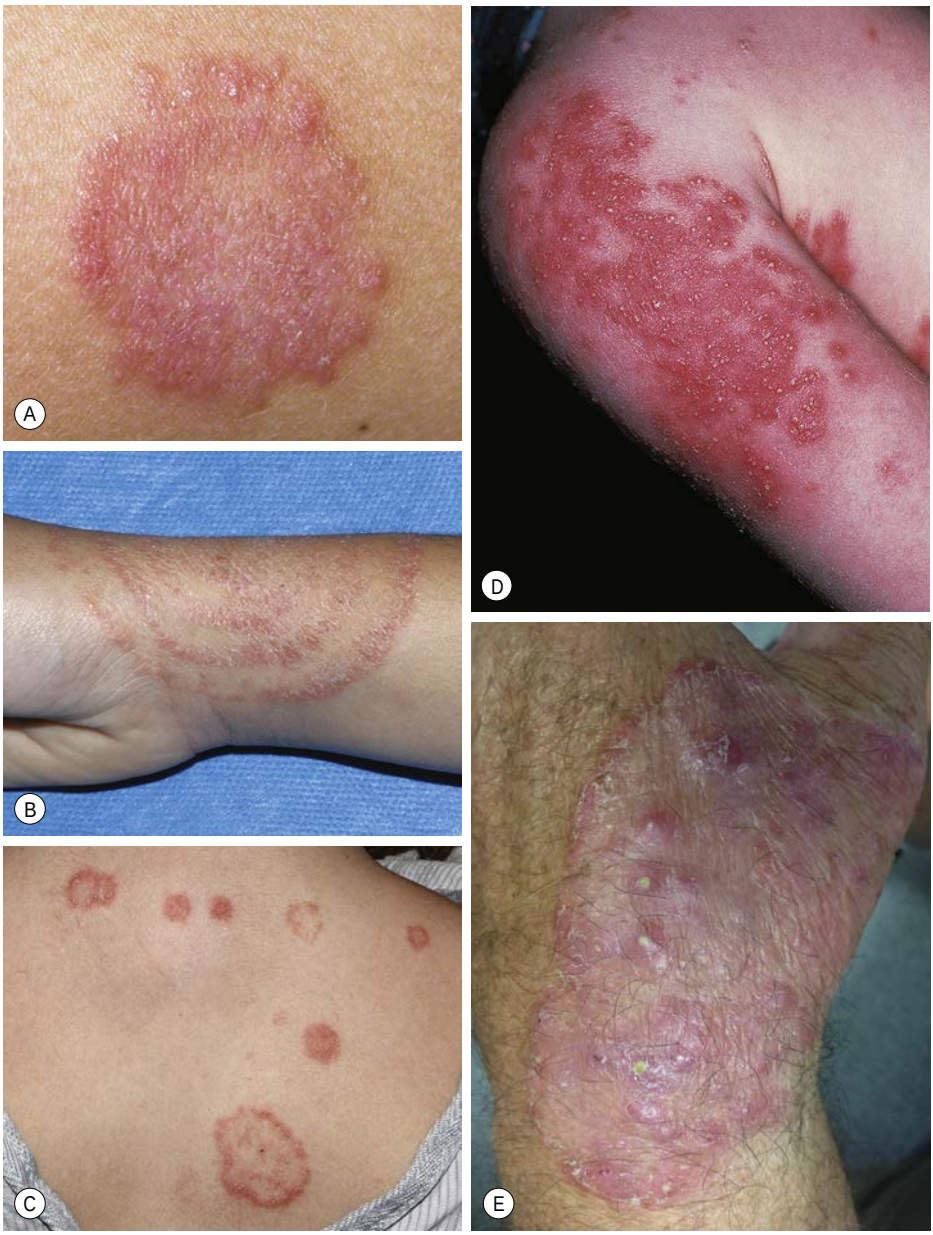


**Fig. 64.5 Tinea corporis.** **A** Lesions with subtle annular configuration and border composed of individual, slightly scaly papules. **B** Scaly concentric rings on the arm. **C** Multiple annular and circinate lesions of various sizes on the upper back. **D** Pustules within multiple figurate lesions on the upper arm. **E** Against the diagnosis of folliculitis, all of the pustules are contained within the pink plaque.
*A, B, D, Courtesy, Julie V. Schaffer, MD; C, Courtesy, Kalman Watsky, MD; E, Courtesy, Karynne O. Duncan, MD.*




**Fig. 64.6 Tinea faciei and tinea incognito.** **A** Area of erythema and scale on the nose and philtrum of a young child. **B** Hyperpigmented lesions with subtle arcuate and annular configurations in a woman with darkly pigmented skin. There is minimal scale following the use of topical CS ("tinea incognito"). The clue to application of topical CS is the relative hypopigmentation as compared with the more medial cheek. **C** Child with pink papules, a few tiny pustules, and thin annular and arcuate scaly plaques in a perinasal and perioral distribution. These clinical findings could be mistaken for periorificial dermatitis. *A, Courtesy, Julie V. Schaffer, MD; B, Courtesy, Kalman Watsky, MD; C, Courtesy, Antonio Torrelo, MD.*

– Tinea unguium of the involved hand is a clinical clue



**Fig. 64.7 Nodular perifolliculitis (Majocchi granuloma).** Perifollicular inflammation and follicular pustules on the leg due to *Trichophyton rubrum.* A few of the lowermost papules have a granulomatous appearance. *Courtesy, Kalman Watsky, MD.*

- Tinea faciei (see Fig. 64.6):
  - Misdiagnosis is common and application of topical CS is a typical history, often leading to tinea incognito
  - An arciform shape with pustules in the border points to the diagnosis
- Tinea barbae (Fig. 64.12; see Fig. 31.7):
  - Often secondary to a zoophilic dermatophyte – i.e. acquired from an animal, e.g. *T. mentagrophytes* (small mammals) and *T. verrucosum* (cattle)
  - Favors postpubertal males
  - Invasion of hair shafts and intense inflammation with follicular pustules and abscess formation; can resemble a kerion
- Tinea capitis (Fig. 64.13):
  - Occurs more frequently in children
  - In the United States as well as other

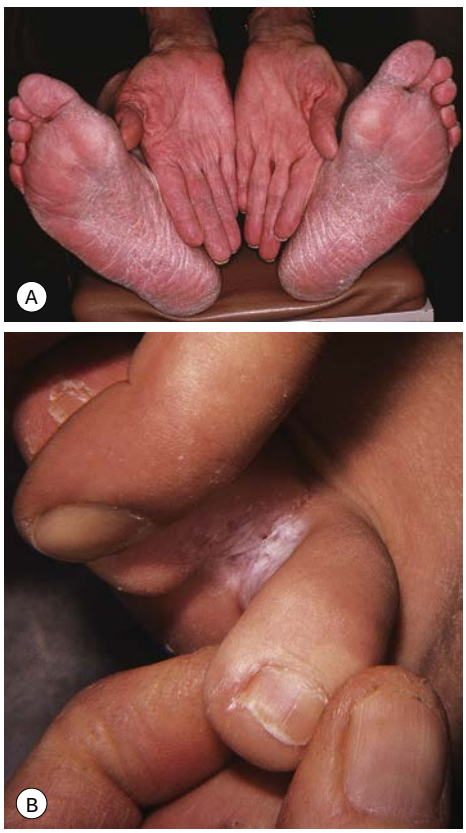


**Fig. 64.8 Tinea pedis.** Diffuse scaling in the moccasin type **(A),** maceration between the third and fourth toes in the interdigital form **(B),** and erythema, scale-crust, and bullae in the inflammatory form **(C)**. The patient in **(A)** also has involvement of the right hand (i.e. one hand–two feet tinea). *A, C, Courtesy, YDRSC; B, Courtesy, Jean L. Bolognia, MD.*

| THERAPEUTIC REGIMENS FOR DERMATOPHYTOSES | | | | |
|---|---|---|---|---|
| **Topical medications** | | | | |
| Twice daily for 2–4 weeks<br>• Allylamines (e.g. terbinafine 1% cream, naftifine 1% gel)<br>• Imidazoles (e.g. econazole 1% cream, sulconazole 1% solution)<br>• Hydroxypyridinones (e.g. ciclopirox 0.77% cream or gel) | | | | |
| **Oral medications** | | | | |
| | **Fluconazole** | **Griseofulvin** | **Itraconazole*** | **Terbinafine** |
| Tinea corporis and pedis (moccasin type)/tinea manuum (*adults*)** | 150–200 mg/week × 2–6 weeks | 500–1000 mg/day (microsize) or 375–750 mg/day (ultra-microsize) × 4 weeks | 200–400 mg/day × 1 week | 250 mg/day × 1–2 weeks |
| Majocchi granuloma | Terbinafine is used most commonly<br>Doses as above × 2–8 weeks (or until all lesions cleared) | | | |
| Tinea corporis and pedis (moccasin type)/tinea manuum (*children*)** | 6 mg/kg/week × 2–6 weeks | 15–20 mg/kg/day (microsize suspension) × 4 weeks | 3–5 mg/kg/day (maximum 400 mg) × 1 week | Daily dosing as for tinea capitis (see below) × 2 weeks |
| Tinea unguium (*adults*) | Toenail ± fingernail involvement | | | |
| | 200–450 mg/week until nails are clear | 1–2 gm/day (microsize) or 750 mg/day (ultra-microsize) until nails are normal† | 200 mg/day × 12 weeks or 200 mg BID × 1 week per month for 3–4 consecutive months | 250 mg/day × 12 weeks |
| | Fingernail involvement only | | | |
| | 200–450 mg/week until nails are clear | 1–2 gm/day (microsize) or 750 mg/day (ultra-microsize) until nails are normal† | 200 mg/day × 6 weeks or 200 mg BID × 1 week per month for 2 consecutive months | 250 mg/day × 6 weeks |
| Tinea capitis (*adults*)‡ | 6 mg/kg/day × 3–6 weeks | 10–15 mg/kg/day (ultra-microsize; usually maximum 750 mg/day) × 6–8 weeks | 5 mg/kg/day (maximum 400 mg) × 4–8 weeks | 250 mg/day × 3–4 weeks§ |
| Tinea capitis (*children*)‡ | 6 mg/kg/day × 3–6 weeks | 20–25 mg/kg/day (microsize suspension) × 6–8 weeks | 5 mg/kg/day (maximum 400 mg) × 4–8 weeks | If available (not in U.S.), granules 125 mg (<25 kg), 187.5 mg (25–35 kg), or 250 mg (>35 kg) × 3–4 weeks§ |

**Not approved in the United States for use in children.*
***In general, the shorter courses and lower doses tend to be used for tinea corporis.*
*†No longer commonly used for this indication.*
*‡Combined with 2.5% selenium sulfide shampoo or ketoconazole 2% shampoo; "id" reaction should not be confused with a medication allergy.*
*§Not recommended for Microsporum canis, unless given at double-dose.*

**Table 64.3 Therapeutic regimens for dermatophytoses.**




**Fig. 64.9 Tinea unguium.** Onycholysis, yellowing, crumbling, and thickening of the fingernails **(A)**, thumb nails **(B)**, and toenails **(C)** in the distal/lateral subungual variant. Diffuse **(D)** white discoloration of the toenail in the superficial white variant. **E** Proximal white subungual onychomycosis of the second and fourth fingernails in an HIV-infected patient. Hyphae within a formalin-fixed, PAS-stained nail plate **(F)**. *A, D, Courtesy, Jean L. Bolognia, MD; B, Courtesy, Louis A. Fragola, Jr., MD; C, Courtesy, Boni E. Elewski, MD and Roderick J. Hay, MD; E, From Callen, J. et al. Dermatological Signs of Systemic Disease, 5th Edition. Elsevier, 2016, ISBN: 9780323358293, Fig. 29.14; F, Courtesy, Mary Stone, MD.*

regions such as the United Kingdom, *T. tonsurans* is the most common pathogen; for example, in the United States, it causes >95% of tinea capitis; *T. tonsurans* favors those with afrocentric hair

– Tinea capitis due to *T. tonsurans* can be more difficult to diagnose because the clinical findings may be subtle with only seborrheic dermatitis-like scaling of the scalp, minimal alopecia, and no fluorescence by Wood's lamp examination (in contrast to ectothrix infection due to *M. canis*)
– Multiple spores (conidia) within or surrounding hair shafts, referred to as endothrix or ectothrix tinea capitis, respectively, cause fragility and breakage of hair, leading to areas of alopecia (see Figs 2.2 and 2.3)
– In addition to alopecia, clinical clues include pustules, scale, and crusting; occasionally, there is formation of a kerion (see Fig. 64.13E) or development

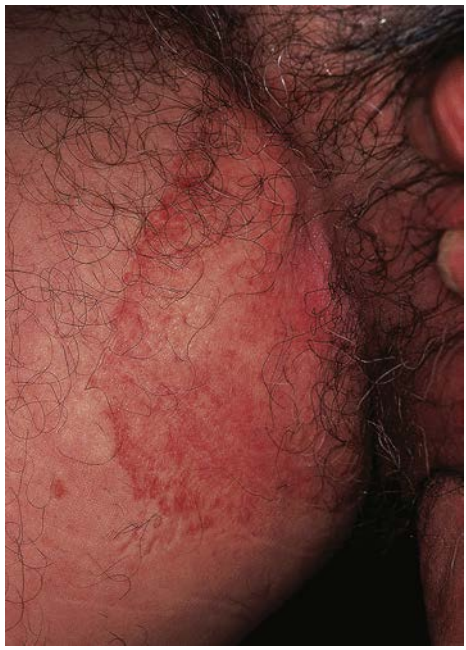

**Fig. 64.10 Tinea cruris.** Note the arciform erythematous border on the upper inner thigh. *Courtesy, YDRSC.*



**Fig. 64.11 Tinea manuum.** Multiple collarettes of scale reminiscent of keratolysis exfoliativa on one palm. *Courtesy, Boni E. Elewski, MD and Roderick J. Hay, MD.*

of posterior cervical and posterior auricular lymphadenopathy

– A type of tinea capitis seen in the Mediterranean basin and Middle East is favus, in which there are keratotic masses that contain hyphae and keratin (Fig. 64.14)



**Fig. 64.12 Tinea barbae.** More superficial form due to *Trichophyton rubrum*. Several follicular pustules are seen. *Courtesy, Jean L. Bolognia, MD.*

– **Rx:** oral treatment is required; for children, an adequate dose of griseofulvin is 20–25 mg/kg/day (microsized suspension) × 6–8 weeks; combination therapy with 2.5% selenium sulfide or 2% ketoconazole shampoo is recommended to kill spores and reduce transmission; see Table 64.3 for additional oral therapies

• Id reactions (see Ch. 11) can occur in the setting of dermatophyte infections; two of the more common examples are as follows (see Fig. 64.4):

– Dyshidrotic eczema-like papules and vesicles of the palms and fingers seen in association with tinea pedis

– Pruritic papules favoring the upper trunk in the setting of tinea capitis, often following the initiation of appropriate therapy

• Erythema annulare centrifugum may also be present in association with tinea pedis (see Ch. 15 and Fig. 64.4).

• **DDx:** outlined in Table 64.4.

• **Rx:** outlined in Table 64.3.

## Candidal Infections

### Superficial Mucocutaneous Candidal Infections

• Most commonly due to *Candida albicans* or *C. tropicalis*.

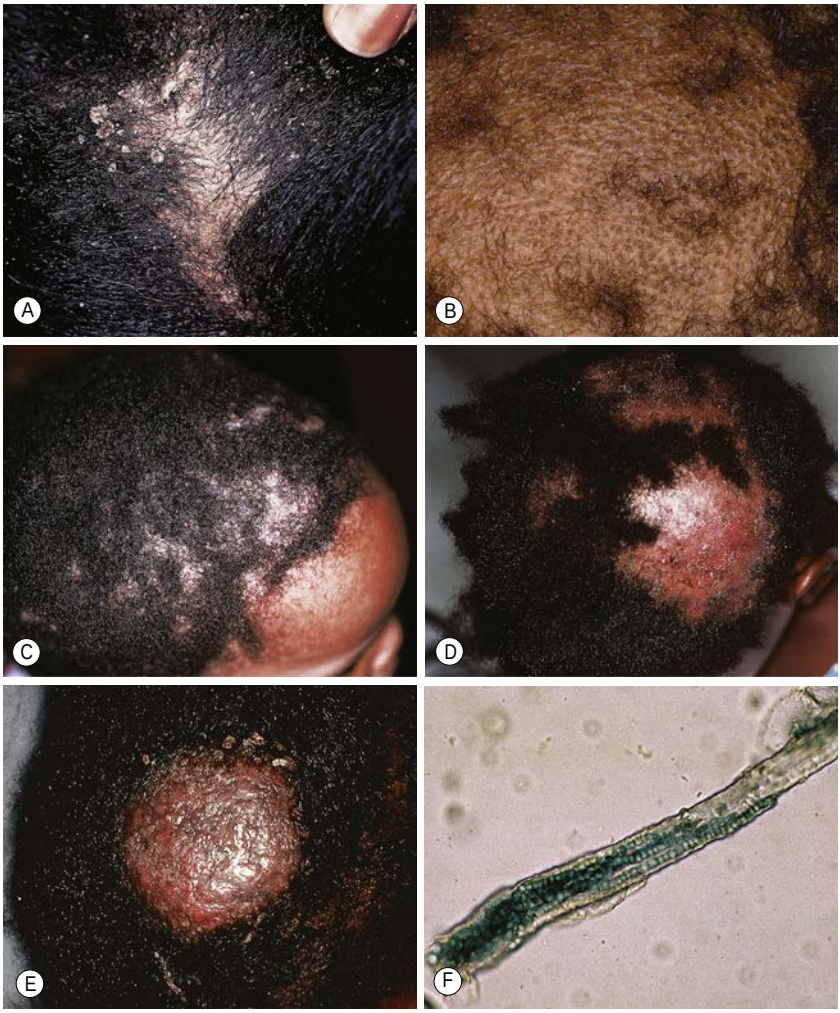


**Fig. 64.13 Tinea capitis.** The range of clinical presentations of tinea capitis due to *Trichophyton tonsurans*, from mild scalp scaling **(A)** to patchy alopecia with black dots **(B)** or scale **(C)** to large areas of alopecia with pustules and scale-crust **(D). E** Kerion formation due to *T. tonsurans*. There is a boggy plaque that can be misdiagnosed as a bacterial abscess. **F** Microscopic examination of involved hairs demonstrates an endothrix pattern (KOH–chlorazol black stain). *A, C, D–F, Courtesy, YDRSC; B, Courtesy, Louis A. Fragola, Jr., MD.*

- Wide spectrum of clinical presentations, from diaper dermatitis in infants (see Fig. 13.4) to intertrigo (see Table 60.5 and Fig. 13.2) to chronic mucocutaneous candidiasis (see Ch. 49).
- Mucosal:
  - Oral candidiasis (thrush) presents as a white exudate resembling cottage cheese; risk factors include diabetes mellitus, treatment with broad-spectrum antibiotics, use of inhaled CS, dentures, and immunosuppression; common in otherwise healthy neonates and infants
  - Additional forms: intraoral erythematous patches and adherent white plaques, glossitis, angular cheilitis (see Fig. 13.5), and vulvovaginitis and balanitis (see Ch. 60)
- Cutaneous:
  - Most common presentation is an erosive, erythematous patch with satellite pustules in an intertriginous zone (inframammary, axillary, inguinal,



**Fig. 64.14 Favus due to *Trichophyton schoenleinii*.** Scarring alopecia with erosions and several scutula on the occipital scalp. The latter represent masses of keratin plus fungi. *Courtesy, Israel Dvoretzky, MD.*

| DIFFERENTIAL DIAGNOSIS OF DERMATOPHYTE INFECTIONS | |
|---|---|
| Tinea corporis | • Dermatitis (atopic, nummular, contact, stasis, seborrheic [petaloid])<br>• Tinea versicolor<br>• Pityriasis rosea<br>• Erythema annulare centrifugum<br>• Annular psoriasis<br>• Parapsoriasis<br>• Subacute cutaneous lupus erythematosus<br>• Granuloma annulare (lacks scale)<br>• Impetigo |
| Tinea capitis | • Alopecia areata<br>• Trichotillomania<br>• Seborrheic dermatitis (unusual in prepubertal populations)<br>• Psoriasis<br>• Tinea amiantacea<br>• If pustules, pyoderma and folliculitis<br>• If scarring, other scarring alopecias (e.g. lichen planus) |
| Tinea unguium | • Onychomycosis due to saprophytes (e.g. *Fusarium*); primarily toenails<br>• Candidal onychomycosis (ridging, yellow discoloration, and onycholysis primarily of fingernails; often there is concurrent paronychia)<br>• Psoriasis<br>• Chronic trauma |
| Tinea faciei | • Dermatitis (seborrheic, contact, atopic, perioral)<br>• Rosacea<br>• Lupus erythematosus<br>• Acne vulgaris<br>• Annular psoriasis (children) |
| Tinea barbae | • Folliculitis (e.g. culture-negative, staphylococcal, herpetic; see Fig. 31.1)<br>• Acne vulgaris, rosacea<br>• Dermatitis (e.g. seborrheic, contact) |
| Tinea pedis (see also Fig. 13.1 and Table 13.1) | If interdigital:<br>• Erythrasma<br>• Gram-negative toe-web infection |

**Table 64.4 Differential diagnosis of dermatophyte infections.**

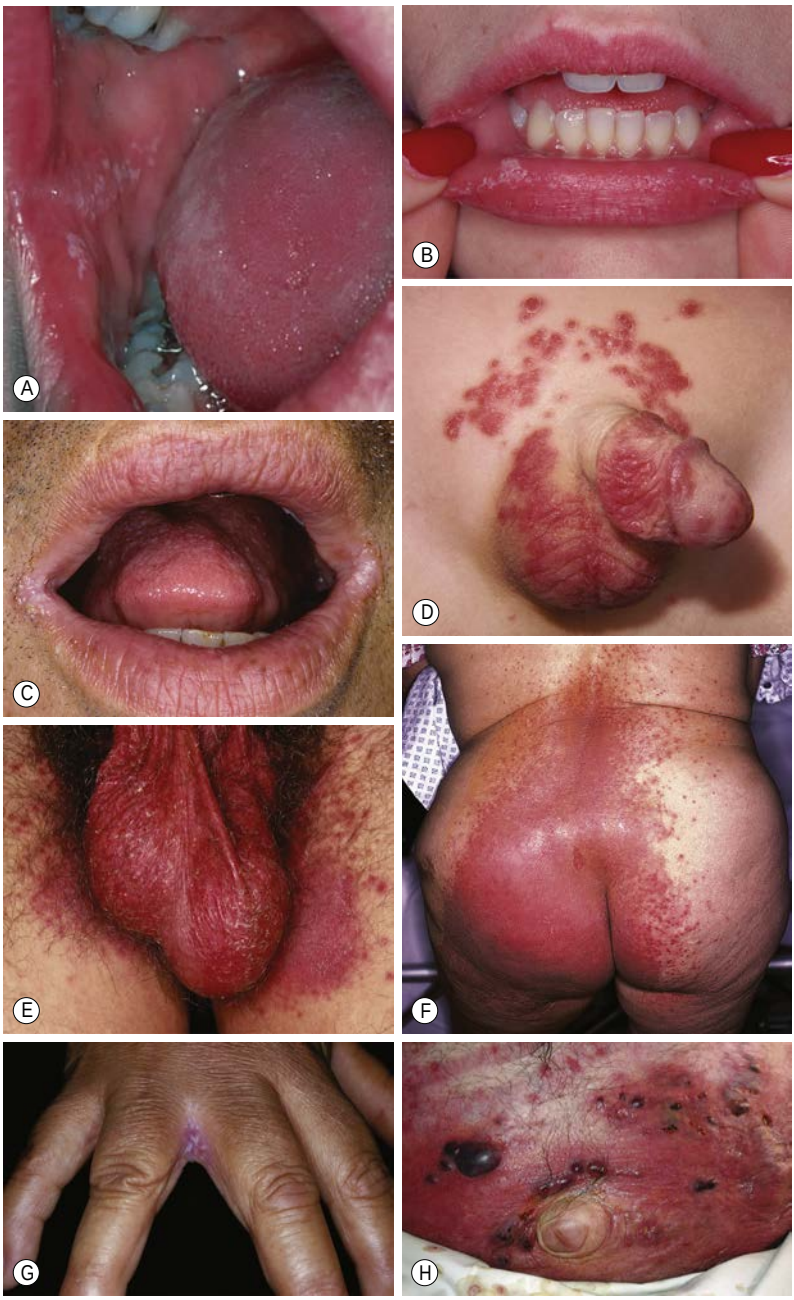


**Fig. 64.15 Mucocutaneous candidiasis.** **A** Thrush with "cottage cheese"-like exudate on the buccal mucosa. **B** Candidal cheilitis with white plaques of the vermilion lip. **C** Angular cheilitis (perlèche). **D** Candidiasis of the suprapubic area, scrotum and penis in a young boy. Note the collarettes of scale on the coalescing, brightly erythematous papules. **E** Candidiasis of the scrotum and medial thighs with beefy red erythema, scale, and satellite papules. **F** This infection occurred in a hospitalized patient with diabetes mellitus who was receiving broad-spectrum antibiotics. Note the multiple satellite lesions. **G** Erosio interdigitalis blastomycetica in the classic location between the third and fourth fingers. **H** Dermal candidiasis in an immunosuppressed patient. *A, Courtesy, Judit Stenn, MD; B, Courtesy, Kalman Watsky, MD; C, D, Courtesy, Louis A. Fragola, Jr., MD; E, G, Courtesy, Eugene Mirrer, MD; F, Courtesy, YDRSC; H, Courtesy, Boni E. Elewski, MD and Roderick J. Hay, MD.*

| TREATMENT OF MUCOCUTANEOUS CANDIDIASIS | |
|---|---|
| **Candidiasis** | **Treatment** |
| Mucosal (continue treatment for 7–14 days after clinical resolution) | Immunocompetent patient<br>• Clotrimazole 10 mg troche five times daily<br>• Nystatin 100,000 units/ml suspension: 4–6 ml swish and swallow four times daily (adults and children); 1 ml in each cheek four times daily (infants)<br>Immunocompromised patient *OR* failure to respond to topical **Rx**<br>• Oral fluconazole 200 mg PO on day 1, then 100–200 mg PO daily |
| Cutaneous | If mild, topical treatment<br>• Imidazoles (e.g. ketoconazole 2% cream) or other topicals (e.g. ciclopirox cream) twice daily for 2 weeks or until resolved<br>If moderate to severe *OR* fails to respond to topical **Rx**<br>• Fluconazole 50–100 mg daily for 14 days *OR*<br>• Fluconazole 150 mg PO weekly for 2–4 weeks<br>*Chronic mucocutaneous candidiasis*<br>• Fluconazole 400–800 mg PO daily for 4–6 months<br>• May require lifelong suppressive treatment with fluconazole 200 mg PO daily |

**Table 64.5 Treatment of mucocutaneous candidiasis.**

beneath a pannus; Fig. 64.15), on the scrotum, or in the diaper area of infants (see Fig. 13.4)
  - Predisposing factors for cutaneous infection – similar to oral candidiasis plus hyperhidrosis with occlusion
- **DDx** of candidal intertrigo: see Chapter 13.
- **Rx:** outlined in Table 64.5.
- **Rx** of candidal intertrigo or balanitis: outlined in Table 60.5.

### Perianal Pseudoverrucous Papules (Granuloma Gluteale Infantum)

- Etiology is multifactorial, including moist occlusion, irritation from urine and stool, and candidal infection.
- Seen primarily in infants but also in older individuals with urinary and fecal incontinence.
- Erythematous papules and nodules, as well as erosions, develop in the anogenital region.
- When the lesions become erosive, some clinicians use the term Jacquet diaper dermatitis or erosive papulonodular dermatosis.
- **DDx:** outlined in Fig. 13.4.

### Congenital Candidiasis

Congenital candidiasis is discussed in Chapter 28.

### Systemic Candidiasis

- Generally affects immunosuppressed hosts in the setting of neutropenia.
- Clinical features are outlined in Table 64.6.
- Although the skin lesions represent septic emboli, blood cultures may be negative; as a result, skin biopsy for tissue culture and histology can play a critical role.

## Deep Fungal Infections

Deep mycoses are treated with oral or intravenous antifungal medications, often for an extended period of time (e.g. 6 months). Culture results direct therapy, but initial empiric treatment is often started based on the clinical presentation plus histologic findings (e.g. itraconazole 200–400 mg/day for chromo(blasto)mycosis).

### Dermal/Subcutaneous

#### CHROMO(BLASTO)MYCOSIS

- Commonly due to several species of dematiaceous fungi – *Fonsecaea pedrosoi*, *F. compacta*, *F. monophora*, *Phialophora verrucosa*, *Cladophialophora carrionii*, and *Rhinocladiella aquaspersa* – that are found in soil and decaying wood.
- Follows trauma and implantation of the fungus into the skin.

| CUTANEOUS FEATURES OF COMMON OPPORTUNISTIC MYCOSES | |
|---|---|
| **Mycosis** | **Common cutaneous presentations** |
| Systemic candidiasis*<br>• *Candida albicans*<br>• *C. tropicalis* (frequent skin lesions)<br>• Other *Candida* spp. (e.g. *C. glabrata*, *C. auris*) | • Firm erythematous papules and nodules, often with a pale center<br>• Lesions can be hemorrhagic, especially in the setting of thrombocytopenia<br>• Ecthyma gangrenosum-like lesions<br>• Occasionally, the lesions are nonspecific, i.e. purpuric macules |
| Aspergillosis*<br>• *Aspergillus flavus*<br>• *A. fumigatus*<br>Serum assays to screen high-risk patients<br>• Galactomannan (more specific, lower sensitivity)<br>• 1,3-D-glucan (less specificity) | • Primary cutaneous<br>– Necrotic papulonodules<br>– May be associated with an intravenous catheter site, burns, trauma, or surgical wounds<br>• Secondary cutaneous (septic emboli from disseminated infection)<br>– Necrotic papulonodules and ecthyma gangrenosum-like lesions<br>– Associated with the final stages of AIDS |
| Zygomycosis*<br>• *Mucor*<br>• *Rhizopus*<br>• *Absidia* | • Ecthyma gangrenosum-like lesions, cellulitis, facial edema (commonly unilateral due to contiguous spread of sino-orbital disease), necrotic papulonodules, plaques, large hemorrhagic crusts on the face<br>• May be associated with an intravenous catheter site (primary cutaneous)<br>• Also associated with poorly controlled diabetes mellitus |
| Cryptococcosis†<br>• *Cryptococcus neoformans* | • Molluscum contagiosum-like lesions, ulceration, cellulitis |
| Phaeohyphomycosis*,†<br>• *Alternaria*<br>• *Exophiala*<br>• *Phialophora* | • Subcutaneous cysts, ulcerated plaques, necrotic papulonodules |
| Hyalohyphomycosis*,‡<br>• *Fusarium*<br>• *Talaromyces*<br>• *Paecilomyces* | • Umbilicated or necrotic papules, pustules, abscesses, cellulitis, subcutaneous nodules<br>• *Fusarium* infection can begin with a periungual focus |
| Trichosporonosis (e.g. *Trichosporon* spp.) | • Papulovesicles, purpuric papules, necrotic papulonodules |

*With the use of prophylactic voriconazole, posaconazole, and isavuconazole in high-risk oncology patients (e.g. neutropenic patients with hematologic malignancies), the incidence of disseminated candidiasis, systemic aspergillosis, and mucormycosis (psoaconazole and isavuconazole) have declined in these individuals.
†Especially in the setting of AIDS; also histoplasmosis, coccidioidomycosis, penicilliosis, and sporotrichosis.
‡Less common infections.

**Table 64.6 Cutaneous features of common opportunistic mycoses.**

• Expanding, verrucous plaque, usually on an extremity (Fig. 64.16); central scarring can occur.
• More common in tropical and subtropical regions.
• Diagnostic histologic finding – round, pigmented bodies with internal septations that are said to resemble copper pennies, also referred to as sclerotic bodies or Medlar bodies.

### MYCETOMA (MADURA FOOT)

• Two major subtypes: (1) actinomycotic mycetoma – secondary to filamentous bacteria, especially *Nocardia* and *Actinomyces* (see Ch. 61); and (2) eumycotic mycetoma – caused by true fungi, e.g. *Madurella mycetomatis*, *Pseudallescheria boydii*.
• Contracted from trauma and implantation of fungus into the skin (Fig. 64.17A).
• Most common site is the distal lower extremity but can also be seen in other sites, such as the distal upper extremity, trunk, and scalp.
• Clinical triad of draining sinuses, grains (macroscopic colonies of organisms; see Ch. 61), and edema (Fig. 64.18). Grains can also




**Fig. 64.16 Chromo(blasto)mycosis.** Annular and figurate plaques due to central clearing and scarring with a verrucous surface on the arm **(A)** and a more granulomatous appearance on the leg **(B)**. *Courtesy, USCDRSC.*

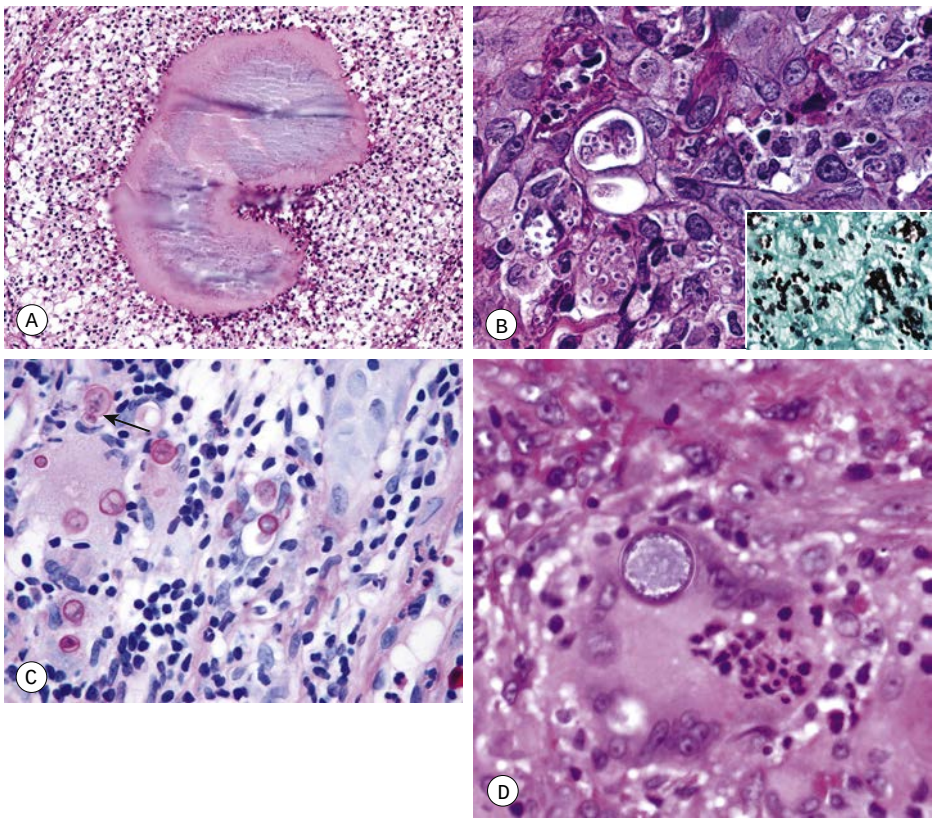


**Fig. 64.17 Histologic features of selected deep fungal infections. A** Eumycetoma with formation of a grain, which represents tightly packed colonies of fungal organisms. **B** Histoplasmosis – *Histoplasma capsulatum* yeast forms are present within macrophages and giant cells, highlighted with a methenamine silver stain (inset). **C** Blastomycosis – budding yeast forms in the dermis, several of which are within a giant cell (PAS stain). Note the single, broad-based budding (arrow). **D** Coccidioidomycosis – an endospore-containing spherule within a giant cell. *A, Courtesy, Lorenzo Cerroni, MD; B, Courtesy, C. Massone, MD; C, Courtesy, Mary Stone, MD; D, Courtesy, Jennifer McNiff, MD.*



**Fig. 64.18 Mycetoma (Madura foot).** Note the soft tissue swelling of the foot as well as multiple nodules with pustular discharge. *Courtesy, USCDRSC.*

| INFECTIOUS CAUSES OF A LYMPHOCUTANEOUS ("SPOROTRICHOID") PATTERN |
|---|
| Most common<br>• Atypical mycobacteria, especially *Mycobacterium marinum*, but also other species (e.g. *M. chelonae*, *M. kansasii*)<br>• Sporotrichosis |
| Unusual<br>• Nocardiosis<br>• Pyogenic bacteria (e.g. *Staphylococcus aureus*, *Streptococcus pyogenes*)<br>• *Pseudallescheria boydii* |
| Rare (in high-income countries)<br>• Leishmaniasis<br>• Tularemia*<br>• Tuberculosis*<br>• Dimorphic fungi (other than *Sporothrix schenckii*)<br>• Opportunistic fungi in immunocompromised hosts (e.g. *Fusarium*, *Alternaria* spp.)<br>• Glanders (*Burkholderia mallei*)*<br>• Cat scratch disease*<br>• Anthrax<br>• Cowpox<br>• *Acanthamoeba* spp. |
| **Often ulceroglandular.* |

**Table 64.7 Infectious causes of a lymphocutaneous ("sporotrichoid") pattern.** There are also noninfectious causes, such as lymphoma, Langerhans cell histiocytosis, and in-transit metastases. In addition, perineural spread of leprosy can mimic a lymphocutaneous pattern.

be seen in botryomycosis and actinomycosis (see Ch. 61).

• **Rx:** excision of more localized lesions; for larger areas of involvement as well as pre- and postoperatively, long-term course (i.e. 6 months or longer) of oral antifungal medication (e.g. itraconazole 400 mg PO daily × 3 months followed by 200 mg PO daily for 9 months).

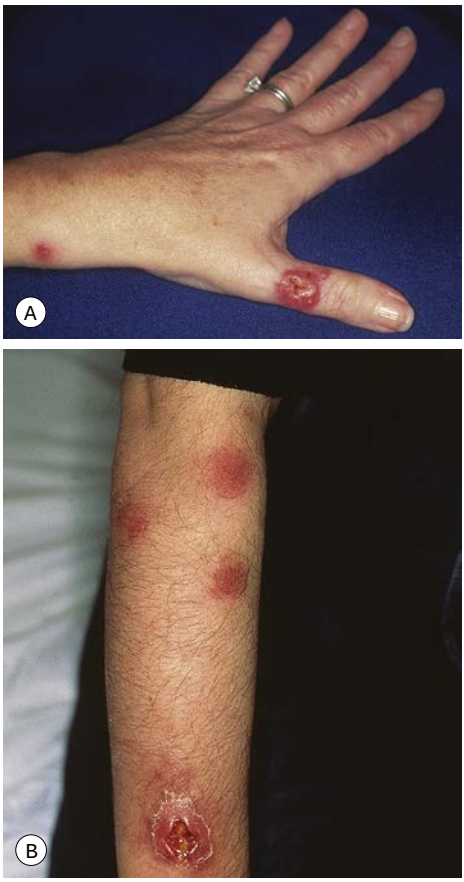


**Fig. 64.19 Lymphocutaneous (sporotrichoid) pattern. A** An eroded nodule on the thumb, representing the primary lesion, with a secondary lesion along the lymphatics due to sporotrichosis. **B** Ulcerated nodule on the extensor forearm with multiple more proximal nodules due to nocardiosis in a patient with lymphoma who was receiving systemic CS. *A, Courtesy, YDRSC; B, Courtesy, Jean L. Bolognia, MD.*

### SPOROTRICHOSIS

• Secondary to organisms of the genus *Sporothrix* (e.g. *Sporothrix schenkii*), which are dimorphic, i.e. a yeast at 37°C (human body) and a mold at 25°C (soil).

• Worldwide distribution; present in soil and sphagnum moss.

• Most common presentation is a lymphocutaneous or "sporotrichoid" pattern (~75% of patients) that initially presents as a papule or nodule at the site of inoculation; this is followed by the appearance of papulonodules along the draining lymphatics (Fig. 64.19; Table 64.7).

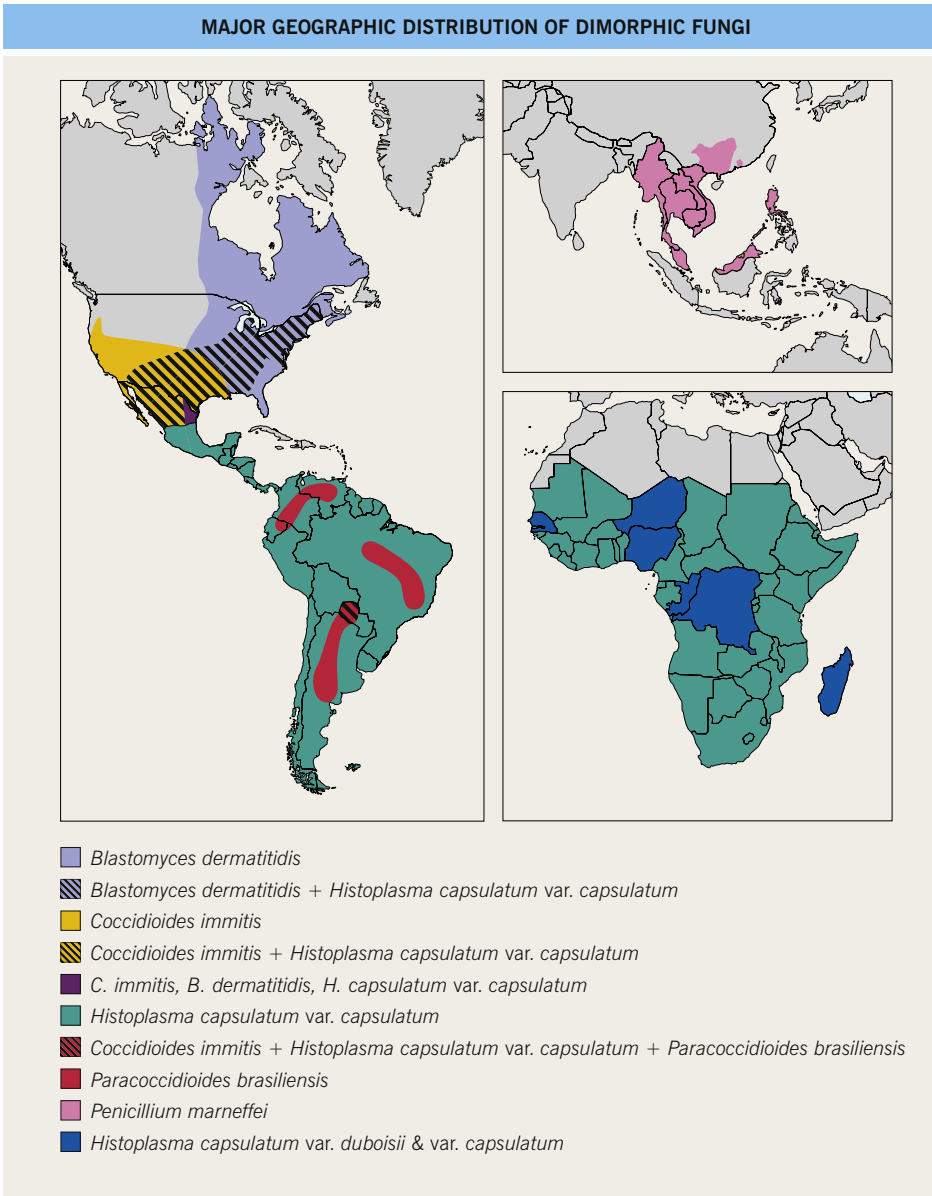


**Fig. 64.20 Major geographic distribution of dimorphic fungi.** *Histoplasma capsulatum* var. *capsulatum* is also endemic along river basins in some areas of India, Southeast Asia, and Australia. *Courtesy, Braden A. Perry, MD.*

- Less common variants: (1) a fixed, ulcerated plaque on the face in someone with prior exposure, a form prevalent in Brazil due to transmission by infected cats; and (2) cutaneous dissemination (e.g. papulonodules) from a systemic infection.

## Systemic (Unless Primary Inoculation into Skin)

### BLASTOMYCOSIS

- Due to *Blastomyces dermatitidis*, a dimorphic fungus; yeast form displays broad-based budding (see Fig. 64.17C).




**Fig. 64.21 Blastomycosis. A** Facial plaque with scale-crust and a border with a granulomatous appearance. **B** Well-demarcated plaques with erosions, central scarring, and black crusting. *A, Courtesy, Louis A. Fragola, Jr., MD; B, Courtesy, Paul Lucky, MD.*




**Fig. 64.22 Coccidioidomycosis.** Moist erythematous plaque on the face **(A)** and multiple papules and suppurative nodules on the arm **(B)** in two patients living in the southwestern United States. *Courtesy, USCDRSC.*

• Endemic to the southeastern United States and other areas of North America (Fig. 64.20).
• Contracted via inhalation, with the skin, bones, and genitourinary tract being the most common sites of secondary infection.
• Cutaneous lesions can vary from papulopustules to verrucous plaques with crusted borders (Fig. 64.21).

### COCCIDIOIDOMYCOSIS

• Due to *Coccidioides immitis*, a dimorphic fungus that forms arthrospores in the soil and spherules within the skin (see Fig. 64.17D).
• Endemic to the southwestern United States (see Fig. 64.20).
• Contracted via inhalation, with disseminated disease more common in African-Americans, Mexicans, and immunocompromised hosts.
• Cutaneous manifestations: lesions vary from papules to pustules, abscesses, and plaques with sinus tracts (Fig. 64.22).
• Non-infectious hypersensitivity reactions include toxic erythema, erythema multiforme, and erythema nodosum.
• Molluscum contagiosum-like lesions may be seen in HIV-infected persons.



**Fig. 64.23 Histoplasmosis.** Papules and nodules with scale-crust in a patient with AIDS. *Courtesy, USCDRSC.*

### CRYPTOCOCCOSIS

- Molluscum contagiosum-like lesions may be seen in HIV-infected patients and other immunocompromised hosts (see Fig. 64.25G), in addition to ulcers and cellulitis (see Fig. 64.25F).

### HISTOPLASMOSIS

- Due to *Histoplasma capsulatum* var. *capsulatum*, a dimorphic fungus (see Fig. 64.17B).
- Endemic to the southeastern and central United States and many other countries with reservoirs in birds, including fowl, and bats (see Fig. 64.20).
- Disease contracted through inhalation or, rarely, implantation.
- Immunocompetent hosts: oral ulcers in up to 75% of patients; occasionally cutaneous papulonodules.
- Immunosuppressed hosts: oral ulcers and multiple papules or plaques (Fig. 64.23), including ones that resemble molluscum contagiosum.

### PARACOCCIDIOIDOMYCOSIS

- Due to *Paracoccidioides brasiliensis*, a dimorphic fungus that displays multiple narrow-based buds in tissue, including the skin.
- Endemic to South America.
- Disease contracted via inhalation, with dissemination primarily to lymph nodes > oropharynx > adrenal glands > spleen and gastrointestinal tract, in addition to the skin.
- Cutaneous lesions are primarily perioorificial and associated with involvement of the oral mucosa; verrucous and ulcerative plaques are seen (Fig. 64.24).




**Fig. 64.24 Paracoccidioidomycosis.** Ulcerated plaques on the palate (**A**) and verrucous granulomatous red-brown plaques with crusting involving the perioral region and upper lip (**B**). *Courtesy, Marcia Ramos-e-Silva, MD, PhD.*

### OPPORTUNISTIC PATHOGENS

See Table 64.6 and Fig. 64.25.

For further information see Ch. 77 from *Dermatology, Fourth Edition*.

**For additional online figures and tables visit www.expertconsult.com**




**Fig. 64.25 Clinical findings of opportunistic fungal infections in immunocompromised hosts.** Primary cutaneous aspergillosis characterized by hyperpigmented plaques with brown-black scale-crusts at the site of intravenous catheters on the arm (**A**); firm pink papulonodule due to disseminated candidiasis (**B**); erythematous papulonodules with central purpura, vesiculation and/or crusting in a leukemic patient with disseminated fusariosis (**C**); necrotic hemorrhagic bulla due to embolus of *Aspergillus flavus* (**D**); cellulitis with large areas of necrosis due to *Rhizopus* (**E**) and *Cryptococcus neoformans* (**F**). *Continued*




**Fig. 64.25** *Continued* **Clinical findings of opportunistic fungal infections in immunocompromised hosts.** Disseminated cryptococcosis presenting with lesion(s) resembling molluscum contagiosum (**G**); and a basal cell carcinoma (**H**); cryptococcal cellulitis (**I**); numerous papules and nodules with central umbilication and crusting in disseminated *Talaromyces (Penicillium) marneffei* infection (**J**). *A, B, D, E, Courtesy, YDRSC; C, F–I, Courtesy, Boni E. Elewski, MD and Roderick J. Hay, MD; J, Courtesy, Evangeline Handog, MD and the Dermatology Department, Research Institute for Tropical Medicine.*

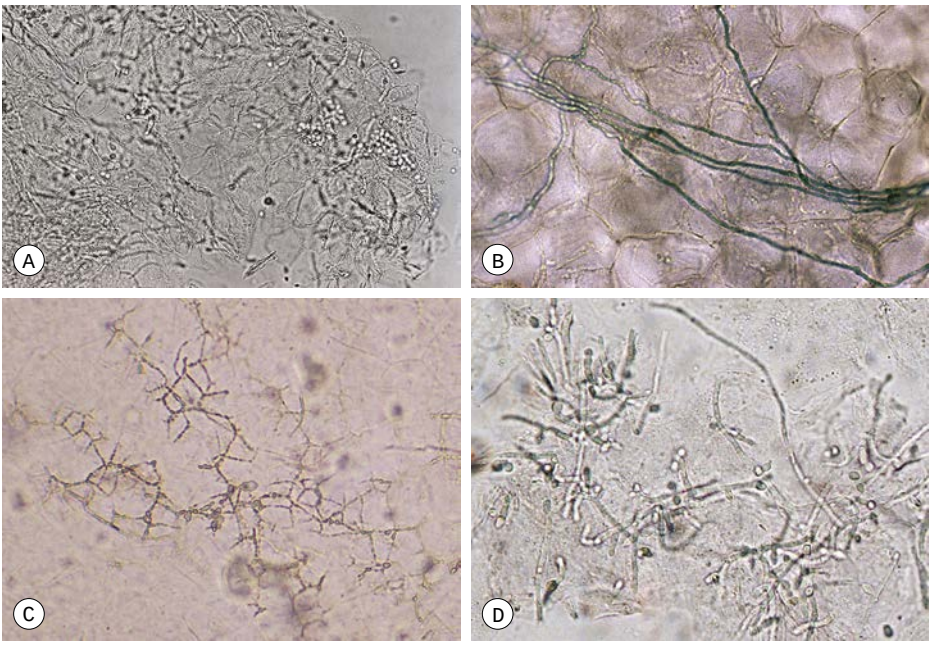


**eFig. 64.1 Potassium hydroxide preparations.** **A** Superficial skin scrapings from tinea (pityriasis) versicolor demonstrating clusters of yeast and short mycelial forms. **B** A dermatophyte, in this case *Trichophyton tonsurans*, demonstrating branching hyphae (chlorazol black stain). Note that the hyphae cross multiple squamous cells. **C** "Mosaic" pattern of cell walls that should not be misinterpreted as hyphae. **D** Yeast and pseudohyphae of candidiasis. *A, Courtesy, Ronald P. Rapini, MD; B, Courtesy, YDRSC; C, Courtesy, Louis A. Fragola, Jr, MD; D, Courtesy, Frank Samarin, MD.*



**eFig. 64.2 Tinea manuum.** Diffuse scaling of the palm of one hand, with accentuation in the creases. *Courtesy, YDRSC.*

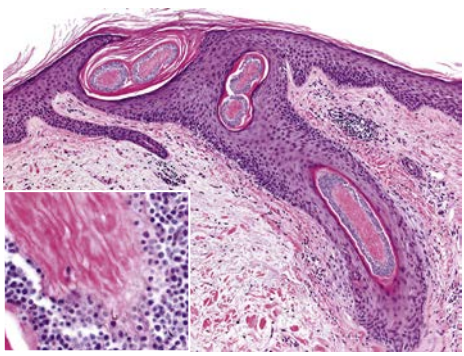

**eFig. 64.3 Tinea capitis.** Histologic examination shows arthroconidia and hyphae within hair shafts to the level of Adamson's fringe (limit of the zone of keratinization; inset). *Courtesy, Lorenzo Cerroni, MD.*



**eFig. 64.4 Tinea pedis.** Extension of tinea pedis onto the dorsal foot in a serpiginous configuration of erythema and papules. Scale is minimal due to the patient's use of a potent topical corticosteroid for presumed dermatitis.
*Courtesy, Julie V. Schaffer, MD.*



**eFig. 64.5 Extensive tinea corporis emanating from tinea manuum and tinea pedis.** Note the confluent involvement, serpiginous scaly borders, and associated tinea unguium of the toenails and one fingernail.

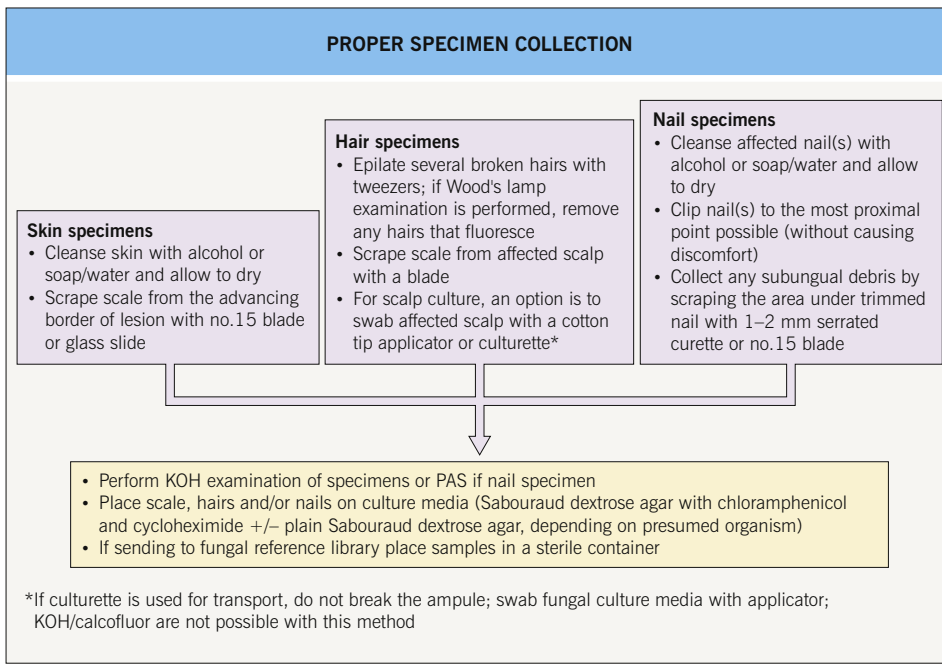


**eFig. 64.6 Proper specimen collection.** Proper collection of skin, hair, and nails is important. Following these simple guidelines will help the clinician to achieve the most accurate diagnosis.
*Courtesy, Judy Warner.*



**eFig. 64.7 Granuloma gluteale infantum.** Coalescing moist, pink papules on the vulva and suprapubic area of an infant. *Courtesy, Julie V. Schaffer, MD.*



**eFig. 64.8 Histoplasmosis.** Disseminated papules and nodules with scale-crust in a patient with AIDS. *Courtesy, USCDRSC.*

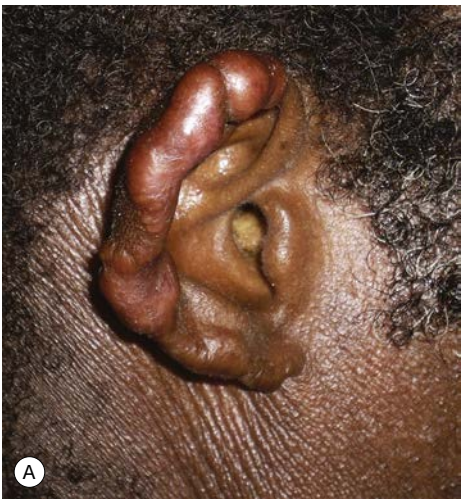





**eFig. 64.9 Lobomycosis. A, B** Multinodular pinkish-brown plaques with a keloid-like appearance on the helix and back. *Courtesy, Regina Carneiro, MD and Caroline Brandao, MD.*



**eFig. 64.10 Phaeohyphomycosis.** Purpuric plaque with central necrosis and surrounding erythema in a patient with subcutaneous phaeohyphomycosis due to *Exserohilum rostratum*.

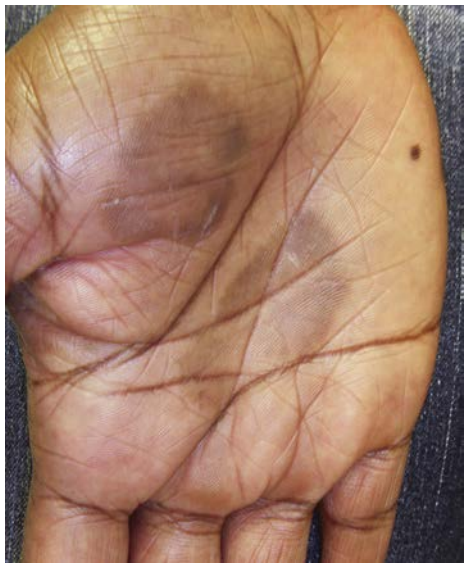

**eFig. 64.11 Tinea nigra.** Two sharply demarcated brown macules on the palm.



**eFig. 64.13 Tinea corporis.** Almost confluent involvement on the neck with well-demarcated, scaly borders.



**eFig. 64.12 Tinea corporis.** Large, expanding area with multiple annular and serpiginous lesions. *Courtesy, Antonio Torrelo, MD.*



**eFig. 64.14 Nodular perifolliculitis (Majocchi granuloma).** Perifollicular inflammation and pustules on the arm due to *Trichophyton rubrum*.



**eFig. 64.15 Tinea cruris and corporis.** *Courtesy, Kalman Watsky, MD.*



**eFig. 64.16 Tinea faciei.** Annular and arcuate plaques on the cheek and around the mouth of a child. *Courtesy, Antonio Torrelo, MD.*



**eFig. 64.17 Tinea faciei.** Large annular plaque with pustules in a young child. *Courtesy, Antonio Torrelo, MD.*



**eFig. 64.18 Tinea capitis due to *Trichophyton tonsurans* resembling seborrheic dermatitis.** *Courtesy, Julie V. Schaffer, MD.*



**eFig. 64.19 Tinea unguium.** Distal/lateral subungual variant.



**eFig. 64.20 Tinea unguium.** White proximal subungual variant.



**eFig. 64.21 Tinea unguium.** Striate form of superficial white variant.



**eFig. 64.22 Tinea unguium and nodular perifolliculitis in an immunosuppressed patient.**



**eFig. 64.24 Disseminated cryptococcosis presenting as purpuric papules.**

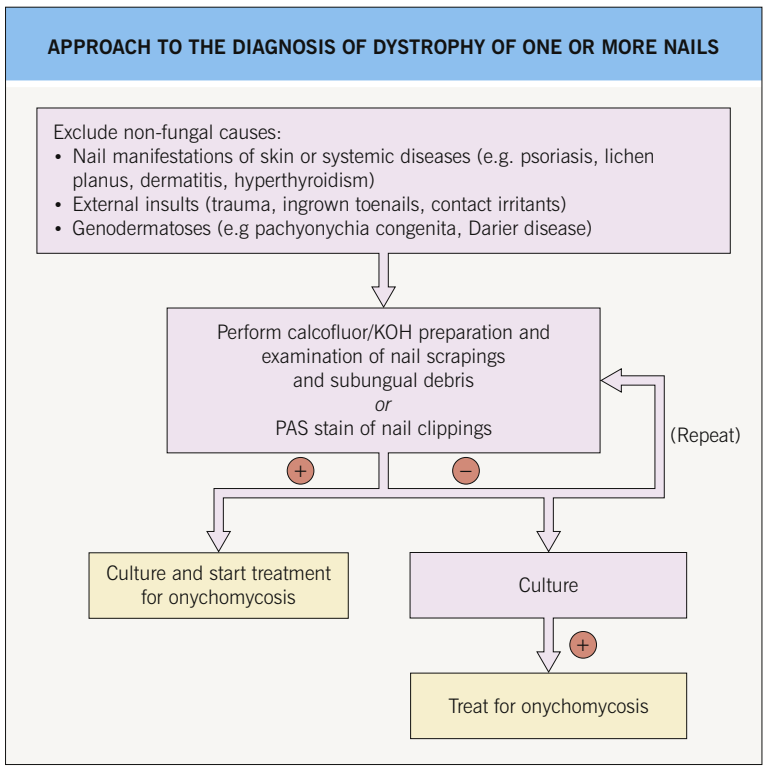


**eFig. 64.23 Approach to the diagnosis of dystrophy of one or more nails.** An organized approach is essential in correctly and efficiently diagnosing onychomycosis.



**eFig. 64.25 Erosive cryptococcal cellulitis.**



**eFig. 64.26 Disseminated *Talaromyces (Penicillium) marneffei* infection.** The papules and nodules exhibit central umbilication and crusting. *Courtesy, Evangeline Handog, MD and the Dermatology Department, Research Institute for Tropical Medicine.*



**eFig. 64.27 Mycetoma.** *Courtesy, Regional Training Center.*

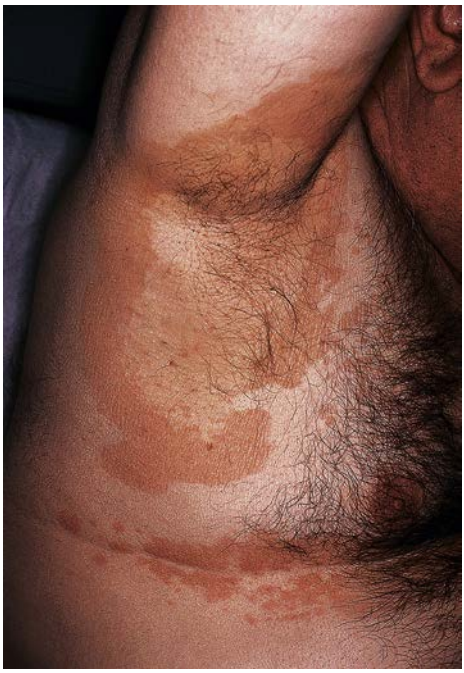

**eFig. 64.28 Tinea (pityriasis) versicolor.** Hyperpigmented variant. *Courtesy, Kalman Watsky, MD.*



**eFig. 64.29 Tinea corporis.** Extensive figurate lesions on the neck and upper chest. *Courtesy, Kalman Watsky, MD.*



**eFig. 64.30 Tinea corporis.** Tinea "incognito" due to use of topical corticosteroids. *Courtesy, Julie V. Schaffer, MD.*

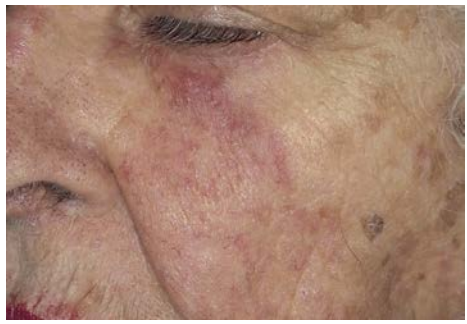

**eFig. 64.31 Tinea faciei.** Serpiginous lesion with minimal scale on the upper cheek of an older woman. *Courtesy, Jean L. Bolognia, MD.*



**eFig. 64.32 Majocchi granuloma.** Perifollicular inflammation and pustules on the buttocks due to *Trichophyton rubrum*. *Courtesy, YDRSC.*



**eFig. 64.33 Tinea unguium.** Onycholysis, yellowing, crumbling, and thickening of the toenails in the distal/lateral subungual variant. *Courtesy, Jean L. Bolognia, MD.*



**eFig. 64.34 Clinical findings of opportunistic fungal infections in immunocompromised hosts.** Necrotic hemorrhagic bulla due to embolus of *Aspergillus flavus*. *Courtesy, Julie V. Schaffer, MD.*



**eFig. 64.36 Opportunistic fungal infection in an immunocompromised host.** Crusted molluscum contagiosum-like lesions due to disseminated cryptococcosis**.** *Courtesy, Athanasia Syrengelas, MD, PhD.*



**eFig. 64.35 Opportunistic fungal infection in an immunocompromised host.** Cellulitis with areas of necrosis due to *Cryptococcus neoformans*. *Courtesy, Kalman Watsky, MD.*

| INDICATORS OF MORE SEVERE ONYCHOMYCOSIS WITH A POOR RESPONSE TO TREATMENT | |
|---|---|
| Nail factors | • Subungual hyperkeratosis >2 mm thick*<br>• Significant lateral involvement<br>• Dermatophytoma†<br>• >50% involvement of nail bed<br>• Slow nail growth rate<br>• Total dystrophic onychomycosis<br>• Matrix involvement |
| Patient factors | • Immunosuppression<br>• Peripheral arterial disease<br>• Poorly controlled diabetes mellitus |

**Measurement of nail plate plus nail bed.*
*†Streak or patch representing a subungual pocket of densely packed hyphae; removal prior to initiating antifungal therapy can be helpful.*

**eTable 64.1 Indicators of more severe onychomycosis with a poor response to treatment.** *Adapted from Carney C, Tosti A, Daniel R, et al. A new classification system for grading the severity of onychomycosis: Onychomycosis Severity Index. Arch Dermatol 2011;147:1277–82.*

# Cutaneous Manifestations of HIV Infection

# 65

There are a number of cutaneous disorders that point to the diagnosis of HIV infection. For some, it is the mere presence of the skin disease, whereas for others, the disease is extensive or proves recalcitrant to therapy (Table 65.1; Figs 65.1–65.14). As HIV infection is associated with immunosuppression, the clinical presentation of various infectious diseases is often reminiscent of that observed in individuals whose immunocompromised state is due to medications (e.g. CS plus chemotherapy) or underlying diseases (e.g. acute leukemia).

In HIV-infected patients, several cutaneous diseases (e.g. disseminated coccidioidomycosis, Kaposi sarcoma) are AIDS-defining conditions (see who.int/hiv/pub/guidelines/HIVstaging150307.pdf), whereas others such as oral hairy leukoplakia and seborrheic dermatitis can serve as early clues to the infection, i.e. when there are >400 $CD4^+$ cells/$mm^3$.

## Epidemiology

- With the advent of antiretroviral therapy (ART), HIV infection/AIDS has become a chronic disease.
- High-risk groups still include commercial sex workers, men who have sex with men (MSM), and intravenous drug users, but heterosexual transmission has become a significant mode of transmission.
- Approximately 70% of individuals living with HIV infection are in sub-Saharan Africa.

## Exanthem of Primary HIV Infection (Acute Retroviral Syndrome)

- Follows an incubation period of 3–6 weeks, but the latter may be shorter if infection acquired hematogenously.
- Morbilliform eruption (40–80% of patients) appears in the setting of peak viremia; accompanied by orogenital ulcerations (5–20%)



**Fig. 65.1 Severe psoriasis in a patient with AIDS.** Both sudden acute exacerbations and treatment resistance can be observed.



**Fig. 65.2 Eosinophilic folliculitis.** Due to associated pruritus, follicular papules are often excoriated; lesions favor the head and upper trunk. *Courtesy, Clay J. Cockerell, MD.*

| MUCOCUTANEOUS DISORDERS ASSOCIATED WITH HIV INFECTION |
|---|
| **Inflammatory disorders** |
| **When severe, recalcitrant, or of sudden onset, consider HIV infection** |
| • Seborrheic dermatitis (e.g. face, scalp) |
| • Psoriasis vulgaris (Fig. 65.1) |
| • Reactive arthritis (previously referred to as Reiter disease) |
| **Alone raises the possibility of HIV infection** |
| • Eosinophilic folliculitis (Fig. 65.2; Ch. 31)* |
| • Pityriasis rubra pilaris type VI, with follicular spines & acne conglobata |
| **Infectious diseases and infestations*** |
| **When severe and/or recalcitrant, consider HIV infection** |
| • Human papilloma virus infections (warts), including acquired epidermodysplasia verruciformis-like lesions (Ch. 66) |
| • Molluscum contagiosum, numerous, coalescent, and/or giant-sized, especially in adults (Fig. 65.3) |
| • Dermatophyte infections (Ch. 64) |
| **Alone raises the possibility of HIV infection** |
| • Syphilis (Fig. 65.4) and other sexually transmitted infections (e.g. chancroid; Ch. 69) |
| • Bacillary angiomatosis (Fig. 65.5) |
| • Botryomycosis ("grains" within the dermis composed of *Staphylococcus*, *Pseudomonas*) |
| • Disseminated mycobacterial infections (tuberculous and nontuberculous; Fig. 65.6) |
| • Chronic oral and anogenital herpes simplex (Fig. 65.7) or disseminated HSV |
| • Herpes zoster, especially if multi-dermatomal, disseminated, verrucous or chronic, but can have classic presentation (see Fig. 67.11A) |
| • Oral hairy leukoplakia due to EBV infection (Fig. 65.8) |
| • Anogenital and oral ulcers, verrucous plaques or morbilliform eruption due to CMV (Ch. 67) |
| • Kaposi sarcoma due to HHV-8 infection (Fig. 65.9; Chs 67 and 94) |
| • Oropharyngeal candidiasis (thrush; Fig. 65.10; Ch. 64) |
| • Proximal subungual onychomycosis |
| • Disseminated cryptococcosis (Fig. 65.11; Ch. 64) |
| • Disseminated dimorphic fungal infections (e.g. coccidioidomycosis, histoplasmosis, penicilliosis) |
| • Crusted scabies (Norwegian scabies; Fig. 65.12) |
| • Disseminated or necrotic cutaneous leishmaniasis |
| **Other** |
| • Papular pruritic eruption of HIV (Fig. 65.13) |
| • Xerosis and acquired ichthyosis |
| • Major aphthae (Fig. 65.14); acute necrotizing ulcerative stomatitis with gingivitis or periodontitis |
| • Porphyria cutanea tarda, often in association with hepatitis C |
| • Facial hyperpigmentation, idiopathic or due to photolichenoid drug eruption |
| • Linear telangiectasias of the chest |
| • Trichomegaly of the eyelashes and change in texture of scalp hair (e.g. curly -> fine and straight) |
| • *Demodex* folliculitis |
| • Cutaneous lesions of non-Hodgkin lymphoma |
| • Anal intraepithelial neoplasia/anal carcinoma |
| • Acral persistent papular mucinosis; atypical variants of granuloma annulare |
| **In particular when there is no known cause of immunosuppression.* |

**Table 65.1 Mucocutaneous disorders associated with HIV infection.**



**Fig. 65.3 Molluscum contagiosum in the setting of HIV infection.** Large lesions due to coalescence of individual papules. The face is a common location.



**Fig. 65.4 Secondary syphilis presenting as lues maligna.** This HIV-positive man had a fever, headache, arthralgias, and myalgias together with this widespread eruption of pustules and crusted papulonodules. *Courtesy, Singapore National Skin Centre.*



**Fig. 65.5 Bacillary angiomatosis.** Lesions can resemble vascular tumors or pyogenic granulomas and are a reflection of infection with *Bartonella henselae* or *B. quintana*. *Courtesy, NYUDSC.*



**Fig. 65.6 *Mycobacterium haemophilum* infection.** This HIV-positive man with a $CD4^+$ T-cell count of 350/$mm^3$ presented with a 4-month history of slowly enlarging, thick plaques on his extremities. The lesions resolved over six months with antimicrobial therapy that included ciprofloxacin, clarithromycin, and ethambutol. *Courtesy, Singapore National Skin Centre.*

as well as fever, fatigue, headache, pharyngitis, arthralgia, myalgia, lymphadenopathy, night sweats and a decrease in circulating $CD4^+$ T cells.

- While the cutaneous eruption usually lasts 4–5 days, the constitutional symptoms can last from a few days to a few months.
- **Dx:** detection of viral RNA by PCR and/or p24 antigen in the plasma; assays for anti-HIV-1 antibodies are less reliable as they may be negative, especially early on in the course of the disease.

## Immune Reconstitution Inflammatory Syndrome (IRIS)

- Those disorders that can "flare" or "worsen" due to an increase in the ability to mount an inflammatory response following the institution of ART are outlined in Table 65.2 (Fig. 65.15).



**Fig. 65.7 Chronic ulcerative herpes simplex viral infection in an HIV-infected patient.** These slowly enlarging ulcers of the buttocks and perianal area have a characteristic scalloped border. *Courtesy, YDRSC.*



**Fig. 65.8 Oral hairy leukoplakia.** Shaggy white keratotic plaques along the lateral aspect of the tongue. A corrugated pattern is often seen. *Courtesy, Charles Camisa, MD.*



**Fig. 65.10 Both oral candidiasis and oral herpes viral infection involving the tongue.** The white plaques represent the former, whereas the circular and scalloped areas of detached epithelium represent the latter. Either of these infections, and especially their combination, points to immunosuppression and the possibility of HIV infection.

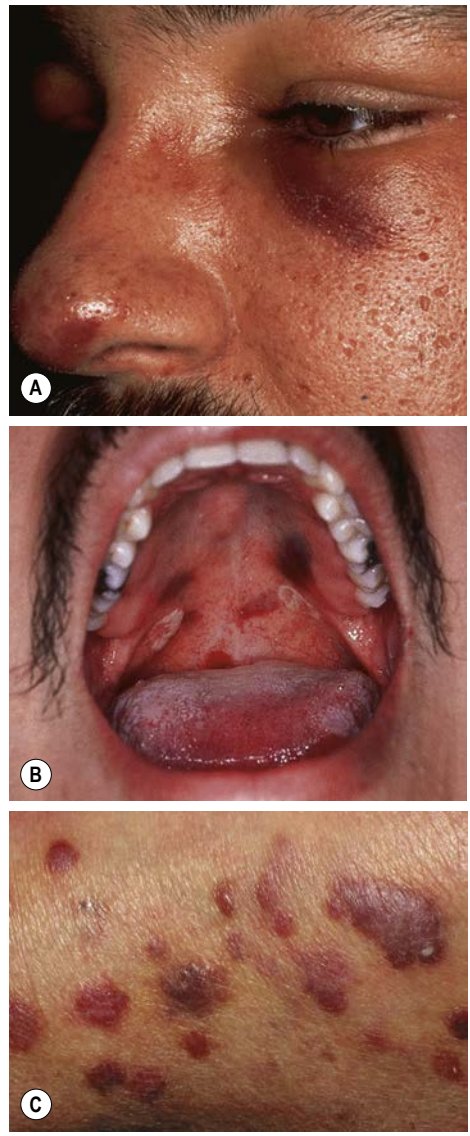


**Fig. 65.9 Kaposi sarcoma in the setting of AIDS.** Violaceous papules and plaques involving the face **(A),** palate **(B),** and an extremity **(C).** The patient also has oral candidiasis. *A, B, Courtesy, YDRSC; C, Courtesy, Thomas Horn, MD.*

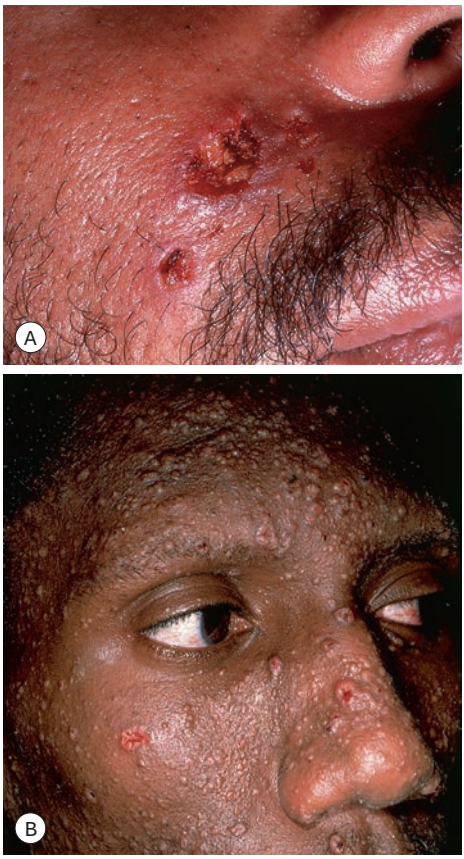


**Fig. 65.11 Disseminated cryptococcosis in the setting of AIDS. A** Several ulcers with rolled borders. **B** Numerous molloscum contagiosum-like lesions. Microscopic examination and culture of either dermal scrapings or a biopsy specimen confirm the diagnosis. *A, Courtesy, YDRSC; B, Courtesy, NYUDSC.*

- It is noteworthy that depending on the patient, some of these disorders improve rather than "worsen" in the setting of ART, e.g. Kaposi sarcoma.

## Antiretroviral Therapy (ART)

- Recommended for all HIV-infected individuals, irrespective of CD4 count.
- For naive patients, first-line therapy consists of *dual* NRTIs (nucleoside reverse transcriptase inhibitors) plus an integrase inhibitor while second-line therapy consists of *dual* NRTIs plus either an NNRTI (non-nucleoside reverse transcriptase inhibitor) or a ritonavir-boosted protease inhibitor. In low- and middle-income countries, the first-line regimen can consist of *dual* NRTIs plus an NNRTI.
- Table 65.3 (Figs 65.16 and 65.17) outlines the mucocutaneous side effects of these antiretroviral drugs (Fig. 65.18); such reactions can lead to the discontinuation of the incriminated medication.
- When taken daily, pre-exposure prophylaxis (PrEP) reduces the risk of contracting HIV infection, e.g. a >90% reduction if due to sexual exposure. However, reduced use of condoms leads to an increase in sexually transmitted infections.

For further information see Ch. 78 from *Dermatology, Fourth Edition*.

**For additional online figures and tables visit www.expertconsult.com**



**Fig. 65.12 Crusted scabies in the setting of HIV infection.** Crusted scabies is often misdiagnosed as dermatitis, but these scale-crusts are teeming with mites. This form of the disease was previously referred to as Norwegian scabies. *Courtesy, YDRSC.*



**Fig. 65.13 HIV-associated pruritic papular eruption.** This eruption is characterized by extremely pruritic erythematous papules and a predilection for the extremities. It is thought to represent a hypersensitivity reaction to arthropod antigens. *Courtesy, Singapore National Skin Centre.*



**Fig. 65.14 Major aphthae in a patient with AIDS.** Resolution of these oral ulcers may require thalidomide. *Courtesy, YDRSC.*



**Fig. 65.15 Exacerbation of leprosy due to immune reconstitution inflammatory syndrome (IRIS) following institution of ART.** *Courtesy, Beatriz Trope, MD, PhD.*



**Fig. 65.16 HIV/ART-associated lipodystrophy.** Marked indentation of the medial cheeks due to lipoatrophy is a characteristic finding, as is a decrease in subcutaneous fat of the extremities and an increase in abdominal fat (central obesity). *Courtesy, Priya Sen, MD.*

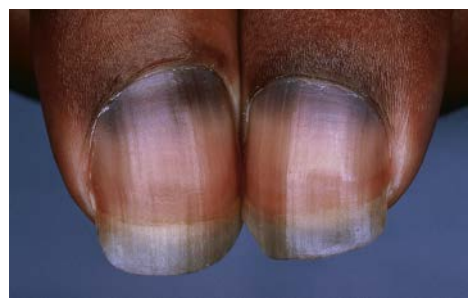

**Fig. 65.17 Zidovudine-associated melanonychia.** Patients receiving zidovudine (AZT) may develop longitudinal streaks, horizontal bands, or diffuse hyperpigmentation as well as oral and cutaneous hyperpigmentation. *Courtesy, YDRSC.*

| CUTANEOUS DISEASES THAT CAN "FLARE" DUE TO THE IMMUNE RECONSTITUTION INFLAMMATORY SYNDROME (IRIS) |
|---|
| **Infections** |
| • *Mycobacterium tuberculosis*<br>• *Mycobacterium leprae* (Fig. 65.15)<br>• *Mycobacterium avium* complex and other species<br>• Herpes simplex virus 1 and 2<br>• Varicella–zoster virus<br>• Epstein–Barr virus (e.g. oral hairy leukoplakia)<br>• Cytomegalovirus<br>• Human papillomavirus<br>• Molluscum contagiosum virus<br>• *Candida* spp.<br>• Dermatophytes<br>• *Cryptococcus* spp.<br>• *Histoplasma capsulatum*, *Penicillium marneffei*<br>• *Demodex*, *Malassezia* spp. (e.g. folliculitis)<br>• *Leishmania* spp. |
| **Inflammatory disorders** |
| • Psoriasis, seborrheic dermatitis<br>• Pityriasis rubra pilaris<br>• Granuloma annulare<br>• Sarcoidosis<br>• Foreign body reactions (granulomatous)<br>• Eosinophilic folliculitis<br>• Acne vulgaris, rosacea<br>• Papular pruritic eruption<br>• Lupus erythematosus (systemic, discoid, tumid), relapsing polychondritis<br>• Alopecia areata<br>• Dyshidrotic eczema<br>• Mid-dermal elastolysis |
| **Neoplasms** |
| • Kaposi sarcoma<br>• Non-Hodgkin lymphoma<br>• Multiple eruptive dermatofibromas |

**Table 65.2 Cutaneous diseases that can "flare" due to the immune reconstitution inflammatory syndrome (IRIS).** IRIS can also occur in other settings of immunosuppression (e.g. solid organ transplants, TNF administration).

| CUTANEOUS SIDE EFFECTS OF ANTIRETROVIRAL THERAPY (ART) | | | | | | |
|---|---|---|---|---|---|---|
| **Type of skin reaction** | **NRTIs/NtRTIs** | **NNRTIs** | **Protease inhibitors** | **Integrase inhibitors** | **CCR5 inhibitors** | **Fusion inhibitors** |
| Injection site reaction | | | | | | |
| Morbilliform eruption | Emtricitabine*<br>Abacavir** | Nevirapine> etravirine, efavirenz | Atazanavir, fosamprenavir^ > darunavir^, tipranavir^ > lopinavir | | | |
| DRESS (DIHS) | **Abacavir**** | **Etravirine, efavirenz**<br>**Nevirapine** | Atazanavir, darunavir^, fosamprenavir^, tipranavir^, lopinavir | Rare | Rare | Rare |
| SJS/TEN | Rare | Rare<br>Nevirapine > efavirenz, etravirine | Rare | Rare | | |
| Lipodystrophy (also insulin resistance and elevated TTGs) | d4T, ddI | Efavirenz | Fig. 65.16 | | | |
| Paronychia, excessive periungual granulation tissue | Lamivudine | | Indinavir | | | |
| Xerosis | | | Indinavir | | | |
| Hyperpigmentation of skin and nails | AZT (Fig. 65.17), emtricitabine (palmoplantar) | | | | | |

**Palmoplantar eruption.*
***Associated with HLA-B*5701 allele.*
*^Sulfonamide-like structure and should be used cautiously in patients with sulfonamide allergy.*

**Table 65.3 Cutaneous side effects of antiretroviral therapy (ART).** In general, patients with HIV infection have an increased risk of developing drug-induced morbilliform eruptions and toxic epidermal necrolysis, e.g. to sulfonamides. Bold = most common; dark-colored cells = common; light-colored cells = less common. A whole cell that lacks specific drug names refers to that class of drugs, whereas in subdivided cells, it refers to the remainder of that class of drugs. AZT, zidovudine; CCR5, CC-chemokine receptor 5; NNRTIs, non-nucleoside reverse transcriptase inhibitors; NRTIs/NtRTIs, nucleoside/nucleotide reverse transcriptase inhibitors; SJS, Stevens–Johnson syndrome; TEN, toxic epidermal necrolysis; TTGs, triglycerides.

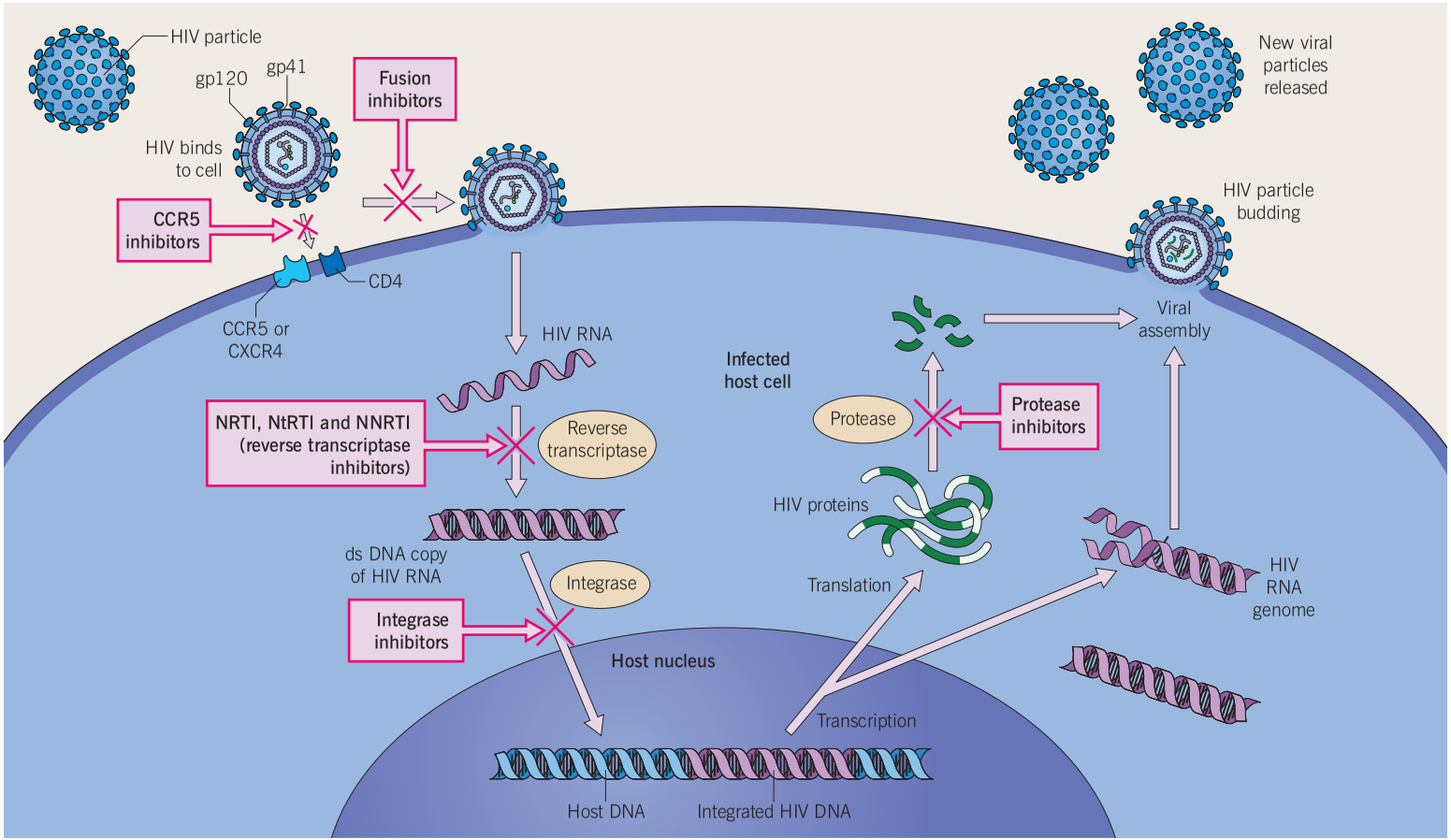


**Fig. 65.18 Replication of HIV within CD4+ lymphocyte and target sites of antiretroviral drugs.** CCR5, CC-chemokine receptor 5; NRTI, nucleoside reverse transcriptase inhibitor; NtRTI, nucleotide reverse transcriptase inhibitor; NNRTI, non-nucleoside reverse transcriptase inhibitor.

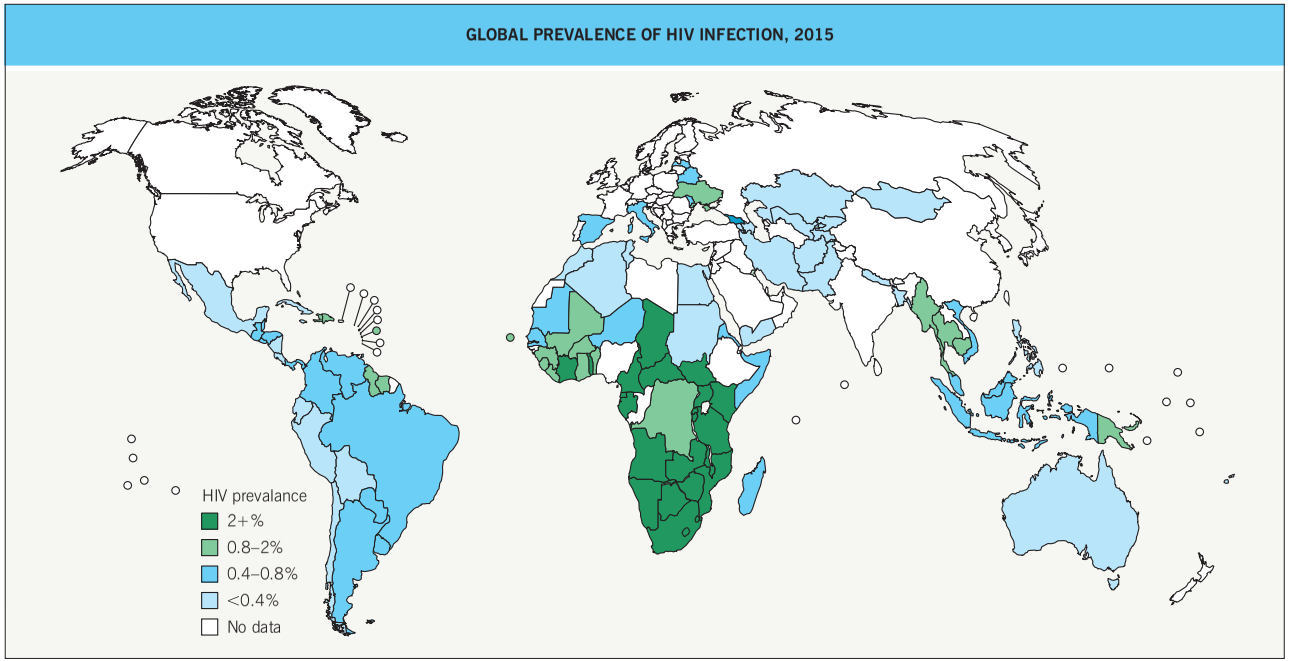


**eFig. 65.1 Global prevalence of HIV infection, 2015.** The worldwide estimate of the number of persons living with HIV infection is 36.9 million. *From the Joint United Nations Programmes on HIV/AIDS.*

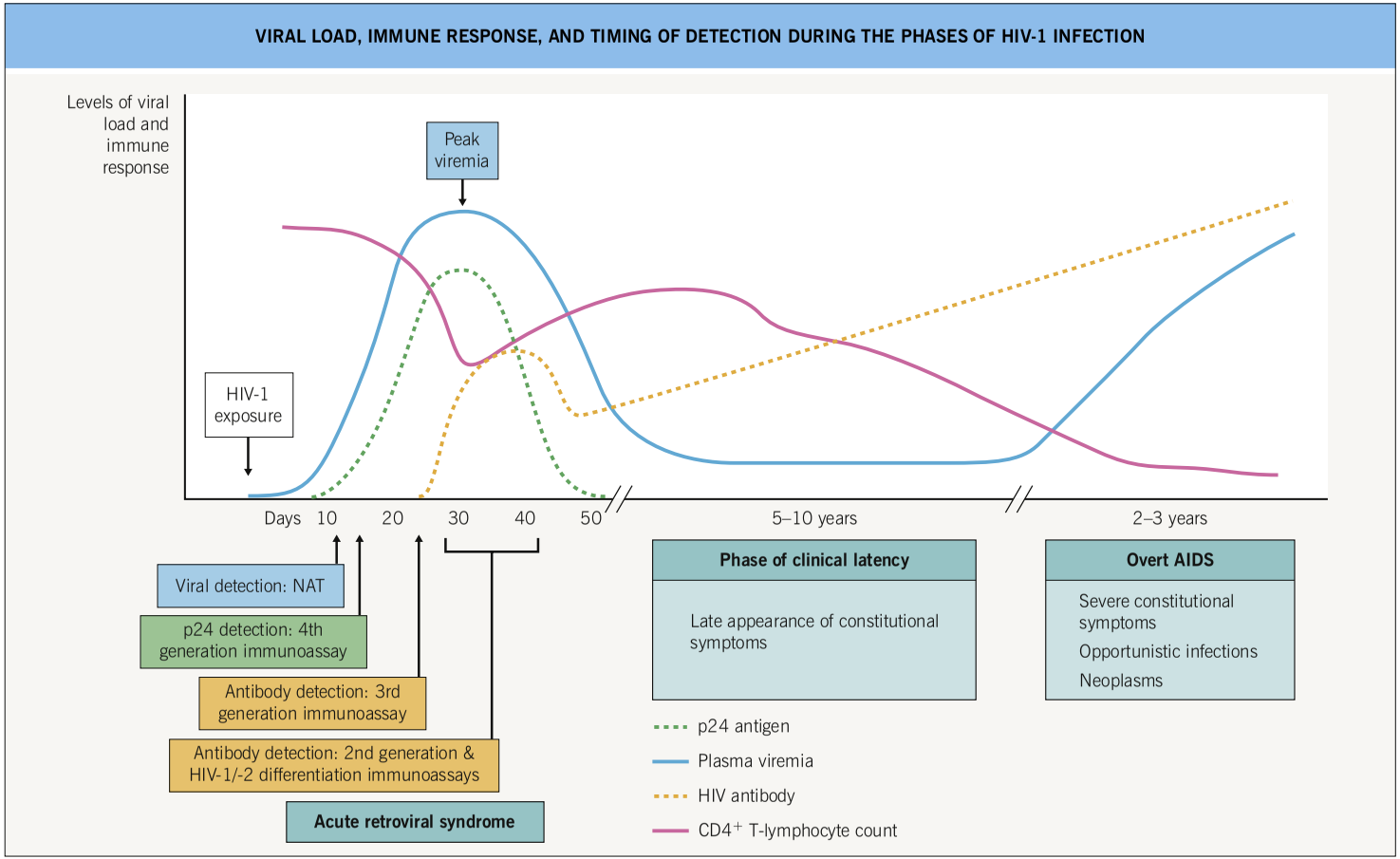


**eFig. 65.2 Viral load, immune response, and timing of detection during the phases of HIV-1 infection.** After HIV-1 exposure, initial virus replication and spread occur in the lymphoid organs, and systemic dissemination of HIV-1 is reflected by the peak of plasma viremia. A clinical syndrome of varying severity is associated with this phase of primary HIV-1 infection in up to 80% of HIV-1-infected persons. Down-regulation of viremia during the transition from the primary to the early chronic phase coincides with the appearance of HIV-1-specific cytotoxic T lymphocytes and with the progressive resolution of the clinical syndrome. The long phase of clinical latency is associated with active virus replication, particularly in the lymphoid tissue. During the clinically latent period, $CD4^+$ T-lymphocyte counts slowly decrease, as does the HIV-1-specific immune response. When $CD4^+$ T-lymphocyte counts decrease below 200 cells/ml (i.e. when overt AIDS occurs), the clinical picture is characterized by severe constitutional symptoms and by the possible development of opportunistic infections and/or neoplasms. NAT, nucleic acid amplification test. *Adapted from Bart PA, Pantaleo G. The immunopathogenesis of HIV-1 infection. In: Cohen J, Powderly WG. Infectious Diseases. Edinburgh: Mosby, 2004:1236.*



**eFig. 65.3 Eosinophilic folliculitis.** Multiple follicular pustules are seen. Either a biopsy or a Giemsa stain of pustular contents will demonstrate eosinophils. *Courtesy, Luis Requena, MD.*



**eFig. 65.4 Extensive perianal condylomata acuminata.** This 65-year-old man was receiving ART and had a $CD4^+$ T-cell count of 240/$mm^3$. *Courtesy, Singapore National Skin Centre.*

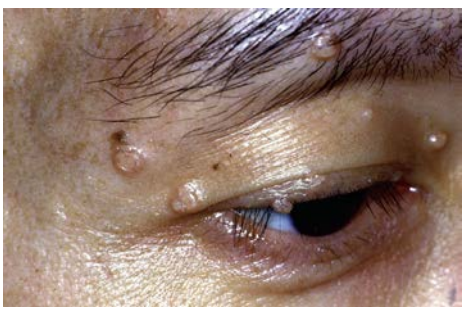

**eFig. 65.5 Molluscum contagiosum.** Multiple facial lesions are commonly seen in HIV-infected patients and are less likely to resolve spontaneously. Disseminated fungal infections may present with molluscum contagiosum-like lesions and should be excluded. *Courtesy, Singapore National Skin Centre.*



**eFig. 65.6 Hypertrophic herpes simplex virus (HSV) infection.** This unusual presentation of HSV is mainly observed in HIV-infected individuals. Treatment entails prolonged courses of antiviral medication or surgery. Biopsy may be required to exclude neoplasia. *Courtesy, Singapore National Skin Centre.*



**eFig. 65.7 Herpes simplex virus (HSV) infection of the pinna.** This patient presented with a chronic, non-healing ulcer due to HSV type 2. Antiviral medication was continued until full clinical resolution occurred. *Courtesy, Singapore National Skin Centre.*



**eFig. 65.8 Oral hairy leukoplakia – clinical findings.** Irregular white plaques on the sides of the tongue due to Epstein–Barr virus. These lesions have no malignant potential and treatment is optional. *Courtesy, Singapore National Skin Centre.*

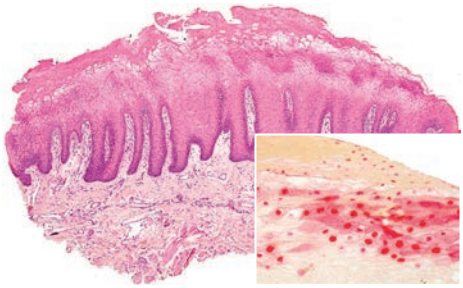

**eFig. 65.9 Oral hairy leukoplakia – histologic findings.** Histologic findings include irregular parakeratosis, acanthosis, and focal balloon cell changes of the epithelium. The inset shows positive staining for Epstein–Barr virus-encoded RNA (EBER) in the nuclei of affected keratinocytes. *Courtesy, Lorenzo Cerroni, MD; inset, Courtesy, Luis Requena, MD.*



**eFig. 65.10 Disseminated histoplasmosis.** Multiple umbilicated papules and ulcers with rolled borders. Diagnosis is via histology with fungal stains and culture. Patients are usually severely immunosuppressed. *Courtesy, Singapore National Skin Centre.*



**eFig. 65.11 Histoplasmosis in a patient with AIDS.** Disseminated papules and nodules, some with central scale-crust. *Courtesy, USCDRSC.*




**eFig. 65.12 Kaposi sarcoma.** Violaceous to red-purple papules, nodules and plaques on the penis (**A**), back (**B**), and foot (**C**). Early ulceration is evident on the lateral foot and some of the lesions on the trunk follow skin cleavage lines. *A, Courtesy, Singapore National Skin Centre; B, Courtesy, YDRSC; C, Courtesy, Thomas Horn, MD.*



**eFig. 65.13 Morbilliform drug eruption due to trimethoprim-sulfamethoxazole (TMP-SMX).** This HIV-positive young man developed a widespread eruption of blanchable erythematous macules and papules 8 days after starting TMP-SMX. Note the coalescence on the upper trunk. *Courtesy, Singapore National Skin Centre.*



**eFig. 65.14 Cutaneous vasculitis.** Drug-induced and infective (e.g. due to hepatitis C virus) causes of vasculitis should be excluded in HIV-infected patients. Corticosteroids and other immunosuppressive therapies should be used with caution. *Courtesy, Singapore National Skin Centre.*

| WHO CLINICAL STAGING OF HIV/AIDS IN THE SETTING OF CONFIRMED HIV INFECTION | | |
|---|---|---|
| **All ages** | **Adults and adolescents** | **Children** |
| **Clinical stage 1 – asymptomatic; immunologic correlate*: >500 CD4+ cells/mm$^3$** | | |
| • Asymptomatic<br>• Persistent generalized lymphadenopathy | | |
| **Clinical stage 2 – mild; immunologic correlate*: 350–499 CD4+ cells/mm$^3$** | | |
| • **Herpes zoster**<br>• **Fungal nail infection**<br>• **Pruritic papular eruptions**<br>• **Angular cheilitis**<br>• **Recurrent oral ulcerations**<br>• Recurrent/chronic upper respiratory tract infections (sinusitis, otitis media/otorrhea, tonsillitis, pharyngitis) | • **Seborrheic dermatitis**<br>• Moderate unexplained weight loss (<10% of body weight) | • **Extensive warts**<br>• **Extensive molluscum contagiosum**<br>• **Lineal gingival erythema**<br>• Unexplained persistent parotid enlargement<br>• Unexplained persistent hepatosplenomegaly |
| **Clinical stage 3 – advanced; immunologic correlate*: 200–349 CD4+ cells/mm$^3$** | | |
| • **Persistent oral candidiasis (after first 6–8 weeks of life)**<br>• **Oral hairy leukoplakia**<br>• **Acute necrotizing ulcerative stomatitis, gingivitis, or periodontitis**<br>• Unexplained chronic diarrhea (>1 month in adults, >2 weeks in children)<br>• Unexplained persistent fever (≥37.6°C intermittent or constant, for >1 month)<br>• Pulmonary tuberculosis (current)<br>• Unexplained anemia (<8 gm/dL), neutropenia (<0.5 × 10$^9$/L) or chronic thrombocytopenia (<50 × 10$^9$/L) | • Unexplained severe weight loss (>10% of body weight)<br>• Severe bacterial infections such as pneumonia, empyema, pyomyositis, bone or joint infection, meningitis, bacteremia | • Unexplained moderate malnutrition or wasting not adequately responding to standard therapy<br>• Recurrent severe bacterial pneumonia<br>• Symptomatic lymphoid interstitial pneumonitis<br>• Lymph node tuberculosis<br>• Chronic HIV-associated lung disease including bronchiectasis |
| **Clinical stage 4 – severe/AIDS-defining conditions; immunologic correlate*: <200 CD4+ cells/mm$^3$** | | |
| • **Chronic herpes simplex infection (orolabial, genital, or anorectal of >1 month's duration or visceral at any site)**<br>• **Kaposi sarcoma**<br>• **Extrapulmonary cryptococcosis including meningitis**<br>• **Disseminated endemic mycosis (coccidioidomycosis or histoplasmosis)**<br>• **Disseminated non-tuberculous mycobacterial infection** | • **Atypical disseminated leishmaniasis**<br>• Recurrent severe bacterial pneumonia<br>• Recurrent non-typhoidal *Salmonella* bacteremia<br>• Invasive cervical carcinoma | • Recurrent severe bacterial infections such as empyema, pyomyositis, bone or joint infection, or meningitis (but excluding pneumonia) |

**eTable 65.1 WHO Clinical Staging of HIV/AIDS in the setting of confirmed HIV infection.** *Continued*

| WHO CLINICAL STAGING OF HIV/AIDS IN THE SETTING OF CONFIRMED HIV INFECTION | | |
|---|---|---|
| **All ages** | **Adults and adolescents** | **Children** |
| • Unexplained severe wasting, stunting or severe malnutrition not responding to standard therapy (HIV wasting syndrome)<br>• Cytomegalovirus infection (retinitis or infection of other organs; onset at age >1 month)<br>• HIV encephalopathy<br>• Progressive multifocal leukoencephalopathy<br>• Extrapulmonary tuberculosis<br>• Candidiasis of the esophagus, trachea, bronchi, or lungs<br>• *Pneumocystis* pneumonia<br>• Central nervous system toxoplasmosis (onset at age >1 month)<br>• Chronic cryptosporidiosis (with diarrhea)<br>• Chronic isosporiasis<br>• Symptomatic HIV-associated nephropathy or symptomatic HIV-associated cardiomyopathy<br>• Cerebral or non-Hodgkin B-cell lymphoma, or other HIV-associated solid tumor | | |
| **In individuals ≥6 years of age; corresponding counts in children <6 years of age are available at www.who.int/hiv/pub/guidelines/hivstaging/en/.* | | |

**eTable 65.1** *Continued* **WHO Clinical Staging of HIV/AIDS in the setting of confirmed HIV infection.** Conditions with mucocutaneous manifestations are in bold.

| CORRELATION OF CD4+ CELL COUNT WITH SPECIFIC HIV-ASSOCIATED DISORDERS | | | | |
|---|---|---|---|---|
| **System*** | **>500 CD4+ cells/mm3** | **<500 CD4+ cells/mm3** | **<250 CD4+ cells/mm3** | **<50 CD4+ cells/mm3** |
| Dermatologic | Acute retroviral syndrome<br>Oral hairy leukoplakia<br>Vaginal candidiasis<br>Seborrheic dermatitis | Oropharyngeal candidiasis (thrush)<br>Herpes zoster<br>Psoriasis, severe or refractory<br>Eruptive atypical melanocytic nevi and melanoma<br>Kaposi sarcoma | Eosinophilic folliculitis<br>Seborrheic dermatitis, refractory<br>Mollusca, extensive<br>Bacillary angiomatosis<br>Miliary/extrapulmonary tuberculosis<br>Herpes simplex virus infection, disseminated<br>Cryptococcosis, disseminated<br>Histoplasmosis, disseminated<br>Coccidioidomycosis, disseminated<br>Botryomycosis<br>Non-Hodgkin lymphoma | Large, non-healing mucocutaneous herpes simplex virus infections (e.g. perianal)<br>Papular pruritic eruption<br>Giant mollusca<br>Perianal ulcers due to cytomegalovirus<br>Aspergillosis<br>Acquired ichthyosis<br>*Mycobacterium avium* complex infections<br>Major aphthae |
| Respiratory | Bacterial pneumonia and sinusitis | Pneumococcal pneumonia<br>Pulmonary tuberculosis<br>Lymphocytic interstitial pneumonia (pediatric) | *Pneumocystis jiroveci* pneumonia (PCP) | *Pseudomonas* spp. pneumonia |
| Nervous | Aseptic meningitis<br>Guillain–Barré syndrome | Mononeuritis multiplex | HIV-associated dementia<br>Cerebral toxoplasmosis<br>Peripheral neuropathy<br>Progressive multifocal leukoencephalopathy | Primary CNS lymphoma |
| Hematologic | Persistent generalized lymphadenopathy | Anemia<br>Idiopathic thrombocytopenic purpura | Non-Hodgkin lymphoma | |
| Other | Myopathy | Cryptosporidiosis<br>Cervical/anal intraepithelial neoplasia<br>Cervical cancer<br>Anal cancer | Esophageal candidiasis<br>Wasting<br>Microsporidiosis<br>Vacuolar myelopathy<br>Cardiomyopathy | Cryptosporidiosis, refractory<br>Cytomegalovirus retinitis, extraocular systemic cytomegalovirus infection |

**Diseases occur with increasing frequency and severity at lower CD4+ cell counts.*

**eTable 65.2 Correlation of CD4+ cell count with specific HIV-associated disorders.**

| LABORATORY TESTS FOR HUMAN IMMUNODEFICIENCY VIRUS (HIV) INFECTION | | |
|---|---|---|
| **Test** | **Target of detection** | **Median "window" period from infection to positive test (days)** |
| **Nucleic acid amplification tests (NATs)** | | |
| Quantitative for HIV-1 viral load assessment | RNA (≥20–40 copies/ml) | 6–10 |
| Qualitative for HIV-1 diagnosis* | RNA (≥100 copies/ml) | 10–12 |
| **Screening tests** | | |
| 4th generation HIV-1/2 antigen/antibody EIA* | IgM, IgG, p24 antigen | 16–18; 19–20 for rapid test** |
| 3rd generation HIV-1/2 antibody EIA* | IgM, IgG | 22–24; 26–32 for rapid test** |
| **Supplemental/confirmatory tests** | | |
| HIV-1/2 antibody differentiation EIA* | IgG | 32–36 |
| HIV-1 Western blot | IgG | 35–40 |
| HIV-1 EIA | IgG | 40+ |

**Currently recommended by the CDC for HIV diagnosis; the qualitative NAT is used when the screening test is positive but the confirmatory test is negative or indeterminate; tests that discriminate between HIV-1 and HIV-2 infection have been referred to as "5th generation".*
***Results available in ≤30 minutes, so suitable for point-of-care use.*

**eTable 65.3 Laboratory tests for human immunodeficiency virus (HIV) infection.** There are currently two FDA-approved home HIV tests: the OraQuick® In-Home HIV Test provides results in 20 minutes from oral fluid (which has lower antibody levels than blood), and the Home Access® HIV-1 Test System involves sending a blood sample to a laboratory and receiving results as early as the next day. EIA, enzyme-linked immunoassay; IFA, indirect immunofluorescence assay; NAT, nucleic acid test. *Data from: Delaney KP, Hanson DL, Masciotra S, et al. Time until emergence of HIV test reactivity following infection with HIV-1: implications for interpreting test results and retesting after exposure. Clin Infect Dis. 2017;64:53–9.*

# 66 Human Papillomaviruses

## Key Points

- Human papilloma viruses (HPV) comprise a large group of at least 200 genotypes of DNA viruses that infect the skin and mucosa.
- Different genotypes cause different skin lesions (Table 66.1).
  - Clinical variants differ as to anatomic location, morphology, histopathology, and HPV subtype; correlation of clinical and histopathologic findings is particularly important for bowenoid papulosis and verrucous carcinoma in order to prevent over- or undertreatment, respectively
- Nongenital warts:
  - Transmitted via person-to-person contact or contact with contaminated surfaces/objects
  - Prevalence of 20% in schoolchildren
  - A third or more self-regress within 1–2 years
  - Numerous warts or persistent/progressive warts should prompt consideration of immunosuppression, defects in cellular immunity, or other syndromes (e.g. HIV infection, epidermodysplasia verruciformis, WHIM syndrome [see Ch. 49])
- Anogenital infection with HPV:
  - Sexually transmitted; in young children may also be acquired perinatally or via the same routes as nongenital warts
  - May be subclinical
- High-risk HPV types, especially 16 and 18, are a major cause of cervical cancer as well as cutaneous (periungual SCC) and other mucosal intraepithelial neoplasias or SCCs, in particular vaginal, vulvar, penile, and anal; HPV-associated oropharyngeal SCC is a recently identified specific subtype.
- **Rx**:
  - If desired, focuses on destruction of visible lesions or induction of an immune response
  - Effective targeted antiviral treatments are not available
- Prevention: prophylactic HPV vaccines (e.g. Gardasil®9) are recommended in both genders from ages 9 to 45.

## Common Warts (Verrucae Vulgares)

- Any site, but commonly on the fingers, dorsal hands, and/or sites prone to trauma (Figs 66.1 and 66.2).

| CLINICAL MANIFESTATIONS OF COMMON HUMAN PAPILLOMAVIRUS (HPV) TYPES | |
|---|---|
| **Skin lesions** | **Frequently detected HPV type** |
| Common, palmar, plantar, myrmecial warts | 1, 2 > 27, 57 |
| Flat warts | 3, 10 |
| Epidermodysplasia verruciformis | 5*, 8* > others (e.g. 9, 20) |
| Condylomata acuminata (anogenital warts) | 6, 11 |
| High-grade squamous intraepithelial neoplasia (cervical lesions, bowenoid papulosis, erythroplasia of Queyrat) | 16, 18, 31, 33 > others (e.g. 35) |
| Cervical cancer | 16, 18 |
| *Oncogenic, like HPV types 16, 18. | |

**Table 66.1 Clinical manifestations of common human papillomavirus (HPV) types.** In clinical practice, subtyping is generally only performed routinely on Papanicolaou smears. Subtyping does not usually change management of cutaneous lesions.



**Fig. 66.1 Verrucae vulgares (common warts).** *Courtesy, A. Geusau, MD.*







**Fig. 66.2 Periungual common warts.** Destruction of the nail matrix and bed can lead to partial **(A)** or complete **(B)** absence of the nail plate. Bowen disease may be considered in the differential diagnosis, especially for a single, recalcitrant digital wart. *A, B, Courtesy, Reinhard Kirnbauer, MD, and Petra Lenz, MD.*

- Hyperkeratotic, exophytic or dome-shaped papules or plaques with punctate black dots (hemorrhage in the stratum corneum) that may require paring to see (Fig. 66.3).
- Histopathology: papillomatosis, acanthosis, hypergranulosis; epidermal keratinocytes have haloes around their nuclei (koilocytes).



**Fig. 66.3 Verrucae plantares (plantar warts).** The photo was taken after shaving of the hyperkeratotic surface; the black dots represent intracorneal hemorrhage. *Courtesy, Reinhard Kirnbauer, MD, and Petra Lenz, MD.*

- **DDx:** seborrheic keratosis, actinic keratosis, cutaneous horn, SCC (especially periungual), trichilemmoma, Spitz nevus.
- **Rx:** outlined in Fig. 66.4; may regress spontaneously within 1–2 years; may be difficult to eradicate.

## Plantar/Palmar Warts

- Thick, exo- and endophytic hyperkeratotic papules and plaques (Fig. 66.5); coalescence of lesions can lead to extensive areas of involvement referred to as mosaic warts.
- May see sloping sides and a central depression (the term *myrmecia* is used because it can resemble an anthill); tender with pressure (Fig. 66.6).
- **DDx:** corns (clavi; see Ch. 74), punctate palmoplantar keratoderma (see Table 47.1), arsenical keratoses, SCC, amelanotic melanoma.
- **Rx:** overlaps with Rx of common warts (see Fig. 66.4).

## Flat Warts (Verrucae Planae)

- Commonly on the dorsal hands, arms, and face, as well as the legs (exacerbated by shaving).
- Skin-colored to pink or brown (sometimes hypopigmented in darker skin), minimally

Downloaded for Novin lib (novinlibrary@yahoo.com) at United Arab Emirates University from ClinicalKey.com by Elsevier on March 26, 2022. For personal use only. No other uses without permission. Copyright ©2022. Elsevier Inc. All rights reserved.

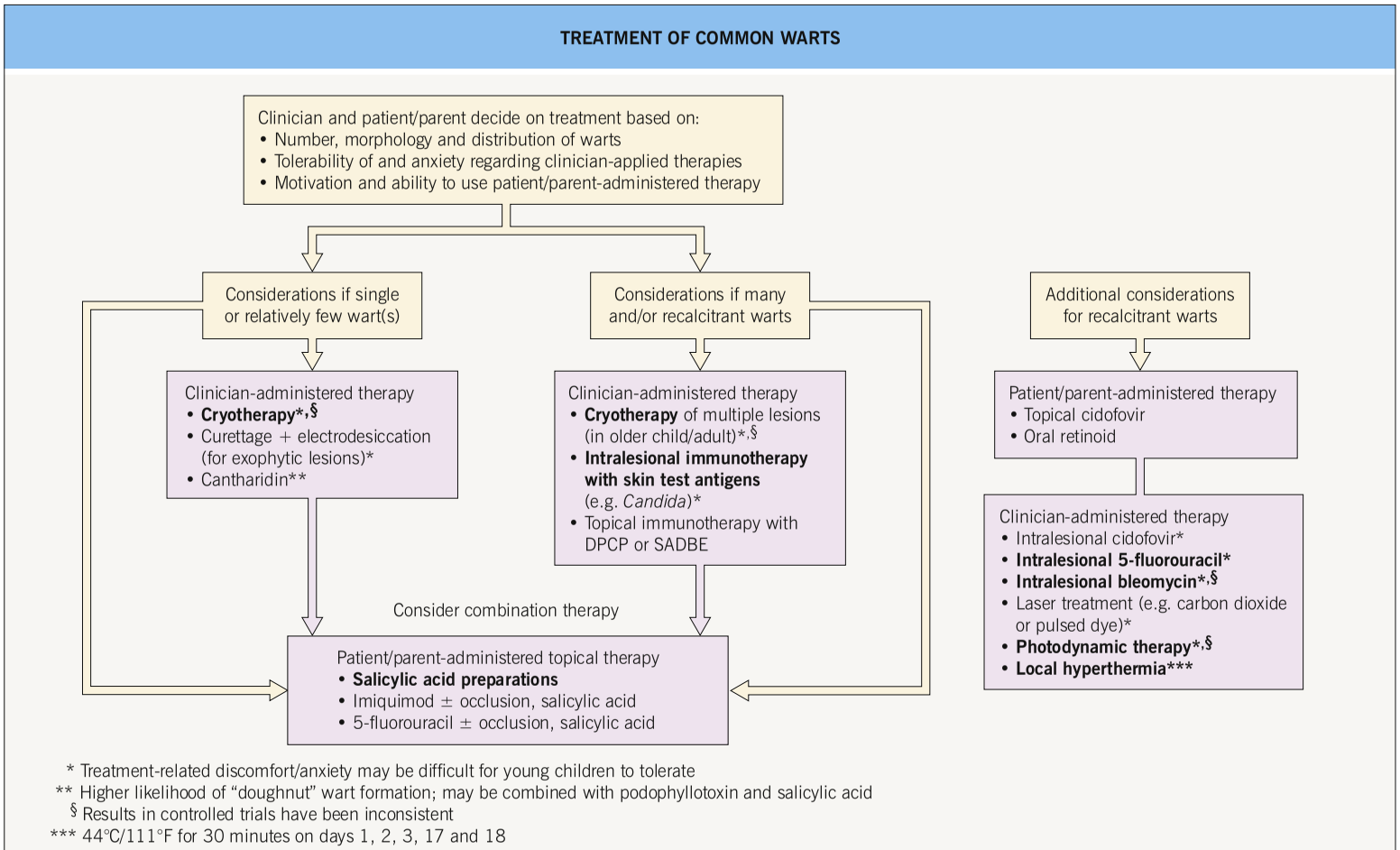


**Fig. 66.4 Treatment of common warts.** Therapies found to be effective in controlled trials are in **bold**. While still employed by some clinicians, three double-blind, placebo-controlled trials failed to confirm efficacy of cimetidine therapy for recalcitrant common warts. DPCP, diphenylcyclopropenone; SADBE, squaric acid dibutyl ester.



**Fig. 66.5 Extensive and chronic verrucosis of the sole in a patient with hepatic cirrhosis due to alcoholism.** HPV-27 DNA was isolated from the lesions. *Courtesy, Reinhard Kirnbauer, MD, and Petra Lenz, MD.*



**Fig. 66.6 Myrmecial wart.** The wart at the base of the distal phalanx of the hallux is painful due to deep endophytic growth; in addition, there are confluent plaques of superficial warts (mosaic warts). *Courtesy, Reinhard Kirnbauer, MD, and Petra Lenz, MD.*

elevated papules; the surface is smooth and often flat-topped (Fig. 66.7).

- **DDx:** small seborrheic keratoses, common warts, Gottron papules of dermatomyositis, lichen nitidus, lichen planus, acrokeratosis verruciformis (see Ch. 48), epidermodysplasia verruciformis (see below).
- **Rx:**
  - If a few lesions, destructive or ablative therapies (e.g. cryosurgery, trichloroacetic acid; see Fig. 66.4)
  - If numerous, topical application of irritants (e.g. retinoids), immunotherapy (see Fig. 66.4), topical 5-fluorouracil







**Fig. 66.7 Verrucae planae (flat warts).** Multiple skin-colored or pink **(A)** to brown **(B)** smooth-surfaced, flat-topped papules. These lesions are typically caused by HPV-3 or -10. *A, Courtesy, Reinhard Kirnbauer, MD, and Petra Lenz, MD; B, Courtesy, Julie V. Schaffer, MD.*

## Oral Warts

- Buccal, gingival, and labial mucosae as well as tongue and hard palate (Fig. 66.8).
- Small, soft, mucosal-colored to white, slightly elevated papillomatous papules.
- **DDx:** bite fibroma, early SCC, leukoedema, Heck disease (focal epithelial hyperplasia; multiple white to pink sessile papules; secondary to HPV types 13 and 32), verrucous proliferative leukoplakia, white sponge nevus.

## Condylomata Acuminata

- Involve primarily the anogenital region.
- Range from discrete, sessile, smooth-surfaced papillomas to large cauliflower-like lesions (Figs 66.9 and 66.10).
- Skin-colored to pink to brown.



**Fig. 66.8 Oral warts.** Papillomas of the labial mucosa in a 6-year-old child. *Courtesy, Reinhard Kirnbauer, MD, and Petra Lenz, MD.*



**Fig. 66.9 Penile condylomata acuminata (genital warts).** Both sessile and exophytic warts are present. *Courtesy, Reinhard Kirnbauer, MD, and Petra Lenz, MD.*

- If present in children, especially those >3 years of age, the possibility of sexual abuse should be considered (see Ch. 75).
- **DDx:** seborrheic keratosis, skin tag, molluscum contagiosum, bowenoid papulosis, SCC, pearly penile papules (see Ch. 95), free sebaceous glands, condyloma lata of secondary syphilis.
- **Rx:** outlined in Fig. 66.11.







**Fig. 66.10 Condylomata acuminata.**
**A** Large, exophytic, broad-based or peduculated papillomas in a healthy 15-year-old boy.
**B** Confluent lesions forming hyperpigmented plaques in the perineal region and along the inguinal fold. A depigmented scar is seen at the site of treatment with liquid nitrogen. *A,B, Courtesy, Reinhard Kirnbauer, MD, and Petra Lenz, MD.*

## Bowenoid Papulosis (Intraepithelial Neoplasia-3; High-Grade Squamous Intraepithelial Lesion)

- Similar to condylomata acuminata, primarily in the anogenital region.
- Multiple pink to red-brown smooth to warty papules or plaques (Figs 66.12 and 66.13; see Fig. 60.9).
- Histopathology: numerous mitoses scattered throughout the epidermis (which distinguishes it from condyloma acuminatum); keratinocytes may show less atypia than in an SCC.
- **Rx:** outlined in Fig. 66.11.

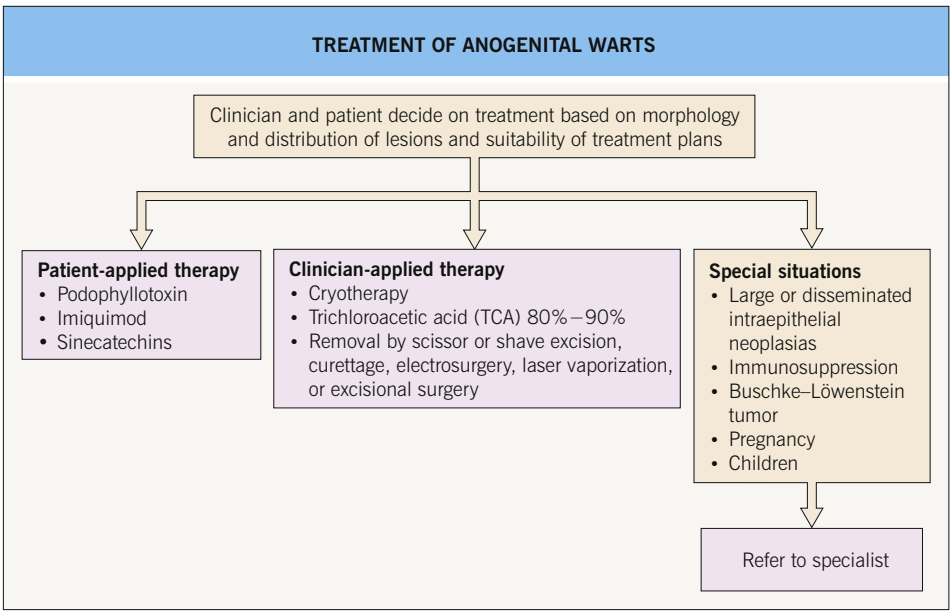


**Fig. 66.11 Treatment of anogenital warts.** TCA, trichloroacetic acid. *Courtesy, Reinhard Kirnbauer, MD, and Petra Lenz, MD.*



**Fig. 66.12 Bowenoid papulosis of the anus positive for high-risk mucosal HPV in a man who had sex with men.** Histology revealed high-grade anal intraepithelial neoplasia (AIN). *Courtesy, Reinhard Kirnbauer, MD, and Petra Lenz, MD.*



**Fig. 66.13 Bowenoid papulosis of the vulva with histopathologic features of vulvar intraepithelial neoplasia (VIN).** Extensive red-brown or whitish papules and plaques containing high-risk mucosal HPV in an HIV-positive patient. Analogous high-grade squamous intraepithelial lesions (HSIL) were present perianally (AIN) and on the cervix (CIN). *Courtesy, Reinhard Kirnbauer, MD, and Petra Lenz, MD.*

## Squamous Cell Carcinoma *In Situ* (Intraepithelial Neoplasia-3 or High-Grade Squamous Intraepithelial Lesion *If Anogenital*; Bowen Disease *If Periungual*; Historically Erythroplasia of Queyrat *If Penile*)

- Favors the glabrous skin of the vulva or penis and the periungual region.
- Well-demarcated pink to red plaque (Fig. 66.14) that over time may progress to invasive carcinoma (Fig. 66.15).
- **DDx:** dermatitis, psoriasis, Rx-resistant periungual wart, lichen sclerosus, erosive lichen planus, candidiasis especially in uncircumcised male, extramammary Paget disease, Zoon balanitis, amelanotic melanoma.
- **Rx:** excision, Mohs surgery, or other destructive modalities depending on patient/lesion characteristics; imiquimod with careful re-evaluation.

## Verrucous Carcinoma

- Low-grade malignancy that is locally invasive and destructive, but rarely metastasizes; lesions can attain a large size when left untreated.
- Major types:
  - Buschke–Löwenstein tumor (Fig. 66.16) – anogenital region; fistulas and/or abscesses may be present
  - Oral florid papillomatosis – oral mucosa or perinasal sinuses – pebbly confluence of whitish papillomas
  - Epithelioma cuniculatum – plantar surface – irregularly shaped, well-demarcated, verrucous nodule, often several centimeters in diameter
  - Papillomatosis cutis carcinoides – other cutaneous sites
- **Rx:** excision.

## Epidermodysplasia Verruciformis (EDV)

- Cutaneous infection with particular HPV types in patients with an inherited predisposition (mutations in *TMC6* [*EVER1*], *TMC8* [*EVER2*]) or acquired immunosuppression (e.g. HIV infection); see Table 66.1.
- Widespread lesions that begin to appear during childhood (inherited form), with a predisposition for sun-exposed areas.
- Lesions vary in color from white to pink to brown and can resemble flat warts or tinea versicolor (Fig. 66.17).
- Distinctive histopathology with expanded gray-blue cytoplasm within the keratinocytes of the upper stratum spinosum.
- Increased risk of SCC, especially in sun-exposed areas.
- **Rx:** difficult (similar to that for flat warts), sun protective measures, address immunosuppression in acquired cases.

For further information see Ch. 79 from *Dermatology, Fourth Edition*.

**For additional online figures visit www.expertconsult.com**



**Fig. 66.14 Erythroplasia of Queyrat.** A well-demarcated velvety plaque of the prepuce positive for high-risk HPV; histology detected a high-grade penile intraepithelial neoplasia (PIN). *Courtesy, Reinhard Kirnbauer, MD, and Petra Lenz, MD.*



**Fig. 66.15 Invasive squamous cell carcinoma of the penis.** It developed over more than a decade from a papular lesion of the prepuce. HPV-16 and -51 DNAs were detected by RT-PCR. *Courtesy, Reinhard Kirnbauer, MD, and Petra Lenz, MD.*



**Fig. 66.16 Giant condylomata acuminata (Buschke–Löwenstein tumor).** Cauliflower-like, deeply infiltrating giant condylomata acuminata in an older woman. *Courtesy, Reinhard Kirnbauer, MD, and Petra Lenz, MD.*



**Fig. 66.17 Epidermodysplasia verruciformis.** Generalized erythematous macules and plaques are seen. Lesions tested positive for HPV-8 and -36. *Courtesy, Reinhard Kirnbauer, MD, and Petra Lenz, MD.*



**eFig. 66.1 Extensive perianal condylomata acuminata.** This 65-year-old man was receiving antiretroviral therapy and had a CD4+ T-cell count of 240/mm$^3$.



**eFig. 66.2 Multiple filiform warts on the lower face.**



**eFig. 66.3 Epidermodysplasia verruciformis.** Confluent scaly papules and plaques resembling flat warts.

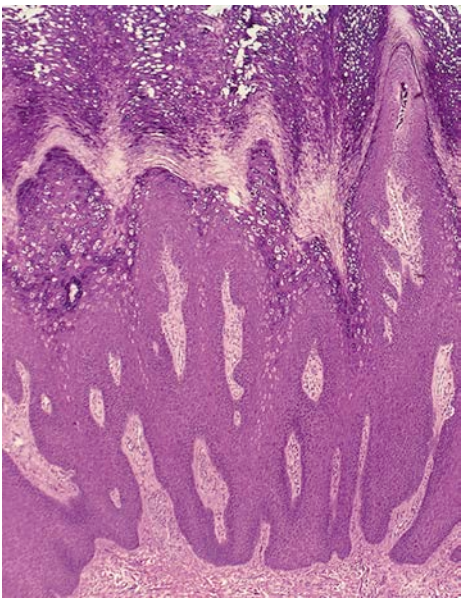

**eFig. 66.4 Verruca vulgaris – histopathologic features.** Note the characteristic features of "church spire" papillomatosis heaped with ortho- and parakeratosis, acanthosis, hypergranulosis and koilocytosis. *Courtesy, R. Tyler, MD.*

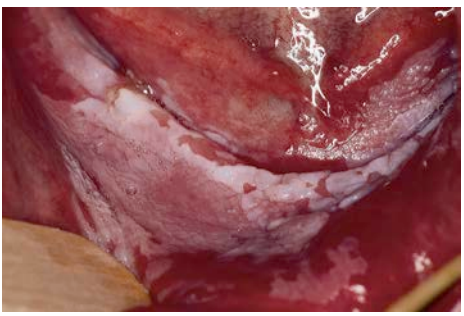

**eFig. 66.5 Verrucous proliferative leukoplakia of the oral cavity.** The lesions have focally progressed to invasive squamous cell carcinoma; HPV DNA was not detectable by PCR.




**eFig. 66.6 Bowenoid papulosis variant of intraepithelial neoplasia. A** Multiple red-brown to brown papules on the shaft of the penis. **B** Coalescence of red-brown to brown papules on the upper inner thigh. *B, Courtesy, Robert Hartman, MD.*



**eFig. 66.7 Extensive and chronic verrucosis of the sole causing pain when walking.** HPV-2a was isolated from the lesion of this otherwise immunocompetent and healthy patient. *Courtesy, Reinhard Kirnbauer, MD, and Petra Lenz, MD.*



**eFig. 66.8 Verrucae planae (flat warts).** Multiple skin-colored or pink to brown smooth-surfaced, flat-topped papules. These lesions are typically caused by HPV-3 or -10. *Courtesy, Julie V. Schaffer, MD.*



**eFig. 66.9 Penile condylomata acuminata (genital warts).** Both sessile and exophytic warts are present. *Courtesy, Reinhard Kirnbauer, MD, and Petra Lenz, MD.*



**eFig. 66.10 Perianal papillomas that are macerated due to moisture from occlusion.** *Courtesy, Reinhard Kirnbauer, MD, and Petra Lenz, MD.*

# 67 Human Herpesviruses

## General

- Human herpesviruses (HHV) are a family of double-stranded DNA viruses (8 members) with a lipid envelope.
- All share the ability to establish lifelong latency in their host following primary infection.
- Basic pathogenesis of HHV infections involves a sequence of primary infection, establishment of latency, reactivation, and recurrent (secondary) infection.
- Clinical presentations depend on the host's age, anatomic location, immune status, and ethnicity (e.g. EBV).
- Spread of infection is usually the result of contact with bodily secretions containing the virus.
- Asymptomatic shedding of virus is common.

## Herpes Simplex Viruses (HSV-1/HHV-1 and HSV-2/HHV-2)

- Ubiquitous pathogens that produce primarily orolabial (HSV-1 > HSV-2) and genital infections (HSV-2 > HSV-1) characterized by recurrent vesicular eruptions (Table 67.1).
- *Transmission* can occur during both symptomatic and asymptomatic periods of viral shedding.
- *Reactivation* can occur either spontaneously or due to an appropriate stimulus (e.g. stress, UVR, fever, tissue trauma, or immunosuppression).
- A wide range of clinical presentations exists, with asymptomatic infection being the most common.
- In ***primary infection***:
  - Onset is usually 3–7 days after exposure
  - *Generalized prodrome* (before the onset of mucocutaneous lesions) of tender lymphadenopathy, fever, and malaise; localized pain, burning, and tenderness
  - Initial lesions: small round vesicles on an erythematous base; often painful or burning; the grouping of these vesicles is a clue to the diagnosis; vesicles may become umbilicated or pustular, followed by erosions or ulcerations with hemorrhagic crusts, often with a scalloped border; lesions resolve over 2–6 weeks (Fig. 67.1)
- In ***reactivation infection***:
  - *Localized prodrome* of dysesthesia (e.g. burning/tingling, pain, pruritus) and tenderness
  - Mucocutaneous lesions similar as in primary but fewer in number, less severe, and shorter duration (Fig. 67.2)
- In addition to the classic orolabial and genital infections, HSV can cause other infections (Table 67.2; Figs 67.3–67.7).
- **DDx** and Dx: see Table 67.1.
- **Rx:** outlined in Table 67.3.

## Varicella–Zoster Virus (VZV or HHV-3)

- **Primary varicella infection (chickenpox)**
  - Usually self-limited in otherwise healthy children but more severe with more numerous lesions and a greater risk for complications in adults (including pregnant women) and immunocompromised individuals (Table 67.4; Fig. 67.8)
- **Herpes zoster (shingles) – reactivation of VZV**
  - Incidence, severity, and risk of complications increase significantly with age and immunosuppression due to a decline in specific cell-mediated immune response to VZV
  - Reactivation results in a sensory neuritis and painful neuralgia, followed by a

| MAJOR CLINICAL FEATURES OF CLASSIC HERPES SIMPLEX VIRUS (HSV) OROLABIAL AND GENITAL INFECTIONS | | | |
|---|---|---|---|
| **Mucocutaneous HSV infection** | **Primary infection*** | **Reactivation infection*** | **DDx** |
| **Orolabial HSV** (HSV1 > HSV2)<br>Latency is established in the neuronal cells of dorsal root ganglia, especially trigeminal | • Asymptomatic infection most common<br>• Gingivostomatitis primarily in children <10 years of age (see Fig. 67.1A)<br>• Pharyngitis and mononucleosis-like syndrome in young adults<br>• Dysphagia and drooling may occur | • Favors vermilion border of lips (see Fig. 67.2B) and occurs less commonly in the perioral region and cheek (see Fig. 67.2A), nasal mucosa, and hard mucosa (i.e. mucosa overlying bone) such as the hard palate and gingivae<br>• In immunocompromised hosts, can see on the soft mucosa, e.g. buccal mucosa and soft palate | **Vermilion lips/perioral**<br>• Impetigo<br>• Coxsackie infection (also intraoral)<br>• EM major or SJS (also intraoral)<br>**Intraoral**<br>• Aphthous stomatitis<br>• Pharyngitis (e.g. EBV)/herpangina<br>• Drug-induced mucositis |
| **Genital HSV** (HSV2 > HSV1)<br>Latency is established in the neuronal cells of dorsal root ganglia, especially sacral | • Seropositive persons often report no history of primary genital infection<br>• Frequently presents with excruciatingly painful erosive balanitis, vulvitis, or vaginitis<br>• In **males** typically involves the glans or shaft of the penis<br>• In **females** can also involve cervix, buttocks (see Fig. 67.1D), and perineum with associated dysuria, urinary retention, and inguinal lymphadenopathy (see Fig. 67.1C) | • Usually a subclinical presentation<br>• Typically a limited number of grouped vesicles* occur on the genitalia or buttocks (especially in females) (see Fig. 67.2C,D)<br>• Frequency of recurrence correlates with the severity of the primary infection | • Trauma<br>• EBV- or CMV-related ulcers<br>• Aphthae<br>• Syphilitic chancre<br>• Chancroid<br>• Lymphogranuloma venereum<br>• Granuloma inguinale |
| Diagnosis is made at the bedside by either (1) performance of a Tzanck smear (see Fig. 2.7; results in minutes); DFA or PCR (results in hours); or viral culture (results in days) or (2) performing a skin biopsy for H&E staining (see Fig. 2.6; results in days).<br>*In immunocompromised hosts it is prudent to request testing for HSV-1, HSV-2, and VZV, as clinical presentations are often atypical.* | | | |
| **For the description of typical lesions, see text; occasionally, intact vesicles are not seen but rather grouped ulcerations with hemorrhagic crusts predominate.* | | | |

**Table 67.1 Major clinical features of classic herpes simplex virus (HSV) orolabial and genital infections.** In the United States, ~50% of adults are seropositive for HSV-1 and ~12% are seropositive for HSV-2. Treatment is outlined in Table 67.3. EM, erythema multiforme; SJS, Stevens–Johnson syndrome.




**Fig. 67.1 Primary herpes simplex virus (HSV) infections. A** Primary herpes gingivostomatitis due to HSV-1 in a child. Note the coalescing lesions with scalloped borders. **B** HSV-2 infection in a teenager (primary vs non-primary initial infection). Note the scalloped borders. **C** Primary genital HSV infection. In addition to 1- to 2-mm hemorrhagic crusts, there are perifollicular vesiculopustules. **D** Grouped vesicles and erosions in the gluteal cleft. *A, Courtesy, Julie V. Schaffer, MD; B, Courtesy, Jean L. Bolognia, MD; C, Courtesy, Stephen K. Tyring, MD; D, Courtesy, Kalman Watsky, MD.*

dermatomal vesicular eruption; clinical course is outlined in Table 67.4 (Figs 67.9–67.11)

– Exposure of a susceptible person to an individual with chickenpox or zoster can lead to primary varicella but not zoster
– **Rx:** early antiviral treatment (within 72 hours of the onset of the first vesicle) is ideal, but initiation after 72 hours but within 7 days may also be helpful (see Table 67.3)
– **Selected complications of herpes zoster:**

**1. Disseminated zoster**

- Defined as >20 vesicles outside the area of the primary or adjacent dermatomes
- Implies viremia and an increased risk for visceral or CNS involvement (see Table 67.4)
- Requires intravenous acyclovir




**Fig. 67.2 Reactivation of herpes simplex virus (HSV) infections. A** Recurrent HSV-1 infection on the cheek. Occasionally such lesions are misdiagnosed as cellulitis or bullous impetigo. **B** Recurrent herpes labialis (cold sore, fever blister). **C, D** Intact grouped vesicles and/or vesiculopustules with an erythematous base on the penis (**C**) and above the gluteal cleft (**D**). The buttock is a common location in women. **E** Healing ulcerations with scalloped borders on the penis. *A, C, D, Courtesy, Kalman Watsky, MD; B, Courtesy, Stephen K. Tyring, MD; E, Courtesy, Joseph L. Jorizzo, MD.*

| MAJOR CLINICAL FEATURES OF OTHER HERPES SIMPLEX VIRUS (HSV) INFECTIONS | |
|---|---|
| **HSV infection** | **Major clinical features** |
| **Eczema herpeticum (Kaposi varicelliform eruption [KVE])** | • Widespread eruption of HSV, usually occurring in association with skin conditions that disrupt the epidermal barrier (e.g. atopic dermatitis, burns, Darier disease) (see Fig. 67.3); DDx includes infections with coxsackievirus or *Streptococcus* |
| **Herpetic whitlow** | • HSV infection of the digit(s) (Fig. 67.4); most often seen in children; in the past was common in health-care workers who did not wear gloves |
| **Herpes gladiatorum** | • Occurs in contact sports (e.g. wrestling) (see Fig. 67.5) |
| **HSV folliculitis** | • Uncommon; most often seen in patients who shave with a blade razor (e.g. herpes sycosis in the beard region) or in immunocompromised hosts (see Fig. 31.4B) |
| **HSV in immunocompromised hosts** (e.g. HIV (+), solid organ and hematopoietic stem cell transplant recipients, leukemia and lymphoma patients) | • May present with chronic or atypical mucocutaneous presentations (e.g. multiple sites; disseminated lesions; verrucous, exophytic or pustular lesions; see Fig. 67.6)<br>• Most common presentation is a chronic, enlarging ulceration; in the buttock area may be misdiagnosed as a pressure ulcer (see Fig. 67.6D) |
| **Ocular HSV** | • Most often acquired in newborns during the vaginal birthing process<br>• *Primary infection:* typically presents as unilateral or bilateral keratoconjunctivitis, eyelid edema, tearing, photophobia, chemosis, and preauricular lymphadenopathy; with *recurrent infection* usually unilateral and may be confused with a contact dermatitis or periocular cellulitis<br>• Potential complications: corneal ulceration, scarring<br>• Pathognomonic finding: branching, dendritic lesions of the corneal epithelium |
| **Neonatal HSV** | • Greatest risk of transmission (30–50%) from infected mother to neonate is among women with first episode of genital HSV near the time of delivery; lowest risk (<3%) is among women with recurrent genital HSV<br>• Significant morbidity and mortality in affected infants, especially if disseminated disease<br>• Clinical presentations vary (see Fig. 67.7 and see Ch. 28) |
| **Herpes encephalitis** | • *No* cutaneous manifestations<br>• Most common cause of sporadic, fatal viral encephalitis in the U.S. |

**Table 67.2 Major clinical features of other herpes simplex virus (HSV) infections.** Treatment is outlined in Table 67.3.

2. **Post-herpetic neuralgia (PHN) and post-herpetic itch (PHI)**
   - Affects 10–20% of patients; incidence and severity increase with age
   - Characterized by persistent pain, dysesthesia (PHN) or pruritus (PHI) along the affected dermatome for weeks to years after the resolution of the eruption
   - **Rx:** gabapentin, tricyclic antidepressants (e.g. amitriptyline, nortriptyline); topical agents (e.g. lidocaine patch, capsaicin); oral analgesics (e.g. ibuprofen, opioids)
   - Note that opioids are typically ineffective or even aggravating in patients with PHI







**Fig. 67.3 Eczema herpeticum. A** Monomorphic, punched-out erosions with a scalloped border in this infant with a history of facial atopic dermatitis. **B** Monomorphic, small hemorrhagic crusts and erosions coalescing in the popliteal fossae, an area of pre-existing atopic dermatitis. *A, Courtesy, Julie V. Schaffer, MD; B, Courtesy, Kalman Watsky, MD.*










**Fig. 67.4 Herpetic whitlow. A** Coalescing vesicles and erosions on the distal finger of a child. **B** An edematous, erythematous plaque with relatively subtle central vesicle formation on the thumb of a child. **C** Grouped vesicles on the toe of an adult. Herpetic whitlow is sometimes misdiagnosed as cellulitis or blistering dactylitis, or, depending on the distribution, paronychia. *A, Courtesy, YDRSC; B, Courtesy, Stephen K. Tyring, MD; C, Courtesy, Louis A. Fragola, Jr, MD.*



**Fig. 67.5 Herpes gladiatorum.** Grouped vesicles and erosions on the neck of a high school wrestler. *Courtesy, Louis A. Fragola, Jr., MD.*




**Fig. 67.6 Herpes simplex viral infections in immunocompromised hosts. A** Enlarging ulcerations in a child with acute lymphocytic leukemia who was presumed to have a *Rhizopus* infection, and **(B)** in a young man with AIDS. **C** Coalescence of eroded, yellow-white papules and plaques on the tongue. **D** Chronic perianal ulcerations in an HIV-infected male. *A–C, Courtesy, YDRSC; D, From Callen JP, Jorizzo JL, et al. Dermatological Signs of Internal Disease, 4th edn.; Saunders/Elsevier, 2009.*



**Fig. 67.7 Neonatal herpes.** Grouped papulovesicles with an erythematous base on the chest. Note the scalloped borders in areas of coalescence. *Courtesy, Frank Samarin, MD.*

| ANTIVIRAL THERAPY FOR HERPES SIMPLEX VIRUS AND VARICELLA–ZOSTER VIRUS | |
|---|---|
| **Disease context** | **Drug and dosage** |
| **Herpes simplex infections** | |
| Orolabial herpes* (recurrence) | *Topical*<br>Docosanol: 5×/d until healed<br>Penciclovir: 1% cream applied q2 h while awake × 4 days<br>Acyclovir: 5% ointment applied q3 h/6 times/day × 7–10 days<br>Acyclovir + hydrocortisone: 5%/1% cream applied 5×/d × 5 days<br>Acyclovir mucoadhesive tablet: 50 mg single application in the canine fossa on the side affected<br>*Oral**<br>Acyclovir**: 400 mg PO TID × 7–10 days<br>Famciclovir: 1.5 gm PO × 1 dose<br>Valacyclovir: 2 gm PO BID × 1 day |
| Genital herpes (first episode) | Acyclovir: 200 mg PO 5×/d × 10 days or 400 mg PO TID × 10 days<br>Famciclovir: 250 mg PO TID × 10 days<br>Valacyclovir: 1 gm PO BID × 10 days |
| Genital herpes (recurrence) | Acyclovir: 400 mg PO TID × 5 days or 800 mg PO BID × 5 days or 800 mg PO TID × 2 days<br>Famciclovir: 1 gm PO BID × 1 day or 500 mg PO × 1 dose then 250 mg PO BID × 2 days or 125 mg PO BID × 5 days<br>Valacyclovir: 500 mg PO BID × 3 days or 1 gm PO daily × 5 days |
| Chronic suppression | Acyclovir: 400 mg PO BID<br>Famciclovir: 250 mg PO BID<br>Valacyclovir: 500 mg PO daily for <10 outbreaks/year or 1 gm PO daily for ≥10 outbreaks/year |
| Neonatal | Acyclovir: 20 mg/kg IV q8 h × 14–21 days |
| Immunocompromised | *Recommend use until all mucocutaneous lesions are healed*<br>Acyclovir: 400 mg PO 5×/d or 5 mg/kg (if age ≥12 y) to 10 mg/kg (if age <12 y) IV q8 h<br>Famciclovir**: 500 mg PO BID<br>Valacyclovir**: 1 gm PO BID |

**Table 67.3 Antiviral therapy for herpes simplex virus and varicella–zoster virus.** Topical antiviral agents should be applied using a finger with intact skin. *Continued*

| ANTIVIRAL THERAPY FOR HERPES SIMPLEX VIRUS AND VARICELLA–ZOSTER VIRUS | |
|---|---|
| **Disease context** | **Drug and dosage** |
| Eczema herpeticum/Kaposi varicelliform eruption** | *Recommend use for 10–14 days or (especially if immunocompromised) until all mucocutaneous lesions are healed*<br>Acyclovir: 15 mg/kg (400 mg max) PO 3–5×/d or, if severe, 5 mg/kg (if age ≥12 y) to 10 mg/kg (if age <12 y) IV q8 h<br>Famciclovir: 500 mg PO BID<br>Valacyclovir: 1 gm PO BID |
| Genital herpes, recurrent in the setting of HIV infection | *Recommend use until all mucocutaneous lesions are healed*<br>Acyclovir**: 400 mg PO TID<br>Famciclovir: 500 mg PO BID<br>Valacyclovir**: 1 gm PO BID |
| Chronic suppression in the setting of HIV infection | Acyclovir**: 400–800 mg PO BID–TID<br>Famciclovir**: 250–500 mg PO BID<br>Valacyclovir: 500 mg PO BID |
| Acyclovir-resistant HSV in immunocompromised patients | Foscarnet: 40 mg/kg IV q8–12 h × 2–3 weeks (or until all lesions are healed)<br>Cidofovir: 1% cream or gel daily × 2–3 weeks or (for severe disease) 5 mg/kg IV weekly × 2 weeks then every other week (together with probenecid) |
| **Varicella–zoster virus infections** | |
| Varicella | Acyclovir: 20 mg/kg (800 mg max) PO 4×/d × 5 days<br>Valacyclovir†: 20 mg/kg (1 gm max) PO TID × 5 days |
| Herpes zoster | Acyclovir: 800 mg PO 5×/d × 7–10 days<br>Famciclovir: 500 mg PO TID × 7 days<br>Valacyclovir: 1 gm PO TID × 7 days |
| Immunocompromised patient or disseminated disease | Acyclovir: 10 mg/kg (500 mg/m$^2$) IV q8 h × 7–10 days *or until cropping has ceased* (depending on the setting, consider continuing until lesions are healed) |

**Indications for and efficacy of antiviral treatment for initial episodes of orolabial herpes in immunocompetent adults have not been defined, but the regimens used for initial genital episodes can be considered in individuals with severe disease; acyclovir 15 mg/kg (200 mg max) PO 5×/day ×7 days (initiated within 3 days of disease onset) has been shown to be beneficial in young children with primary herpes gingivostomatitis.*
***Not specifically FDA-approved for this indication.*
*†FDA-approved for ages 2–17 years; pharmacies can compound valacyclovir tablets into an oral suspension (25 or 50 mg/ml).*

**Table 67.3** *Continued* **Antiviral therapy for herpes simplex virus and varicella–zoster virus.**
d, day; h, hours; q, every.

3. **Ocular involvement (see Fig. 67.9H)**
   - Occurs in ~10% of patients, with 20–70% developing ocular disease (occasionally blindness)
   - Due to VZV reactivation in the first division of the trigeminal nerve ($V_1$)
   - Clues to its diagnosis include lesions in the $V_1$ distribution (see Fig. 67.10), which may be accompanied by unilateral eye pain or conjunctivitis
   - *Hutchinson sign* is the presence of vesicles at the tip, side, or bridge of the nose, indicating involvement of the nasociliary branch of the trigeminal nerve, which also innervates the cornea
   - Initial and longitudinal evaluation by ophthalmology is required
4. **Ramsay–Hunt syndrome (herpes zoster oticus)**
   - Due to VZV reactivation in the geniculate ganglion
   - Clues to its diagnosis: vesicles in the ear canal, tongue, and/or hard palate
   - Patients may have severe ear pain, acute facial nerve paralysis, and/or taste loss of the anterior two-thirds of the tongue
   - If the vestibulocochlear nerve is also affected, may have tinnitus, hearing loss, or vertigo
   - Consider referral to otolaryngology

| MAJOR CLINICAL FEATURES OF VARICELLA-ZOSTER VIRUS (VZV) INFECTIONS | | | |
|---|---|---|---|
| **VZV infection** | **Major clinical features** | **Complications (also see text)** | **DDx** |
| **Primary infection*: Varicella (chickenpox)**<br>Latency is established in the neuronal cells of dorsal root ganglia<br>~98% of adults worldwide are seropositive | • 11- to 20-day incubation period<br>• *Generalized prodrome* of mild fever, malaise, and myalgia, followed by an eruption of erythematous, pruritic macules and papules that develop central vesicles ("dew drops on a rose petal") and then evolve into pustules and crusts (see Fig. 67.8); lesions heal over 7–10 days<br>• Favors scalp and face first, with progression to trunk, extremities, and sometimes oral mucosa (see Fig. 67.8D)<br>• *Hallmark:* lesions in all stages of development (see Fig. 67.8A-C)<br>• Affected individual is contagious via airborne droplets and contact with vesicular fluid (until all lesions have crusted over)<br>• *Breakthrough varicella:* seen in previously immunized persons; characterized by a much milder course and often an atypical presentation, e.g. only a few papules or papulovesicles | ***Immunocompetent host***<br>**Most common:** secondary bacterial infection (especially staphylococcal and streptococcal), scarring<br>**Less common**: pneumonia<br>**Rare**: CNS (e.g. Reye syndrome, encephalitis); glomerulonephritis; optic neuritis; hepatitis<br>**Congenital varicella**: associated with multiple fetal abnormalities as well as cutaneous scarring<br>***Immunocompromised host***<br>• Significant morbidity and mortality with more extensive, atypical eruptions (e.g. hemorrhagic, purpuric) and an increased likelihood of CNS and visceral involvement (lung, liver) | • Vesicular viral exanthems (e.g. coxsackievirus, ECHO)<br>• PLEVA<br>• Disseminated HSV†<br>• Rickettsialpox<br>• Drug eruption<br>• Scabies<br>• Insect bites |
| **Reactivation infection**: Zoster (shingles)** | • *Localized (dermatomal) prodrome* of intense pain and dysesthesia, with subsequent development of cutaneous lesions<br>• Painful grouped vesicles on erythematous bases, developing within a sensory dermatome (see Figs 67.9 and 67.10)<br>• Most often on the trunk > face, neck, scalp, extremity<br>• Typically self-limited in children and young adults<br>• Occasionally localized dysesthesia but no cutaneous eruption ("*zoster sine herpete*") | ***Immunocompetent host***<br>• Postherpetic neuralgia (~10–15%)<br>• Local: secondary bacterial infection; scarring; motor paralysis<br>• Systemic (see below): occasionally pneumonitis<br>• Ophthalmic zoster (see Fig. 67.9H)<br>• Ramsay–Hunt syndrome<br>***Immunocompromised host*** (see Fig. 67.11)<br>• More severe and unusual presentations (e.g. persistent and verrucous lesions or postherpetic hyperhidrosis)<br>• Disseminated disease<br>• Visceral involvement: pneumonitis; meningoencephalitis; hepatitis | • Zosteriform HSV<br>• Localized contact dermatitis<br>• Bacterial skin infection (e.g. bullous impetigo, cellulitis) |
| Diagnosis is outlined in Table 67.1 | | | |

**Prevention is now a major focus: In the United States, all eligible children are recommended to receive the two-dose, live-attenuated VZV vaccine. Varicella IgG (VIG) given to immunocompromised hosts with first-time exposure; VIG given to neonates whose mothers became infected shortly before birth.*
***Prevention is now a major focus in the United States and United Kingdom; in 2017 the FDA approved a two-dose, adjuvanted recombinant VZV vaccine for individuals 50 years of age or older (efficacy is ~91–97%).*
*†Especially in immunocompromised hosts.*

**Table 67.4 Major clinical features of varicella–zoster virus (VZV) infections.** Treatment is outlined in Table 67.3. ECHO, enteric cytopathic human orphan; PLEVA, pityriasis lichenoides et varioliformis acuta.




**Fig. 67.8 Primary varicella–zoster virus (VZV) infection (varicella or chickenpox). A–C** Lesions in different stages of evolution, including vesicles, pustules, and hemorrhagic crusts. Vesicles often develop central umbilication. **D** Oral lesions can also occur (arrow). *A, B, Courtesy, Robert Hartman, MD; C, Courtesy, Julie V. Schaffer, MD; D, Courtesy, Judit Stenn, MD.*

## Epstein–Barr Virus (EBV or HHV-4)

- Table 67.5 and Figs 67.12 and 67.13.

## Cytomegalovirus (CMV or HHV-5)

- Table 67.6 and Fig. 67.14.

## Human Herpesvirus 6 and 7 (HHV-6 and HHV-7)

- Table 67.7 and Fig. 67.15.

## Human Herpesvirus 8 (Kaposi Sarcoma-Associated Herpesvirus [KSHV])

- Table 67.8 and Fig. 67.16.

For further information see Ch. 80 from *Dermatology, Fourth Edition*.

**For additional online figures and tables visit www.expertconsult.com**




**Fig. 67.9 Herpes zoster (shingles) infection. A, B** Erythematous, edematous plaques with early vesicle formation. Note the perifollicular accentuation **(B). C**, **D** Later stages of evolution with prominent pustule formation **(C)** and a dusky purple color associated with older vesicles **(D). E** Bullous variant on the flexor arm. **F–H** Facial herpes zoster. **F** In the distribution of $V_3$, grouped pustules on the left side of the chin and hemorrhagic crusting of the lower lip, with one lesion extending past the midline. This could be mistaken for an acneiform eruption or impetigo. **G** In the same patient, erosions are present on the left side of the tongue. The anterior two-thirds of the tongue is innervated by the facial nerve (VII; taste) as well as $V_3$ (sensory). **H** Ophthalmic zoster ($V_1$) with sharp midline demarcation of erythema and crusts on the forehead as well as contralateral periorbital edema. *A, D, E, H, Courtesy, YDRSC; B, Courtesy, Jean L. Bolognia, MD; C, Courtesy, Louis A. Fragola, Jr., MD; F, G, Courtesy, Kalman Watsky, MD.*

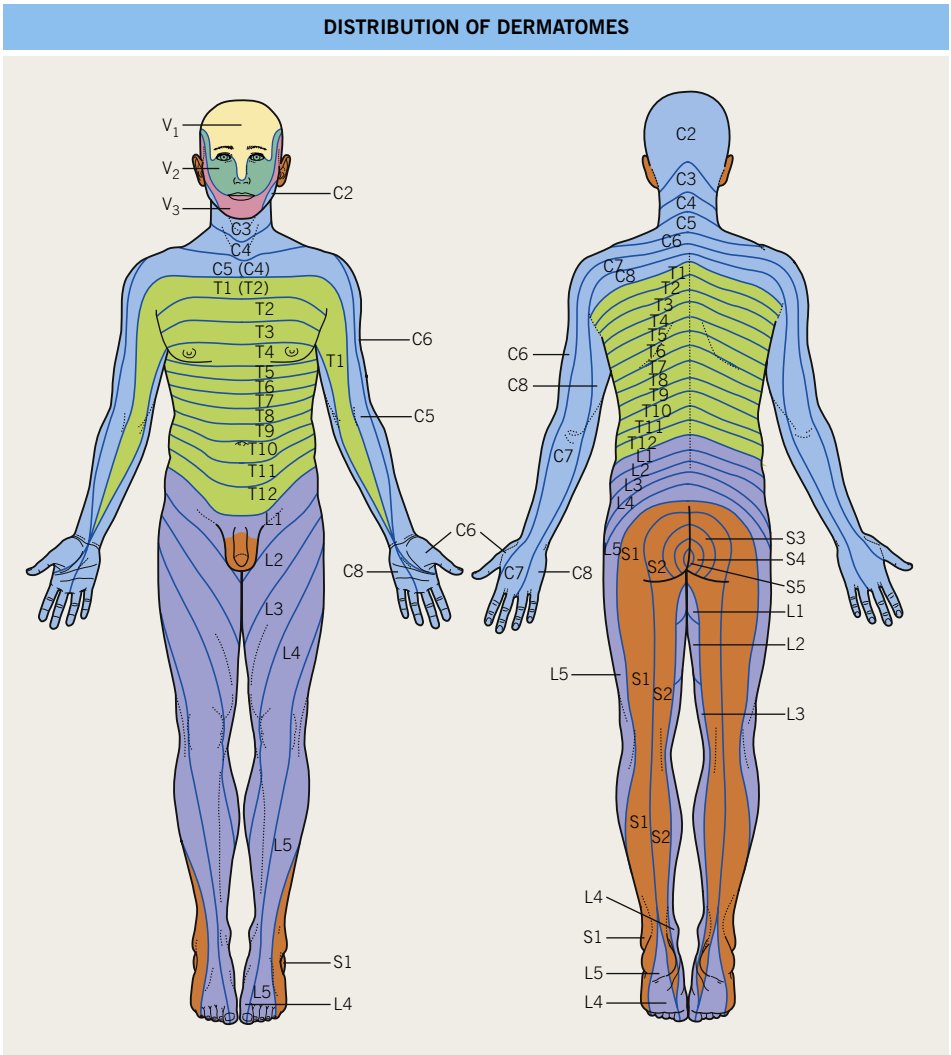


**Fig. 67.10 Distribution of dermatomes.**

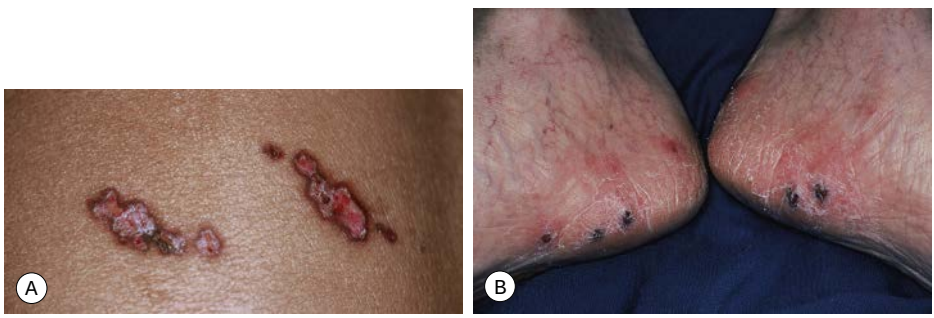


**Fig. 67.11 Herpes zoster (shingles) in immunocompromised hosts. A** Chronic verrucous zoster in an HIV-infected patient. **B** Disseminated cutaneous zoster with multiple violet-black papules on the feet. Patients with disseminated cutaneous skin lesions should be evaluated for possible CNS or visceral involvement, e.g. hepatic, pulmonary, especially if they are immunocompromised. *Courtesy, YDRSC.*

| MAJOR CLINICAL FEATURES OF EPSTEIN–BARR VIRUS (EBV) INFECTIONS | | | |
|---|---|---|---|
| **EBV infection** | **Major clinical features** | **Complications** | **DDx** |
| **Primary infection*: Infectious mononucleosis (IM)**<br>Latency is established in B lymphocytes<br>~95% of adults worldwide are seropositive | • Long, 30- to 50-day incubation period; usually asymptomatic in children, but symptomatic in adolescents and young adults<br>• *Generalized prodrome* of headache, malaise, fatigue<br>• *Classically,* ~80% present with triad of fever, pharyngitis, and lymphadenopathy<br>• *Other clinical findings*: exudative tonsillitis, splenomegaly (50%), lymphocytosis with atypical lymphocytes, mild hepatitis<br>• *Cutaneous eruption:* onset ~day 4 and lasts several days; most often a faint, nonspecific exanthem on trunk and proximal extremities, with spread to face and forearms<br>• Occasionally eyelid, palatal, and cutaneous petechiae<br>• Less often genital ulcers (see Fig. 67.12), Gianotti–Crosti syndrome, urticaria > erythema multiforme, erythema nodosum | **Common, *not* serious:** antibiotic-induced hypersensitivity reaction (most often with penicillins or cephalosporins); this is not a true allergic reaction and typically safe for that patient to take the antibiotic in the future (see Fig. 67.13)<br>**Rare, but serious**: splenic rupture, especially post-traumatic; airway and oral compromise from oropharyngeal lymphoid tissue swelling<br>**Other**: severe hepatitis; thrombocytopenia; hemolytic anemia; glomerulonephritis; CNS (e.g. encephalitis, aseptic meningitis) | **Oro-cutaneous**<br>• Primary CMV, HHV-6, or HIV infections<br>• Drug eruption (e.g. DRESS/DIHS)<br>**Pharyngitis**<br>• Group A *Streptococcus* infection<br>**Other**<br>• Acute viral hepatitis<br>• Lymphoma<br>• Toxoplasmosis |
| **Reactivation infection**: EBV lymphoproliferative disorders** | ***In United States***: B-cell lymphoma; lymphoproliferative disorders in immunocompromised hosts (e.g. solid organ transplant recipients; HIV (+) infection; and taking immunosuppressive medications, classically methotrexate and/or infliximab in the setting of rheumatoid arthritis)<br>***Worldwide*:** Hydroa vacciniforme, necrotic hypersensitivity to mosquito bites, African (endemic) Burkitt lymphoma, nasopharyngeal carcinoma | | • Other cutaneous and systemic lymphomas (see Chs 97–99) |

*Diagnosis of suspected ***primary EBV infection*** is confirmed by a positive heterophile antibody test ("Monospot" test); if the heterophile antibody test is negative but IM is still suspected (e.g. early in the course of disease [≤6 weeks]) or in younger children (<2 years), then consider: repeat heterophile antibody testing, EBV-specific serologies, and/or EBV DNA levels.

**Diagnosis of a suspected ***EBV lymphoproliferative disorder*** is confirmed by the presence of elevated circulating EBV DNA levels.

**Table 67.5 Major clinical features of Epstein–Barr virus (EBV) infections.** Treatment of primary EBV infection is primarily supportive; treatment of EBV lymphoproliferative disorders is focused on reversing the host's immunosuppressed state, if possible.



**Fig. 67.12 Vulvar ulcers associated with primary EBV infection.** EBV-related genital ulcers, which are most common in adolescent girls, are often misdiagnosed as genital herpes simplex infection and in some patients represent a variant of aphthosis. *Courtesy, YDRSC.*



**Fig. 67.14 TORCH syndrome due to cytomegalovirus.** Multiple firm, red-violet papules of dermal erythropoiesis. *Courtesy, Mary S. Stone, MD.*



**Fig. 67.15 Exanthem subitum (roseola infantum).** Small pink-red macules and papules developed on the trunk and neck of this 9-month-old boy during defervescence of a high fever that lasted 5 days. *Courtesy, Julie V. Schaffer, MD.*



**Fig. 67.13 Ampicillin-induced eruption in a patient with infectious mononucleosis due to Epstein–Barr virus infection.** Erythematous macules and papules have become confluent on the upper trunk. *Courtesy, YDRSC.*



**Fig. 67.16 Classic Kaposi sarcoma.** Multiple red-violet nodules with hemorrhagic crusting and plaques on the ankle and foot. *Courtesy, Joyce Rico, MD.*

| MAJOR CLINICAL FEATURES OF CYTOMEGALOVIRUS (CMV) INFECTIONS | | | |
|---|---|---|---|
| **CMV infection*** | **Major clinical features** | **Complications** | **DDx of skin lesions** |
| **Primary infection**<br>Latency is established primarily in monocytes and macrophages<br>~40–100% of adults are seropositive | • 4–8 week incubation period<br>**Immunocompetent hosts**<br>• >90% are subclinical and in children > adults<br>• Occasionally (adults > children) presents as a mononucleosis-like syndrome; usually less severe, no exudative tonsillitis, and heterophile antibody (–); in those patients, ~33% have a morbilliform or petechial eruption<br>**Congenital and neonates**<br>• ~5–10% of infected neonates present with jaundice, IUGR, thrombocytopenia, chorioretinitis, and petechiae or the papules of extramedullary hematopoiesis ("blueberry muffin" lesions) (see Fig. 67.14)<br>**AIDS patients**<br>• Chorioretinitis, esophagitis, colitis, pneumonitis<br>• Rarely, chronic perineal and lower extremity ulcerations<br>**Organ transplant recipients**<br>• Gastrointestinal involvement and pneumonitis | **Immunocompetent hosts:** rarely colitis, encephalitis, myocarditis, and anterior uveitis<br>**Congenital and neonates:** congenital deafness; intellectual disability<br>**AIDS patients:** blindness | **Immunocompetent hosts**<br>• Other mononucleosis-like syndromes (e.g. EBV, HHV-6, toxoplasmosis)<br>• Morbilliform drug eruption<br>• Other causes of petechiae (see Ch. 18)<br>**Congenital and neonates**<br>• Other causes of TORCH |
| **Reactivation infection** | • May result from reactivation of latent CMV (greatest risk in immunosuppressed hosts) or from reinfection with a novel exogenous strain of CMV<br>• Overall rare in immunocompetent hosts<br>• Clinical presentations are similar to those described in primary CMV infections | | |

**Diagnosis is made via various techniques: (1) serologies (e.g. IgM and IgG antibodies); (2) various molecular amplification techniques (e.g. PCR); (3) cultures (helpful to determine if drug resistance is present); (4) CMV antigenemia assays (helpful in immunosuppressed hosts); (5) biopsy of cutaneous lesions (e.g. ulcerations) may show characteristic findings of enlarged endothelial cells with prominent intranuclear inclusions ("owl's eyes").*

**Table 67.6 Major clinical features of cytomegalovirus (CMV) infections.** Treatment of uncomplicated CMV infection in immunocompetent hosts is primarily supportive; treatment in immunocompromised hosts or in those with complicated infections involves systemic therapy (e.g. intravenous ganciclovir, oral valganciclovir, cidofovir, foscarnet). Prevention is possible by matching CMV serologies between donor and transplant recipients. IUGR, intrauterine growth retardation; TORCH, toxoplasmosis, other agents, rubella, cytomegalovirus, herpes simplex virus.

| MAJOR CLINICAL FEATURES OF HUMAN HERPESVIRUS 6 AND 7 (HHV-6 AND HHV-7) INFECTIONS | | | |
|---|---|---|---|
| **Infection** | **Primary infection** | **Reactivation infection** | **DDx** |
| **HHV-6*** <br>Latency is established in T lymphocytes <br>~70–90% of adults are seropositive | • Usually acquired between 6 months and 2 years of age <br>• ~30% of children develop observable clinical manifestations <br>• Febrile seizures may occur in infants <br>**Clinical presentations** <br>***Exanthem subitum (roseola, sixth disease)*** <br>• 3–5 days of high fever followed by cutaneous eruption as fever fades (see Fig. 67.15) <br>• Discrete circular "rose red," 2- to 5-mm macules or maculopapules, often surrounded by a white halo <br>• Enanthem of red papules on soft palate (Nagayama spots) <br>• Late, may see palpebral edema <br>***Febrile syndrome without a cutaneous eruption*** <br>***Mononucleosis-like syndrome in adults*** | **Seen primarily in immunosuppressed hosts** <br>• Fever, cutaneous eruption, hepatitis, pneumonitis, bone marrow suppression, encephalitis, colitis <br>• Also implicated in DRESS/DIHS syndrome and possibly pityriasis rosea | ***Exanthem subitum*** <br>• Other viral exanthems (see Ch. 68); Kawasaki disease (if fever persists after appearance of eruption) <br>***Mononucleosis-like syndrome*** <br>• EBV, CMV, toxoplasmosis |
| **HHV-7**** <br>Latency is established in T lymphocytes <br>~85% of U.S. adults are seropositive | • Usually acquired in the first 5 years of life, peaking at about age 3 years <br>• Usually asymptomatic <br>• Can cause *exanthem subitum*, but is less common than HHV-6 <br>• Potential complications include febrile seizures and acute hemiplegia | • Implicated in DRESS/DIHS syndrome and possibly pityriasis rosea | • See above, under *exanthem subitum* |

*Diagnosis of HHV-6 is clinical in most cases of classic exanthema subitum in children; laboratory investigation with serologies and seroconversion data (e.g. IgM and IgG antibodies and titers) or detection of HHV-6 DNA in clinical/tissue specimens is reserved for atypical presentations and complications or in immunosuppressed hosts.
**Serologic tests and quantitative PCR may be useful for immunosuppressed hosts.

**Table 67.7 Major clinical features of human herpesvirus 6 and 7 (HHV-6 and HHV-7) infections.** No definitive treatment is available.

| MAJOR CLINICAL FEATURES OF HUMAN HERPESVIRUS 8 (HHV-8) INFECTIONS | | |
|---|---|---|
| **HHV-8 infection** | **Major clinical features** | **DDx** |
| **Primary infection**<br>Latency is established in B lymphocytes and vascular endothelial cells | **Children**<br>• Fever and morbilliform eruption<br>**Men who have sex with men (MSM)**<br>• New-onset lymphadenopathy, fatigue, diarrhea, and a localized cutaneous eruption<br>**Immunosuppressed hosts (e.g. solid organ transplant recipients, HIV (+) infection)**<br>• Fever, splenomegaly, lymphoid hyperplasia, pancytopenia<br>• Occasionally rapid-onset KS | |
| **Reactivation infection** | **Kaposi sarcoma (KS) (four subtypes)**<br>• Cutaneous lesions progress through stages as red, brown, or violaceous papules, plaques, and nodules<br>1. ***Classic KS*** (see Fig. 67.16)<br>• Indolent; primarily seen in elderly males of Mediterranean and Jewish descent; favors the lower extremities<br>2. ***African-endemic KS***<br>• Seen in equatorial Africa; primarily in children and young adults; more aggressive than classic KS; may disseminate to lymph nodes, bone, or skin<br>3. ***Iatrogenic immunosuppression-associated KS***<br>• Most often seen in solid organ transplant recipients; similar to AIDS-related KS; may be acquired from the donor or transplanted tissue; typically regresses with reduction of immunosuppression medications or a change to sirolimus<br>4. ***AIDS-related KS***<br>• Typically presents with more widely distributed lesions on the skin and internally (e.g. lungs, GI tract); can improve with ART treatment, but can also flare as part of IRIS<br>**Primary effusion lymphoma**<br>• B-cell lymphoma<br>**Multicentric Castleman disease**<br>• Lymphoproliferative disorder characterized by fever, hepatosplenomegaly, and massive lymphadenopathy | **KS (lower extremity)**<br>• Acroangiodermatitis (pseudo-KS)<br>• Lymphoma<br>• Ecchymoses<br>**KS (more widespread distribution)**<br>• Bacillary angiomatosis<br>• Ecchymoses<br>• Other vascular tumors and hyperplasias (see Ch. 94)<br>• Lymphoma |
| The optimal serologic assay for diagnosis of HHV-8 is not known; when cutaneous lesions are present, a skin biopsy for histochemical analysis for LANA-1 can be diagnostic. | | |
| *HHV-8 is also known as Kaposi sarcoma (KS)-associated herpesvirus. Treatment of KS involves reconstitution of the host's immune system (e.g. decrease immunosuppressive therapy, ART, change to sirolimus); systemic and intralesional chemotherapy; radiation therapy; cryotherapy.* | | |

**Table 67.8 Major clinical features of human herpesvirus 8 (HHV-8) infections.** IRIS, immune reconstitution inflammatory syndrome.



**eFig. 67.1 Primary genital herpes.** Grouped vesicles on an erythematous base. *Courtesy, Stephen K. Tyring, MD*.







**eFig. 67.2 Reactivation of herpes simplex virus (HSV) infections. A** Grouped vesiculopustules on the buttock, a common location for women. **B** Intact, grouped vesicles on the penis. Note the genital wart at the base of the penis. *Courtesy, Louis A. Fragola, Jr., MD.*



**eFig. 67.3 Herpetic whitlow on the finger of a child.** *Courtesy, Eugene Mirrer, MD.*

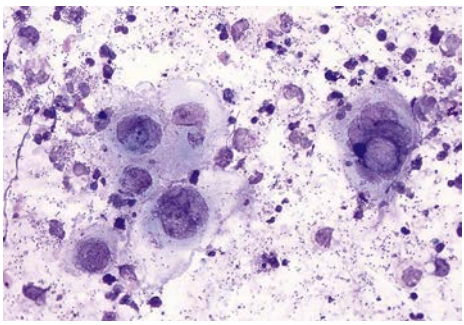

**eFig. 67.4 Tzanck smear.** Note the multinucleated epithelial giant cells from a patient with herpes simplex viral infection. *Courtesy, Louis A. Fragola, Jr., MD.*

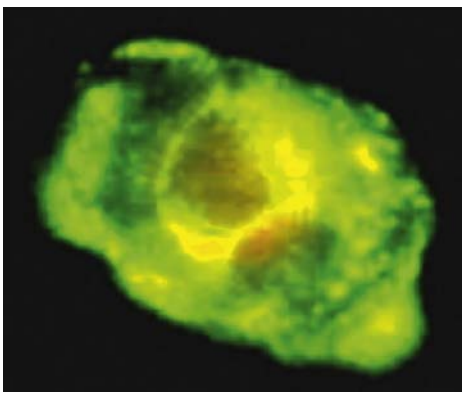

**eFig. 67.5 Direct fluorescent antibody assay.** A keratinocyte that is infected with herpes simplex virus fluoresces green. This assay can also detect the presence of varicella–zoster virus and it has a rapid turnaround time. *Courtesy, Marie L. Landry, MD.*

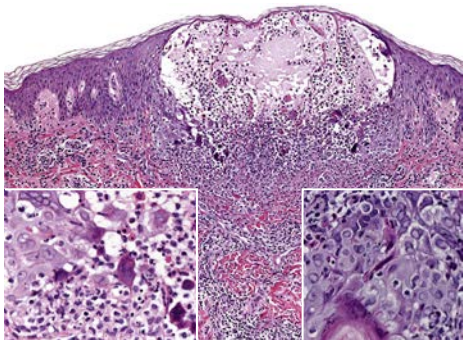

**eFig. 67.6 Histopathology of herpes simplex viral infection.** Intraepidermal vesicle with ballooning degeneration of keratinocytes and multinucleated giant cells; the latter arise from the fusion of infected keratinocytes. Note the steel-gray nuclei with margination of chromatin and inclusions (inset). *Courtesy, Lorenzo Cerroni, MD.*




**eFig. 67.7 Varicella. A, B** Note the lesions in different stages of evolution. *A, Courtesy, Julie V. Schaffer, MD; B, Courtesy, Stephen K. Tyring, MD.*




**eFig. 67.8 Herpes zoster. A** Erythematous edematous plaques with early vesicle formation. **B, C** Facial herpes zoster. Clustered vesicles in a linear array within the distribution of $V_1$ (**B**). Focal hemorrhagic crusting with scalloped borders arising in an erythematous patch on the forehead (**C**) within the $V_1$ distribution. Note the periorbital edema. *A, Courtesy, Louis A. Fragola, Jr., MD; B, C, Courtesy, Kalman Watsky, MD.*



**eFig. 67.9 Granulomatous dermatitis in the site of previous herpes zoster.** Pink papules and plaques developed several weeks after an episode of herpes zoster in the same dermatomes. A sharp midline demarcation was observed on the back. Histopathologically, a granulomatous dermatitis was present within the dermis and focally a perineural distribution pattern was seen. *Courtesy, Rebecca Vaughn, MD.*



**eFig. 67.11 Genital ulcers associated with primary EBV infection.** Extreme pain with urination required placement of a Foley catheter in this 13-year-old girl. EBV-related genital ulcers are often misdiagnosed as a genital herpes simplex virus infection. *Courtesy, Julie V. Schaffer, MD.*




**eFig. 67.10 Herpes zoster following varicella vaccination.** This healthy 3-year-old boy developed an eruption of erythematous papulovesicles in the C5 and C6 dermatomes of the right arm. He had received the varicella vaccine in the right shoulder at age 12 months, and several erythematous, edematous papulonodules had appeared in the region of the injection 2 weeks later. *Courtesy, Julie V. Schaffer, MD.*

| DOSE REDUCTIONS FOR ACYCLOVIR, VALACYCLOVIR AND FAMCICLOVIR IN PATIENTS WITH RENAL DISEASE | | | | | | |
|---|---|---|---|---|---|---|
| | Acyclovir | | Valacyclovir | | Famciclovir | |
| **Indication** | **Creatinine clearance (ml/min)** | **Adjusted dose** | **Creatinine clearance (ml/min)** | **Adjusted dose** | **Creatinine clearance (ml/min)** | **Adjusted dose** |
| Primary genital herpes simplex | <10 | 200 mg PO BID | 10–29 | 1 gm daily | 20–39 | 125 mg BID |
| | | | <10 | 500 mg daily | <20 | 125 mg daily |
| Recurrent genital herpes simplex | | | <30 | 500 mg daily | 40–59 | 500 mg BID × 1 day |
| | | | | | 20–39 | 500 mg once |
| | | | | | <20 | 250 mg once |
| Chronic suppression of herpes simplex | | | <30 | 500 mg q48 h or daily | 20–39 | 125 mg BID |
| | | | | | <20 | 125 mg daily |
| Recurrent orolabial herpes simplex | <10 | 200 mg PO BID* | 30–49 | 1 gm BID × 1 day | 40–59 | 750 mg once |
| | | | 10–29 | 500 mg BID × 1 day | 20–39 | 500 mg once |
| | | | <10 | 500 mg once | <20 | 250 mg once |
| Herpes zoster | 10–25 | 800 mg PO TID | 30–49 | 1 gm BID | 40–59 | 500 mg BID |
| | <10 | 800 mg PO BID | 10–29 | 1 gm daily | 20–39 | 500 mg daily |
| | | | <10 | 500 mg daily | <20 | 250 mg daily |
| Immunocompromised patients with mucocutaneous herpes simplex; for IV acyclovir, also herpes encephalitis and disseminated zoster | 25–50 | 5–10 mg/kg IV q12 h | | | | |
| | 10–24 | 5–10 mg/kg IV q24 h | 10–29 | 1 gm daily* | 20–39 | 500 mg daily* |
| | <10 | 2.5–5 mg/kg IV q24 h | <10 | 500 mg daily* | <20 | 250 mg daily* |

*Not specifically FDA-approved for this indication.*

**eTable 67.1 Dose reductions for acyclovir, valacyclovir, and famciclovir in patients with renal disease.** In hemodialysis patients, the medication should be administered after dialysis. h, hours; q, every.

| CLINICAL FINDINGS RELATED TO THE DERMATOME INVOLVED IN HERPES ZOSTER | | |
|---|---|---|
| **Dermatome/nerve involved** | **Cutaneous findings** | **Extracutaneous findings** |
| Ophthalmic division of the trigeminal nerve ($V_1$; ~10–15% of zoster patients) | *Hutchinson's sign* refers to increased risk of ocular involvement if skin lesions are in the distribution of the nasociliary branch, which supplies the nasal tip, dorsum and root of the nose, and medial canthus as well as the cornea | • ~50% of patients have ocular involvement, which can include conjunctivitis, (epi)scleritis, keratitis, uveitis, acute retinal necrosis, and optic neuritis<br>• May lead to ocular scarring and visual loss |
| Geniculate ganglion of the facial nerve – *Ramsay Hunt syndrome* | Lesions affecting the external auditory canal, tympanic membrane, anterior two-thirds of the tongue, and/or hard palate | • Ear pain<br>• Facial nerve paralysis (peripheral)<br>• Loss of taste in anterior two-thirds of the tongue<br>• Dry mouth and eyes<br>• If the vestibulocochlear nerve is also affected: tinnitus, hearing loss and/or vertigo |
| Cervical dermatome | Lesions in cervical dermatome | • Peripheral motor neuropathy of the arm, which may result in muscle atrophy with gradual recovery of strength<br>• Diaphragmatic weakness (C3–5) |
| Thoracic dermatome | Lesions in thoracic dermatome | • Abdominal muscle weakness<br>• Abdominal wall pseudohernia |
| Lumbar dermatome | Lesions in lumbar dermatome | • Peripheral motor neuropathy of the leg, which may result in muscle atrophy with gradual recovery of strength |

**eTable 67.2 Clinical findings related to the dermatome involved in herpes zoster.**

| CUTANEOUS DISORDERS THAT CAN DEVELOP WITHIN SITES OF HERPES ZOSTER |
|---|
| ***Acneiform*** – comedones, furunculosis, "acneiform eruption", rosacea (trigeminal distribution)<br>***Dermatitis and urticaria*** – contact dermatitis (allergic and irritant), chronic localized urticaria<br>***Granulomatous*** – granuloma annulare (including perforating variant), granulomatous dermatitis (sarcoidal, tuberculoid, unclassified, periadnexal, perineural), granulomatous vasculitis, lichenoid and granulomatous dermatitis*<br>***Infiltrative*** – pseudolymphoma†, xanthomatous, Rosai–Dorfman disease<br>***Malignancies, hematologic*** – leukemia (especially CLL), lymphoma cutis**<br>***Malignancies, other*** – Kaposi sarcoma (HIV-associated form), angiosarcoma, solid-organ metastases<br>***Papulosquamous*** – psoriasis, lichen planus, lichenoid GVHD*<br>***Sclerosing*** – lichen sclerosus, morphea, hypertrophic scars/keloids<br>***Ulcerative*** – trophic syndrome (trigeminal, cervical)<br>***Miscellaneous –*** acquired perforating disorder (acquired perforating collagenosis), nodular solar degeneration, tinea, bullous pemphigoid |
| **"Giant cell lichenoid dermatitis" has also been described within herpes zoster scars in an allogeneic bone marrow transplant recipient.*<br>***Some solid organ metastases may show a zosteriform arrangement of the lesions without history of previous herpes zoster.*<br>†*In patients with chronic lymphocytic leukemia, a diagnosis of "pseudolymphoma" should be made only if leukemia cutis has been excluded.* |

**eTable 67.3 Cutaneous disorders that can develop within sites of herpes zoster.** The phenomenon of a new, unrelated disease appearing in the same location as a previously healed disease is referred to as the *Wolf isotopic response.* This list does not include routine scarring and acute complications such as bacterial infections. Additional possible associations include basal cell carcinoma and squamous cell carcinoma. CLL, chronic lymphocytic leukemia.

| EBV-ASSOCIATED DISORDERS |
|---|
| Infectious mononucleosis |
| Gianotti–Crosti syndrome |
| Genital ulcers* |
| Periodontal disease |
| Oral hairy leukoplakia |
| Hydroa vacciniforme and related conditions |
| • Typical hydroa vacciniforme |
| • Severe hydroa vacciniforme-like eruptions** |
| • Hydroa vacciniforme-like lymphoproliferative disorder† |
| Severe hypersensitivity to mosquito bites* |
| Lymphadenitis, including Kikuchi disease |
| Lymphoproliferative disorders and lymphomas |
| • Post-transplant lymphoproliferative disorder/lymphoma |
| • Methotrexate-associated lymphoproliferative disorder (usually in patients with rheumatoid arthritis) |
| • Systemic EBV+ T-cell lymphoma of childhood |
| • EBV+ mucocutaneous ulcer |
| • X-linked lymphoproliferative syndrome |
| • Hemophagocytic lymphohistiocytosis (susceptibility to develop) |
| • Lymphomatoid granulomatosis |
| • Burkitt lymphoma, endemic » sporadic |
| • Extranodal NK/T-cell lymphoma, nasal type |
| • EBV+ diffuse large B-cell lymphoma, NOS |
| • Angioimmunoblastic T-cell lymphoma |
| • Other non-Hodgkin lymphomas (including T-cell), particularly in HIV-infected patients |
| • Hodgkin disease |
| Other malignancies |
| • Nasopharyngeal carcinoma |
| • Gastric carcinoma |
| • Leiomyosarcoma |
| Smooth muscle tumors |
| **There may or may not be evidence of EBV within the ulcer; reactive non-sexually related acute genital ulcers (formerly referred to as Lipschütz ulcers) can be triggered by EBV and other infections (e.g. cytomegalovirus, influenza,* Mycoplasma pneumoniae*), most often in adolescent girls; this is thought to represent a form of aphthosis, which may be recurrent and associated with a history of oral aphthous ulcers.* |
| ***Present with bullous, necrotic and ulcerative skin lesions together with fever, lymphadenopathy, hepatosplenomegaly and natural killer (NK)-cell lymphocytosis.* |
| *†Can progress to a T- or NK-cell lymphoma or hemophagocytic lymphohistiocytosis.* |

**eTable 67.4 EBV-associated disorders.** Other skin conditions that are only occasionally associated with EBV include erythema nodosum, urticaria, erythema multiforme, erythema annulare centrifugum, DRESS, small vessel vasculitis, granuloma annulare-like eruptions, and pityriasis lichenoides. NOS, not otherwise specified.

| EBV SEROLOGIES | | | | | |
|---|---|---|---|---|---|
| **Antibody** | **Timing of appearance** | **Timing of disappearance** | **Acute primary infection** | **Past/latent infection** | **Reactivated (RA)/chronic active (CA)* infection** |
| VCA IgM | Prior to onset of symptoms | Usually within 3 months | Positive | Negative | Negative in RA/variable in CA |
| VCA IgG | With onset of symptoms | Persists for life | Positive | Positive | Positive |
| EA IgG† | With onset of symptoms | Usually within 3–6 months; positive if active infection‡ | Positive | Negative‡ | Positive |
| EBNA IgG | 1–6 months after onset of symptoms, upon establishment of latency | Persists for life | Negative | Positive | Positive in RA/variable in CA |

**Associated with hemophagocytic lymphohistiocytosis, lymphoproliferative disorders, and lymphomas.*
*†Not usually included in routine serologic testing.*
*‡Persists following resolution of infection in ~20% of healthy individuals.*

**eTable 67.5 EBV serologies.** EA, early antigen; EBNA, EBV nuclear antigen; VCA, viral capsid antigen.

| CUTANEOUS MANIFESTATIONS OF CMV INFECTIONS |
|---|
| **Immunocompetent host** |
| **Mononucleosis-like syndrome** |
| • Maculopapular/morbilliform eruption<br>• Petechiae and purpura<br>• Ampicillin-induced eruption<br>• Urticaria<br>• Erythema nodosum |
| **Congenital infections** |
| • "Blueberry muffin" lesions (extramedullary hematopoiesis; see Ch. 99)<br>• Petechiae and purpura<br>• Vesicles |
| **Immunocompromised host** |
| Cutaneous vasculitis<br>Maculopapular/morbilliform eruption<br>Petechiae and purpura<br>Ulcers<br>Vesicles<br>Verrucous plaques<br>Nodules and hyperpigmented plaques |

**eTable 67.6 Cutaneous manifestations of CMV infections.**

# 68 Other Viral Diseases

Viral infections frequently have cutaneous manifestations, especially in children. This chapter covers classic childhood exanthems, poxvirus infections, and several other viral infections with characteristic skin findings. *Nonspecific viral exanthems*, typically presenting with blanchable erythematous macules and papules in a widespread distribution, are also common in children infected with enteroviruses (see below) and a variety of respiratory viruses, generally resolving spontaneously within a week. Fig. 68.1 outlines clinical features to consider when evaluating a patient with a morbilliform ("maculopapular") exanthem, and Chapter 3 addresses considerations in patients with fever and a rash. HIV, human papillomavirus, and herpesvirus (including infectious mononucleosis and roseola infantum) infections are discussed in Chapters 65–67.

## Enterovirus Infections

- Non-polio enteroviruses (e.g. coxsackieviruses, echoviruses) are single-stranded RNA picornaviruses with a worldwide distribution; they cause a variety of exanthems, enanthems, and systemic manifestations.
- Spread via fecal–oral (e.g. swimming pools, ingestion of oysters) and respiratory routes, with an incubation period of 3–6 days; most common in the summer and fall in temperate climates, favoring young children.
- *Hand-foot-and-mouth disease* (HFMD; in the United States, coxsackievirus A16 and A6 > others) features oval vesicles on the hands and feet (palms/soles > dorsally) and buttocks plus an erosive stomatitis (e.g. tongue, buccal mucosa, palate, tonsils), often associated with fever and malaise (Fig. 68.2A–C); onychomadesis occasionally occurs 1–2 months later.
- Coxsackievirus A6 infection can produce a more widespread vesiculobullous exanthem favoring the perioral area > oral mucosa, extremities > trunk, and areas of previous dermatitis ("eczema coxsackium") or injury as well as the classic sites of HFMD (Fig. 68.2D–F; see Fig. 3.6B–D).
- *Herpangina* presents with fever and oropharyngeal erosions, but usually no exanthem.
- The diverse spectrum of enteroviral exanthems also includes morbilliform, scarlatiniform, Gianotti–Crosti syndrome-like, petechial, and pustular eruptions (see Fig. 3.6A); eruptive pseudoangiomatosis is an uncommon manifestation.
- Organ systems that can be affected by enteroviral infections include the respiratory (upper > lower) and gastrointestinal tracts, liver, CNS (meningitis > encephalitis; especially with enterovirus 71), eyes (hemorrhagic conjunctivitis), joints, muscles, and heart.
- Spontaneous resolution typically occurs within 1–2 weeks.

## Measles (Rubeola)

- Incidence has decreased dramatically since introduction of a live vaccine for this single-stranded RNA paramyxovirus in 1963; however, measles outbreaks still occur in both low- and high-income countries, often because of unfounded fears of vaccination.
- Highly contagious and spread by respiratory droplets, with an incubation period of 10–14 days.
- Prodrome of fever, *c*ough, *c*oryza, and *c*onjunctivitis (the 3 Cs), followed in 2–4 days by the appearance of pathognomonic Koplik spots (gray-white papules on the buccal mucosa).
- An exanthem develops 3–5 days after the onset of symptoms, with erythematous macules and papules spreading cephalocaudally from the forehead, hairline, and behind the ears to the trunk and extremities (Fig. 68.3); after 5 days, the eruption fades in the order it appeared.

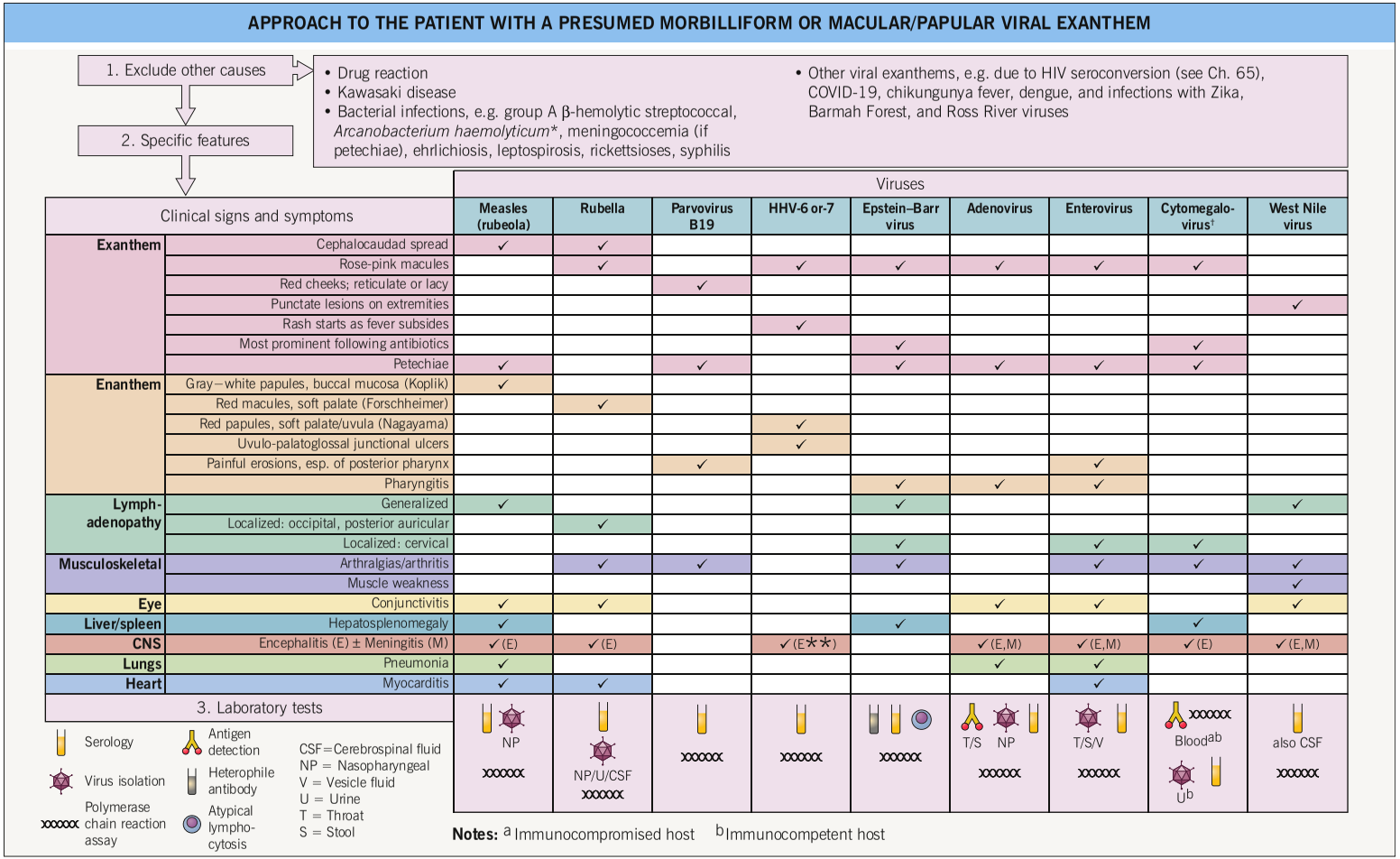


**Fig. 68.1 Approach to the patient with a presumed morbilliform or macular/papular viral exanthem.** *Gram-positive rod; may result in severe pharyngitis and scarlatiniform exanthem in adolescents and young adults. †Intracellular inclusions in endothelial cells are another finding. **Usually febrile seizures.

- Complications include otitis media, pneumonia, and encephalitis; subacute sclerosing panencephalitis occasionally develops 5–10 years later.
- *Atypical measles* in the setting of partial immunity features high fevers, cough, and a variable exanthem that may be vesicular, petechial, or associated with acral edema.
- **Rx:** vitamin A administration for children with acute disease; prevention via vaccination.

## Rubella (German Measles)

- Incidence has markedly declined since introduction of a live vaccine for this single-stranded RNA togavirus in 1969.
- Spread via respiratory droplets, with an incubation period of 16–18 days.
- Mild prodrome of fever, headache, and upper respiratory symptoms, followed in 1–5 days




**Fig. 68.2 Hand-foot-and-mouth disease (HFMD). A** Oval vesicle and erythematous macules on the plantar surface. **B** Multiple erythematous macules on the palm, some with a dusky appearance reminiscent of erythema multiforme. **C** Small oval erosions on the buccal mucosa resembling aphthae. **D** Coxsackievirus A6 infection presenting as vesicles and papulovesicles in a widespread distribution including the thigh. *Continued*



**Fig. 68.2** *Continued* **Hand-foot-and-mouth disease (HFMD).** Coxsackievirus A6 infection presenting as: perioral monomorphic crusted lesions resembling eczema herpeticum (**E**); and more extensive "eczema coxsackium" in a toddler with atopic dermatitis (**F**). *A, B, D–F, Courtesy, Julie V. Schaffer, MD; C, Courtesy, Kalman Watsky, MD.*

by an eruption of erythematous macules and papules that spreads downward from the face and lasts ~3 days; Forchheimer spots (red or petechial macules on the soft palate) and tender lymphadenopathy (especially occipital and posterior auricular) are characteristic findings.

- Although usually self-limited, complications include arthralgias/arthritis (especially in adolescent girls and women), thrombocytopenia, and encephalitis.
- *Congenital rubella syndrome*, most common with maternal infection in the first 16 weeks of pregnancy; can result in cataracts, deafness, congenital heart defects, and microcephaly; a "blueberry muffin baby" presentation occasionally occurs (see Fig. 67.14).



**Fig. 68.3 Measles.** Pink macules and minimally elevated papules. *Courtesy, Louis A. Fragola, Jr., MD.*

## Parvovirus B19 Infection (Erythema Infectiosum, Fifth Disease, "Slapped Cheek Disease")

- Single-stranded DNA virus with tropism for erythroid progenitor cells; found worldwide.
- Transmitted via respiratory secretions and blood products as well as vertically from mother to fetus, with an incubation period of 4–14 days; peak incidence in the winter and spring, favoring children 4–10 years of age.
- A mild prodrome (e.g. low-grade fever, myalgias, headache) is followed in 7–10 days by bright red, macular erythema on the cheeks; a few days later, a lacy, reticulated pattern of erythematous macules and papules may appear on the extremities > trunk, lasting 1–3 weeks and fluctuating in intensity (with flares upon sun exposure and overheating) (Fig. 68.4).
- *Papular–purpuric gloves and socks syndrome* (parvovirus B19 > other viruses) features painful acral edema, erythema, and petechiae/purpura (especially on the palms and soles; Fig. 68.5).
- More widespread petechial eruptions and an enanthem (petechiae, erosions) can also occur.
- Complications include arthritis/arthralgias favoring small joints of the hands (especially in young adults) and aplastic

anemia > pancytopenia in susceptible individuals (e.g. with red blood cell disorders or immunosuppression).

- *Fetal parvovirus B19 infection* may lead to self-limited anemia, hydrops fetalis (extensive edema), or miscarriage/stillbirth (2–6%, especially if in first half of pregnancy).
- **Rx:** NSAIDs for arthropathy, RBC transfusions for severe aplastic crises, serial fetal ultrasonography for infections during the first two trimesters of pregnancy.

## Unilateral Laterothoracic Exanthem (Asymmetric Periflexural Exanthem of Childhood)

- A consistent causative infectious agent has not been identified.
- Most often occurs in the spring and favors preschool-aged children.
- Morbilliform or eczematous eruption that begins unilaterally (axilla > trunk or thigh) and then spreads to contralateral sites (Fig. 68.6).
- Often pruritic and may be preceded by upper respiratory or gastrointestinal symptoms.
- **DDx:** allergic contact dermatitis, eczematous reaction to molluscum contagiosum, pityriasis rosea, scabies; eruptions with a more widespread distribution may overlap with Gianotti–Crosti syndrome.
- Resolves spontaneously, usually within 3–8 weeks.
- **Rx:** topical CS are often of limited benefit.

## Gianotti–Crosti Syndrome (Papular Acrodermatitis of Childhood)

- Associated with a variety of infectious triggers, most often Epstein–Barr virus, hepatitis B virus (outside the United States), and vaccines.
- Most common in the spring and early summer, favoring young children.
- Often preceded by a low-grade fever and/or upper respiratory symptoms.
- Rapid onset of monomorphic, skin-colored to pink-red, edematous papules > papulovesicles in a symmetric distribution on the extensor surfaces of the extremities, buttocks, and face (Fig. 68.7); pruritus, purpuric lesions, and extension to the trunk occasionally occur.
- **DDx:** inflammatory response to molluscum contagiosum, id reaction (e.g. due to allergic contact dermatitis to nickel), papular




**Fig. 68.4 Erythema infectiosum.** Bright macular erythema on the cheeks, with characteristic sparing of perioricial areas **(A)**. Lacy, reticulated erythematous eruption on the thigh **(B)** and arm **(C)** during the second stage of the exanthem. *A, Courtesy, Louis A. Fragola, Jr., MD; B, C Courtesy, Julie V. Schaffer, MD.*



**Fig. 68.5 Papular–purpuric gloves and socks syndrome.** Erythema and edema with associated petechiae and small purpuric papules on the dorsal aspect of the fingers and hands. *Courtesy, Luis Requena, MD.*

urticaria, another viral exanthem (e.g. coxsackievirus A6), drug eruption, scabies.

- Resolves spontaneously, usually within 3–8 weeks (longer than a classic viral exanthem); laboratory evaluation for specific viral agents can be performed if indicated by clinical findings and geographic region.
- **Rx:** topical CS are often of limited benefit.

## Molluscum Contagiosum (MC)

- Common cutaneous infection caused by a poxvirus.
- Spread by skin-to-skin contact >> fomites (e.g. towels), favoring young children but also occurring via sexual contact in adults; larger and more numerous lesions may be seen in immunocompromised hosts, especially those with HIV infection.
- Firm, skin-colored to pink papules with a waxy surface and central umbilication; predilection for the skin folds (e.g. axillae, neck, groin), lateral trunk, thighs, buttocks, genitals, and face (Fig. 68.8).
- Inflammatory reactions frequently occur, including eczematous dermatitis (diffuse or nummular) in the skin surrounding MC lesions, furuncle-like inflammation of individual MC lesions, and a Gianotti–Crosti syndrome-like eruption of pruritic erythematous papules favoring the elbows and knees (see Fig. 68.8B–F).
- **DDx** (in addition to above): *multiple lesions* – verrucae, condyloma acuminata, papular eczema; *solitary to few lesions* – juvenile xanthogranuloma or Spitz nevus in a child, BCC in an adult; *in immunocompromised*




**Fig. 68.6 Unilateral laterothoracic exanthem.** Erythematous macules and papules involving the left axilla and upper flank **(A)** and a slightly more extensive distribution on the left lateral trunk **(B)**. *Courtesy, NYUDSC.*

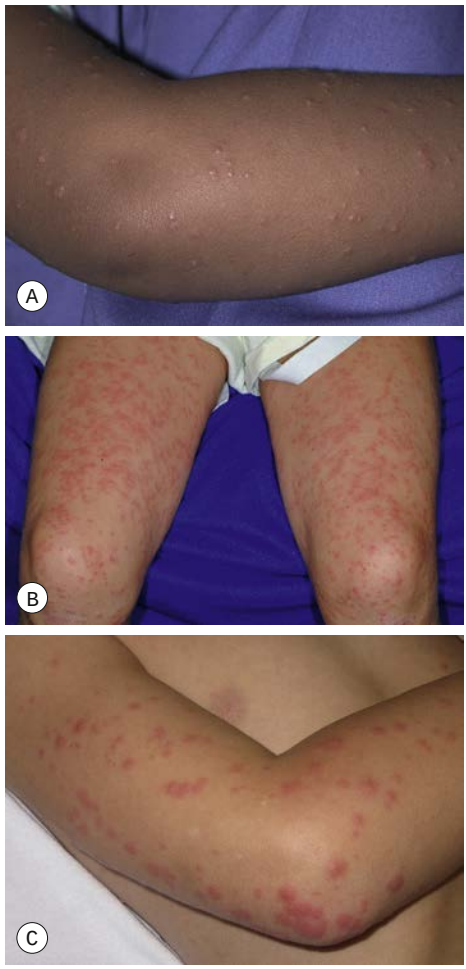


**Fig. 68.7 Gianotti–Crosti syndrome.**
**A** Monomorphic, small erythematous papules on the elbow. **B** A more exuberant eruption of coalescing edematous, erythematous papules on the thighs and knees. **C** Larger edematous, erythematous papules on the elbow.
*A, C, Courtesy, YDRSC; B, Courtesy, Anthony Mancini, MD.*

*hosts* – cryptococcosis, histoplasmosis, other dimorphic fungal infections.

- Microscopic evaluation following curettage of lesional contents or biopsy shows large, round intracytoplasmic inclusion bodies (see Ch. 2); dermoscopy can identify a characteristic yellow-white, lobular central structure surrounded by a "crown" of blood vessels.
- Resolves spontaneously over months to several years in immunocompetent children, with larger numbers of lesions often developing in those with atopic dermatitis.
- **Rx:** options are listed in Table 68.1.

## Other Poxvirus Infections

- The most historically significant poxvirus infection was smallpox, which has been responsible for millions of human deaths; the world was declared free of smallpox in 1980, although two reference collections remain (in the United States and Russia) and it is feared that smallpox could be exploited for bioterrorism.
- The clinical manifestations of smallpox and varicella are compared in Table 68.2, and selected poxvirus infections and complications of smallpox vaccination are presented in Figs 68.9 and 68.10 and Table 68.3.

## Hemorrhagic Fevers and Other Viral Infections with Cutaneous Manifestations

- *Hemorrhagic fevers*: group of zoonotic viral infections with nonspecific cutaneous manifestations that include petechiae, purpura, and mucosal hemorrhage; although overall most common in Africa and South America (e.g. Ebola, Marburg, and yellow fever viruses), some have a worldwide distribution (e.g. hantavirus).
- Cutaneous manifestations of coronavirus disease 2019 (COVID-19 [SARS-CoV-2]) include urticarial, morbilliform, papulovesicular, erythema multiforme-like, chilblains-like, and purpuric eruptions; livedo reticularis/racemosa and retiform purpura (primarily in severely ill adults) and a multisystem inflammatory syndrome in children (MIS-C) with mucocutaneous findings similar to Kawasaki disease (see Ch. 3) may also occur.
- Cutaneous manifestations of hepatitis A, B, and C infections are listed in Table 68.4.
- Major features of other viral infections with cutaneous findings are presented in Table 68.5.

For further information see Ch. 81 from *Dermatology, Fourth Edition*.

**For additional online figures and tables visit www.expertconsult.com**

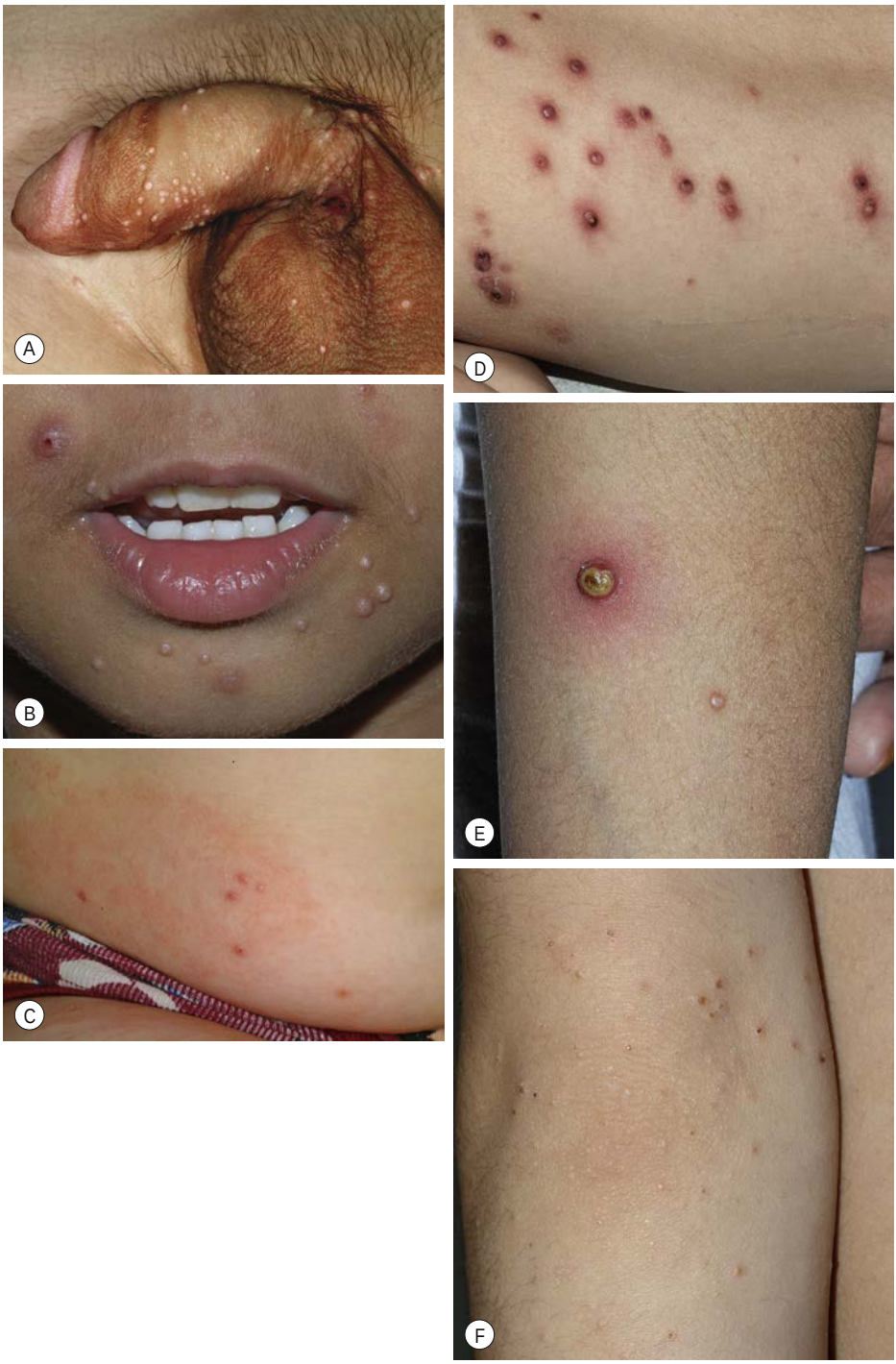


**Fig. 68.8 Molluscum contagiosum.** Multiple pearly, umbilicated papules in the genital area **(A)** and on the face **(B)**; note the inflamed lesion on the right cheek. Inflammatory reactions are a sign of the host immune response to the virus. **C** Inflamed lesions surrounded by "molluscum dermatitis." **D, E** Pustular presentations of inflamed molluscum. Cultures revealed only normal skin flora. **F** Monomorphic eruption of pruritic pink papules with crusting on the elbow. These reactive lesions were also present on knees of this child with molluscum contagiosum on the trunk. *A, C, Courtesy, Anthony Mancini, MD; B, D–F, Courtesy, Julie V. Schaffer, MD.*

| TREATMENT OF MOLLUSCUM CONTAGIOSUM |
|---|
| **No direct therapy** |
| Spontaneous involution in immunocompetent patients (mean duration ~1 year)<br>Treatment of associated dermatitis with a topical CS can prevent autoinoculation from scratching |
| **Physical modalities** |
| Curettage* (1) or manual extraction (3)<br>Cryotherapy (2)<br>Electrodesiccation* (3) |
| **Topical therapy** |
| Cantharidin (1)<br>Podophyllotoxin (1)<br>Retinoids (3)<br>Trichloroacetic acid (1) |
| **Discomfort can be minimized by prior application of a topical anesthetic (e.g. lidocaine 4–5% cream).* |

**Table 68.1 Treatment of molluscum contagiosum.** Other options include topical sinecatechins, KOH 5–10% solution, other irritants (e.g. retinoids), intralesional immunotherapy with *Candida* antigen, pulsed dye laser, and (for extensive lesions) systemic medications (e.g. oral cimetidine or [in immunosuppressed patients] intravenous cidofovir). Imiquimod was found to be ineffective in two large randomized controlled trials. Key to evidence-based support: (1) prospective controlled trial; (2) retrospective study or large case series; (3) small case series or individual case reports.

| COMPARISON OF VARICELLA/DISSEMINATED ZOSTER TO SMALLPOX | | |
|---|---|---|
| | **Varicella/disseminated zoster** | **Smallpox** |
| Prodrome | None or mild fever and malaise | Fever ≥101°F/38.3°C for 1–4 days prior to rash onset, plus malaise, headache, backache and/or abdominal pain |
| Distribution of lesions | Initially on face/scalp; trunk > distal extremities<br>May have an enanthem | Concentrated on face and limbs; can progress to involve entire body surface<br>Oropharyngeal lesions often precede cutaneous eruption |
| Stage of lesions | Different stages occur simultaneously in any one area of the skin (nonsynchronous) | Adjacent lesions are all at same stage of development (synchronous) |
| Types of lesions | Superficial papules, vesicles, and pustules | Papulovesicles → firm, deep-seated pustules with a tendency to confluence |
| Course | Lesions appear in crops over a 3-day period | Lesions spread over 1–2 weeks<br>Crusting develops over 1 week |
| Scarring | Rare in uncomplicated cases | Common and marked |

**Table 68.2 Comparison of varicella/disseminated zoster to smallpox.**

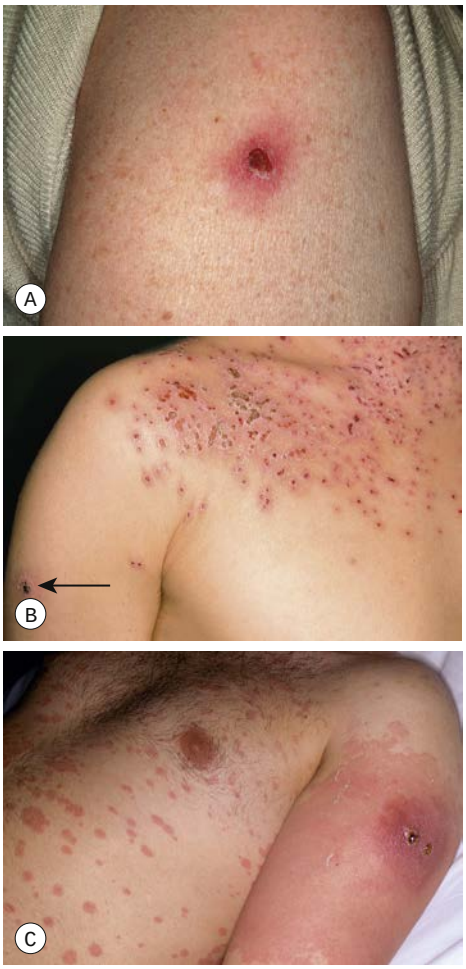


**Fig. 68.9 Smallpox vaccine. A** Crusted papule at the site of vaccination, 14 days following administration. **B** Eczema vaccinatum in a patient with atopic dermatitis. Spread from the vaccination site (arrow) to areas of eczema. **C** Erythema multiforme-like reaction associated with marked erythema and edema at the vaccination site. *A, Courtesy, Anthony J. Mancini, MD, and Ayelet Shani-Adir, MD; B, C, Courtesy, Louis A. Fragola, Jr., MD.*



**Fig. 68.10 Orf.** Erythematous nodule with oozing and central ulceration on the dorsal aspect of the hand. *Courtesy, Luis Requena, MD.*

| SELECTED POXVIRUS INFECTIONS | |
|---|---|
| **Disease/virus (genus; host)** | **Major features** |
| Smallpox/variola (*Orthopoxvirus*; only humans) | • Theoretically eradicated; respiratory transmission, 7- to 17-day incubation period<br>• See Table 68.2 for clinical findings*<br>• Complications: panophthalmitis, arthritis, encephalitis |
| Vaccinia (*Orthopoxvirus*; used as vaccine in humans) | • Currently used for smallpox vaccination in the military and first responders<br>• Papule at vaccination site (e.g. deltoid or thigh) → vesiculopustules → crust (Fig. 68.9A) → scar, occasionally with satellite lesions; fever and LAN are common, and urticarial or exanthematous eruptions may develop 1–3 weeks postvaccination<br>• Possible adverse events*<br>– Superinfection of the vaccination site or lymph nodes<br>– Inadvertent autoinoculation or contact transmission<br>– Generalized or progressive vaccinia (especially in immunocompromised hosts)<br>– Eczema vaccinatum (e.g. in patients with atopic dermatitis) (Fig. 68.9B)<br>– Postvaccination nonviral pustulosis or erythema multiforme (Fig. 68.9C)<br>– Ocular vaccinia, myo/pericarditis, postvaccinial CNS disease |
| Monkeypox (*Orthopoxvirus*; monkeys, rodents) | • Primarily in Africa; cutaneous inoculation or respiratory transmission, 10- to 12-day incubation period<br>• Malaise and fever, then nonsynchronous eruption of papules (few to >100) → vesiculopustules → crusts → scars, favoring face and extremities (often on palms/soles); LAN and respiratory symptoms<br>• Smallpox vaccination protective |
| Cowpox (*Orthopoxvirus*; cats > rodents > cattle) | • Primarily in Europe and Central Asia; 7-day incubation period<br>• At site of contact (usually hands or face) with infected animal: papule → vesicle → pustule → crusted eschar → scar; often fever and LAN<br>• Occasionally generalized in patients with atopic dermatitis |
| Orf (*Parapoxvirus*; sheep, goats, reindeer) | • At-risk occupations: shepherds, veterinarians, butchers<br>• On hands (Fig. 68.10) following contact with infected animal (especially perioral area and udder of ewes): papule (1 to few) → targetoid lesion → nodule (weeping then dry with black dots then papillomatous) → regression without scar; ± fever and LAN, and erythema multiforme may occur 10–14 days later<br>• Diagnosis often made histologically |
| Milker's nodules (bovine papular stomatitis)/parapoxvaccinia (*Parapoxvirus*; cattle) | • At-risk occupations: dairy farmers, ranchers, butchers, veterinarians<br>• Lesions on hands virtually identical to orf (see above) |

**Additional information (e.g. diagnostic criteria, algorithms, case definitions) is available at http://www.cdc.gov/smallpox/index.html.*

**Table 68.3 Selected poxvirus infections.** Real-time PCR is currently the diagnostic method of choice. Other poxviruses that occasionally lead to skin lesions (single or few) in humans include *deer-associated parapoxvirus* (eastern United States; reported in deer hunters) and *tanapox* (equatorial Africa; endemic in nonhuman primates, likely arthropod vector). LAN, lymphadenopathy.

| CUTANEOUS MANIFESTATIONS OF HEPATITIS A, B, AND C INFECTIONS | |
|---|---|
| Acute urticaria (A, B, C)<br>Serum sickness-like reaction (B, C)<br>Gianotti–Crosti syndrome (B > A, C)<br>Small vessel vasculitis (B, C > A)<br>Cryoglobulinemic vasculitis (C > B > A)<br>Urticarial vasculitis (B, C)<br>Polyarteritis nodosa (classic – B, cutaneous – C)<br>Livedo reticularis (C) | Necrolytic acral erythema (C)<br>Porphyria cutanea tarda (B, C)<br>Pruritus (B, C > A)<br>Lichen planus – especially erosive oral disease (C)<br>Sarcoidosis (with interferon and/or ribavirin therapy; C > B)<br>Erythema multiforme (B, C)<br>Erythema nodosum (B > C) |

**Table 68.4 Cutaneous manifestations of hepatitis A, B, and C infections.**

| ADDITIONAL SELECTED VIRAL INFECTIONS WITH CUTANEOUS FINDINGS | | |
|---|---|---|
| **Viral infection (family)** | **Geography/primary source of infection** | **Major features** |
| Dengue (Flaviviridae) | Caribbean, Mexico, Central and South America, Africa, Asia (especially tropics)/ mosquitoes | • 3- to 10-day incubation period → variable fever, headache (especially retro-orbital), myalgias, vomiting*<br>• ~50% of patients: macular erythema of head, neck, and upper trunk, followed by morbilliform eruption with islands of sparing and often petechiae* |
| West Nile (Flaviviridae) | Africa, Europe, Asia, North > South America, Australia/ mosquitoes that feed on infected birds | • 5- to 14-day incubation period → fever, headache, myalgias > meningo-encephalitis, flaccid paralysis<br>• ~25% of patients: exanthem with erythematous macules/papules, often punctate and favoring extremities |
| Zika (Flaviviridae) | Caribbean, Mexico, Central and South America, Africa, Pacific Islands, Asia (especially tropics)/ mosquitoes, sexual contact, mother to fetus, blood products | • 2- to 14-day incubation period → symptomatic in ~20% of patients: fever, arthralgias, headache, conjunctivitis, morbilliform exanthem (often pruritic, may involve palms/soles)<br>• Risk of fetal microcephaly with maternal infection |
| Chikungunya (Togaviridae) | Asia, Indian and Pacific islands, Africa, Europe, Americas/mosquitoes | • 1- to 14-day incubation period → fever, headache, myalgias/arthralgias<br>• ~50% of patients: acrofacial erythema/edema, morbilliform exanthem; occasionally ulcers (genital, intertriginous, oral), vesiculobullae, and postinflammatory hyperpigmentation (freckle-like, flagellate, or diffuse) |
| Trichodysplasia spinulosa (viral-associated trichodysplasia) (Polyomaviridae) | Worldwide** | • Numerous erythematous to skin-colored, spiny papules favoring the mid face and ears; ± alopecia or leonine facies |

**Severe dengue (including dengue hemorrhagic fever and shock syndrome), which is more common in children and following repeat infection with a second virus serotype, features marked thrombocytopenia with bleeding, plasma leakage leading to shock and respiratory distress, and organ impairment.*
***In solid organ transplant recipients or patients receiving chemotherapy for a hematologic malignancy.*

**Table 68.5 Additional selected viral infections with cutaneous findings.** Other viruses with limited geographic distributions have prominent skin findings, e.g. Barmah Forest virus in Australia.

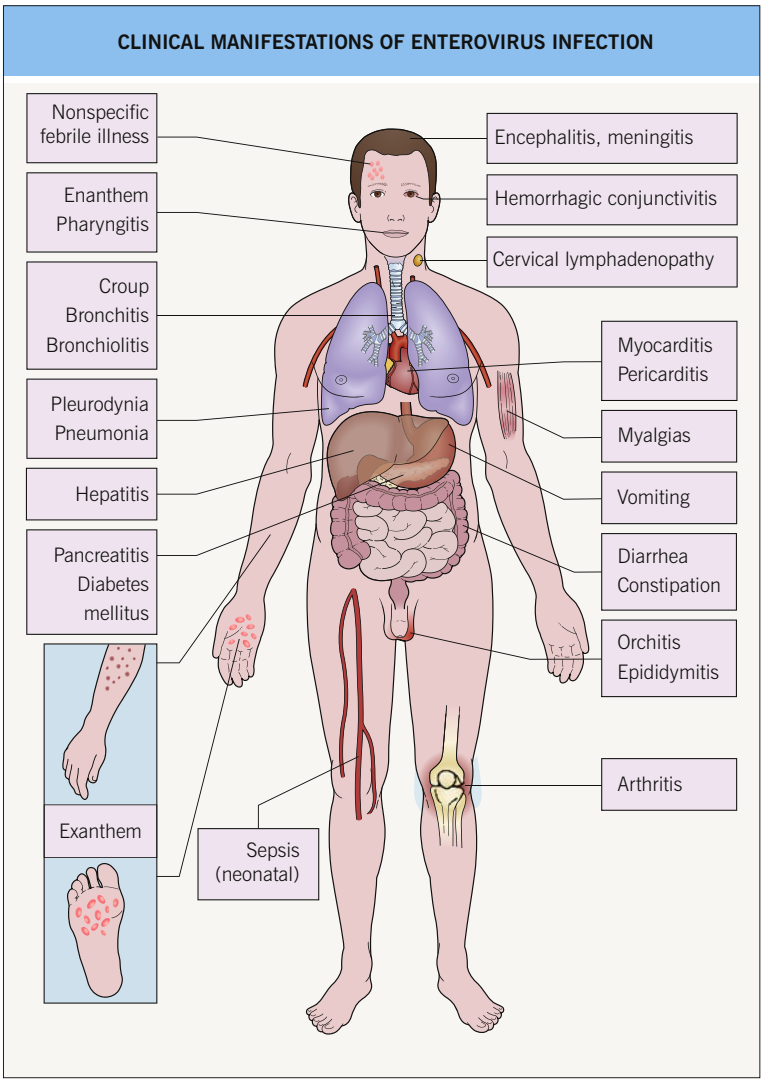


**eFig. 68.1 Clinical manifestations of enterovirus infection.**




**eFig. 68.2 Hand-foot-and-mouth disease.** Coxsackievirus A6 infection presenting with multiple papulovesicles and crusts on the arm (**A**), on the knee (**B**), in the perioral area with accentuation in a scar on the chin (**C**), in the groin (**D**), and on the dorsal aspect of the hand (**E**). *A, Courtesy, Robert Sidbury, MD; B–E, Courtesy, Julie V. Schaffer, MD.*



**eFig. 68.3 Petechial enteroviral exanthem.** *Courtesy, Julie V. Schaffer, MD.*



**eFig. 68.6 Orf.** Vesiculopustule and ulceration on the finger. *Courtesy, Anthony Mancini, MD.*



**eFig. 68.4 Erythema infectiosum.** Lacy, reticulated erythema on the arms during the second stage of the exanthem. *Courtesy, Kalman Watsky, MD.*




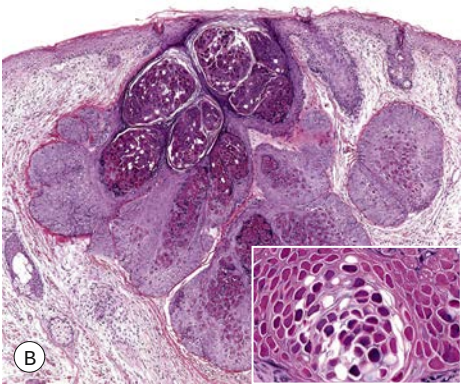


**eFig. 68.7 Molluscum contagiosum.** **A** Inflamed lesions surrounded by "molluscum dermatitis". **B** Histologic evaluation shows numerous molluscum bodies (inset). Demonstrating these bodies in a saline preparation of expressed lesional contents serves as a technique for bedside diagnosis. *A, Courtesy, Julie V. Schaffer, MD; B, Courtesy, Lorenzo Cerroni, MD.*



**eFig. 68.5 Papular–purpuric gloves and socks syndrome.** Erythematous patches with petechiae on the plantar surface. *Courtesy, Anthony Mancini, MD.*



**eFig. 68.8 Trichodysplasia spinulosa (viral-associated trichodysplasia) in a renal transplant recipient.** Numerous skin-colored to pink folliculocentric papules, many with central spiny excrescences, are present on the nose and cheeks. This disorder most commonly occurs in the setting of immunosuppression due to systemic calcineurin inhibitors. This patient was receiving tacrolimus, mycophenolate mofetil, and prednisone. *Courtesy, Mark Kirchhof, MD, and Sheila Au, MD.*

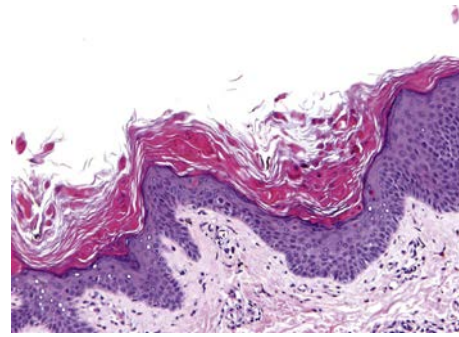

**eFig. 68.9 Trichodysplasia spinulosa histology.** Nucleated eosinophilic keratinocytes contain large trichohyaline granules. *Courtesy, Boni Elewski, MD.*

| PARVOVIRUS B19 CLINICAL ASSOCIATIONS |
|---|
| **Established associations** |
| **Mucocutaneous** |
| • Erythema infectiosum<br>• Papular–purpuric gloves and socks syndrome<br>• Petechial/purpuric eruptions in a generalized, bathing trunk, periflexural, acral, and/or perioral distribution<br>• Enanthem with erosions and petechiae<br>• Degos-like lesions |
| **Extracutaneous** |
| • Arthropathy<br>• Hydrops fetalis<br>• Transient aplastic crises in at-risk individuals*<br>• Chronic anemia<br>• Thrombocytopenia, neutropenia, pancytopenia<br>• Hepatitis |
| **Possible associations** |
| **Vasculitides** |
| • Small vessel vasculitis<br>• Henoch–Schönlein purpura<br>• Cryoglobulinemic vasculitis<br>• Polyarteritis nodosa<br>• Granulomatosis with polyangiitis |
| **Additional exanthems** |
| • Microvesicular eruption<br>• Unilateral laterothoracic exanthem<br>• Gianotti–Crosti syndrome |
| **Other** |
| • Neurologic disease<br>• Chronic fatigue syndrome<br>• Systemic lupus erythematosus-like illness<br>• Hemophagocytic lymphohistiocytosis<br>• Myositis |
| **Patients suffering from decreased red cell production (e.g. iron deficiency, thalassemias) or increased red cell destruction (e.g. sickle cell anemia, hereditary spherocytosis, pyruvate kinase deficiency, glucose-6-phosphate dehydrogenase deficiency), as well as patients with HIV infection and recipients of allogeneic hematopoietic stem cell or solid organ transplants.* |

**eTable 68.1 Parvovirus B19 clinical associations.** Asymptomatic infection may also occur.

| POTENTIAL ETIOLOGIES REPORTED IN ASSOCIATION WITH GIANOTTI–CROSTI SYNDROME | |
|---|---|
| **Viral** | |
| • **Hepatitis B virus*** | • Rotavirus |
| • **Epstein–Barr virus†** | • Parvovirus B19 |
| • Hepatitis A and C viruses | • Mumps virus |
| • Cytomegalovirus | • Human herpesvirus-6 |
| • Coxsackievirus | • Herpes simplex virus 1 |
| • Respiratory syncytial virus | • Influenza virus |
| • Adenovirus | • Human immunodeficiency virus |
| • Parainfluenza virus | |
| **Non-viral** | |
| • Group A β-hemolytic streptococci | • *Bartonella henselae* |
| • *Mycoplasma pneumoniae* | • *Neisseria meningitidis* |
| **Vaccines** | |
| • Polio | • Hepatitis B > A |
| • Diphtheria–pertussis–tetanus (DPT) | • Influenza |
| • Measles–mumps–rubella (MMR) | |
| **Reported most commonly in Europe.* | |
| *†Most common cause in US.* | |

**eTable 68.2 Potential etiologies reported in association with Gianotti–Crosti syndrome.** A pruritic Gianotti–Crosti syndrome-like eruption can also occur in patients with molluscum contagiosum (see text). Most common viral etiologies are in bold.

# 69 Sexually Transmitted Infections

In this chapter, five sexually transmitted infections (STIs) are covered – syphilis, gonorrhea, chancroid, lymphogranuloma venereum (LGV), and granuloma inguinale. Additional more common STIs including herpes simplex infections, mollusca contagiosa, condyloma acuminata, pubic lice, and HIV infection are discussed in Chapters 67, 68, 66, 71, and 65, respectively. When one STI is present, a search for others is indicated.

## Syphilis (Lues)

- Etiologic agent is the spirochete *Treponema pallidum*; the infection is divided into four phases: primary, secondary, latent, and tertiary (Fig. 69.1), in addition to a congenital form.
- Syphilis is currently 7–10 times more common in men than in women in the United States and the incidence has been rising, especially in men, over the past 15 years; the highest rates are in Black and Hispanic individuals and in men who have sex with men (MSM); there is an increased risk of transmission of HIV infection in those with ulcers due to syphilis as well as chancroid or herpes simplex viral infection.
- One or more ulcers, usually anogenital, characterize *primary syphilis* and are referred to as chancres (Fig. 69.2); the ulcers are painless (unless secondarily infected) and upon palpation the base is firm; regional lymphadenopathy may be present (Fig. 69.3).
- *Secondary syphilis* reflects hematogenous dissemination and the skin lesions vary from macular to papulosquamous and from annular to granulomatous (Figs 69.4 and 69.5; see Fig. 65.4); mucosal involvement is common and includes mucous patches, split papules at the angles of the mouth and condyloma lata (Fig. 69.6); usually accompanied by constitutional symptoms (Table 69.1).
- *Tertiary syphilis* is preceded by a latent phase that can last for years (Fig. 69.7); the skin and mucous membranes, as well as the bones, develop gummas (Fig. 69.8), with cardiovascular syphilis and neurosyphilis representing the major causes of death in those who remain untreated.
- *In utero* infection of a fetus can occur, primarily during the secondary or latent phases, leading to congenital syphilis or stigmata (Tables 69.2 and 69.3); the cutaneous lesions of early congenital syphilis are similar to those of secondary syphilis (Fig. 69.9), but they may be bullous; additional findings include a bloody or purulent nasal discharge ("snuffles"), perioral and perianal fissures, and osteochondritis.
- Dx: darkfield microscopic examination (serous exudate from primary or secondary lesions); anti-cardiolipin antibodies (*r*apid *p*lasma *r*eagin [RPR] or *V*enereal *D*isease *R*esearch *L*aboratory [VDRL] assay): ~80%+ in primary and 99%+ in secondary; anti-*T. pallidum* (TP) antibodies (*m*icro*h*em*a*gglutination assay [MHA-TP] or *f*luorescent *t*reponemal *a*ntibody *abs*orption [FTA-ABS]: ~90%+ in primary and 99%+ in secondary.
- A false-positive VDRL can occur in pregnant women and in association with a number of disorders including antiphospholipid antibody syndrome, LE, lymphoma, and drug abuse as well as infections (e.g. endemic treponematoses, borreliosis, malaria), while a false-positive FTA-ABS can occur in patients with LE, HIV infection, hypergammaglobulinemia, endemic treponematoses, and borreliosis.
- **DDx:** see Table 69.4.
- **Rx:** see Table 69.5 for treatment of primary, secondary, and early latent syphilis; patients with symptoms or signs suggesting neurologic disease should have CSF analysis and HIV-infected patients are at increased risk for

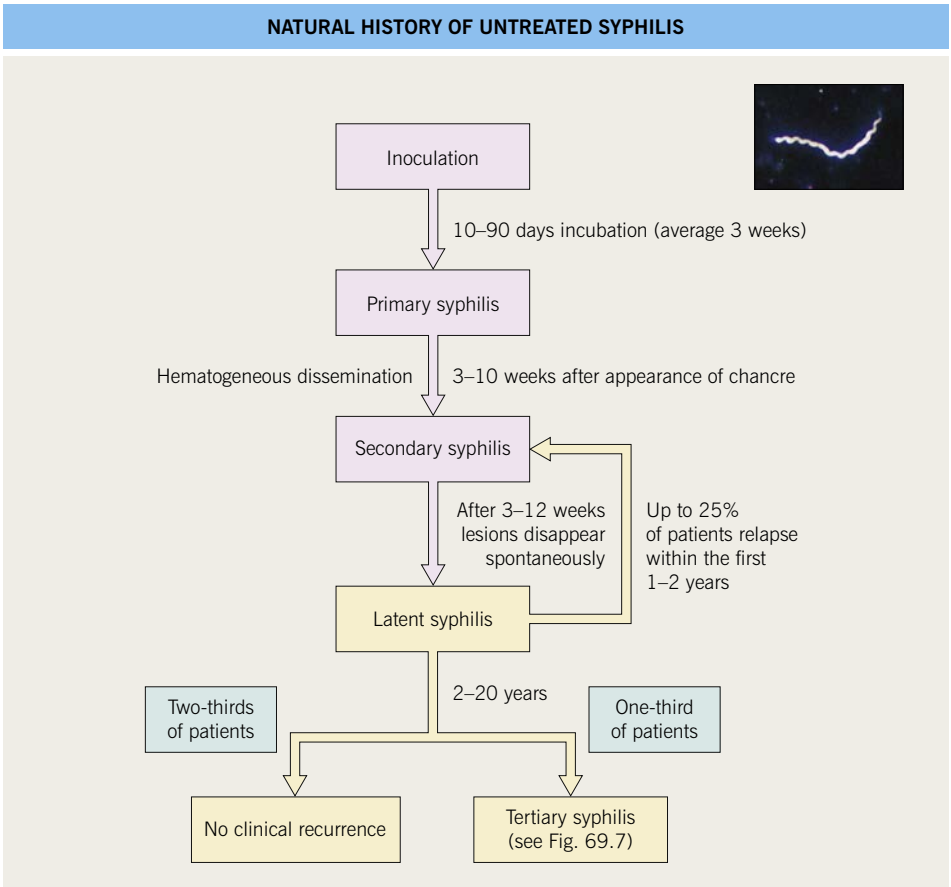


**Fig. 69.1 Natural history of untreated syphilis.** Chancres spontaneously resolve after a few weeks (see Fig. 69.3). In the group of patients with no recurrence, the rapid plasma reagin (RPR) becomes negative in 50% and remains positive in 50%. *Adapted from Rein MF, Musher DM. Late syphilis. In: Rein MF (Ed.), Atlas of Infectious Diseases, Vol. V: Sexually Transmitted Diseases. New York: Current Medicine, 1995:10.1–10.13. Inset figure: Adapted from Morse SA, et al. Atlas of Sexually Transmitted Diseases and AIDS, 3rd ed. London: Mosby; 2003.*

neurosyphilis; for treatment of late latent, ocular, tertiary, and congenital syphilis as well as neurosyphilis, see www.cdc.gov/std/treatment or download the CDC STD Tx Guide App; a fourfold decrease in the antibody titer based on the RPR or VDRL assay is indicative of successful treatment.

## Gonorrhea

- The etiologic agent is *Neisseria gonorrhoeae* and the primary infection is usually genital but can be anal, rectal, or oropharyngeal; gonorrhea is acquired primarily via sexual contact and the incubation period is 2–5 days.
- While acute urethritis in men accompanied by a purulent discharge is the most common clinical presentation, the manifestations of gonorrhea are varied (Fig. 69.10; Table 69.6); asymptomatic infections are common in women and when the rectum or pharynx is the site of infection.
- In disseminated gonococcal infection, often referred to as the arthritis–dermatosis syndrome, a limited number of acral inflammatory pustules appear due to septic vasculitis, along with fever, arthralgia, and tenosynovitis (Fig. 69.11); risk factors include menstruation and deficiencies of the late components of complement (C5–C9; see Ch. 49).

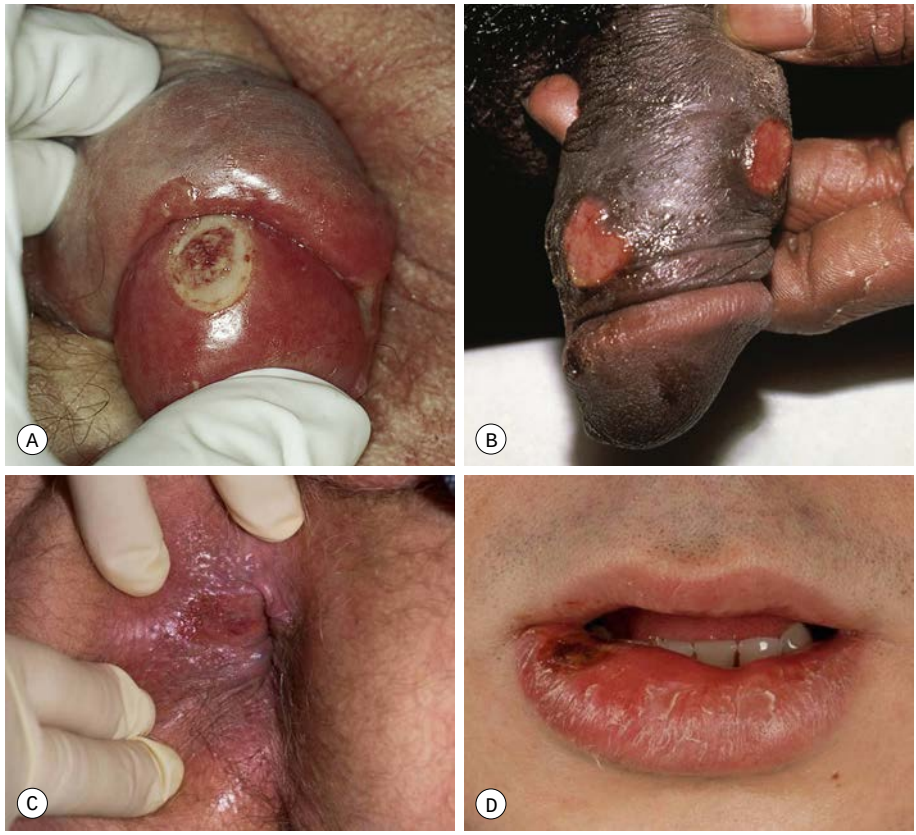


**Fig. 69.2 Chancres of primary syphilis.** The lesions are firm to palpation and are occasionally multiple. Sites of chancres include the penis **(A, B),** perianal area **(C),** and lip **(D)**, as well as the fingers, cervix, and breast. *A, C, D, Courtesy, Angelika Stary, MD; B, Courtesy, YDRSC.*

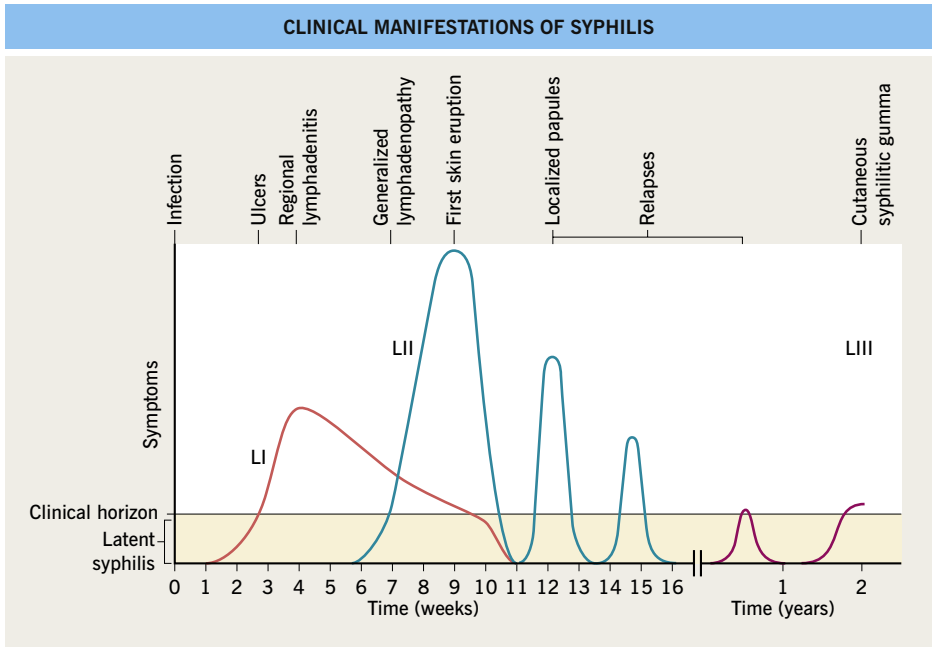


**Fig. 69.3 Clinical manifestations of syphilis.** LI, primary syphilis (lues); LII, secondary syphilis (lues); LIII, tertiary syphilis (lues). *Adapted from Fritsch P, Zangerle R, Stary A. Venerologie. In: Fritsch P (Ed.), Dermatologie und Venerologie. Berlin: Springer, 1998:865–86.*

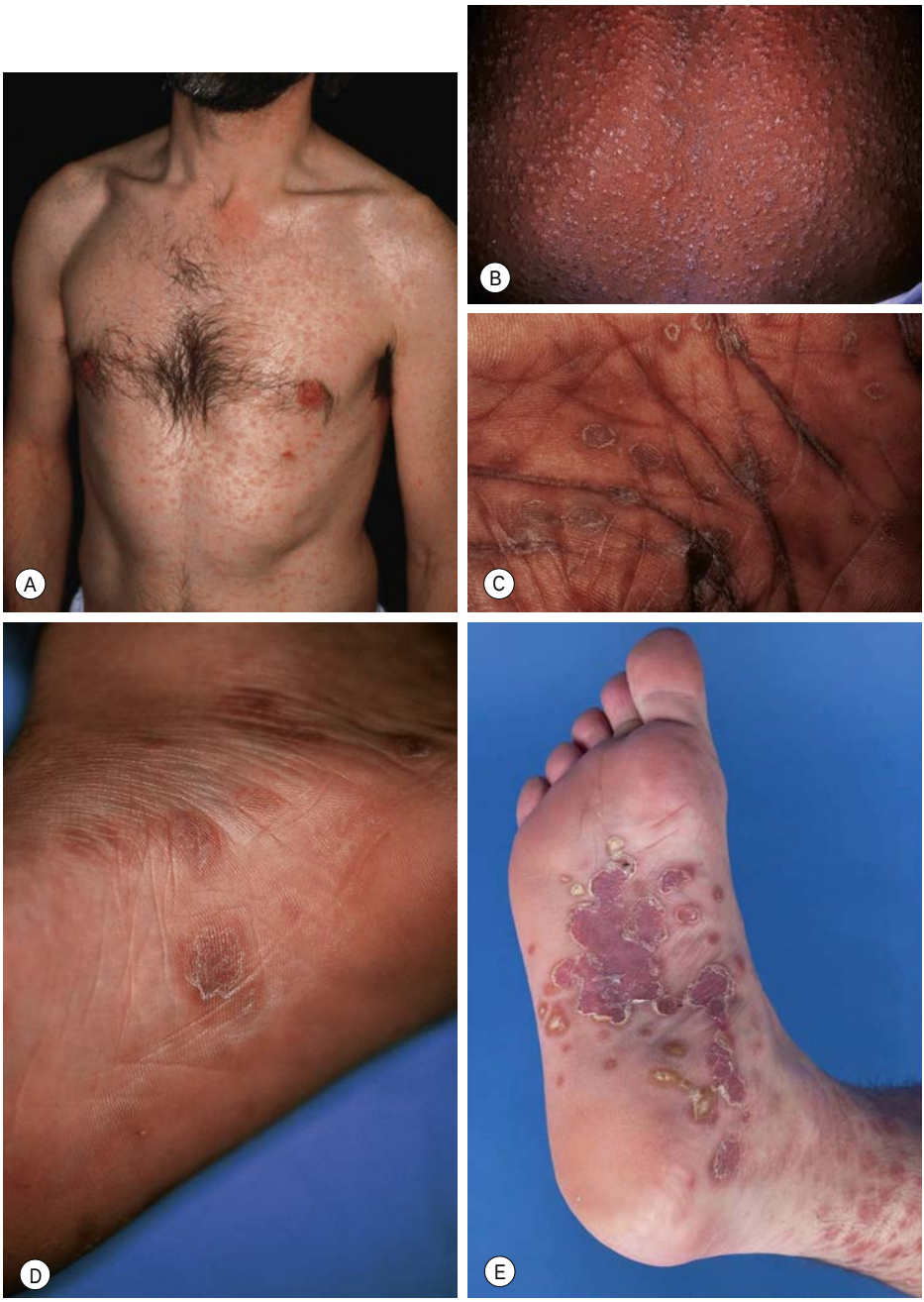


**Fig. 69.4 Secondary syphilis – cutaneous manifestations.** Widespread exanthem of pink papules **(A)** and generalized papulosquamous lesions **(B)**. Lesions on the palms **(C)** and soles **(D**, **E)** can have a collarette of scale; in patients with more darkly pigmented skin, these lesions may have a copper color. *A–D, Courtesy, YDRSC; E, Courtesy, Angelika Stary, MD.*

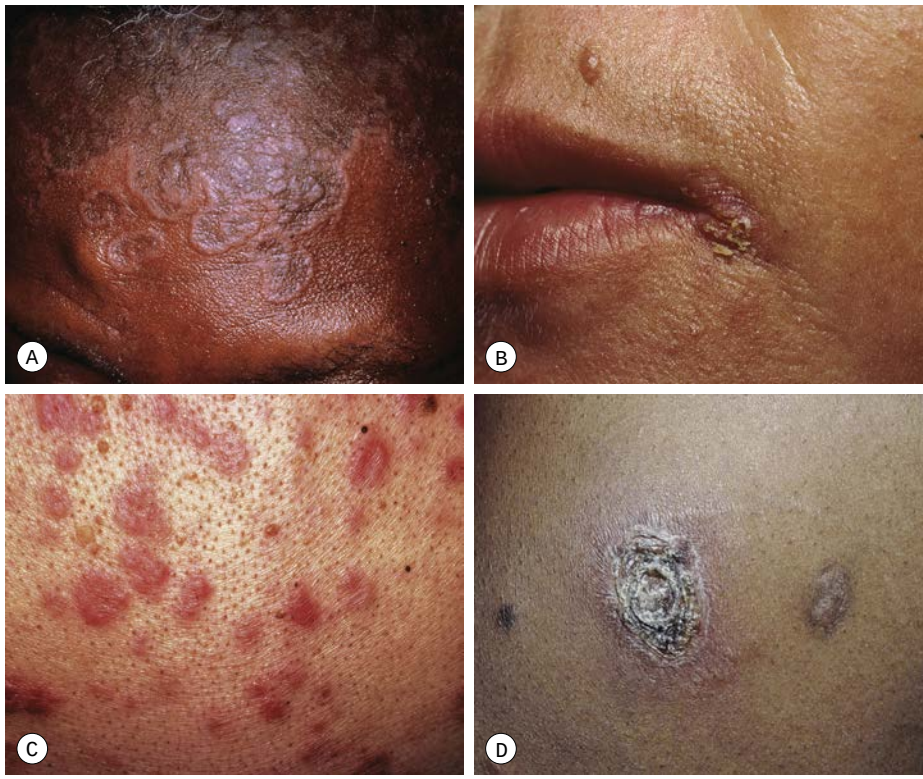


**Fig. 69.5 Less common manifestations of secondary syphilis. A** Annular plaques with central hyperpigmentation on the forehead. **B** Split papule at the oral commissure. **C** Granulomatous nodules and plaques. **D** Necrotic lesion with scale-crust in a patient with AIDS. *A–C, Courtesy, YDRSC; D, Courtesy, Judit Stenn, MD.*

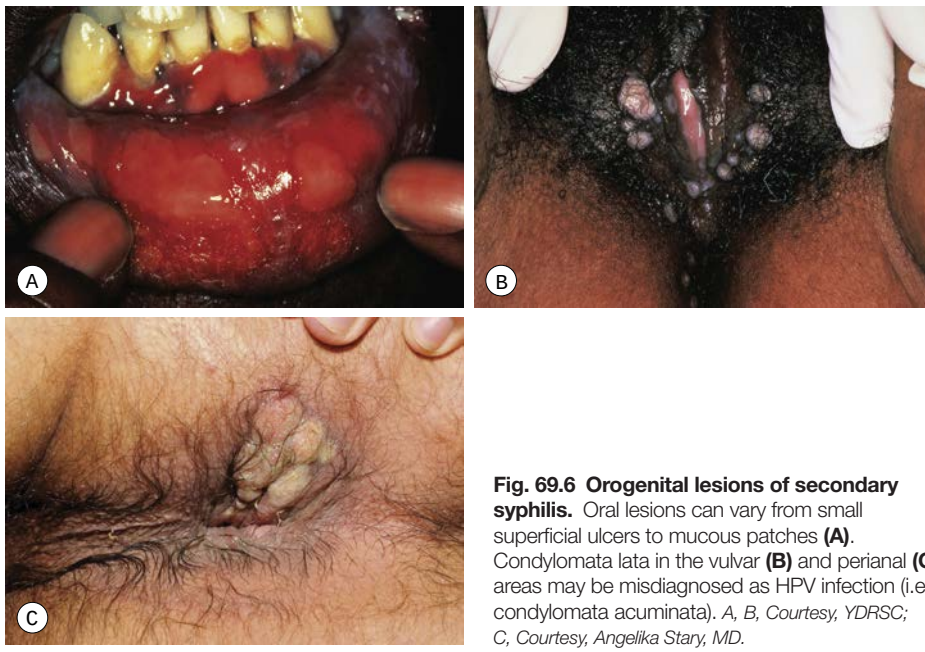


**Fig. 69.6 Orogenital lesions of secondary syphilis.** Oral lesions can vary from small superficial ulcers to mucous patches **(A)**. Condylomata lata in the vulvar **(B)** and perianal **(C)** areas may be misdiagnosed as HPV infection (i.e. condylomata acuminata). *A, B, Courtesy, YDRSC; C, Courtesy, Angelika Stary, MD.*

| CLINICAL FEATURES OF SECONDARY SYPHILIS |
|---|
| • **Prodromal symptoms and signs**<br>  • Weight loss<br>  • Low-grade fever<br>  • Malaise<br>  • Headache (meningeal irritation)<br>  • Sore throat<br>  • Conjunctivitis (iridocyclitis)<br>  • Arthralgia (periostitis)<br>  • Myalgias, bone pain<br>  • Hepatosplenomegaly (mild hepatitis) |
| • **Generalized lymphadenopathy with indolent enlargement of lymph nodes** (50–85%) |
| • **Skin manifestations**<br>  • *Early* (10%): generalized eruption; non-pruritic, roseola-like, discrete macules, initially distributed on the flanks and shoulders<br>  • *Late* (70%): generalized maculopapular and papulosquamous eruptions; more infiltrated lesions, often copper-colored; annular plaques on the face; corymbose arrangement (satellite papules around a larger central lesion); occurs in successive waves and is polymorphic<br>  • *Localized syphilids* (specific infiltrations of treponemes; positive darkfield examination):<br>  – palms and soles: symmetric papules and plaques with a collarette of scale (collarette of Biett)<br>  – anogenital area: condylomata lata<br>  – seborrheic area: "corona veneris" along the hairline<br>  • *Hypopigmented macules*, mainly on the neck (postinflammatory; "necklace of Venus") |
| • **Manifestations involving mucous membranes** (30%)<br>  • Syphilitic perlèche, split papules<br>  • Mucous patches: "plaques muqueuses" in the oropharynx (equivalent to condylomata lata in the genital area)<br>  • Syphilitic sore throat: inflammation of the whole pharynx |
| • **Patchy alopecia** (7%): "moth-eaten" localized areas of hair loss; toxic telogen effluvium |

**Table 69.1 Clinical features of secondary syphilis.** *Courtesy, Angelika Stary, MD.*

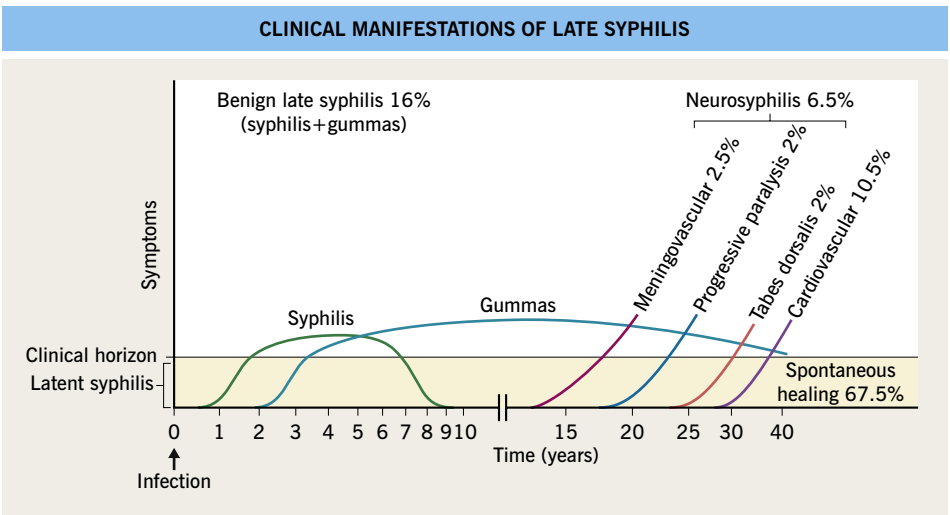


**Fig. 69.7 Clinical manifestations of late syphilis.** Gummas occur most commonly in the skin (70%) and less often in the bones (10%) or mucous membranes (10%). In neurosyphilis, both endarteritis and direct invasion of the brain parenchyma can occur. Tabes dorsalis presents with painful paresthesias of the limbs, ataxia, and Argyll Robertson pupils. *Adapted from Fritsch P, Zangerle R, Stary A. Venerologie. In: Fritsch P (Ed.), Dermatologie und Venerologie. Berlin: Springer, 1998:865–86.*



**Fig. 69.8 Cutaneous gummas of tertiary syphilis.** Arciform, erythematous eroded plaques with central scarring. *Courtesy, NYUDSC.*

| MOTHER-TO-CHILD TRANSMISSION OF UNTREATED SYPHILIS AND ITS CONSEQUENCES |
|---|
| **Risk** |
| • Infection of the mother from conception to 7th month of pregnancy: transmission in nearly 100% (often fetal demise or severe congenital syphilis) |
| • Infection at least 2 years before pregnancy: reduced risk of transmission to 50% |
| • Infection during 7th, 8th, or early 9th month: reduced risk of transmission |
| • Infection 3–6 weeks before labor: no placental transmission; risk of perinatal transmission |
| **Consequences of infection** |
| • Spontaneous abortion (second or third trimester) (10%) |
| • Stillbirth (10%) |
| • Infant death (20%) |
| • Congenital syphilis (20%) |
| • Healthy child (40%) |

**Table 69.2 Mother-to-child transmission of untreated syphilis and its consequences.** *Courtesy, Angelika Stary, MD.*

• Dx: stained smears of urethral and cervical exudates or cutaneous pustules; culture, PCR, or DNA hybridization of samples from any site of infection.
• **DDx:** for urethral or cervical discharge, other infections, in particular *Chlamydia trachomatis*; for the cutaneous lesions due to gonococcemia, other infectious emboli, small vessel vasculitis, and neutrophilic dermatoses.
• **Rx:** see Table 69.7. Resistance to multiple antibiotics, including ciprofloxacin, is of concern.

## Chancroid

• The etiologic agent is *Haemophilus ducreyi*; this infection occurs more commonly in Africa and South Asia (Fig. 69.12), and it has a male:female ratio of 10:1.
• After an incubation period of 3–10 days, painful genital ulcers, usually multiple, develop in conjunction with tender inguinal lymphadenitis (usually unilateral; Fig. 69.13); the base of the ulcer is purulent and soft, as opposed to the induration of syphilitic chancres.
• Dx: stained smears and culture (on special media) of ulcer exudate; PCR.
• **DDx:** see Table 69.8.
• **Rx:** see Table 69.9.

## Lymphogranuloma Venereum (LGV)

• The etiologic agent is *Chlamydia trachomatis* serovars L1–L3; endemic in regions of Africa, Asia, and South America; elsewhere, e.g. in the United States and Western Europe, primarily MSM are affected.
• Infection is acquired via the anogenital or rectal mucosa with subsequent lymphatic spread, leading to lymphadenopathy which is usually unilateral (Fig. 69.14); ~50% of patients develop a herpetiform lesion at the initial site of infection that heals

| STIGMATA OF CONGENITAL SYPHILIS |
|---|
| **Cutaneous** |
| • Rhagades (radial periorificial [mouth, nose, eyes, anus] scars at sites of previous fissures) |
| **Dental** |
| • Hutchinson teeth – peg-shaped, notched permanent incisors* |
| • Mulberry molars – multiple rounded rudimentary cusps on the permanent first molars |
| • Caries due to defective enamel |
| **Skeletal** |
| • Saddle nose – depression of the nasal root due to destruction of cartilage/bone |
| • Frontal bossing of Parrot ("Olympian brow") |
| • Hypoplastic maxilla, relatively prominent mandible |
| • High palatal arch ± perforation |
| • Higouménakis sign – thickening of the medial clavicle |
| • Scaphoid scapulae |
| • Saber shins – anterior tibial bowing |
| • Clutton joints – painless synovitis and effusions of the knees |
| **Other** |
| • Eighth nerve deafness* |
| • Interstitial keratitis leading to corneal ulcers and opacities* |
| **Components of Hutchinson's triad.* |

**Table 69.3 Stigmata of congenital syphilis.** These findings represent the delayed consequences of inflammation at the sites of infection. *Courtesy, Angelika Stary, MD.*

spontaneously, following an incubation period of 3–12 days; the subsequent clinical manifestations are outlined in Table 69.10.

- Dx: detection of *Chlamydia*-specific DNA by PCR from affected tissues.
- **DDx:** see Table 69.8.
- **Rx:** see Table 69.9.



**Fig. 69.9 Congenital syphilis.** Red-brown plaques on the plantar surface, reminiscent of secondary syphilis in adults. Laboratory diagnosis includes identification of treponemes by darkfield microscopy and/or detection of 19S antibodies by the FTA-ABS-19S-IgM test (90% sensitivity) or spirochetemia by PCR.

## Granuloma Inguinale (Donovanosis)

- The etiologic agent is *Klebsiella granulomatis* (previously named *Calymmatobacterium granulomatis*), and the majority of infections occur in southern Africa, Southeast Asia, and northern Australia; histologically, "parasitized" macrophages with intracellular organisms (Donovan bodies) are seen.
- Clinically, an initial small papulonodule in the anogenital region ulcerates and then enlarges following an incubation period of up to 1 year (usually ~15–20 days); the base of the ulcer is often quite vascular with a foul-smelling drainage (Fig. 69.15).
- Dx: detection of Donovan bodies in smears of tissue scrapings or touch preps of biopsy specimens (see Ch. 2).
- **DDx:** see Table 69.8.
- **Rx:** see Table 69.9.

For further information see Ch. 82 from *Dermatology, Fourth Edition*.

**For additional online figures visit www.expertconsult.com**

| DIFFERENTIAL DIAGNOSES FOR SYPHILIS |
|---|
| **Primary syphilis** |
| Other causes of genital ulcers should be considered:<br>• Genital trauma<br>• Entities in Tables 69.8 and 60.7 (e.g. genital herpes, lichen planus, reactive non-sexually related acute genital ulcers [multiple etiologies including EBV])<br>• Fixed drug eruption<br>• Ulcerative genital carcinoma (e.g. squamous cell carcinoma)<br>• Behçet disease |
| **Secondary syphilis** |
| • Cutaneous: pityriasis rosea, guttate psoriasis, viral exanthems, lichen planus, pityriasis lichenoides chronica, primary HIV infection, drug eruption, nummular eczema, folliculitis<br>• Mucous membranes: lichen planus; chronic aphthae; hand, foot, and mouth disease; herpangina; perlèche<br>• Condylomata lata: warts due to HPV, bowenoid papulosis, squamous cell carcinoma |
| **Tertiary syphilis** |
| • Cutaneous: lupus vulgaris, chromoblastomycosis, dimorphic fungal infections, leishmaniasis, lupus erythematosus, mycosis fungoides, sarcoidosis, tumors, venous ulcer |

**Table 69.4 Differential diagnoses for syphilis.** *Courtesy, Angelika Stary, MD.*

| TREATMENT RECOMMENDATIONS FOR EARLY SYPHILIS (PRIMARY, SECONDARY, AND EARLY LATENT [ACQUIRED <1 YEAR PREVIOUSLY]) |
|---|
| ***Recommended*** |
| • Benzathine penicillin, 2.4 million units* IM as a single dose - *or* -<br>• Procaine penicillin, 1.2 million units IM daily for 10 days# |
| ***Alternative regimens for penicillin-allergic patients‡*** |
| • Doxycycline, 200 mg daily (100 mg PO BID preferred over a single 200-mg dose) for 14 days - *or* -<br>• Tetracycline, 500 mg PO qid for 14 days - *or* -<br>• Ceftriaxone, 1–2 gm IM or IV daily for 10–14 days - *or* -<br>• Azithromycin, 2 gm PO as a single dose§ |
| **Pregnancy** |
| ***Recommended*** |
| • Benzathine penicillin, 2.4 million units IM weekly for two doses |
| ***In the case of penicillin allergy*** |
| • Desensitization to penicillin - *or* -<br>• Alternative regimens**<br>  • Azithromycin, 500 mg daily for 10 days - *or* -<br>  • Ceftriaxone, 1 gm IM or IV daily for 10–14 days |
| **In children, 50,000 U/kg IM up to the adult dose.*<br>*#Alternative treatment regimen in the World Health Organization (WHO) guidelines (www.who.int/reproductivehealth/publications/rtis/syphilis-treatment-guidelines/en/) and the guidelines of the International Union against Sexually Transmitted Infections (IUSTI) (www.iusti.org/sti-information/guidelines/).*<br>*‡Limited data; desensitization to penicillin is recommended when compliance is an issue.*<br>*§Resistance reported; not recommended in men who have sex with men and pregnant women.*<br>***Limited data; not recommended by the CDC but included in the WHO and European Branch of the International Union against Sexually Transmitted Infections (IUSTI) guidelines.* |

**Table 69.5 Treatment recommendations for early syphilis (primary, secondary, and early latent [acquired <1 year previously]).** A Jarisch–Herxheimer reaction characterized by the acute onset of fever, headache, and myalgias can occur upon treatment of early syphilis. See the Centers for Disease Control and Prevention (CDC) guidelines (http://www.cdc.gov/std/treatment) or download the CDC STD Tx Guide App. h, hours; qid, four times daily.

| CLINICAL MANIFESTATIONS OF GONORRHEA | | |
|---|---|---|
| **Disseminated infection** | **Local extension** | **Direct mucosal infection** |
| • Arthritis<br>• Fever<br>• Tenosynovitis<br>• Acral cutaneous pustules<br>• Scalp abscesses*<br>• Endocarditis<br>• Meningitis | • Prostatitis<br>• Vesiculitis<br>• Epididymitis<br>• Salpingitis<br>• Oophoritis<br>• Pelvic inflammatory disease | • Urethritis<br>• Cervicitis<br>• Proctitis<br>• Pharyngitis<br>• Vulvovaginitis (children)<br>• Ophthalmia neonatorum |

**In neonates at sites of fetal scalp monitor electrodes.*

**Table 69.6 Clinical manifestations of gonorrhea.** Both urethritis and cervicitis lead to a purulent discharge. *Courtesy, Angelika Stary, MD.*



**Fig. 69.10 Gonococcal urethritis with a purulent urethral discharge.**



**Fig. 69.11 Gonococcemia (arthritis–dermatosis syndrome).** Pustule with surrounding erythema on the toe. *Courtesy, Angelika Stary, MD.*

**ESTIMATED WORLDWIDE PREVALENCE OF CHANCROID**

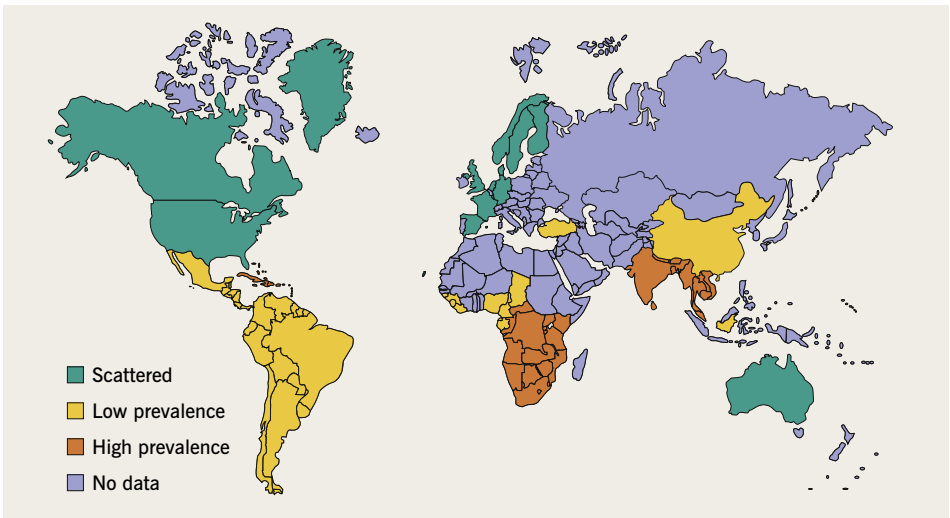


**Fig. 69.12 Estimated worldwide prevalence of chancroid.** *Adapted from Ronald A. Chancroid. In: Mandell GL (Ed.-in-Chief), Rein MF (Ed.), Atlas of Infectious Diseases: Vol. 5. Sexually Transmitted Diseases. New York: Current Medicine, 1995:16.1–10.*

| TREATMENT RECOMMENDATIONS FOR GONOCOCCAL INFECTIONS |
|---|
| **Uncomplicated gonococcal infections of the urethra, cervix, rectum or pharynx** |
| *Recommended regimen* |
| • Ceftriaxone, 500 mg IM in a single dose, PLUS doxycycline 100 mg PO BID x 7 days* |
| *Alternative regimens (urethra, cervix, rectum)* |
| • Gentamicin, 240 mg IM in a single dose, PLUS azithromycin 2 gm PO in a single dose<br>• Cefixime, 800 mg PO in a single dose, PLUS doxycycline 100 mg PO BID x 7 days* |
| **Disseminated gonococcal infection** |
| *Recommended regimen* |
| • Ceftriaxone, 1 gm IM or IV q24h, PLUS azithromycin 1 gm PO in a single dose<br>• 24–48 hours after substantial clinical improvement and guided by antimicrobial susceptibility testing, can switch to oral agent (e.g. cefixime 400 mg PO BID) to complete at least 1 week of therapy |
| *Alternative regimens* |
| • Cefotaxime or ceftizoxime, 1 gm IV q8h, PLUS azithromycin 1 gm PO in a single dose<br>• Switch to oral agents as above |
| *If *Chlamydia* not excluded, add doxycyline or during pregnancy add azithromycin 1 g in a single dose; dose of ceftriaxone is 1 gm IM if patient weighs ≥150 kg. |

**Table 69.7 Treatment recommendations for gonococcal infections.** Examination and treatment of sexual partners is also indicated. Recommendations are based on the CDC guidelines (www.cdc.gov/std/treatment). h, hours; q, every.




**Fig. 69.13 Chancroid. A** Well-demarcated painful ulcers on the penis. **B** Multiple purulent ulcers with undermined borders. **C** Unilateral lymphadenitis with overlying erythema. *A, C, Courtesy, YDRSC; B, Courtesy, Joyce Rico, MD.*

| INFECTIOUS CAUSES OF GENITAL ULCER DISEASE | | | | |
|---|---|---|---|---|
| **Disease** | **Incubation time** | **Clinical lesion** | **Diagnosis** | **Organism** |
| Genital herpes | 3–7 days | Vesicles, erosions, ulcers; history of herpes infection; painful | PCR, culture, DFA, Tzanck (if vesicles) | HSV 2 > 1 |
| Primary syphilis | 10–90 days, average 3 weeks | Non-purulent; usually single ulcer; indurated; relatively painless | Darkfield microscopy, serology, PCR | *Treponema pallidum* |
| Chancroid | 3–10 days | Purulent; often multiple ulcers; soft, undermined edges; painful | Culture, PCR | *Haemophilus ducreyi* |
| LGV | 3–12 days | Transient ulcer; indurated; painless | PCR, culture, serology | *Chlamydia trachomatis* serovars L1–L3 |
| Donovanosis | 2–12 weeks | Chronic ulcer; indurated, beefy red, friable | Smears, histology | *Klebsiella* (*Calymmatobacterium*) *granulomatis* |

**Table 69.8 Infectious causes of genital ulcer disease.** LGV, lymphogranuloma venereum. *Courtesy, Angelika Stary, MD.*

| TREATMENT REGIMENS FOR CHANCROID, LGV, AND GRANULOMA INGUINALE |
|---|
| **Chancroid** |
| • Azithromycin, 1 gm PO, single dose - *or* -<br>• Ceftriaxone, 250 mg IM, single dose - *or* -<br>• Ciprofloxacin, 500 mg PO BID for 3 days*,† - *or* -<br>• Erythromycin base, 500 mg PO QID for 7 days† |
| **LGV** |
| • Recommended: doxycycline, 100 mg PO BID<br>• Alternative and in case of pregnancy: erythromycin base, 500 mg PO QID<br>**Duration for both regimens:** at least 3 weeks |
| **Granuloma inguinale** |
| ***Recommended*****<br>• Azithromycin, 1 gm PO once weekly - *or* - 500 mg PO daily<br>Alternative**<br>• Doxycycline, 100 mg po BID – *or* –<br>• Trimethoprim–sulfamethoxazole, 1 double-strength (160 mg/800 mg) tablet PO BID - *or* -<br>• Ciprofloxacin, 750 mg PO BID - *or* -<br>• Erythromycin base, 500 mg PO QID<br>**Duration for all regimens:** until all lesions completely healed (at least 3 weeks) |
| **Contraindicated for pregnant or lactating women.*<br>†*Worldwide, isolates with intermediate resistance.*<br>***For any of the regimens, the addition of an aminoglycoside (e.g. gentamicin 1 mg/kg iv q8h) should be considered if lesions do not respond within the first few days of therapy.* |

**Table 69.9 Treatment regimens for chancroid, LGV, and granuloma inguinale.** Examination and treatment of sexual partners is also indicated. LGV, lymphogranuloma venereum; QID, four times daily. *Courtesy, Angelika Stary, MD.*

| CLINICAL MANIFESTATIONS OF LYMPHOGRANULOMA VENEREUM |
|---|
| **Initial manifestations: 3–12 days** |
| • Papule<br>• Erosion or ulcer<br>• Herpetiform vesicle<br>• Nonspecific urethritis or cervicitis |
| **Inguinal syndrome: 10–30 days up to 6 months** |
| • Regional lymphadenopathy (mostly inguinal and femoral; also perirectal, deep iliac)<br>• Overlying erythema<br>• Constitutional symptoms<br>• Eruption of buboes<br>• Pelvic inflammatory disease (PID), back pain |
| **Ano-genito-rectal syndrome: months to years** |
| • Proctocolitis<br>• Hyperplasia of intestinal and perirectal lymphatic tissue<br>• Perirectal abscesses<br>• Ischiorectal and rectovaginal fistulas<br>• Anal fistulas<br>• Rectal strictures and stenoses |
| **Other manifestations** |
| • Urethro-genito-perineal syndrome<br>• Peno-scrotal elephantiasis<br>• Erythema nodosum<br>• Submaxillary or cervical lymphadenopathy associated with oropharyngeal lesions |

**Table 69.10 Clinical manifestations of lymphogranuloma venereum.** *Courtesy, Angelika Stary, MD.*



**Fig. 69.14 Lymphogranuloma venereum.** Inguinal bubo that has ruptured and drained. *Courtesy, Angelika Stary, MD.*

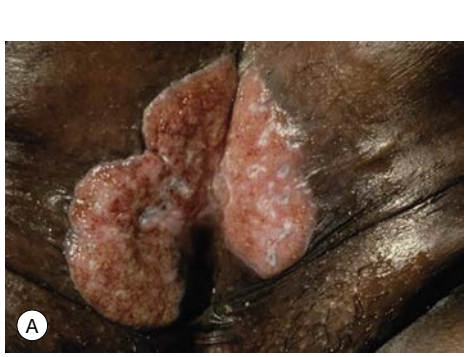





**Fig. 69.15 Granuloma inguinale (donovanosis). A** Large ulcers with a characteristic "beefy" appearance. **B** The vulva is the most common site of involvement in women with granulomatous plaques as well as ulcerations. *A, Courtesy, Joyce Rico, MD; B, Courtesy, Francisco Bravo, MD.*

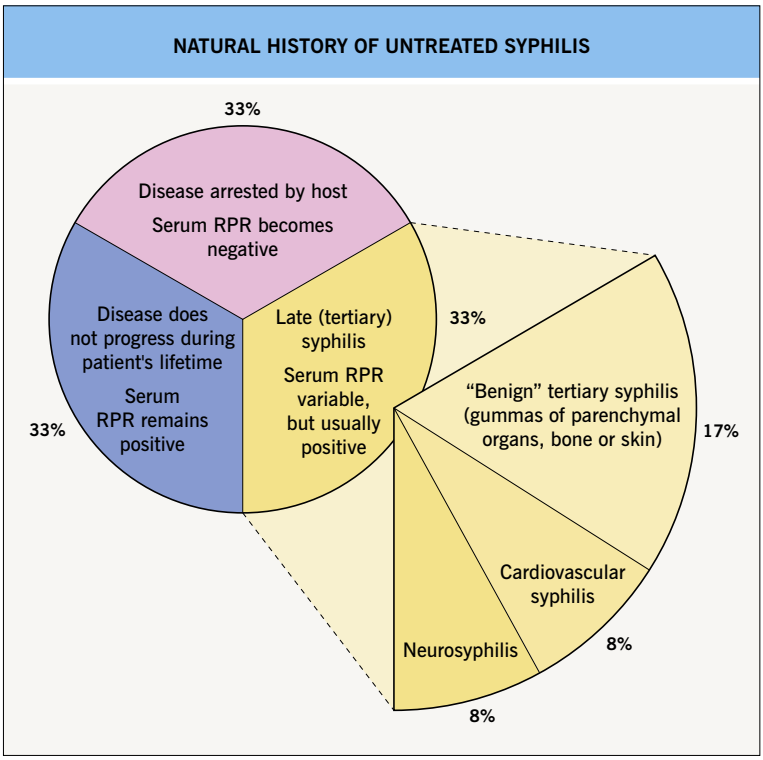


**eFig. 69.1 Natural history of untreated syphilis.** The data represent a composite of several studies. The specific antibody assays (e.g. MHA-TP, FTA-ABS) usually remain positive. *Courtesy, Angelika Stary, MD.*



**eFig. 69.2 Positive darkfield examination.** Treponemes are recognized by their characteristic corkscrew shape as well as their deliberate forward and backward movement with rotation about the longitudinal axis. *From Morse SA, et al. Atlas of Sexually Transmitted Diseases and AIDS, 3rd edn. London: Mosby, 2003.*

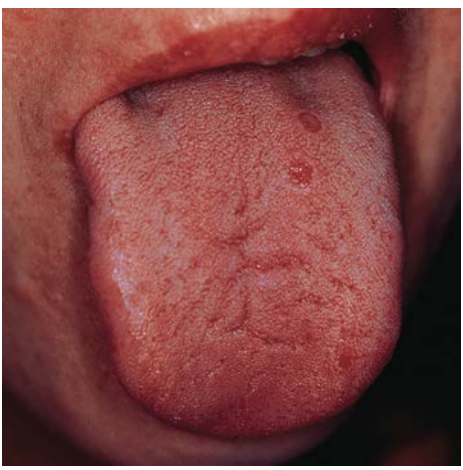

**eFig. 69.3 Small superficial tongue ulcer in a patient with secondary syphilis.** *Courtesy, YDRSC.*



**eFig. 69.4 "Malignant" syphilis.** Multiple necrotic, ulcerated, and crusted lesions associated with severe constitutional symptoms. *Courtesy, Angelika Stary, MD.*

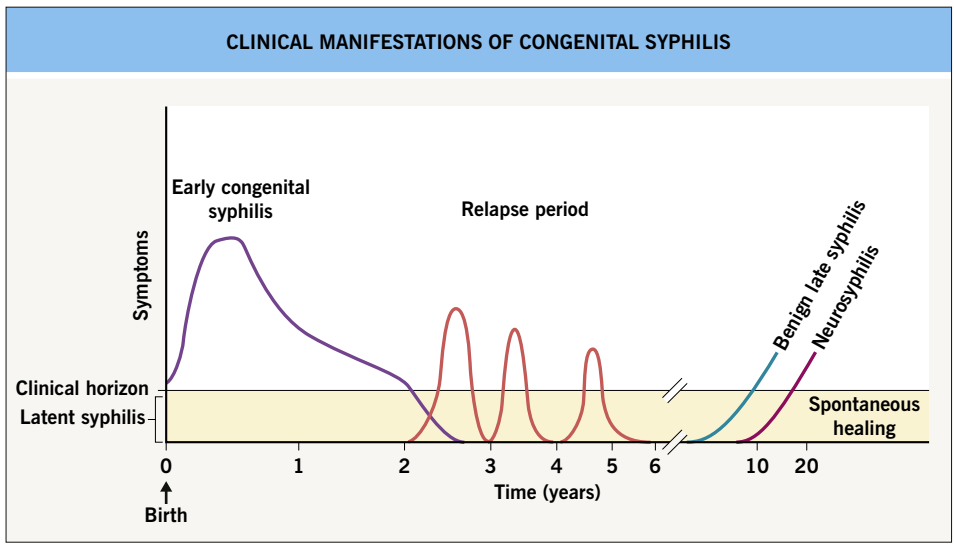


**eFig. 69.5 Time course for clinical manifestations of congenital syphilis.** *Adapted from Fritsch P, Zangerle R, Stary A. Venerologie. In: Fritsch P (ed). Dermatologie und Venerologie. Berlin: Springer, 2004:865–86.*

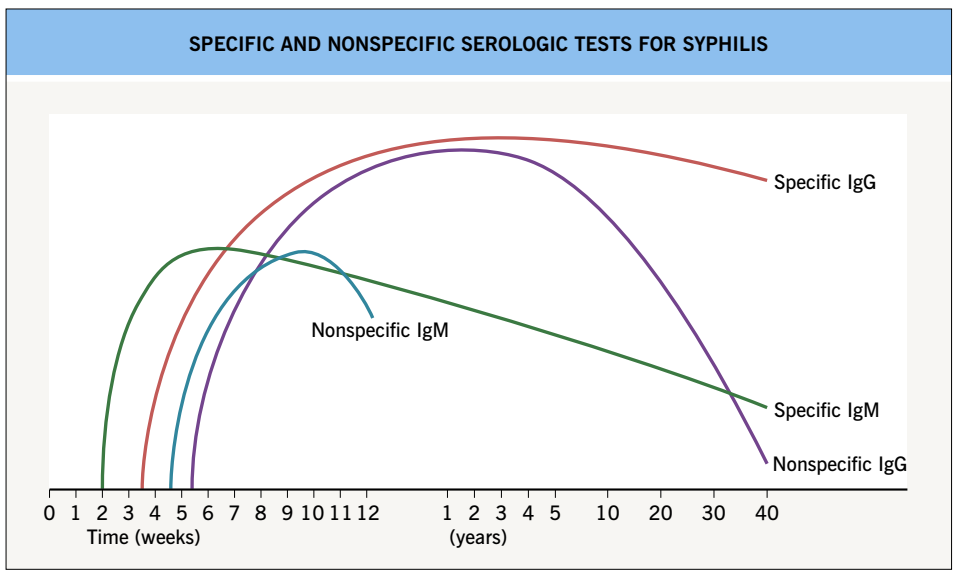


**eFig. 69.6 Specific and nonspecific serologic tests for syphilis.** These curves represent untreated patients. Non-treponemal tests are nonspecific and treponemal tests are specific. *Adapted from Fritsch P, Zangerle R, Stary A. Venerologie. In: Fritsch P (ed). Dermatologie und Venerologie. Berlin: Springer, 2004:865–86.*

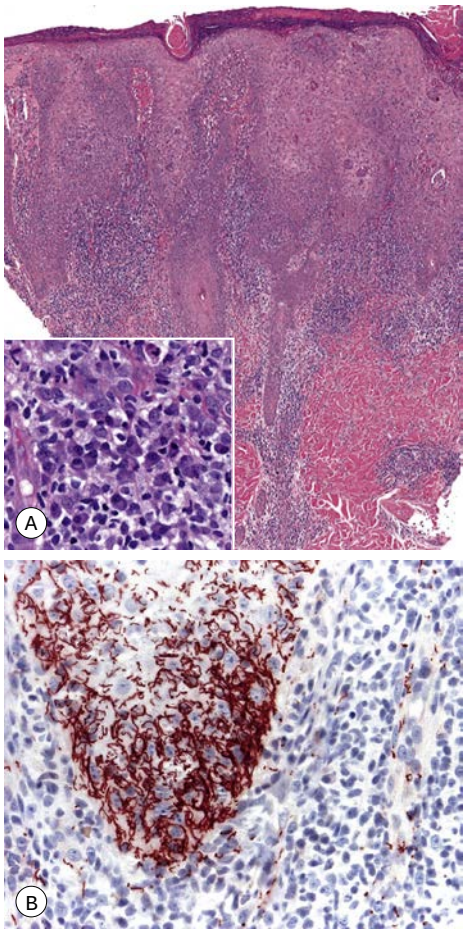


**eFig. 69.7 Histopathology of secondary syphilis.** **A** Psoriasiform epidermal hyperplasia and a dense dermal infiltrate of plasma cells (see inset), lymphocytes, and histiocytes are observed. **B** Positive immunohistochemical staining with an anti-*Treponema pallidum* antibody; note the characteristic elongated, twisted shape of the spirochetes. *Courtesy, Lorenzo Cerroni, MD.*

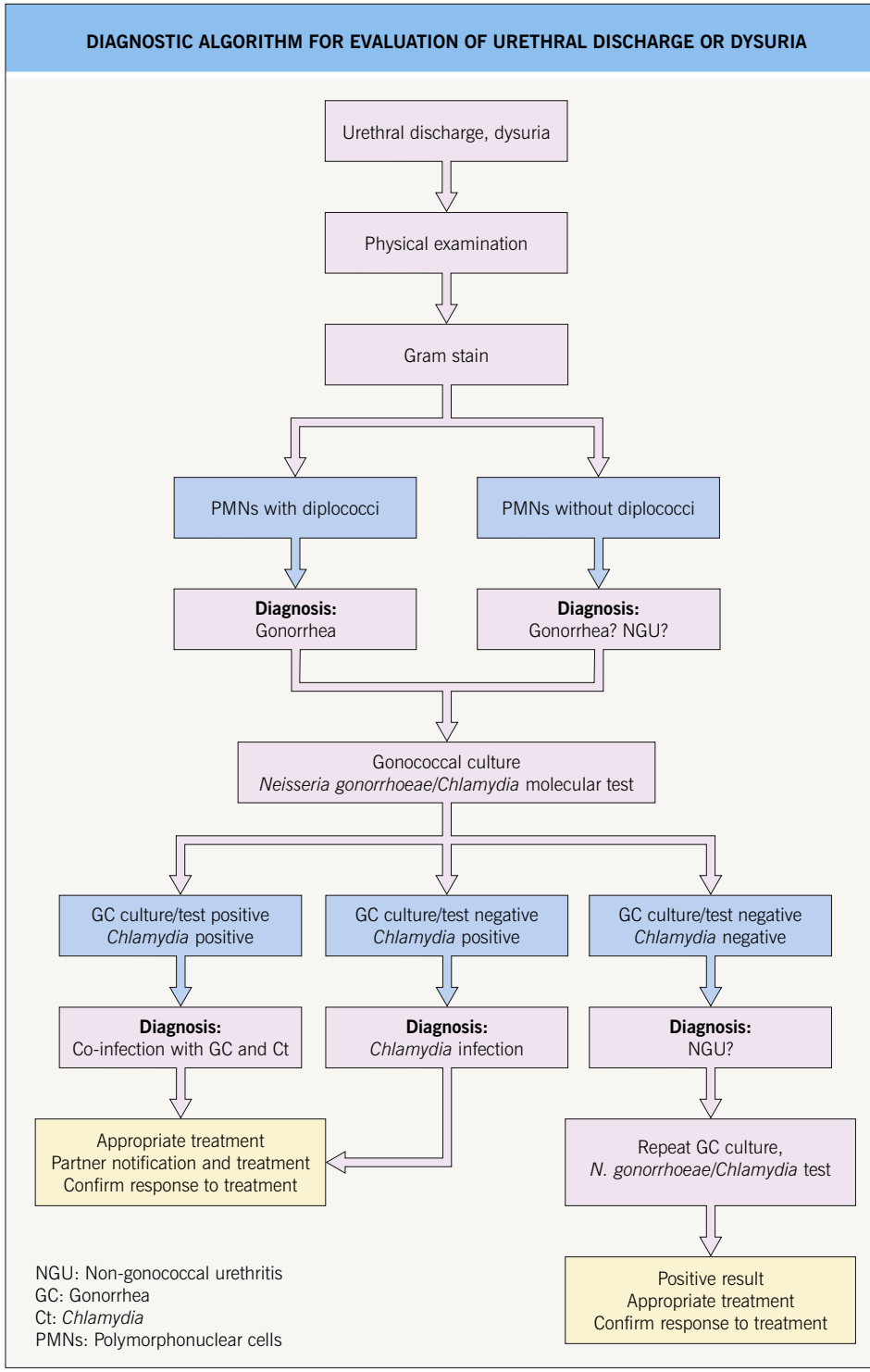


**eFig. 69.8 Diagnostic algorithm for evaluation of urethral discharge or dysuria.** *Courtesy, Angelika Stary, MD.*

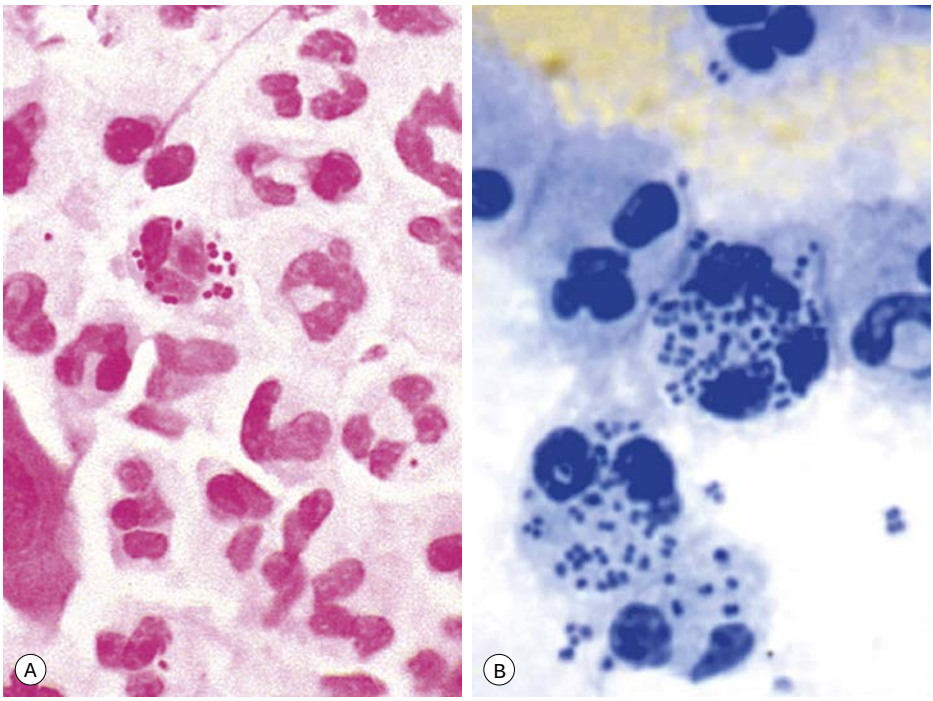


**eFig. 69.9 Gonococci in Gram-stained (A) and methylene blue-stained (B) smears of urethral discharge.** Neutrophils containing Gram-negative or methylene blue-positive diplococci, consistent with *Neisseria gonorrhoeae*, are evident. *B, Courtesy, Harald Moi, MD.*

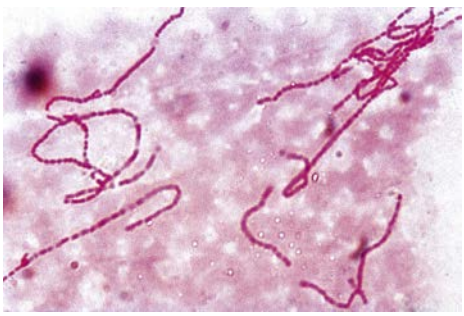

**eFig. 69.10 Gram-stained smear in chancroid.** This smear of exudate from a genital ulcer shows the characteristic chaining pattern of *Haemophilus ducreyi*. *Courtesy, Angelika Stary, MD.*

# 70 Protozoa and Worms

## Leishmaniasis

- Three major forms: (1) cutaneous (Fig. 70.1); (2) mucocutaneous (Fig. 70.2); and (3) visceral (e.g. liver, spleen).
- Caused by more than 15 different species of *Leishmania* (Table 70.1).
- Vector = sandfly (*Phlebotomus* and *Lutzomyia* spp.) (Fig. 70.3).
- Disease seen worldwide but endemic in areas of Asia, Africa, Latin America, and the Mediterranean basin (Fig. 70.4).
- Cutaneous disease affects skin only and is commonly a papule that expands and ulcerates (Fig. 70.5); pattern may be sporotrichoid (Fig. 70.6; see Table 64.7), disseminated, or diffuse (Fig. 70.7); lesion(s) may heal spontaneously (Fig. 70.8).
- Mucocutaneous form, often due to *Leishmania brasiliensis*, involves mucosal (e.g. nose, lips, oropharynx) sites as well as the skin.
- Visceral leishmaniasis (kala-azar) affects the bone marrow, spleen, and liver and is commonly due to *Leishmania donovani*; symptoms include fever, cough, lymphadenopathy, and hepatosplenomegaly; post-kala-azar dermal leishmaniasis (Fig. 70.9) may follow treatment.
- **Rx:** for an isolated or limited number of lesions, conservative therapy (e.g. observation, heat, cryotherapy), topical paromycin, or intralesional pentavalent antimonial; for more extensive disease, IV or IM pentavalent antimonial (sodium stibogluconate, meglumine antimonate), oral miltefosine.

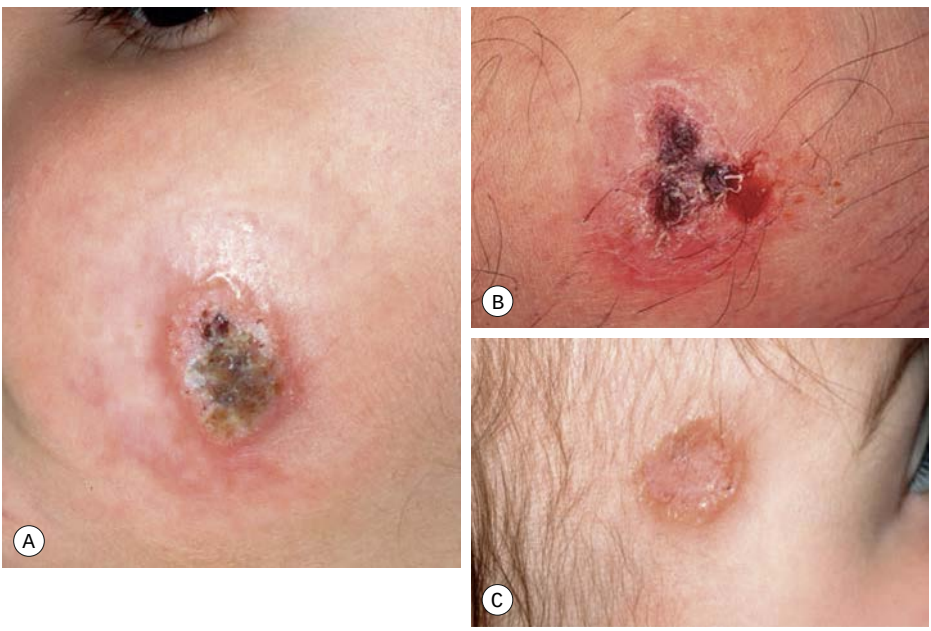


**Fig. 70.1 Variable presentations of cutaneous leishmaniasis.** Ulcerated plaques with rolled border **(A)** and central crusting **(A, B)**. Plaque with translucent borders containing telangiectasias and central scarring **(C).** Cutaneous leishmaniasis is sometimes mistaken for a basal cell carcinoma in adults. *A, C, Courtesy, Julie V. Schaffer, MD; B, Courtesy, YDRSC.*

| FOUR MAJOR SPECIES OF *LEISHMANIA* THAT CAUSE CUTANEOUS DISEASE | | |
|---|---|---|
| **Complex** | **Species** | **Major geographic distribution** |
| *Leishmania tropica* | *L. major* | Arid areas of Africa (north and south of the Sahara), Middle East, Central Asia |
| | *L. tropica* | Eastern Mediterranean region, Middle East, Central Asia |
| *Leishmania mexicana* | *L. mexicana* | Mexico, Central America |
| *Leishmania braziliensis* | *L. braziliensis** | Central and South America |

**Can also cause mucosal leishmaniasis or visceral leishmaniasis in immunocompromised individuals.*

**Table 70.1 Four major species of *Leishmania* that cause cutaneous disease.**

• For assistance in diagnosis and treatment, helpful sources of information include the Centers for Disease Control and World Health Organization.

## Amebiasis

• Protozoan infection (*Entamoeba histolytica*) that most commonly causes colitis; fecal–oral spread.
• Occasionally presents in the skin with necrotic ulcers that can resemble pyoderma gangrenosum or verrucous plaques that resemble squamous cell carcinoma or condyloma acuminatum.
• Skin involvement generally secondary to extension of rectal amebiasis to perianal or perigenital skin or extension of a liver abscess to skin of abdominal wall.
• **Rx:** for *Entamoeba histolytica*, metronidazole; other treatments include diloxanide, tinidazole.

## Free-Living Ameba

• *Balamuthia mandrillaris* can infect immunocompetent (especially children) and immunocompromised patients; the typical cutaneous lesion is a slow-growing indurated plaque on the central face with eventual hematogenous spread to the central nervous system.
• *Acanthamoeba* spp. can cause cutaneous papulonodules and encephalitis in immunocompromised patients.

## Trypanosomiasis – American (Chagas disease)

• *Trypanosoma cruzi* carried by reduviid (kissing) bugs.



**Fig. 70.2 Mucocutaneous leishmaniasis.** Ulceration and induration of the nasal vestibule extending onto the cutaneous lip due to *Leishmania braziliensis*. *Courtesy, Kalman Watsky, MD.*

• Endemic in areas of Central and South America.
• Systemic disease that can affect the autonomic nervous system, gastrointestinal tract, and heart.
• Primary acute phase: local erythema and edema at inoculation site ± regional lymphadenopathy; when periorbital, termed Romaña sign (Fig. 70.10).
• Chronic phase seen after years to decades: congestive heart failure, arrhythmias, including heart block, megacolon, megaesophagus.

## Trypanosomiasis – African

• Vector = tsetse fly.
• Found in both West (*Trypanosoma brucei gambiense*) and East (*Trypanosoma brucei rhodesiense*) Africa.
• Skin findings: trypanosomal chancre (localized bite reaction; Fig. 70.11) and annular erythematous eruption with fever.

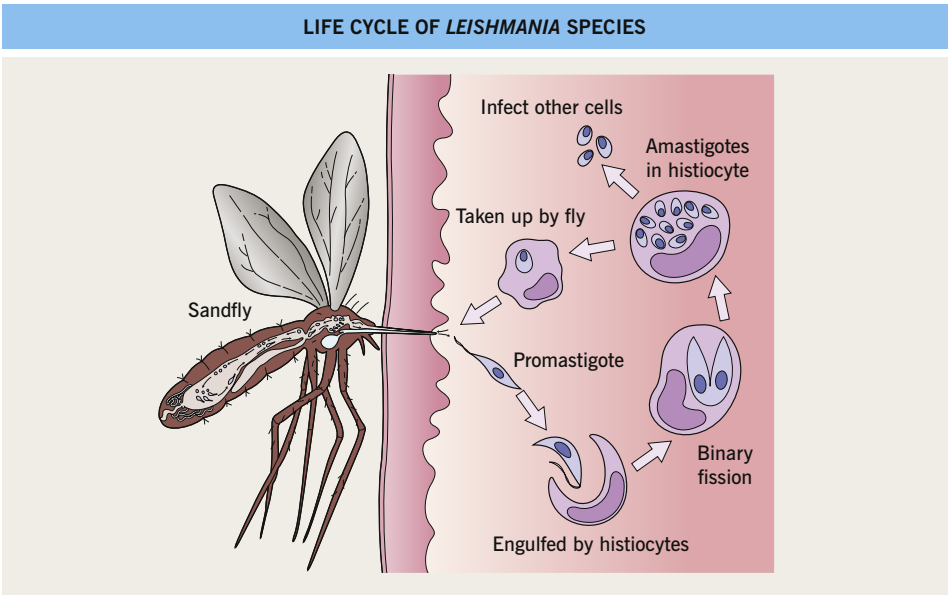


**Fig. 70.3 Life cycle of *Leishmania* species.** Promastigotes develop within the gut of the sandfly and then migrate to the proboscis.

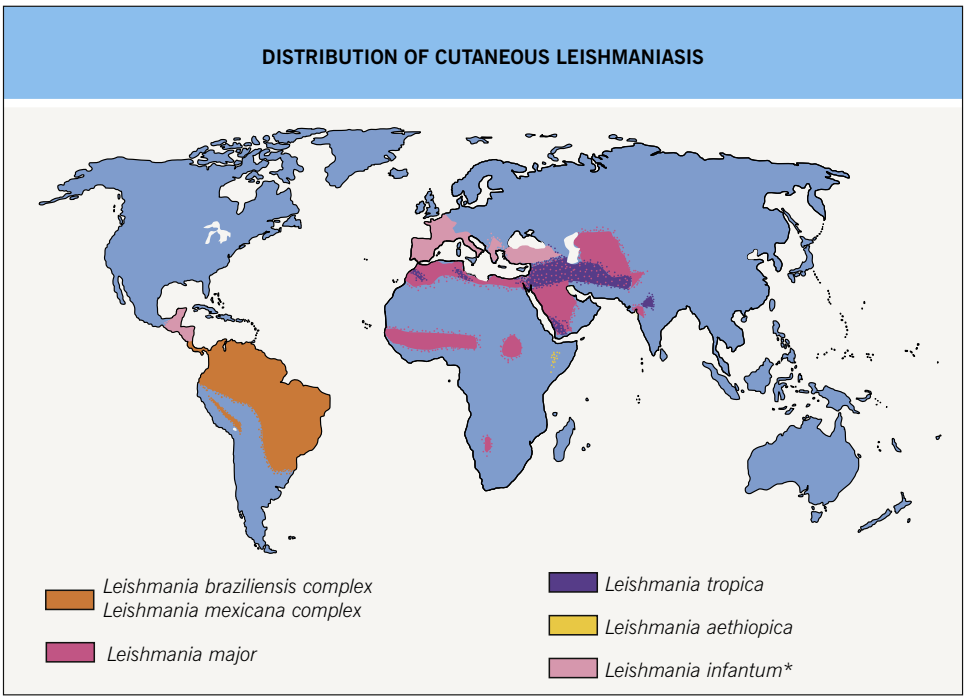


**Fig. 70.4 Distribution of cutaneous leishmaniasis.** *The *L. infantum* subspecies in Central and South America was previously known as *L. chagasi*. *Adapted with permission from Davidson RN, Leishmaniasis. In Cohen J, Powderly WG (Eds.), Infectious Diseases. Edinburgh, UK: Mosby, 2004.*



**Fig. 70.5 Ulcerative cutaneous leishmaniasis on the leg and a positive Montenegro test.** This expanding ulcer could be misdiagnosed as pyoderma gangrenosum. *Courtesy, Omar P. Sangüeza, MD.*




**Fig. 70.7 Diffuse and disseminated cutaneous leishmaniasis. A** Diffuse cutaneous leishmaniasis presenting with large nodules that resemble lepromatous leprosy. **B** Small papules in disseminated cutaneous leishmaniasis. *Courtesy, Francisco G. Bravo.*

- Winterbottom's sign – enlargement of nodes of posterior cervical triangle – classic finding in West African form.

## Toxoplasmosis

- Worldwide infection secondary to *Toxoplasma gondii*; oocytes present in cat feces or infected meat.
- Rare skin involvement; congenital infections present with necrotic or hemorrhagic papules on the trunk ('T' in TORCH complex).



**Fig. 70.6 Sporotrichoid form of cutaneous leishmaniasis.** *With permission from Tyring S, Lupi O, Hengge U (Eds.), Tropical Dermatology. Oxford: Churchill Livingstone, 2005.*

- Common presentations include cervical lymphadenitis or chorioretinitis.
- Tissue cysts may lead to recrudescence in immunosuppressed individuals.

## Cutaneous Larva Migrans

- Secondary to larvae of *animal* (e.g. usually wild/domestic dogs/cats) hookworms (intestinal nematodes), e.g. *Ancylostoma braziliense.*
- Worldwide, but especially common in tropical/subtropical areas and the southwestern United States.
- Larvae in infected soil, including sand, penetrate the skin.
- Pruritic, inflamed, serpiginous tracks are produced by migrating organisms (Fig. 70.12); migration averages 1–2 cm/day.
- Most common locations are the lower extremities, especially the feet, and buttocks, due to walking and sitting at the beach.
- **DDx:** not to be confused with larva currens (secondary to *Strongyloides*; see Table 70.2).
- Disease is self-limited but treatment can include oral albendazole or ivermectin; topical thiabendazole for localized disease.



**Fig. 70.8 Scars secondary to previous cutaneous leishmaniasis.** Circular scars at previous sites of cutaneous leishmaniasis are often the only sign of a prior infection. *Courtesy, Omar P. Sangüeza, MD.*



**Fig. 70.10 Chagas disease.** Young child with unilateral periorbital edema characteristic of this disease (Romaña sign) when the conjunctiva is the portal of entry. *Courtesy, Omar P. Sangüeza, MD.*

## Onchocerciasis

- Secondary to *Onchocerca volvulus*, a tissue-dwelling nematode.
- Vector = black fly (*Simulium*).
- Endemic in Africa, Yemen, and some areas of Central and South America; near fast-flowing rivers.
- Skin findings: subcutaneous nodules containing adult worms (onchocercomas), pruritic papular dermatitis, depigmented, lichenified skin, especially over the shins (sowda) (Fig. 70.13).
- Chronic ocular involvement leads to sclerosing keratitis, iridocyclitis, and ultimately blindness, hence the name river blindness.
- **Rx:** oral ivermectin (single dose – non-endemic areas; repeated doses – endemic areas); sometimes doxycycline is subsequently added to sterilize adult female worms.



**Fig. 70.9 Post-kala-azar dermal leishmaniasis.** Nodules of various sizes, some pedunculated, are seen in this patient who had been treated for kala-azar over a period of 6 months, 20 years previously. *With permission from Peters W, Pasvol G. Tropical Medicine and Parasitology, 6th edition, London, Mosby, 2007.*

## Filariasis

- Tissue nematodes (*Wuchereria bancrofti* or *Brugia malayi/B. timori*) infect the lymphatic system.
- Vector = mosquito (*Culex*, *Anopheles*, *Aedes* spp.).



**Fig. 70.11 Trypanosomal chancre.** The bite reaction, the earliest clinical lesion, is known as a "trypanosomal chancre." It resembles a boil but is usually painless. Fluid aspirated from the nodule contains actively dividing trypanosomes. This reaction is seen more commonly in *T. b. rhodesiense* than in *T. b. gambiense* infection. *With permission from Peters W, Pasvol G, Tropical Medicine and Parasitology, 6th ed. London: Mosby, 2007.*




**Fig. 70.12 Cutaneous larva migrans.** Note the characteristic serpiginous erythematous tracks on the lateral foot **(A)**, both feet **(B),** and the shoulder **(C)**. Vesiculation and crusting **(B)** are sometimes seen. *B, Courtesy, Peter Klein, MD; C, Courtesy, Julie V. Schaffer, MD.*

- Endemic in tropical and subtropical regions of India, the Americas, and Africa.
- Acute form: lymphangitis and orchitis.
- Chronic form: lymphedema, elephantiasis (the enlarged limb becomes indurated with skin folds and overlying verrucous changes), hydrocele, chyluria.
- Complicated by recurrent cellulitis.

## Schistosomiasis

- Trematode (fluke) infection secondary to three major species with specific geographic distributions (Africa – *Schistosoma hematobium*, Asia – *S. japonicum*, South America – *S. mansoni*); intermediate host is the freshwater snail; organisms penetrate skin.
- Variants of cutaneous disease – cercarial dermatitis (transient erythema, urticaria, or pruritic papules), Katayama fever (systemic allergic reaction with urticaria, fever, chills, sweats, headache, peripheral eosinophilia).
- Chronic fibro-occlusive disease in the liver (*S. japonicum*), intestine (*S. mansoni*), or urinary tract (*S. hematobium*).

## Swimmer's Itch

- Cercariae of >20 species of *animal* schistosomes (e.g. *Ornithobilharzia*) can penetrate skin and cause swimmer's itch.

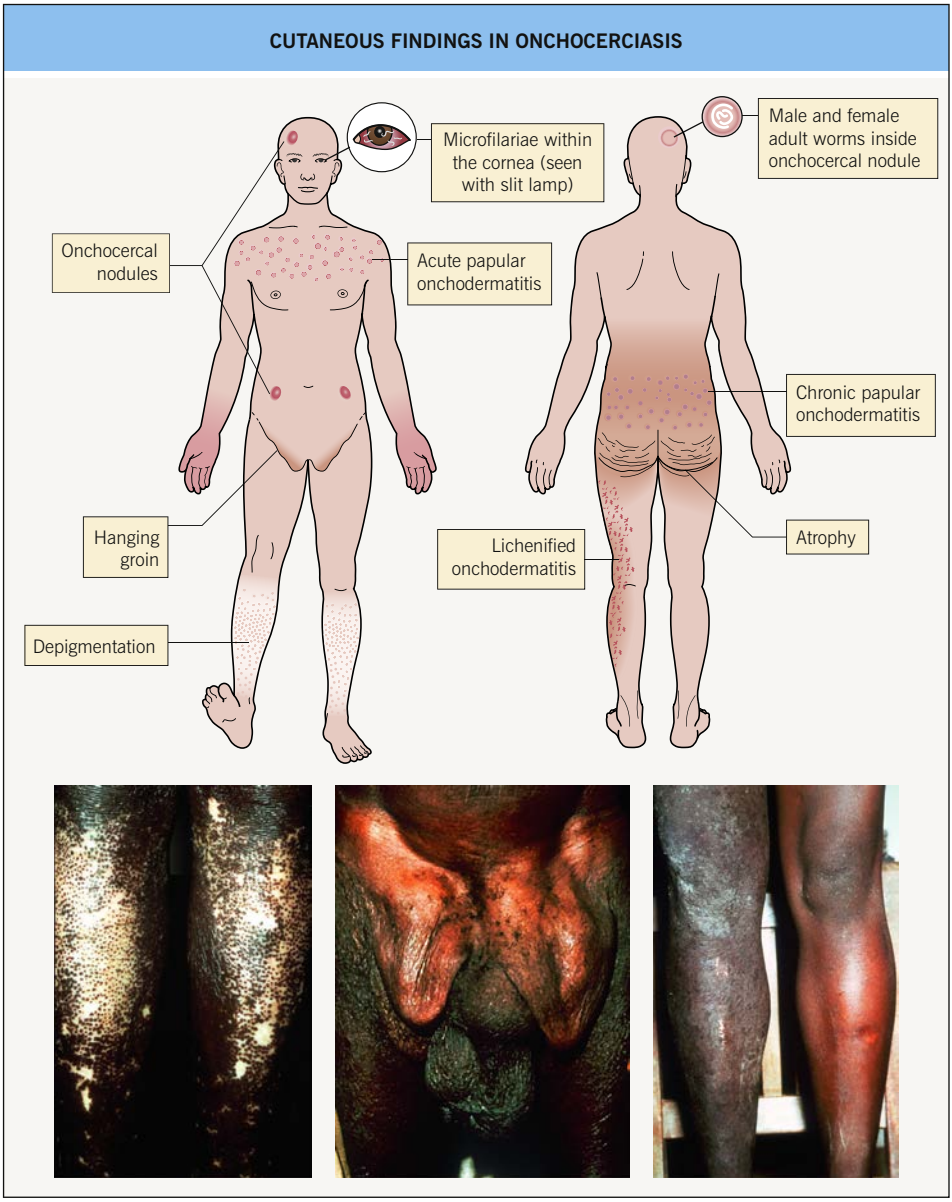


**Fig. 70.13 Cutaneous findings in onchocerciasis.** Photos: left, depigmentation with perifollicular sparing ("leopard" skin); middle, hanging groin due to chronic lymphatic obstruction and lymph node involvement; right, lichenified onchodermatitis ("sowda"). *Insets, courtesy, David O. Freeman, MD.*



**Fig. 70.14 Swimmer's itch.** Numerous edematous dark red papules on the feet and ankles. *Courtesy, Kalman Watsky, MD.*

- Worldwide; endemic to the Great Lakes.
- Erythematous papules on exposed skin (Fig. 70.14).
- Self-limited (7–10 days).
- Not to be confused with seabather's eruption (secondary to *Linuche*, *Edwardsiella* spp.), which affects areas under the swimsuit (see Ch. 72).

## Cysticercosis

- Cestodes (tapeworms; e.g. *Taenia solium*) that more commonly infect animals may infect humans; spread from ingestion of contaminated meat or fecal–oral spread.



**Fig. 70.15 Strongyloidiasis hyperinfection.** Multiple purpuric lesions (sometimes referred to as "thumbprint" purpura) on the abdomen of an immunocompromised patient. *Courtesy, Jean L. Bolognia, MD.*

- Skin findings: small, asymptomatic papulonodules.
- May have systemic involvement of the brain, eye, heart, muscles, or peritoneal cavity.

## Echinococcosis

- Cestode (tapeworm *Echinococcus*) that usually infects dogs; spread from ingestion of contaminated dog feces.
- Human may be an intermediate host and develop liver or lung hydatid cysts.
- Rarely leads to urticaria, asthma, or anaphylaxis.

## Gnathostomiasis

- Due to ingestion of raw or poorly cooked freshwater fish (e.g. ceviche) and eels or frogs that contain larvae of *Gnathostoma* spp. (nematodes).
- Transient subcutaneous swellings that may be pruritic are due to migration of the larvae.

See Table 70.2 for a summary of other major parasitic worms that cause skin findings.

For further information see Ch. 83 from *Dermatology, Fourth Edition*.

**For additional online figures visit www.expertconsult.com**

| OTHER MAJOR PARASITIC WORMS THAT CAUSE CUTANEOUS MANIFESTATIONS IN HUMANS | | | | | |
|---|---|---|---|---|---|
| **Disease** | **Organism** | **Distribution** | **Mode of spread** | **Skin findings** | **Systemic findings** |
| Enterobiasis (pinworms), intestinal nematode | *Enterobius vermicularis* | Widespread and high prevalence, especially in countries within temperate zones | Ingestion of eggs | Perianal and perineal pruritus | Restlessness<br>Asymptomatic in most patients |
| Ancylostomiasis (human hookworms), intestinal nematode | *Ancylostoma duodenale*, *Necator americanus* | Tropical and subtropical distribution | Percutaneous via contact with infective larvae in soil | Dermatitis ("ground itch") at the site of larval entry | Iron deficiency anemia, GI symptoms, Loeffler syndrome, eosinophilia |
| Strongyloidiasis, intestinal nematode | *Strongyloides stercoralis* | Occurs worldwide, especially in tropical areas; in cooler climates found in warm humid deep mines | Percutaneous via contact with infective larvae; occasionally ingestion of larvae<br>Autoinfection via penetration of perianal skin<br>Hyperinfection in immunocompromised patients, due to penetration of intestinal mucosa | Generalized or localized urticarial eruption beginning perianally and extending to the buttocks, thighs, and abdomen (larva currens)<br>"Thumbprint" purpura in hyperinfection (Fig. 70.15) | Diarrhea, duodenitis, eosinophilia, pulmonary symptoms<br>Symptoms more severe in immunocompromised patients |
| Loiasis, tissue nematode | *Loa loa* | West and central Africa | Transmitted by bite of tabanid flies of the genus *Chrysops* (mango flies) carrying infective larvae<br>Mature in connective tissue | Transient localized subcutaneous edema (Calabar swellings), often of the hands, wrists and forearms; represent tracts of migrating adult worms; associated with pruritus and pain | Conjunctivitis (due to movement of adult worms under conjunctiva), eosinophilia, renal disease |

**Table 70.2 Other major parasitic worms that cause cutaneous manifestations in humans.** *Continued*

| OTHER MAJOR PARASITIC WORMS THAT CAUSE CUTANEOUS MANIFESTATIONS IN HUMANS | | | | | |
|---|---|---|---|---|---|
| **Disease** | **Organism** | **Distribution** | **Mode of spread** | **Skin findings** | **Systemic findings** |
| Dirofilariasis, tissue nematodes of animals | *Dirofilaria immitis* (dog heartworms); *D. tunuis* (filaria of raccoons); *D. repens* (filaria of dogs and cats); *D. ursi* (filaria of bears) | *D. immitis* occurs worldwide; *D. tunuis* in southeast US; *D. repens* in Europe and Asia; *D. ursi* in North America and Japan | Transmitted by mosquitoes carrying infective larvae<br>Do not mature in humans | *D. tunuis*, *D. repens*, and *D. ursi* cause small painful subcutaneous nodules with or without inflammation | *D. immitis* causes nodules in the lungs |
| Dracunculiasis (guinea worm), tissue nematode | *Dracunculus medinensis* | Africa, particularly Ghana and the Sudan | Ingestion of infected water fleas of the genus *Cyclops* in drinking water<br>Migrate from intestine to subcutaneous tissue, usually of the legs | Papulonodule then blister and/or ulceration, usually of the lower extremity; calcified nodules | Anaphylactic shock, rheumatic symptoms |
| Trichinosis, tissue nematode | *Trichinella spiralis* | Widespread in temperate zones | Ingestion of encysted larvae from raw/undercooked animal meat, usually pork | Periorbital edema in severe infection, splinter hemorrhages | Most infections are subclinical<br>Heavy infection also leads to fever, enteritis, myositis, and eosinophilia; occasionally myocarditis and encephalitis |
| Sparganosis, larval stage of tapeworms of dogs and cats, cestode | *Spirometra* | Sporadic in most countries, seen most frequently in the Far East | Ingestion of larvae in intermediate hosts (e.g. snakes, frogs, fish)<br>Occasionally following application of frogs to eyes as poultice | Painless small subcutaneous nodules at sites of larval proliferation<br>Edema if periorbital involvement | Rarely, pulmonary or CNS involvement |

**Table 70.2** *Continued* **Other major parasitic worms that cause cutaneous manifestations in humans.**



**eFig. 70.1 Cutaneous leishmaniasis.** Ulcerated nodule with rolled border. *Courtesy, Omar P. Sangüeza, MD.*



**eFig. 70.2 Mucocutaneous leishmaniasis.** Infiltration of the nose and upper lip is evident. Note the destruction of the nasal alae and crusting of the upper lip. *Courtesy, Jaqueline Luque, MD.*

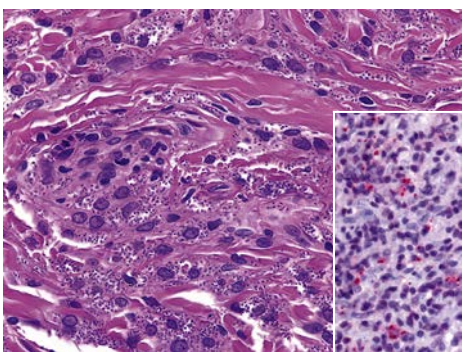

**eFig. 70.3 Histopathology of leishmaniasis.** Parasitized macrophages that contain amastigotes are seen in the dermis and highlighted by CD1a immunostaining (inset). Each amastigote has a nucleus and kinetoplast (not always visible) at opposite poles. *Courtesy, Luis Requena, MD; inset, courtesy, Lorenzo Cerroni, MD.*



**eFig. 70.4 Cutaneous amebiasis.** Multiple large ulcers on the leg of a patient with amebiasis. Note the extensive tissue destruction and resemblance to pyoderma gangrenosum. *Courtesy, Omar P. Sangüeza, MD.*




**eFig. 70.5** ***Balamuthia mandrillaris*** **infection.** **A** Indurated plaque on the nose. **B** Infiltration that has progressed to involve a large portion of the face. **C** Indurated plaque on the knee, which represents another common site. *A, B, with permission from Tyring S, Lupi O, Hengge U (eds). Tropical Dermatology. Churchill Livingstone, 2005.*




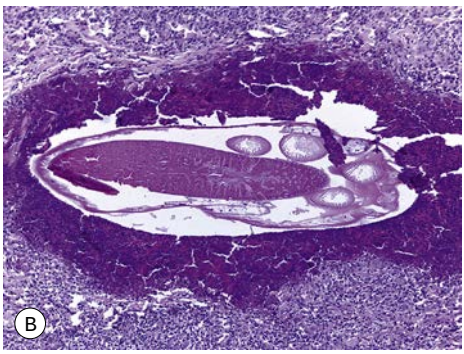


**eFig. 70.6 Gnathostomiasis. A** Note the diffuse erythema and induration resembling a panniculitis and the serpiginous pattern over the breast similar to larva migrans. **B** A skin biopsy specimen occasionally reveals the *Gnathostoma* third-stage larva. *Courtesy, Francisco G. Bravo.*



**eFig. 70.7 Onchocerciasis.** Extraction of adult worms from an onchocercal nodule on the buttocks. *Courtesy, Francisco G. Bravo.*

# 71 Infestations

## Scabies

- Infestation by *Sarcoptes scabiei* var. *hominis*, a mite that lives within the stratum corneum of human skin (Fig. 71.1).
- Transmission is primarily by direct contact with an infested person and occasionally by fomites (e.g. clothing); incubation period may be up to 6 weeks; in some tropical regions, scabies can infest the majority of individuals in a community.
- Asymptomatic infestation by scabies is not uncommon ("carriers" of scabies).
- In symptomatic cases, pruritus is severe, often worse at night or after a hot shower; secondary bacterial infections (e.g. staphylococcal, streptococcal) may occur. Poststreptococcal glomerulonephritis can be a significant issue in countries with endemic scabies and poor resources.
- Skin lesions are variable and include erythematous papules with scale-crust, small patches of eczema, excoriations, vesicles (especially acrally in infants), and nodules; the classic burrow – a thread-like, grayish-white, wavy, 1- to 10-mm linear structure – favors acral sites (Figs 71.2–71.4).
- Clinical confirmation is by mineral oil examination of skin scrapings (see Ch. 2) or dermoscopy (see Fig. 71.3).
- Usually <100 mites, but often no more than 10–15, living on an infested individual (Fig. 71.5); there may be thousands of mites in crusted scabies (thick scale, especially acrally, with minimal inflammation), which affects immunocompromised hosts, those with altered skin sensation, and sometimes the elderly (Fig. 71.6).
- In general, the mites live off the body ≤3 days; if accompanied by sloughed skin, as in crusted scabies, the duration may be longer.
- **DDx:** arthropod bites, including bites of animal mites (e.g. *Cheyletiella*); diseases associated with generalized pruritus (e.g. atopic dermatitis; see Table 4.1); in infants, infantile acropustulosis (may also occur following successful treatment of scabies), incontinentia pigmenti.
- **Rx:** see Table 71.1:
  - Two overnight applications of a topical antiscabetic medication, 1 week apart, to the entire body surface from the neck down to the toes; in infants, the elderly, and the immunocompromised, need to include the face and scalp
  - Permethrin 5% cream is the preferred topical agent
  - Oral ivermectin (200–400 mcg/kg given on days 1 and 8) is increasingly replacing topical medications, especially when large groups of individuals are affected as in a nursing home
  - All clothing and bedding should be washed in hot water and dried with high heat, or stored in a bag for 10 days (3 days after the second treatment)
  - All family members and close contacts should be treated simultaneously, even if asymptomatic

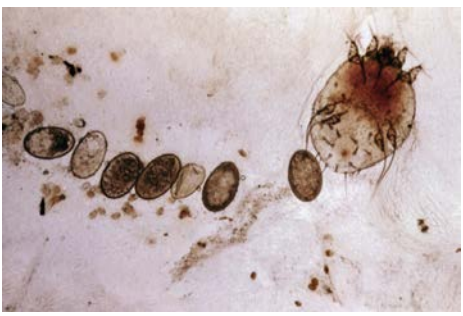

**Fig. 71.1 Female scabies mite with eggs and scybala in skin scrapings.** Note the mite's flattened, oval body and eight legs. *Courtesy, YDRSC.*




**Fig. 71.2 Scabies. A, B** Erythematous papules, linear burrows, areas of crusting and acral vesiculopustules in two infants with scabies. **C** Close-up of a linear burrow. **D, E** Penile involvement with erythematous papules and nodules. **F** Nodular scabies in an infant. *A, B, Courtesy, Julie V. Schaffer, MD; C, Courtesy, USCDRSC; D, Courtesy, YDRSC; E, Courtesy, Robert Hartman, MD; F, Courtesy, Kalman Watsky, MD.*




**Fig. 71.3 Scabietic burrows and microscopy of a skin scraping from a patient with scabies.** **A** Classic scabietic burrows – wavy, white, thread-like linear structures 1–10 mm in length. Burrows are highest yield in terms of isolating mites via skin scraping. **B** Dermoscopy can aid in identifying mites. By dermoscopy, a characteristic "jet with contrail" structure can be identified corresponding to the anterior part of the mite (arrow) and the burrow behind it. **C** Four mites, eggs, and scybala are present. The mites blend in with the background scale, making them difficult to see. *A, C, Courtesy, YDRSC; B, Courtesy, Iris Zalaudek, MD.*

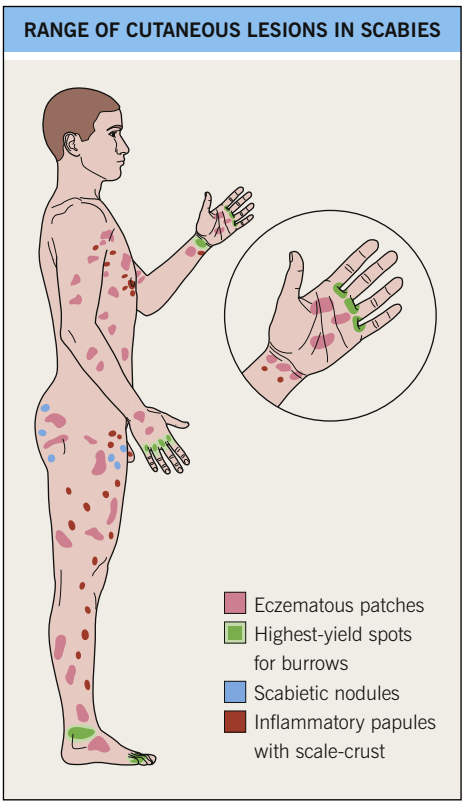


**Fig. 71.4 Range of cutaneous lesions in scabies.** Typical sites affected by scabies are highlighted. In infants and the elderly or immunocompromised, all surfaces can be involved, including the scalp and face.

- Pruritus and cutaneous lesions often last 2–4 weeks after successful treatment, but patients may feel relief within 3 days
- Once the diagnosis is established and initial treatment has been administered, topical corticosteroids (mild to moderate strength) can be used for symptomatic relief
- In crusted scabies, additional measures are necessary (e.g. combined and/or repeated treatments, cutting of nails, longer storage of clothing, vacuuming upholstery)

## Head Lice (Pediculosis Capitis)

• Secondary to *Pediculus capitis*, a blood-sucking, six-legged insect that lays its eggs near the base of the hairs on the scalp (Fig. 71.7); the casing remains after the egg


A L G r a w a n y

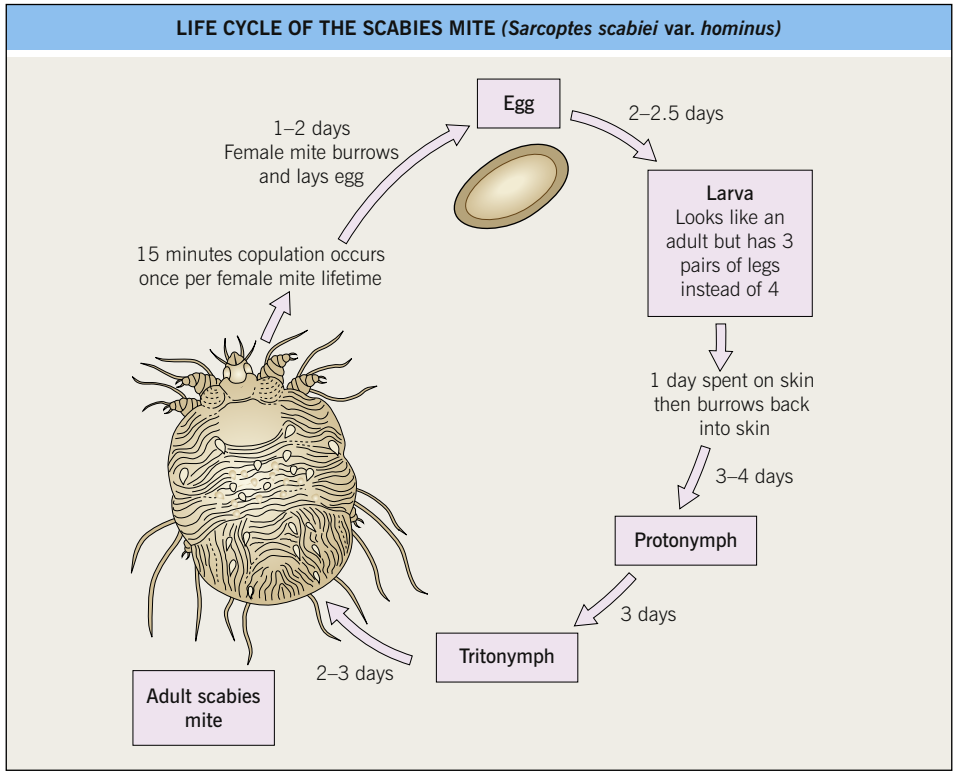


**Fig. 71.5 Life cycle of the scabies mite (*Sarcoptes scabiei* var. *hominus*).**



**Fig. 71.6 Crusted scabies.** Asymptomatic hyperkeratosis of the hands, which may be misdiagnosed as hand dermatitis. This disorder was previously referred to as Norwegian scabies. *Courtesy, Joyce Rico, MD.*

hatches and migrates outward with growth of the hair shaft.

- Transmission is by direct contact with an infested person or fomites (e.g. hats, brushes).
- Pruritus is variable.
- In addition to the presence of lice and eggs, there may be erythema, scaling, and excoriations of the head and neck region; occasionally there is a secondary pyoderma.
- Diagnosis is generally made by visual examination, followed by microscopic inspection and the detection of 0.8 mm eggs or their casings attached to scalp hairs ("nits"); high-yield locations include hairs above the ears and the lower occipital scalp (Fig. 71.8).
- **DDx** of scalp pruritus: seborrheic dermatitis, psoriasis, atopic dermatitis.
- **DDx** of nits: hair casts, dandruff, hair gel, and other causes of hair shaft nodules (see Fig. 64.3).
- **Rx:** outlined in Table 71.2. Most schools have a no-nit policy which requires mechanical removal of nits.

## Crab Lice (Pediculosis Pubis)

- Secondary to *Phthirus pubis*, a bloodsucking, six-legged insect that lives on the terminal hairs of the pubic region, beard, eyelashes, axillae, and perianal region.

| TOPICAL AND ORAL TREATMENTS FOR SCABIES | | | | | |
|---|---|---|---|---|---|
| **Treatment** | **Administration on days 1 and 8** | **Concerns** | **Efficacy and resistance** | **Use in infants** | **FDA pregnancy category** |
| Permethrin cream (5%) | Topically overnight | Allergic contact dermatitis in individuals with sensitivity to formaldehyde | Good, but some signs of resistance developing | FDA approved for infants ≥2 months of age | B |
| Ivermectin (available as 3 mg tablets) | Oral dose of 200–400 mcg/kg | Potential CNS toxicity in infants and young children | Excellent | Safety not established for children weighing <33 pounds (15 kg) or breastfeeding mothers | C (but generally not recommended for scabies in pregnant women) |

**Table 71.1 Topical and oral treatments for scabies.** All treatments should be given on two separate occasions, 1 week apart. Other topical therapies are sometimes utilized, based on availability, but suffer from inferior efficacy and toxicities, e.g. lindane (CNS toxicity), sulfur 5–10%, and crotamiton.



**Fig. 71.7 Head louse family.** From left to right: female, male, and nymph. *With permission from Taplin D, Meinking TL. Infestations. In: Schachner LA, Hansen RC (Eds.), Pediatric Dermatology, 4th edn. Edinburgh, UK: Mosby, 2011:1141–1180.*

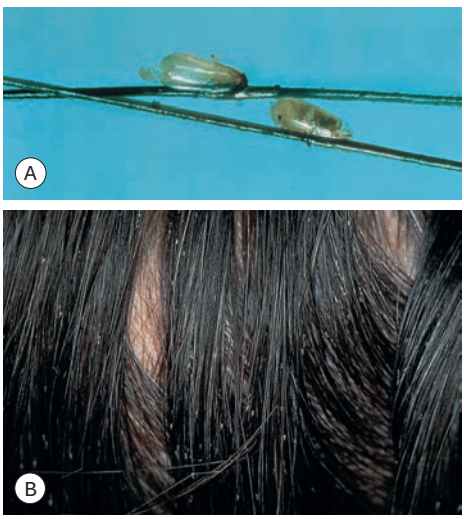


**Fig. 71.8 Head lice. A** The head louse egg or nit is 0.8 mm in length. **B** Head lice nits on hair. *With permission from Taplin D, Meinking TL. Infestations. In: Schachner LA, Hansen RC (Eds.), Pediatric Dermatology, 4th edn. Edinburgh, UK: Mosby, 2011:1141–1180.*

- While body and head lice are similar in appearance, crab lice are shorter and broader, thus actually resembling crabs (Fig. 71.9).
- Transmission is by direct contact (may be sexual) or occasionally via contaminated clothing, towels, or bedding.
- May coexist with other STIs; pruritus is common.
- In addition to lice that are attached to hairs or moving about the surface of the skin (Fig. 71.10A), hemorrhagic crusts, perifollicular erythema, and macula caerulea (asymptomatic slate-gray to blue macules on the trunk and thighs) may be seen; secondary bacterial infection may also occur.

| TOPICAL AND ORAL TREATMENTS FOR HEAD LICE | | | |
|---|---|---|---|
| **Treatment** | **Administration on days 1 and 8** | **Concerns** | **Efficacy and resistance** |
| Permethrin cream rinse or lotion (1%)* | Topical application for 10 minutes to clean, dry hair | None | Poor–fair; resistance common |
| Pyrethrins (0.33%) synergized with piperonyl butoxide (4%), various formulations* | Topical application for 10 minutes to dry hair | Allergic reactions in individuals with sensitivity to chrysanthemums, ragweed, and related plants | Poor–fair; resistance common |
| Ivermectin lotion (0.5%)^ | Topical application for 10 minutes to dry hair | Ocular irritation | Good; no resistance noted to date |
| Benzyl alcohol lotion (5%)^ | Topical application for 10 minutes to dry hair | Potential skin irritation | Fair–good; no resistance noted to date |
| Spinosad cream rinse (0.9%)^ | Topical application for 10 minutes to dry hair | None | Good; no resistance noted to date |
| Malathion lotion or gel (0.5%)** | Topical application for 8–12 hours to dry hair (Ovide® and gel products with isopropyl alcohol base are effective at 20 minutes) | Flammable isopropyl alcohol base; burning or stinging at sites of eroded skin | Excellent (in United States); resistance noted in United Kingdom and France, but to date not in United States |
| Ivermectin (available as 3 mg tablets) | Oral dose of 200–400 mcg/kg | Potential CNS toxicity; not recommended for children weighing <33 pounds (15 kg), breastfeeding mothers, or pregnant women (category C) | Excellent; no resistance noted to date |

*Over-the-counter products.
**Approved for individuals ≥6 years of age; pregnancy category B.
^Approved for individuals ≥6 months of age; pregnancy category B.

**Table 71.2 Topical and oral treatments for head lice.** In general, treatments should be given on two separate occasions, 1 week apart, with the exception of a single application for ivermectin lotion or abametapir 0.74% lotion, an ovicidal metalloproteinase inhibitor. Carbaryl shampoo (0.5%), lindane shampoo (1%), and permethrin cream (5%) are sometimes used, but generally have inferior efficacy. Dimethicone (4%) is a silicone oil that can be applied for 15 minutes or overnight. AirAllé® is an FDA-cleared medical device that uses hot air to treat head lice via dehydration of their eggs, and, to a lesser degree, hatched lice.

- If the infestation involves the eyelashes, feces can accumulate at the base of the hairs and at the inferior margin of the lower eyelid (Fig. 71.10B).
- **DDx:** other causes of genital pruritus; nits must be distinguished from other causes of hair nodules (see Fig. 64.3).
- **Rx:** see Table 71.3.

## Body Lice (Pediculosis Corporis)

- Secondary to infestation of clothing and humans by *Pediculus humanus* var. *corporis*, a bloodsucking six-legged insect.
- Associated with overcrowding, poor hygiene, poverty, wars, and natural disasters.



**Fig. 71.9 Adult crab louse.** The shape is shorter and broader than that of head and body lice. *Courtesy, Tony Burns, MD.*

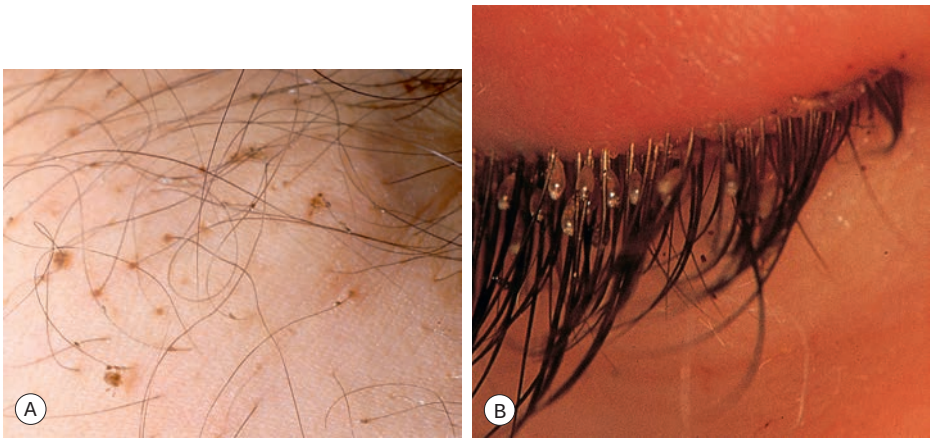


**Fig. 71.10 Crab lice. A** Both adult crab lice and nits are evident on pubic hairs. **B** Crab lice nits and feces on the eyelashes. *A, Courtesy, Louis A. Fragola, Jr., MD; B, With permission from Taplin D, Meinking TL. Infestations. In: Schachner LA, Hansen RC (Eds.), Pediatric Dermatology, 4th edn. Edinburgh, UK: Mosby, 2011:1141–1180.*

| TOPICAL AND ORAL TREATMENTS FOR CRAB LICE | | |
|---|---|---|
| **Treatment** | **Administration on days 1 and 8** | **Efficacy** |
| Permethrin (1%) cream rinse or synergized pyrethrin shampoo* | Topical application for 10 minutes to clean, dry hair | Fair |
| Permethrin cream (5%) | Topical application for 8–12 hours | Good |
| Ivermectin (available as 3 mg tablets) | Oral dose of 250 mcg/kg | Excellent |

**Over-the-counter products.*

**Table 71.3 Topical and oral treatments for crab lice.** All crab lice treatments should be given on two separate occasions, 1 week apart. Lindane shampoo (1%) is occasionally used but has inferior efficacy.

- Body lice can transmit epidemic typhus (*Rickettsia prowazekii*), trench fever (*Bartonella quintana*), and relapsing fever (*Borrelia recurrentis*).
- Severe pruritus common, especially on the back, waist, shoulders, and neck.
- Body lice and nits are primarily found in clothing seams (Fig. 71.11).

- **DDx:** bites from other arthropods and other causes of generalized pruritus (e.g. amphetamine use; see Tables 4.1 and 4.2); systemic diseases associated with pruritus (e.g. hepatic or renal impairment).
- **Rx:** incinerate clothing and bedding if possible; otherwise wash and dry with high heat; in epidemics, mass delousing with dusting powders (e.g. DDT).



**Fig. 71.11 Body lice eggs in the seams of clothing.** *Courtesy, YDRSC.*

## Tungiasis

- Secondary to the burrowing flea, *Tunga penetrans*.
- Endemic in Central and South America, Caribbean Islands, Africa, Pakistan, and India.
- Pregnant female flea burrows into the skin, especially on the feet of individuals who do not wear shoes or wear only flip-flops (Fig. 71.12).



**Fig. 71.12 Tungiasis in a child.** *Courtesy, Terri L. Meinking, MD, Craig N. Burkhart, MD, and Craig G. Burkhart, MD.*

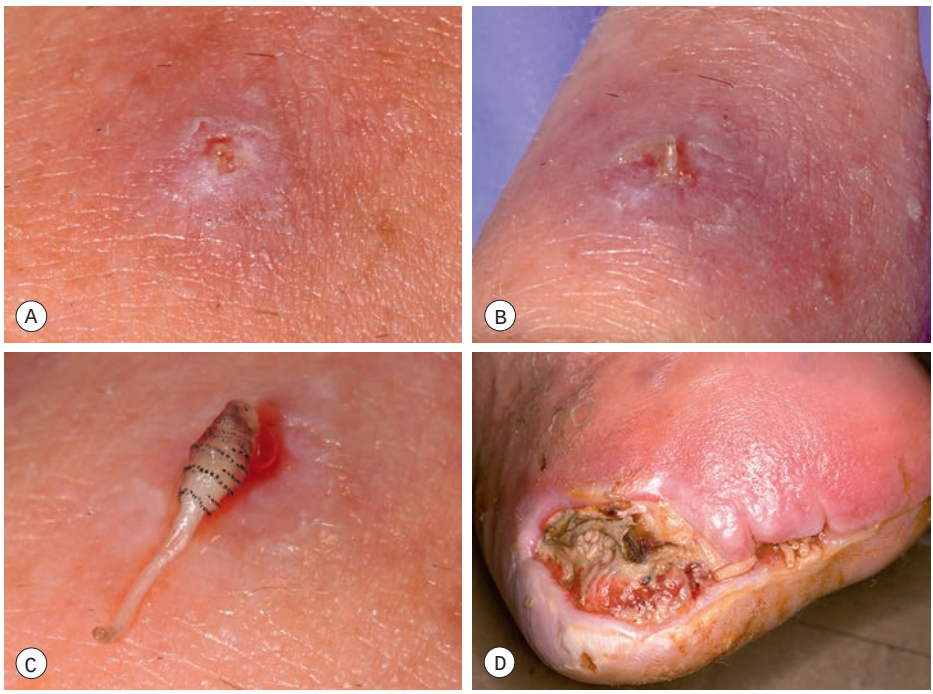


**Fig. 71.13 Cutaneous myiasis.** Furuncular myiasis presenting as a papulonodule with a central punctum (**A**) through which the larva's posterior end, which contains respiratory spiracles, may protrude (**B**). Note the characteristic appearance of the extracted botfly larva, with parallel rows of dark spines and hooks (**C**). **D** Wound myiasis in an amputation stump. *A–C, Courtesy, Edward W. Cowen, MD, MHSc; D, Courtesy, Louis A. Fragola, Jr., MD.*

- First sign is a small black dot that becomes a whitish papule and then a 1- or 2-cm nodule with surrounding erythema; there may be multiple lesions.
- Rarely, tetanus, gangrene, or autoamputation may result.
- **DDx:** myiasis, persistent arthropod bite reaction, cercarial dermatitis, pyoderma, wart, squamous cell carcinoma.
- **Rx:** removal of the flea; tetanus prophylaxis should be considered.
- Prevention: wear shoes and avoid sitting on sandy beaches in endemic areas.

## Cutaneous Myiasis

- Infestation of skin by fly larvae; furuncular myiasis presents as a boil-like lesion, most commonly secondary to *Dermatobia hominis* (human botfly) and *Cordylobia anthropophaga* (tumbu fly); wound myiasis is most often due to *Cochliomyia hominivorax* or *Chrysomya bezziana* (Fig. 71.13).
- Complications may occur, especially when the sinuses, nasal cavity, or scalp are involved.
- **DDx** for furuncular myiasis: ruptured cyst, abscess, furunculosis, and foreign body reaction.
- **Rx:** excision or removal of larvae for furuncular myiasis; debridement and irrigation for wound myiasis; consider oral ivermectin if oral/ocular involvement. As myiasis can be a portal of entry for *Clostridium tetani*, vaccination of affected individuals should be considered.
- Prevention: insect repellent, including on the scalp; ironing all line-dried items will kill eggs of the tumbu fly.

For further information see Ch. 84 from *Dermatology, Fourth Edition*.

**For additional online figures visit www.expertconsult.com**

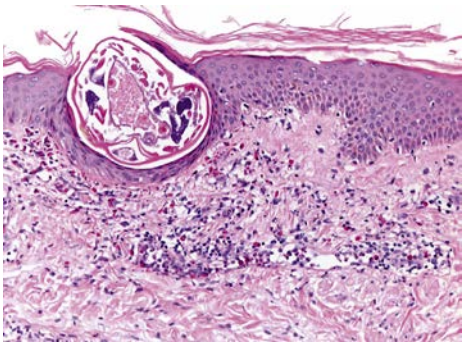

**eFig. 71.1 Scabies – histologic features.**
A mite is evident in the stratum corneum and an eosinophil-rich dermal infiltrate is present.
*Courtesy, Lorenzo Cerroni, MD.*

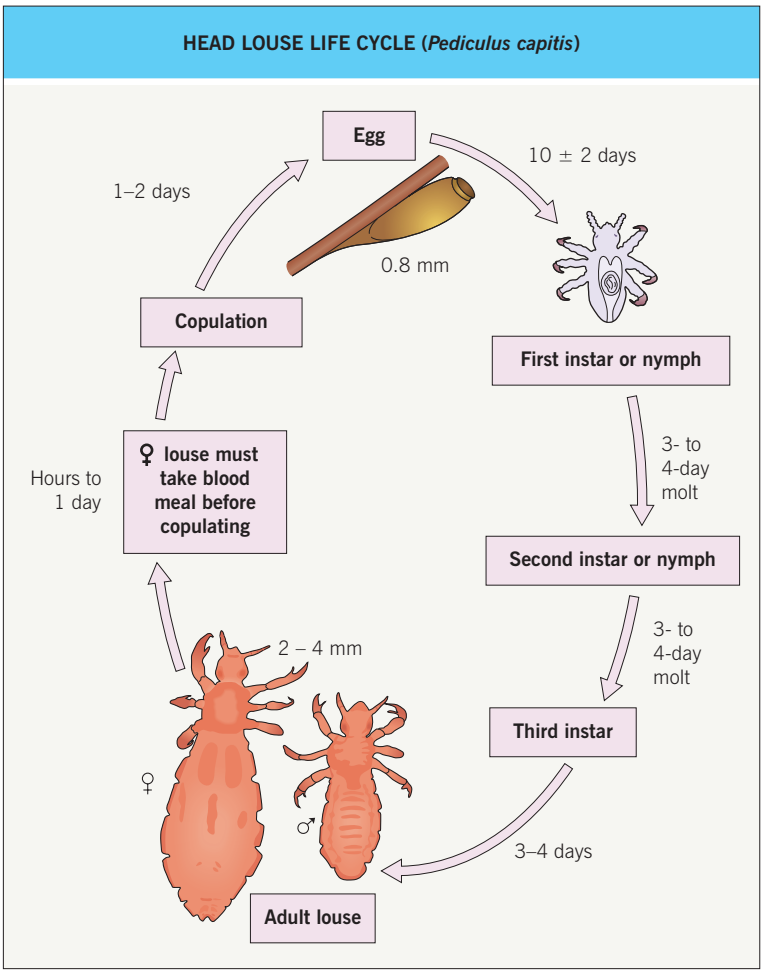


**eFig. 71.2 Head louse life cycle (*Pediculus capitis*).**

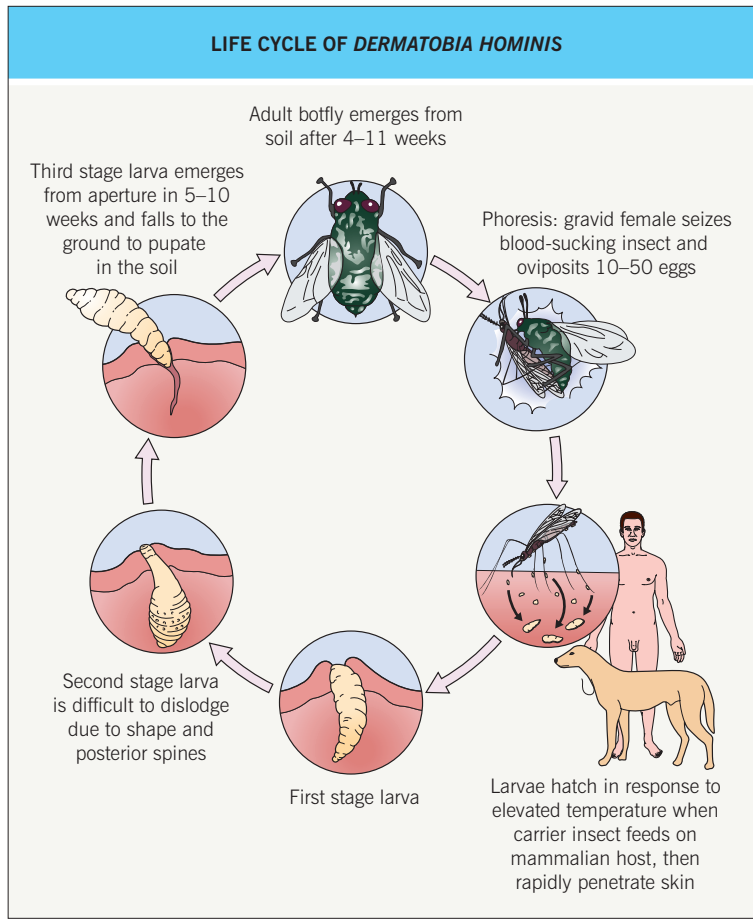


**eFig. 71.3 Life cycle of *Dermatobia hominis* in cutaneous myiasis.**

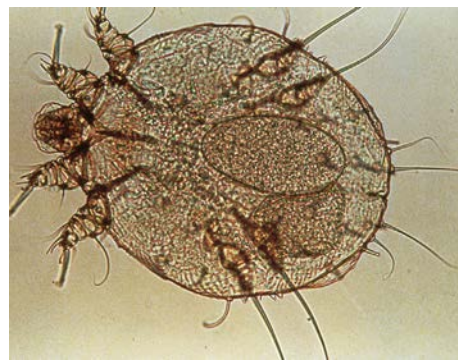

**eFig. 71.4 Female scabies mite with egg.** The female scabies mite in a potassium hydroxide wet mount obtained from skin scrapings, revealing a flattened, oval body with wrinkle-like corrugations, eight short legs, and an egg ready for deposition (40×). *With permission from Taplin D, Meinking TL. Infestations. In: Schachner LA, Hansen RC (Eds.), Pediatric Dermatology, 4th edn. Edinburgh, UK: Mosby, 2011:1141–1180.*




**eFig. 71.5 Scabies. A, B** Erythematous papules, linear burrows, areas of crusting and acral vesiculopustules in two infants with scabies. *A, Courtesy, YDRSC; B, Courtesy, USCDRSC.*




**eFig. 71.6 Cutaneous myiasis.** Botfly larva. *Courtesy, NYUDSC.*

# 72 Bites and Stings

## Insects

- The bite of any insect can lead to a local cutaneous reaction whose intensity can vary depending on the individual's level of sensitivity; the typical presentation is a 2- to 8-mm, erythematous urticarial papule in an exposed area (Fig. 72.1); lesions are often multiple and can be grouped (Fig. 72.2).
- Secondary changes consisting of excoriations may be present; less often, vesicles or bullae develop at the site of bites (Fig. 72.3).
- Bite reactions typically resolve over 5–10 days; occasionally, patients develop persistent bite reactions that on biopsy may be diagnosed as pseudolymphoma (see Ch. 99).
- Postinflammatory hyperpigmentation is common, especially in patients with darkly pigmented skin.
- Secondary infection is a potential complication, most commonly from staphylococci or streptococci.
- Exaggerated bite reactions can be seen in patients with chronic lymphocytic leukemia; rarely, hypersensitivity reactions to mosquito bites that become necrotic can be associated with EBV infection (see Ch. 67).
- Anaphylaxis with urticaria and angioedema is generally due to stings from hymenopterids (bees, wasps, hornets, and fire ants) (Fig. 72.4).
- Insects may be vectors of infectious diseases (Table 72.1).
- Bites can trigger papular urticaria, especially in children, in which edematous papules are more widespread and longer-lasting; some of the lesions can represent reactivation.
- Prevention: insect repellents (e.g. DEET), mosquito netting, and protective or permethrin-treated clothing; Table 72.2.
- **Rx:** anti-pruritic topical agents (e.g. pramoxine, calamine), topical CS ± occlusion; for persistent lesions, intralesional CS (e.g. triamcinolone 5 mg/ml).



**Fig. 72.1 Mosquito bite reactions.** This patient has excoriated edematous papules and papulovesicles. When both insect repellent and sunscreen are used, the latter should be applied first. *Courtesy, Julie V. Schaffer, MD.*

## Arachnids

### Hard Ticks

- Site of the tick bite can become papular, nodular, bullous, or plaque-like; expanding lesion suggests possible erythema migrans.
- Attached ticks may go unnoticed (e.g. scalp, groin); occasionally the attached tick is misinterpreted as a "new mole."
- Ticks are important disease vectors, especially in the nymphal stage (Table 72.3; see Fig. 63.1); tick control measures are important for public health (see Fig. 63.8 for geographic distribution of vector tick species).
- Removal of ticks should be performed carefully by grasping the protruding end of the tick as close to the skin surface as possible and firmly pulling away from the attachment site with fine-tipped tweezers.




**Fig. 72.2 Insect bite reactions.** Linear, pruritic papules with central crusts demonstrating the "breakfast, lunch, and dinner" sign (**A**) that is characteristic of, but not specific to, bedbug bite reactions. Bedbug bite reactions are typically pink, edematous papules in linear to arcuate arrays with central punctum or excoriation (**B, C**). Residual hyperpigmentation following bug bite reactions is common in individuals with darker skin types and can persist for months. *A, Courtesy, Antonio Torrelo, MD; B, Courtesy, Kalman Watsky, MD; C, Courtesy, Julie V. Schaffer, MD.*




**Fig. 72.3 Spectrum of insect bite reactions.** Sometimes patients develop large, erythematous, edematous plaques **(A)**, frank bullae **(B),** or purpuric lesions that may be mistaken for leukocytoclastic vasculitis (**C**). *A, B, Courtesy, Julie V. Schaffer, MD; C, Courtesy Jean L. Bolognia, MD.*



**Fig. 72.4 Fire ant bites presenting as clusters of sterile pustules on the foot.** *Courtesy, Dirk M. Elston, MD.*

- Prevention: permethrin repellent can be sprayed on clothing or other fabrics; protective clothing.
- **Rx** of persistent tick bite reactions: potent topical CS, intralesional CS, or even excision in severe cases; doxycycline is recommended in suspected cases of Rocky Mountain spotted fever (10-day course; see Ch. 63) or Lyme disease (14- to 21-day course).

### Mites

- Thousands of species; parasitize humans as well as animals and plants.
- Human mites include *Demodex folliculorum* and *D. brevis* (may lead to folliculitis and exacerbate rosacea) and *Sarcoptes scabiei*, which causes scabies (see Ch. 71); these mites complete their life cycle on humans.
- *Cheyletiella* mites ("walking dandruff") are found on small mammals (e.g. cats, dogs) and may cause papulovesicular lesions in humans (Fig. 72.5); similar lesions can be seen in individuals exposed to avian mites.
- Chigger mites in Asia are vectors for scrub typhus; in other regions they lead to multiple bite reactions that tend to favor the buttocks and anogenital region.
- House mouse mites are vectors for rickettsialpox.

### Spiders

- Black widow spider (*Latrodectus mactans* is the primary species in the United States):
  - Bites lead to acute pain and edema
  - Systemic symptoms may include an acute abdomen or rhabdomyolysis
  - **Rx:** if severe reaction, emergency medical treatment
- Brown recluse spider (*Loxosceles reclusa* is the predominant species in the United States) (Fig. 72.6):
  - Bites can cause dermonecrosis (sphingomyelinase D is the major toxin) which begins with erythema and/or vesiculation that becomes dusky, sometimes with bullae formation and eventual necrosis (Fig. 72.7)
  - Rarely, systemic findings of shock, hemolysis, renal insufficiency, and disseminated intravascular coagulation
  - **Rx:** rest, ice, and elevation are the mainstays of treatment

## Dog and Cat Bites

- Infection of bite sites is common, especially with streptococci, staphylococci, *Pasteurella multocida*, *Capnocytophaga canimorsus*, and anaerobes (e.g. *Fusobacterium*).
- **Rx:** broad-spectrum antibiotics (e.g. amoxicillin–clavulanate) to cover the above organisms; depending on clinical setting, consider rabies vaccine/immunoglobulin and tetanus booster.

## Marine Stings/Injuries

- Vary from dermatitis (secondary to contact with sea anemone, coral, or sponges) to foreign body reactions (e.g. to embedded sea urchin spines) to acute reactions (e.g. erythematous, urticarial or hemorrhagic streaks secondary to jellyfish stings; Fig. 72.8).
- Complications include secondary bacterial infection (e.g. *Staphylococcus aureus*);



**Fig. 72.5 *Cheyletiella* bites.** These mites are non-burrowing and are found on cats, rabbits, and dogs. *Courtesy, Dirk M. Elston, MD.*

**DISTRIBUTION IN THE US OF SPIDERS THAT MAY CAUSE DERMONECROTIC REACTIONS**



**Brown recluse spider**
(*Loxosceles reclusa*)

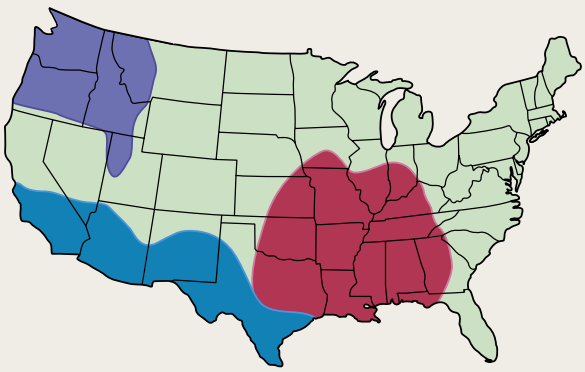

*Tegenaria agrestis* (hobo)

*Loxosceles reclusa* (brown recluse)

Other *Loxosceles spp.*

**Fig. 72.6 Distribution in the United States of spiders that may cause dermonecrotic reactions.** *Adapted from Sams HH, Dunnick CA, Smith ML, et al. Necrotic arachnidism. J Am Acad Dermatol 2001;44:561–73.*



**Fig. 72.7 Dermonecrotic spider bite reaction.** Note the central dusky necrosis. The patient was initially misdiagnosed with cellulitis and hospitalized after failure to respond to oral antibiotic therapy. *Courtesy, YDRSC.*

| MAJOR INSECTS OF DERMATOLOGIC SIGNIFICANCE | | | |
|---|---|---|---|
| **Insect, size of an adult (length)** | **Example(s)** | **Lesional clues** | **Vector of:** |
| Bedbugs, ~5–8 mm  | *Cimex lectularius,* species most commonly found in the United States | • Lesions noted upon awakening<br>• Bites often in groups of 2 or 3 | |
| Triatome reduviids, ~1–3 cm  | *Triatoma dimidiata*, *Rhodnius prolixus* | • Painless bites with delayed erythema, edema, and pruritus<br>• Unilateral eyelid swelling (Romaña sign), a conjunctival reaction to infected feces | American trypanosomiasis (bugs defecate as they eat and infectious feces are rubbed into the wound) |
| Fleas*, ~2–10 mm  | • *Pulex irritans* (human flea; shown here)<br>• *Ctenocephalides felis* (often found on dogs)<br>• *Xenopsylla cheopsis* (oriental rat flea) | • Lesions often limited to lower extremities as fleas jump but cannot fly<br>• Wider distribution if an infested pet is held, groomed, or shares bed | • Endemic (murine) typhus, primarily oriental rat flea<br>• Flea-borne spotted fever and plague, primarily oriental rat flea |
| Fire ants, 2–6 mm | *Solenopsis invicta* | Clusters of sterile pustules (Fig. 72.4), sometimes in rosettes | |
| Blister beetles, ~1–2.5 cm | *Epicauta occidentalis* | Vesicles/bullae result from secreted cantharidin | |

*See Chapter 71 for information on Tunga penetrans, a burrowing flea.

**Table 72.1 Major insects of dermatologic significance.** *Photographs: inset 1, courtesy, YDRSC; insets 2, 3, courtesy, Dirk M. Elston, MD.*

| TREATMENT AND PREVENTION OF MAJOR INSECTS OF DERMATOLOGIC SIGNIFICANCE | |
|---|---|
| Bedbugs | • Extermination |
| Triatome reduviids | • Elimination of hiding spots/ breeding grounds (e.g. cracked stone walls)<br>• Extermination |
| Fleas | • Treat infested animals (e.g. fipronil, methoprene)<br>• Treat house with insecticide |
| Fire ants | • Eradication of fire ant mounds |

**Table 72.2 Treatment and prevention of major insects of dermatologic significance.**

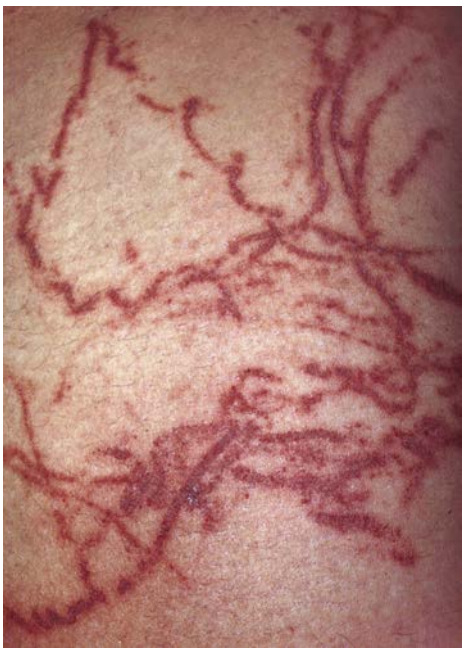

**Fig. 72.8 Jellyfish sting.** Painful red papules and papulovesicles in multiple linear streaks. *Courtesy, Joyce Rico, MD.*



**Fig. 72.9 Seabather's eruption.** Edematous pink papules in the same distribution as the bathing trunks. *Courtesy, Kalman Watsky, MD.*

*Vibrio vulnificus* infections with hemorrhagic bullae more common in patients with liver disease.

- **Rx:** for acute marine envenomations – soaking in hot water to denature venom proteins; for symptoms of delayed reactions or dermatitis – topical CS; for foreign body reactions – removal of foreign material.
- Seabather's eruption:
  - Pruritic papules, localized to the bathing suit area and intertriginous areas (Fig. 72.9)
  - Secondary to a variety of stinging larvae, e.g. *Linuche unguiculata* (jellyfish), *Edwardsiella lineata* (sea anemone)

For further information see Ch. 85 from *Dermatology, Fourth Edition*.

**For additional online figures and tables visit www.expertconsult.com**

| MAJOR TICKS OF DERMATOLOGIC SIGNIFICANCE | | |
|---|---|---|
| **Tick** | **Example/distribution** | **Vector of:** |
| *Ixodes*<br> | • *Ixodes scapularis* (black-legged tick; shown here), United States: eastern and mid-Atlantic states, Great Lakes region<br>• *Ixodes pacificus* (western black-legged tick), western United States<br>• *Ixodes ricinus*, Europe<br>• *Ixodes persulcatus*, Eurasia | • Lyme disease<br>• Babesiosis<br>• Human granulocytic anaplasmosis<br>• Other borrelial and rickettsial infections, e.g. Japanese spotted fever<br>• Powassan encephalitis |
| *Amblyomma*<br> | • *Amblyomma americanum* (lone star tick; shown here), United States: from Texas to Iowa and Connecticut<br>• *Amblyomma maculatum*, U.S. Gulf Coast | • Human monocytic ehrlichiosis<br>• *Ehrlichia ewingii* infection<br>• Southern tick-associated rash illness (STARI)<br>• Occasionally, rickettsial diseases are transmitted by *Amblyomma* species<br>• Tularemia |
| *Dermacentor*<br> | • *Dermacentor variabilis* (shown here), most of United States, except Rocky Mountain states<br>• *Dermacentor andersoni*, United States: Rocky Mountain states<br>• *Dermacentor reticulatus*, Europe | • Rocky Mountain spotted fever (United States)<br>• Colorado tick fever<br>• Tularemia<br>• Other rickettsial infections (especially Europe, Asia); also Pacific Coast tick fever (*Rickettsia philipii*, type strain "Rickettsia 364D")<br>• Ehrlichiosis<br>• Occasionally, human monocytic ehrlichiosis and Q fever |
| *Rhipicephalus* (brown dog tick)<br> | Southwestern United States and Mexico | • Boutonneuse fever<br>• Occasionally Rocky Mountain spotted fever |

**Table 72.3 Major ticks of dermatologic significance.** *Dermacentor* ticks primarily attach to the head and neck region; *Amblyomma* ticks prefer the lower legs and buttocks; *Ixodes* ticks may be found at any site, but the trunk is common. *Photographs, courtesy, Dirk M. Elston, MD.*



**eFig. 72.1 Bullous insect bite reactions.** The sterile blister fluid is serous and the ankle is a common site. *Courtesy, Luis Requena, MD.*



**eFig. 72.2 Insect bite reactions.** In this patient, there are papulovesicles as well as excoriated papules with hemorrhagic crusting. In more darkly pigmented individuals, residual hyperpigmentation is common and can persist for months. *Courtesy, Julie V. Schaffer, MD.*



**eFig. 72.3 Brown recluse spider bite with central dusky necrosis.** *Courtesy, YDRSC.*

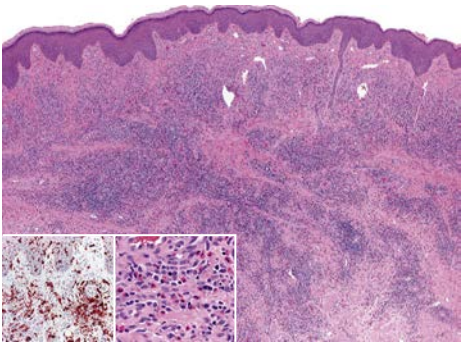

**eFig. 72.4 Insect bite reaction with Langerhans cell hyperplasia.** Note the dense superficial and deep lymphohistiocytic infiltrate with prominent eosinophils (right inset) and CD1a-positive, dendritic Langerhans cells (left inset). *Courtesy, Lorenzo Cerroni, MD.*



**eFig. 72.5 Characteristic train-track hemorrhage from exposure to *Megalopyge opercularis* (puss caterpillar).** *Courtesy, Dirk M. Elston, MD.*



**eFig. 72.6 Avian mite bites.** Multiple erythematous pruritic papules, several of which have hemorrhagic crusts. The exposure was birds nesting on the patient's house. *Courtesy, Jean L. Bolognia, MD.*

| COMMONLY USED INSECT REPELLENTS | |
|---|---|
| **Conventional repellents in EPA classification** | |
| DEET (N,N-diethyl-3-methylbenzamide)* | Effective against a wide range of arthropods |
| | Long history of use |
| Picaridin (KBR 3023) | Good evidence for mosquitoes |
| | Fewer studies support repellent effect against ticks |
| **Biopesticide and insecticide repellents in EPA classification** | |
| IR3535 (3-[N-butyl-N-acetyl]-amino propionic acid, ethyl ester) | Good evidence for mosquitoes in some, but not all, studies |
| | Fewer studies support repellent effect against ticks |
| p-Menthane-3,8-diol† | Good evidence for mosquitoes |
| | Fewer studies support repellent effect against ticks |
| Botanicals (e.g. soybean oil, citronella, neem oil, fennel oil, geraniol) | Have consumer appeal as "natural" repellents |
| | Best published evidence is for neem oil |
| | Lack of evidence does not necessarily equate to lack of efficacy, but available evidence to date suggests they are inferior to the synthetic repellents listed above |
| Permethrin | Best used when applied on clothing |

**There is a plateau of efficacy at 30% with long-acting products, and higher concentrations should generally be avoided. Because sunscreens require frequent reapplication and DEET does not, combination products with these ingredients are not recommended.*
*†The active ingredient of oil of lemon eucalyptus; use on children less than 3 years of age is not recommended.*

**eTable 72.1 Commonly used insect repellents.** Agents are listed in order of decreasing evidence of efficacy. Treatment of clothing and other fabrics with permethrin can also be helpful, especially to repel ticks and chiggers (see text). EPA, Environmental Protection Agency.

| CUTANEOUS AND SYSTEMIC REACTIONS ASSOCIATED WITH LEPIDOPTERISM | | | |
|---|---|---|---|
| **Moth/caterpillar common name** | **Scientific name** | **Locale** | **Clinical findings** |
| Gypsy moth caterpillar | *Lymantria dispar* | Northeastern US | "Dermatitis" from direct contact or from hairs on clothesline-dried clothing |
| Io moth caterpillar | *Automeris io* | US | Immediate stinging sensation, "dermatitis" (often transient urticarial papules) |
| Saddleback caterpillar | *Acharia stimulea* (formerly *Sibine stimulea*) | US | Immediate stinging sensation, "dermatitis" (often transient urticarial papules) |
| Buck moth caterpillar | *Hemileuca maia* | Eastern US | Immediate stinging sensation, "dermatitis" |
| Puss caterpillar | *Lagoa crispata* (also known as *Megalopyge crispata*) | Oklahoma and eastern US | Immediate burning sensation, "dermatitis"; in Oklahoma, spines contain high concentrations of tannins (ingested from oak trees) |
| Southern flannel caterpillar, puss caterpillar, wooly asp | *Megalopyge opercularis* | Southern US, Mexico and Central America | Immediate intense radiating pain; characteristic "railroad track" pattern of hemorrhage; edema, hives and systemic symptoms may occur |
| Saturniid moth caterpillar, giant silkworm moth | *Lonomia achelous, L. oblique* | Latin America | Local and severe systemic reactions, in particular with a bleeding diathesis (with complications such as renal failure) |
| Processionary caterpillars: pine, Cyprus and oak (characteristically travel single-file) | *Thaumetopoea pityocampa*, *T. wilkinsoni*, *T. processionea* | Mediterranean region, central Europe, Britain | Urticaria (often immunologic), angioedema, anaphylaxis, conjunctivitis, respiratory distress, abdominal pain, hypertension, lytic bone lesions in the digits; airborne urticating hairs are spread by the wind |
| Pine moth caterpillar and cocoon | *Dendrolimus punctatus* | China, imported elsewhere | "Dermatitis," arthritis (usually monoarticular), chondritis, ophthalmia nodosa |
| Tussock moth caterpillar | *Orgyia pseudotsugata* | Western US, especially Pacific Northwest | "Dermatitis," pruritus of the skin and eyes as well as respiratory symptoms (irritant and allergic mechanisms); forestry workers |
| Yellowtail moth (adult female) | *Hylesia metabus*, *H. alinda* | Mexico and South America (including *H. metabus* in the Venezuelan port of Caripito) | Papular urticaria (Caripito itch); ship crew members are classically affected |

**eTable 72.2 Cutaneous and systemic reactions associated with lepidopterism.** "Dermatitis" can include pruritic urticarial papules as well as eczematous reactions. Tape stripping of skin has been used to identify caterpillar hairs (setae). Caterpillars can have short spines projecting from a long slender shaft or short tapered shafts with ball-in-socket structures resembling trichorrhexis invaginata.

| TICK CONTROL MEASURES | |
|---|---|
| **Personal** | **Environmental** |
| Protective clothing tightly laced, snapped or tied | Removal of leaf debris |
| Clothing treated with permethrin | Area acaricide application |
| Clothing treated with repellents such as DEET | Exclusion of animal hosts |
| Regular tick inspections | Acaricide-treated feed corn |

**eTable 72.3 Tick control measures.**

| MITES OF MEDICAL IMPORTANCE | |
|---|---|
| *Acarus siro* | Grain mite: hay, grain, house dust |
| | **Baker's itch** |
| *Cheyletiella* spp. | **Walking dandruff on pets** |
| *Cheyletus malaccensis* | Wheat mite |
| | **Wheat warehouse itch** (Japan) |
| *Demodex* spp. | **Folliculitis; possibly rosacea, blepharitis; demodectic mange in dogs and cats** |
| *Dermanyssus gallinae, D. avium* | Fowl mite: chickens, wild birds, rodents, rabbits |
| *Dermatophagoides farinae, D. pteronyssinus* | Dust mite (**allergy**): dust, blankets, mattresses, pillows, pets, stored foods and grains |
| *Euroglyphus maynei* | Dust mite (**allergy, cross-reactions with other dust mites**) |
| *Glycyphagus domesticus* | Cheese mite, barn mite, grocer's mite: cheese, grains, hay, mattresses |
| | **Grocer's itch** |
| *Laelaps* spp., *Androlaelaps* spp., *Eulaelaps* spp. | Rodent mites |
| *Lepidoglyphus destructor* | Dust mite, hay mite |
| *Liponyssoides (Allodermanyssus) sanguineus* | House mouse mite |
| | **Rickettsialpox** |
| *Neotrombicula autumnalis* | Harvest mite (Northern Europe) |
| *Ophionyssus natricus* | Snake mite |
| *Ornithonyssus sylviarum, O. bacoti, O. bursa* | Tropical rat mite, fowl mite, tropical fowl mite, northern fowl mite: rodents, chickens, wild birds, carnivores |
| *Pyemotes ventricosus, P. tritici* | Straw itch mite, grain mite: parasites of insects in grains and straw |
| *Trombicula (Eutrombicula) alfreddugesi* | Chigger mite, red bug |
| *Trombicula (Leptotrombidium) akamushi, L. deliense, L. fletcheri, L. arenicola, L. pallidum, L. pavlovskyi, L. scutellare* | Scrub mite |
| | **Scrub typhus** |
| *Tyrophagus putrescentiae* | Mold mite, grain storage mite |
| | **Copra itch** |

**eTable 72.4 Mites of medical importance.** Scientific names, common names and associated diseases (in bold) are listed. With the exception of *Demodex* and dust mites, mite bites typically lead to pruritic papular eruptions in humans.

| PATHOGENS ASSOCIATED WITH HUMAN AND ANIMAL BITE WOUND INFECTIONS | |
|---|---|
| **Bite** | **Pathogens** |
| Human bites | *Staphylococcus aureus*<br>*Streptococcus pyogenes*<br>*Eikenella corrodens*<br>Various anaerobes† |
| Cat bites | *Pasteurella multocida* (75%)*<br>*Moraxella* spp.<br>*Neisseria weaveri*<br>*Bergeyella zoohelcum*<br>Various anaerobes† |
| Dog bites | *Pasteurella* spp. (*canis* > *multocida*) (50%)*<br>*S. aureus* (20%)<br>*Str. pyogenes*<br>*N. weaveri*<br>*Capnocytophaga canimorsus*<br>*B. zoohelcum*<br>Various anaerobes† |
| Rat bites (see Table 61.6) | *Streptobacillus moniliformis* |
| Horse and sheep bites | *Actinobacillus* spp.<br>*Pasteurella* spp.<br>Various anaerobes† |
| Marine animal bites | *Vibrio* spp.<br>*Aeromonas hydrophila*<br>*Pseudomonas* spp.<br>*Plesiomonas shigelloides* |

†*May include Fusobacterium, Bacteroides, Porphyromonas, and Prevotella spp.*
**Relatively short incubation period of 12–24 hours.*

**eTable 72.5 Pathogens associated with human and animal bite wound infections.** Most infections are polymicrobial and include aerobic and anaerobic bacteria (median of 4–5 isolates), which can originate from the skin of the patient as well as the oral flora of the biting animal or human.

# 73 Photodermatoses

## Photo Facts

- The UV radiation (UVR) emitted by the sun is arbitrarily subdivided based on wavelength into UVA (400–320 nm), UVB (320–290 nm), and UVC (290–200 nm).
- More than 95% of UVR that reaches the earth's surface is UVA.
- UVA, but not UVB, can penetrate through glass windows.
- The penetration of UVR into the skin is wavelength-dependent (Fig. 73.1).
- Principles and formulations of sunscreens are discussed in the Appendix.

## Cutaneous Effects of UVR Exposure: Acute

- The visible short-term effects of UVR include sunburn and tanning; in addition, it leads to vitamin D synthesis, epidermal hyperplasia, proinflammatory responses, and immunosuppression.
- **Sunburn** = inflammation + erythema; UVC (absorbed by ozone) > UVB > UVA in potential to cause sunburn.
- **MED** = "minimal erythema dose" = the lowest dose of UVR capable of inducing erythema (sunburn) in a given individual.

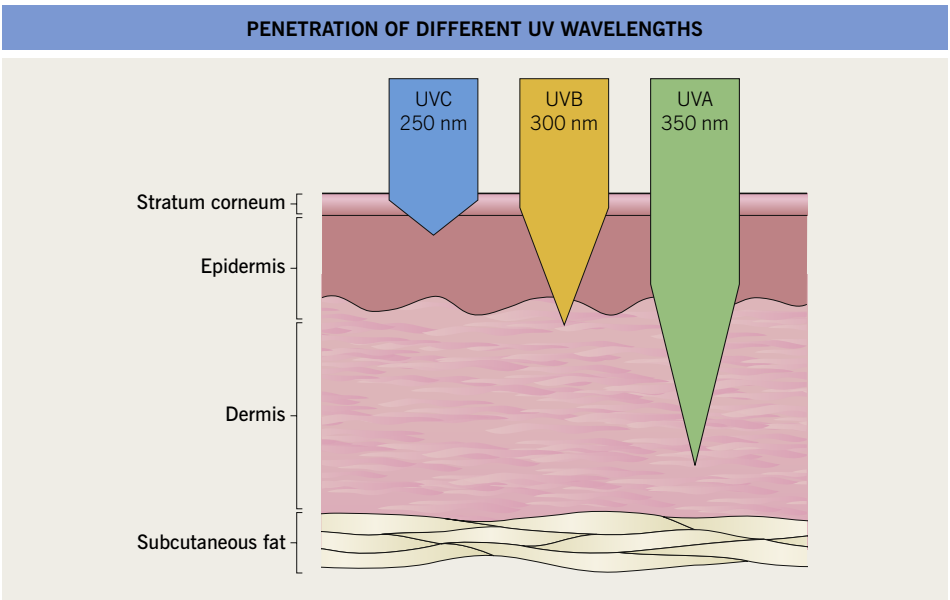


**Fig. 73.1 Depth of penetration of different wavelengths of UV light into human skin.** Depth of penetration varies greatly with the thickness of the different skin layers and their composition (e.g. melanin content). The beginning of the wedge-shaped portion of the penetration symbol represents a decrease to approximately one-third of the incident energy density, and the tip of the symbol represents a decrease to approximately 1%. Figure not drawn to scale.

- Typically, a UVB-induced sunburn appears within 30 minutes to 8 hours of sufficient exposure, peaks at 12–24 hours, and diminishes over hours to days with desquamation.
- **Tanning** occurs as a biphasic response to UVR and is wavelength-dependent.
  - **"Immediate pigment darkening"** occurs during and immediately after exposure and is most prominent with UVA
  - **"Delayed tanning"** usually results from UVB exposure and peaks about 3 days after sun exposure
- A "UVA-induced tan," such as from the use of tanning beds, provides 5–10 times less protection from subsequent UVR exposure than does a "UVB-induced tan," most likely because UVB also induces epidermal hyperplasia.

## Cutaneous Effects of UVR Exposure: Chronic

- The visible long-term effects of UVR include **photoaging** and **photocarcinogenesis.**
- Cutaneous signs of photoaging are pictured in Fig. 73.2 and also include solar lentigines, sunburn lentigines, and ephelides; in more darkly pigmented skin, small seborrheic keratoses, melasma, and dyspigmentation may be seen.




**Fig. 73.2 Cutaneous signs of significant photoaging. A, B** Solar elastosis of the cheek (**A**) and neck and V of the chest (**B**) with the characteristic yellow discoloration, thickening and furrowing of the skin. **C** Cutis rhomboidalis nuchae with deep furrowing of the posterior neck. **D** Poikiloderma of Civatte with sparing of the submental region and follicular skin. *Continued*




**Fig. 73.2** *Continued* **Cutaneous signs of significant photoaging. E** Multiple open comedones of the malar region in Favre–Racouchot syndrome. **F** Brown discoloration of the dorsal hand due to hemosiderin deposits from recurrent solar purpura. **G** Skin tear due to fragility of atrophic photodamaged skin (dermatoporosis) and pseudoscars from previous tears. **H** Erosive pustular dermatosis of the bald scalp. **I** Photoaging in a 93-year-old African-American woman, demonstrating fine wrinkling and numerous tiny seborrheic keratoses. **J** Sharp demarcation on the thigh of solar lentigines and the dyspigmentation of photodamaged skin. The patient consistently wore spandex shorts. *A, E, I Courtesy, Henry Lim, MD; B, Courtesy, Kalman Watsky, MD; C, Courtesy, YDRSC; D, F, G, J, Courtesy, Jean L. Bolognia, MD; H, Courtesy, Harvey Lui, MD.*

| CLASSIFICATION OF THE MORE COMMON PHOTODERMATOSES |
|---|
| **Idiopathic, probably immunologically mediated photodermatoses (Table 73.2)** |
| • Polymorphous light eruption (PMLE)<br>• Actinic prurigo<br>• Hydroa vacciniforme<br>• Chronic actinic dermatitis (CAD)<br>• Solar urticaria |
| **Photoaggravated dermatoses (Table 73.2)** |
| • Atopic dermatitis<br>• Seborrheic dermatitis > psoriasis<br>• Lupus erythematosus, dermatomyositis<br>• Rosacea<br>• Grover disease (transient acantholytic dermatosis)<br>• Other: erythema multiforme, bullous pemphigoid, pityriasis rubra pilaris, Darier disease, GVHD, disseminated actinic superficial porokeratosis (DSAP), lichenoid keratoses |
| **Chemical- and drug-induced photosensitivity (Table 73.3)** |
| **Inherited disorders characterized by defective DNA repair or chromosomal instability (Table 73.5)** |

**Table 73.1 Classification of the more common photodermatoses.** In some patients, clinicopathologic correlation (e.g. routine histopathology of a skin biopsy specimen), laboratory evaluation (e.g. ANA; anti-SSA/Ro, -SSB/La antibodies; plasma porphyrins, followed by complete porphyrin profile if positive [see Ch. 41]), and phototesting or photopatch testing (see Fig. 73.16) are required to make a diagnosis.



**Fig. 73.3 Photoaggravated atopic dermatitis induced by solar stimulator.** This was the appearance 24 hours after irradiation. *Courtesy, John L. M. Hawk, MD.*

• Chronic UVR is responsible for development of actinic keratoses, squamous cell carcinoma, basal cell carcinoma, and cutaneous melanoma (see Chs 88 and 93).

## Photodermatoses

• The photodermatoses are classified into four broad categories (Table 73.1) and are discussed in Table 73.2 (Figs 73.3–73.11), Table 73.3 (Figs 73.12–73.13), and Table 73.5 (Fig. 73.14).

• Clues to the diagnosis of various photodermatoses are outlined in Fig. 73.15.

• Of all the photodermatoses, polymorphous light eruption (PMLE) is the most common, followed by photoaggravated dermatoses; drug-induced photosensitivity is also a common disorder.

• *Phototoxicity* results from direct tissue and cellular injury following UVR-induced activation of a phototoxic agent; resembles a sunburn (Table 73.4).

• *Photoallergy* is a delayed-type hypersensitivity response that requires both a photoallergen (usually topical) and UVR exposure; resembles eczema (Table 73.4).

• Photosensitivity to some medications (e.g. methotrexate [see Fig. 73.13], 5-fluorouracil, retinoids) does not require UVR activation of the drug.

• It is important to recognize photodistributed versus photoprotected areas on the body; sparing of certain sites, including behind the ears, under the chin, the upper eyelids, and the nasolabial folds, is a clue to a photodistributed eruption (Fig. 73.17).

• Some patients may have no cutaneous findings at the time of the visit and the diagnosis is based on historical information, in particular those with PMLE and solar urticaria.




**Fig. 73.4 Polymorphous light eruption (PMLE) of the upper extremity. A** Small pink edematous papules that are coalescing into plaques on the forearm of an Asian patient. **B** Scattered discrete papulovesicles. **C** Larger and more pronounced edematous papules and plaques. *A, Courtesy, Henry W. Lim, MD and Cheryl F. Rosen, MD; B, Courtesy, NYUDSC; C, Courtesy, YDRSC.*




**Fig. 73.5 Polymorphous light eruption (PMLE) of the face. A** Larger erythematous patch on the nose as well as erythematous plaques on the malar eminence and chin. **B** Edematous erythematous plaques on the cheek in a young child. *A, Courtesy, Henry W. Lim, MD and Cheryl F. Rosen, MD; B, Courtesy, NYUDSC.*



**Fig. 73.6 Polymorphous light eruption (PMLE) of the thigh.** Edematous papules becoming confluent into plaques. *Courtesy, Jean L. Bolognia, MD.*

| CLINICAL FEATURES OF THE IDIOPATHIC, PROBABLY IMMUNOLOGICALLY MEDIATED PHOTODERMATOSES AND PHOTOAGGRAVATED DERMATOSES | | | |
|---|---|---|---|
| **Photodermatosis (action spectrum)** | **Clinical features** | **DDx** | **Rx** |
| **Polymorphous light eruption (PMLE)**<br>Figs 73.4–73.6<br>(UVB and UVA; rarely visible light) | • **Onset:** one to several hours after sun exposure; appears primarily in spring and early summer, but initial episode may follow intense sun exposure (e.g. trip to the tropics in the winter)<br>• **Duration:** lesions last days; tends to diminish or cease with repeated sun ("hardening" phenomenon)<br>• **Clinical:** lesions seen on sun-exposed skin (extensor forearms > dorsal hands > face and neck > other areas); typically, recurrences have a similar appearance in a given individual<br>• Symmetric, pruritic, skin-colored to red, various-sized papules and/or papulovesicles that often coalesce into larger plaques<br>• Confluent erythema or edema may be seen on the face<br>• "Juvenile spring eruption" is a clinical variant seen most often in boys, presenting as papulovesicles on the helices of the ears | • LE (lasts weeks to months)<br>• Solar urticaria (more rapid onset and resolution)<br>• Photoaggravated atopic or seborrheic dermatitis (eczematous)<br>• Erythema multiforme<br>• EPP (painful)<br>• Parvovirus infection<br>• In children also consider rare entities in Table 73.5 | **Mild:** photoprotection*, topical CS<br>**Severe**<br>• Short course of antimalarials (e.g. hydroxychloroquine 5–6.5 mg/kg/day [ideal body weight] for 4–8 weeks)<br>• "Hardening" via phototherapy (may lead to flare requiring oral CS) |
| **Actinic prurigo**<br>Fig. 73.7<br>(UVR: UVA + UVB) | • **Onset:** childhood; flares within hours of sun exposure<br>• **Duration:** lesions are chronic and persistent throughout childhood, but often fade in adolescence<br>• **Clinical:** seen most commonly in Native Americans; females > males<br>• Typically involves sun-exposed skin (e.g. face/nose, distal limbs), but with time can involve non-exposed skin<br>• Pruritic, erythematous papules and nodules with hemorrhagic crusts and lichenification<br>• Fine, linear or pitted scars may be seen on the face as lesions resolve<br>• Cheilitis, conjunctivitis | • Photoaggravated atopic dermatitis<br>• Photoallergic contact dermatitis<br>• PMLE (resolves more quickly)<br>• Scabies, arthropod bites<br>• Prurigo nodularis | **Mild:** photoprotection*, topical CS or CIs<br>**Moderate–severe**<br>• Antimalarials<br>• "Hardening" phototherapy as for PMLE<br>**Recalcitrant:** thalidomide, azathioprine, cyclosporine |

**Table 73.2 Clinical features of the idiopathic, probably immunologically mediated photodermatoses and photoaggravated dermatoses.** *Continued*

| CLINICAL FEATURES OF THE IDIOPATHIC, PROBABLY IMMUNOLOGICALLY MEDIATED PHOTODERMATOSES AND PHOTOAGGRAVATED DERMATOSES | | | |
|---|---|---|---|
| **Photodermatosis (action spectrum)** | **Clinical features** | **DDx** | **Rx** |
| **Hydroa vacciniforme (HV)**<br>Figs 73.8 and 73.9<br>(Primarily UVA) | • **Onset:** childhood; flares within hours of sun exposure<br>• **Duration:** active lesions last weeks; may resolve during adolescence or early adulthood<br>• **Clinical:** males > females<br>• Typically presents on sun-exposed skin (e.g. face, dorsal hands) as symmetric, pruritic or painful, erythematous macules and papules that progress to vesicles/bullae with central umbilication and hemorrhagic crusts<br>• Resolves with varioliform scarring<br>• Severe form features ulcerated nodules, a more widespread distribution, systemic findings (e.g. fever, hepatosplenomegaly, high circulating EBV DNA load and NK cells), and a high risk of hemophagocytic syndrome/lymphoma<br>• Patients with HV should be screened for active EBV infection | • Overlaps with EBV-related necrotic hypersensitivity to mosquito bites<br>• HSV, VZV<br>• LE, dermatomyositis<br>• Cutaneous porphyrias<br>• Lymphoma<br>• Histopathology, along with *in situ* hybridization for EBV RNA within lymphocytes, is very helpful in the diagnosis of HV | • Often refractory to therapy, as no effective medication is available for underlying EBV infection<br>**Mild:** photoprotection*, beta-carotene, fish oil, antimalarials<br>**Severe:** thalidomide, azathioprine, cyclosporine, hematopoietic stem cell transplant (if progression to lymphoma) |
| **Chronic actinic dermatitis (CAD)**<br>Fig. 73.10<br>(UVB > UVA; occasionally visible light) | • **Onset:** older age at onset (>50 years)<br>• **Duration:** persistent for years; typically, ~10% of cases resolve within 5 years, ~20% by 10 years, and 50% by 15 years<br>• **Clinical:** males > females; darker phototypes<br>• Presents on sun-exposed skin (initially with sharp cut-off at lines of clothing) as pruritic, eczematous papules and plaques with lichenification<br>• Occasionally pseudolymphomatous papules, plaques, and erythroderma are seen<br>• There is often a coexisting allergic contact dermatitis to plants (e.g. daisies) | • Photoaggravated dermatoses (e.g. atopic dermatitis)<br>• Photoallergic contact dermatitis<br>• Photoallergic drug<br>• LE<br>• Mycosis fungoides | **Mild:** photoprotection*, topical CS and CIs, and avoid relevant contact allergens and drugs<br>**Severe/recalcitrant:** cyclosporine, azathioprine, mycophenolate mofetil, low-dose PUVA |

**Table 73.2** *Continued* **Clinical features of the idiopathic, probably immunologically mediated photodermatoses and photoaggravated dermatoses.** *Continued*

| CLINICAL FEATURES OF THE IDIOPATHIC, PROBABLY IMMUNOLOGICALLY MEDIATED PHOTODERMATOSES AND PHOTOAGGRAVATED DERMATOSES | | | |
|---|---|---|---|
| **Photodermatosis (action spectrum)** | **Clinical features** | **DDx** | **Rx** |
| **Solar urticaria** Fig. 73.11 (UVA, visible light, rarely UVB; this action spectrum may change over the years) | • **Onset:** within 5–10 minutes of sun exposure; often older age at onset (30s–40s)<br>• **Duration:** lesions typically resolve over 1–2 hours; ~15% of cases resolve within 5 years and ~25% by 10 years<br>• **Clinical:** females > males<br>• Seen on sun-exposed skin only, favoring the upper chest and outer arms<br>• Individual lesions look like typical urticaria and cause pruritus, burning > pain<br>• 20–50% of affected individuals also have atopic dermatitis<br>• Several clinical variants exist, e.g. severe, anaphylactoid attacks; fixed; delayed; and drug-induced | • Other urticarias (not solely photodistributed)<br>• EPP (childhood, pain)<br>• PMLE (more delayed onset and lasts longer)<br>• LE | **Mild:** photoprotection* is recommended but often not helpful because of visible light induction; oral antihistamines<br>**Moderate–severe**<br>• Graduated exposure to UVA, PUVA<br>**Recalcitrant:** antimalarials, omalizumab, cyclosporine, plasmapheresis, IVIg |
| **Photoaggravated dermatoses** See Table 73.1 for list of disorders and Fig. 73.3 (UVA, UVB) | • **Onset:** usually flares within hours of sun exposure, but sometimes delayed a day or more<br>• **Duration:** days to months<br>• **Clinical:** exacerbation of underlying skin condition in sun-exposed and sometimes non-sun-exposed areas | • Sweat-aggravated dermatoses<br>• PMLE<br>• CAD | • Photoprotection* and treat the underlying dermatosis |
| **Photoprotection generally includes avoidance of sun, sun-protective clothing, broad-spectrum sunscreens, hats, sunglasses; for UVA-sensitive disorders, must also caution about protection from UVR received while driving or through glass windows; zinc- and titanium dioxide-based sunscreens are best for visible light-sensitive disorders.* | | | |

**Table 73.2** *Continued* **Clinical features of the idiopathic, probably immunologically mediated photodermatoses and photoaggravated dermatoses.**
CAD, chronic actinic dermatitis; CI, calcineurin inhibitor; EPP, erythropoietic protoporphyria; PMLE, polymorphous light eruption.




**Fig. 73.7 Actinic prurigo.** **A** The clinical features, including a photodistribution and worsening in the summer, are somewhat suggestive of polymorphous light eruption, but the lesions were persistent, and the HLA type was that seen in association with actinic prurigo. Note the involvement of the ears. **B** Multiple papules on the upper cheek, several of which have central crusts. A linear excoriation is seen on the lower portion of the upper eyelid. **C** The cheilitis is more severe on the lower vermilion lip. On the upper lip, chronic inflammation has led to blurring of the border between vermilion lip and the cutaneous lip. **D** The crusted papules are more dense on the distal arms. **E** This patient with severe actinic prurigo has involvement of the buttocks as well as sun-exposed sites. *A, D, E, Courtesy, John L. M. Hawk, MD; B, Courtesy, Henry W. Lim, MD and Cheryl F. Rosen, MD; C, Courtesy, Jean L. Bolognia, MD.*




**Fig. 73.8 Hydroa vacciniforme.** **A** There is an early, polymorphous light eruption-like appearance, but with vesicles around the mouth and umbilicated lesions on the nose. **B** Papulovesicles with crusting on the nose, cheeks and lips appeared a few days after sun exposure. **C** Hemorrhagic crusts are admixed with varioliform scars; the latter are the sequelae of repeated acute attacks. Note the scaling and erosions of the lower vermilion lip. **D** Varioliform scars and postinflammatory hyperpigmentation on the cheek. *A, Courtesy, John L. M. Hawk, MD; B, D, Courtesy, Tor Shwayder, MD; C, Courtesy, Jean L. Bolognia, MD.*

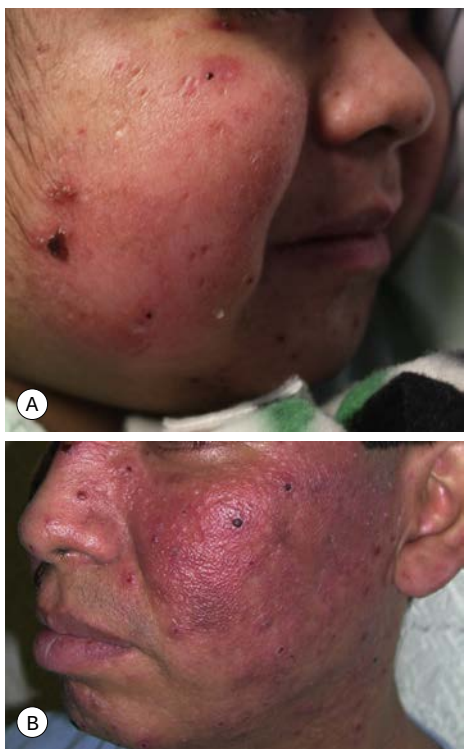


**Fig. 73.9 EBV-associated hydroa vacciniforme-like eruption.** **A** This Hispanic child had >50,000 copies of EBV DNA/100,000 WBCs as well as EBV RNA within skin lesions by *in situ* hybridization; he subsequently died of lymphoma. Note the facial edema, erythema, papulovesicles, hemorrhagic crusts, and varioliform scars. **B** Extensive involvement of the face by erythematous edematous plaques with hemorrhagic crusts at sites of vesiculation. *A, Courtesy, Richard Antaya, MD; B, Courtesy, Henry W. Lim, MD and Cheryl F. Rosen, MD.*

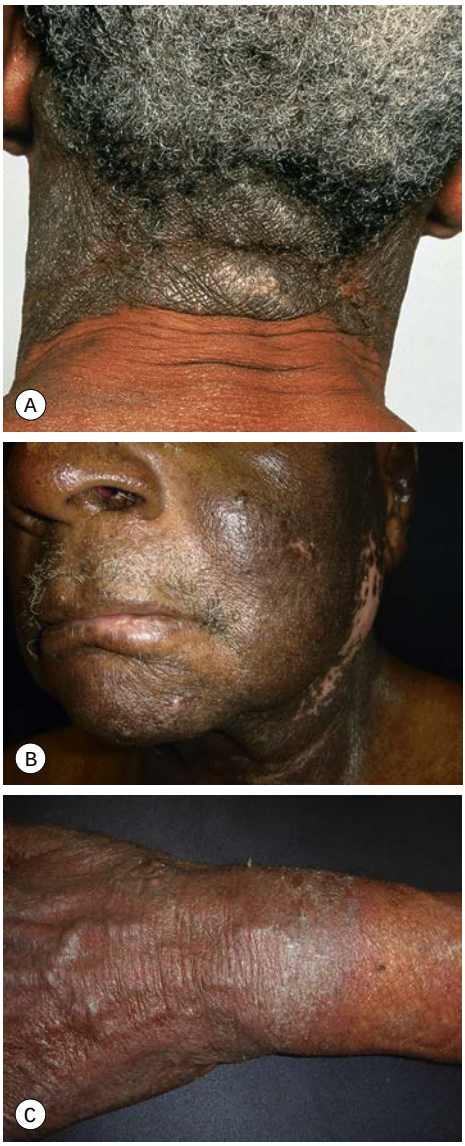


**Fig. 73.10 Chronic actinic dermatitis (CAD).** **A** Chronic eczematous changes of the posterior neck with lichenification and a sharp cut-off at the collar in a patient with phototype V skin. **B** Lichenification and hyperpigmentation in sun-exposed sites with areas of depigmentation. Note the sparing of sun-protected areas (i.e. nasolabial fold and shoulder). **C** Chronic eczematous changes of the dorsal hand and wrist with associated hyperpigmentation and scaling. Note the sharp cut-off at the distal forearm. *Courtesy, Henry Lim, MD.*



**Fig. 73.11 Solar urticaria.** Wheal and flare responses within minutes of exposure to UVB irradiation in a patient undergoing phototesting. *Courtesy, John L. M. Hawk, MD.*



**Fig. 73.12 Drug-induced photosensitivity and hyperpigmentation.** Gray-brown patches involving the sun-exposed skin of a patient receiving diltiazem. *Courtesy, Henry Lim, MD.*



**Fig. 73.13 Phototoxic reaction in a patient receiving methotrexate.** The erythema and bullae are obviously limited to sun-exposed sites and resemble an exaggerated sunburn. Patients on methotrexate can also experience a "sunburn-recall" phenomenon. *Courtesy, YDRSC.*

| CHEMICAL- AND DRUG-INDUCED PHOTOSENSITIVITY | | |
|---|---|---|
| **Disorder and etiology** | **Clinical features** | **DDx/evaluation** |
| **Exogenous** | | |
| **Phototoxicity**<br>• Phototoxic drug reaction to systemic medication > phototoxic contact dermatitis to topical medication or chemical (Table 73.4)<br>• Requires exposure to drug or chemical plus exposure to UVR (UVA > UVB) | • **Onset:** hours after sun exposure<br>• **Clinical**: Typically presents as an exaggerated sunburn reaction; associated burning or stinging; when severe, vesicles and/or bullae develop; resolves with desquamation and hyperpigmentation<br>• Other skin findings may include:<br>1. Photo-onycholysis (e.g. tetracyclines, psoralens) (Ch. 58)<br>2. Pseudo-PCT (e.g. NSAIDs) (Ch. 41)<br>3. Lichenoid eruption (e.g. thiazide diuretics [see Fig. 17.12], quinidine)*<br>4. Slate-gray hyperpigmentation (e.g. amiodarone, diltiazem [see Fig. 73.12], tricyclic antidepressants) | • Sunburn<br>• LE<br>• Photoallergy (see below)<br>• Airborne contact dermatitis<br>• EPP<br>• Solar urticaria<br>**Evaluation**<br>• If persistent despite discontinuation of suspected drug or chemical, consider phototesting and photopatch testing (Fig. 73.16) |
| **Phytophotodermatitis** (Ch. 12)<br>• Phototoxic reaction due to exposure to plants ("phyto") that contain a phototoxin plus exposure to UVA<br>• Most commonly due to furocoumarins found in limes, celery, and false Bishop's weed | • **Inflammatory reaction** (onset usually within 1 day): initially erythematous streaks, often with vesicles or bullae, reflecting exposure to the plant or its juice**;** painful, nonpruritic; configuration may be unusual, depending on the type of exposure<br>• **Delayed pigmentary reaction:** hyperpigmented streaks (occasionally appear without a preceding inflammatory phase); may last months to years | • Allergic contact dermatitis to plants, e.g. poison ivy or poison oak; distribution includes sites that are exposed to the environment but not the sun, e.g. inner arms<br>• May be confused with child abuse |

**Table 73.3 Chemical- and drug-induced photosensitivity.** *Continued*

| CHEMICAL- AND DRUG-INDUCED PHOTOSENSITIVITY | | |
|---|---|---|
| **Disorder and etiology** | **Clinical features** | **DDx/evaluation** |
| **Photoallergy**<br>• Photoallergic contact dermatitis to topical medication or chemical > photoallergic drug reaction to systemic medication<br>• Requires exposure to drug or chemical plus UVR (Table 73.4) | • **Onset:** first exposure: 7–10 days; subsequent: minutes to hours<br>• **Clinical:** pruritic, eczematous eruption; occasionally vesicles and bullae | • Allergic contact dermatitis<br>• Photoaggravated dermatosis (e.g. atopic dermatitis)<br>• Airborne contact dermatitis<br>• Phototoxicity<br>**Evaluation**<br>• If persistent despite discontinuation of suspected topical medication or systemic drug, consider phototesting and photopatch testing; photopatch testing is positive, whereas phototoxicity is negative (see Fig. 73.16) |
| **Endogenous** | | |
| **Erythropoietic protoporphyria (EPP)** (Ch. 41) | | |
| **Porphyria cutanea tarda (PCT)** (Ch. 41) | | |
| **Lichenoid drug eruptions, including photolichenoid drug eruptions, are discussed in Chapter 9.* | | |

**Table 73.3** *Continued* **Chemical- and drug-induced photosensitivity.** Treatment of phototoxic and photoallergic reactions includes discontinuation of the offending agent or medication, photoprotection, symptomatic care, and occasionally topical or oral CS if severe. Photoprotection generally includes avoidance of sun, sun-protective clothing, broad-spectrum sunscreens, hats, and sunglasses; for UVA-sensitive disorders, must also caution about protection from UVR received while driving or through glass windows; zinc-and titanium dioxide-based sunscreens are best for visible light-sensitive disorders. EPP, erythropoietic protoporphyria; PCT, porphyria cutanea tarda.

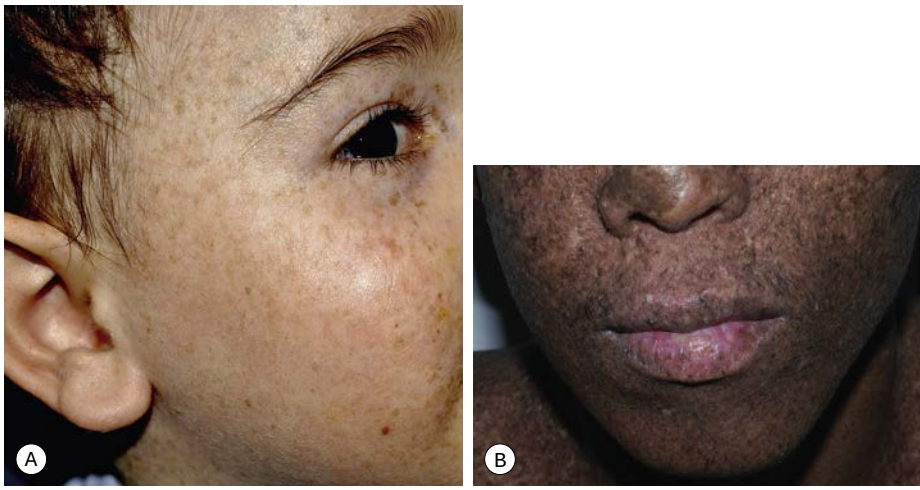

**Fig. 73.14 Xeroderma pigmentosum. A** Multiple solar lentigines on the face and a history of photosensitivity in this four-year-old child. **B** A 17-year-old boy with skin phototype V who has hyper- and hypopigmentation admixed with scarring, lentigines, and seborrheic as well as actinic keratoses. Note the squamous cell carcinoma *in situ* of the lower lip in association with severe actinic cheilitis.
*A, Courtesy, Antonio Torrelo, MD; B, Courtesy, Julie V. Schaffer, MD.*

## Grover Disease (Transient Acantholytic Dermatosis)

- Although referred to as transient, is often persistent; thought to result from a combination of photodamage and sweating.
- Occurs primarily in middle-aged males > females as pruritic, often crusted, skin-colored to pink papules and papulovesicles on the trunk, primarily in sun-exposed areas (see Fig. 48.2 and Fig. 73.18).
- **Rx:** difficult but may include low- to mid-potency topical CS and avoidance of exacerbating factors (e.g. heat, friction, sun exposure).

For further information see Ch. 87 from *Dermatology, Fourth Edition*.

**For additional online figures and tables visit www.expertconsult.com**

| COMMON PHOTOTOXIC AND PHOTOALLERGIC AGENTS | |
|---|---|
| **Common phototoxic agents** | **Common photoallergic agents** |
| • Antiarrhythmics<br>Amiodarone<br>Quinidine<br>• Anti-fibrotic agents<br>Pirfenidone<br>• Triazole antifungals<br>Voriconazole*<br>• Antimicrobials<br>Quinolones (e.g. ciprofloxacin, sparfloxacin, nalidixic acid)<br>Sulfonamides<br>Tetracyclines (e.g. doxycycline*, demeclocycline)<br>• Calcium channel blockers<br>Diltiazem (see Fig. 73.12)<br>• Diuretics<br>Furosemide<br>Thiazides*<br>• Nonsteroidal anti-inflammatory drugs<br>Nabumetone<br>Naproxen<br>Piroxicam<br>• Phenothiazines<br>Chlorpromazine<br>Prochlorperazine<br>• Photodynamic therapy agents<br>Aminolevulinic acid<br>Methyl aminolevulinate<br>• Psoralens (e.g. 5-, 8-methoxypsoralen)<br>• St. John's wort (hypericin)<br>• Sulfonylureas<br>• Tar (topical)<br>• Targeted therapies<br>Vemurafenib* | **Topical agents**<br>• Sunscreens (e.g. oxybenzone [benzophenone-3], octocrylene)<br>• Fragrances<br>6-Methylcoumarin<br>Musk ambrette<br>Sandalwood oil<br>• Antimicrobial agents<br>Bithionol<br>Chlorhexidine<br>Fenticlor<br>Hexachlorophene<br>• Nonsteroidal anti-inflammatory drugs<br>Diclofenac<br>Ketoprofen<br>• Phenothiazines<br>Chlorpromazine<br>Promethazine<br>**Systemic agents**<br>• Antiarrhythmics<br>Quinidine<br>• Antimalarials<br>Quinine<br>• Antifungals<br>Griseofulvin<br>• Antimicrobials<br>Quinolones (e.g. enoxacin, lomefloxacin)<br>Sulfonamides<br>• Nonsteroidal anti-inflammatory drugs<br>Ketoprofen<br>Piroxicam** |
| *Also cause accelerated photocarcinogenesis.<br>**Often have positive patch test to thimerosol. | |

**Table 73.4 Common phototoxic and photoallergic agents.**

| CLINICAL FEATURES OF SELECTED INHERITED PHOTOSENSITIVITY DISORDERS ASSOCIATED WITH DEFECTIVE DNA NUCLEOTIDE EXCISION REPAIR OR CHROMOSOMAL INSTABLILITY | |
|---|---|
| **Inherited disorder** | **Clinical features** |
| Defective DNA nucleotide excision repair | |
| **Xeroderma pigmentosum (XP)** (Fig. 73.14) | • Photosensitivity, xerosis, early onset lentigines (about age 2 years) and dyspigmentation<br>• BCCs, SCCs, cutaneous melanomas in sun-exposed areas; median age of NMSC onset is 9 years & for melanomas, 22 years<br>• Photophobia, keratitis, corneal opacification<br>• Increased incidence of intraoral and ocular malignancies as well as CNS tumors<br>• Neurologic abnormalities (e.g. hyporeflexia, deafness, seizures) |
| **Cockayne syndrome (CS)** | • Photosensitivity, pigmented macules, thinned skin, alopecia, nail clubbing, acral edema, prominent ears, dental caries<br>• Progressive signs of premature aging<br>• Cachectic dwarfism, microcephaly, hypogonadism, deafness, intellectual impairment<br>• No increase in malignancies |
| Chromosomal instability | |
| **Bloom syndrome** | • More common in Ashkenazi Jews<br>• Presents in first few weeks of life with malar erythema and telangiectasias, exacerbated by sun exposure<br>• Café-au-lait macules with adjacent hypopigmented macules<br>• Growth delay, short stature, normal intelligence, recurrent infections<br>• Increased incidence of internal malignancies (e.g. leukemia) |
| **Rothmund–Thomson syndrome** | • Presents in first few months of life with photodistributed erythema, edema, and vesicles on cheeks and face<br>• Later develop poikiloderma on dorsal extremities and buttocks<br>• Acral keratoses, short stature and radial ray defects<br>• Increased risk of SCC and osteosarcoma<br>• Normal immune function and intelligence |

**Table 73.5 Clinical features of selected inherited photosensitivity disorders associated with defective DNA nucleotide excision repair or chromosomal instability.** All of these diseases are rare and inherited in an autosomal recessive fashion. Another photosensitivity disorder due to hereditary defects in DNA repair is trichothiodystrophy (TTD; see Table 46.1).

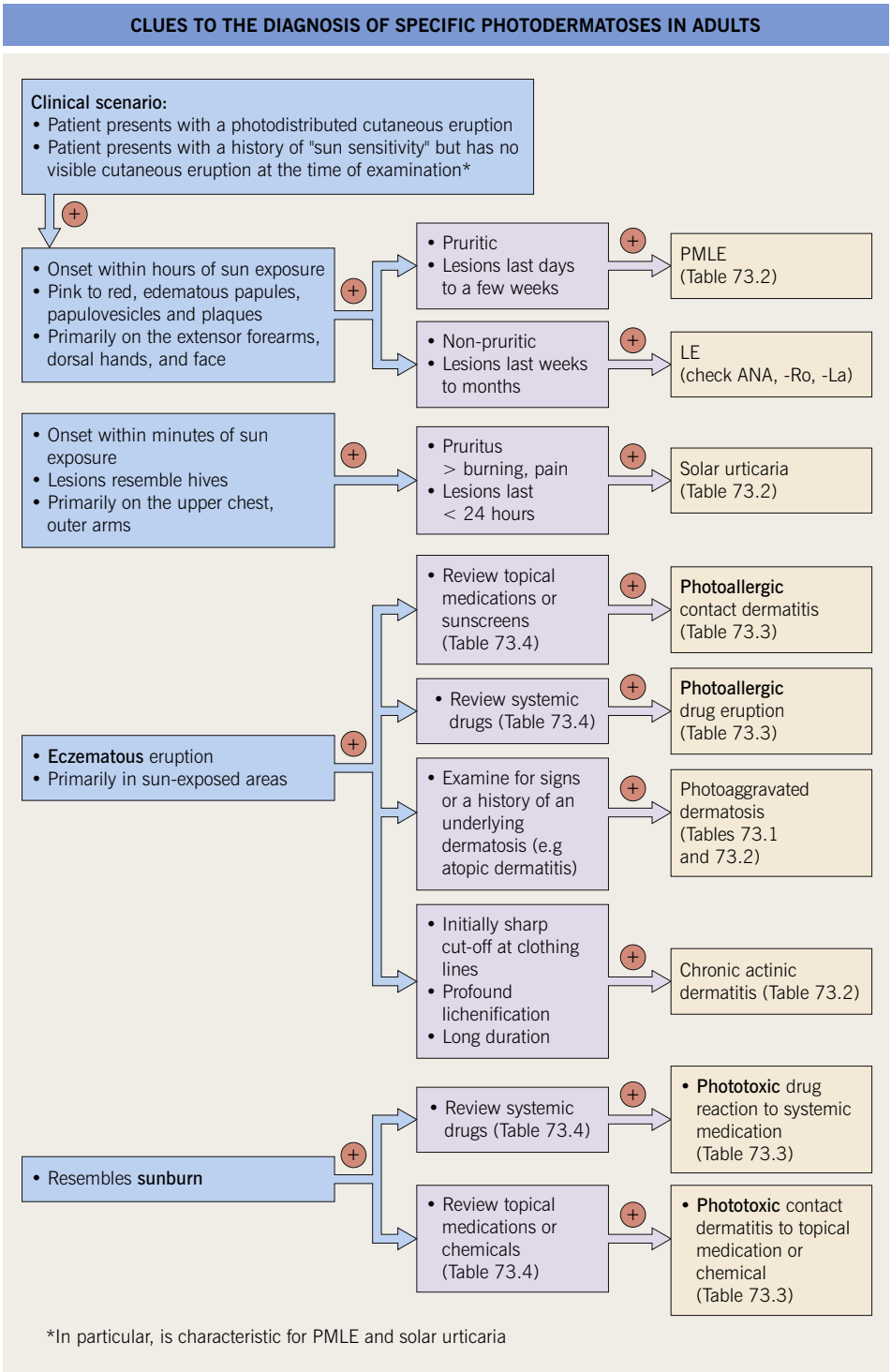


**Fig. 73.15 Clues to the diagnosis of specific photodermatoses in adults.** PMLE, polymorphous light eruption.

**EXOGENOUS CHEMICAL-INDUCED PHOTOSENSITIVITY: INTERPRETATION OF PHOTOPATCH TESTS**

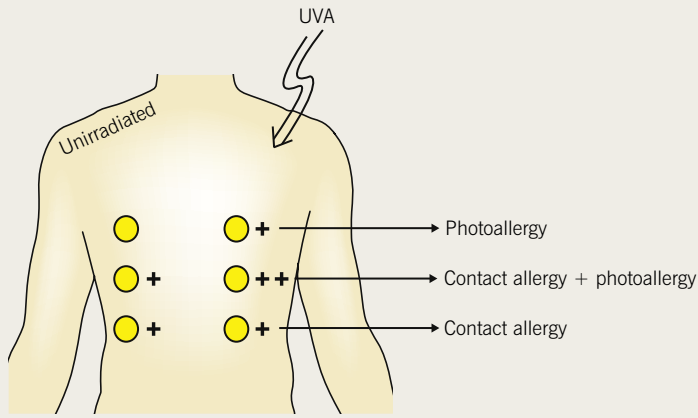


**Fig. 73.16 Exogenous chemical-induced photosensitivity: interpretation of photopatch tests.** This schematic demonstrates the interpretation of photopatch tests. The UVA dose is usually the lower of 5 J/cm$^2$, or 50% of the MED to UVA.

**SITES OF SPARING IN PHOTODISTRIBUTED DERMATOSES OF THE HEAD AND NECK**

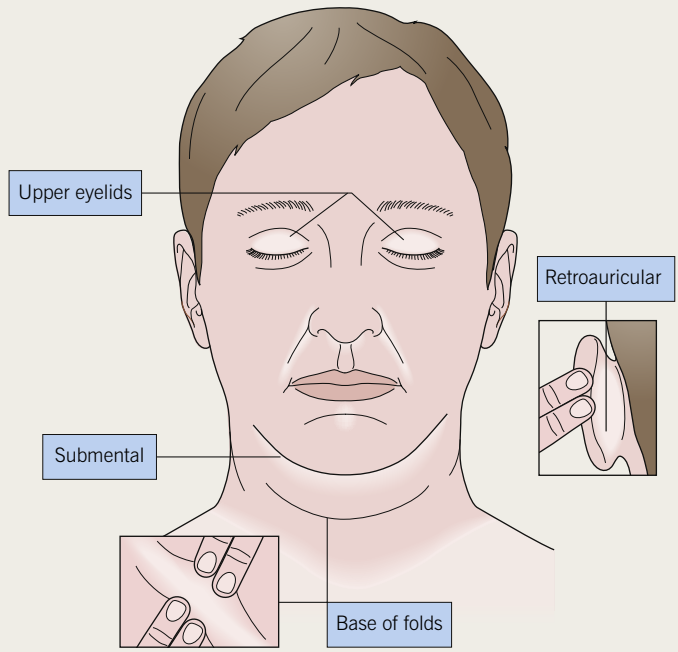


**Fig. 73.17 Sites of sparing in photodistributed dermatoses of the head and neck (e.g. chronic actinic dermatitis and photoallergic dermatitis).** Relatively sun-protected sites include the upper eyelids, nasolabial folds, retroauricular areas, submental region, and deepest portion of skin furrows. In airborne contact dermatitis, these areas may be involved.




**Fig. 73.18 Grover disease.** Crusted papules of the trunk **(A)** and obvious sparing of the sun-protected skin of the buttocks **(B)** in this patient with significant photodamage.
*Courtesy, Jean L. Bolognia, MD.*

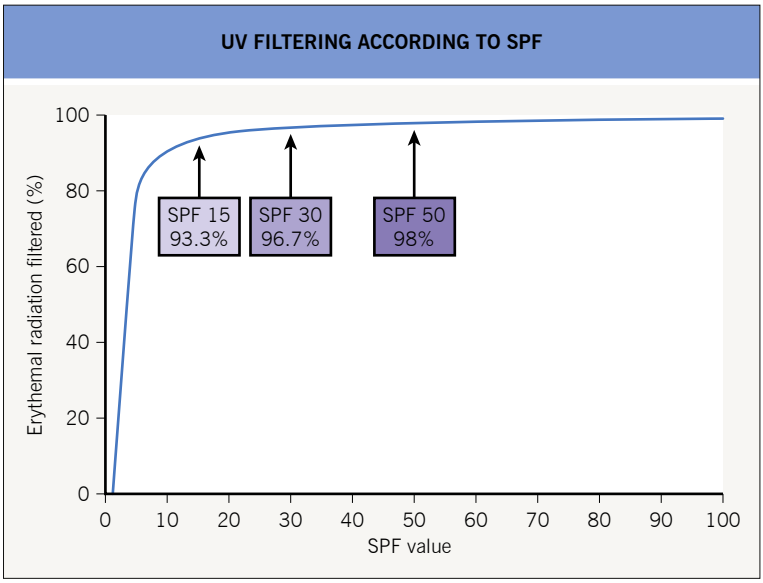


**eFig. 73.1 Relationship between sun protection factor (SPF) and the amount of UV radiation that is filtered by a sunscreen.** The percentage of UV blockage basically levels off above SPF 30.

**ACTIVE COMPONENTS OF SUNSCREENS**

| | Absorption | | | |
|---|---|---|---|---|
| | UVB | UVA2 | UVA1 | Visible |
| | 290–320 | 320–340 | 340–400 | 400–800 |
| **Organic, soluble, "chemical absorbers"** | | | | |
| **PABA derivatives** | | | | |
| Padimate O (octyl dimethyl PABA) | ■ | | | |
| **Cinnamates** | | | | |
| Octyl methoxycinnamate (Octinoxate, Parsol MCX) | ■ | | | |
| Cinoxate | ■ | | | |
| Amiloxate* | ■ | | | |
| **Salicylates** | | | | |
| Octisalate (octyl salicylate) | ■ | | | |
| Homosalate (homomethyl salicylate) | ■ | | | |
| **Benzophenones** | | | | |
| Dioxybenzone (benzophenone-8) | ■ | ▒ | | |
| Oxybenzone (benzophenone-3) | ■ | ■ | | |
| Sulisobenzone (benzophenone-4) | | ■ | ▒ | |
| **Others** | | | | |
| Octocrylene | ■ | | | |
| Ensulizole (phenylbenzimidazole sulfonic acid) | ■ | | | |
| Enzacamene (4-methyl-benzylidene camphor [4-MBC], Eusolex 6300, Neo Heliopan® MBC)* | ■ | | | |
| Ethylhexyl triazone [octyl triazone] (Uvinal® T 150)* | ■ | | | |
| Iscotrizinol (diethylhexyl butamido triazone, Uvasorb® HEB)* | ■ | ■ | | |
| Drometrizole trisiloxane (Mexoryl™ XL)* | ■ | ■ | ■ | |
| Bisoctrizole (methylene-bis-benzotriazolyl tetramethylbutylphenol, Tinosorb® M)* | ■ | ■ | ■ | |
| Menthyl anthranilate (meradimate) | | ■ | | |
| Avobenzone (butyl methoxydibenzoyl methane, Parsol 1789) | | ■ | ■ | |
| Ecamsule (terephthalylidene dicamphor sulfonic acid, Mexoryl™ SX)** | | ■ | ■ | |
| Bemotrizinol (bis-ethylhexyloxyphenol methoxyphenyl triazine, Tinosorb® S)* | | ■ | ■ | |
| Diethyamino hydroxybenzoyl hexyl benzoate (Uvinul® A Plus)* | | ■ | ■ | |
| Bisdisulizole (Neo Heliopan® AP)* | | ■ | ■ | |
| **Inorganic, insoluble, "physical blockers"*** ** | | | | |
| Titanium dioxide | ■ | ■ | ■ | ▒ |
| Zinc oxide | ■ | ■ | ■ | ▒ |
| **Other agents (not considered active screens)** | | | | |
| Dihydroxyacetone | ▒ | ▒ | ▒ | ▒ |
| Iron oxide | ▒ | ▒ | ▒ | ▒ |

*Currently not FDA-approved.
**This agent is approved for use by the FDA in a single line of commercial products approved under an Individual New Drug (IND) process.
***Depending on particle size, with micronized particles shifting protection toward UVA2; inorganic filters, especially when micronized, have been shown to function primarily by photon absorption rather than by scattering in the UV range.

**eFig. 73.2 Active components of sunscreens.** Lighter colored bars represent variable efficacy. "Boosters" that are not UV filters are also added to sunscreen products, e.g. tiny spheres that scatter incoming radiation and agents that increase the spread of the sunscreen on the skin.



**eFig. 73.3 Sunburn.** Twenty-four hours after an accidental 10-fold overdose of UVB prescribed as phototherapy. *Courtesy, Department of Dermatology, University of Würzburg, Germany.*



**eFig. 73.4 Sequelae of exposure to UV light.** UVA-induced tan with reduced pigmentation within an area of relative ischemia (due to pressure while lying on a tanning bed); this leads to reduced UVA-induced, oxygen-dependent melanin oxidation within this area. Excessive sun exposure plus long-term use of tanning beds has led to a leather-like appearance to the skin. *Courtesy, Jean L. Bolognia, MD.*

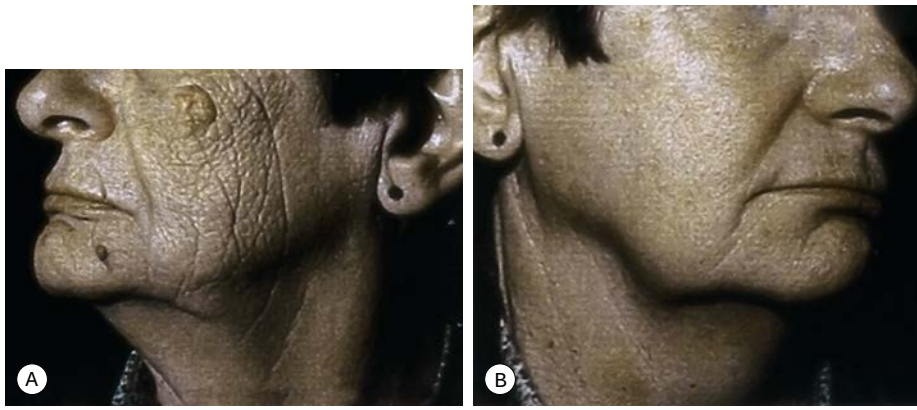


**eFig. 73.5 Unilateral photoaging following 15 years of unilateral sun exposure through window glass. A** Exposed side of face. **B** Non-exposed side of face. This individual had been working in the same office for 15 years, close to a window, with the left cheek always facing the window. Biopsy confirmed the diagnosis of nodular cutaneous elastosis with cysts and comedones (Favre–Racouchot disease). Since UVB does not penetrate window glass, this observation identifies UVA as an effective agent in photoaging. *Reproduced with permission from Moulin G, Thomas L, Vigneau M, Fiere A. Un cas unilateral d'élastose avec kystes et comédons de Favre et Racouchot. Ann Dermatol Venereol 1994;121:721–3.*




**eFig. 73.6 Cutaneous signs of significant photoaging.** **A** Solar elastosis of the arm with characteristic yellow discoloration and thickening of the skin. **B** Solar elastosis of the neck, extending onto the back, in a patient with oculocutaneous albinism from sub-Saharan Africa. **C** Poikiloderma of Civatte with sparing of the anterior neck. **D** Solar (actinic) purpura and residual discoloration due to hemosiderin. There is also evidence of skin fragility. **E** Fragility and atrophic photodamaged skin of the shin. **F** Erosive pustular dermatosis of the bald scalp. *A, E, Courtesy, Jean L. Bolognia, MD; B, Courtesy, Rosemarie Moser, MD; C, Courtesy, NYUDSC; D, Courtesy, Henry W. Lim, MD and Cheryl F. Rosen, MD; F, Courtesy, YDRSC.*

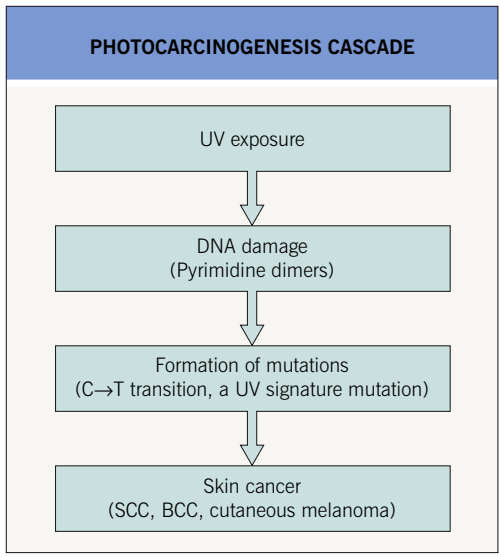


**eFig. 73.7 Photocarcinogenesis cascade.** UV-induced DNA damage generates mutations, which, after accumulation of a sufficient number of mutations in critical genes, may finally result in malignant transformation of single keratinocytes or melanocytes and with that formation of skin cancer. *Courtesy, Thomas M. Rünger, MD PhD.*

**MECHANISMS THAT PROTECT AGAINST OR PREVENT THE PHOTOCARCINOGENESIS CASCADE AND DISORDERS THAT PREDISPOSE TO SKIN CANCER BECAUSE OF IMPAIRED INTRINSIC PROTECTIVE MECHANISMS**

| Intrinsic protective mechanisms | | Hereditary or acquired disorders with an increased risk for UV-induced skin cancer | Methods to prevent skin cancer |
|---|---|---|---|
| | UV exposure | | |
| Hair/fur | | Alopecia, in particular androgenetic | Sun avoidance<br>Protective clothing, hats |
| Pigmentation<br>Epidermal thickening and hyperkeratosis<br>Anti-oxidative enzymes | | Oculocutaneous albinism | Broad-spectrum sunscreens<br>Antioxidants |
| | DNA damage | | |
| DNA repair<br>High-fidelity translesional DNA synthesis<br>Cell cycle arrest/apoptosis | | Xeroderma pigmentosum<br>Xeroderma pigmentosum variant<br>Familial melanoma | Increased DNA repair<br>Increased apoptosis |
| | Mutations | | |
| Removal of mutated cells<br>(immune surveillance) | | Immunosuppression, e.g. solid organ transplant patients | Improve immune surveillance |
| | Skin cancer | | |

**eFig. 73.8 Mechanisms that protect against or prevent the photocarcinogenesis cascade and disorders that predispose to skin cancer because of impaired intrinsic protective mechanisms.** Several intrinsic mechanisms protect against the formation of skin cancer following UV exposure at different points of the photocarcinogenesis cascade of events. These mechanisms are impaired in disorders with increased risk for UV-induced skin cancer. Each step of the photocarcinogenesis cascade can be targeted for therapeutic modification and reduction of skin cancer risk. *Courtesy, Thomas M. Rünger, MD PhD.*




**eFig. 73.9 Polymorphous light eruption.** **A** Pinhead-sized papules on the forearm in an African-American adult. **B** Papulovesicles on the upper back. Some have a central crust. **C** Numerous small papules. *A, B, Courtesy, Henry W. Lim, MD and Cheryl F. Rosen, MD; C, Courtesy, YDRSC.*

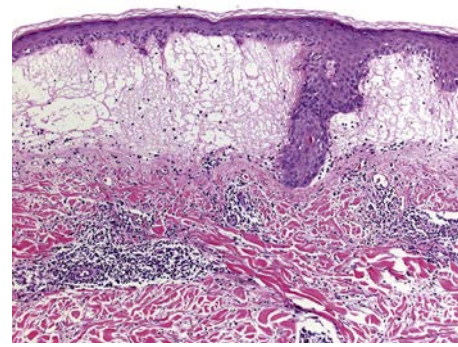

**eFig. 73.10 Polymorphous light eruption (PMLE) – histopathologic features.** Within the dermis, there is a perivascular mononuclear cell infiltrate as well as marked papillary edema. *Courtesy, Lorenzo Cerroni, MD.*



**eFig. 73.11 Actinic prurigo.** Papules, plaques with scale, and excoriations on the dorsal hand and extensor forearm. *Courtesy, Henry W. Lim, MD and Cheryl F. Rosen, MD.*



**eFig. 73.12 Hydroa vacciniforme.** More severe crusting and scarring. *Courtesy, John L. M. Hawk, MD.*

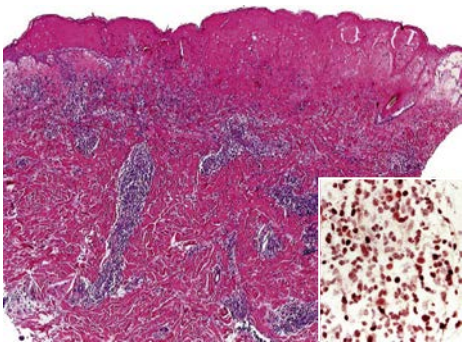

**eFig. 73.13 Hydroa vacciniforme – histopathologic features.** Necrosis of the epidermis with dense, mainly perivascular, infiltrates of lymphocytes within the entire dermis. Note positivity of lymphocytes for EBV as detected by *in situ* hybridization for EBER-1 (inset). *Courtesy, Lorenzo Cerroni, MD.*




**eFig. 73.14 Phytophotodermatitis.** **A** Bullous phase with associated burning but no pruritus. The linear bullae were replaced by hyperpigmentation. **B** Streaky hyperpigmentation due to contact with a psoralen-containing plant followed by exposure to sunlight. *A, Courtesy, Jean L. Bolognia, MD; B, Courtesy, Lorenzo Cerroni, MD.*

| DETERMINATION OF THE SUN PROTECTION FACTOR (SPF) |
|---|
| 10 human subjects<br>Skin type I or II<br>Irradiation: light source which mimics solar spectrum<br>Procedure: determine minimal erythema dose (MED) in sunscreen-protected* and unprotected skin<br><br>$SPF = \frac{\text{MED protected}}{\text{MED unprotected}}$<br><br>To test substantivity – after application and before MED testing:<br>Water resistant (40): 2 × 20-min water immersions (whirlpool bath)†<br>Water resistant (80): 4 × 20-min water immersions (whirlpool bath)† |
| **Sunscreen product applied at 2 mg/cm$^2$.*<br>*†Air drying in between immersions.* |

**eTable 73.1 Determination of the sun protection factor (SPF).**

| GUIDELINES FOR PHOTOPROTECTION |
|---|
| Avoid direct sun exposure between 10 AM and 4 PM whenever possible |
| Seek the shade to shelter you from direct sun exposure |
| Wear protective clothing, hats, and sunglasses whenever possible |
| Apply sunscreen to all exposed skin when you will be outdoors |
| Use a sunscreen with an SPF 30 or greater that is labeled as BROAD SPECTRUM |
| Use up to 1 to 2 ounces of sunscreen to cover exposed skin (in an adult) |
| Apply the sunscreen 15 minutes before sun exposure |
| Use a water-resistant sunscreen if you are going to swim or perspire heavily |
| Re-apply sunscreen every 2 hours or after swimming or excessive sweating |
| Spray sunscreens must be applied liberally to achieve the rated SPF |

**eTable 73.2 Guidelines for photoprotection.** SPF, sun protection factor. *Courtesy, Vincent A. DeLeo, MD.*

| CUTANEOUS SIGNS OF SIGNIFICANT PHOTODAMAGE |
|---|
| Solar elastosis (Fig. 73.2A,B) |
| Cutis rhomboidalis nuchae (Fig. 73.2C) |
| Wrinkling (coarse > fine) |
| Favre–Racouchot syndrome (nodular elastosis with cysts and comedones) (Fig. 73.2E) |
| Poikiloderma of Civatte (Fig. 73.2D) |
| Solar purpura and hemosiderin deposition (Fig. 73.2F) |
| Fragility (Fig. 73.2G) |
| Pseudoscars |
| Erosive pustular dermatosis (Fig. 73.2H) |
| Dyschromia, including idiopathic guttate hypomelanosis |
| Solar lentigines, ephelides |
| Actinic keratoses |
| Squamous cell carcinoma |
| Basal cell carcinoma |
| Cutaneous melanoma, including lentigo maligna |
| Colloid milium |
| Solar elastotic bands |
| Elastoma of Dubreuilh |
| Acquired elastotic hemangioma |
| Elastotic nodules of the ear |
| Weathering nodules |

**eTable 73.3 Cutaneous signs of significant photodamage.**

| EVALUATION OF PHOTOSENSITIVITY – POSSIBLE LABORATORY INVESTIGATIONS |
|---|
| Routine histology |
| Antinuclear antibodies |
| Anti-SSA/Ro, -SSB/La antibodies |
| Plasma porphyrins, followed by complete porphyrin profile if positive (see Ch. 41) |
| Phototesting to UVA, UVB, and visible light |
| Photopatch testing (see Fig. 73.16) |

**eTable 73.4 Evaluation of photosensitivity – possible laboratory investigations.**



A L G r a w a n y

| COMMONLY EMPLOYED PHOTOPATCH TEST SERIES | | | |
|---|---|---|---|
| | | North American photopatch series | European photopatch baseline series |
| **Class of photoallergen** | **Photoallergen** | **Conc/vehicle** | |
| Sunscreen ingredients | Ethylhexyl methoxycinnamate (Parsol MCX) | 7.5% pet | 10% pet |
| | Benzophenone-4 | 10% pet | 2% pet |
| | PABA | 5% alcohol and 5% pet | 10% pet |
| | Ethylhexyl dimethyl PABA | 5% alcohol and 10% pet | |
| | Benzophenone-3 | 10% pet | 10% pet |
| | Ethylhexyl salicylate | 5% pet | |
| | Butyl methoxydibenzoyl methane (Parsol 1789) | 5% pet | 10% pet |
| | Homosalate | 5% pet | |
| | Methyl anthranilate | 5% pet | |
| | 6-methyl coumarin | 1% alcohol | |
| | 4-methyl-benzylidene camphor (Eusolex 6300) | | 10% pet |
| | Octocrylene | | 10% pet |
| | Isoamyl p-methoxycinnamate | | 10% pet |
| | Bis-ethylhexylphenol methoxyphenol triazine (Tinosorb® S) | | 10% pet |
| | Drometrizole trisiloxane (Mexoryl™ XL) | | 10% pet |
| | 2-(4-Diethylamino-2-hydroxybenzoyl)-benzoic acid hexylester (Uvinul® A Plus) | | 10% pet |
| | Ethylhexyl triazone | | 10% pet |
| | Methylene bis-benzotriazolyl tetramethylbutylphenol (Tinosorb® M) | | 10% pet |
| | Diethylhexyl butamido triazone (Uvasorb® HEB) | | 10% pet |
| Microbicides | Dichlorophene | 1% pet | |
| | Triclosan | 2% pet | |
| | Hexachlorophene | 1% pet | |
| | Chlorhexidine diacetate | 0.5% aq | |
| | 3,4,5-Tribromosalicylanilide | 1% pet | |
| | Bithionol | 1% pet | |
| | 2,2'-thiobis(4-chlorophenol) (Fentichlor) | 1% pet | |
| Anti-psychotics | Chlorpromazine | 0.1% pet | |
| | Promethazine hydrochloride | 1% pet | 0.1% pet |
| NSAIDs | Ketoprofen | | 1% pet |
| | Etofenamate | | 2% pet |
| | Piroxicam | | 1% pet |
| | Benzydamine hydrochloride | | 2% pet |
| Miscellaneous | Sandalwood oil | 2% pet | |
| | Benzydamine hydrochloride | | 2% pet |
| | Decyl glucoside | | 5% pet |

**eTable 73.5 Commonly employed photopatch test series.** A petrolatum (100%) patch test is also applied as a control. When comparing to sunscreen agents, octyl = ethylhexyl. Aq, aqueous solution; Conc, concentration; pet, petrolatum.

# 74 Environmental and Sports-Related Skin Diseases

## Cutaneous Injury Due to Heat Exposure

### Thermal Burns

- Traumatic injury to the skin caused by an external heat source (Fig. 74.1).
- The depth of the burn injury depends on the temperature of and the amount of contact time with the heat source as well as the thickness of the affected skin.
- The *burn depth* determines the severity and classification of the injury, its potential for healing, and need for surgical intervention (Table 74.1).
- An exact classification of the burn injury may not be possible upon initial presentation and may take up to 3 weeks to determine; burns may be deeper than initially suspected when occurring on thinner skin (e.g. in pediatric and elderly patients; on ears, volar forearms, medial thighs, and perineum).
- The *extent of burn injury* is expressed as a percentage of the body surface area (BSA) involved and is essential for guiding therapy and determining a patient's disposition (e.g. hospital admission for a partial-thickness burn involving >10% BSA in an individual 10–50 years of age).



**Fig. 74.1 Thermal burn.** This superficial partial-thickness burn is characterized by bullae that contain serous fluid. *Courtesy, Kalman Watsky, MD.*

- The most accurate method for estimating BSA involvement in adults and children is the Lund–Browder chart (https://www.remm.nlm.gov/LundBrowder.pdf); the "rule of nines" method is perhaps more expeditious in adults, but it cannot be used for children (Fig. 74.2).
- General principles of treatment are outlined in Table 74.1.

### Erythema Ab Igne

- Localized areas of reticulated erythema and hyperpigmentation due to chronic exposure to heat that is below the threshold for a thermal burn.
- Multiple heat sources have been implicated (Table 74.2).
- Most commonly seen in the lumbosacral region (due to heating pads applied to relieve pain from degenerative spinal disease); more recently seen on the anterior thighs from heated batteries in laptop computers.
- In long-standing erythema ab igne (latency period ≥30 years) there is an associated risk of malignant degeneration, resulting in thermal keratoses and SCC.
- *Early lesions*: asymptomatic, initially transient, blanchable macular erythema in a broad, reticulated pattern that corresponds to the venous plexus; size and shape approximates that of the heat source (Fig. 74.3A).
- *Later lesions*: dusky reticulated hyperpigmentation; lesions are fixed and no longer blanchable (Fig. 74.3B).
- *End stage*: may become keratotic and bullae may appear.
- **DDx:** livedo reticularis, cutis marmorata, poikiloderma (e.g. due to CTCL, dermatomyositis, several genodermatoses); the latter has a tighter net-like pattern.
- **Rx:** remove the heat source; if applicable, identify and treat the underlying source of pain.

| CLASSIFICATION AND TREATMENT OF THERMAL BURNS | | |
|---|---|---|
| **Type** | **Depth** | **Clinical features**<br>**Treatment*** |
| **FIRST DEGREE (Superficial)** | Epidermis only | • Pain, tenderness<br>• Dry, erythema, no blistering<br>• Blanches with pressure<br>• Heals without scar in 3–6 days<br>• No specific treatment needed<br>• Aloe vera**, sun protection |
| **SECOND DEGREE (Partial thickness – superficial)** (Fig. 74.1) | Epidermis and superficial dermis | • Severe pain and tenderness<br>• Serous or hemorrhagic bullae, deep rubor, erosion and exudation<br>• Blanches with pressure<br>• Heals in 7–21 days with mild but variable scarring<br>• Daily dressing changes with topical antibiotic (e.g. silver sulfadiazine¶, silver nitrate¶¶, mafenide acetate, mupirocin) and gauze until re-epithelialization occurs***<br>• Sun protection |
| **SECOND DEGREE (Partial thickness – deep)** | Epidermis and most of dermis destroyed, including deep follicular structures | • Intense pain but reduced sensation (pressure only)<br>• Deep red to pale and speckled in color<br>• Does not blanch with pressure<br>• Serosanguinous bullae (easily unroofed), erosions<br>• May appear devitalized initially<br>• Prolonged healing time (>21 days)<br>• Hypertrophic scars and marked wound contracture<br>• Surgical intervention¶¶¶ |
| **THIRD DEGREE (Full thickness)** | Full-thickness epidermal and dermal destruction | • Sensation to deep pressure only<br>• Dry, hard, waxy white to gray or charred black in color<br>• Does not blanch with pressure<br>• Small lesions heal with significant scarring<br>• Most require surgical correction<br>• Surgical intervention¶¶¶ |
| **FOURTH DEGREE** | Extends through the skin into fascia, muscle, bone, and/or joints | • Sensation to deep pressure only<br>• Does not heal unless surgical intervention<br>• Potentially life-threatening<br>• Surgical intervention¶¶¶ |

**General principles of treatment include removal of the heat source; assessment and treatment of cardiopulmonary issues; cool compresses; pain control; cleaning of the wound (soap and water) and removal of foreign material; prevention of infection; tetanus prophylaxis; and creation of a proper wound healing environment.*

***May act as an anti-inflammatory agent and decrease levels of thromboxane, but can cause allergic contact dermatitis.*

****A basic dressing may include a first layer of a nonadherent gauze (e.g. Adaptic or Xeroform), a second layer of dry gauze, and an outer layer of wrapped gauze.*

*¶Extensive use/percutaneous absorption may cause leukopenia, pseudoeschar, and argyria.*

*¶¶Potential for argyria.*

*¶¶¶Serial excisions; skin substitutes.*

**Table 74.1 Classification and treatment of thermal burns.**

**ASSESSING THE EXTENT OF BODY SURFACE AREA (BSA) INVOLVEMENT IN BURN INJURIES: RULE OF NINES**

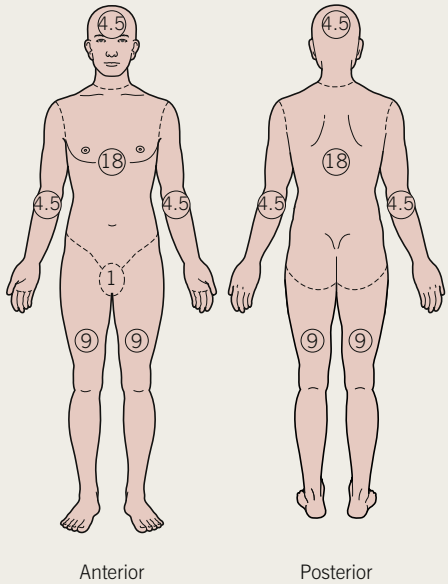


**Fig. 74.2 Assessing the extent of body surface area (BSA) involvement in burn injuries: rule of nines.** In adults, an estimate of burn extent is often based on this surface area distribution chart. Infants and children have a relatively increased head:trunk surface area ratio and this chart is ineffective for them. Note that the palm is ~1% of BSA and can be used for estimating patchy areas. These estimates are also used for primary cutaneous disorders. Only partial- and full-thickness burns are considered in BSA measurements. The most accurate method of estimating the BSA involvement of burn injury in adults and children is with the Lund–Browder chart (https://www.remm.nlm.gov/LundBrowder.pdf).

## Burns Associated with MRI and Fluoroscopy

### MRI

- MRI may produce first-, second-, or third-degree burns due to metal or wire contact with skin, creating a closed-loop conduction system.
- The shape and size of the burns are determined by the conductor causing the injury (e.g. circular burns under ECG electrodes).

### FLUOROSCOPY

- Fluoroscopy, especially when performed repeatedly in patients with cardiovascular disease, may result in radiation-induced injury (radiodermatitis).
- This radiodermatitis may be acute, but with time continued changes can develop, e.g. hair loss, desquamation, permanent erythema, and ulceration (Fig. 74.4).

**HEAT SOURCES REPORTED TO CAUSE ERYTHEMA AB IGNE**

- Heating pads
- Hot water bottles
- Electric stove/heater
- Open fires
- Coal stoves
- Peat fires
- Wood stoves
- Sauna belt
- Prolonged hot bathing
- Steam radiators
- Heated car seats
- Heated reclining chairs
- Heating blanket
- Hot bricks
- Infrared lamps
- Microwave popcorn
- Laptop computer*

**Anterior thighs >> abdomen*

**Table 74.2 Heat sources reported to cause erythema ab igne.** *Courtesy, Michael L. Smith, MD.*

## Cutaneous Injury Due to Cold Exposure

### Frostbite

- Can occur when the skin temperature drops below about −2°C (28°F).
- Tissue freezing, vasoconstriction, and inflammatory mediator release are key features of its pathophysiology.
- There are four categories of severity based on depth of tissue injury; these are only recognizable upon rewarming (Fig. 74.5).
- Symptomatically, early erythema, edema, and numbness are replaced by marked hyperemia and pain.
- **Rx:** rapid rewarming in a warm water bath is the cornerstone of treatment, followed by appropriate wound care.

### Pernio (Chilblains)

- An abnormal inflammatory response to cold, damp, non-freezing conditions.

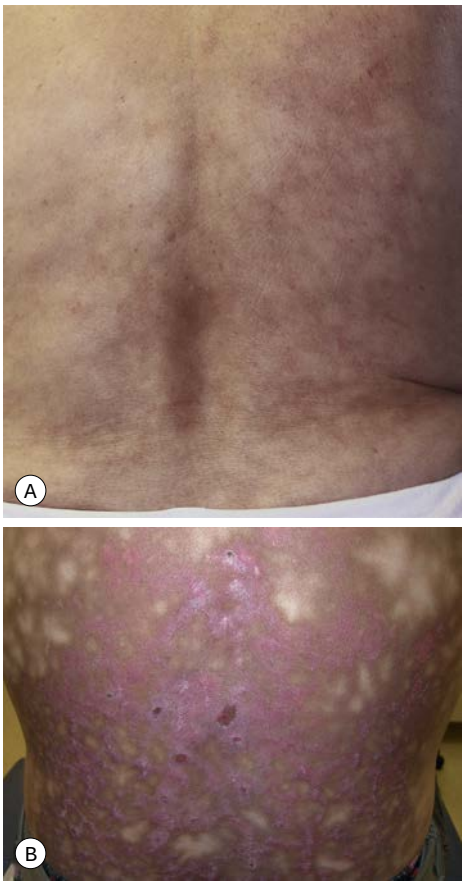


**Fig. 74.3 Erythema ab igne. A** Early phase with pink reticulated patches on the back, resulting from overuse of a heating blanket. **B** Later phase with large area of reticulated hyperpigmentation and superimposed pink keratotic plaques centrally. *A, Courtesy, Karynne O. Duncan, MD; B, Courtesy, Peter Klein, MD.*

- Classically presents with single or multiple erythematous to blue-violet macules, papules, or nodules distributed symmetrically on distal toes and fingers (Fig. 74.6), and less often on the remainder of the foot or hand, nose and ears.
- In severe cases, blistering and ulceration may be seen.
- Patients describe pruritus, burning, or pain; histopathology demonstrates a perivascular and perieccrine lymphohistiocytic infiltrate.
- Lesions typically resolve in 1–3 weeks but can take much longer or become chronic in elderly patients with venous insufficiency.



**Fig. 74.4 Fluoroscopy-induced radiation dermatitis.** The left upper back is a characteristic location for patients who have undergone attempts at coronary artery revascularization (e.g. angioplasty, stent placement). *Courtesy, Jeffrey P. Callen, MD.*

- **DDx:** chilblain lupus; frostbite; lupus pernio (a variant of sarcoidosis involving mainly the nose and ears) (Table 74.3).
- **Rx:** adequate clothing; avoidance of cold, damp conditions; keeping feet dry; avoidance of smoking; and use of nifedipine in recalcitrant cases.

## Cutaneous Injury Due to Chemical Exposure

### Chemical Hair Discoloration

- May be a voluntary cosmetic change or the result of chemical or metal exposure (Table 74.4).
- Most hair discoloration normalizes over time upon discontinuation of the offending exposure.
- Numerous anecdotal treatment remedies have been described, e.g. hot oil, hydrogen peroxide, and various shampoos (e.g. alkaline or EDTA-based).

### Chronic Arsenical Dermatoses

- Chronic arsenic exposure most often occurs via contaminated drinking water or occupational exposure; long latency period (up to 40 years).
- Chronic arsenicism is characterized by mottled hyperpigmentation with areas of hypopigmentation; arsenical keratoses on the palms and soles (Fig. 74.7); multiple non-melanoma skin cancers (particularly Bowen disease); peripheral neuropathy and internal malignancies (e.g. bladder, lung, liver).



**Fig. 74.5 Frostbite. A** Erythema, edema, and hemorrhage are seen on the fingertips in a ***first-degree frostbite (frostnip)***; full recovery is expected, with only mild desquamation. **B** Bullae filled with clear fluid on the distal plantar surfaces in a ***second-degree frostbite***; many such patients develop long-term sensory neuropathies. In ***third-degree frostbite*** there is full-thickness dermal loss with hemorrhagic bullae or waxy, dry, mummified skin. In ***fourth-degree frostbite*** there is full-thickness loss of the entire part, with skin, muscle, tendon, and bone damage; amputation may occur. *A, Courtesy, Michael L. Smith, MD; B, Courtesy, Timothy Givens, MD.*



**Fig. 74.6 Pernio. A** Distal erythema of multiple toes with some edema in a symmetric pattern. **B** Erythematous papules and plaques of the distal fingers with scaling and an erosion. *Courtesy, Kalman Watsky, MD.*

## Cutaneous Findings Resulting from Toxic and Heavy Metal Exposure

- Various toxic and heavy metals are known to cause irritant and/or allergic contact dermatitis, including the following (Table 74.5):
  - ***Beryllium*** is a metal known to cause dermatitis and sarcoidosis-like granulomas of the skin and lung
  - ***Gold***, as an elemental salt, can cause a variety of cutaneous eruptions (Table 74.6)



**Fig. 74.7 Cutaneous manifestations of chronic arsenicism. A, B** Arsenical keratoses on the plantar and palmar surface. *A, Courtesy, YDRSC; B, Courtesy, Jeffrey P. Callen, MD.*

| DIFFERENTIAL DIAGNOSIS AND EVALUATION OF SKIN LESIONS INDUCED BY NON-FREEZING COLD EXPOSURE | | |
|---|---|---|
| **Disorder** | **Features** | **Possible associated conditions** |
| Acrocyanosis | Red to purple discoloration<br>Hands and feet<br>Painless | Erythromelalgia<br>Cryoproteins<br>Anorexia nervosa |
| Pernio (chilblains) (see Fig. 74.6) | Erythrocyanotic<br>Symmetric distribution of painful macules and papules, mostly on digits; scaling develops as lesions heal | Low body mass index<br>SARS-CoV-2 infection<br>Hematologic disorders (e.g. paraproteinemia)<br>Viral hepatitis |
| Raynaud phenomenon (see Ch. 35) | Well-demarcated pallor, followed by blue, then red discoloration; painful<br>Idiopathic form (common) – no nail-fold capillary changes; pulp ulcerations rare | AI-CTD (especially systemic sclerosis)<br>Blood dyscrasias (e.g. polycythemia vera)<br>Drugs (e.g. beta-blockers, bleomycin)<br>Trauma |
| Livedo reticularis (see Ch. 87) | Bluish, broad reticulated patches corresponding to venous plexus<br>May be idiopathic | Vascular occlusive diseases (e.g. severe atherosclerosis)<br>AI-CTD (e.g. lupus erythematosus)<br>Hematologic disorders (e.g. antiphospholipid syndrome)<br>Infections (e.g. hepatitis C infection)<br>Medications (e.g. amantadine) |
| Cold panniculitis (see Ch. 83) | Erythematous indurated plaques, most often on cheeks of children or thighs in equestrians | |
| Cold urticaria (see Ch. 14) | Cold-induced wheals | Cryoproteins<br>Familial cold autoinflammatory syndrome |
| Chilblain lupus (see Ch. 33) | Cold-induced acral lesions, similar to pernio<br>Histopathologic features of LE<br>Coexistent LE | |
| Retiform purpura due to cryoproteins*<br>• Cryoglobulins<br>• Cryofibrinogen**<br>• Cold agglutinins or hemolysins** | Favors acral sites (see Fig. 18.3)<br>Cold serum protein precipitate<br>Cold plasma protein precipitate<br>RBCs agglutinate or lyse in cold<br>Paroxysmal hemoglobinuria if RBC lysis | Type I (monoclonal) cryoglobulinemia due to plasma cell dyscrasias<br>Lymphoproliferative disorders (e.g. Waldenström macroglobulinemia)<br>Infections (e.g. hepatitis C infection)<br>Malignancies (e.g. non-Hodgkin lymphoma)<br>Infections (e.g. with *Mycoplasma*, EBV, CMV)<br>Lymphoproliferative disorders |

**Table 74.3 Differential diagnosis and evaluation of skin lesions induced by non-freezing cold exposure.** *Continued*

| DIFFERENTIAL DIAGNOSIS AND EVALUATION OF SKIN LESIONS INDUCED BY NON-FREEZING COLD EXPOSURE |
|---|
| **Evaluation considerations** |
| • CBC with platelets and differential<br>• ANA with profile<br>• Hypercoagulable evaluation (see Table 18.5)<br>• Cryoprotein analysis<br>• Serum protein electrophoresis and immunofixation electrophoresis<br>• Lesional biopsy |
| **Acrocyanosis, Raynaud phenomenon, livedo reticularis, and cold urticaria can also be observed in association with cryoproteins.*<br>***Rarely cause cold-related occlusion syndromes.* |

**Table 74.3** *Continued* **Differential diagnosis and evaluation of skin lesions induced by non-freezing cold exposure.** *Courtesy, Michael L. Smith, MD.*

| CAUSES OF UNINTENTIONAL HAIR DISCOLORATION | | |
|---|---|---|
| **Green (chlorotrichosis)** | **Yellow, orange, or golden** | **Purple** |
| Copper (swimming pools)<br>Selenium sulfide<br>Tar shampoo<br>Cobalt<br>Chromium<br>Nickel<br>Yellow mercuric oxide | Tar shampoo<br>Anthralin<br>Minoxidil<br>Copper (cosmetic plant extracts, metallic eyeglass frames) | Alkalinized anthralin |

**Table 74.4 Causes of unintentional hair discoloration.** *Courtesy, Michael L. Smith, MD.*

  - ***Mercury***, in elemental, inorganic, or organic forms, may cause acrodynia, tattoo reaction (cinnabar), granulomas, exanthems, cutaneous hyperpigmentation, allergic and irritant contact dermatitis, baboon syndrome
  - Cutaneous contact with ***silver*** may result in argyria, irritant contact dermatitis, or skin ulceration
  - ***Thallium***, in its soluble form, may cause alopecia, acneiform papules, hyperkeratotic plaques on hands and feet, and Mees' lines in nails
- For most cutaneous exposures to these toxic and heavy metals, effective treatment requires prompt soap and/or water washing; an exception is lithium, in which washing is contraindicated and gentle brushing off is preferred.

## Cutaneous Findings of Frictional and Traumatic Injury to the Skin

### Corns and Calluses

- Keratotic lesions resulting from repeated trauma and the subsequent cycle of friction, pressure, and thickening (Fig. 74.8).
- Contributing factors include ill-fitting footwear, bony protuberances, abnormal biomechanical foot function, and specific activities that involve repetitive activity.
- *Hard corns* are usually located on the dorsal aspects of the toes, while *soft corns* are typically found in the interdigital web spaces.
- Corns and calluses can often be mistaken for verrucae; gentle paring of the lesions with a blade and noticing the lesion's effect on dermatoglyphics can help distinguish between these three entities (Table 74.7).
- Treatment involves both symptomatic relief and correction of the underlying biomechanical problem:
  - Symptomatic relief:
    1. Paring of the callosity with removal of the corn's central core may bring immediate relief of discomfort, followed by periodic foot filing
    2. Application of keratolytic agents (e.g. 40% salicylic acid pads; 6% salicylic acid, 10–40% urea, or 12% ammonium lactate creams), from daily to twice weekly, depending on strength

| SELECTED TOXIC AND HEAVY METALS KNOWN TO CAUSE CONTACT DERMATITIS | |
|---|---|
| **Irritant contact dermatitis** | **Allergic contact dermatitis** |
| • Cobalt salts<br>• Copper salts<br>• Lithium<br>• Mercury, organic and inorganic<br>• Selenium | • Chromium<br>• Cobalt<br>• Gold<br>• Mercury, organic<br>• Nickel |

**Table 74.5 Selected toxic and heavy metals known to cause contact dermatitis.**

| CUTANEOUS ERUPTIONS ASSOCIATED WITH GOLD EXPOSURE (AS AN ELEMENTAL SALT) | |
|---|---|
| **Most common** | **Less common** |
| • Lichen planus, lichenoid drug eruption<br>• Allergic contact dermatitis<br>• Pityriasis rosea-like eruptions<br>• Erosive stomatitis | • Chrysiasis<br>• Erythema nodosum<br>• Erythema multiforme, toxic epidermal necrolysis<br>• Exfoliative dermatitis |

**Table 74.6 Cutaneous eruptions associated with gold exposure (as an elemental salt).**



**Fig. 74.8 Callus plus hard corns.** Calluses are broad based and have increased skin markings while corns are round, more sharply defined papules with a central translucency and an interruption in dermatoglyphics. The skin overlying the second and third metatarsal heads is a common location for such lesions. *Courtesy, Jean L. Bolognia, MD.*

3. Soft cushions (e.g. silicone sheet, sheep skin) and donut-shaped corn pads

– *Biomechanical* correction – properly fitted footwear and use of appropriate orthotics
– *Recalcitrant* lesions – consider X-ray to look for exostoses and referral to orthopedic or podiatric surgeon

## Black Heel (Talon Noir) and Black Palm

• Black macules on the palms or soles due to hemoglobin within the thickened stratum corneum (Fig. 74.9).
• Secondary to impact trauma and resolves with paring or spontaneously with time.
• Harmless, but because of its dark color must be differentiated from acral cutaneous melanoma (does not resolve with gentle paring).

## Chondrodermatitis Nodularis Helicis (CNH)

• A tender, inflammatory process of the ear that primarily affects patients older than 50 years of age; initiated by ischemia-related inflammation of the cartilage.
• Presents with a skin-colored to erythematous, dome-shaped papule or nodule with a central crust or keratin-filled crater; often exquisitely tender (Fig. 74.10).
• Most often a unilateral process affecting the most protuberant portion of the ear, primarily the upper helical rim or the middle to lower antihelical rim.
• **DDx:** SCC, KA, BCC, AK, cutaneous horn, weathering nodule, verruca, calcinosis cutis, gouty tophus; often distinguished via biopsy.
• **Rx:** mostly anecdotal and not standardized (e.g. intralesional CS, topical antibiotics, specially designed CNH pillows for sleeping, cryosurgery, electrodesiccation and curettage, $CO_2$ laser ablation); full-thickness excision is the most definitive and favored treatment for particularly bothersome lesions.

## Acanthoma Fissuratum

• Results from ill-fitting eyeglass frames that create a frictional injury to the postauricular sulcus or the upper lateral nose (Fig. 74.11).

| DISTINGUISHING FEATURES OF VERRUCAE, CORNS AND CALLUSES | | |
|---|---|---|
| **Lesion** | **Paring revelations** | **Effect on dermatoglyphics** |
| Verruca | Thrombosed capillaries, multiple bleeding points | Interrupted |
| Corn | Central translucent, whitish-yellow core | Interrupted |
| Callus | Layers of yellowish keratin | Accentuated |

**Table 74.7 Distinguishing features of verrucae, corns, and calluses.**



**Fig. 74.9 Black heel (talon noir) and black palm.** This black color is due to hemoglobin within the thickened stratum corneum of palmar skin. *Courtesy, Jean L. Bolognia, MD.*

- Presents as a firm or sometimes soft, skin-colored to erythematous nodule or plaque with a central vertical groove or fissure; occasionally tenderness, serous discharge, or slight hyperkeratosis.
- **DDx:** BCC, SCC, chronic dermatitis or benign acanthoma; biopsy is occasionally necessary to exclude a non-melanoma skin cancer.
- **Rx:** adjust or replace the offending eyeglasses.

### Weathering Nodules of the Ears

- Multiple, bilateral, firm (feels like cartilage), asymptomatic, whitish, 2- to 3-mm papules located along the inner rim of the helices in older males >> females (Fig. 74.12).
- Associated consistently with a history of significant sun exposure and actinic damage.
- **DDx:** CNH, gouty tophi, calcinosis cutis, elastotic nodules, granuloma annulare.
- **Rx:** not necessary.

## Sports-Related Dermatoses

- Participation in sports is often associated with a number of cutaneous injuries, dermatoses, or infections, related to acute and chronic mechanical trauma (Tables 74.8 and 74.9; Figs 74.13–74.16).

For further information see Ch. 88 from *Dermatology, Fourth Edition*.

**For additional online figures and tables visit www.expertconsult.com**







**Fig. 74.10 Chondrodermatitis nodularis helicis (CNH). A** Tender, erythematous papulonodule with central scale on the superior helix of an older woman. This represented the site most susceptible to pressure-induced ischemia. **B** Tender, erythematous papulonodule with central scale-crust on the mid antihelix of an older woman. *A, Courtesy, Kalman Watsky, MD; B, Courtesy, Harvey Lui, MD.*



**Fig. 74.12 Weathering nodules.** Multiple asymptomatic, small, whitish papules along the helix of an older man with photodamage. *Courtesy, Jean L. Bolognia, MD.*



**Fig. 74.11 Acanthoma fissuratum.** Keratotic plaque of the postauricular sulcus; note the linear fissure. *Courtesy, Luis Requena, MD.*

| SELECTED FRICTIONAL AND MECHANICAL DERMATOSES IN ATHLETES | | | |
|---|---|---|---|
| **Condition** | **Clinical features** | **Sports** | **Etiology/pathogenesis**<br>**Prevention/treatment** |
| Subungual hematoma* | Red/maroon, purple or black discoloration beneath all or part of the nail (see Ch. 58 and Fig. 74.14) | Running<br>Tennis | Sudden impact of toe tip with end of shoe<br>Enlarged shoe toe box with proper arch and metatarsal support; drainage of hematoma may be necessary |
| Jogger's nipple | Pain, erythema, fissuring, occasional bleeding | Running | Repeated friction of rough shirt fabric<br>Women: jogging bra<br>Men: taping, lubrication, semisynthetic or silk shirt |
| Tennis toe | Toe tip callus, nail thickening, subungual hyperkeratosis (see Fig. 74.15) | Tennis<br>Running | Repeated trauma of longest toe against inside of toe box<br>Proper shoe fit, enlarged toe box, improved arch support |
| Fibrotic knots (e.g. surfer's nodules) | Thick fibrotic nodules on knees, knuckles, dorsal feet, and anterior lower ribs (surfers) | Surfing, boxing, football, marbles, yoga, video game playing | Chronic pressure over bony prominences<br>Position change, padding |

**Table 74.8 Selected frictional and mechanical dermatoses in athletes.** *Courtesy, Michael L. Smith, MD.*

| CUTANEOUS INFECTIONS IN ATHLETES |
|---|
| **Bacterial** |
| • Impetigo (see Fig. 61.2)<br>• Folliculitis (see Ch. 31)<br>• Hot tub folliculitis (see Fig. 31.3)<br>• *Pseudomonas* hot-foot syndrome (see Fig. 61.16)<br>• Furuncles (boils)<br>• Erythrasma (see Fig. 13.2 and/or Fig. 61.10)<br>• Pitted keratolysis ("toxic sock syndrome") (see Fig. 61.11)<br>• Otitis externa (swimmer's ear) |
| **Mycobacterial** |
| • Swimming pool granuloma (see Fig. 62.17) |
| **Viral** |
| • Verruca vulgaris (warts) (see Ch. 66)<br>• Herpes simplex viral infection (herpes gladiatorum) (see Fig. 67.5)<br>• Molluscum contagiosum (see Fig. 68.8) |
| **Fungal (see Ch. 64)** |
| • Tinea pedis (athlete's foot)<br>• Tinea cruris (jock itch)<br>• Tinea corporis (tinea gladiatorum) (see Fig. 74.16) |
| **Other** |
| • Seabather's eruption (sea lice) (see Fig. 72.9)<br>• Swimmer's itch (see Fig. 70.14) |

**Table 74.9 Cutaneous infections in athletes.** *Courtesy, Michael L. Smith, MD.*



**Fig. 74.13 Multinodular deformity of the external ear, often referred to as "cauliflower ear," in a jiu-jitsu fighter.** It is the result of repeated auricular hematomas. *Courtesy, Kalman Watsky, MD.*



**Fig. 74.14 Subungual hematoma.** A common sports-related (e.g. tennis, running, basketball) injury due to the sudden impact of the toe tip with the end of the shoe. Note the subungual dark purplish discoloration, which may be misdiagnosed as melanoma. Clues to the diagnosis of subungual hematoma include: a normal-appearing proximal nail plate upon gentle retraction of the cuticle (arrow); characteristic dermoscopic features (e.g. red-brown to purplish-black round globules); and determination that the discoloration grows out distally. *Courtesy, Jean L. Bolognia, MD.*



**Fig. 74.15 Chronic "tennis toe."** Chronic and repeated trauma of the longer second toe against the end of the tennis shoe toe box during sudden stops creates the distal callus formation and nail plate thickening known as "tennis toe." *Courtesy, Michael L. Smith, MD.*



**Fig. 74.16 Tinea gladiatorum.** Erythematous, scaly, annular plaque with an active border on the dorsal hand of this high school wrestler. *Courtesy, Karynne O. Duncan, MD.*

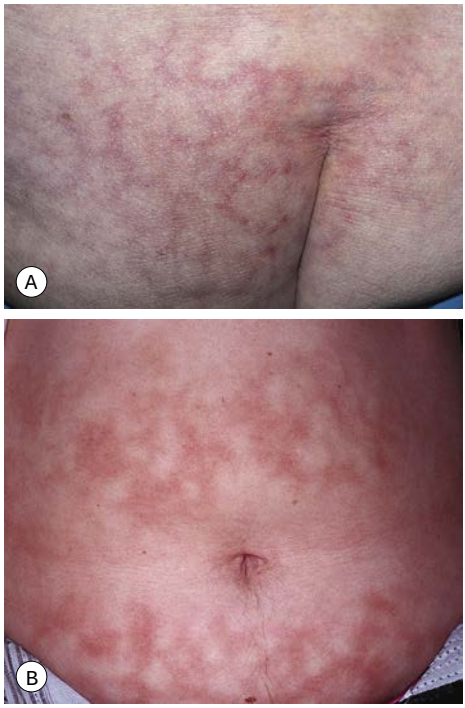


**eFig. 74.1 Erythema ab igne. A** Reticulated erythema of the buttocks that corresponds to the dermal venous plexus and is due to chronic exposure to heat. **B** Early phase with pink reticulated patches predominating over reticulated hyperpigmentation. *A, Courtesy, Kalman Watsky, MD; B, Courtesy, Jeffrey P. Callen, MD.*




**eFig. 74.2 Pernio (chilblains). A, B** Violaceous macules and patches, primarily on the toes but also on the plantar surface of the foot; note the associated scaling (**A**). **C, D** Recurrent, more severe disease with thin violaceous papules and plaques, hemorrhage, desquamation, scarring, and postinflammatory dyspigmentation. **E** A dense perivascular and peri-eccrine lymphocytic infiltrate. Detail of predominantly lymphocytic perivascular infiltrate without atypical features (inset). Note the thickened stratum corneum characteristic of an acral site. *A, Courtesy, Jean L. Bolognia, MD; B–D, Courtesy, Kalman Watsky, MD; E, Courtesy, Lorenzo Cerroni, MD.*



**eFig. 74.3 Electrical burn.** It is characterized by erythema, edema, bulla formation and sloughing of the necrotic epidermis. *Courtesy, Timothy Givens, MD.*



**eFig. 74.4 Cutaneous manifestations of chronic arsenicism.** Guttate hypopigmentation superimposed on hyperpigmentation resembles "raindrops on a dusty road." *Courtesy, John Steinbaugh, MD.*



**eFig. 74.5 Toe tip callus due to a hammer toe deformity.** There is also a small central hemorrhagic crust and subungual hyperkeratosis of the third toe. *Courtesy, Kalman Watsky, MD.*



**eFig. 74.6 Hammer toes with callus and early corn formation overlying the interphalangeal joints.** The changes are most pronounced on the second toes bilaterally. *Courtesy, Kalman Watsky, MD.*

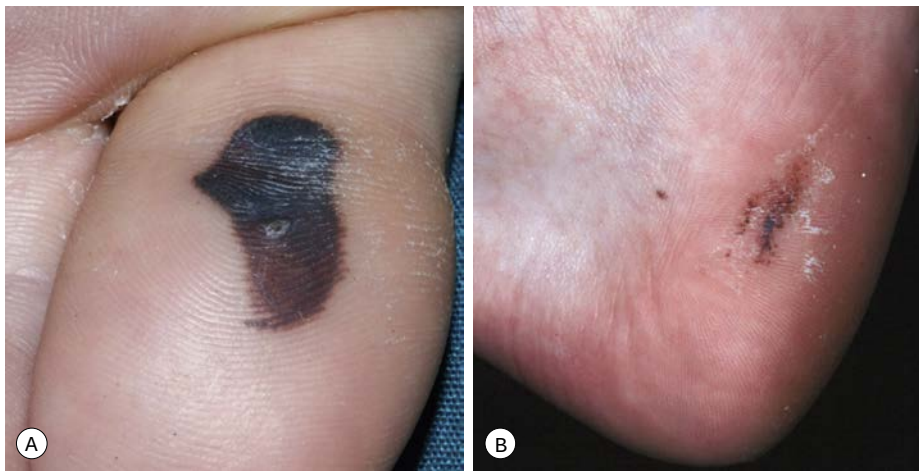


**eFig. 74.7 Black heel (talon noir) and palm. A, B** This black color is due to hemoglobin within the thickened stratum corneum of plantar skin. *A, Courtesy, Julie V. Schaffer, MD; B, Courtesy, Jeffrey P. Callen, MD.*

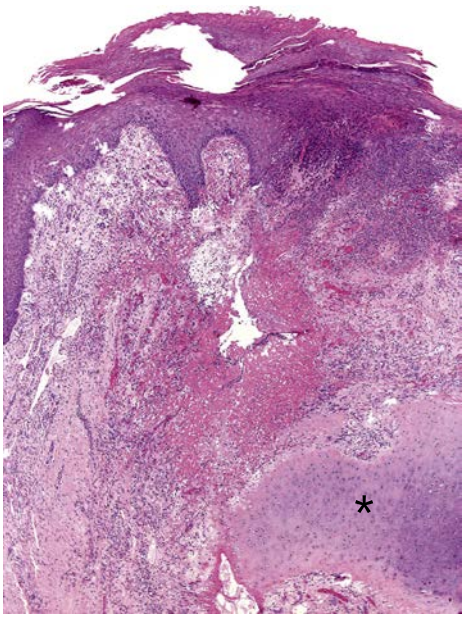


**eFig. 74.8 Chondrodermatitis nodularis (anti)helicis.** Central hyperkeratosis with scale-crust, epithelial hyperplasia, chronic inflammation, hemorrhage, fibrosis, granulation tissue, and degenerated cartilage (*) are seen on histopathologic examination. *Courtesy, Lorenzo Cerroni, MD.*



**eFig. 74.10 Piezogenic papules.** Yellowish outpouchings on the heel represent herniation of subcutaneous fat through the plantar fascia in this sometimes painful condition that can be seen in distance runners, figure skaters, and with other high impact sports. *Courtesy, YDRSC.*



**eFig. 74.9 Acanthoma fissuratum.** Thin pink plaque with scale of the postauricular sulcus. Note the linear fissure (arrow). *Courtesy, Mary Beth Cole, MD, and Michael L. Smith, MD.*

| RISK FACTORS FOR HEAT-RELATED ILLNESS | |
|---|---|
| • Occupational exposure | • Age (elderly, young child) |
| • Poverty | • Insufficient acclimatization |
| • Alcoholism, mental illness, dementia | • Obesity |
| • Medications (anticholinergics, phenothiazines, diuretics) | |
| **Medical conditions** | |
| • Excessive fluid loss (e.g. diarrhea, uncontrolled diabetes mellitus)<br>• Suboptimal sweating (e.g. ectodermal dysplasias)<br>• Excessive sweating<br>• Inadequate fluid intake (see above)<br>• Decreased thirst (e.g. cystic fibrosis)<br>• Abnormal thermoregulation (prior heat illness, malnutrition) | |

**eTable 74.1 Risk factors for heat-related illness.** *Courtesy, Michael L. Smith, MD.*

| RISK FACTORS FOR BURNS DURING MAGNETIC RESONANCE IMAGING | |
|---|---|
| • ECG leads<br>• Monitoring cables<br>• Pulse oximeter<br>• Pins in halo fixation device<br>• Transdermal patches | • Metallic body piercing jewelry<br>• Tattoos<br>• Extremity skin-to-skin contact<br>• Clothing with metal threads |

**eTable 74.2 Risk factors for burns during magnetic resonance imaging.** *Courtesy, Michael L. Smith, MD.*

| AIRBAG INJURIES TO SKIN | | |
|---|---|---|
| **Type** | **Frequency** | **Clinical features** |
| Abrasions/friction burns | 65% | Patches of erythema or ecchymosis, typically with superficial erosion |
| Contusion | 40% | Ecchymosis |
| Lacerations | 20% | Variable severity |
| Thermal burns | 8% | First- and second-degree most common |
| | | Localized full-thickness burn may result from metallic accessories or melted clothing |
| | | Face and forearms, followed by hands, chest |
| Chemical burns | ? | Painful, superficial, violaceous erythema and edema |
| | | Partial- to full-thickness, often in splash pattern |
| Irritant dermatitis | ? | Erythema and edema of upper chest, arms, face |
| | | Burning or stinging sensation |
| | | Desquamation and postinflammatory hyperpigmentation common |

**eTable 74.3 Airbag injuries to the skin.** *Courtesy, Michael L. Smith, MD.*

| FOUR STAGES OF FROSTBITE | | |
|---|---|---|
| **Phase** | **Physiologic events** | **Clinical findings** |
| I (cooling) | • Cyclic vasoconstriction and vasodilation<br>• Extracellular ice formation (–2°C, 28°F)<br>• Intracellular ice crystal formation (if rapid freeze of >10°C or 18°F/min)<br>• Intravascular ice formation leads to erythrocyte sludging, vessel occlusion | Cool extremity<br>Blanched appearance<br>Numbness<br>Hard, woody texture |
| II (thawing and rewarming) | • Ice melts<br>• Dehydrated cells start to swell<br>• Loss of integrity of vessel walls, creating edema<br>• Vascular tone is compromised, leading to vasodilation<br>• Inflammatory mediator release leads to aggregation of platelets and leukocytes, causing thrombosis | Erythematous to violaceous color<br>Intense pain<br>Blisters form |
| III (extension of injury) | • Thromboxane A2 levels increase<br>• Platelet and leukocyte aggregation extends into bordering tissue, creating vascular compromise | Blisters rupture |
| IV (resolution) | • Tissue either re-epithelializes or desiccates and mummifies<br>• Vasomotor instability may persist indefinitely | Healing or amputation |

**eTable 74.4 Four stages of frostbite.** *Courtesy, Michael L. Smith, MD.*

| CLINICAL FEATURES OF ACUTE AND CHRONIC ARSENIC POISONING |
|---|
| **Acute** |
| **Skin** |
| • Flushing, erythema, facial edema, acrodynia, urticaria<br>• Loss of hair and nails<br>• Remaining nails show Mees' lines after 8 weeks |
| **Gastrointestinal** |
| • Nausea, vomiting, severe abdominal pain, profuse watery diarrhea, malabsorption |
| **Neurologic** |
| • Acute peripheral neuropathy<br>• May progress to Guillain–Barré-like ascending paralysis |
| **Other** |
| • Pancytopenia, metallic breath odor, cardiac arrhythmias, renal failure, respiratory failure |
| **Chronic** |
| **Skin** |
| • Hyperpigmentation of axillae, groin, nipples, palms, soles and pressure points, with superimposed guttate hypopigmentation ("raindrops on a dusty road")<br>• Alopecia<br>• Arsenical keratoses – precancerous papules on palms and soles<br>– Symmetric, yellow, punctate, corn-like papules measuring 2–10 mm<br>– Favor thenar and hypothenar eminences, distal palms, lateral fingers, dorsal aspect of IP joints, weight-bearing plantar surfaces<br>– Rarely on trunk, proximal extremities, eyelids, genitalia<br>– May coalesce to plaques<br>• Blackfoot disease (vascular occlusive disease with blackening of skin) |
| **Other** |
| • Nasal septum perforation<br>• Peripheral neuropathy<br>• Bone marrow hypoplasia<br>• Diarrhea<br>• Hepatomegaly, hepatic fibrosis<br>• Obstructive or restrictive lung disease<br>• Diabetes mellitus |
| **Malignancies** |
| • Bowen disease<br>– Any skin surface<br>– If no HPV, occurrence on sun-protected skin might suggest arsenic exposure<br>– Skin-colored to erythematous papules and plaques that become keratotic<br>– Scale-crust removal leaves red, moist, papillomatous base<br>– Multiple lesions common<br>– Invasive squamous cell carcinoma develops in 5–20%<br>• Squamous cell carcinoma<br>– Arising in arsenical keratosis or Bowen disease, has more aggressive behavior<br>– Metastasis in one-third<br>• Basal cell carcinoma<br>– Multiple, superficial, may resemble Bowen disease<br>• Extracutaneous malignancies<br>– Genitourinary, especially bladder<br>– Lung<br>• Liver |

**eTable 74.5 Clinical features of acute and chronic arsenic poisoning.** IP, interphalangeal.
*Courtesy, Michael L. Smith, MD.*

| MUCOCUTANEOUS FINDINGS ASSOCIATED WITH EXPOSURE TO TOXIC AND HEAVY METALS | | | | | |
|---|---|---|---|---|---|
| **Metal** | **Form** | **Cutaneous health hazards** | **Treatment and protection** | **IDLH*** | **Cancer risk** |
| Aluminum | Alum, sulfates | Irritant contact dermatitis | Wash off | – | – |
| Antimony | Metal | Irritant contact dermatitis | Soap wash immediately | 50 $mg/m^3$ | – |
| Arsenic | Inorganic | See eTable 74.5 | Avoidance, chelation Soap and water wash immediately | Cancer: 5 $mg/m^3$ | Lung, bladder and skin cancer |
| | Arsine | Cold injury with arsine gas, including frostbite | See text | Cancer: 3 ppm | Lung cancer, lymphoma |
| Barium | Chloride, nitrate | Irritant contact dermatitis, burns | Water flush immediately | 50 $mg/m^3$ | – |
| Beryllium | Metal | Dermatitis, granulomas | – | Cancer: 4 $mg/m^3$ | Lung cancer |
| Bismuth | Telluride | Irritant contact dermatitis, black tongue | Soap wash immediately | – | – |
| Boron | Borates, oxide, tribromide, trifluoride | Erythema, irritant contact dermatitis, burns | Soap wash, water flush promptly | 25 ppm as trifluoride; 2000 $mg/m^3$ as oxide | – |
| Cesium | Hydrate, hydroxide | Irritant contact dermatitis, burns | Water flush immediately | – | – |
| Chromium | Hexavalent | Allergic and irritant contact dermatitis, skin ulceration, burns; systemic absorption can lead to renal failure, hepatic failure, anemia, coagulopathy | Water flush promptly | Cancer: 15 $mg/m^3$ as Cr VI | Lung cancer |
| Cobalt | Metal dust | Dermatitis, diffuse nodular fibrosis | Soap wash | 20 $mg/m^3$ | – |
| Copper | Metal dust | Dermatitis | Soap wash promptly | 100 $mg/m^3$ | – |

**eTable 74.6 Mucocutaneous findings associated with exposure to toxic and heavy metals.** *Continued*

| MUCOCUTANEOUS FINDINGS ASSOCIATED WITH EXPOSURE TO TOXIC AND HEAVY METALS | | | | | |
|---|---|---|---|---|---|
| **Metal** | **Form** | **Cutaneous health hazards** | **Treatment and protection** | **IDLH*** | **Cancer risk** |
| Gold | Elemental salts | Most common: lichen planus, lichenoid drug eruption, allergic contact dermatitis, eczematous dermatitis, PR-like eruption, pruritus, flushing, erosive stomatitis<br>Less common: chrysiasis, erythema nodosum, erythema multiforme, toxic epidermal necrolysis, exfoliative dermatitis | Avoid gold-laden liquor | – | – |
| Indium | Metal | Irritant and allergic contact dermatitis | Soap wash | – | – |
| Iron | Salts | Irritant contact dermatitis, mucosal irritation | Soap wash | – | – |
| Lead | Metal | Irritant contact dermatitis, gingival lead line | Soap wash promptly | 100 $mg/m^3$ | – |
| Lithium | Hydride | Irritant contact dermatitis, burns | Brush off gently, DO NOT WASH | 0.5 $mg/m^3$ | – |
| Magnesium | Carbonate | Irritant contact dermatitis | – | – | – |
| Manganese | Cyclopentadienyl tricarbonyl | Irritant contact dermatitis | Soap wash | – | – |
| Mercury | Elemental, inorganic, organic | Acrodynia, tattoo reaction (cinnabar), granulomas, exanthem, slate-gray discoloration, allergic and irritant contact dermatitis, baboon syndrome | Soap wash promptly<br>Avoid mercury-laden cosmetics | 10 $mg/m^3$ (elemental)<br>2 $mg/m^3$ (organic) | – |

**eTable 74.6** *Continued* **Mucocutaneous findings associated with exposure to toxic and heavy metals.** *Continued*

| MUCOCUTANEOUS FINDINGS ASSOCIATED WITH EXPOSURE TO TOXIC AND HEAVY METALS | | | | | |
|---|---|---|---|---|---|
| **Metal** | **Form** | **Cutaneous health hazards** | **Treatment and protection** | **IDLH*** | **Cancer risk** |
| Nickel | Elemental | Allergic contact dermatitis | Water wash immediately | 10 $mg/m^3$ | Lung and nasal cancer |
| Osmium | Tetroxide | Irritant contact dermatitis | Soap wash immediately | 1 $mg/m^3$ | – |
| Platinum | Metal | Irritant contact dermatitis | Soap wash | – | – |
| Polonium | $^{210}Po$ radionuclide | Erythema, alopecia; ulceration in higher doses<br>Triad of early emesis, hair loss, and bone marrow failure is characteristic of acute radiation sickness | Avoid ingestion; wash off | 0.1–0.3 GBq (fatal in 3–4 weeks) | |
| Selenium | Elemental, alloy | Irritant contact dermatitis, skin burns | Soap wash immediately | 1 $mg/m^3$ | – |
| Silver | Metal | Argyria, irritant contact dermatitis, skin ulceration | Water flush | 10 $mg/m^3$ | – |
| Tantalum | Metal | Irritant contact dermatitis | | 2500 $mg/m^3$ | |
| Tellurium | | Dermatitis, garlic smell of sweat | Soap wash promptly | 25 $mg/m^3$ | – |
| Thallium | Soluble | Alopecia, acneiform papules, keratotic plaques on hands and feet, Mees' lines, hyperpigmentation | Water wash promptly<br>Prussian blue, dialysis | 15 $mg/m^3$ | – |
| Tin | Metal, organic | Irritant contact dermatitis, skin burns, pruritus | Water flush immediately | 100 $mg/m^3$ (metal)<br>25 $mg/m^3$ (organic) | – |
| Tungsten | | Irritant contact dermatitis | Soap/water wash immediately | – | – |

**eTable 74.6** *Continued* **Mucocutaneous findings associated with exposure to toxic and heavy metals.** *Continued*

| MUCOCUTANEOUS FINDINGS ASSOCIATED WITH EXPOSURE TO TOXIC AND HEAVY METALS | | | | | |
|---|---|---|---|---|---|
| **Metal** | **Form** | **Cutaneous health hazards** | **Treatment and protection** | **IDLH*** | **Cancer risk** |
| Uranium | | Irritant contact dermatitis, skin burns | Soap/water wash immediately | 10 $mg/m^3$ | Lung cancer |
| Vanadium | Dust, fume | Irritant contact dermatitis, green tongue | Soap wash promptly | 35 $mg/m^3$ | – |
| Zinc | Chloride | Irritant contact dermatitis, skin burns (fixes tissue *in situ*), mucocutaneous hyperpigmentation | – | 50 $mg/m^3$ | – |
| Zirconium | | Irritant contact dermatitis, granulomas, blue-gray skin discoloration | Soap wash | 50 $mg/m^3$ | |

**Concentration posing immediate danger to life and health (IDLH). Since 1979, the National Institute for Occupational Safety and Health (NIOSH) has not allowed detectable levels of known carcinogens.*

**eTable 74.6** *Continued* **Mucocutaneous findings associated with exposure to toxic and heavy metals.** GBq, gigabecquerel; PR, pityriasis rosea. *Courtesy, Michael L. Smith, MD.*

| SENILE GLUTEAL DERMATOSIS |
| --- |
| • Synonyms: hyperkeratotic lichenified skin lesion of the gluteal region, grandfather's disease<br>• Risk factors: elderly, low body mass, prolonged sitting, men > women<br>• Etiology: pressure and friction<br>• Clinical features: gradual appearance of poorly defined, ridged brown plaques; ridges are horizontal and can be keratotic<br>• Locations: medial aspects of the mid to upper buttocks, upper gluteal cleft, over ischial tuberosities<br>• Distribution pattern: usually bilateral and there may be a triangular distribution pattern<br>• Symptoms: asymptomatic (~60%), pruritic (~35%), painful (<10%)<br>• DDx: anosacral amyloidosis, lichen simplex chronicus<br>• Treatment: relieve pressure via cushions |

**eTable 74.7 Senile gluteal dermatosis.**

| ENVIRONMENT-RELATED DISORDERS OF THE EXTERNAL EAR | | | | |
|---|---|---|---|---|
| **Disorder** | Chondrodermatitis nodularis helicis (and antihelicis) | Acanthoma fissuratum | Weathering nodules | Auricular hematoma |
| **Synonyms** | Chondrodermatitis nodularis chronica helicis, ear corn, chondrodermatitis nodularis chronica helicis et antihelicis | Granuloma fissuratum, spectacle frame acanthoma, eyeglass frame acanthoma | | Wrestler's ear, cauliflower ear |
| **Pathogenesis** | Precise etiology unknown, but contributing factors include local ischemia due to pressure (often affects most protruding portion of the ear), actinic damage, cold exposure, and trauma, leading to inflammation | Ill-fitting eyeglass frames create a frictional injury | Precise pathogenesis unknown, but presence of chronic photodamage suggests a role for UV light | A glancing blow or twisting movement against the anterolateral pinna avulses the anterior perichondrium from the underlying cartilage<br>Shearing forces rupture vessels that then bleed into the subperichondrial or intracartilaginous space |
| **Clinical features** | Usually seen in older adults<br>Men tend to develop lesions on the helix at an earlier age, while women often develop antihelix lesions<br>Skin-colored to erythematous, dome-shaped papules with central crusts or occasionally keratin-filled craters<br>Can be painful and tender | Firm, skin-colored to erythematous plaque or nodule on the upper portion of the postauricular sulcus or upper lateral nose, with a central vertical groove or fissure<br>Tenderness, a serous discharge, slight hyperkeratosis, or an inflammatory halo may be present | Occur primarily in men with skin phototypes I and II and evidence of chronic photodamage<br>Asymptomatic, 1–3 mm, white to skin-colored papules along the free margin of the helix<br>Usually bilateral and create a scalloped appearance to the helical rim | Most commonly occurs in wrestlers, boxers, rugby players, and piano movers<br>Painless to slightly tender swelling appears on the upper anterior aspect of the pinna in the scaphoid or triangular fossa; swelling can persist, especially if left untreated, becoming either firmer due to fibroneocartilage production or soft and cystic<br>Color varies from skin-colored to slightly bluish<br>Repeated injury produces the multinodular deformity known as cauliflower ear |

**eTable 74.8 Environment-related cutaneous disorders of the external ear.** *Continued*

| ENVIRONMENT-RELATED DISORDERS OF THE EXTERNAL EAR | | | | |
|---|---|---|---|---|
| **Pathology** | Well-circumscribed area of acanthosis, parakeratosis, and hypergranulosis; a central crater with epidermal disruption may be filled with a keratotic plug or dermal debris<br>The underlying dermis shows degenerative changes with fibrosis and variable lymphohistiocytic inflammation; the infiltrate extends into a thickened perichondrium | Irregular acanthosis, most marked at the lesion's periphery, with occasional pseudoepitheliomatous hyperplasia<br>The central depression may show epidermal thinning with compact orthohyperkeratosis and patchy areas of parakeratosis near the central groove<br>Dermal papillae exhibit dilated vessels and a moderately dense perivascular inflammatory infiltrate comprised of lymphocytes, histiocytes and plasma cells, with occasional neutrophils; slight fibrosis may be noted in the superficial and mid dermis | Fibrous tissue spur with cartilage metaplasia extending upward from disrupted perichondrium<br>No inflammation or epidermal disruption are noted | Hematoma plus fibrosis and foci of new cartilage formation<br>Older lesions may exhibit calcification and even ossification within the hematoma |
| **Differential diagnosis** | AK, SCC, BCC, cutaneous horn, verruca > KA, weathering nodule, calcinosis cutis, gouty tophi, reactive perforating collagenosis | BCC, SCC *in situ*, lichen simplex chronicus superimposed on seborrheic or allergic contact dermatitis > keloid | Gouty tophi, calcinosis cutis, CNH, elastotic nodules, amyloidosis, granuloma annulare | Auricular pseudocyst, relapsing polychondritis, epidermoid cyst |
| **Treatment** | Padding to relieve pressure, surgical excision, cryotherapy, corticosteroid injections, topical corticosteroids, laser ablation, soft tissue fillers, nitroglycerin gel and patches | Lesions usually clear within a few months of discontinuation, replacement, or proper adjustment of the offending spectacles<br>Excision can be considered for persistent lesions<br>Intralesional corticosteroids (case reports) | Treatment rarely required<br>Cryosurgery (case reports) | Evacuation of the hematoma and prevention of fluid reaccumulation via aspiration or incision and drainage (with or without cartilage removal) then splinting |

**eTable 74.8** *Continued* **Environment-related cutaneous disorders of the external ear.** Elastotic nodules of the ears are due to chronic photodamage and favor the antihelix. CNH, chondrodermatitis nodularis helicis.

| FRICTIONAL AND MECHANICAL DERMATOSES IN ATHLETES | | | | |
|---|---|---|---|---|
| **Condition** | **Clinical features** | **Sports** | **Etiology/pathogenesis** | **Prevention/treatment** |
| **Acute injury** | | | | |
| Friction blisters (see Ch. 27) | Bullae and superficial erosions | Any | Friction or tangential impact to foot while in warm moist shoes | Frequent drying of feet, lubrication, proper shoe fit, drain blisters/leave roof |
| Contusion | Ecchymosis | Any | Perpendicular mechanical trauma producing vascular damage | Padding |
| Subungual hematoma | | Running, tennis, basketball | Sudden impact of toe tip with end of shoe | Enlarged shoe toe box with proper arch and metatarsal support, drainage of hematoma may be needed |
| Black heel | See text | | | |
| Turf toe | Painful, erythematous, edematous hallux | Football, soccer | Acute dorsal and plantar tendonitis | Rest |
| Jogger's nipple | Pain, erythema, fissuring, occasional bleeding | Running | Repeated friction of rough shirt fabric | Women: jogging bra<br>Men: taping, lubrication, semisynthetic or silk shirt |
| **Chronic injury** | | | | |
| Callosities | See text | Many | | |
| Tennis toe | Toe tip callus, nail thickening, subungual hyperkeratosis | Tennis, running, ice hockey, skating | Repeated trauma of longest toe against inside of toe box | Proper shoe fit, enlarged toe box, improved arch support |
| Nail dystrophy | Onycholysis, hematoma, subungual hyperkeratosis, paronychia, onychocryptosis (ingrown nail) | Many | Repeated trauma to nails | Keeping nails trimmed |

**eTable 74.9 Frictional and mechanical dermatoses in athletes.** *Continued*

| FRICTIONAL AND MECHANICAL DERMATOSES IN ATHLETES | | | | |
|---|---|---|---|---|
| **Condition** | **Clinical features** | **Sports** | **Etiology/pathogenesis** | **Prevention/treatment** |
| Fibrotic nodules (e.g. surfer's knots) | Thick fibrotic nodules on knees, knuckles, dorsal feet | Surfing, boxing, football, marbles, cricket, baseball, ice hockey, skating | Chronic pressure over bony prominences | Padding, position change, prone rather than kneeling on surfboard |
| Skate bite | Painful inflammatory plaques or pseudonodules under the tongue of the skate | Ice hockey, figure skating | Pressure from a rigid skate tongue over the anterior ankle or dorsal foot | Padding under the skate tongue or improve pliability of the tongue |
| Piezogenic papules | Multiple asymptomatic to tender yellowish outpouchings on the medial and lateral aspects of the heels when standing | Distance running, high-impact sports, figure skating | Herniation of subcutaneous fat through small tears in plantar fascia | None known |
| Runner's rump | Small ecchymoses in upper gluteal cleft | Running | Constant friction with each stride | Lubrication |
| Swimmer's shoulder | Erythematous plaque on shoulder | Swimming | Friction of unshaven beard against the shoulder during the swim stroke | More frequent shaving |
| Alopecia and hypertrichosis | Transient alopecia on forearms followed by hypertrichosis | Gymnastics | Frictional alopecia, compensatory regrowth | |

**eTable 74.9** *Continued* **Frictional and mechanical dermatoses in athletes.** Acne mechanica, auricular pseudocyst (seen most often in rugby players) and auricular hematoma ("cauliflower ear") are additional mechanical dermatoses seen in athletes. *Courtesy, Michael L. Smith, MD.*

| CUTANEOUS INFECTIONS IN ATHLETES | | | | |
|---|---|---|---|---|
| **Condition** | **Common name** | **Clinical features** | **Organisms** | **Typical sport** |
| Impetigo | | Small vesicles to large bullae on glistening erythematous bases; honey-colored crusts | *Staphylococcus aureus*, β-hemolytic streptococci | Most sports |
| Folliculitis | | Erythematous follicular papules and pustules | *S. aureus* | Most sports |
| Hot tub folliculitis | | Markedly erythematous, edematous follicular papulopustules, few in number, often involving axillae, breasts, pubic area, and buttocks | *Pseudomonas aeruginosa* | Swimming; use of whirlpool, hot tub, or Jacuzzi |
| *Pseudomonas* hot-foot syndrome | | Tender nodules on soles | *P. aeruginosa* | Use of wading pool |
| Furuncles | Boils | Tender, warm, red nodules or abscesses on trunk or extremities | *S. aureus*, including MRSA | Football, wrestling, basketball, swimming |
| Erythrasma | | Reddish-brown dry patches in axillae, groin, or toe webs | *Corynebacterium minutissimum* | Most sports, especially with occlusive clothing |
| Pitted keratolysis | Toxic sock syndrome | Malodorous feet with 1–3 mm, punched-out, plantar erosions extending only through the stratum corneum of overhydrated skin | *Corynebacterium* spp., *Kytococcus* (*Micrococcus*) *sedentarius*, *Dermatophilus congolensis* | Running, tennis, basketball, ice hockey, skating |
| Otitis externa | Swimmer's ear | Pruritus may be followed by pain, discharge, tenderness of the pinna, sensation of fullness and reduced hearing | *P. aeruginosa* most common; also streptococci, diphtheroids and staphylococci | Swimming, diving (those with an atopic diathesis at risk) |

**eTable 74.10 Cutaneous infections in athletes.** *Continued*

| CUTANEOUS INFECTIONS IN ATHLETES | | | | |
|---|---|---|---|---|
| **Condition** | **Common name** | **Clinical features** | **Organisms** | **Typical sport** |
| Swimming pool granuloma | | Firm, acral, red papules | *Mycobacterium marinum* | Swimming |
| Verruca vulgaris | Warts | Verrucous, keratotic papules and plaques | Human papillomavirus | Any that use locker-room showers or public pools |
| Herpes simplex viral infection | Herpes gladiatorum | Clustered vesicles on erythematous bases at point of skin-to-skin contact | Herpes simplex virus | Wrestling |
| Molluscum contagiosum | | Shiny, umbilicated 2–3 mm papules at the skin contact site | Parapoxvirus | Wrestling, swimming |
| Tinea pedis | Athlete's foot | Maceration, scaling, pruritus in toe webs; diffuse plantar erythema and scale | *Trichophyton rubrum, T. mentagrophytes, Epidermophyton floccosum* | Any sport |
| Tinea cruris | Jock itch | Annular to polycyclic erythema with scaly, active borders; perifollicular papules or pustules; favors upper inner thighs | Same as tinea pedis | Any sport |
| Tinea corporis | Tinea gladiatorum | Except for location, the same as tinea cruris | *Trichophyton* spp. | Wrestling |
| Seabather's eruption | Sea lice | Pruritic papules on areas covered by bathing suit | *Edwardsiella lineata, Linuche unguiculata* | Salt water swimming |
| Swimmer's itch | Cercarial dermatitis | Pruritic erythematous papules on exposed skin | Avian schistosome cercaria | Fresh water pond and lake swimming and wading |

**eTable 74.10** *Continued* **Cutaneous infections in athletes.** *Courtesy, Michael L. Smith, MD.*

| DERMATOLOGIC CONDITIONS IN LIMB AMPUTEES | | | |
|---|---|---|---|
| **Physical/mechanical effects** | **Allergic contact dermatitis (most common allergens)** | **Infections** | **Exacerbation of pre-existing condition** |
| Pruritus<br>Sensitive and/or painful skin<br>Altered temperature sensation<br>Hyperhidrosis<br>Erythema<br>Callus and verrucous hyperplasia<br>Hypertrichosis<br>Edema<br>Blisters<br>Abrasions<br>Ulceration<br>Folliculitis (normal flora)<br>Inclusion cyst, milia | Para-phenylenediamine (PPD)<br>Formaldehyde<br>Epoxy resin<br>Mercapto mix<br>Fragrance mix | Group A β-hemolytic *Streptococcus*<br>• impetigo, cellulitis<br>*Staphylococcus aureus*<br>• impetigo, cellulitis, folliculitis<br>*S. epidermidis*<br>Dermatophytes<br>*Candida* spp. | Psoriasis<br>Eczema<br>Pyoderma gangrenosum |

**eTable 74.11 Dermatologic conditions in limb amputees.** Localized pemphigoid of the stump has also been reported. *Courtesy, Michael L. Smith, MD.*

| DERMATOSES CAUSED BY MUSICAL INSTRUMENTS | | | |
|---|---|---|---|
| **Condition (synonym)** | **Clinical features** | **Pathogenesis** | **Associated instruments** |
| Acne mechanica (fiddler's neck, clarinetist's cheilitis, flautist's chin) | Follicular papules and pustules, lichenification, hyperpigmentation | Repetitive friction and pressure, coupled with occlusion and moisture (sweat, saliva) | Violin, viola, clarinet, saxophone, flute |
| Cellist's chest | Sternal skin tenderness, erythema, edema, hyperpigmentation | Pressure and friction | Cello |
| Cellist's knee | Erythema, scale, callus, and hyperpigmentation of left medial knee | Friction callus | Cello |
| Finger calluses | Hyperkeratotic callosities on fingertip pads | Repetitive friction | All strings |
| Drummer's digit | Vesicle or erosion on the radial aspect of the left ring finger distal and middle phalanx, followed by callus formation | Friction from holding left drumstick in classical position | Drums |
| Garrod's pads (violinist's pads) | Calluses on dorsal aspect of proximal interphalangeal joints of left index and middle fingers | Repeated extension and flexion of extensor tendon over tightly flexed joint | Violin, viola |
| Guitar nipple | Unilateral mastitis with erythema, edema, pain | Pressure and friction of guitar sound box pressed against chest | Guitar |
| Paronychia, onycholysis, subungual hemorrhage | | Repeated trauma to nail apparatus | Piano, strings (especially playing pizzicato), harp, guitar |

**eTable 74.12 Dermatoses caused by musical instruments.** *Courtesy, Michael L. Smith, MD.*

| ALLERGIC CONTACT DERMATITIS ASSOCIATED WITH MUSICAL INSTRUMENTS | | |
|---|---|---|
| **Sensitizer/contactant** | **Skin distribution** | **Instrument** |
| Rosin/colophony (abietic acid) | Hands, face, neck | Violin, viola, cello, double bass |
| Rosewood | Lips, chin, cheek | Strings, reeds |
| Makassar ebony | Chin | Violin |
| Cocobolo wood | Lips | Recorder |
| African blackwood | Lips | Recorder, oboe |
| Nickel | Chin | Violin |
| | Fingers, hands | Cello, sitar |
| | Lips, chin | Flute, brass |
| Reed (perhaps only irritant) | Lips | Saxophone, clarinet |
| Propolis (bee glue) | Hands | Violin |
| Chromium | Hands | Harp, violin |
| Paraphenylenediamine | Chin | Violin, viola |

**eTable 74.13 Allergic contact dermatitis associated with musical instruments.** *Courtesy, Michael L. Smith, MD.*

# 75 Cutaneous Signs of Drug, Child, and Elder Abuse

## Drug Abuse

- The skin often displays evidence of injection and inhalation drug abuse.
- A broad spectrum of cutaneous findings can result from local and systemic effects of the drug itself, adulterants, or associated infectious agents (Tables 75.1 and 75.2; Figs 75.1–75.10).
- Skin and soft tissue infections as well as thrombophlebitis are the most common conditions for which drug addicts seek medical care and are hospitalized.

## Child Abuse

- Child abuse encompasses a broad spectrum of non-accidental maltreatment of children, including physical, emotional, and sexual abuse as well as neglect.
- Children with disabilities, behavioral problems, and stressful home situations (e.g. parental unemployment or substance use) are at increased risk of abuse, and serious injury is more frequent in boys.
- Cutaneous signs of physical abuse:
  - Unexplained bruises (Fig. 75.11), curvilinear or binding marks (e.g. produced by belts, ropes, or cords), buckle imprints, and burns (e.g. from cigarettes or scalding; Fig. 75.12)
  - Skin injuries in areas less prone to accidental trauma (e.g. ears, neck, trunk, buttocks, upper arms) or in infants who are not independently mobile
  - Delay between the injury and seeking medical care
- Physical signs are present in a small minority of sexually abused children; suggestive findings (in the absence of a plausible history of accidental injury) include acute laceration or bruising of genital/perianal tissues, complete transection of the posterior hymen, and scars of the perianal area or posterior fourchette.
- Anogenital warts in children may be perinatally acquired, transmitted during routine child care, autoinoculated from other sites, or acquired from sexual abuse; the latter is an uncommon etiology of anogenital warts in children <5 years of age.
- **DDx:** conditions that can mimic physical and sexual abuse in children are listed in Tables 75.3 and 75.4 (Fig. 75.13).
- **Rx:** guidelines for evaluation of suspected child abuse are available at http://pediatrics.aappublications.org/content/pediatrics/135/5/e1337.full.pdf (physical abuse) and http://pediatrics.aappublications.org/content/116/2/506.full.pdf (sexual abuse).



**Fig. 75.1 Injection sites ("skin tracks") in an intravenous drug user.** There is overlying hyperpigmentation and scarring of veins due to inflammation from repeated non-sterile injections as well as injections of irritating drugs and adulterants. *Courtesy, Mark Pittelkow, MD.*

| MUCOCUTANEOUS SIGNS OF DRUG ABUSE | |
|---|---|
| **Finding** | **Route(s) and example drugs** |
| **Sequelae of tissue injury** | |
| Skin tracks (Fig. 75.1) and skin popping scars (Fig. 75.2) | IV and SC/intradermal, respectively |
| Lymphedema | IV, SC |
| Ulcers | IV – cocaine, propoxyphene*<br>SC – barbiturates, pentazocine<br>Intra-arterial injection leading to ischemia |
| Retiform purpura (Fig. 75.3) with ulceration (associated with neutropenia) | Snorting/IV cocaine or smoking crack cocaine adulterated with levamisole |
| Sclerosis | SC – pentazocine (Fig. 75.4), barbiturates, cocaine |
| Hyperkeratosis ± linear or circular black plaques on palms/fingers; erosions or blisters on lips; madarosis | Smoking crack cocaine |
| Circumferential pigmented bands due to tourniquet | IV |
| Pseudoaneurysm (tender pulsatile mass with bruit) associated with petechiae/purpura ± reduced pulses; distal purpuric papules/papulopustules due to embolization (Fig. 75.5) | Intra-arterial injection in groin or an extremity |
| Pressure erythema, bullae (Fig. 75.8), and ulcers | Overdose with barbiturates or other sedatives |
| **Sequelae of CNS effects** | |
| Pruritus ± excoriations | Methamphetamine (dry, leathery skin), heroin (associated with flushing), cocaine (with chronic use) |
| Formication/delusions of parasitosis leading to skin picking (Fig. 75.7) and self-induced ulcers | Cocaine, methamphetamine |
| **Other skin findings** | |
| Granulomas (Fig. 75.6; onset may be delayed) | Injection of talc (e.g. in narcotic tablets) or starch |
| Hyperhidrosis | Amphetamines, LSD |
| Acne vulgaris | Anabolic steroids†, methamphetamine (especially acne excoriée), marijuana |
| Perinasal or perioral irritant dermatitis | Sniffing volatile solvents/inhalants |
| **Oral findings** | |
| Xerostomia | Amphetamines, heroin |
| Dental caries, gingivitis, tooth loss | Methamphetamine, heroin |

**Withdrawn from prescription drug market in 2010 in the United States and Europe.*
*†May also be associated with androgenetic alopecia, hirsutism, clitoral enlargement, testicular atrophy, and gynecomastia.*

**Table 75.1 Mucocutaneous signs of drug abuse.** Infections associated with drug abuse are presented in Table 75.2 A variety of cutaneous drug reactions can also develop, such as morbilliform or fixed drug eruptions, urticaria, small vessel vasculitis, and Stevens–Johnson syndrome/toxic epidermal necrolysis. LSD, lysergic acid diethylamide.

| SKIN INFECTIONS RELATED TO DRUG ABUSE | |
|---|---|
| **Finding** | **Route(s) and example drugs** |
| Abscesses and cellulitis (Fig. 75.9): *Staphylococcus aureus* > *Streptococcus* spp. > GNRs, anaerobes; often polymicrobial and associated with lymphangitis* | IV, SC, intradermal<br>• Adulterated (e.g. "black tar") heroin: *Clostridium* (including wound botulism from *C. botulinum*)<br>• Heroin or pentazocine: *Pseudomonas* spp. |
| Necrotizing fasciitis (Fig. 75.10; severe, disproportionate pain): usually polymicrobial, may include anaerobes | IV, SC |
| Disseminated candidiasis with pustular folliculitis | Injection of heroin (e.g. brown heroin in 1980s) |
| Zygomycosis (necrotic cellulitic plaque or abscess) | IV |
| Nasal verrucae in setting of nasal irritation | Snorting cocaine or heroin |
| Hepatitis C > B viral infection leading to cryoglobulinemic vasculitis (e.g. palpable purpura) | Needle/syringe sharing |

**May also be associated with osteomyelitis, septic arthritis, bacteremia, septic thrombophlebitis, and endocarditis (often tricuspid valve).*

**Table 75.2 Skin infections related to drug abuse.** GNRs, Gram-negative rods.




**Fig. 75.2 "Skin popping" scars. A–C** Multiple circular depressed scars, some with rims of postinflammatory hyperpigmentation, admixed with circular hemorrhagic crusts overlying ulcerations. Cocaine was injected into the thighs. *A, Courtesy Miguel Sanchez, MD; B, C, Courtesy, Mark Pittelkow, MD.*







**Fig. 75.3 Retiform purpura due to levamisole-adulterated cocaine. A, B** The earlobe is a common site of involvement and purpuric lesions of the earlobe had been described previously as a side effect of levamisole. At the time of writing, up to 70% of the cocaine in the United States contained levamisole, compared to <3% of the heroin. *Courtesy, Jeffrey P. Callen, MD.*



**Fig. 75.4 Atrophic depressions on the thighs and extensive calcification from multiple pentazocine injections.** The calcified areas are firm upon palpation. *Courtesy, Mark Pittelkow, MD.*



**Fig. 75.5 Purpuric papules of the palm due to emboli of pill fragments following an intra-arterial injection.** *Courtesy, Jean L. Bolognia, MD.*



**Fig. 75.6 Foreign body granuloma formation leading to papules at the sites of injection of adulterated heroin.** *Courtesy, Mark Pittelkow, MD.*




**Fig. 75.7 Multiple excoriations in a cocaine addict.** The patient felt "crawling" sensations in his skin. *Courtesy, Mark Pittelkow, MD.*



**Fig. 75.8 Coma bulla.** Large bulla with subsequent erosion on the medial ankle due to a prolonged coma from barbiturate overdose. *Courtesy, Mark Pittelkow, MD.*



**Fig. 75.9 Cellulitis of the lower extremity in an intravenous drug user.** *Courtesy, Mark Pittelkow, MD.*



**Fig. 75.10 Necrotizing fasciitis of the upper extremity with extensive tissue necrosis in an intravenous drug user.** Surgical debridement has been performed. *Courtesy, Mark Pittelkow, MD.*




**Fig. 75.11 Bruising and petechiae. A, B** Bruising and petechiae of the pinna and post-auricular area in a 6-year-old boy, consistent with a hand slap by an adult. *From Hobbs CJ, Wynne JM. Physical Signs of Child Abuse. © 2001 WB Saunders. Continued*

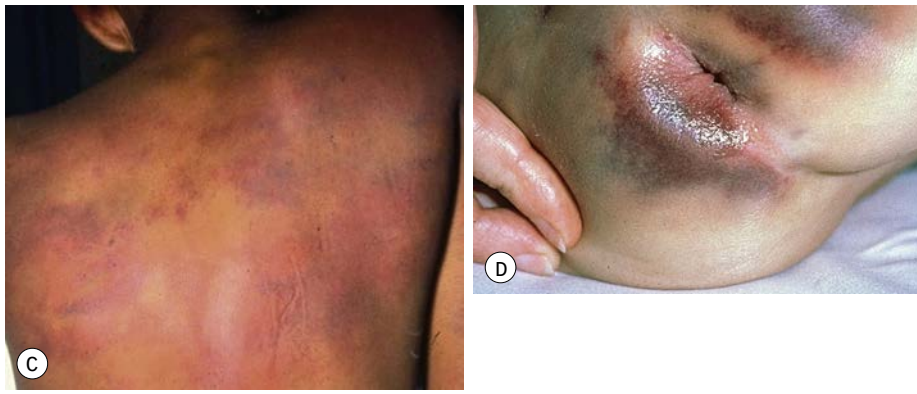


**Fig. 75.11** *Continued* **Bruising and petechiae. C** Bruising from a belt and belt buckle on the back of an 8-year-old boy. **D** Bruising of the buttocks and perianal area of a sexually abused 2-year-old child. *Courtesy, Sharon Ann Raimer, MD.*

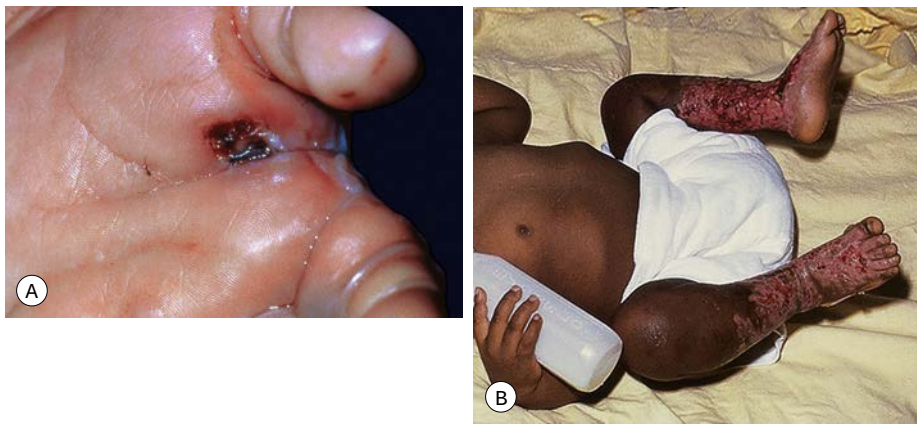


**Fig. 75.12 Injuries produced by burns. A** Cigarette burn. **B** Burn injury due to dunking in hot water, with a sharp line of demarcation on the lower legs. "Donut-type sparing" on the child's buttocks may be seen when the buttocks are held against the cooler tub while water scalds the surrounding immersed skin. *A, Courtesy, Sharon Ann Raimer, MD; B, Courtesy, Leo Litter, MD.*

## Elder Abuse

- Elder abuse may involve intentional actions that cause harm (physical, psychological, sexual, or financial) as well as failure by a caretaker to satisfy the basic needs of an elder or to protect him or her from harm.
- Risk factors include dementia and social isolation.
- Elder self-neglect is a related entity where individuals fail or refuse to address their own basic needs in a way that threatens their health and safety.
- The National Center on Elder Abuse (https://ncea.acl.gov) provides resources to assist in the recognition and management of elder abuse.

For further information see Chs 89 and 90 from *Dermatology, Fourth Edition*.

**For additional online figures visit www.expertconsult.com**

| CONDITIONS THAT CAN MIMIC CHILD ABUSE |
|---|
| **Bleeding into the skin (ecchymoses, purpura)** |
| • Multiple bruises due to platelet/clotting disorders or Ehlers–Danlos syndrome (especially on shins, knees)<br>• Bruising due to "cupping" or cao gio (coin rubbing)<br>• Vasculitis, particularly Henoch–Schönlein purpura (HSP; favors lower extremities) and acute hemorrhagic edema of infancy (favors face) |
| **Blue discoloration of skin mistaken as bruising** |
| • Dermal melanocytosis (favors sacral area and back; color does not progress to green/yellow)<br>• Infantile hemangioma (deep) or vascular malformation |
| **Linear hyperpigmentation** |
| • Phytophotodermatitis (Fig. 75.13A)<br>• Sock-line or mitten-line hyperpigmentation |
| **Vesicles, bullae, or erosions mistaken as non-accidental burns or other intentional injuries** |
| • Impetigo, ecthyma, blistering distal dactylitis<br>• Erythema multiforme, fixed drug eruption<br>• Bullous mastocytosis<br>• Irritant contact dermatitis (e.g. from laxative mimicking immersion burn, chemical burns from topical application of apple cider vinegar or garlic) (Fig. 75.13B)<br>• Arthropod bite reaction<br>• Moxibustion<br>• Burn from a hot car seat or seat belt buckle<br>• Genetic disorders of skin fragility, e.g. epidermolysis bullosa or porphyria |
| **Other** |
| • Osteogenesis imperfecta<br>• Hair tourniquet<br>• Self-inflicted injury |

**Table 75.3 Conditions that can mimic child abuse.**

| CONDITIONS OCCASIONALLY MISDIAGNOSED AS SEXUAL ABUSE IN CHILDREN |
|---|
| • Congenital anomalies or anatomic variants (e.g. white line in the posterior vestibule)<br>• Accidental injury<br>• Anal fissure due to constipation<br>• Perianal streptococcal infection<br>• Lichen sclerosus (Fig. 75.13C; may be associated with purpura or hemorrhagic bullae)<br>• Genital vitiligo<br>• Localized vulvar bullous pemphigoid or other bullous diseases<br>• Crohn disease (Fig. 75.13D)<br>• Infantile hemangioma (especially if ulcerated) or vascular malformation<br>• Entities misdiagnosed as genital or perianal warts<br>– Perianal pyramidal protrusion (Fig. 75.13E)<br>– Molluscum contagiosum<br>– Pseudoverrucous papules and nodules due to encopresis or urinary incontinence |

**Table 75.4 Conditions occasionally misdiagnosed as sexual abuse in children.**




**Fig. 75.13 Cutaneous disorders that may be misdiagnosed as physical or sexual abuse.** **A** Linear hyperpigmented streaks due to phytophotodermatitis on the back of a 2-year-old girl; the mother had lime juice on her hand when she touched the child. **B** Chemical burn from topical application of apple cider vinegar in an infant. Note the sharply demarcated erythema with angular borders and sparing of the skin folds, as well as the superficial blistering and desquamation. **C** Genital lichen sclerosus may have associated purpura or hemorrhagic bullae. **D** Cutaneous Crohn disease can present with vulvar erythema and swelling as well as perianal ulcers. **E** A perianal pyramidal protrusion in the typical location, just anterior to the anus in the midline. This finding is most common in infant girls. *A, Courtesy, Anthony J. Mancini, MD; B, D, E, Courtesy, Julie V. Schaffer, MD; C, Courtesy, Sharon Ann Raimer, MD.*



**eFig. 75.1 Tooth decay (arrow) is a common physical finding in drug addicts.** The term "meth mouth" has been used for those who abuse methamphetamines. *Courtesy, Mark Pittelkow, MD.*



**eFig. 75.3 Cutaneous disorders that may be misdiagnosed as physical or sexual abuse.** Self-induced suction purpura from a drinking glass on the upper lip of a young girl. *Courtesy, Julie V. Schaffer, MD.*



**eFig. 75.2 Retiform purpura due to levamisole-adulterated cocaine.** *Courtesy, Boni Elewski, MD.*

# 76 Histiocytoses

- Group of disorders in which the predominant cell type is a Langerhans cell, a mononuclear cell/macrophage, or a dermal dendrocyte.
- Traditionally, there are two major groups: Langerhans cell histiocytoses and non-Langerhans cell histiocytoses. The V600E variant of BRAF has been detected in both groups.
- Within these two main groups, the disorders overlap and form a clinicopathologic spectrum.

## Langerhans Cell Histiocytoses

- Langerhans cells, which represent the major antigen-presenting cells of the epidermis, are CD1a-positive, S-100 protein-positive, and langerin (CD207)-positive.
- Langerhans cells have Birbeck granules by electron microscopy.
- Common in children ages 1–3 years, but can occur at any age.

### Multisystem Variant

- There is an acute, diffuse form (formerly termed Letterer–Siwe disease) that can have multisystem involvement (skin, lung, liver, lymph nodes, bone, bone marrow), classically in children <1–2 year(s) of age. Skin lesions are small, 1- to 3-mm, skin-colored to pink papules, which can coalesce; sometimes they are admixed with pustules or vesicles. Secondary changes include scale, crusts, and petechiae/purpura. These lesions favor the scalp, flexural neck, axilla, perineum, and trunk (Fig. 76.1).
- A triad (formerly termed Hand–Schüller–Christian disease) can occur, consisting of diabetes insipidus (in 30%), exophthalmos, and osteolytic bone lesions (especially in the cranium); the disease is usually chronic and progressive and classically affects children ages 2–6 years. Skin lesions (see Fig. 76.1) are present in ~30%. Due to the chronic course, older lesions are often more xanthomatous (i.e. yellow in color due to accumulations of lipid within macrophages) and occasionally they are ulcerated. Premature loss of teeth can occur.
- **DDx** includes seborrheic dermatitis (see Fig. 13.4), intertrigo (see Fig. 13.2), scabies, impetigo, atopic dermatitis, contact dermatitis. **DDx** of xanthomatous lesions includes juvenile xanthogranuloma.

### Single System Variant

- Occasionally, there is localized bone involvement (formerly termed eosinophilic granuloma), classically in children (ages 7–12 years). It often presents as a single, asymptomatic bony lesion often favoring the cranium.
- A skin-limited, rapidly self-healing variant ("congenital self-healing reticulohistiocytosis" [Hashimoto–Pritzker disease]) presents at birth or during the first few days of life. Skin lesions are variable from a single nodule to widespread red-brown papules/nodules that crust and involute after several weeks (Fig. 76.2). Longitudinal follow-up is recommended because a small percentage of patients can develop systemic disease.

## Non-Langerhans Cell Histiocytoses

### Juvenile Xanthogranuloma

- Most common of the non-Langerhans cell histiocytoses.
- Appears primarily in infants and children (75% present during the first year of life).
- Usually a single papule or nodule (Fig. 76.3).




**Fig. 76.1 Langerhans cell histiocytosis – clinical spectrum.** **A** Scalp involvement may initially be diagnosed as seborrheic dermatitis; however, there are usually more discrete papules and crusting. **B** Pink, thin plaques with fissuring along the inguinal crease can also resemble seborrheic dermatitis. **C** Advanced disease with coalescence of papules into large plaques and prominent inguinal lymphadenopathy. **D** The presence of petechiae and purpuric papules is a clue to the diagnosis. **E** In an adult, the clinical presentation of inguinal involvement is similar to that of infants. **F** This subcutaneous nodule on the scalp involved the skull and represented the initial manifestation of multisystem Langerhans cell histiocytosis in an infant. **G** In patients with darkly pigmented skin, the papules can be hypopigmented. *A, C, E, Courtesy, YDRSC; B, Courtesy, Richard Antaya, MD; D, F, G, Courtesy, Julie V. Schaffer, MD.*



**Fig. 76.2 Langerhans cell histiocytosis with spontaneous resolution in a neonate ("congenital self-healing reticulohistiocytosis").** Crusted papules and hemorrhagic crusts on the ankle. *Courtesy, Kristin Hook, MD.*

- The color is initially pink to red-brown, but over time a yellow hue develops due to accumulation of intracellular lipid.
- Head/neck > trunk > upper extremities > lower extremities.
- Self-limiting; no treatment necessary.
- If multiple lesions, consider ophthalmologic examination for ocular involvement.
- If multiple café-au-lait macules are present, then consider the rare triple association with neurofibromatosis type I and an increased risk of developing juvenile myelomonocytic leukemia (see Table 45.8).
- **DDx:** mollusca contagiosa; when solitary, Spitz nevus; in an adult with multiple lesions, Erdheim-Chester disease, a rare disorder with multi-system involvement frequently associated with BRAF V600E mutations.

## Benign Cephalic Histiocytosis

- Rare, generally in infants <1 year old.
- 2- to 5-mm red-brown macules or papules on the face and neck, rarely elsewhere (Fig. 76.4).
- Self-limiting after months to years; no treatment necessary.

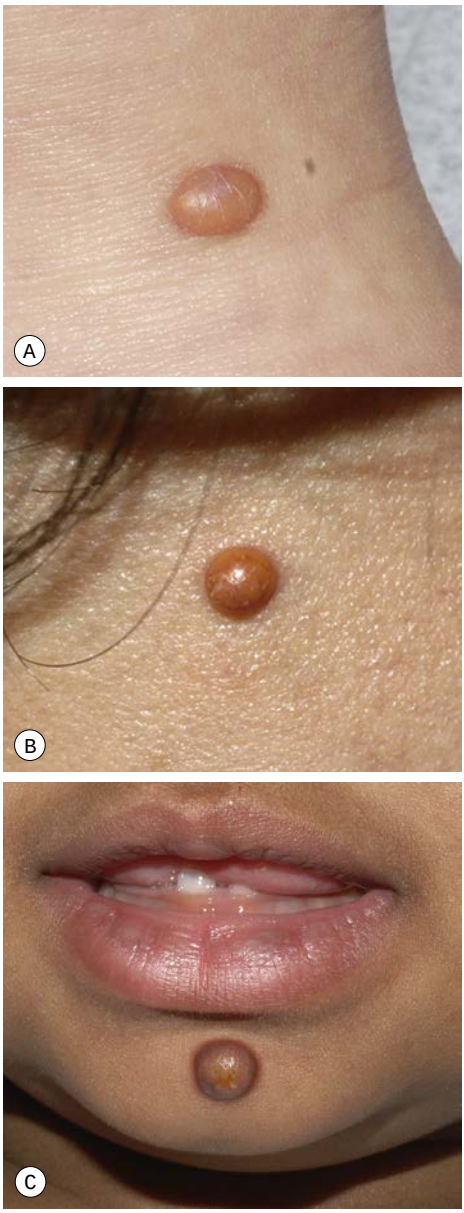


**Fig. 76.3 Juvenile xanthogranuloma.** Well-developed lesions that vary in color from pale yellow (**A**) to dark yellow/yellow-red (**B**) to yellow-brown (**C**), with the yellow hue reflecting the accumulation of lipid within histiocytes. *A, C, Courtesy, Julie V. Schaffer, MD; B, Courtesy, Luis Requena, MD.*

## Generalized Eruptive Histiocytoma

- Rare, generally in adults.
- Recurrent crops of tens to hundreds of small red-brown, firm papules (Fig. 76.5).
- Widespread on trunk.
- Self-limiting; no treatment necessary.



**Fig. 76.4 Benign cephalic histiocytosis.** Multiple light pink-brown papules on the face of a young child. *Courtesy, Julie V. Schaffer, MD.*

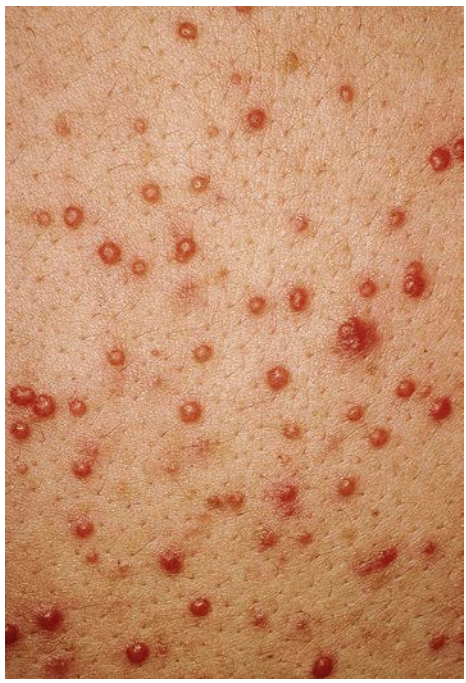

**Fig. 76.5 Generalized eruptive histiocytoma.** Multiple firm red papules on the trunk. *Courtesy, YDRSC.*

## Indeterminate Cell Histiocytosis

- Rare, all ages affected.
- Clinically indistinguishable from generalized eruptive histiocytoma.
- Diagnosis made by evaluation of biopsy specimen, with cells expressing CD1a, S100 protein, and CD68 (a marker of macrophages); lack of Birbeck granules ultrastructurally.



**Fig. 76.6 Necrobiotic xanthogranuloma.** Yellow-brown papules and plaques in a periorbital distribution in a patient with chronic lymphocytic leukemia. Such lesions may initially be mistaken for xanthelasma. *Courtesy, Kalman Watsky, MD.*

## Necrobiotic Xanthogranuloma

- Rare, generally in adults >50 years of age.
- Firm, yellowish plaques or papulonodules; sometimes ulcerated.
- Classically periorbital (Fig. 76.6).
- IgG monoclonal gammopathy in at least 70% of patients (see Table 45.8); hepatosplenomegaly, increased ESR, leukopenia, hypocomplementemia.
- Underlying plasma cell dyscrasia common; also increased risk of lymphoproliferative disorders.

## Multicentric Reticulohistiocytosis/ Giant Cell Reticulohistiocytoma

- Generally in adults.
- When single:
  - A skin-colored to pink papulonodule often on the head
  - Cutaneous disease only
- When multiple (Fig. 76.7):
  - Pink to red-brown papulonodules that favor the hands (especially periungual) and elbows; occasionally photodistributed
  - 50% with mucous membrane involvement




**Fig. 76.7 Multicentric reticulohistiocytosis.** **A** Grouped firm pink papules on the dorsal surface of the fingers, hand, and wrist of a 73-year-old African-American woman. **B** Grouped pink papulonodules on the elbow in a second patient. **C** A more subtle presentation in a third patient, with small pink papules and thin plaques that favor the skin overlying the small joints of the hands; this is the form that can initially be confused with dermatomyositis. **D** Telescoping of fingers due to arthritis mutilans.
*A, Courtesy, Susan D. Laman, MD; B, Courtesy, Jean L. Bolognia, MD; C, D, Courtesy, Kalman Watsky, MD.*

  - Associated with destructive arthritis that can clinically resemble rheumatoid arthritis; in up to 50%, arthritis is preceded by skin disease
  - Up to one third of affected patients can have an associated malignancy (see Table 45.8)

### Rosai–Dorfman Disease (Sinus Histiocytosis with Massive Lymphadenopathy)

- Generally in children and young adults.
- Nonspecific red, red-brown, or yellow papulonodule(s) (Fig. 76.8).
- Favor eyelids and malar area.
- Skin-limited form being increasingly recognized.
- Often self-limited, but there may be a protracted course.
- Systemic disease presents as massive bilateral cervical lymphadenopathy; fever and IgG polyclonal hypergammaglobulinemia may be present.

### Xanthoma Disseminatum

- Rare, generally before age 25 years.
- Triad of cutaneous xanthomas, mucous membrane xanthomas (in 40–60%), and diabetes insipidus (in 40%).
- Symmetric eruption of tens to hundreds of yellow, red, or brown papules and plaques.
- Favors face and flexural areas, including major folds (Fig. 76.9).
- Rarely sclerosis (Fig. 76.10).



**Fig. 76.8 Cutaneous Rosai–Dorfman disease.** Discrete, dome-shaped, brown papules. *Courtesy, YDRSC.*



**Fig. 76.9 Xanthoma disseminatum.** Symmetric involvement of the major flexures is a characteristic finding. Note the yellow discoloration of some of the coalescing papulonodules. *Courtesy, David Wetter, MD.*

- Mucous membrane involvement: oral, upper airway, ocular (may threaten vision).
- Can be associated with a monoclonal gammopathy.
- May self-resolve, be persistent, or progressive.

## Papular Xanthoma

- Any age.
- Generalized yellow papulonodules, sparing flexures.



**Fig. 76.10 Xanthoma disseminatum.** Sclerotic form of xanthoma disseminatum in a patient who developed multiple myeloma. *Courtesy, YDRSC.*

## Progressive Nodular Histiocytoma

- Any age.
- Generalized yellow papulonodules with prominent facial involvement.

Although we have made all these distinctions in the non-Langerhans cell histiocytoses, patients may have overlapping clinical and histopathologic features (including immunohistochemical staining). As a result, the evaluation of a patient with a non-Langerhans cell histiocytosis should include a total body skin examination and general physical examination, inclusive of eyes, mucosae, and lymph nodes. In addition, laboratory testing should include serum protein electrophoresis, immunofixation electrophoresis, and evaluation for diabetes insipidus.

For further information see Ch. 91 from *Dermatology, Fourth Edition*.

**For additional online figures visit www.expertconsult.com**

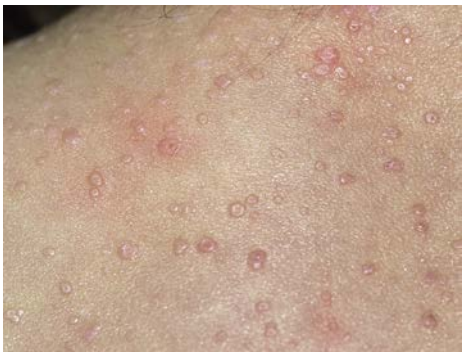

**eFig. 76.1 Langerhans cell histiocytosis.** Pale pink to skin-colored papules, several of which have central umbilication and resemble mollusca contagiosa. *Courtesy, Kristen Hook.*



**eFig. 76.2 Benign cephalic histiocytosis.** Multiple tan to brown papules. *Courtesy, YDRSC.*

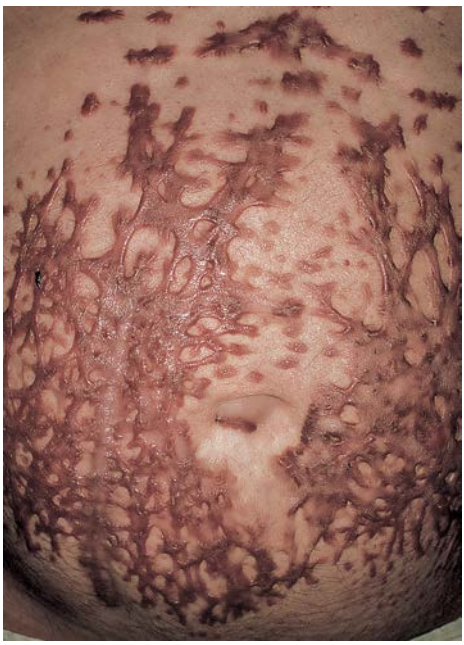

**eFig. 76.3 Xanthoma disseminatum.** Sclerotic form of xanthoma disseminatum in a patient who developed multiple myeloma. *Courtesy, YDRSC.*



**eFig. 76.4 Langerhans cell histiocytosis (eosinophilic granuloma of the bone).** Radiography of the femur shows a large well-circumscribed osteolytic lesion. *Courtesy, Edward McCarthy, MD.*



**eFig. 76.5 Langerhans cell histiocytosis with spontaneous resolution in a neonate ("congenital self-healing reticulohistiocytosis").** Solitary eroded nodule on the plantar surface. *Courtesy, Richard Antaya, MD.*

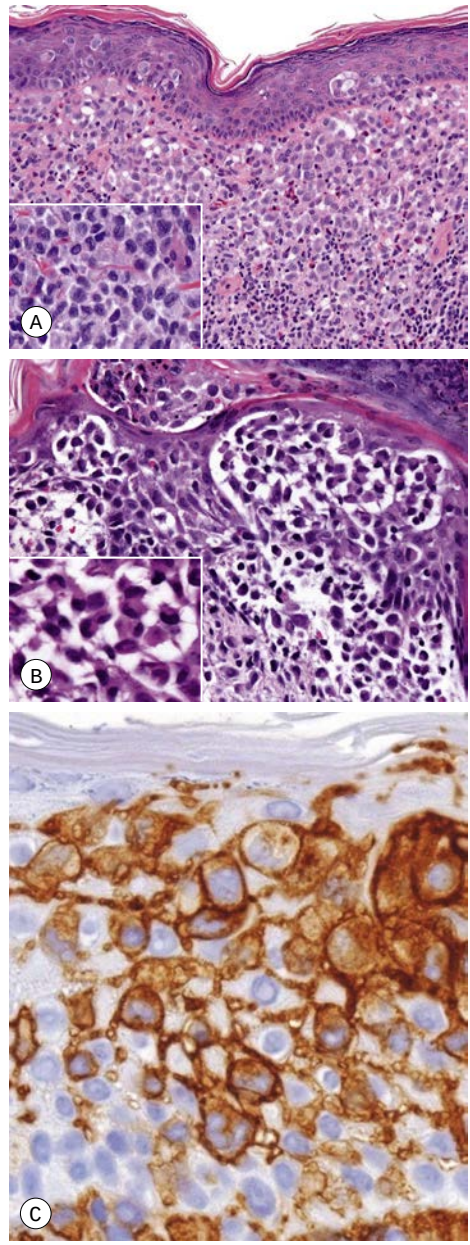


**eFig. 76.6 Langerhans cell histiocytosis (LCH) – histologic features. A** A somewhat lichenoid infiltrate of Langerhans cells with some involvement of the epidermis; the infiltrate also contains lymphocytes and numerous eosinophils. Inset: note the reniform-shaped nuclei. **B** Another example with larger collections of Langerhans cells within the epidermis. **C** CD1a immunostain highlighting Langerhans cells within the epidermis. *A,C Courtesy, Warren T. Goodman, MD and Terry L. Barrett, MD. B, Courtesy, Lorenzo Cerroni, MD.*

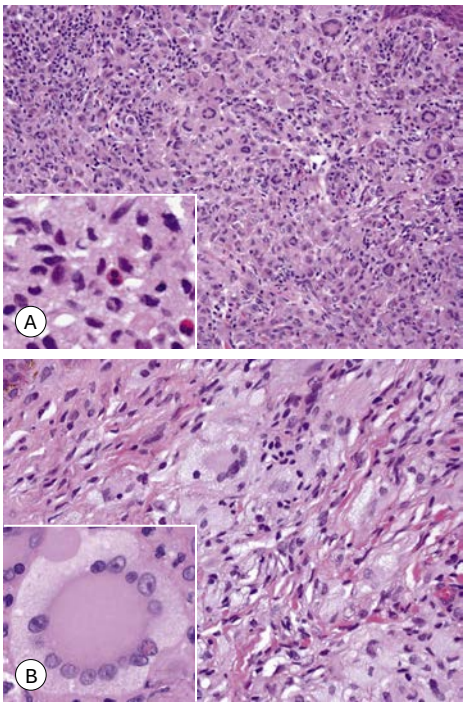


**eFig. 76.7 Juvenile xanthogranuloma.**
**A** Earlier lesion – the dermal histiocytic infiltrate contains relatively few Touton giant cells. Lymphocytes and eosinophils are also present (inset). **B** Older lesion – multiple foamy (xanthomatous) histiocytes and giant cells as well as a classic Touton giant cell with a "wreath-like" arrangement of nuclei (inset). *Courtesy, Lorenzo Cerroni, MD.*

# Xanthomas 77

## Key Points

- Cutaneous xanthomas are due to an accumulation of lipid, primarily within dermal macrophages (foam cells), and they have a characteristic yellow-orange hue.
- Four major types of xanthomas: eruptive, tuberous, tendinous, and plane.
- They may be a sign of hyperlipidemia, either primary or secondary, or an underlying monoclonal gammopathy.
- The type of xanthoma and its anatomic location are clues to the specific lipid abnormality or associated disorder (Tables 77.1 and 77.2; Fig. 77.1).
- **DDx** depends on the type of xanthoma (Table 77.3).
- In general, **Rx** is focused on correcting any underlying hyperlipidemia.

**MAJOR TYPES OF HYPERLIPIDEMIA**

| Type | Laboratory findings | Clinical findings | |
|---|---|---|---|
| | | Skin (types of xanthoma) | Systemic |
| Type I (familial LPL deficiency, familial hyperchylomicronemia) | Slow chylomicron clearance<br>Reduced LDL and HDL levels<br>Hypertriglyceridemia | Eruptive | No increased risk of coronary artery disease |
| Type II (familial hypercholesterolemia or familial defective apo B-100) | Reduced LDL clearance<br>Hypercholesterolemia | Tendinous, tuberoeruptive, tuberous, plane (xanthelasma, intertriginous areas, interdigital web spaces*) | Atherosclerosis of peripheral and coronary arteries |
| Type III (familial dysbetalipoproteinemia, remnant removal disease, broad beta disease, apo E deficiency) | Elevated levels of chylomicron remnants and IDLs<br>Hypercholesterolemia<br>Hypertriglyceridemia | Tuberoeruptive, tuberous<br>Plane (palmar creases) – most characteristic<br>Tendinous | Atherosclerosis of peripheral and coronary arteries |
| Type IV (endogenous familial hypertriglyceridemia) | Increased VLDLs<br>Hypertriglyceridemia | Eruptive | Frequently associated with type 2 non-insulin-dependent diabetes mellitus, obesity, alcoholism |
| Type V | Decreased LDLs and HDLs<br>Hypertriglyeridemia | Eruptive | Diabetes mellitus |

**Plane xanthomas in the interdigital web space are said to be pathognomonic for the homozygous state.*

**Table 77.1 Major types of hyperlipidemia.** apo, apolipoprotein; HDL, high-density lipoprotein; IDL, intermediate-density lipoprotein; LDL, low-density lipoprotein; LPL, lipoprotein lipase; VLDL, very-low-density lipoprotein.

| CAUSES OF HYPERTRIGLYCERIDEMIA | |
|---|---|
| **Primary** | |
| Genetic factors (see Table 77.1) | |
| **Secondary** | |
| Diabetes mellitus, especially when poorly controlled (see Table 45.10) | |
| Medications | Systemic retinoids (e.g. bexarotene, acitretin) |
| | Antiretrovirals (e.g. ritonavir, indinavir, stavudine) |
| | Azacitidine, cyclosporine, estrogen, olanzapine |
| Obesity | |
| Alcohol intake | |
| Other underlying systemic disorders (e.g. primary biliary cholangitis [see Table 45.6], hypothyroidism [see Table 45.12], nephrotic syndrome) | |

**Table 77.2 Causes of hypertriglyceridemia.** Severe elevation is generally defined as triglycerides >500 mg/L, but eruptive xanthomas usually develop at much higher levels; more than one factor can be present in a patient. See Table 77.4 for recommended laboratory tests.

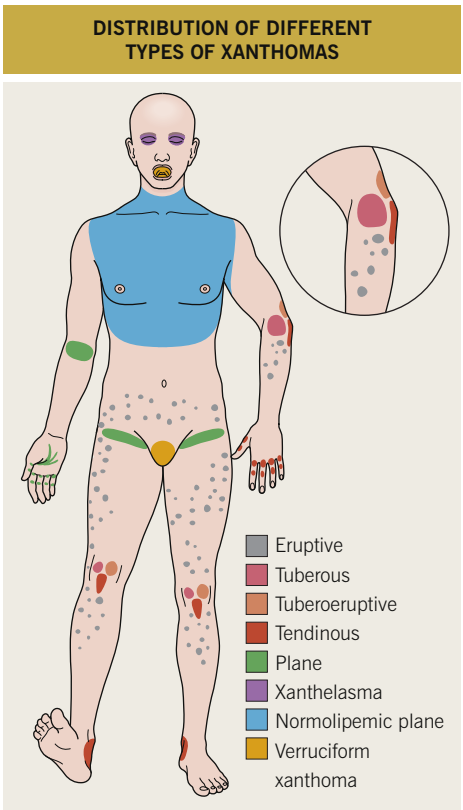


**Fig. 77.1 Distribution of different types of xanthomas.**



**Fig. 77.2 Eruptive xanthomas due to hypertriglyceridemia.** The lesions favored the extensor surface of the lower extremities, in particular the knees. *Courtesy, YDRSC.*

## Xanthomas Associated with Hyperlipidemia

### Eruptive Xanthomas

- Yellow-pink papules, 1–5 mm in diameter.
- May be widespread, but favor the extensor surfaces of the extremities and buttocks (Figs 77.2 and 77.3; see Fig. 45.10C).
- An inflammatory halo, tenderness, and/or pruritus may be present.
- Associated with hypertriglyceridemia (often >3000–4000 mg/dl) (see Table 77.2).
- Seen in the setting of type I, IV, or V hyperlipidemia and most commonly when associated

diabetes mellitus is under poor control (see Table 45.10).

- Lesions often resolve within weeks of aggressive **Rx:** insulin; triglyceride-lowering agents, e.g. fenofibrate.

### Tuberous/Tuberoeruptive Xanthomas

- Pink-yellow to yellow-brown papules (tuberoeruptive) or nodules (tuberous) on extensor surfaces, especially the elbows and knees (Figs 77.4 and 77.5); tuberous xanthomas can be >3 cm in diameter.

| DIFFERENTIAL DIAGNOSIS OF XANTHOMAS |
|---|
| **Eruptive xanthomas** |
| • Non-Langerhans cell histiocytosis<br>– Xanthoma disseminatum<br>– Papular xanthoma<br>– Generalized eruptive histiocytoma<br>– Indeterminate cell histiocytosis<br>– Rosai–Dorfman disease<br>– Juvenile xanthogranuloma (micronodular form)<br>• Xanthomatous lesions of Langerhans cell histiocytosis<br>• Disseminated granuloma annulare |
| **Tuberous xanthomas** |
| • Erythema elevatum diutinum<br>• Multicentric reticulohistiocytosis |
| **Tendinous xanthomas** |
| • Giant cell tumor of the tendon sheath<br>• Rheumatoid nodule<br>• Subcutaneous granuloma annulare<br>• Erythema elevatum diutinum |
| **Xanthelasma** |
| • Syringomas<br>• Necrobiotic xanthogranuloma<br>• Sebaceous hyperplasia<br>• Palpebral sarcoidosis |

**Table 77.3 Differential diagnosis of xanthomas.**

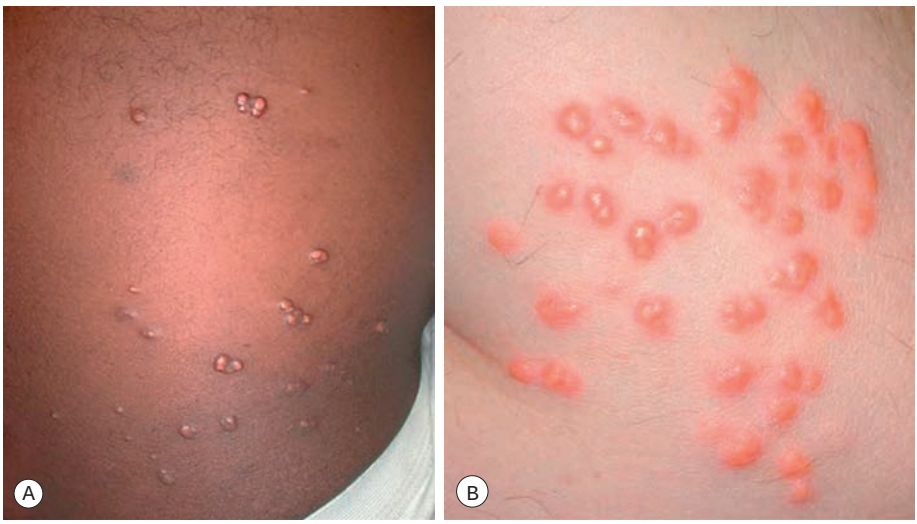


**Fig. 77.3 Eruptive xanthomas. A, B** The yellowish hue is influenced by the degree of pigmentation of the skin. Note the clustering of some of the lesions. *A, Courtesy, YDRSC; B, Courtesy, W. Trent Massengale, MD.*

• Associated with hypercholesterolemia (type II or III hyperlipidemia).
• May be slow to regress with cholesterol-lowering agents (e.g. "statins").

### Tendinous Xanthomas

• Firm, smooth, skin-colored nodules due to lipid deposits within the Achilles tendons and the extensor tendons of the hands, knees, and/or elbows (Figs 77.6 and 77.7).
• Can serve as an early clue to the presence of type II hyperlipidemia.
• Rarely form as a consequence of accumulation of cholestanol (cerebrotendinous xanthomatosis) or plant sterols (β-sitosterolemia).

### Plane Xanthomas and Xanthelasma

• Yellow to orange macules and patches or thin papules and plaques.
• Of the different types of xanthomas, xanthelasma is the most common; however, hyperlipidemia is detected in only 50% of patients.



**Fig. 77.4 Tuberoeruptive xanthomas on the elbow of a child with homozygous familial hypercholesterolemia.** Note the yellowish hue. *Courtesy, Julie V. Schaffer, MD.*



**Fig. 77.6 Tendinous xanthoma.** Linear swelling of the Achilles area, representing a tendinous xanthoma in a patient with dysbetalipoproteinemia. *Courtesy, W. Trent Massengale, MD, and Lee T. Nesbitt, Jr., MD.*



**Fig. 77.5 Nodular tuberous xanthoma of the elbow.** *Courtesy, Lorenzo Cerroni, MD.*



**Fig. 77.7 Tendinous xanthomas of the fingers in a patient with homozygous familial hypercholesterolemia.** Note interdigital plane xanthomas of the web spaces. *Courtesy, W. Trent Massengale, MD, and Lee T. Nesbitt, Jr., MD.*



**Fig. 77.8 Plane xanthomas of the antecubital fossae.** This young patient had dysbetalipoproteinemia. *Courtesy, W. Trent Massengale, MD, and Lee T. Nesbitt, Jr., MD.*

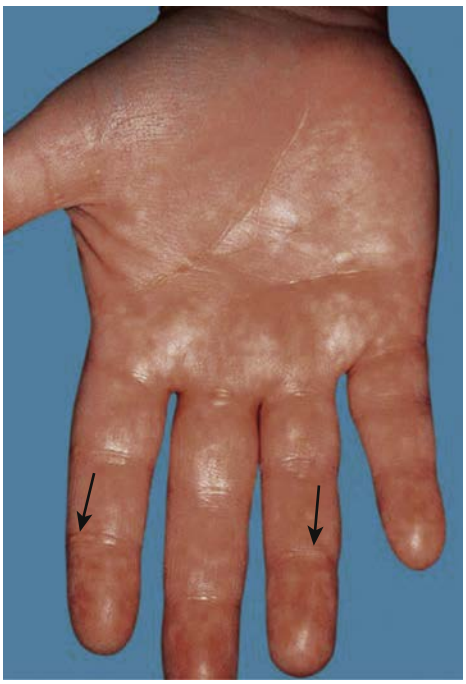

**Fig. 77.9 Plane xanthomas of the palmar creases (arrows) in a patient with dysbetalipoproteinemia.** They are seen in approximately two-thirds of patients with this disorder. Plane xanthomas are also seen in the setting of cholestasis, e.g. biliary atresia or primary biliary cholangitis. *Courtesy, W. Trent Massengale, MD, and Lee T. Nesbitt, Jr., MD.*

- Site:
  - Intertriginous – antecubital fossae, finger web spaces, and palmar creases (Figs 77.8 and 77.9)

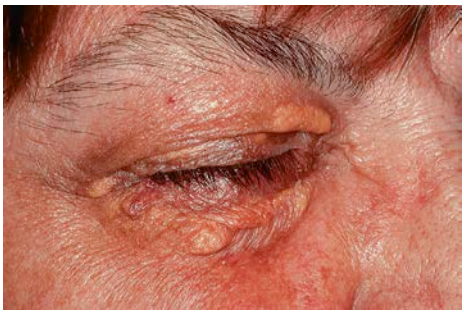

**Fig. 77.10 Xanthelasma palpebrarum with typical yellowish hue.** *Courtesy, YDRSC.*

  - Eyelids (xanthelasma), especially the medial aspect of the upper eyelid (Fig. 77.10)
- Intertriginous plane xanthomas can be seen in primary hyperlipidemia (type II or III) as well as secondary hyperlipidemia (e.g. biliary atresia, primary biliary cholangitis; see Table 45.6).
- **Rx** of xanthelasma: destructive methods (e.g. trichloroacetic acid application, laser ablation), surgical excision.

Laboratory evaluation for suspected hyperlipidemia is outlined in Table 77.4.

## Normolipemic Xanthomas

### Plane Xanthomas Associated with Monoclonal Gammopathy

- In contrast to plane xanthomas due to hyperlipidemia, these yellow-orange patches and thin plaques are usually larger in size and have a more extensive distribution pattern; the latter often includes the trunk (Fig. 77.11).
- In addition to the trunk, lesions may be seen on the neck, in flexural folds, and in the periorbital region.
- The monoclonal gammopathy is most commonly due to a plasma cell dyscrasia, and occasionally due to a lymphoproliferative disorder (see Table 45.8).

### Verruciform Xanthoma

- Asymptomatic verrucous plaque, 1 to 2 cm in diameter (Fig. 77.12).
- Oral mucosa or anogenital region.
- May be seen in association with lymphedema, epidermolysis bullosa, and CHILD (congenital hemidysplasia with ichthyosiform erythroderma and limb defects) syndrome.

For further information see Ch. 92 from *Dermatology, Fourth Edition*.

| LABORATORY EVALUATION OF SUSPECTED HYPERLIPIDEMIA |
|---|
| • Fasting lipid panel* |
| • Fasting glucose level |
| • Liver function tests** |
| • Thyroid-stimulating hormone (TSH) level |
| • Serum albumin |

**Lipid panel: Total cholesterol, trigylcerides, HDL cholesterol, LDL cholesterol, calculated non-HDL cholesterol. If elevated serum lipids, evaluate for systemic disease (see Tables 77.1 and 77.2).*
***If elevated serum alkaline phosphatase and bilirubin, evaluate for biliary disease.*

**Table 77.4 Laboratory evaluation of suspected hyperlipidemia.**



**Fig. 77.11 Normolipemic plane xanthoma.** The large thin plaques have a yellow-orange color. On longitudinal evaluation, the patient was found to have a monoclonal gammopathy. *Courtesy, Whitney High, MD, JD.*



**Fig. 77.12 Verruciform xanthoma of the oral mucosa.** *Courtesy, Kishore Shetty, DDS.*

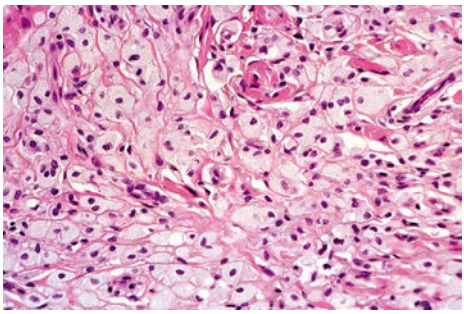

**eFig. 77.1 Histology of a tuberous xanthoma.** Foamy macrophages fill the dermis. *Courtesy, Lorenzo Cerroni, MD.*



**eFig. 77.2 Skin signs of cardiac disease.** Multiple tendinous xanthomas in a patient with familial hypercholesterolemia. *Courtesy, Dermatology Department, Hospital Regional Honorio Delgado Espinoza de Arequipa, Peru.*

| IMPORTANT APOPROTEINS | | |
|---|---|---|
| **Apoprotein** | **Lipoprotein association** | **Function and comments** |
| A-I | Chylomicrons, HDLs | Major protein of HDL; activates lecithin:cholesterol acyltransferase (LCAT) |
| B-48 | Chylomicrons, chylomicron remnants | Unique marker for chylomicrons |
| B-100 | VLDLs, IDLs, and LDLs | Major protein of LDL; binds to LDL receptor |
| C-II | Chylomicrons, VLDLs, IDLs, and HDLs | Activates lipoprotein lipase |
| E (at least 3 alleles [$E_2$, $E_3$, $E_4$]) | Chylomicrons, chylomicron remnants, VLDLs, IDLs, and HDLs | Binds to LDL receptor |

**eTable 77.1 Important apoproteins.** HDL, high-density lipoprotein; IDL, intermediate-density lipoprotein; LDL, low-density lipoprotein; VLDL, very-low-density lipoprotein. *Courtesy, William Trent Massengale, MD.*

# Non-infectious Granulomatous Disorders, Including Foreign Body Reactions

# 78

When histiocytes form granulomas within the skin, the cutaneous disorders are referred to as granulomatous. This group of disorders is further divided into infectious (e.g. mycobacterial infections, dimorphic fungal infections) and non-infectious (e.g. sarcoidosis, granuloma annulare). This chapter focuses on the latter category.

## Sarcoidosis

- Disorder of unknown etiology in which granulomas develop in one or more organs, most commonly the lung, skin, liver, and spleen.
- Cutaneous manifestations occur in >30% of patients and may be the first and/or only sign of the disease (Table 78.1).
- The classic lesion is a red-brown papule or plaque with a yellowish color on compression (diascopy), most commonly on the face (Figs 78.1 and 78.2; see Fig. 45.1A).
- Variants:
  - Lupus pernio – purple to red-brown papules and plaques of the nose, ears, and cheeks; may be beaded along the nasal rim (Fig. 78.2C); associated with chronic pulmonary sarcoidosis (75% of patients), upper respiratory tract sarcoidosis (50%), and cysts within the distal phalanges
  - Darier–Roussy sarcoidosis (subcutaneous variant) – painless, firm, mobile nodules or plaques
  - Löfgren syndrome – hilar adenopathy, fever, migrating polyarthritis, and acute iritis; erythema nodosum is the primary skin finding (see Table 83.2); often spontaneously remits
  - Heerfordt syndrome – parotid gland enlargement, uveitis, fever, cranial nerve palsies
- Once the diagnosis of cutaneous sarcoidosis is established, evaluation for systemic involvement is necessary (Table 78.2)
- **DDx** of classic papule/plaque other entities in this chapter, granulomatous rosacea and perioral dermatitis, dimorphic fungal infections, cutaneous tuberculosis; in young children, consider Blau syndrome (see Ch. 37).
- **Rx** of cutaneous lesions: CS (topical, intralesional); oral medications include minocycline, antimalarials, methotrexate, tacrolimus, TNF inhibitors, thalidomide, and JAK inhibitors.

## Granuloma Annulare

- May be a delayed-type hypersensitivity reaction to an unknown antigen; by history can follow an arthropod bite, trauma.
- Common clinical variants (see Table 78.1) – localized, often acral (Fig. 78.3); subcutaneous on hands, shins, and scalp in children; generalized (Fig. 78.4).
- Less common variants are perforating, often on the hands (Fig. 78.5), patch type on the trunk, and micropapular (Fig. 78.6).
- Generalized granuloma annulare, also referred to as disseminated, is more likely to be associated with diabetes mellitus (see Table 45.10) or lipid abnormalities (e.g. hypercholesterolemia) compared to other variants; atypical presentations seen in HIV-infected patients.
- **DDx:** other entities in this chapter (see Table 78.1), tinea, interstitial granulomatous dermatitis, inflammatory morphea.
- **Rx:** spontaneous resolution may occur; first-line – CS (topical including under occlusion, intralesional); second-line – cryosurgery, niacinamide +/– tetracycline, antimalarials, retinoids, PUVA/UVA1/excimer laser and apremilast.

## Necrobiosis Lipoidica

- Formerly referred to as "necrobiosis lipoidica diabeticorum," a term abandoned given that not all patients with this disorder have diabetes mellitus (see Table 45.10).

| CLINICAL FEATURES OF THE MAJOR GRANULOMATOUS DERMATITIDES | | | | | | |
|---|---|---|---|---|---|---|
| | **Sarcoidosis*** | **Classic granuloma annulare^** | **Necrobiosis lipoidica** | **IGD/PNGD** | **Cutaneous Crohn disease** | **Rheumatoid nodule (see Fig. 37.2)** |
| Average age (years) | 25–35, 45–65 | <30 | 30 | 40–70 | 35 | 40–50 |
| Sex predilection | Female | Female | Female | IGD: Female | Female | Male† |
| Racial/ethnic predilection in United States | African-American | None | None | Caucasian | Ashkenazi Jews | None |
| Sites | Symmetric on face, neck, upper trunk, extremities | Hands, feet, extensor aspects of extremities | Anterior and lateral aspects of shins | IGD: lateral trunk, medial arms/thighs; PNGD: elbows, fingers | Anogenital region, buttocks, lower > upper extremities | Juxta-articular areas, especially elbows, hands, ankles, feet |
| Appearance | Protean; most commonly red-brown or violaceous papules and plaques; occasionally violaceous or annular | Papules coalescing into annular plaques | Plaques with elevated borders, telangiectasias centrally | IGD: erythematous papules and plaques, sometimes annular; PNGD: umbilicated papules | Dusky erythema, lymphedema, ulceration, vegetating plaques | Skin-colored, firm, mobile subcutaneous nodules |
| Size of lesions | 0.2 to >5 cm | 1- to 3-mm papules, annular plaques usually <6 cm | 3 to >10 cm | IGD: 5 mm to > 2 cm; PNGD: 1–4 mm | Variable | 1–3 cm |
| No. of lesions | Variable | 1–10 | 1–10 | 1 to >20 | 1–5 | 1–10 |
| Associations | Systemic manifestations of sarcoidosis; can be drug-induced (e.g. IFN, TNF inhibitors) or reaction pattern to underlying lymphoma | Possible diabetes mellitus, thyroid disease, or hyperlipidemia; rare reports of HIV infection, malignancy | Diabetes mellitus | Medications, e.g. statins, TNF inhibitors; autoimmune disease, e.g. rheumatoid arthritis | Intestinal Crohn disease | Rheumatoid arthritis |
| Special clinical characteristics | Occasional central atrophy and hypopigmentation; develop within scars and tattoos | Central hyperpigmentation | Yellow-brown atrophic centers, ulceration | "Rope sign" (linear cords) | Draining sinuses and fistulas | Occasional ulceration, especially at sites of trauma |

*Clinical variants include lupus pernio and subcutaneous (Darier–Roussy), psoriasiform, ichthyosiform, angiolupoid, and ulcerative sarcoidosis .
^Clinical variants include generalized/disseminated, micropapular, nodular, perforating, subcutaneous, and patch granuloma annulare.
†Although rheumatoid arthritis has a female:male ratio of 2–3:1.

**Table 78.1 Clinical features of the major granulomatous dermatitides.** AEGCG, annular elastolytic giant cell granuloma; IGD, interstitial granulomatous dermatitis; PNGD, palisaded neutrophilic and granulomatous dermatitis. *Courtesy, Clifton R. White, Jr., MD.*




**Fig. 78.1 Sarcoidosis. A** Cutaneous sarcoidosis usually consists of papules and plaques with a typical reddish-brown color. **B, C** Lesions often favor the nose, lips, and perioral region. **D** Hyperpigmented plaques, some of which have scale. **E** Papules of cutaneous sarcoidosis arising within a tattoo; the differential diagnosis includes foreign body reaction. *A, C–E, Courtesy, YDRSC; B, Courtesy, Misha Rosenbach, MD.*

- Typically red-brown plaques on the shins with central clearing that may become yellow and atrophic over time; occasionally, lesions involve the upper extremities, face, and scalp (Fig. 78.7; see Table 78.1; see Fig. 45.10D).
- **DDx:** granuloma annulare, sarcoidosis, and non-Langerhans cell histiocytoses, in particular necrobiotic xanthogranuloma.
- **Rx:** CS (topical, intralesional, rarely systemic) are the mainstay; for intralesional CS, test sites are recommended.

## Annular Elastolytic Giant Cell Granuloma

- Clinically most closely resembles granuloma annulare but lesions have an atrophic, hypopigmented center and sites of predilection are sun-exposed sites including the face, neck, and forearms (Fig. 78.8; see Table 78.1).
- Biopsy needs to be elliptical and involve the center, the border, and uninvolved skin with longitudinal sectioning.
- **Rx:** often ineffective, can try topical and intralesional CS.

## Interstitial Granulomatous Dermatitis (IGD) and Palisaded Neutrophilic and Granulomatous Dermatitis (PNGD) (Reactive Granulomatous Dermatitis)

- Two clinicopathologic patterns of granulomatous dermatitis that occur in patients (women > men) with rheumatoid arthritis (RA) and other autoimmune disorders.

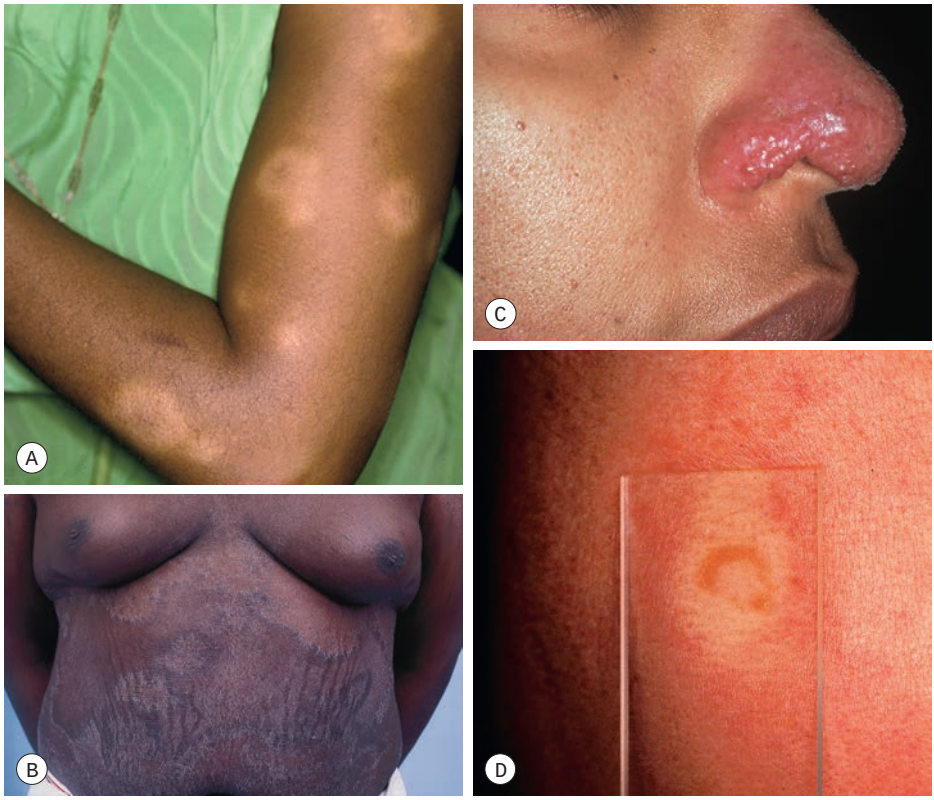


**Fig. 78.2 Sarcoidosis – clinical variants and appearance with diascopy. A** The hypopigmented variant is more noticeable in individuals with dark skin. **B** Ichthyosiform presentation with obvious scale. **C** Coalescing violaceous papules on the nose in lupus pernio; note the notching of the nasal rim. **D** Diascopy: pressure applied to a lesion creates a yellow-brown, "apple-jelly", color. *A, Courtesy, Louis A. Fragola, Jr., MD; B, Courtesy, Jean L. Bolognia, MD; C, D, Courtesy, YDRSC.*

**SUGGESTED INITIAL SYSTEMIC EVALUATION OF A PATIENT WITH CUTANEOUS SARCOIDOSIS**

*In ALL patients:*

- **CXR (PA and lateral)***
- **PFTs with DLCO**
- **Ophthalmologic examination**
- **CBC, LFTs, BUN/Cr, TSH, serum calcium, serum 25-hydroxy- and 1,25-dihydroxy-vitamin D levels, ACE level**
- TST or IFN-gamma release assay (e.g. QFT-GIT)**
- ECG***

*Based upon findings from thorough history, review of systems, physical examination:*

- Heart palpitations, syncopal or pre-syncopal episodes, abnormal ECG: refer to cardiology (further cardiac imaging will be performed, e.g. cardiac MRI or PET)
- Extensive facial involvement (e.g. lupus pernio, multiple nasal/perinasal lesions): refer to otolaryngology (evaluation for sinus and/or upper airway involvement)
- Cough, chest pain, dyspnea, velcro rales in lung base, abnormal CXR or PFTs: refer to pulmonology
- Neuropathy (e.g. peripheral, cranial, small fiber): refer to neurology

*Items in **bold** should be repeated annually.*
**High resolution chest CT scan is more sensitive than CXR and should be ordered if any suspicious findings on CXR or if normal CXR but high clinical suspicion for pulmonary involvement.*
***To exclude tuberculosis, which can present with similar radiographic signs.*
****Any abnormalities should prompt referral to cardiology.*

**Table 78.2 Initial systemic evaluation of a patient with cutaneous sarcoidosis.** ACE, angiotensin converting enzyme; DLCO, diffusing capacity for carbon monoxide; PET, positron emission tomography; PFTs, pulmonary function tests; QFT-GIT, Quantiferon-gold TB In-Tube test.

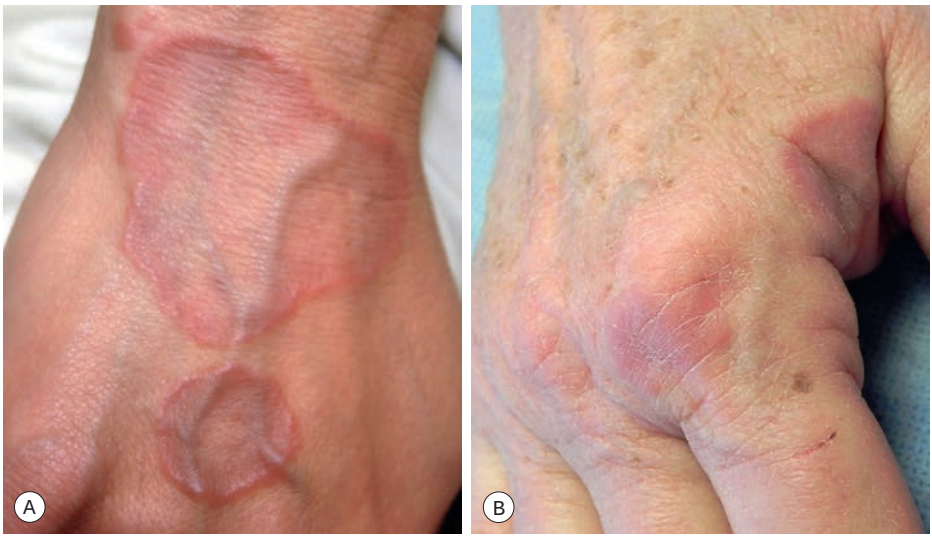


**Fig. 78.3 Granuloma annulare. A,B** Annular pink to pink-brown plaques; discrete papules may be seen. The dorsal aspect of the hand is a common location. *A, Courtesy YDRSC; B, Courtesy, Misha A. Rosenbach, MD.*



**Fig. 78.4 Generalized granuloma annulare.** Numerous papules and small annular plaques. *Courtesy, YDRSC.*



**Fig. 78.5 Perforating granuloma annulare.** Papules can have a central keratotic plug or umbilication. *Courtesy, Ronald P. Rapini, MD.*

- *IGD* presents as annular erythematous plaques or linear cords ("rope sign") that favor the lateral and upper trunk, axillae, medial thighs, and buttocks (Fig. 78.9); patients often have RA or seronegative arthritis.
- *PNGD* presents as skin-colored to erythematous, umbilicated papulonodules that are often crusted and favor the elbows (see Fig. 19.11B) and extensor hands/fingers; associated with RA, SLE, and ANCA-positive systemic vasculitides (e.g. eosinophilic granulomatosis with polyangiitis); see Table 45.1.
- Because interstitial granulomatous drug reactions can have clinical and histologic features similar to those of IGD and PNGD, a review of all medications should be performed; culprit drugs include calcium channel blockers, angiotensin-converting enzyme inhibitors, statins, and TNF inhibitors.

• Histologically, a dense pandermal infiltrate is seen in both entities; IGD features rosettes of palisading histiocytes surrounding tiny foci of degenerated collagen, while findings in PNGD range from a predominance of neutrophils with foci of leukocytoclastic vasculitis to well-developed palisaded granulomas surrounding basophilic degenerated collagen.



**Fig. 78.6 Papular granuloma annulare of the dorsal hand.** Several of the lesions have a central dell. *Courtesy, Joyce Rico, MD.*

• **DDx:** interstitial granulomatous drug reaction (see above); *for IGD* – patch-type granuloma annulare (GA), morphea (inflammatory stage), mycosis fungoides and leprosy; *for PNGD* – papular GA, rheumatoid nodules/nodulosis, perforating disorders.
• **Rx:** high-potency topical or intralesional CS, dapsone (if prominent neutrophils); may improve with treatment of the underlying disorder.

## Cutaneous Crohn Disease

• Skin lesions may be the presenting sign of Crohn disease in up to 20% of patients and they may be specific or nonspecific; examples of the latter include pyoderma gangrenosum and erythema nodosum (see Table 45.4).
• Specific lesions can be contiguous or noncontiguous (metastatic), and both show granulomas on biopsy:
  – Contiguous lesions are seen in the mouth, perioral or anogenital region, and

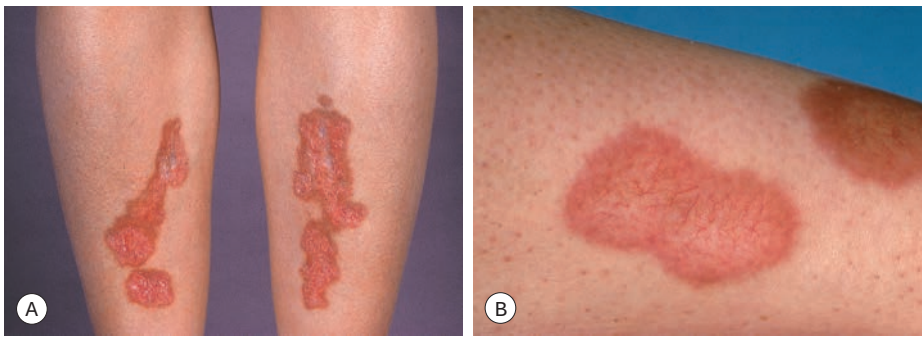


**Fig. 78.7 Necrobiosis lipoidica. A** Pink-brown atrophic plaques on the shins. **B** Annular plaques with central telangiectasias. *A, B, Courtesy, NYUDSC.*

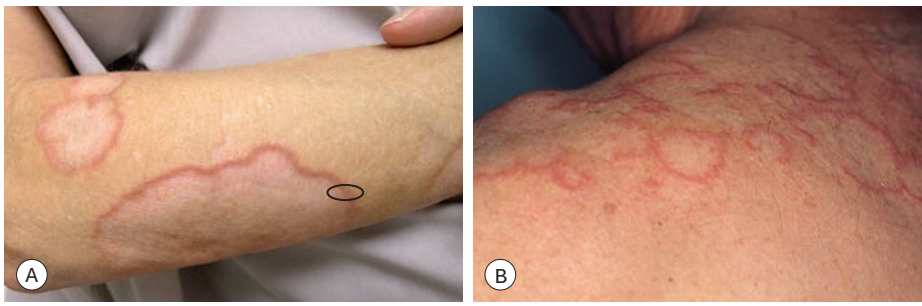


**Fig. 78.8 Annular elastolytic giant cell granuloma.** The border resembles granuloma annulare but the central portion is hypopigmented and/or atrophic **(A, B)**. A biopsy specimen that includes the area outlined in **A** would contain the three characteristic histologic zones: absence of elastic fibers, granulomatous inflammation, and normal skin. Longitudinal sectioning of the surgical specimen is preferred. *A, Courtesy, Misha A. Rosenbach, MD; B, Courtesy, Kalman Watsky, MD.*

peristomal areas with clinical presentations varying from fissures to cobblestoning to swelling (Figs 78.10 and 78.11; see Fig. 45.4A)
  - Metastatic lesions present as vegetating plaques or nodules, most commonly on the lower extremities (see Table 78.1)
  - Sinuses from GI disease may extend to the skin, particularly in the anogenital region or surgical sites on the abdomen

- **Rx of skin lesions**: often improve with systemic Rx of GI disease; oral metronidazole (250 mg three times daily); topical, intralesional, and oral CS; other systemic agents (e.g. sulfasalazine, TNF inhibitors).

## Foreign Body Granulomas

- An inflammatory reaction to inorganic (e.g. suture) or organic (e.g. keratin) materials implanted into the skin.
- The most common foreign body is keratin due to ruptured cysts or hair follicles (Table 78.3; Figs 78.12–78.18).
- The clinical presentation is usually a red to red-brown papule, nodule, or plaque that may be ulcerated or extruding the foreign material.
- History and histologic findings including polarization can aid in identifying the foreign material; occasionally other procedures (e.g. energy dispersive X-ray analysis) are necessary.

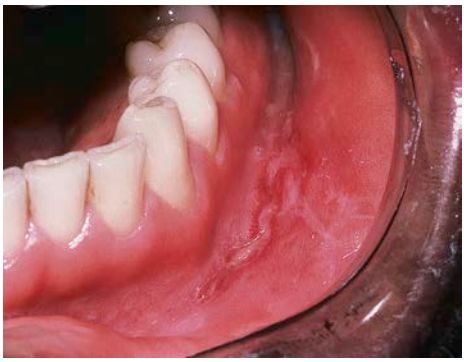

**Fig. 78.10 Crohn disease.** Linear ulceration of the mandibular vestibule: the classic oral manifestation of this disease. *Courtesy, Charles Camisa, MD.*

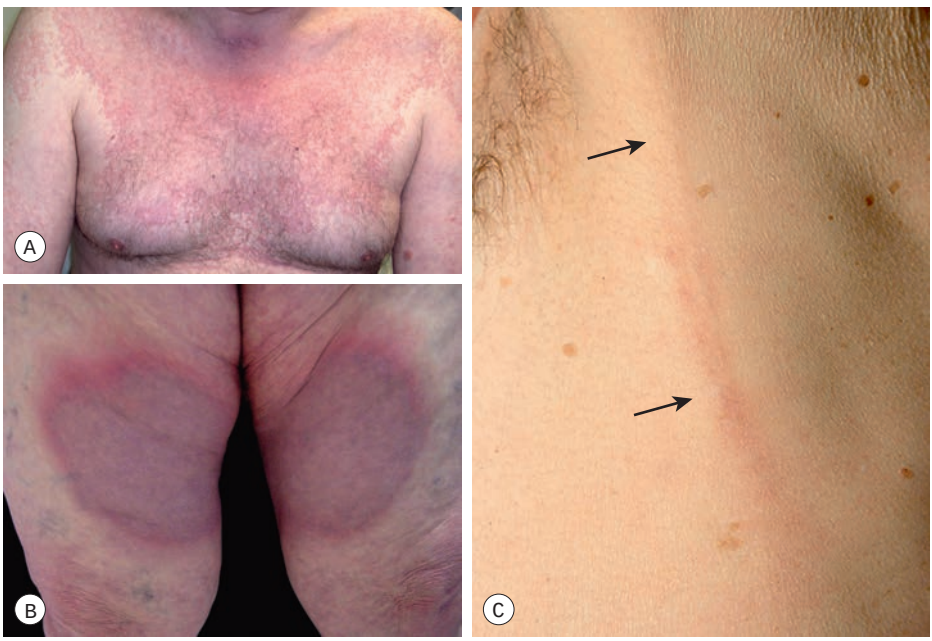


**Fig. 78.9 Interstitial granulomatous dermatitis (IGD). A** Large, symmetric pink patches and thin plaques that often resemble patch-type granuloma annulare. **B** Annular lesions on the medial thighs. **C** Firm linear cord along the axillary line in a patient with rheumatoid arthritis. *A, YDRSC; B, Courtesy, Jeffrey P. Callen, MD; C, Courtesy Kathryn Schwarzenberger, MD.*

For further information see Chs 93 and 94 from *Dermatology, Fourth Edition*.




**Fig. 78.11 Cutaneous Crohn disease.**
**A** Vulvar and perianal erythema and induration. Note the marked asymmetric vulvar swelling and perianal erosions. **B** Marked lymphedema of the prepuce with lymphedema and induration of the scrotum. **C** Inflammation and edema leading to twisting of the penis along its long axis, referred to as a "saxophone penis". **D** Perianal tags and indurated plaques. **E** Firm erythematous plaques of the mons pubis and labia majora and minora. There are also draining sinuses. *A, Courtesy, Julie V. Schaffer, MD; B,D, Courtesy, Misha Rosenbach, MD; C, E, Courtesy, Luis Requena, MD; D, Courtesy, Mary Stone, MD.*

| FEATURES OF SELECTED FOREIGN BODY REACTIONS | | |
|---|---|---|
| **Foreign body** | **Clinical presentations** | **Cause/common site(s)** |
| **Endogenous material** | | |
| Keratin | • Erythema, induration, papules, nodules<br>• Pseudofolliculitis/acne keloidalis nuchae<br>• Pyogenic granuloma-like lesions<br>• Pilonidal disease | • Ruptured follicle/cyst<br>• Ingrown hair/nail<br>• Beard area<br>• Neck<br>• Sacral area |
| **Generally exogenous material** | | |
| Tattoo pigment | • Erythema, induration, papules, nodules (Fig. 78.12)<br>• Lichenoid papules and plaques<br>• Eczematous dermatitis (including photoallergic reactions) | • Decorative/cosmetic<br>• Accidental (Fig. 78.13)<br>• Iatrogenic |
| Silica (silicon dioxide) | • Nodules, indurated plaques within scar (Fig. 78.14)<br>• Disseminated papules (blast injury)<br>• Prolonged incubation period (sometimes decades) | • Wound contamination<br>• Blast injury |
| Zirconium | • Persistent, brown, soft papules<br>• Involvement of axillary skin | • Topical application of deodorants, antipruritic medications |
| Beryllium | • Nodule, ulcer<br>• Widely scattered papules (systemic reaction) | • Laceration by broken fluorescent lamps<br>• Inhalation |
| Cactus | • Dome-shaped, skin-colored papules with a central black dot | • Accidental<br>• Occupational |
| Jellyfish, corals, sea urchin spines | • Pruritic lichenoid papules and plaques (onset 2–3 weeks after exposure)<br>• Linear, zigzag, and whip-like (flagellate) patterns of erythema/edema (early), hyperpigmentation or lichenoid papules (late) (Fig. 78.15) | • Accidental<br>• Swimming or diving |
| **Implanted/injected material during procedures (Fig. 78.16)** | | |
| Suture | • Wound/scar appears inflamed and edematous (or develops papules or nodules) and opens to form a fistula | |
| Intralesional corticosteroids | • Skin-colored to yellow-white papules or nodules develop at the site of a previous intralesional injection of corticosteroid<br>• Incubation period varies from weeks to months | |
| Talc | • Sarcoidosis-like papules<br>• Thickening and erythema of an old scar<br>• Involvement of intertriginous zones, IV injection sites (e.g. self-prepared drugs)<br>• Pyogenic granuloma-like papulonodules of the umbilicus in infants (following talc application to umbilical stump) | |
| Starch | • Papules and nodules | |
| Aluminum | • Persistent subcutaneous nodule at vaccine injection site | |
| Zinc | • Furuncles at insulin injection sites | |

**Table 78.3 Features of selected foreign body reactions.** *Continued*

| FEATURES OF SELECTED FOREIGN BODY REACTIONS | | |
|---|---|---|
| **Foreign body** | **Clinical presentations** | **Cause/common site(s)** |
| **Injected material for tissue augmentation** | | |
| Paraffin | • Firm nodules, indurated plaques on genitalia or breasts<br>• Ulceration or abscess formation (Fig. 78.17)<br>• Occasionally periorbital (due to topical paraffin-containing preparations) | |
| Silicone | • Erythema, induration, nodules, ulcers on breasts<br>• Often appears after years<br>• Sometimes injected into the buttocks or face for cosmetic purposes, including for HIV-associated lipodystrophy (Fig. 78.18; see Ch. 84) | |
| Bovine collagen,* hyaluronic acid,* fillers containing synthetic particles | • Generally injected into the face<br>• Induration and erythema<br>• Papules and nodules (Fig. 78.19)<br>• Abscesses | |

*Often resorbable.*

**Table 78.3** *Continued* **Features of selected foreign body reactions.**



**Fig. 78.12 Granulomatous reaction within the red portions of a tattoo.** Over the past several years, cinnabar (mercuric sulfide) has been gradually replaced by cadmium selenide (cadmium red), ferric hydrate (sienna), and organic compounds. *Courtesy, Lorenzo Cerroni, MD.*



**Fig. 78.13 Traumatic tattoo of the eyelid due to asphalt following a motor vehicle accident.** This type of tattoo responds favorably to Q-switched laser therapy. *Courtesy, M. Abdel Rahim Abdallah, MD.*



**Fig. 78.14 Silica granulomas.** *Courtesy, Kenneth Greer, MD.*



**Fig. 78.15 Coral envenomation.** Delayed lichenoid reaction on the calf. The patient accidentally came into contact with a coral reef and developed acute dermatitis that resolved, to be followed 3 weeks later by this severely itchy eruption that responded favorably to intralesional triamcinolone injection. *Courtesy, M. A. Abdallah, MD.*



**Fig. 78.17 Sclerosing lipogranuloma of the penis.** The penis was injected in order to relieve urinary retention following a motorbike accident, and an ulcerated, indurated yellow plaque with telangiectasias developed at the site. *Courtesy, Glen Foxton, MD, and Clare Tait, MD.*



**Fig. 78.16 Foreign body reactions to polyamide synthetic "hair" implantation.** In addition to multiple perifollicular granulomas, there is evidence of chronic folliculitis. *Courtesy, Marwa Abdallah, MD.*



**Fig. 78.18 Granulomatous reaction due to silicone injections.** The procedure was performed in a beauty salon for cosmetic purposes. *Courtesy, M. Abdel Rahim Abdallah, MD.*

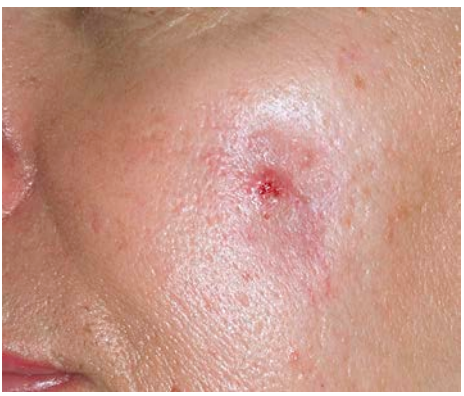

**Fig. 78.19 Foreign body reaction at site of bovine collagen injection.** Formation of granulomas at bovine collagen injection sites occurs in ~1% of patients who have had two negative skin tests. *Courtesy, YDRSC.*

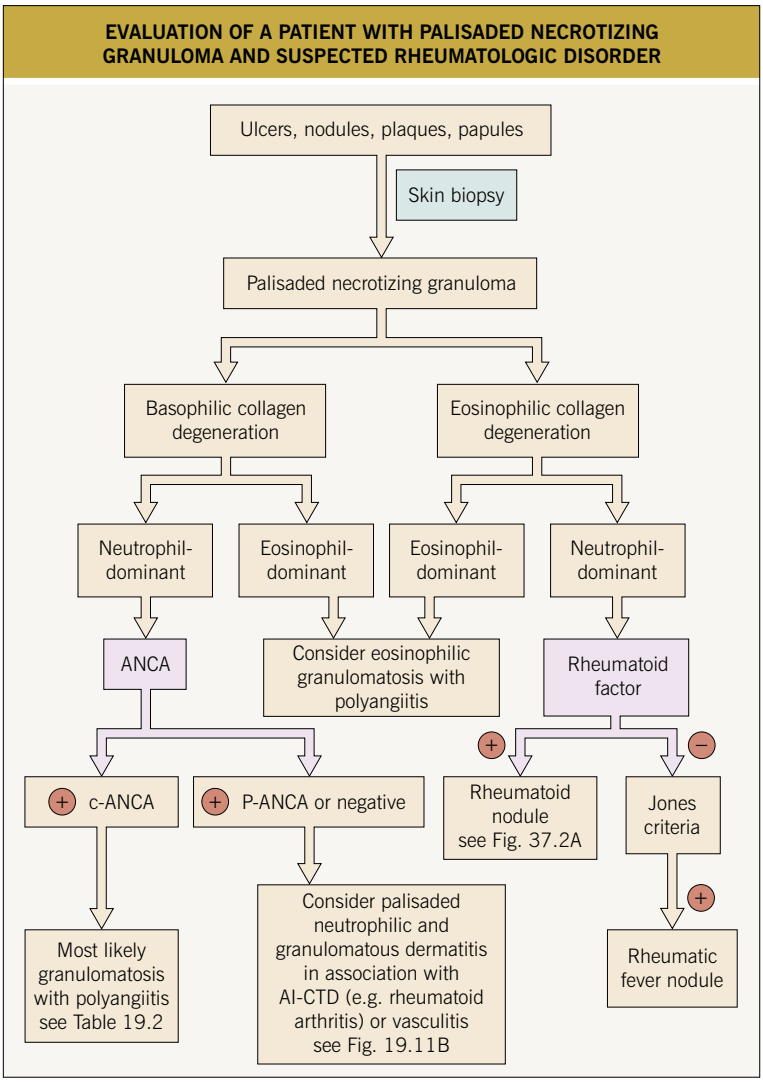


**eFig. 78.1 Evaluation of a patient with palisaded necrotizing granuloma and suspected rheumatologic disorder.** Jones major criteria for rheumatic fever in low-risk populations are carditis or valvulitis, polyarthritis, Sydenham chorea, erythema marginatum, and subcutaneous nodules; minor criteria are fever, polyarthralgia, and elevated acute phase reactants (ESR, C-reactive protein), and prolonged PR interval on an ECG. Two major or one major plus two minor criteria are required for diagnosis with evidence of an antecedent group A streptococcal infection. *Courtesy, Carlos H. Nousari, MD.*

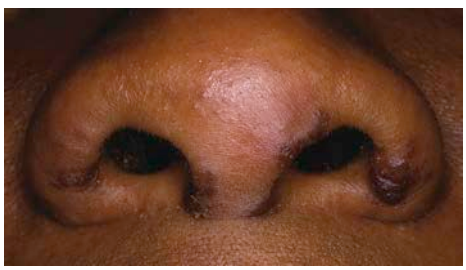

**eFig. 78.2 Sarcoidosis.** Lesions often favor the nose, lips, and perioral region. *Courtesy, Louis A. Fragola, Jr., MD*



**eFig. 78.3 Sarcoidosis.** Papules of cutaneous sarcoidosis arising within a tattoo; the differential diagnosis includes foreign body reaction. *Courtesy, YDRSC.*



**eFig. 78.4 Granuloma annulare.** Large lesion on the arm with a figurate border composed of coalescing papules. Note the red-brown color of previously involved skin. *Courtesy, YDRSC.*



**eFig. 78.5 Disseminated granuloma annulare in an HIV-infected patient.** *From Callen, JP, et al. Dermatological Signs of Internal Disease, 4th edn. 2009. Saunders: Philadelphia. Courtesy, Kalman Watsky, MD.*



**eFig. 78.6 Annular elastolytic giant cell granuloma.** The border resembles granuloma annulare but the central portion is hypopigmented and/or atrophic. A biopsy specimen that includes the area outlined would contain the three characteristic histologic zones: absence of elastic fibers, granulomatous inflammation, and normal skin. Longitudinal sectioning of the surgical specimen is preferred. *Courtesy, YDRSC.*



**eFig. 78.7 Cutaneous Crohn disease.** Note the swelling and violaceous discoloration of the labia majora in this prepubescent girl. *Courtesy, Joseph L. Jorizzo, MD.*



**eFig. 78.8 Granulomatous reaction to the red (cinnabar) portions of a tattoo.** During the past several years, cinnabar (mercuric sulfide) has been gradually replaced by cadmium selenide (cadmium red), ferric hydrate (sienna), and organic compounds. *Courtesy, Ronald P. Rapini, MD.*

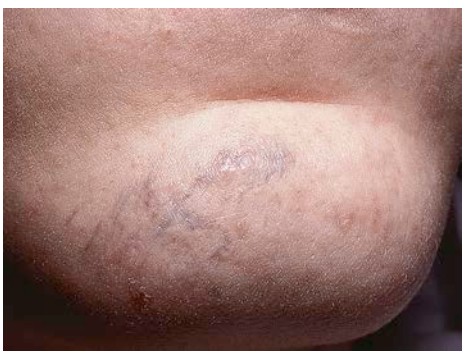

**eFig. 78.9 Traumatic tattoo of the chin.** Bluish discoloration and slight erythema, predominantly due to silica. *Courtesy, Ronald P. Rapini, MD.*



**eFig. 78.10 Granulomatous reaction to bovine collagen injection.** *Courtesy, YDRSC.*



**eFig. 78.11 Granuloma annulare.** *Courtesy, Karynne O. Duncan, MD.*



**eFig. 78.12 Erythema nodosum in a patient with sarcoidosis.** These patients often have hilar lymphadenopathy. Löfgren syndrome consists of erythema nodosum, hilar lymphadenopathy, fever, and arthritis. *Courtesy, Louis A. Fragola, Jr., MD.*

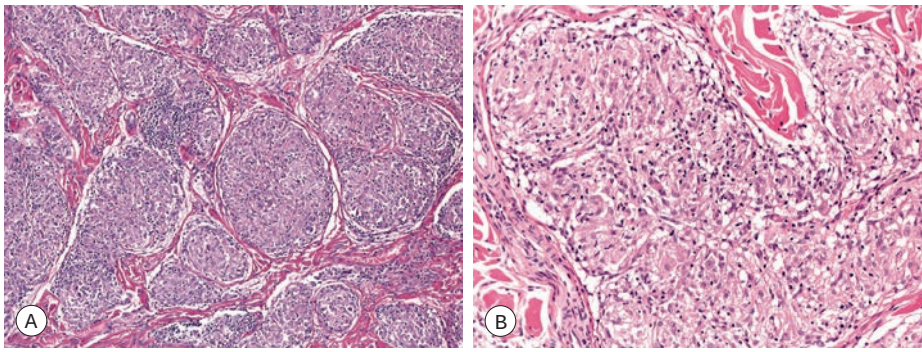


**eFig. 78.13 Cutaneous sarcoidosis – histopathologic features.** **A** Nodular aggregates of epithelioid histiocytes forming tubercles filling the dermis. **B** A sarcoidal tubercle with a sparse admixture of lymphocytes ("naked tubercle"). *Courtesy, Lorenzo Cerroni, MD.*



**eFig. 78.14 Granuloma annulare – generalized/disseminated variant.** Numerous small annular plaques on the trunk of a child. *Courtesy, Antonio Torrelo, MD.*

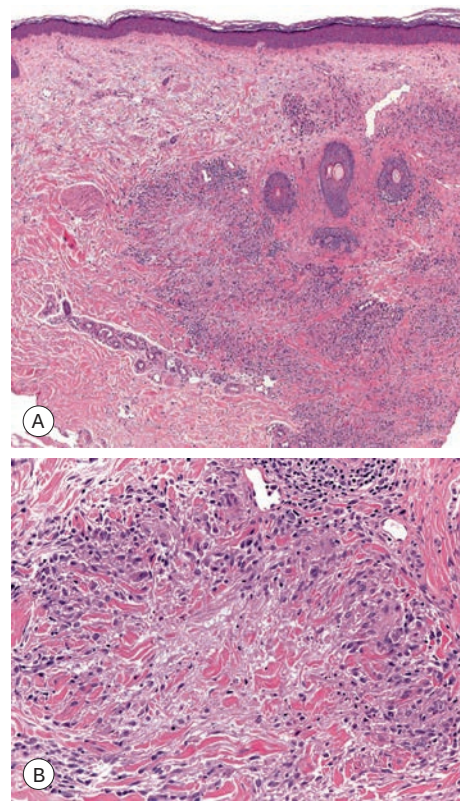


**eFig. 78.15 Granuloma annulare – palisading granuloma pattern.** **A** Multiple palisaded granulomas within the dermis. Degenerative collagen and mucin deposition are present in the central portion of the granulomas. **B** A palisaded granuloma with epithelioid histiocytes surrounding an anuclear dermis characterized by altered collagen and pallor due to deposition of acid mucopolysaccharides/glycosaminoglycans (mucin). *Courtesy, Lorenzo Cerroni, MD.*

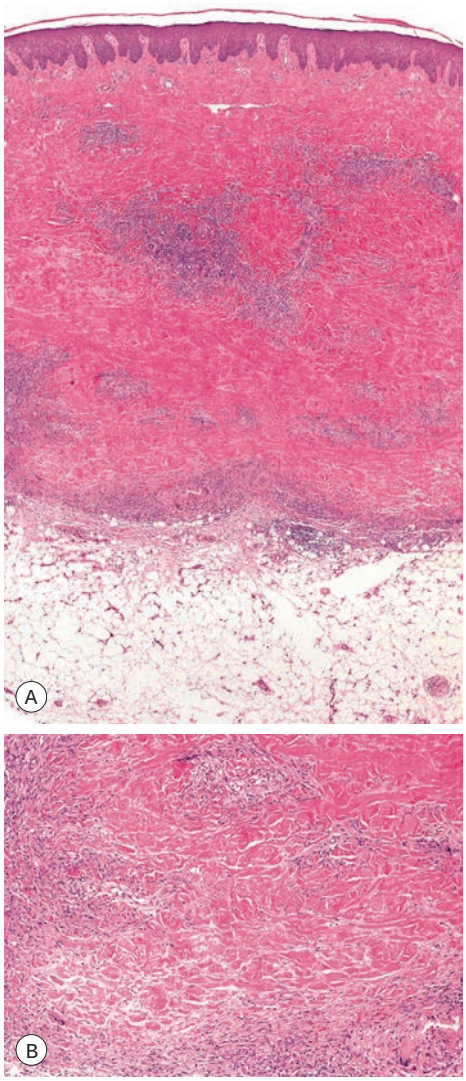


**eFig. 78.16 Necrobiosis lipoidica – histopathologic features. A** Multiple granulomas within the entire dermis extending into the subcutaneous fat. Note the layered tiers of granulomatous inflammation aligned parallel to the skin surface. **B** Palisaded granuloma composed of epithelioid histiocytes with altered collagen centrally. *Courtesy, Lorenzo Cerroni, MD.*

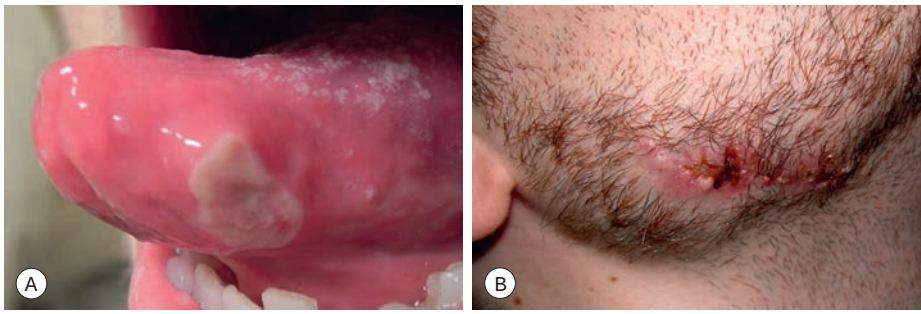


**eFig. 78.17 Cutaneous Crohn disease. A** Intraoral ulcer that resembles a major aphthous ulcer. **B** Ulcerated erythematous plaque of the mandible with draining sinuses. *A, Courtesy, Misha Rosenbach, MD; B, Courtesy, Luis Requena, MD.*



**eFig. 78.18 Interstitial granulomatous dermatitis – clinical features.** Multiple violet-brown plaques, some of which are annular, on the lower extremities of a young woman with mixed connective tissue disease. *Courtesy, Lorenzo Cerroni, MD.*

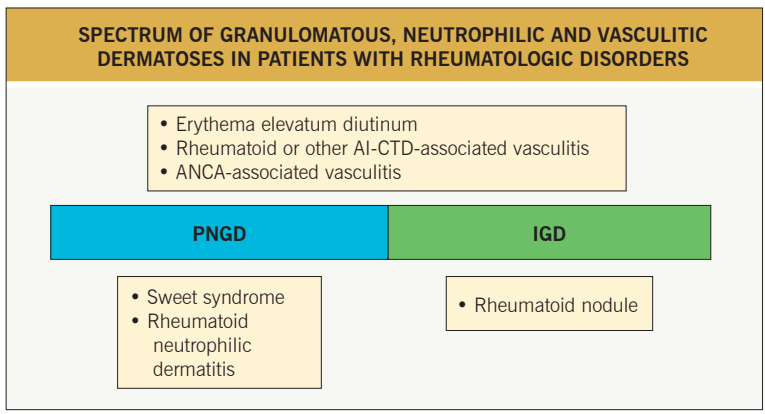


**eFig. 78.19 Spectrum of granulomatous, neutrophilic and vasculitic dermatoses in patients with rheumatologic disorders.** IGD, interstitial granulomatous dermatitis; PNGD, palisaded neutrophilic and granulomatous dermatitis. *Courtesy, Julie V. Schaffer, MD.*

| SPECTRUM OF CUTANEOUS MANIFESTATIONS OF SARCOIDOSIS | |
|---|---|
| **Common** | |
| • *Papules* – favor periorificial sites on face | • *Plaques* – favor trunk and extremities |
| • *Lupus pernio* – favors nose, ears and cheeks | • Scar-associated – initial insult weeks to decades prior |
| • *Tattoo-associated* – favors sites of red and yellow pigments | |
| **Uncommon** | |
| • *Annular* | • Atrophic – favors head and neck region |
| • Lichenoid | • *Psoriasiform* |
| • Subcutaneous (Darier–Roussy) – favors extremities | |
| **Rare** | |
| • Alopecia – scarring or nonscarring | • Angiolupoid – favors face and can mimic rosacea |
| • Erythrodermic | • *Hypopigmented* |
| • *Ichthyosiform* | • Micropapular |
| • Nail dystrophy – subungual hyperkeratosis, onycholysis | • Photodistributed/photo-exacerbated |
| • Ulcerative | • Verrucous |
| **Nonspecific and common** | |
| • *Erythema nodosum* | |

**eTable 78.1 Spectrum of cutaneous manifestations of sarcoidosis.** Photographs of entities in chapter or online in italics.

| SYSTEMIC MANIFESTATIONS OF SARCOIDOSIS | | | |
|---|---|---|---|
| **Organ** | **% of patients affected** | **Clinical manifestations/ radiographic and laboratory findings** | **Evaluation** |
| Lungs | 90–95 | Dyspnea, non-productive cough/pulmonary infiltrates, fibrosis, restrictive lung disease (↓VC, ↓RV, ↓TLC, ↓DLCO) | CXR, high resolution chest CT scan (more sensitive than CXR), PFTs that include DLCO |
| Lymph nodes (LN) | 30–40* | Lymphadenopathy/enlarged hilar and/or paratracheal LN | CXR, high resolution chest CT scan (more sensitive than CXR) |
| Eyes | 25 | Uveitis (can be asymptomatic despite being severe), conjunctivitis, sicca symptoms | Yearly ophthalmologic examination |
| Liver/spleen | 10–20 | Hepatomegaly and/or splenomegaly (rarely clinically relevant), cirrhosis, consequences of splenic enlargement (e.g. thrombocytopenia)/↑LFTs, ↓plts | • LFTs, physical examination<br>• If clinically relevant hypersplenism suspected, abdominal/pelvic CT scan (lymphadenopathy common finding) |

| SYSTEMIC MANIFESTATIONS OF SARCOIDOSIS | | | |
|---|---|---|---|
| **Organ** | **% of patients affected** | **Clinical manifestations/ radiographic and laboratory findings** | **Evaluation** |
| Heart | 25 (5% clinically relevant) | Palpitations, sudden death, CHF/arrhythmias, cardiomegaly | • ECG, echocardiogram, Holter monitor<br>• If any abnormalities on history, physical examination, or initial screening, referral to cardiologist and additional testing (PET scan, cardiac MRI) |
| CNS and peripheral nervous system | 10–20 | Neuropathies – cranial, spinal cord, peripheral, small fiber | • Dictated by symptoms (e.g. MRI, nerve conduction studies)<br>• Referral to neurologist |
| Upper respiratory tract, including sinuses | 5–10 | Sinusitis, nasal congestion, stridor, parotiditis | Referral to otolaryngologist and/or dedicated imaging |
| Bones | 5–10 | Usually asymptomatic/lytic bone lesions | Radiography |
| Joints/muscles | 5–10 | Arthritis, weakness (up to a third of patients have severe fatigue), myopathy | • Referral to rheumatologist<br>• EMG |
| Bone marrow | 50 | • Lymphopenia (↓$CD4^+$:$CD8^+$ ratio), leukopenia, eosinophilia, hypergammaglobulinemia, nonhemolytic anemia (5%)<br>• Elevated risk of developing lymphoma is debatable** | CBC, SPEP |
| Kidneys | 10–40 | Nephrolithiasis/hypercalciuria, ↓renal function | • BUN, Cr, serum calcium, spot urine calcium : Cr ratio, 24-hour urine for calcium excretion<br>• Referral to nephrologist |
| Endocrine | 5–10 | • Pituitary or thyroid dysfunction<br>• Hypercalcemia (increased calcitriol synthesis by sarcoidal histiocytes) | • Thyroid function tests<br>• Expanded hormonal testing when clinically indicated |
| Other | <1 (rare) | • "Masses" – GI tract (luminal), ovarian, testicular – often asymptomatic<br>• Granulomatous breast infiltration that can lead to ulceration | Site-specific imaging |

**Pertains to peripheral lymphadenopathy; up to 90% have hilar lymphadenopathy.*
***An association is based primarily on two studies, one of which found two cases of lymphoma in 2544 patients with sarcoidosis and the other had a standardized incidence ratio of 1.52 with a CI of 1.12–2.02. Multiple other studies have failed to find an association.*

**eTable 78.2 Systemic manifestations of sarcoidosis.** CHF, congestive heart failure; CXR, chest X-ray; DLCO, diffusing capacity for carbon monoxide; PET, positive emission tomography; PFTs, pulmonary function tests; plts, platelets; RV, residual volume; TLC, total lung capacity; VC, vital capacity. *Adapted from Chen ES, Moller DR. Sarcoidosis – scientific progress and clinical challenges. Nat Rev Rheumatol. 2011;7:457–67 and Haimovic A, Sanchez M, Judson MA, Prystowsky S. Sarcoidosis: a comprehensive review and update for the dermatologist: part I. Cutaneous disease. J Am Acad Dermatol. 2012;66:699.e1–18. Courtesy, Misha Rosenbach, MD.*

| TREATMENT OF CUTANEOUS SARCOIDOSIS |
|---|
| Topical or intralesional corticosteroids (2) |
| Topical calcineurin inhibitors (3) |
| Oral tetracyclines (e.g. minocycline, doxycycline) (2) |
| Oral hydroxychloroquine or chloroquine (2) |
| Methotrexate (2) |
| Systemic corticosteroids (2) |
| Thalidomide (2) |
| TNF inhibitors (adalimumab, infliximab)* (2) |
| Phosphodiesterase inhibitors (pentoxifylline, apremilast) (2) |
| Leflunomide (2) |
| Intralesional chloroquine (3) |
| Allopurinol (3) |
| Isotretinoin (3) |
| PUVA (psoralen plus UVA) (3) |
| Mycophenolate mofetil (3) |
| Pulsed dye or $CO_2$ laser (3) |
| Photodynamic therapy (3) |
| Surgical excision (3) |
| **Can trigger sarcoidosis.* |

**eTable 78.3 Treatment of cutaneous sarcoidosis.** Key to evidence-based support: (1) prospective controlled trial; (2) retrospective study or large case series; (3) small case series or individual case reports. TNF, tumor necrosis factor. *Adapted from Wanat KA, Rosenbach M. A practical approach to cutaneous sarcoidosis. Am J Clin Dermatol. 2014;15:283–97.*

| CAUSES OF INTERSTITIAL GRANULOMATOUS DRUG REACTION | |
|---|---|
| **Common** | |
| • **Calcium channel blockers**: diltiazem, verapamil, nifedipine<br>• Angiotensin-converting enzyme inhibitors: enalapril, lisinopril<br>• β-blockers: labetalol, metoprolol, atenolol, propranolol<br>• Furosemide<br>• **HMG-CoA reductase inhibitors**: simvastatin, pravastatin, lovastatin<br>• Antihistamines ($H_1$ or $H_2$ blockers): famotidine, cimetidine, ranitidine, brompheniramine<br>• **TNF inhibitors**: infliximab, etanercept, adalimumab; lenalidomide, thalidomide<br>• Anakinra | |
| **Uncommon** | |
| • Allopurinol<br>• Bupropion<br>• Carbamazepine<br>• Chinese herbal medications<br>• Darifenacin<br>• Diazepam<br>• HCTZ<br>• Febuxostat | • Ganciclovir<br>• Gemfibrozil<br>• Methotrexate<br>• Sennoside<br>• Sorafenib<br>• Soy<br>• Strontium ranelate<br>• Trastuzumab |

**eTable 78.4 Causes of interstitial granulomatous drug reaction.** These reactions are also referred to as drug-induced interstitial granulomatous dermatitis. Most common classes of drugs are in bold. HMG, β-hydroxy-β-methylglutaryl.

# 79 Perforating Disorders

Classically, a group of disorders in which there is transepidermal elimination ("perforation") of components of the dermis, in particular collagen and/or elastic fibers (Table 79.1). Etiologies are multiple and include inherited as an isolated cutaneous disease or inherited in association with genetic disorders that affect connective tissue (e.g. Ehlers–Danlos syndrome). Most commonly, however, the perforating disorder is acquired and is related to the cutaneous trauma that results from scratching pruritic skin, especially in the setting of chronic kidney disease. A number of other cutaneous diseases occasionally undergo perforation, e.g. granuloma annulare, calcinosis cutis, chondrodermatitis nodularis helicis.

## Acquired Perforating Dermatosis (APD)

- The most commonly observed perforating disorder (see Table 79.1); it is an acquired disease that affects primarily adults; the term APD encompasses several overlapping entities including *acquired* reactive perforating collagenosis (RPC), Kyrle disease, and perforating folliculitis.
- In general, affected individuals have pruritic skin that has been scratched; the vast majority of patients have chronic kidney disease and/or diabetes mellitus, with most of the latter individuals having diabetic nephropathy; it affects up to 10% of patients receiving chronic hemodialysis.
- Occurs less often in patients with pruritus due to other causes, e.g. insect bites, scabies, primary biliary cholangitis, Hodgkin disease.
- Erythematous, skin-colored or hyperpigmented papules and papulonodules with a central keratotic core that favor the extensor surfaces of the extremities (Figs 79.1–79.3); the central core is a reflection of the transepidermal elimination of collagen and/or elastic fibers as well as hyperkeratosis associated with epidermal hyperplasia.
- **DDx:** see Table 79.2.
- **Rx:** difficult; topical antipruritics (e.g. pramoxine), sedating antihistamines, CS-impregnated tape, intralesional CS, cryotherapy, tangential excision, Unna boot (impregnated gauze wrapping that serves as a physical barrier against scratching), NB- or BB-UVB, topical or oral retinoids.

## Elastosis Perforans Serpiginosa (EPS)

- Annular or serpiginous plaques composed of keratotic papules that are usually skin-colored (Fig. 79.4); lesions favor flexural sites, in particular the neck and antecubital fossae, and can be several centimeters in diameter.
- Occurs in patients with inherited disorders that affect connective tissue (~40% of cases of EPS; Fig. 79.5) or as a consequence of medications that disrupt elastin formation, e.g. penicillamine; in the first group, the onset is during childhood or early adulthood; there is also a skin-limited childhood form that may be inherited.
- Elastic fibers are surrounded by a hyperplastic epidermis and then eliminated transepidermally.
- **DDx:** see Table 79.2.
- **Rx:** lesions may spontaneously resolve over a period of years; cryotherapy, tangential excision, nonaggressive electrosurgical or laser therapy (to avoid scarring).

## Familial Reactive Perforating Collagenosis (RPC)

- Rare inherited disorder with an onset during childhood; affects sites of trauma, especially the arms and hands (Fig. 79.6).

Downloaded for Novin lib (novinlibrary@yahoo.com) at United Arab Emirates University from ClinicalKey.com by Elsevier on March 26, 2022. For personal use only. No other uses without permission. Copyright ©2022. Elsevier Inc. All rights reserved.

| MAJOR PERFORATING DISORDERS | | | | | |
|---|---|---|---|---|---|
| **Disease** | **Incidence** | **Time of onset** | **Most common location** | **Perforating substance** | **Associations** |
| Acquired perforating dermatosis (APD) | Common | Adulthood | Extensor extremities (legs > arms); occasionally generalized | Necrotic material +/or collagen >> elastic fibers | Pruritus, usually in the setting of chronic kidney disease +/or diabetes mellitus* affects 10% of patients on chronic hemodialysis |
| Elastosis perforans serpiginosa (EPS) | Rare | Childhood, early adulthood; variable if drug-induced | Flexures, especially neck, antecubital fossae; face | Elastic fibers | Genetic disorders (see Fig. 79.5); penicillamine |
| Familial reactive perforating collagenosis (RPC) | Rare | Childhood | Arms, hands, sites of trauma | Collagen | None |
| Perforating calcific elastosis | Rare, but more common in African-American women | Adulthood | Periumbilical, abdomen > breast | Calcified elastic tissue | Primarily multiparity, obesity; occasionally chronic kidney disease |
| Perforating folliculitis (in the absence of pruritus) | Uncommon | Early adulthood | Extremities, trunk | Necrotic tissue | May represent rupture of ordinary folliculitis |

**Occasionally affects patients with pruritus due to other disorders, e.g. scabies, Hodgkin disease, primary biliary cholangitis; can also be induced by several medications (see Fig. 79.5).*

**Table 79.1 Major perforating disorders.** *Courtesy, Ronald Rapini, MD.*



**Fig. 79.1 Acquired perforating dermatosis.** Numerous papules and papulonodules on the legs in a patient with diabetes mellitus and chronic kidney disease. Note the central keratotic core. *Courtesy, Ronald Rapini, MD.*



**Fig. 79.2 Acquired perforating dermatosis.** Keratotic papules on the arm of a diabetic woman on hemodialysis. Note the central keratotic core which is sometimes dislodged by the patient. *Courtesy, YDRSC.*

| DIFFERENTIAL DIAGNOSIS OF PERFORATING DISEASES |
|---|
| **Acquired perforating dermatosis and reactive perforating collagenosis** |
| • Excoriations from a variety of causes (prurigo simplex)<br>• Prurigo nodularis<br>• Folliculitis<br>• Arthropod bites<br>• Perforation of exogenous foreign material<br>• Perforation of endogenous substances (e.g. calcium)<br>• Multiple keratoacanthomas<br>• Dermatofibromas<br>• If Koebner phenomenon, psoriasis, lichen planus, verrucae (autoinoculation) |
| **Elastosis perforans serpiginosa (see Ch. 15 for DDx of annular lesions)** |
| • Granuloma annulare<br>• Tinea } Common annular diseases<br>• Sarcoidosis<br>• Annular elastolytic giant cell granuloma (actinic granuloma)<br>• Perforating pseudoxanthoma elasticum<br>• Porokeratosis<br>• Discoid lupus erythematosus |

**Table 79.2 Differential diagnosis of perforating diseases.** This is in addition to other perforating disorders discussed in this chapter.



**Fig. 79.3 Acquired perforating dermatosis.** Note the linear arrangement of the keratotic papules (Koebner phenomenon). *Courtesy, Ronald Rapini, MD.*




**Fig. 79.4 Elastosis perforans serpiginosa.** **A** Multiple annular plaques favoring the antecubital fossae, a flexural site. **B** Closer view with foci of hyperkeratosis at sites of transepidermal elimination. The patient had received penicillamine. *Courtesy, YDRSC.*

- Skin-colored papules with a central core composed of "perforating" collagen fibers; a linear array due to Koebner phenomenon may be seen.
- **DDx:** other perforating disorders, perforating GA.
- **Rx:** lesions spontaneously resolve over a period of a few months.

## Perforating Calcific Elastosis

- Most common site of involvement is periumbilical (Fig. 79.7); may be seen on the breast in the setting of chronic kidney disease.
- The periumbilical form favors obese, middle-aged, multiparous black women.
- Plaques usually have a keratotic or verrucous rim and may have a yellowish hue; histologically, calcified elastic fibers (with an appearance similar to the elastic fibers of pseudoxanthoma elasticum [PXE]) are undergoing transepidermal elimination.
- Although this entity has been referred to as perforating PXE, these patients do not have the genetic disorder PXE.

For further information see Ch. 96 from *Dermatology, Fourth Edition*.

**For additional online figures visit www.expertconsult.com**

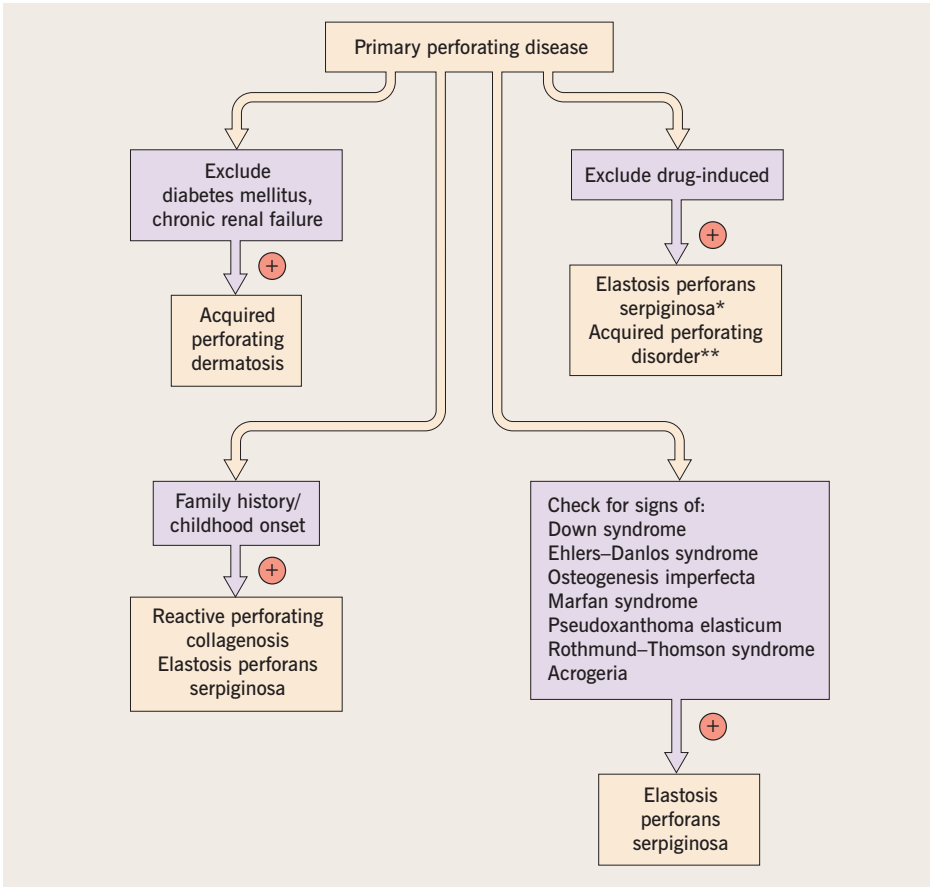


**Fig. 79.5 Approach to the patient with a primary perforating disease.** *Penicillamine. **Tumor necrosis factor inhibitors, epidermal growth factor receptor inhibitors (e.g. gefitinib) and other kinase inhibitors (e.g. nilotinib), antivirals (e.g. telaprevir, indinavir), sirolimus, several monoclonal antibodies (e.g. natalizumab, bevacizumab).



**Fig. 79.6 Reactive perforating collagenosis of the arm.** Several erythematous papules with a central scale-crust core. *Courtesy, Lorenzo Cerroni, MD.*



**Fig. 79.7 Perforating calcific elastosis.** When a biopsy was performed from the elevated edge of this supraumbilical plaque in a multiparous African-American woman, resistance was felt, as well as a grinding sound. *Courtesy, YDRSC.*



**eFig. 79.1 Elastosis perforans serpiginosa in the setting of Marfan disease.** Annular papules and plaques developed on the ear. *Courtesy, Ronald Rapini, MD.*

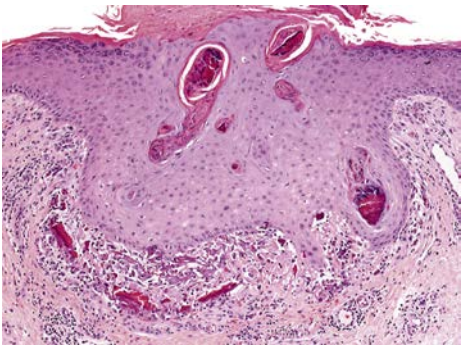

**eFig. 79.3 Elastosis perforans serpiginosa – histopathologic features.** Hyperplastic epidermis with transepidermal elimination of dermal elastic fibers via channels. The elastic fibers are characteristically brightly eosinophilic. Note the surface scale-crust. *Courtesy, Lorenzo Cerroni, MD.*



**eFig. 79.2 Elastosis perforans serpiginosa.** Papules arranged in an annular configuration on the neck. *Courtesy, Ronald Rapini, MD.*



**eFig. 79.4 Reactive perforating collagenosis.** This keratotic papule on the upper extremity followed minor trauma in a healthy man who had developed similar papules since childhood. *Courtesy, Ronald Rapini, MD.*

# Heritable Connective Tissue Disorders

# 80

Heritable connective tissue disorders present with a broad range of cutaneous and extracutaneous manifestations. Recognition of characteristic skin findings is often critical to establishing the diagnosis and identifying associated internal involvement, which may include life-threatening cardiovascular disease, e.g. in the vascular type of Ehlers–Danlos syndrome (EDS) and pseudoxanthoma elasticum (PXE).

## Ehlers–Danlos Syndrome

- Clinically and genetically heterogeneous group of connective tissue disorders caused by defective function of various collagens, extracellular matrix-processing enzymes, and associated proteins.
- The cardinal physical findings of hyperextensible, fragile skin and hypermobile joints (Fig. 80.1) are present to varying degrees in different subtypes of EDS (Table 80.1).
- Manifestations of cutaneous fragility include easy bruising (sometimes leading to suspicion of a bleeding disorder; see Fig. 80.1D) and gaping, "fish-mouth" wounds from minor trauma that heal with widened, atrophic scars (see Fig. 80.1C); additional findings may include smooth velvety skin, molluscoid pseudotumors (fleshy nodules in sites of repetitive trauma), subcutaneous spheroids over bony prominences (small, hard nodules that represent calcified fat lobules), piezogenic papules (see Ch. 82), and elastosis perforans serpiginosa (see Ch. 79).
- **Rx:** prevention of trauma; patients with the vascular type of EDS require close monitoring (especially during pregnancy) to avoid serious complications.

## Pseudoxanthoma Elasticum

- Uncommon autosomal recessive disorder characterized by distorted and calcified elastic fibers in the skin, eyes, and cardiovascular system; typically caused by mutations in the *ABCC6* gene, which encodes an ABC-cassette transporter (expressed primarily in the liver) that facilitates the export of anti-mineralization factors into the circulation.
- Skin changes and asymptomatic ocular findings usually appear during the first two decades of life, with ocular and cardiovascular complications typically developing in the third and fourth decades.
- Thin yellowish papules coalesce to form cobblestoned plaques (resembling "plucked chicken skin") on the lateral neck and in other flexural sites (e.g. antecubital and popliteal fossae, axillae, groin) (Fig. 80.2); decreased elasticity leads to sagging skin in affected areas (see Fig. 80.2D), and yellow papules on the oral mucosa may be evident (see Fig. 80.2E).
- Early ocular findings include angioid streaks, which reflect breaks in the calcified elastic lamina of Bruch's membrane (also seen in other metabolic/genetic disorders, e.g. sickle cell anemia), and mottling of the retinal pigment epithelium; choroidal neovascularization and hemorrhage can result in progressive loss of vision.
- Calcification of elastic fibers in the walls of medium-sized arteries leads to luminal narrowing and clinical sequelae such as intermittent claudication, renovascular hypertension, angina, myocardial infarction, and stroke; GI hemorrhage may also occur.
- **DDx:** PXE-like cutaneous and extracutaneous findings can be seen in generalized arterial calcification of infancy (*ENPP1* mutations), PXE-like disorder with coagulation factor deficiency (*GGCX* mutations), β-thalassemia, and sickle cell anemia; other conditions featuring PXE-like skin lesions are outlined in Table 80.2.
- **Rx:** an approach to management of PXE is presented in Table 80.3.




**Fig. 80.1 Clinical features of Ehlers–Danlos syndrome (EDS).** Patients with classic EDS demonstrating hyperextensible skin **(A),** joint hypermobility at the wrist **(B)**, and atrophic horseshoe-shaped scars on the shin **(C).** Extensive bruising on the shins in a patient with dermatosparaxis **(D)**; similar changes can be seen in vascular EDS. *A–C, Courtesy, Addenbrooke's Hospital, Cambridge, UK; D, Courtesy, Julie V. Schaffer, MD.*

## Cutis Laxa

- Heterogeneous group of heritable and acquired disorders (Table 80.4) characterized by loose, sagging skin due to sparse and fragmented elastic fibers.
- Skin involvement is often generalized, giving patients a prematurely aged appearance (Fig. 80.3), but it may be localized to acral or periorbital sites; cutaneous findings are present at birth in most heritable forms of cutis laxa, developing later in acquired cutis laxa and some autosomal dominant variants.
- Extracutaneous manifestations can include emphysema, hernias (e.g. umbilical, inguinal), diverticula (e.g. GI, genitourinary),

| MAJOR TYPES OF EHLERS–DANLOS SYNDROME | | | |
|---|---|---|---|
| **EDS type** | **Cutaneous findings** | **Extracutaneous manifestations** | **Inheritance, mutated protein** |
| Classic (I/II)* | Hyperextensible and fragile skin, with easy bruising and atrophic scars | Joint hypermobility, absence of inferior labial and lingual frenula, ability to touch nose with tongue (Gorlin sign) | AD, type V collagen |
| Hypermobility (III) | Hyperextensible skin | Joint hypermobility, pain and dislocations | AD, tenascin-X (F > M) |
| Vascular (IV)† | Thin, translucent skin with excessive bruising; decreased facial fat | Distal joint hypermobility; arterial, gastrointestinal, and uterine rupture | AD, type III collagen |
| Kyphoscoliosis (VIA) | Hyperextensible and fragile skin | Joint hypermobility, congenital scoliosis, osteopenia; neonatal hypotonia; ocular fragility | AR, lysyl hydroxylase |
| Musculocontractural (VIB) | Hyperextensible and fragile skin; wrinkled palms | Joint hypermobility, contractures, scoliosis, craniofacial anomalies; ocular fragility | AR, dermatan-4-sulfotransferase 1 or dermatan sulfate epimerase |
| Arthrochalasia (VIIA/B) | Hyperextensible and fragile skin | Severe joint hypermobility with congenital bilateral hip dislocation | AD, type I collagen |
| Dermatosparaxis (VIIC) | Sagging, doughy and extremely fragile skin, with easy bruising and tearing | Hernias; PROM; delayed closure of fontanelles, puffy eyelids, micrognathia | AR, procollagen I N-peptidase |

**Most common form of Ehlers–Danlos syndrome. Tenascin-X deficiency is an AR condition with similar findings except for normal scarring, and it may be associated with congenital adrenal hyperplasia due to a contiguous gene syndrome.*
*†Loeys–Dietz syndrome (see Table 80.5) can have a similar clinical presentation.*

**Table 80.1 Major types of Ehlers–Danlos syndrome.** AD, autosomal dominant; AR, autosomal recessive; PROM, premature rupture of fetal membranes.

cardiovascular defects, musculoskeletal or craniofacial anomalies, and developmental delay; these findings are most common in autosomal recessive variants and occasionally occur in acquired forms.

- **DDx:** PXE and related conditions, middermal elastolysis (see Ch. 82), anetoderma (see Ch. 82; smaller, circumscribed lesions), hereditary gelsolin amyloidosis.
- **Rx:** reconstructive surgery for cutaneous disease; multidisciplinary approach for internal involvement.

## Other Disorders

- Additional heritable connective tissue disorders with cutaneous manifestations are summarized in Table 80.5.

For further information see Chs 95 and 97 from *Dermatology, Fourth Edition*.

**For additional online figures visit www.expertconsult.com**




**Fig. 80.2 Mucocutaneous findings in pseudoxanthoma elasticum.** Yellowish papules and "cobblestoned" plaques on the neck **(A, B)** and in the antecubital fossa **(C).** Thickened, yellowish, sagging skin in the axilla **(D)**. Yellow papules on the inner aspect of the lower lip **(E)**. *A, B, Courtesy, YDRSC; C, D, Courtesy, Julie V. Schaffer, MD; E, Courtesy, Addenbrooke's Hospital, Cambridge, UK.*

| DIFFERENTIAL DIAGNOSIS OF PSEUDOXANTHOMA ELASTICUM (PXE)-LIKE SKIN FINDINGS | | |
|---|---|---|
| **Disorder** | **Patient characteristics** | **Clinical features** |
| Actinic elastosis | Middle-aged and older adults with lightly pigmented skin and a history of chronic sun exposure | Yellow to gray, thickened, lax, finely to coarsely wrinkled skin; photodistribution on the lateral forehead, neck, dorsal aspect of the forearms |
| Perforating calcific elastosis* | 5th–8th decades; primarily multiparous black women** | Plaque composed of coalescing keratotic papules (most apparent at the periphery); periumbilical area >> breasts |
| PXE-like papillary dermal elastolysis (PPDE)† and white fibrous papulosis of the neck (WFPN)† | 5th–9th decades; primarily Caucasian women and (for WFPN) Japanese men | Multiple 2- to 3-mm yellow, skin-colored, or (in WFPN) whitish papules; in PPDE, coalesce to form plaques with a cobblestone appearance; neck > upper trunk, axillae, flexor forearms, lower abdomen |

**Also referred to as periumbilical perforating PXE.*
***Occasionally associated with an increased calcium-phosphate product in chronic kidney disease.*
*†Related conditions within the spectrum of fibroelastolytic papulosis; late-onset focal dermal elastosis has a similar clinical presentation.*

**Table 80.2 Differential diagnosis of pseudoxanthoma elasticum (PXE)-like skin findings.** Additional considerations may include PXE-like skin lesions in patients receiving D-penicillamine, exposed to saltpeter, or with chronic kidney disease, β-thalassemia, or sickle cell anemia.

| A MULTIDISCIPLINARY APPROACH TO THE MANAGEMENT OF PSEUDOXANTHOMA ELASTICUM |
|---|
| **General** |
| • Antioxidant and magnesium supplementation, moderate calcium intake<br>• Regular exercise, weight control, avoidance of smoking or excessive alcohol intake |
| **Skin** |
| • Surgical intervention for excessive skin folds |
| **Eyes** |
| • Biannual funduscopic examination, use of Amsler grid to assess for central visual field defects<br>• Use of sunglasses; avoidance of head trauma or heavy straining<br>• Laser photocoagulation or photodynamic therapy for choroidal neovascularization if visual symptoms<br>• Intravitreal injections of VEGF antagonists |
| **Cardiovascular system** |
| • Baseline electrocardiogram and echocardiogram, annual cardiac examination<br>• Low-dose acetylsalicylic acid (if not contraindicated), correction of hyperlipidemia and hypertension<br>• Pentoxyfylline, cilostazol or clopidogrel for intermittent claudication |

**Table 80.3 A multidisciplinary approach to the management of pseudoxanthoma elasticum.** VEGF, vascular endothelial growth factor.




**Fig. 80.3 Clinical features in cutis laxa. A** Loose skin and drooping jowls in an infant with heritable cutis laxa. **B** Sagging folds of skin giving a prematurely aged appearance to a man with acquired cutis laxa associated with multiple myeloma. *A, Courtesy, Thomas Schwarz, MD; B, Courtesy, Jeffrey P Callen, MD.*

| ETIOLOGIES OF CUTIS LAXA |
|---|
| **Hereditary cutis laxa** |
| **Defects in elastic fiber components**, e.g. elastin, fibulin-4/5 or latent TGF-β binding protein-4<br>Defective glycosylation and vesicular trafficking of elastic fiber components<br>Defective mitochondrial proline biosynthetic enzymes |
| **Acquired cutis laxa*** |
| **Skin disorders**, e.g. Sweet syndrome-like eruptions (Marshall syndrome),* urticaria/angioedema, drug eruptions, cutaneous lymphoma<br>**Monoclonal gammopathies** with various underlying plasma cell dyscrasias; cutis laxa may be acral or (especially with heavy chain disease) generalized<br>**Direct effects of drug intake**, particularly penicillamine |
| **Sometimes in the setting of $\alpha_1$-antitrypsin deficiency.* |

**Table 80.4 Etiologies of cutis laxa.** TGF-β, transforming growth factor-β.

| ADDITIONAL HERITABLE CONNECTIVE TISSUE DISORDERS WITH CUTANEOUS FINDINGS | | | |
|---|---|---|---|
| **Disease** | **Cutaneous findings** | **Extracutaneous manifestations** | **Inheritance, mutated protein** |
| Marfan syndrome | Striae, elastosis perforans serpiginosa, decreased fat in extremities | Tall stature with long limbs, arachnodactyly, scoliosis; lens subluxations (upward), myopia; dilation/dissection of ascending aorta* | AD, fibrillin-1 |
| Loeys–Dietz syndrome | Translucent skin, easy bruising, atrophic scarring, ± multiple facial milia | Marfanoid habitus, joint hypermobility; aortic aneurysms, arterial tortuosity; hypertelorism, bifid uvula | AD, TGF-β receptors 1 & 2, TGF-β2 & 3, SMAD family member 3 |
| Homocystinuria | Malar flush, livedo reticularis, diffuse pigmentary dilution, tissue paper-like scars | Marfanoid habitus, lens subluxations (downward), thrombosis, intellectual disability | AR, cystathionine synthase > other enzymes |
| Buschke–Ollendorff syndrome | Connective tissue nevi with increased elastin or collagen (dermatofibrosis lenticularis disseminata); occasionally cutaneous sclerosis associated with melorheostosis | Osteopoikilosis ("spotted" bones); occasionally melorheostosis (sclerotic bone resembling "dripping candle wax" on radiographs) | AD, LEM domain-containing 3 (antagonist of TGF-β signaling) |

**Rx:* *β-blockers and angiotensin II receptor blockers, which antagonize pathogenic TGF-β signaling.*

**Table 80.5 Additional heritable connective tissue disorders with cutaneous findings.** AD, autosomal dominant; AR, autosomal recessive; TGF-β, transforming growth factor-β.



**eFig. 80.1 Widened atrophic scar in classic Ehlers–Danlos syndrome.** *Courtesy, Franziska Ringpfeil, MD, and Jouni Uitto, MD, PhD.*



**eFig. 80.2 Piezogenic papules on the heel in classic Ehlers–Danlos syndrome.** *Courtesy, Addenbrooke's Hospital, Cambridge, UK.*



**eFig. 80.3 The Gorlin sign in classic Ehlers–Danlos syndrome.** *Courtesy, Franziska Ringpfeil, MD, and Jouni Uitto, MD, PhD.*



**eFig. 80.4 Molluscoid pseudotumors on the knees in a patient with Ehlers–Danlos syndrome.** *Courtesy, Addenbrooke's Hospital, Cambridge, UK.*



**eFig. 80.5 Typical facial features of the vascular type of Ehlers–Danlos syndrome.** *Courtesy, Addenbrooke's Hospital, Cambridge, UK.*

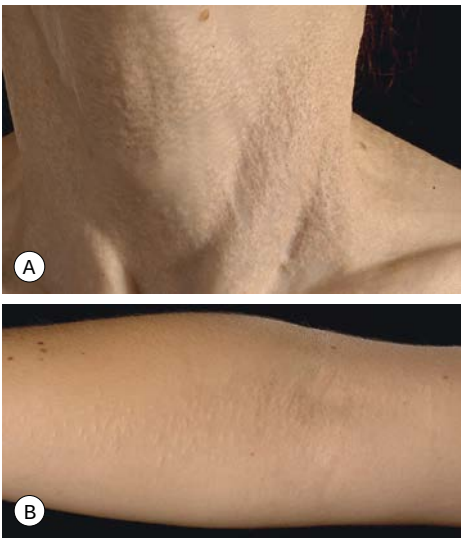


**eFig. 80.6 Clinical features of pseudoxanthoma elasticum.** Yellowish papules and cobblestone plaques on the neck (**A**) and antecubital fossa (**B**). *Courtesy, Addenbrooke's Hospital, Cambridge, UK.*

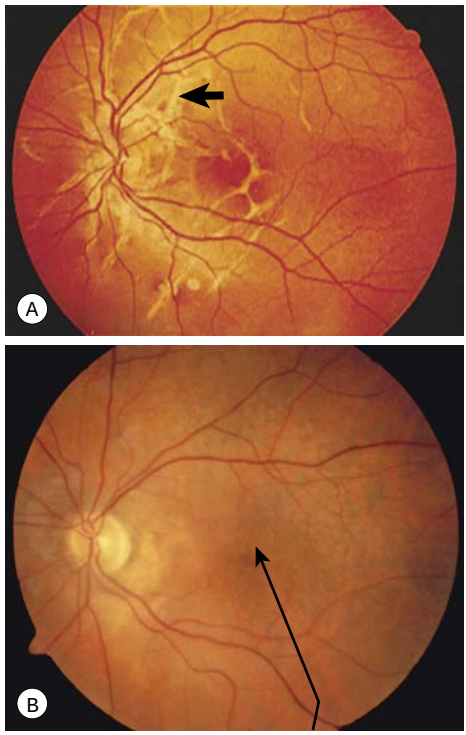


**eFig. 80.7 Funduscopic findings in pseudoxanthoma elasticum (PXE). A** Broad, lightly colored streaks (arrow) represent angioid streaks. **B** Mottling with "peau d'orange" color changes (arrow) over the entire retinal pigment epithelium, which may precede the onset of angioid streaks and represents the most common ophthalmologic finding in PXE. *Courtesy, Franziska Ringpfeil, MD, and Jouni Uitto, MD, PhD.*

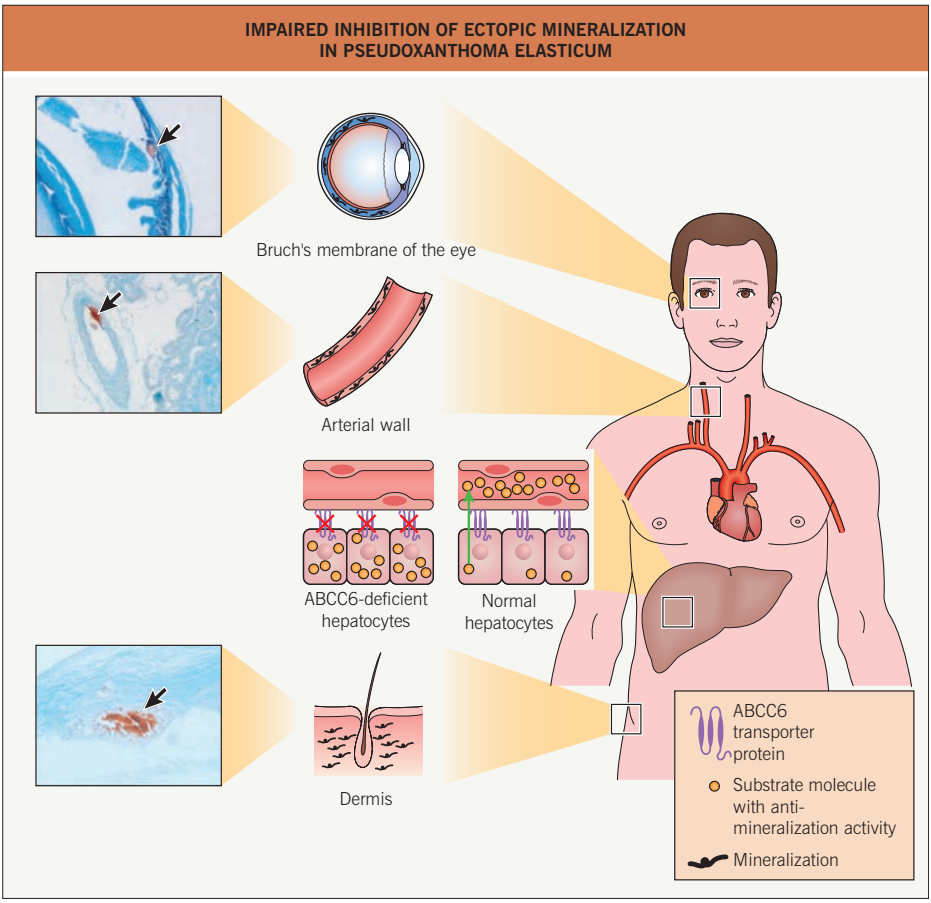


**eFig. 80.8 Impaired inhibition of ectopic mineralization in pseudoxanthoma elasticum.** The normal liver expresses high levels of the ABC-binding cassette subfamily C member 6 (ABCC6) protein, which serves as an efflux pump on the basolateral surface of hepatocytes, transporting molecules from inside these cells to the circulation. In patients with pseudoxanthoma elasticum (PXE), an absence of ABCC6 transporter activity in the liver results in reduced circulating concentrations of molecules that serve as physiologic anti-mineralization factors. This leads to calcification of connective tissues in the eye, arterial walls (media and intima) and dermis. The presence of calcium is evident on histopathological examination of these tissues (Alizarin red staining; see arrows in left panels) in $ABCC6^{-/-}$ mice, which recapitulate the features of human PXE. *Redrawn from Uitto J, Li Q, Jiang Q. Pseudoxanthoma elasticum: molecular genetics and putative pathomechanisms. J Invest Dermatol. 2010;130:661–70.*

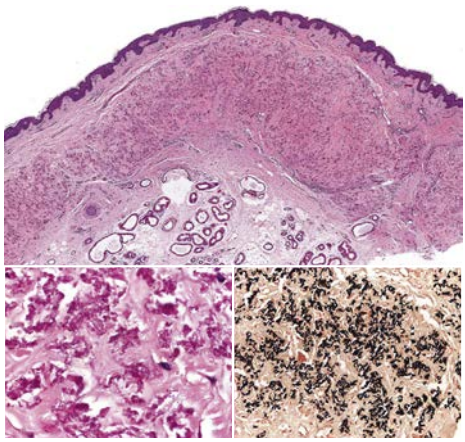

**eFig. 80.9 Histopathology of pseudoxanthoma elasticum (PXE).** Purple clumps in the mid and deep reticular dermis in H&E-stained sections represent calcium deposits on elastic fibers in advanced PXE (see left inset). An orcein stain highlights the fragmented, clumped elastic fibers (see right inset). *Courtesy, Lorenzo Cerroni, MD.*



**eFig. 80.10 Acquired cutis laxa associated with pseudoxanthoma elasticum-like skin changes from penicillamine use for cystinuria.** *Courtesy, Jonathan Leventhal, MD.*

# 81 Dermal Hypertrophies

## Hypertrophic Scar

- Firm, initially pink to purple in color then becomes skin-colored to hypopigmented, occasionally hyperpigmented; papule or plaque limited to an excision site or wound (Figs 81.1 and 81.2).
- Most commonly seen on the trunk and shoulders.
- Sometimes pruritic.
- With treatment, can reduce pruritus and height but not width of scar.
- **Rx** options include silicone gel sheets, intralesional triamcinolone (initially 5–10 mg/ml), re-excision (but may recur), laser (e.g. pulsed dye laser to improve color), massage/pressure, postoperative radiotherapy.

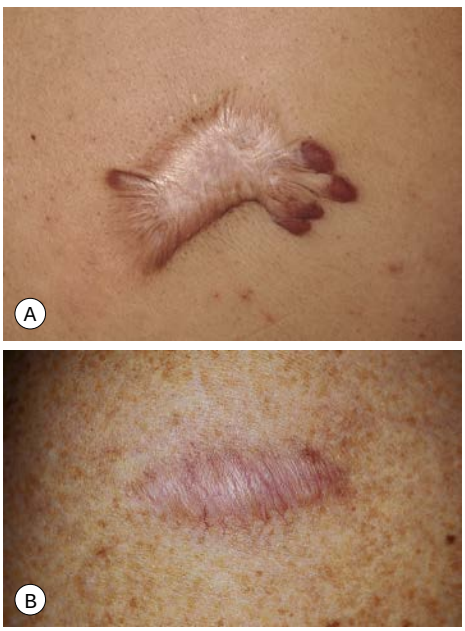


**Fig. 81.1 Comparison of a keloid and a hypertrophic scar. A** The keloid has claw-like extensions that extend beyond the original wound margin into adjacent normal skin. **B** The hypertrophic scar remains confined to the site of the original surgical wound. *A, Courtesy, Edward Cowen, MD; B, Courtesy, Jean L. Bolognia, MD.*

## Keloid

- More common in patients with darkly pigmented skin who have a familial predisposition.
- Rarely associated with syndromes (e.g. Rubinstein–Taybi or Goeminne syndromes).
- Raised, often skin-colored firm plaque(s) that, in contrast to hypertrophic scars, extend beyond the wound margin (Fig. 81.3; Table 81.1); color may vary as in hypertrophic scars.
- Follow trauma from surgical procedures (including ear piercing) and inflammatory disorders, especially acne, but can occur spontaneously (Fig. 81.4).
- Poor response to treatment.
- **Rx** options include silicone gel sheets; intralesional injections of triamcinolone (initially 10–20 mg/ml), interferon-α-2b, or 5-fluorouracil; pressure; laser (e.g. pulsed dye laser to improve color); excision followed by other modalities such as low-dose radiation or topical imiquimod.



**Fig. 81.2 Hypertrophic scar at the site of a knife injury.** *Courtesy, Luis Requena, MD.*

| CLINICAL FEATURES OF CONVENTIONAL SCARS, HYPERTROPHIC SCARS, AND KELOIDS | | | |
|---|---|---|---|
| | **Conventional scar** | **Hypertrophic scar** | **Keloid scar** |
| Preceded by injury | Yes | Yes | Not always |
| Onset | Immediate | Immediate | Delayed |
| Erythema | Temporary | Prominent | Varies |
| Profile | Flat | Raised | Raised |
| Symptomatic | No | Yes | Yes |
| Confined to wound margin | Yes | Yes | No |
| Increased mast cells | No | Yes | Yes |
| Spontaneous resolution | N/A | Possible, gradual | Rare |
| Treatment response | N/A | Good | Poor |

**Table 81.1 Clinical features of conventional scars, hypertrophic scars, and keloids.** N/A, not applicable.



**Fig. 81.3 Keloid of the chest, a common site.** Note the extension of the keloid into the normal surrounding skin and the central flattening in larger lesions. *Courtesy, Luis Requena, MD.*

## Dupuytren Disease

- Fibromatosis of the fascia of the ventral aspect of the digit and the palm.
- Starts as a linear thickening proximal to the fourth > fifth finger that is most apparent with extension of the digits.
- May gradually progress to flexion contractures (Fig. 81.5).
- Associated with other fibromatoses (e.g. plantar, penile), alcoholism, and diabetes mellitus; vemurafenib may cause new onset or worsening of existing disease.
- Surgical correction usually helpful; injection of collagenase also sometimes effective.




**Fig. 81.4 Keloids.** The upper trunk **(A)** and neck **(B)** are common sites. There is a higher prevalence of keloids in patients with darkly pigmented skin, but they can occur in individuals with any skin phototype. Note the extension of keloids into the normal surrounding skin in a claw-like manner. *A, Courtesy, Lorenzo Cerroni, MD; B, Courtesy, YDRSC.*



ALGrawany



**Fig. 81.5 Dupuytren disease.** Fibrotic nodule at the base of the fourth finger with an obvious cord extending proximally. In addition to palpation, fibrotic cords can be accentuated by extension of the digit. Eventually, flexion contractures develop. *Courtesy, Luis Requena, MD.*



**Fig. 81.6 Cutis verticis gyrata.** Cerebriform folding of the skin of the scalp. *Courtesy, Luis Requena, MD.*

## Elastic Tissue-Related Disorders

- See Figs 73.2A–C and E, 79.4, 79.7; Tables 80.2, 80.5.

## Cutis Verticis Gyrata

- Hypertrophy and linear folding of the scalp only (Fig. 81.6); male predominance with onset during puberty in idiopathic cases.
- Primary (idiopathic) form is more common and may be associated with systemic findings (neurologic, ophthalmologic).



**Fig. 81.7 Juvenile hyaline fibromatosis.** Firm pearly papules favor the ears. *Courtesy, YDRSC.*

- Secondary form associated with endocrinopathies (e.g. acromegaly, myxedema), insulin resistance, and genetic disorders (e.g. Turner syndrome).
- **DDx** includes several disorders, including benign tumors or hamartomas (e.g. cerebriform congenital melanocytic nevus of the scalp, plexiform neurofibroma), pachydermoperiostitis (involves the face and acral sites as well as the scalp), and dissecting cellulitis (scalp is boggy and painful).

## Hyaline Fibromatosis Syndrome (Juvenile Hyaline Fibromatosis and Infantile Systemic Hyalinosis)

- Autosomal recessive spectrum of disorders due to *ANTXR2* mutations.
- Presents during infancy or early childhood with papulonodules on the ears, hands, and periorificial areas (Fig. 81.7), in addition to gingival hypertrophy and flexion contractures.
- Severe form (infantile systemic hyalinosis) has internal organ involvement.

For further information see Ch. 98 from *Dermatology, Fourth Edition*.

**For additional online figures and table on treatment options visit www.expertconsult.com**

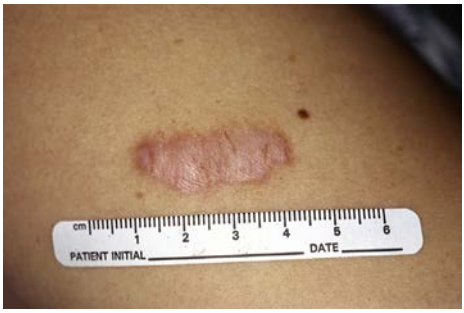


**eFig. 81.1 Hypertrophic scar at the site of an excision of an atypical melanocytic nevus.** The deltoid region is a common location for hypertrophic scars. *Courtesy, Jean L. Bolognia, MD.*



**eFig. 81.2 Multiple hypertrophic scars due to acne vulgaris.** The posterior trunk is a common location for hypertrophic scars. *Courtesy, Julie V. Schaffer, MD.*



**eFig. 81.3 Keloid of the flexor arm in an African-American man.** Note the extension of the keloid into the normal surrounding skin in a claw-like manner and the central involution. *Courtesy, Claude Burton, MD.*



**eFig. 81.4 Spontaneous generalized keloids.** Extensive spontaneous keloids in a patient with darkly pigmented skin. *Courtesy, Claude Burton, MD.*



**eFig. 81.5 Dupuytren disease.** There is greater involvement of the fifth finger than the fourth finger. Fibrotic cords can be felt and are accentuated by extension of the digits. Eventually, flexion contractures develop. *Courtesy, Jean L. Bolognia, MD.*



**eFig. 81.6 Cutis verticis gyrata.** Cerebriform folding of the skin of the scalp. Erythema in the posterior grooves is related to a previous superinfection. *Courtesy, NYUDSC.*



**eFig. 81.7 Spontaneous keloids.** This is a common site for their development. There is a higher prevalence of keloids in patients with darkly pigmented skin, but they can occur in individuals with any skin phototype. Note the extension of the keloids into the normal surrounding skin in a claw-like manner. *Courtesy, YDRSC.*

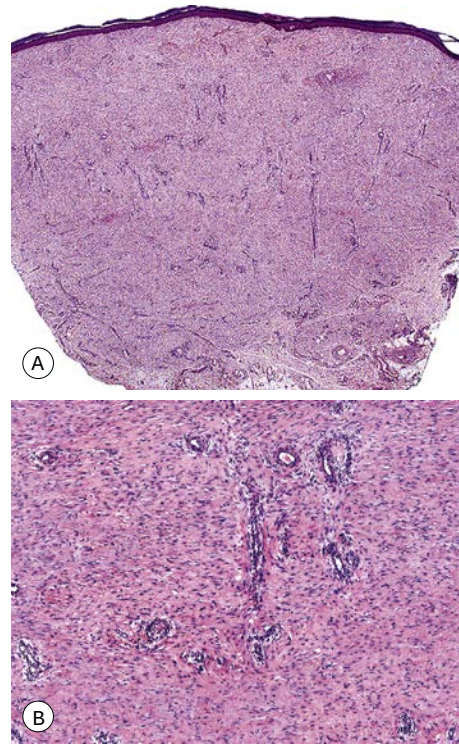


**eFig. 81.8 Hypertrophic scar – histopathologic features. A** Increased density of collagen fibers within the dermis and vertically oriented blood vessels. **B** Increase in the number of fibroblasts and density of collagen fibers, both of which are oriented horizontally (parallel to the epidermis). The central blood vessel is oriented vertically and there is a sparse perivascular inflammatory infiltrate. *Courtesy Luis Requena, MD.*

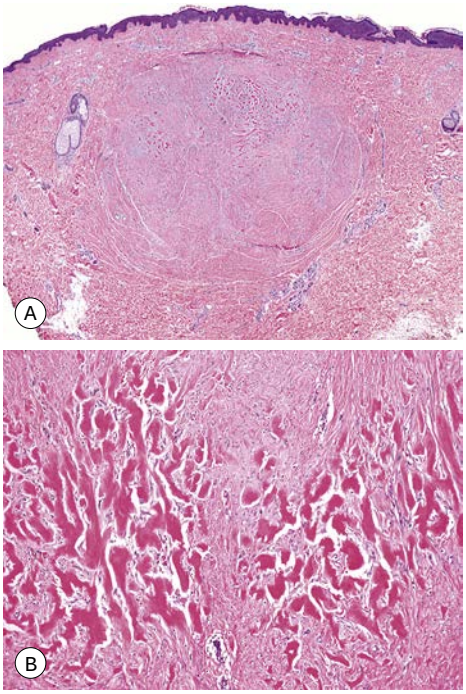


**eFig. 81.9 Keloid – histopathologic features. A** Nodules of thick collagen bundles are oriented haphazardly within the dermis (keloidal collagen). There is neither flattening of the epidermis nor involvement of the papillary dermis, and a sharp demarcation is seen between the normal-appearing papillary and reticular dermis and the nodules. **B** Strikingly thick, glassy, homogeneous collagen bundles composed of multiple, densely packed fibrils. *Courtesy, Lorenzo Cerroni, MD.*



**eFig. 81.10 Pachydermoperiostosis (primary hypertrophic osteoarthropathy).** There is exaggerated cutis verticis gyrata-like folding of the scalp skin. *Courtesy, Dr D. Timaná and Dr J. Valverde, Hospital Docente de Trujillo.*

| TREATMENT OPTIONS FOR HYPERTROPHIC SCARS AND KELOIDS | | |
|---|---|---|
| **Treatment** | **Mechanism(s) of action** | **Level of evidence** |
| Silicone sheeting | Reduction in collagen deposition due to an increase in temperature, hydration (reduces water vapor loss), and perhaps oxygen tension | 2 |
| Pressure therapy | Pressure-induced hypoxic effects lead to collagen and fibroblast degeneration | 2 |
| Onion extract (topical) | Decrease in inflammation and fibroblast proliferation rate | 1 |
| Vitamin E (topical) | Antioxidant properties | 2 |
| Triamcinolone (intralesional; 10–40 mg/ml)* | Inhibits fibroblast proliferation and collagen synthesis; vasoconstriction; decreases in TGF-β1 and TGF-β2 | 1 |
| 5-Fluorouracil (intralesional; 50 mg/ml not to exceed 100 mg/session; administered weekly) | Inhibits fibroblast proliferation | 2 |
| Bleomycin (1.5 IU/ml – multiple puncture technique; maximum 2 ml/cm$^2$ and 10 IU per session; once monthly) | Direct or indirect, TGF-β-mediated, inhibitory effects on collagen | 2 |
| Surgical scar revision | Reorientation and construction of multiple tension vectors | 2 |
| Cryosurgery (needles more effective than contact or spray; monthly × 3–10 months)* | Direct cellular freezing effects; post-thaw vascular stasis | 2 |
| Radiation therapy (postoperative [within 72 hours]; 10 Gy in a single dose; 6–15 Gy in 3–5 fractions) | Induction of fibroblast apoptosis; restoration of balance between synthesis and degradation of collagen within scar; damage to connective tissue stem cells | 2 |
| Laser therapy (pulsed dye laser [PDL] – can begin day of suture removal then every 3–4 weeks; $CO_2$ fractional laser*) | Induces wound contraction and collagen remodeling following thermal necrosis; decreased levels of TGF-β from heat shock response | 1 (PDL) |
| Avotermin (intralesional)** | Recombinant TGF-β3 (form of TGF associated with a reduction in scarring) | 1 (phase II trial; no difference in phase III trial) |
| Human recombinant interleukin-10 (intralesional)** | Anti-inflammatory activity | 1^,^^ |
| Mannose-6-phosphate (intralesional)** | Inhibition of TGF-β1 and TGF-β2 signaling (two forms of TGF associated with an increase in scarring) | 1^ |
| Insulin (intralesional) | Inhibitor of myofibroblasts | 1 |

**Cryotherapy or $CO_2$ laser sometimes administered prior to intralesional injections of corticosteroids.*

***Not commercially available.*

*^Based upon phase II trial.*

*^^In lightly, but not darkly, pigmented individuals. TGF, transforming growth factor.*

**eTable 81.1 Treatment options for hypertrophic scars and keloids – mechanisms of action and levels of evidence.** There are also reports of the use of topical retinoic acid, calcineurin inhibitors, imiquimod (deemed ineffective in controlled trials), and tamoxifen; botulinum toxin A; mitomycin C (topical or intralesional); and systemic methotrexate and calcium channel blockers. Treatments reserved for the treatment of keloids are shaded in darker brown. Key to evidence-based support: (1) prospective controlled trial; (2) retrospective study or large case series; (3) small case series or individual case reports. *Adapted from Tziotzios et al. J Am Acad Dermatol 2012;66:13–24. Courtesy, Salma Machan, MD, Ana María Molina-Ruiz, MD, Luis Requena, MD.*

# Atrophies of Connective Tissue 82

This chapter focuses primarily on entities in which there is a reduction in collagen and/or elastic tissue within the dermis. They vary from very common skin disorders such as striae to cutaneous manifestations of rare genetic syndromes. Loss of subcutaneous fat, i.e. lipoatrophy, is covered in Chapter 84, while acrodermatitis chronica atrophicans is covered in Chapter 97 and Ehlers–Danlos syndrome and cutis laxa are covered in Chapter 80.

## Striae (Distensae)

- Linear atrophic lesions that reflect dermal damage ("breaks") at sites of mechanical stress due to stretching of the skin, hence the popular term "stretch marks"; most commonly observed in adolescents undergoing growth spurts or weight gain and on the abdomen in up to 75% of pregnant women.
- Striae are multiple, symmetric, and arranged along the lines of cleavage, with the typical sites of involvement and characteristic patterns shown in Fig. 82.1; early lesions may be red-purple in color (striae rubra) but with time, most striae become skin-colored to white with fine wrinkling (striae alba) (Fig. 82.2).
- Additional causes include hypercortisolism (e.g. Cushing syndrome), application of potent topical CS (especially in areas of occlusion such as major body folds), and heredity; in weightlifters, mechanical stress and muscle enlargement can lead to striae.
- **DDx:** linear focal elastosis, in particular when lesions are present on the lower mid-back.
- **Rx:** difficult, but striae often become less noticeable over a period of years; possible modest improvement with topical tretinoin 0.1% cream; lasers (e.g. pulsed dye for striae rubra, 308 nm excimer for striae alba) have reportedly led to improvement.

## Pizogenic Pedal Papules (Piezogenic Papules)

- Herniations of fat in the heel region where there is reduced dermal connective tissue; the skin-colored papules appear with the pressure of weight-bearing and disappear when the leg is raised (Fig. 82.3A); occasionally they occur on the wrist.
- In an infantile variant, larger nodules occur on the medial aspect of the heel and their appearance does not require weight-bearing (Fig. 82.3B).

## Anetoderma

- Well-circumscribed, skin-colored, flaccid lesions that result from a marked focal decrease in elastic tissue within the dermis (Fig. 82.4).
- Often arises *de novo* (primary form), with lesions usually measuring 1–2 cm in diameter; there are also secondary forms of anetoderma that can follow inflammation or infection of the skin (e.g. varicella, lepromatous leprosy, acute cutaneous lupus) or are seen in association with cutaneous tumors (e.g. involuted infantile hemangiomas) or the antiphospholipid antibody syndrome.
- Anetoderma of prematurity presents as atrophic lesions resulting from minor iatrogenic trauma to immature skin in the setting of neonatal intensive care.
- Although the individual lesions of the primary form are often elevated, they can be even with the skin surface or depressed (Fig. 82.4C); however, all lesions are soft to palpation and the focal reduction in elastic tissue results in a feel similar to that of an abdominal hernia (referred to as a "buttonhole" sign, which is also seen in neurofibromas).

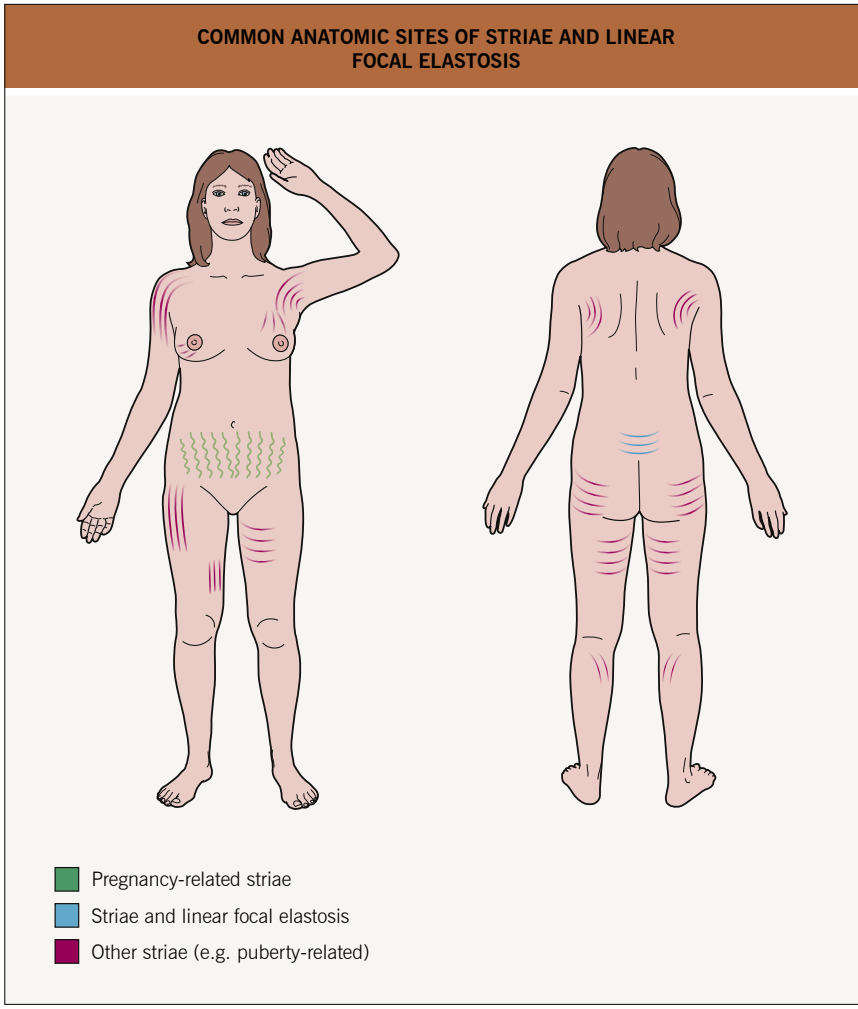


**Fig. 82.1 Common anatomic sites of striae and linear focal elastosis.** In teenage boys, striae are commonly seen in the same site and in the same orientation as focal elastosis.

- The primary form favors the neck, upper trunk, and upper extremities of young adults, with lesions appearing over a period of years, while the distribution pattern of the secondary form reflects that of the preceding inflammatory disorder.
- **DDx:** post-traumatic scars, papular elastorrhexis (similar clinical appearance but firm to palpation), anetoderma-like scars (perifollicular elastolysis) due to acne vulgaris, pseudoxanthoma elasticum-like papillary dermal elastolysis (flexural areas; see Table 80.2).
- **Rx:** difficult; for secondary form, treatment of underlying disease may prevent new lesions; surgical excision can lead to scars.

## Atrophoderma of Pasini and Pierini

- Minimally depressed hyperpigmented patches, primarily of the posterior trunk (Fig. 82.5); the characteristic "cliff-drop" sign at the peripheral edge may be subtle; significant overlap with "burnt-out" plaque-type morphea, and notably a minority of patients have both disorders.

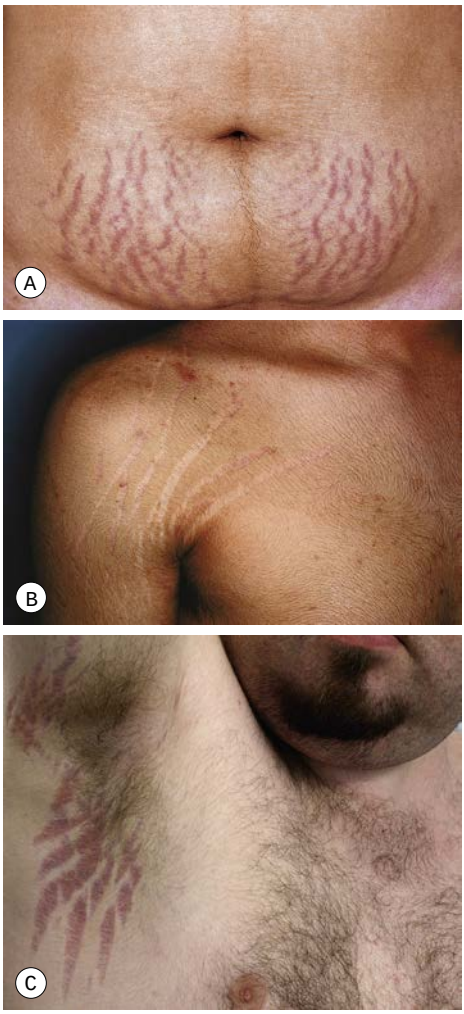


**Fig. 82.2 Striae. A** Linear erythematous lesions on the abdomen (striae rubra). **B** Multiple linear atrophic streaks of striae alba in a teenager. **C** Large axillary striae in a patient receiving chronic, high-dose systemic corticosteroids. *A, Courtesy, USCDRSC; B, Courtesy, Kalman Watsky, MD; C, Courtesy, YDRSC.*




**Fig. 82.3 Pizogenic pedal papules. A** Skin-colored to yellowish outpouchings on the heel represent herniation of subcutaneous fat through the plantar fascia and they are sometimes painful. **B** Soft nodules on the medial and plantar surface of the foot in an infant. *B, Courtesy, Julie V. Schaffer, MD.*

• Onset typically during adolescence or young adulthood; the patches are often oval in shape, 2–8 cm in diameter, number from one to several, and persist for decades; rarely, lesions are present at birth or arise along the lines of Blaschko (atrophoderma of Moulin; Fig. 82.6; see Ch. 51).
• Because the reduction in the thickness of the dermis is subtle, an elliptical biopsy that includes both involved and uninvolved skin and is sectioned longitudinally is usually required for diagnosis.
• **DDx:** morphea, but in contrast to atrophoderma, induration and/or an inflammatory rim is observed; postinflammatory hyperpigmentation; if a limited number of lesions, dermatofibrosarcoma protuberans (primarily in children).
• **Rx:** difficult; modest improvement in hyperpigmentation reported with pigment-specific laser therapy.

## Mid-Dermal Elastolysis

• Idiopathic disorder characterized by large, skin-colored patches with fine wrinkling and occasionally follicular papules with central delling; the lesions are often clinically subtle (Fig. 82.7) and histologically, there is a selective loss of elastic tissue in the mid dermis best demonstrated by special elastic stains.
• Most commonly affects the trunk, neck, and arms of middle-aged Caucasian women.
• **DDx:** the major entity is generalized acquired cutis laxa.
• **Rx:** none currently available.




**Fig. 82.4 Anetoderma – primary and secondary.** Lesions can range from soft, skin-colored papules that herniate upon palpation **(A)** to flaccid papules that have a central depression **(B)**. The upper trunk and neck is a common location for primary anetoderma; an admixture of elevated, macular and depressed lesions is seen **(C)**. Wrinkling of the skin from secondary anetoderma due to sarcoidosis **(D)** and lepromatous leprosy **(E).** *A, Courtesy, Ronald Rapini, MD; B, Courtesy, Catherine Maari, MD, and Julie Powell, MD; C, Courtesy, Thomas Schwarz, MD; D, Courtesy, Catherine Maari, MD, and Julie Powell, MD; E, Courtesy, Louis A. Fragola, Jr., MD.*

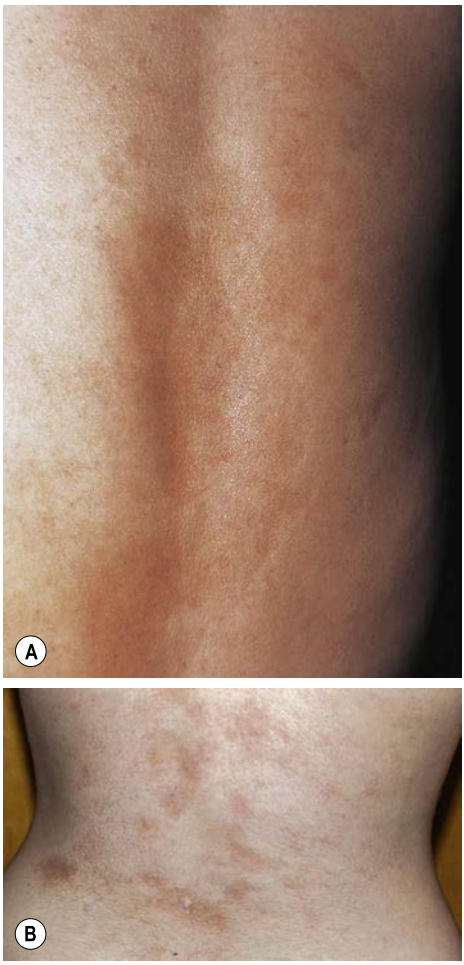


**Fig. 82.5 Atrophoderma of Pasini and Pierini. A, B** Multiple light brown patches on the back; note the subtle depression of the lesions with a "cliff-drop" edge. In **(B)**, dermal blood vessels are seen within a few patches; the white papule is a healed biopsy site. *A, Courtesy, Catherine C. McCuaig, MD; B, Courtesy, Julie V. Schaffer, MD.*



**Fig. 82.6 Atrophoderma of Moulin.** Linear hyperpigmented streaks along the lines of Blaschko. Note the subtle depression of the lesions on the upper lateral thigh. *Courtesy, Jean L. Bolognia, MD.*

## Follicular Atrophoderma

- Small depressions at the sites of hair follicles.
- Clinical presentations include:
  - As atrophoderma vermiculatum of the cheeks (Fig. 82.8), which can be sporadic, inherited in an autosomal dominant manner, or be a component of the keratosis pilaris atrophicans spectrum in which there is also follicular hyperkeratosis (Table 82.1; Fig. 82.9)
  - As patulous follicles on the dorsal aspect of the hands and feet in the X-linked dominant Bazex–Dupré–Christol syndrome in which patients also develop BCCs and alopecia
  - As follicular pits within streaks along the lines of Blaschko in the X-linked dominant disorder Conradi–Hünermann–Happle syndrome (form of chondrodysplasia punctata)

## Atrophia Macularis Varicelliformis Cutis (AMVC)

- Acquired thin linear depressions on the face that measure 2–10 mm in length and can be admixed with small circular depressions; there is no history of preceding inflammation, acne, or trauma (Fig. 82.10).

For further information see Ch. 99 from *Dermatology, Fourth Edition*.




**Fig. 82.7 Mid-dermal elastolysis. A** Large patch with fine wrinkling and a slightly reticulated border on the upper back and shoulder. The junction of involved and uninvolved skin is marked with an arrow. **B** Both circumscribed areas of wrinkling and follicular papules are present. *A, Courtesy, Judit Stenn, MD; B, Courtesy, Lorenzo Cerroni, MD.*



**Fig. 82.8 Atrophoderma vermiculatum.** Multiple small pitted scars on the cheek of a young girl. Note the honeycomb pattern on the lower inner cheek; the skin is said to appear "worm-eaten." The atrophic lesions may be preceded by inflammatory papules. *Courtesy, Robert Hartmann, MD.*

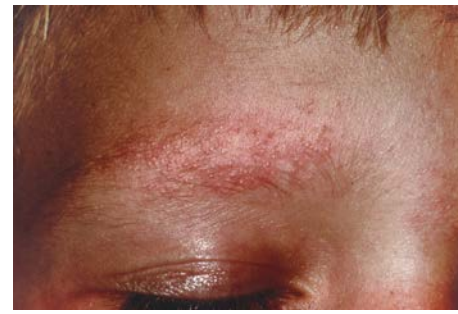

**Fig. 82.9 Ulerythema ophryogenes.** Alopecia of the eyebrows admixed with tiny follicular papules with a thin erythematous rim. *Courtesy, Jean L. Bolognia, MD.*

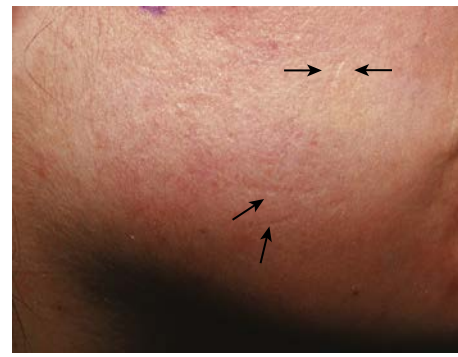

**Fig. 82.10 Atrophia macularis varicelliformis cutis.** Multiple linear scar-like depressions (between and above arrows) with no history of trauma. *Courtesy, Jean L. Bolognia, MD.*

| THE SPECTRUM OF KERATOSIS PILARIS ATROPHICANS | | | | | | |
|---|---|---|---|---|---|---|
| **Disorder** | **Mode of inheritance** | **Age of onset** | **Distribution** | **Cutaneous features** | **KP*** | **Other findings and associations** |
| Keratosis pilaris atrophicans faciei (ulerythema ophryogenes) | AD<br>AR (*LRP1* mutations) | Infancy | Eyebrows, particularly the lateral third (Fig. 82.9) > temples, cheeks, forehead | • Erythematous follicular papules with central keratotic plugs, eventuating in follicular atrophy<br>• Scarring alopecia of the lateral eyebrows distinguishes it from KP rubra | + | Associated with Noonan syndrome and other RASopathies |
| Atrophoderma vermiculata | See text and Fig. 82.8 | | | | – | |
| Keratosis follicularis spinulosa decalvans (KFSD) | XR (*MBTPS2* mutations) | Childhood | Face, scalp, limbs, trunk | • Erythematous follicular papules with central keratotic plugs, eventuating in follicular atrophy<br>• Scarring alopecia of the scalp, eyebrows, and eyelashes | ++ | • Palmoplantar keratoderma, facial erythema<br>• Keratitis, photophobia |

**Associated keratosis pilaris (KP) on the extremities and trunk, which does not typically eventuate in atrophy.*

**Table 82.1 The spectrum of keratosis pilaris atrophicans.** There is also an autosomal dominant form of KFSD with scalp involvement. AD, autosomal dominant; MBTPS2, membrane-bound transcription factor peptidase, site 2 (involved in sterol regulation); XR, X-linked recessive; +, mild to moderate; ++, severe.



**eFig. 82.1 Linear focal elastosis.** This is the most common site of involvement. Note that the lesions are elevated and yellowish in color. In teenage boys, striae are commonly seen in the same site and in the same orientation as focal elastosis. *Courtesy, YDRSC.*

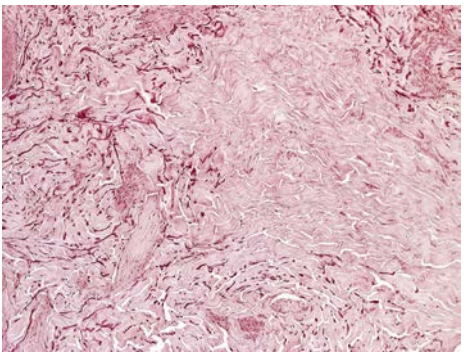

**eFig. 82.2 Anetoderma – histopathologic features.** A decrease of elastic fibers in both the papillary and reticular dermis (Weigert's stain). *Courtesy, Lorenzo Cerroni, MD.*







**eFig. 82.3 Linear atrophoderma of Moulin. A**,**B** Hyperpigmented depressions with "cliff-drop" borders following the lines of Blaschko. The morphology of the lesions resembles that of atrophoderma of Pasini and Pierini. *Courtesy, Julie V. Schaffer, MD.*

| SECONDARY ANETODERMA – ASSOCIATED CONDITIONS | |
|---|---|
| **Infectious** | Varicella<br>Folliculitis<br>Syphilis (cutaneous)<br>Lepromatous leprosy<br>Molluscum contagiosum<br>Tuberculosis (cutaneous)<br>HIV infection<br>Acrodermatitis chronica atrophicans<br>Post-hepatitis B immunization |
| **Drugs** | Penicillamine |
| **Inflammatory** | Acne vulgaris<br>Mastocytosis<br>Lichen planus<br>Granuloma annulare<br>Juvenile xanthogranuloma<br>Cutaneous sarcoidosis<br>Cutaneous lymphoid hyperplasia (lymphocytoma cutis)<br>Prurigo nodularis<br>Insect bites |
| **Autoimmune** | Discoid and systemic lupus erythematosus<br>Antiphospholipid syndrome<br>Primary Sjögren syndrome<br>Addison disease<br>Graves disease |
| **Tumors and depositions** | Involuted infantile hemangioma<br>Pilomatricoma<br>Melanocytic nevus<br>Dermatofibroma<br>Dermatofibrosarcoma protuberans<br>Primary cutaneous marginal zone B-cell lymphoma (formerly primary cutaneous plasmacytoma or immunocytoma)<br>Mycosis fungoides<br>Nodular amyloidosis<br>Xanthoma |

**eTable. 82.1 Secondary anetoderma – associated conditions.**

# 83 Panniculitis

## Introduction

- Adipose tissue plays many active roles in the body beyond insulation, e.g. storing and releasing lipids, mediating inflammation, and modulating endocrine and reproductive systems.
- Panniculitis = inflammation of adipose tissue.
- Clinically and histopathologically, the adipose tissue has a limited repertoire of responses to insults and inflammation.
- Most often clinically presents as tender, inflamed, subcutaneous nodules or plaques; with the exception of erythema nodosum, ulceration with drainage may develop.
- There are various etiologies, and a clinical classification system is presented in Table 83.1.
- Diagnosis is challenging and involves consideration of (1) patient characteristics such as age, immune status, underlying dis-

| CLINICAL CLASSIFICATION OF THE PANNICULITIDES |
|---|
| **Reactive panniculitis** |
| • Erythema nodosum (EN)<br>• Subacute nodular migratory panniculitis<br>• Erythema induratum (EI) |
| **Predominantly childhood panniculitis (see Table 83.3)** |
| **Metabolic panniculitis** |
| • $\alpha_1$-Antitrypsin deficiency panniculitis<br>• Pancreatic panniculitis |
| **Connective tissue disease panniculitis** |
| • Lupus erythematosus panniculitis<br>• Dermatomyositis-associated panniculitis<br>• Morphea/systemic sclerosis (see Chs 35 and 36) |
| **Physical/traumatic panniculitis** |
| • Cold panniculitis<br>• Factitial panniculitis<br>• Blunt trauma panniculitis<br>• Injection-related panniculitis (e.g. abatacept, glatiramer acetate)<br>• Sclerosing lipogranuloma |
| **Infection-induced panniculitis (see Table 83.2)** |
| **Panniculitis-like T-cell lymphomas (see Table 83.4 and Ch. 98)** |
| **Other** |
| • Lipodermatosclerosis (LDS)<br>• Idiopathic neutrophilic lobular panniculitis (overlapping with subcutaneous Sweet syndrome)<br>• Cytophagic hemophagocytic panniculitis (CHP)* |
| **The majority represent an underlying subcutaneous lymphoma.* |

**Table 83.1 Clinical classification of the panniculitides.**

eases; (2) location of the lesions (Fig. 83.1); (3) the presence or absence of ulceration and/or drainage; and (4) histopathologic findings.

- A biopsy is usually necessary to establish the diagnosis, and it is critical that the specimen include a generous portion of the subcutaneous (SC) fat.
- Excisional biopsies or narrow incisional biopsies that incorporate a broad expanse of SC fat are preferable to punch biopsies.
- Once the diagnosis of panniculitis is made, further evaluation for an underlying etiology or associated conditions is necessary (Tables 83.2–83.4).
- **DDx:** primarily differentiating among the various forms of panniculitis, superficial thrombophlebitis.
- **Rx:** involves specific treatment of the panniculitis and often treatment of an underlying disorder (see Tables 83.2–83.4).

**MOST COMMON LOCATIONS FOR SEVERAL FORMS OF PANNICULITIS**

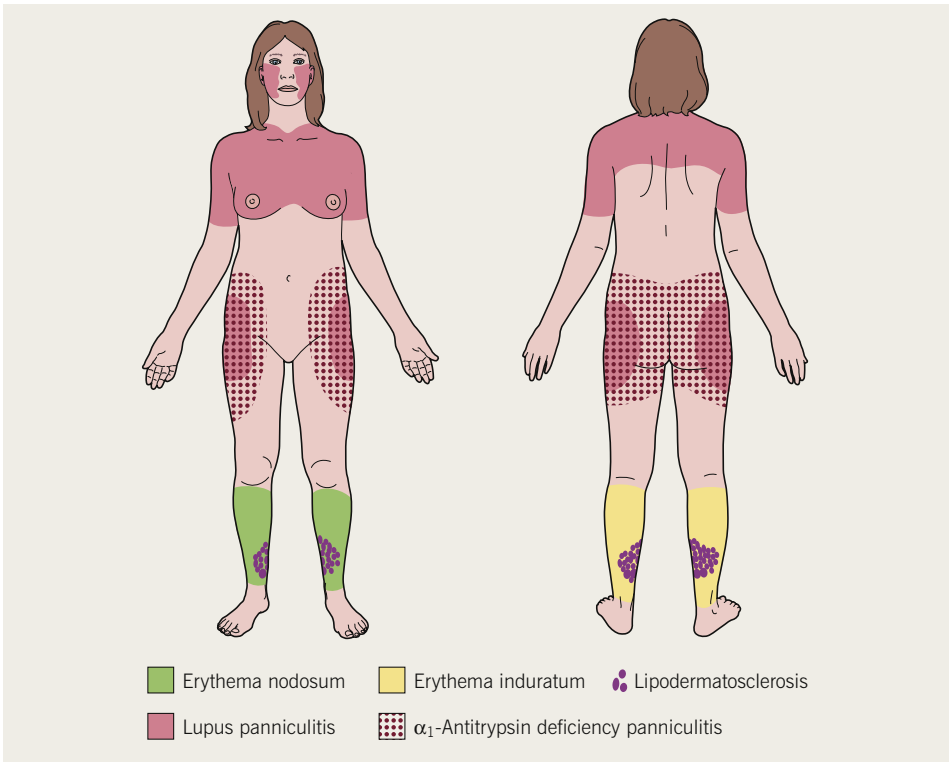


**Fig. 83.1 Most common locations for several forms of panniculitis.**

For further information see Ch. 100 from *Dermatology, Fourth Edition*.

**For additional online figures and tables visit www.expertconsult.com**

| THE MORE COMMON PANNICULITIDES | | | |
|---|---|---|---|
| **Panniculitis** | **Classic clinical and histopathologic features** | **Systemic findings and further evaluation** | **Treatment** |
| **Most common** | | | |
| Erythema nodosum (EN) | • Females > males; 2nd–4th decade<br>• Acute eruption of inflamed, tender SC nodules, favoring the pretibial area bilaterally (Fig. 83.2A), but may occur elsewhere<br>• No ulceration or drainage<br>• May last days to weeks<br>• Late lesions can have a bruise-like appearance (Fig. 83.2B)<br>• Histopathology: prototypical septal panniculitis | • ± Fevers, arthralgias, malaise<br>• Other findings may be related to underlying etiology (Table 83.5) | • Address and treat underlying etiology (Table 83.6) |
| Lipodermatosclerosis (LDS) | • Typically middle-aged to older individuals with chronic venous disorders (CVD)<br>**ACUTE**<br>• Painful, warm, red-purple, poorly defined plaques with variable induration (Fig. 83.3A)<br>• Favors the lower extremities, usually initially involves the skin above the medial malleolus<br>• Sometimes involves lower abdominal pannus<br>**CHRONIC**<br>• Induration and hyperpigmentation of the lower legs (Fig. 83.3B), with an "inverted champagne bottle" appearance<br>**ACUTE on CHRONIC**<br>• Occasionally acute onset of pain in the region of chronic LDS<br>• Histopathology: lipomembranous change | • Strong association with obesity, venous insufficiency, systemic hypertension<br>• Consider Doppler studies to evaluate venous system and to look for valvular or vein incompetence<br>• Consider ABI before instituting compression therapy | **ACUTE**<br>• Compression therapy (consider the Velcro strip variant)<br>• If too painful for compression therapy alone, add fibrinolytic agent (e.g., anabolic steroids such as oxandrolone 10 mg BID) plus pentoxifylline (400–800 mg TID)<br>**CHRONIC**<br>• Compression stockings (≥20–30 mmHg)<br>• Consider endovenous laser or radiofrequency ablation of incompetent veins |
| **Less common** | | | |
| Erythema induratum (nodular vasculitis) | • Females >> males; young to middle-aged<br>• Tender, inflamed nodules or plaques on posterior lower legs (Fig. 83.4)<br>• Ulceration and drainage can occur<br>• Heal with scarring; recurrent<br>• Histopathology: neutrophilic vasculitis | • Other findings may be related to underlying etiology (Table 83.5) | • Address and treat underlying etiology (Table 83.6) |

**Table 83.2 The more common panniculitides.** *Continued*

| THE MORE COMMON PANNICULITIDES | | | |
|---|---|---|---|
| **Panniculitis** | **Classic clinical and histopathologic features** | **Systemic findings and further evaluation** | **Treatment** |
| $\alpha_1$-Antitrypsin deficiency panniculitis | • Inherited in an autosomal co-dominant pattern<br>• Panniculitis may be initial presentation of disease or develop well into its course<br>• Painful red or purpuric SC nodules or plaques favoring the lower trunk or proximal extremities (Fig. 83.5)<br>• May spontaneously ulcerate and drain an oily material<br>• Histopathology: liquefactive necrosis of dermis and SC septa | • COPD<br>• Chronic liver disease<br>• Dx made by demonstrating low plasma concentrations of $\alpha_1$-antitrypsin (AAT) and either observation of a deficient variant of the protein AAT by protease inhibitor typing (PI ZZ variant most common) or by molecular genetic testing for *SERPINA1* gene mutations | • **MILD disease**<br>– Doxycycline, dapsone<br>• **SEVERE disease**<br>– Intravenous $\alpha_1$-antitrypsin replacement<br>• **REFRACTORY disease**<br>– Plasma exchange, liver transplant |
| Lupus erythematosus panniculitis | • Uncommon form of chronic cutaneous LE<br>• Associated with SLE in at least 10% of cases<br>• Associated with discoid LE (DLE) in at least one-third of cases, but may be an isolated finding<br>• Painful SC nodules or plaques in a characteristic pattern – on face, shoulders, upper arms, breasts, hips, and buttocks (Fig. 83.6), notably sparing lower extremities<br>• Chronic remitting course; can be elicited by trauma<br>• Overlying skin may be normal, depressed, bound down, or have changes of DLE ("lupus profundus")<br>• Histopathology: hyaline necrosis and lymphoplasmacytic infiltrate | • May have other findings of SLE (see Ch. 33)<br>• If associated with SLE often portends a good prognosis<br>• ANA often (+) but in low titers<br>• Hematologic abnormalities may be the only other abnormality<br>• Needs to be distinguished from subcutaneous panniculitis-like T-cell lymphoma (see Ch. 98) | • Intralesional CS<br>• Systemic medications most effective<br>• **First-line**<br>– Antimalarials<br>• **Second-line**<br>– Methotrexate, dapsone, mycophenolate mofetil, azathioprine, thalidomide |
| Infection-induced panniculitis<br>• Bacterial<br>• Mycobacterial<br>• Fungal<br>• Viral<br>• Parasitic | • Most often seen in immunocompromised patients, but not exclusively<br>• Three typical clinical scenarios:<br>– Direct inoculation of infectious organisms into the SC fat (may see sporotrichoid pattern)<br>– Hematogenous spread to SC fat, as in septicemia (disseminated lesions)<br>– Extension to the SC fat from underlying infection<br>• Typically presents with ≥1 fluctuant nodules that ulcerate and drain<br>• Favors lower extremities<br>• Histopathology: necrosis and neutrophils; special stains can highlight organisms, but tissue culture ± PCR also recommended | • May be profoundly ill (e.g. septicemia) or appear well (e.g. normal host with isolated lesion)<br>• Dx requires a high index of suspicion, *pre*-biopsy, so that a sterile, deep biopsy specimen can be sent to microbiology for tissue culture ± PCR, in addition to pathology | • Empirical, broad-spectrum coverage in severely ill host<br>• Otherwise tailored to identified organism |

**Table 83.2** *Continued* **The more common panniculitides.**

| PREDOMINANTLY CHILDHOOD PANNICULITIDES | | | |
|---|---|---|---|
| **Panniculitis** | **Classic features*** | **Systemic findings and further evaluation** | **Treatment** |
| Subcutaneous fat necrosis of the newborn† | • Usually seen in full-term neonates<br>• Onset during the first 2–3 weeks of life<br>• Mobile, firm SC nodules or plaques, favoring the cheeks, shoulders, back, buttocks, and thighs (Fig. 83.7) | • Hypercalcemia (usually within 2 months of onset), thrombocytopenia, hypertriglyceridemia<br>• May be precipitated by hypothermia, hypoglycemia, perinatal distress/hypoxia | • Spontaneous resolution common<br>• Favorable prognosis<br>• Supportive care |
| Post-steroid panniculitis† | • Onset usually within 10 days after the rapid withdrawal of systemic CS<br>• Firm red plaques on the cheeks, arms, trunk | • May be related to the condition that required the systemic CS | • May resolve spontaneously<br>• Consider readministration and slower tapering of systemic CS |
| Cold panniculitis | • Favors the cheeks of infants and children due to popsicles or ice cubes and the medial thighs of equestrians due to riding in cold temperatures plus tight-fitting clothing (Fig. 83.8) | • Possibly other signs of hypothermia | • Remove cold exposure and rewarm |
| Sclerema neonatorum† | • Seen in premature, extremely ill neonates<br>• Onset during the first week of life<br>• Diffusely cold, rigid, board-like skin | • Death common due to septicemia<br>• May be precipitated by hypothermia, dehydration, perinatal asphyxia | • No good treatment<br>• Supportive care |

**All entities, except for cold panniculitis, will demonstrate needle-shaped clefts on histopathology.*
*†Seen exclusively in infants or children.*

**Table 83.3 Predominantly childhood panniculitides.**

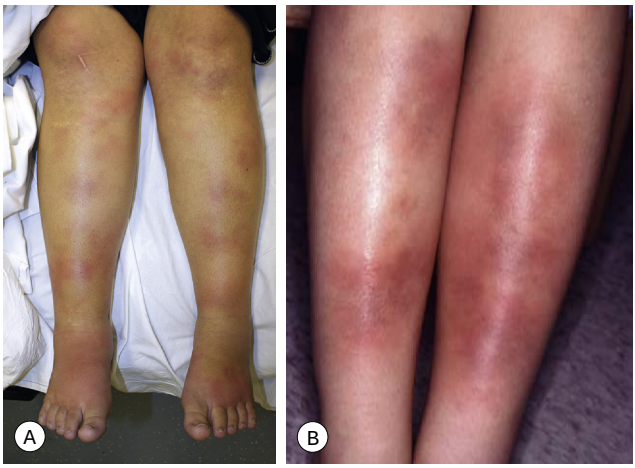


**Fig. 83.2 Erythema nodosum.** **A** Erythematous, tender nodules bilaterally on the shins and dorsal feet; the patient is pregnant. **B** The nodules and plaques may develop a bruise-like appearance. *A, Courtesy, Ian Odell, MD, PhD; B, Courtesy, Kalman Watsky, MD.*




**Fig. 83.3 Lipodermatosclerosis.** **A** Acute phase with tender erythematous plaques on both lower extremities. This condition is often misdiagnosed as "bilateral recurrent cellulitis." **B** Chronic phase with sclerotic red-brown plaque on the lower medial leg. *A, Courtesy, James Patterson, MD; B, Courtesy, Kenneth E. Greer, MD.*



**Fig. 83.4 Erythema induratum.** Nodular lesions on the lower leg, with evidence of ulceration. *Courtesy, Kenneth E. Greer, MD.*



**Fig. 83.5 $\alpha_1$-Antitrypsin deficiency panniculitis.** Purpuric nodules on the ankles. *Courtesy, Kenneth E. Greer, MD.*




**Fig. 83.6 Lupus panniculitis. A** Erythematous plaque on the upper arm. The lesions may resolve with lipoatrophy. **B** Red-brown plaques on the upper outer arm. Note the significant subcutaneous atrophy and overlying lesions of discoid lupus erythematosus. *A, Courtesy, YDRSC; B, Courtesy, Kenneth E. Greer, MD.*



**Fig. 83.7 Subcutaneous fat necrosis of the newborn.** Red-violet indurated plaques, primarily on the back and shoulders. *Courtesy, Lorenzo Cerroni, MD.*



**Fig. 83.8 Cold panniculitis.** Violaceous nodules and plaques, some with central crusting, on the thigh of a young woman. *Courtesy, Kendra Lesiak, MD.*

| THE LESS COMMON PANNICULITIDES | |
|---|---|
| **Panniculitis** | **Classic features** |
| Subacute nodular migratory panniculitis (chronic EN) | • Resembles EN but is typically chronic, unilateral, and tends to migrate and/or form annular lesions<br>• May be associated with streptococcal infections or thyroid disease |
| Pancreatic panniculitis | • May be the initial presentation of pancreatic disease (pancreatitis > cancer) or develop during its course<br>• Favors lower legs (Fig. 83.9), but also arms, chest, abdomen<br>• May become fluctuant, ulcerate, and drain an oily substance<br>• Eosinophilia and polyarthritis are associated findings |
| Dermatomyositis-associated panniculitis | • More common in juvenile dermatomyositis<br>• Tender SC nodules or plaques on thighs, arms, buttocks, and abdomen; calcify with time |
| Panniculitis-like T-cell lymphomas (see Ch. 98) | • Dx is often suggested after a biopsy is performed in a patient whose lesions fail to improve or worsen, e.g. in a patient with a clinical Dx of EN<br>• Two major types, requiring histopathologic differentiation: subcutaneous panniculitis-like T-cell lymphoma ($\alpha\beta$ type) and $\gamma\delta$ T-cell lymphoma<br>• Evaluation for systemic involvement is necessary<br>• DDx includes lupus panniculitis |
| Cytophagic histiocytic panniculitis (CHP) | • Dx is usually made after histopathologic examination of SC nodules or plaques (Fig. 83.10) when the finding of hemophagocytosis is identified<br>• The majority of patients have subcutaneous involvement with an aggressive lymphoma, e.g. $\gamma\delta$ T-cell lymphoma; may have a fatal course due to a hemophagocytic syndrome |

**Table 83.4 The less common panniculitides.** EN, erythema nodosum.



**Fig. 83.9 Pancreatic panniculitis.** Multiple red to violet-brown nodules on the arm. There is also postinflammatory desquamation. *Courtesy, Lorenzo Cerroni, MD.*



**Fig. 83.10 Cytophagic histiocytic panniculitis.** Subcutaneous nodules with purpura. The majority of these patients have an underlying subcutaneous lymphoma. *Courtesy, Kenneth E. Greer, MD.*

**TRIGGERS OF ERYTHEMA NODOSUM AND ERYTHEMA INDURATUM AND SUGGESTED EVALUATIONS**

| | Erythema nodosum | Erythema induratum |
|---|---|---|
| **Most common causes** | • Idiopathic<br>• Streptococcal infections, especially of the upper respiratory tract<br>• Other infectious associations:<br>– Bacterial gastroenteritis – *Yersinia* > *Salmonella*, *Campylobacter*<br>– Viral upper respiratory tract infections<br>– Coccidioidomycosis<br>• Sarcoidosis*<br>• Inflammatory bowel disease<br>• Drugs:<br>– Estrogens/oral contraceptives<br>– Antibiotics (e.g. sulfonamides, penicillins) | • Tuberculosis<br>• Idiopathic |
| **Less common causes** | • Other infections (e.g. brucellosis, tuberculosis, hepatitis B†)<br>• Neutrophilic dermatoses (e.g. Sweet syndrome, Behçet disease)<br>• Pregnancy<br>• Drugs:<br>– TNF inhibitors (e.g. etanercept, infliximab, adalimumab)**<br>– Immune checkpoint inhibitors (e.g. ipilimumab, nivolumab)***<br>– BRAF inhibitors (e.g. vemurafenib, dabrafenib)‡<br>– Bromides, iodides<br>• Malignancy (e.g. acute myelogenous leukemia) | • Other infections (e.g. *Nocardia*, *Pseudomonas*, viral hepatitis)<br>• Non-infectious associations (e.g. superficial thrombophlebitis, hypothyroidism, RA, Crohn disease)<br>• Drugs (e.g. propylthiouracil) |

**Table 83.5 Triggers of erythema nodosum and erythema induratum and suggested evaluations.** *Continued.*

| TRIGGERS OF ERYTHEMA NODOSUM AND ERYTHEMA INDURATUM AND SUGGESTED EVALUATIONS | | |
|---|---|---|
| | **Erythema nodosum** | **Erythema induratum** |
| **Suggested workup**§ | • Anti-streptolysin O and/or anti-DNase B titers<br>• Chest X-ray<br>• Tuberculin skin test or IGRA<br>• Viral hepatitis panel<br>• If diarrhea, check fecal WBC and stool culture for bacteria, ova and parasites<br>• Consider GI referral if bloody diarrhea, fecal WBC, and negative cultures<br>• β-HCG in women<br>• Malignancy workup as indicated by history and physical exam | • Chest X-ray<br>• Tuberculin skin test or IGRA<br>• Consider PCR of skin biopsy for *M. tuberculosis*<br>• Viral hepatitis panel<br>• TSH<br>• CBC, ESR<br>• Rheumatoid factor<br>• Consider GI referral if diarrhea |

**Löfgren syndrome is an acute, spontaneously resolving form of sarcoidosis characterized by erythema nodosum, fever, hilar lymphadenopathy, polyarthritis, and uveitis.*
***Also lupus-like.*
****Also sarcoid-like.*
*†Erythema nodosum secondary to hepatitis B vaccine has also been reported.*
*‡Also neutrophilic lobular as with other tyrosine kinase inhibitors (e.g. imatinib, dasatinib, ibrutinib).*
*§Basic workup in patients with erythema nodosum and erythema induratum with no obvious etiology.*

**Table 83.5** *Continued* **Triggers of erythema nodosum and erythema induratum and suggested evaluations.** HCG, human chorionic gonadotropin; IGRA, interferon-γ release assay; RA, rheumatoid arthritis.

| TREATMENT RECOMMENDATIONS FOR ERYTHEMA NODOSUM AND ERYTHEMA INDURATUM | | |
|---|---|---|
| **Treatment** | **Erythema nodosum** | **Erythema induratum** |
| In all patients | • Discontinue possible causative medications<br>• Diagnose and treat underlying cause/infection<br>• Bed rest and leg elevation<br>• Compression | |
| First-line | • Nonsteroidal anti-inflammatory medications<br>• Salicylates<br>• Potassium iodide (see Appendix) | |
| Second-line, *once infection excluded or treated* | • Colchicine*<br>• Infliximab**<br>• Hydroxychloroquine***<br>• Adalimumab***<br>• Etanercept<br>• Mycophenolate mofetil | • Systemic CS<br>• Tetracyclines<br>• Mycophenolate mofetil |
| Third-line, *once infection excluded or treated* | • Systemic CS<br>• Thalidomide**<br>• Cyclosporine*<br>• Dapsone | |

**Helpful for erythema nodosum occurring in the setting of Behçet disease.*
***Helpful for erythema nodosum occurring in the setting of inflammatory bowel disease.*
****Helpful for chronic erythema nodosum.*

**Table 83.6 Treatment recommendations for erythema nodosum and erythema induratum.**



**eFig. 83.1 Erythema nodosum.** Erythematous, tender nodules located bilaterally on the shins. *Courtesy, Kenneth E. Greer, MD.*

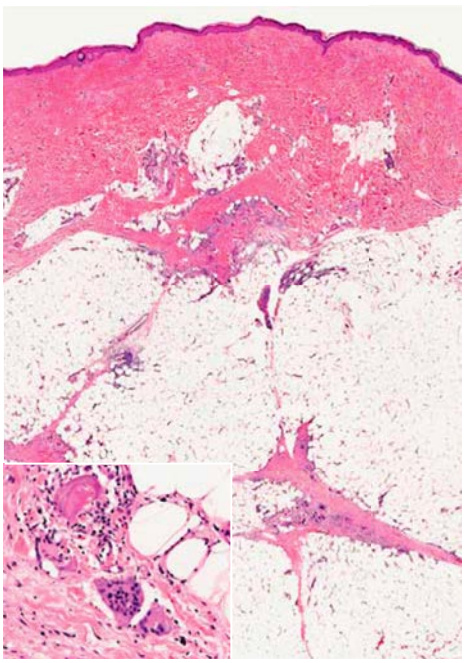

**eFig. 83.2 Erythema nodosum – histopathologic features.** A predominantly septal panniculitis with Miescher microgranulomas within the septa. Note the multinucleated giant cells (inset). *Courtesy, Lorenzo Cerroni, MD.*

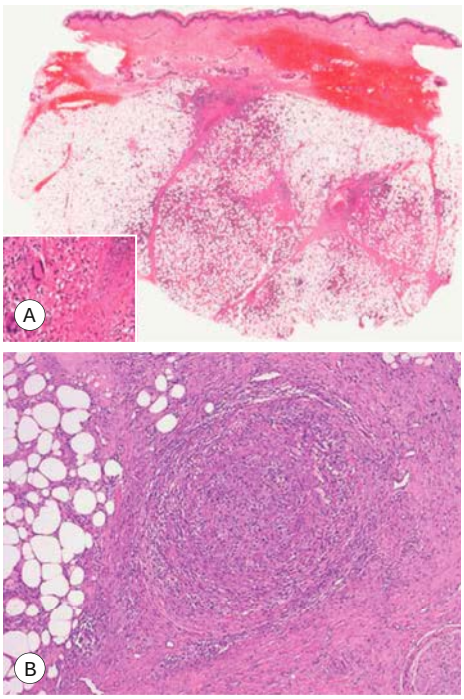


**eFig. 83.3 Erythema induratum – histopathologic features. A** A predominantly lobular panniculitis is seen with an infiltrate that is lymphocytic and granulomatous; note the multinucleated giant cells (inset). **B** Vasculitis involving a medium-sized vessel in the subcutis. *Courtesy, Luis Requena, MD.*



**eFig. 83.4 Subcutaneous fat necrosis of the newborn.** Indurated plaques on the trunk. *Courtesy, YDRSC.*



**eFig. 83.5 Cold panniculitis.** Erythematous to violaceous plaques on the thighs of a young woman with equestrian cold panniculitis. *Courtesy, Kenneth E. Greer, MD.*



**eFig. 83.6 Lupus panniculitis.** Erythematous plaque involving the orbital area. *Courtesy, James Patterson, MD.*

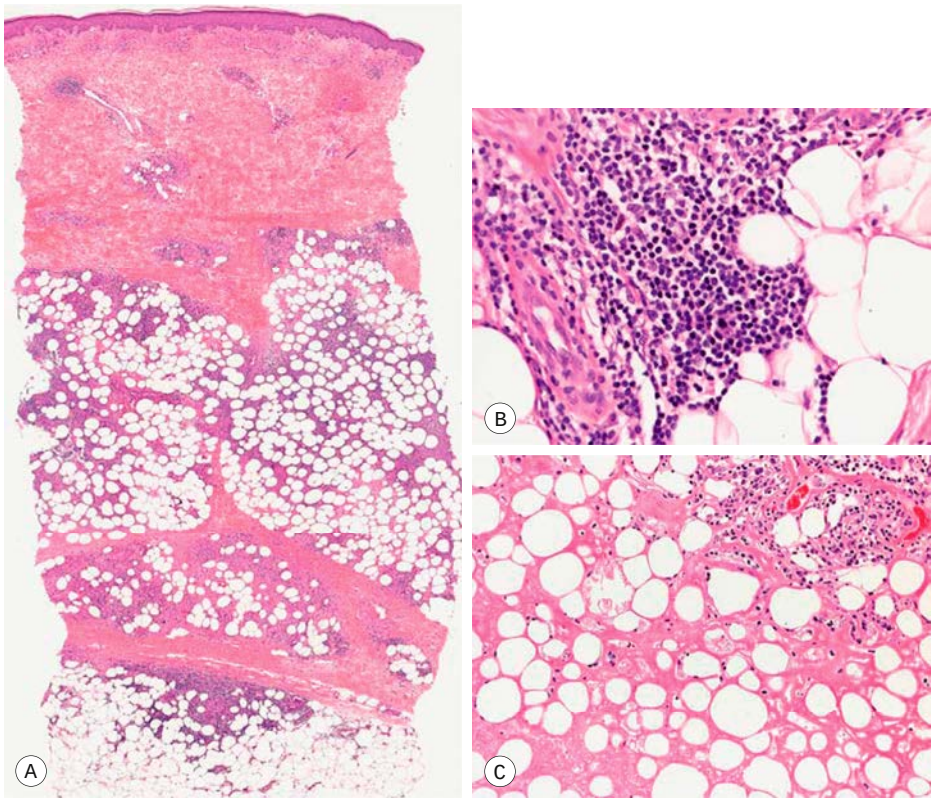


**eFig. 83.7 Lupus panniculitis – histopathologic features. A, B** A primarily lobular panniculitis with nodular aggregates of lymphocytes. **C** Hyaline necrosis of fat lobules is also a characteristic feature. A focus of lipomembranous changes, a nonspecific finding observed in the late stages of several types of panniculitis, is present. *Courtesy, Lorenzo Cerroni, MD.*



**eFig. 83.8 Pancreatic panniculitis.** Multiple nodules on the legs. *Courtesy, Kenneth E. Greer, MD.*

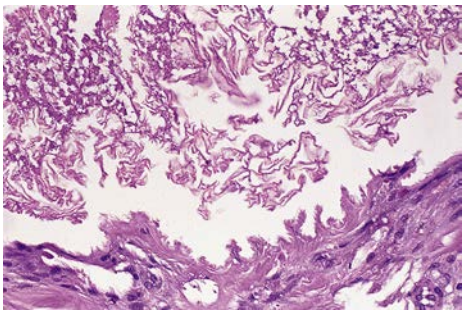

**eFig. 83.9 Lipodermatosclerosis.** Lipomembranous change, consisting of cystic formation with elaborate papillary configurations. *Courtesy, James W. Patterson, MD.*

| CAUSES OF ERYTHEMA NODOSUM | | |
|---|---|---|
| **Incidence** | **Cause** | **Comments** |
| Most common | Idiopathic | Still the largest single category, accounting for a third to a half of cases |
| | Streptococcal infections, especially of the upper respiratory tract | The largest single infectious cause |
| | Other infections:<br>Viral upper respiratory tract infections<br>Bacterial gastroenteritis – *Yersinia* > *Salmonella, Campylobacter* | Overall, infection may account for a third or more of cases |
| | Coccidioidomycosis | Erythema nodosum is associated with a lower incidence of disseminated disease |
| | Drugs* | Especially estrogens and oral contraceptive pills; also sulfonamides, penicillin, bromides, iodides; occasionally, TNF inhibitors, BRAF inhibitors^ |
| | Sarcoidosis** | 10–20% of cases in some series |
| | Inflammatory bowel disease | Crohn disease has a stronger association with erythema nodosum than does ulcerative colitis |
| Uncommon | Infections:<br>*Brucella melitensis Chlamydophila pneumonia*†<br>*Chlamydia trachomatis*<br>*Mycoplasma pneumoniae*<br>*Mycobacterium tuberculosis*<br>*Histoplasma capsulatum*<br>Hepatitis B virus‡ | |
| | Neutrophilic dermatoses:<br>Behçet disease<br>Sweet syndrome | "Erythema nodosum" in Behçet disease more closely resembles erythema induratum (nodular vasculitis) |
| | Acne fulminans, including isotretinoin-associated | |
| | Pregnancy | |

**eTable 83.1 Causes of erythema nodosum including rare entities.** *Continued*

| CAUSES OF ERYTHEMA NODOSUM | | |
|---|---|---|
| **Incidence** | **Cause** | **Comments** |
| Rare | Pernicious anemia | *Erythema nodosum leprosum* is a different disease that is characterized by a cutaneous small vessel vasculitis |
| | Diverticulitis | |
| | Infections:<br>*Neisseria gonorrhoeae*, *N. meningitidis*<br>*Escherichia coli*, *Bartonella henselae*, *Bordetella pertussis*<br>*Treponema pallidum*<br>Dermatophytes (kerion), *Blastomyces dermatitidis*<br>HIV<br>Giardiasis, amebiasis (abscesses) | |
| | MonoMAC syndrome (*GATA2* mutations) | |
| | Malignancy, most often acute myelogenous leukemia, Hodgkin disease | May overlap with Sweet syndrome |

**To be distinguished from panniculitis that can develop at sites of injection of medications, e.g. glatiramer acetate, interferon-β, phytonadione (vitamin K), interleukin-2, heparin (eosinophilic panniculitis), pentazocine, vaccines (e.g. tetanus).*
***Löfgren syndrome is an acute, spontaneously resolving form of sarcoidosis characterized by erythema nodosum, hilar lymphadenopathy, fever, polyarthritis and uveitis.*
*^Also lobular neutrophilic panniculitis.*
*†Previously referred to as* Chlamydia.
*‡Erythema nodosum secondary to the hepatitis B vaccine has also been reported.*

**eTable 83.1** *Continued* **Causes of erythema nodosum including rare entities.**

| FINDINGS SUGGESTIVE OF A SYSTEMIC CAUSE FOR ERYTHEMA NODOSUM |
|---|
| • Synovitis<br>• Diarrhea*<br>• Abnormal chest X-ray<br>• Preceding upper respiratory tract infection<br>• Elevated antistreptolysin O and/or anti-DNase B titers<br>• Positive tuberculin skin test or interferon-gamma release assay (e.g. QuantiFERON®-TB Gold In-Tube test, T-SPOT®.TB test) |

**Check for fecal white blood cells, fecal calprotectin, stool culture for bacteria and, if indicated, ova and parasites.*

**eTable 83.2 Findings suggestive of a systemic cause for erythema nodosum.** Additional evaluation can include viral hepatitis panel and in women of child-bearing age, serum β-human chorionic gonadotropin.

| INFECTION-INDUCED PANNICULITIS – REPORTED CAUSATIVE AGENTS |
|---|
| **Bacteria** |
| *Staphylococcus aureus*<br>Group A *Streptococcus*<br>*Pseudomonas aeruginosa*<br>*Brucella melitensis*<br>*Nocardia asteroides*<br>*Tropheryma whipplei* (causative agent of Whipple disease) |
| **Mycobacteria** |
| *M. tuberculosis*<br>*M. marinum, M. avium-intracellulare, M. chelonae, M. fortuitum, M. ulcerans* |
| ***Coxiella*** |
| *C. burnetii* |
| ***Borrelia*** |
| *B. burgdorferi* |
| **Fungi** |
| *Blastomyces dermatitidis, Histoplasma capsulatum*<br>*Microsporum* spp. (including *M. canis)*<br>*Candida* spp. (including *C. albicans)*<br>*Cryptococcus neoformans*<br>*Aspergillus* spp. (including *A. flavus*), *Mucor* or related zygomycetes, *Fusarium* spp., *Aureobasidium pullulans* |
| **Helminths & protozoa** |
| Nematodes (*Gnathostoma* spp.)<br>Trematodes (*Fasciola hepatica*, *Schistosoma* spp.) |

**eTable 83.3 Infection-induced panniculitis – reported causative agents.** *Courtesy, James W. Patterson, MD.*

# 84 Lipodystrophies

- Lipodystrophy is characterized by areas of fat loss/absence (lipoatrophy), and/or fat accumulation (lipohypertrophy), with both often coexisting in the same patient; lipoatrophy can lead to the appearance of muscular hypertrophy (Fig. 84.1).
- Lipoatrophy may be classified as:
  - Generalized, partial, or localized (Fig. 84.2)
  - Inherited (often appears during childhood) or acquired
  - Stable or progressive
- Localized lipo*atrophy* may be idiopathic (Fig. 84.3) or secondary to various causes, e.g. injection of medications (in particular CS), pressure (Figs 84.4 and 84.5), trauma, autoimmune connective tissue disease (e.g. lupus panniculitis; Figs 84.6 and 84.7), and other panniculitides due to inflammation or lymphoma.
- Localized lipo*hypertrophy* is most commonly seen in the setting of multiple insulin injections.
- HIV/antiretroviral therapy (HIV/ART) causes a distinct syndrome of central lipohypertrophy and peripheral lipoatrophy (Fig. 84.8).
- Extensive lipodystrophy syndromes have characteristic distributions of fat atrophy and hypertrophy (Figs 84.2 and 84.9–84.11).
- Fat is a metabolically active tissue with important endocrine functions; therefore, non-localized lipodystrophy is often seen in conjunction with the metabolic syndrome (insulin resistance, diabetes mellitus, hyperinsulinemia, dyslipidemia, cardiovascular disease, and fatty hepatic steatosis).
- Other associations include hormonal abnormalities, anabolic syndrome, glomerulonephritis, and autoinflammatory syndromes (e.g. CANDLE syndrome, see Table 37.3).
- **Rx:** depends in part on underlying etiology (see Fig. 84.2); (1) remove inciting cause (e.g. relieve pressure or rotate sites of injections); (2) address the metabolic syndrome if present; (3) consider metreleptin for inherited or acquired generalized lipoatrophy; (4) improve cosmetic appearance (e.g. injection of poly-L-lactic acid or autologous fat transfer into the cheeks).



**Fig. 84.1 Lipoatrophy of the lower extremities, leading to the appearance of muscular hypertrophy.** *Courtesy, William D. James, MD.*

For further information see Ch. 101 from *Dermatology, Fourth Edition*.

**For additional online figures visit www.expertconsult.com**

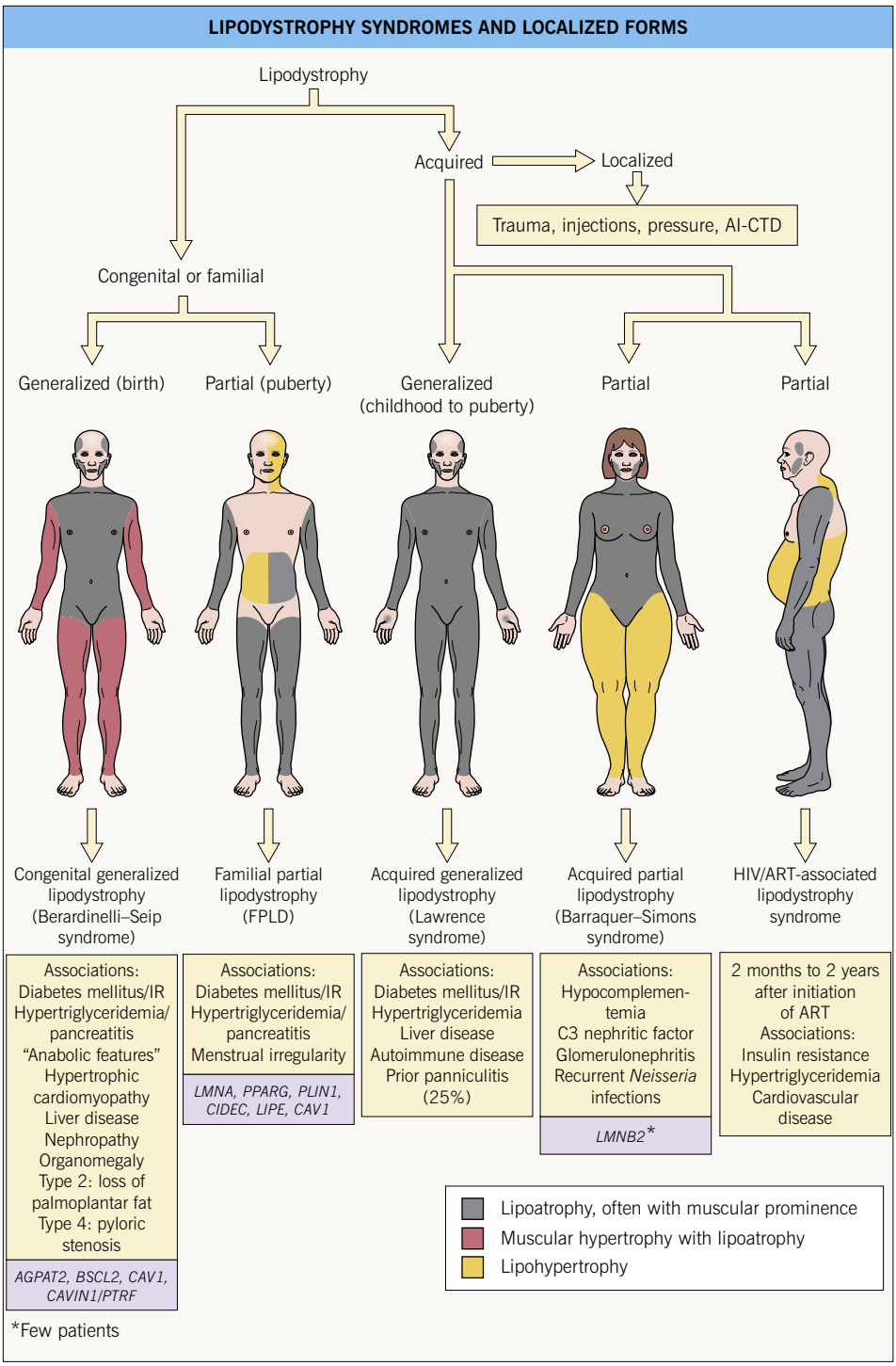


**Fig. 84.2 Lipodystrophy syndromes and localized forms.** Schematic representation of the predominant sites of lipoatrophy and lipohypertrophy. Shaded boxes include best-described underlying genetic mutations. In familial partial lipodystrophy, *LMNA* mutations are associated with facial lipohypertrophy and abdominal lipoatrophy while *PPARG* mutations are associated with abdominal lipohypertrophy. IR, insulin resistance.



**Fig. 84.3 Lipodystrophia centrifugalis abdominalis infantilis (centrifugal lipodystrophy).** A 5-year-old Malay boy with a two-year history of progressive lipoatrophy involving the groin bilaterally and the lower abdomen. The veins in the involved area are readily visible. *Courtesy, National Skin Centre, Singapore.*



**Fig. 84.4 Localized lipoatrophy of the upper lateral calf due to pressure.** A fairly common finding in women who cross their legs while seated. *Courtesy, Jean L. Bolognia, MD.*



**Fig. 84.5 Lipoatrophia semicircularis (semicircular lipoatrophy).** Bilateral slightly curved depressions on the anterolateral thighs. *Courtesy, Diane Thaler, MD.*

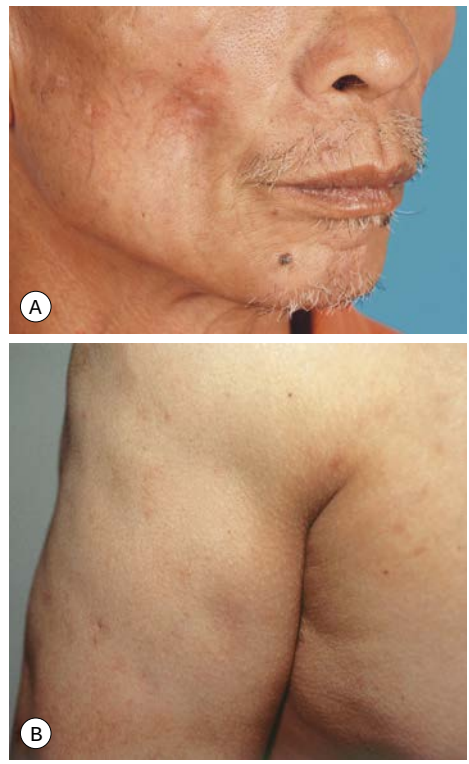


**Fig. 84.6 Lipoatrophy secondary to lupus panniculitis. A** An area of depression on the cheek due to burnt-out lupus panniculitis; note the dyspigmentation and scarring from an overlapping lesion of discoid lupus erythematosus. **B** Circular depressions on the upper arm, a common location for lupus panniculitis. Lipoatrophy can be seen with other connective tissue disorders, including dermatomyositis in children. *A, Courtesy National Skin Centre, Singapore; B, Courtesy, YDRSC.*

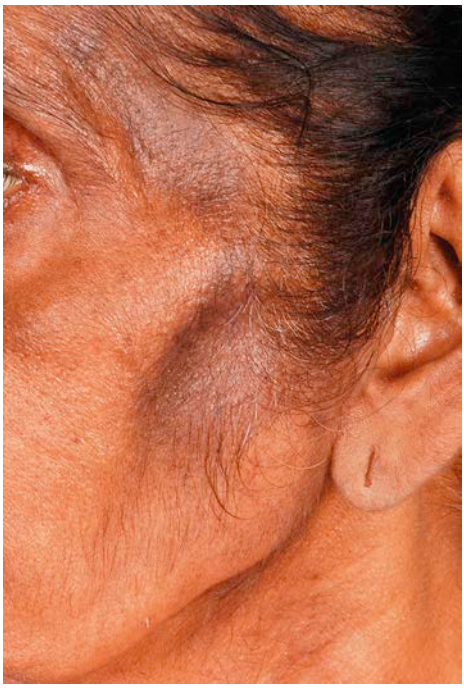

**Fig. 84.7 Acquired partial lipodystrophy syndrome in a patient with Sjögren syndrome.** Lipoatrophy of the face with sunken eyes and loss of temporal and buccal fat pads. The facial pigmentation is related to lichen planus. *Courtesy, Priya Sen, MD.*

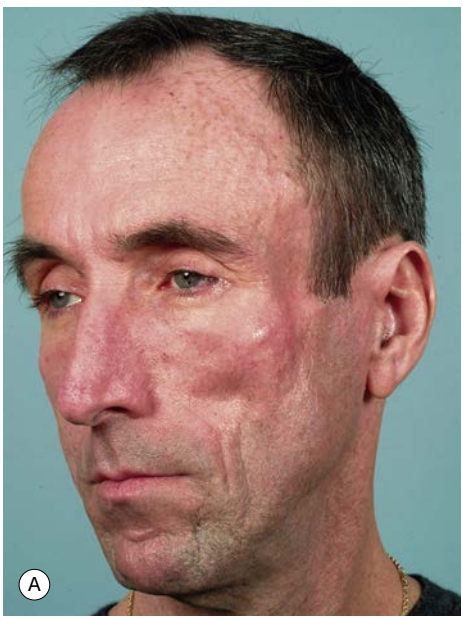


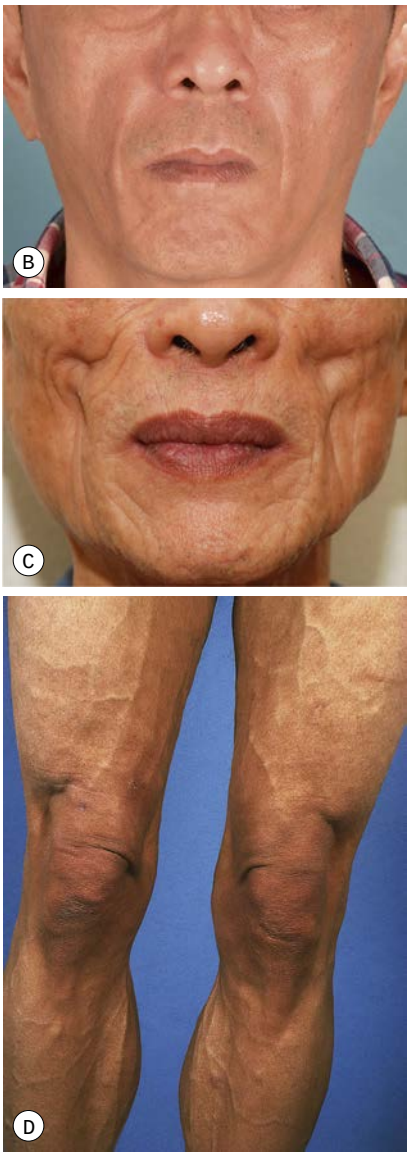


**Fig. 84.8 HIV/ART-associated lipodystrophy. A** The side view highlights the loss of temporal fat. **B** There is symmetric loss of buccal and parotid fat, resulting in prominent zygomata and a cachectic appearance. **C** Marked indentation of the medial cheeks in an older patient with redundancy of the melolabial folds. In particular, stavudine and protease inhibitors are most strongly associated with lipoatrophy. **D** Lower extremities with defined veins and prominent musculature. *A, Courtesy, Ken Katz, MD; B, Courtesy, National Skin Centre, Singapore; C, Courtesy, Priya Sen, MD; D, Courtesy, Alison Sharpe Avram, MD and Matthew Avram, MD.*




**Fig. 84.9 Congenital generalized lipodystrophy syndrome (Berardinelli–Seip syndrome). A** Lipoatrophy of the trunk leading to muscle definition. **B** Extensive acanthosis nigricans. *A, B, Courtesy, Edward Cowen, MD.*



**Fig. 84.10 Acquired generalized lipodystrophy.** There is loss of subcutaneous fat, resulting in a muscular appearance of the legs and accentuation of the tendons. *Courtesy, Jacqueline Junkins-Hopkins, MD.*



**Fig. 84.11 Acquired partial lipodystrophy in a patient with nephritic factor and renal disease.** Lipoatrophic features are most prominent on the face, with a marked loss of buccal fat. Axillary acanthosis nigricans was present. *Courtesy, Kenneth E. Greer, MD.*

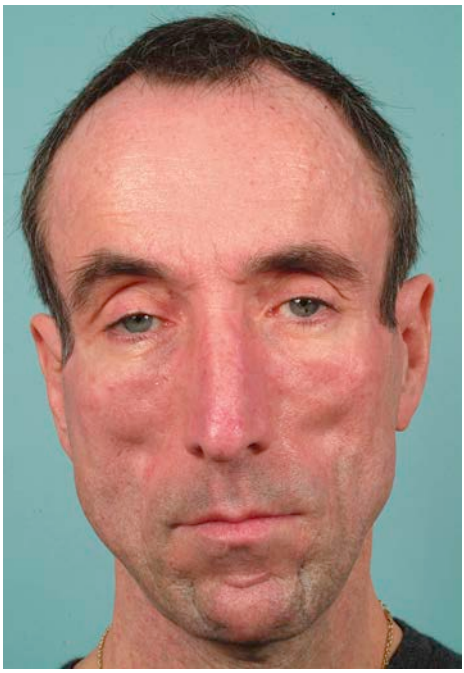

**eFig. 84.1 HIV/ART-associated lipodystrophy.** There is symmetric loss of buccal, parotid, and preauricular (Bichat's) fat pads, resulting in prominent zygomata, sunken eyeballs, and a cachectic appearance. *Courtesy, Ken Katz, MD.*

# Infantile Hemangiomas and Vascular Malformations

# 85

- Vascular anomalies, which often present at birth or during early infancy, are classified into two groups based on their biologic and clinical behavior:
  - *Vascular tumors*, most commonly the infantile hemangioma (IH), that are characterized by endothelial cell proliferation
  - *Vascular malformations* that result from abnormal vascular morphogenesis
- Features that distinguish IHs from vascular malformations are presented in Table 85.1, and differences in their natural histories are depicted in Fig. 85.1.
- Additional vascular neoplasms are discussed in Chapter 94; other vascular ectasias,

**COMPARISON OF INFANTILE HEMANGIOMAS WITH VASCULAR MALFORMATIONS**

| Characteristic | Infantile hemangiomas | Vascular malformations |
|---|---|---|
| Epidemiology | More common in:<br>• Girls (female:male ratio 3–5:1)<br>• Premature and/or low-birth-weight infants<br>• Infants whose mothers are older or underwent CVS | • Equal sex ratio<br>• No predilection based on gestational history<br>• Certain variants have autosomal dominant inheritance (see text) |
| Appearance at birth | • Often absent<br>• ~50% with a subtle precursor lesion, e.g. telangiectatic, vasoconstricted, pink or bluish bruise-like macules or patches (Fig. 85.2) | • Typically present and already demonstrate characteristic clinical findings |
| Natural history | • *Postnatal proliferation* for 6–9 months, followed by *slow involution* over several years | • *Lifelong persistence*, with commensurate growth during childhood and often *gradual worsening* (e.g. thickening of capillary malformations) over time |
| Radiology | • Well-defined mass with high-flow vessels | • Varies depending on the type (see text) |
| Pathology | In the proliferative phase:<br>• Dense lobules of hyperplastic endothelial cells forming capillaries with tiny lumens<br>• Increased cellular turnover demonstrated by markers of proliferation (e.g. Ki-67) | • Ectatic or distorted vascular channels<br>• Typically no increase in cellular turnover |
| Immunophenotype | • GLUT1-positive | • GLUT1-negative |

**Table 85.1 Comparison of infantile hemangiomas with vascular malformations.** CVS, chorionic villus sampling; GLUT1, glucose transporter protein-1 (expressed by the placenta as well as infantile hemangiomas, but no diffuse expression in other vascular tumors).

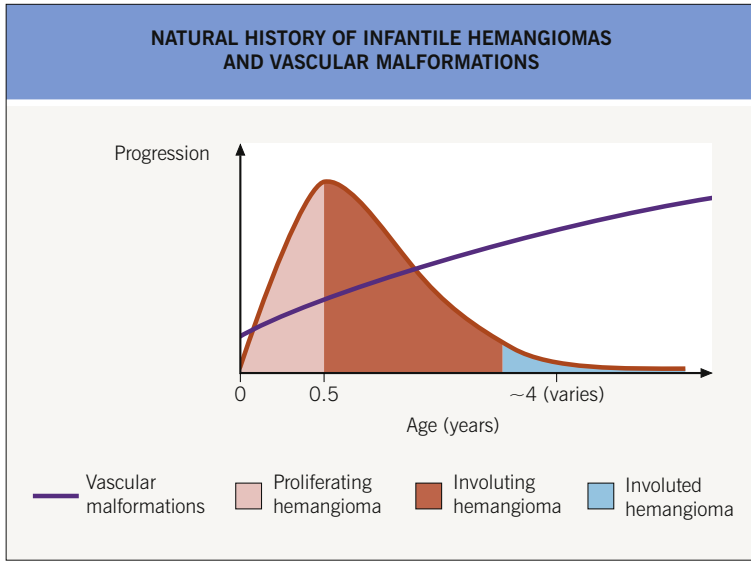


**Fig. 85.1 Natural history of infantile hemangiomas and vascular malformations.**




**Fig. 85.2 Hemangioma precursors.** These initial lesions can have a "bruised" **(A)** or blanched **(B)** appearance. *A, Courtesy, Maria Garzon, MD; B, Courtesy, Julie V. Schaffer, MD.*

such as telangiectasias and angiokeratomas, are covered in Chapter 87.

## Infantile Hemangioma (IH)

- Benign vascular neoplasm that represents the most common tumor of infancy.
  - Affects ~5% of infants, with a predilection for girls and premature neonates (see Table 85.1)
- IHs appear during the first few weeks of life, with a characteristic course:
  - *Proliferation* for 5–9 months, tending to "mark out their territory" early on and then grow primarily in volume; overall, ~80% of growth is in the first 5 months of life, with the most rapid growth in the first 2–3 months
  - Subsequent *involution* gradually over several years (completed at a median age of 3 years), with development of a duller, lighter red to gray color and softening followed by flattening (Fig. 85.3)
  - Some IHs involute with little or no visible sequelae, whereas others (especially pedunculated or exophytic lesions) leave atrophic, fibrofatty, or telangiectatic residua in addition to scars at sites of previous ulceration (discussed later; Fig. 85.4)



**Fig. 85.3 Involuting infantile hemangioma.** Note the duller red to grayish color with areas of complete fading. These color changes were accompanied by gradual softening and flattening. *Courtesy, YDRSC.*

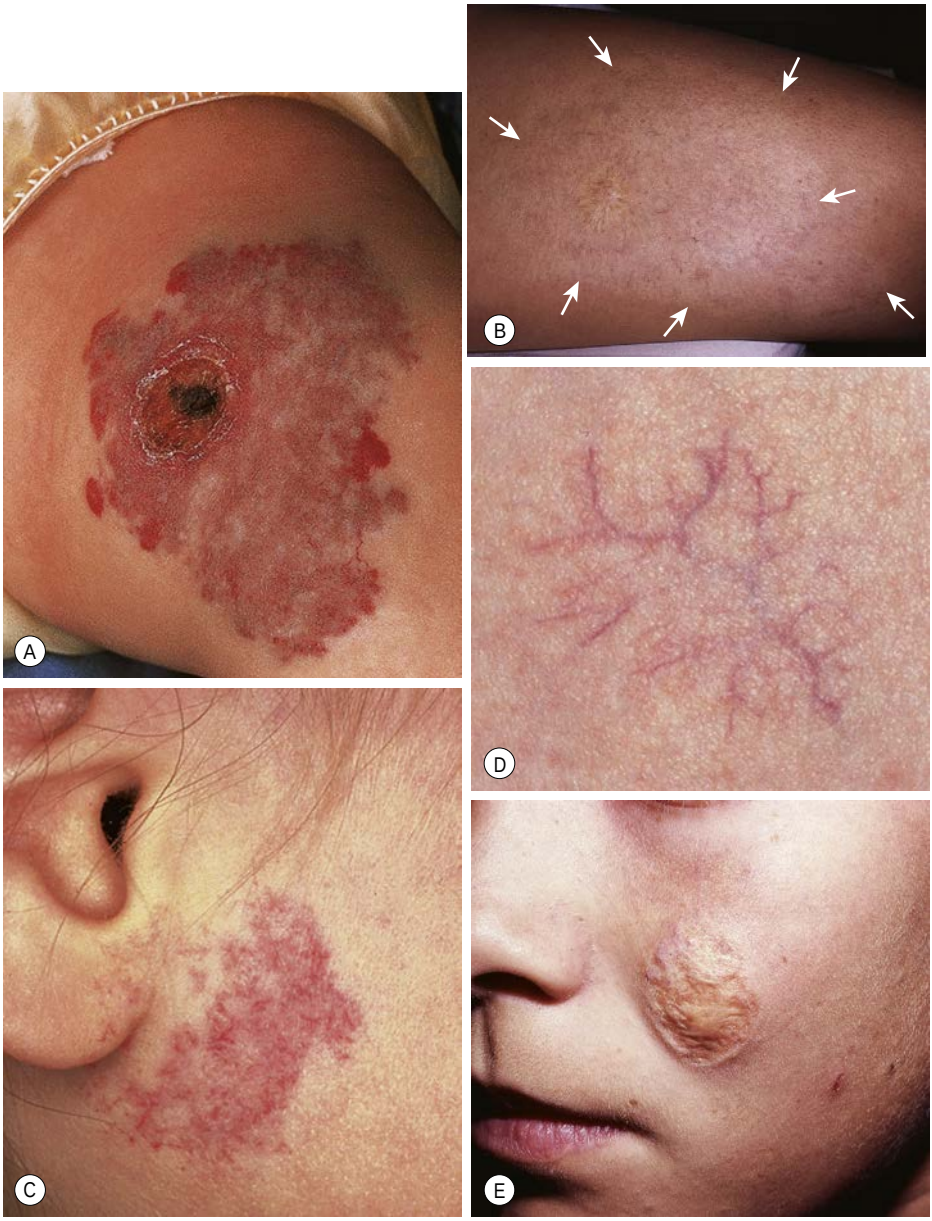


**Fig. 85.4 Residua of infantile hemangiomas. A** Superficial hemangioma with a healing ulcer in an infant. **B** Hypopigmentation (arrows) and a circular scar at the site of the previous ulcer in the same patient 20 years later. **C, D** Residual telangiectasias. **E** Atrophy and fibrofatty changes. *A, B, E, Courtesy, Ronald P. Rapini, MD; C, Courtesy, YDRSC; D, Courtesy, Jean L. Bolognia, MD.*

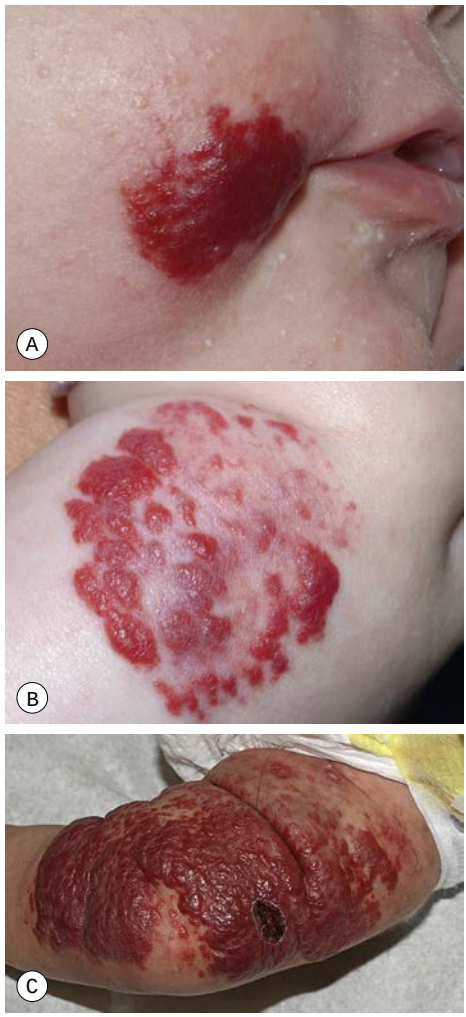


**Fig. 85.5 Superficial infantile hemangiomas.** Note the bright red color and finely lobulated surface. Involvement may be diffuse or broken up, and lesions can be focal (**A**, **B**) or have a broader, segmental distribution (**C**). *Courtesy, Julie V. Schaffer, MD.*

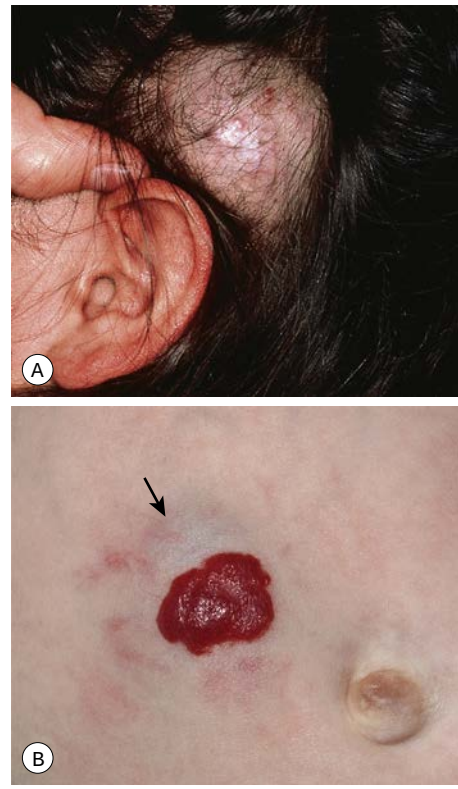


**Fig. 85.6 Deep and mixed infantile hemangiomas. A** Skin-colored deep hemangioma with overlying telangiectasias and alopecia on the scalp. **B** Mixed hemangioma composed of a well-demarcated, bright red superficial plaque plus a broader, ill-defined underlying deep nodule with a subtle light bluish hue (arrow) and scattered telangiectasias. *A, Courtesy, YDRSC; B, Courtesy, Julie V. Schaffer, MD.*

- Divided into three clinical subtypes based on the depth of cutaneous involvement:
  - *Superficial* lesions (~50%; upper dermis) are bright red with a finely lobulated surface ("strawberry" hemangiomas) during proliferation, changing to a mixture of purple-red and gray during involution (Fig. 85.5)
  - *Deep* lesions (~15%; lower dermis and subcutis) present as warm, ill-defined, light blue-purple, rubbery nodules or masses (Fig. 85.6A); often become evident later and proliferate ~1 month longer than superficial lesions
  - *Mixed* lesions (~35%) have superficial and deep components – e.g. a well-defined red plaque overlying a poorly circumscribed bluish nodule (Fig. 85.6B)
- IHs have two major distribution patterns:
  - *Focal* lesions arise from a localized nidus (see Fig. 85.5A,B)
  - *Segmental* lesions cover a broader area or developmental unit and are more likely to be associated with regional extracutaneous abnormalities – e.g. PHACE(S) and LUMBAR syndromes (discussed later) (Fig. 85.7; see Fig. 85.5C)




**Fig. 85.7 Segmental infantile hemangiomas.** **A** Segmental facial hemangioma mimicking a capillary malformation. **B** Smaller segmental hemangioma on the lip. This is a cosmetically sensitive site, especially when lesions cross the vermilion border. Hemangiomas on the vermilion lip are prone to ulceration. **C** Thicker segmental facial hemangioma partially obstructing the visual axis. This patient and the one depicted in **A** had PHACE(S) syndrome. **D** Segmental lumbosacral hemangioma. This child is at risk for LUMBAR syndrome. *Courtesy, Julie V. Schaffer, MD.*

- Some superficial IHs have *minimal or arrested growth (IH-MAG)*, presenting as patches of reticulated erythema with telangiectasias, often on a vasoconstricted background, and variable development of small red papules involving <25% of the surface area (Fig. 85.8).
- **DDx:** *precursors and early lesions*: capillary malformation, telangiectasias; *well-developed lesions*: pyogenic granuloma, other vascular tumors (e.g. kaposiform hemangioendothelioma, which can lead to Kasabach–Merritt phenomenon, see Ch. 94 and Fig. 85.15D), venous/lymphatic malformation, and rare entities such as nasal glioma and soft tissue sarcomas (see Table 53.1); *multiple lesions:* glomuvenous malformations, blue rubber bleb nevus syndrome, multifocal lymphangioendotheliomatosis with thrombocytopenia, "blueberry muffin baby" (see Ch. 99).
- When an atypical clinical appearance or natural history leads to consideration of entities in the DDx of an IH, additional evaluation may include ultrasonography, other imaging, and biopsy.

## Complications of IHs

- *Ulceration*: occurs in ~10% of lesions, especially those on the lip and in the anogenital region or other skin folds, at a median age of 4 months (Fig. 85.9); whitish discoloration of an IH in an infant <3 months of age may signal impending ulceration; results in pain, a risk of infection (relatively uncommon), and eventual scarring (see Fig. 85.4A,B).
- *Disfigurement and interference with function due to the IH's location and/or large size.*
  - *Periocular IH* – risk of astigmatism if puts pressure on globe, amblyopia if



**Fig. 85.8 Infantile hemangiomas with minimal or arrested growth (IH-MAG).** Focal small bright red papules cover <25% of the surface area and are evident at the periphery (**A**) and on the vulva and upper buttock (**B**). Presence of these papules (which may be subtle or absent), reticulated erythema, and characteristic fine to coarse telangiectasias help to distinguish these lesions from capillary–venous malformations. *Courtesy, Julie V. Schaffer, MD.*

obstructs the visual axis, and strabismus if affects orbital musculature (see Fig. 85.7A,C); requires ophthalmologic evaluation
  - *IH on nasal tip, columella, or lip (especially if crosses the vermilion border)* – high risk of distortion of facial structures (as well as ulceration if on the lip) (see Fig. 85.7B)
  - *IH on breast* (in girls) – may affect underlying breast bud, so early surgery should be avoided
- *Associated extracutaneous abnormalities.*
  - *IHs in "beard" area of the lower face* – often associated with *airway IHs*, which may present with noisy breathing or biphasic stridor; otolaryngologic evaluation is needed for infants with symptoms or when the IH is likely to be actively proliferating (i.e. <5 months of age) (Fig. 85.10)
  - *Large facial IHs, particularly segmental lesions* – risk of *PHACE(S)* syndrome: *P*, posterior fossa malformations; *H*, hemangioma; *A*, arterial abnormalities (cervical, cerebral); *C*, cardiac defects, especially coarctation of the aorta; *E*, eye anomalies; *S*, sternal defects and supraumbilical raphe (Table 85.2; Figs 85.11 and 85.12; see Fig. 85.7A,C)

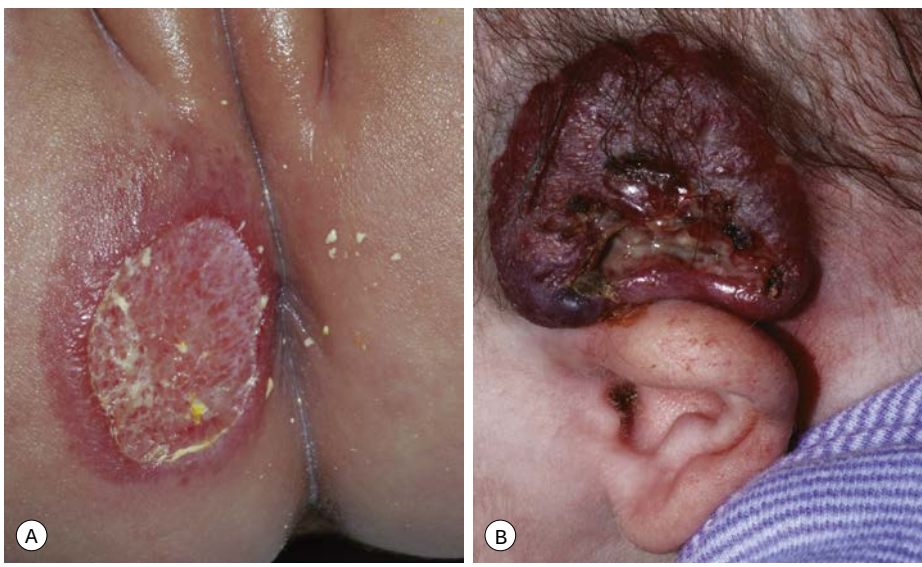

**Fig. 85.9 Ulcerated infantile hemangiomas. A** Ulcerated hemangioma on the buttock. Because the hemangioma component may not be obvious, this diagnosis should be considered when an infant presents with an ulcer in the diaper area. **B** Ulcerated superficial hemangioma above the ear. Note the distortion of the pinna. *Courtesy, Julie V. Schaffer, MD.*

**HEMANGIOMAS IN A "BEARD" DISTRIBUTION**

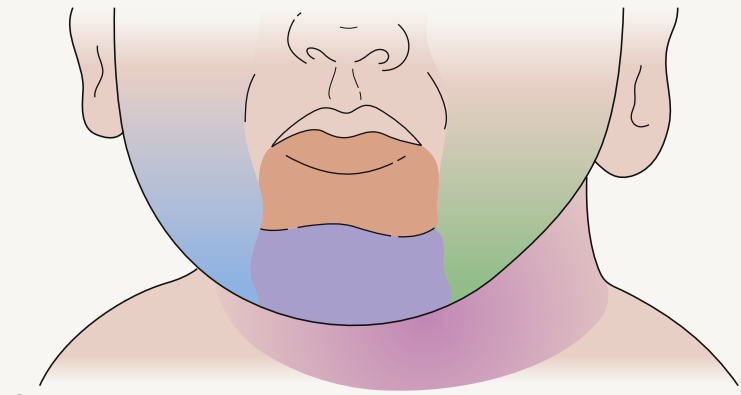

A

- Involvement of each of the five areas scores as 1 point
- In one study of 16 children with a score ≥ 4, 63% had some degree of symptomatic airway involvement



B

**Fig. 85.10 Infantile hemangiomas in a "beard" distribution. A** Anatomic sites associated with risk of an airway hemangioma. **B** Infant with a laryngeal hemangioma in addition to cutaneous lesions in a "beard" distribution. *A, Adapted with permission from Orlow SJ, Isakoff MS, Blei F. Increased risk of symptomatic hemangiomas of the airway in association with cutaneous hemangiomas in a 'beard' distribution. J Pediatr 1997;131:643–6; B, Courtesy, Julie V. Schaffer, MD.*

– *Large IHs on the lower body, particularly segmental lesions (often IH-MAG)* – risk of *LUMBAR* syndrome: *L*, *l*ower body/*l*umbosacral IH and *l*ipomas; *U*, *u*rogenital anomalies and *u*lceration; *M*, *m*yelopathy (spinal dysraphism); *B*, *b*ony deformities; *A*, *a*norectal and *a*rterial anomalies; *R*, *r*enal anomalies (Fig. 85.13; see Figs 85.7D and 85.12)
– *Midline lumbosacral IHs* – risk of *spinal dysraphism* (see Ch. 53)
– *Multifocal IHs (≥5)* – may be associated with *extracutaneous hemangiomas*, most often hepatic; the cutaneous IHs are usually relatively small and superficial, but hepatic involvement can be associated with complications such as high-output cardiac failure and

| DIAGNOSTIC CRITERIA FOR PHACE(S) SYNDROME | | |
|---|---|---|
| **Definite PHACE(S):**<br>• Hemangioma >5 cm in diameter of the head including scalp PLUS 1 major criterion or 2 minor criteria<br>• Hemangioma of the neck, upper trunk, or trunk and proximal upper extremity PLUS 2 major criteria<br>**Possible PHACE(S):**<br>• Hemangioma >5 cm in diameter of the head including scalp PLUS 1 minor criterion<br>• Hemangioma of the neck, upper trunk, or trunk and proximal upper extremity PLUS 1 major criterion or 2 minor criteria<br>• No hemangioma PLUS 2 major criteria | | |
| **Organ system** | **Major criteria** | **Minor criteria** |
| **Arterial** | • Anomalies of major cerebral or cervical arteries* – dysplasia**, hypoplasia, stenosis/occlusion, aberrant origin/course<br>• Persistent carotid–vertebrobasilar anastomosis (e.g. proatlantal segmental, hypoglossal, otic, trigeminal arteries) | • Aneurysm of cerebral arteries |
| **Structural brain** | • Posterior fossa anomalies – Dandy–Walker complex, other hypoplasia/dysplasia of the mid or hind brain | • Midline anomalies<br>• Malformation of cortical development |
| **Cardiovascular** | • Aortic arch anomalies<br>• Aberrant origin of subclavian artery ± vascular ring | • Ventricular septal defect<br>• Right/double aortic arch<br>• Systemic venous anomalies |
| **Ocular** | • Posterior segment anomalies – persistent hyperplastic primary vitreous/persistent fetal vasculature, retinal vascular anomalies, optic nerve hypoplasia, morning glory disc anomaly | • Anterior segment anomalies, e.g. sclerocornea, cataract, coloboma, microphthalmia |
| **Ventral or midline** | • Sternal defect/pit/cleft<br>• Supraumbilical raphe | • Hypopituitarism<br>• Ectopic thyroid<br>• Midline sternal papule/hamartoma |
| **Includes internal carotid artery; middle, anterior, or posterior cerebral artery; and vertebrobasilar system.*<br>***Includes kinking, looping, tortuosity, and/or dolichoectasia.* | | |

**Table 85.2 Diagnostic criteria for PHACE(S) syndrome.**

| REASONS TO CONSIDER SYSTEMIC THERAPY FOR INFANTILE HEMANGIOMAS |
|---|
| **Threatened vital functions** |
| • Vision<br>• Airway |
| **Potential for disfigurement** |
| • Nasal tip or columella<br>• Lip, especially if crosses the vermilion border<br>• Large or rapidly growing lesion, especially if on the face |
| **Severe/recalcitrant ulceration** |
| **High-output cardiac failure** |

**Table 85.3 Reasons to consider systemic therapy for infantile hemangiomas.**

hypothyroidism (due to iodothyronine deiodinase production by the IH) (Fig. 85.14; see Fig. 85.12)

## Treatment of IHs

- "Active non-intervention," including education of parents and observation with periodic photography, is sufficient for most small IHs expected to have a good cosmetic outcome.
- Patients with a potentially problematic IH should be referred for systemic therapy by 4–6 weeks of age.
- **Local Rx:** topical timolol, e.g. one drop (0.25 mg) of 0.5% gel-forming ophthalmic solution applied BID (systemic absorption

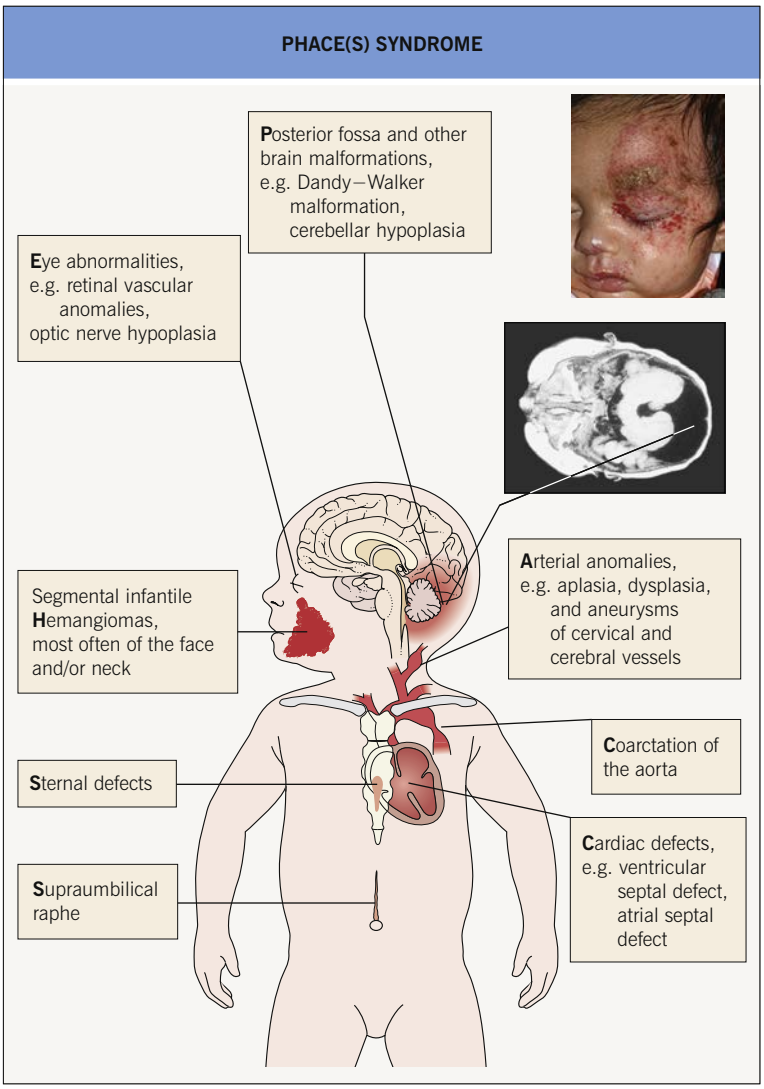


**Fig. 85.11 PHACE(S) syndrome.** Major clinical features are illustrated. Additional possible associated features include hearing impairment and endocrine abnormalities such as hypothyroidism.

possible, especially if ulcerated or involving mucous membranes; limit to <0.25 mg/kg/day), or superpotent CS for thin superficial lesions; intralesional CS for thicker lesions (avoiding the periocular area); pulsed dye laser for residual telangiectasias and possibly for thin superficial lesions.

- **Systemic Rx:** indications are listed in Table 85.3; oral propranolol (Table 85.4) has replaced prednisolone as the first-line systemic therapy.
- Management of an ulcerated IH includes wound care (e.g. hydrocolloid dressings), pain management, monitoring for infection, and specific therapies directed at the ulcer (e.g. pulsed-dye laser) or IH (e.g. β-blockers; faster healing with propranolol dose ≤1 mg/kg/d).
- Surgical excision is useful to remove fibrofatty tissue and redundant skin in involuted or partially involuted IHs; often done in preschool-aged children with cosmetically significant lesions (e.g. on the lip), and earlier resection may be considered when eventual surgery is inevitable (e.g. for some pedunculated lesions).

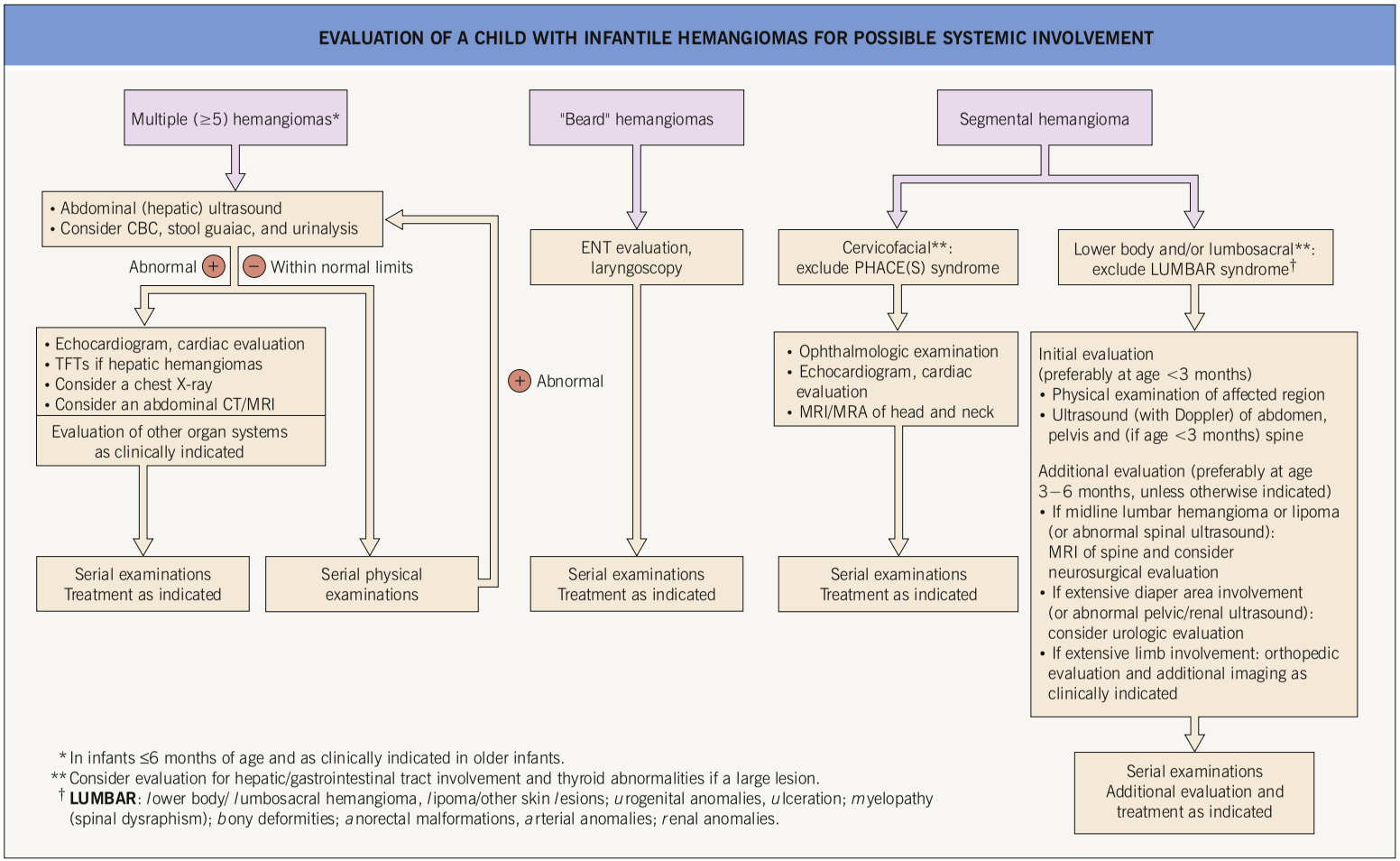


**Fig. 85.12 Evaluation of a child with infantile hemangiomas for possible systemic involvement.** See Fig. 85.11 and Table 85.2 for additional information on PHACE(S) syndrome. TFTs, thyroid function tests.

| ADMINISTRATION OF PROPRANOLOL FOR INFANTILE HEMANGIOMAS (IHS): PRETREATMENT EVALUATION, DOSING, AND MONITORING |
|---|
| **Pretreatment evaluation** |
| • *If history of bronchospasm/reactive airway disease* (a relative contraindication to propranolol therapy): consult with a pulmonologist or consider alternate therapy<br>• *If at risk for PHACE(S) syndrome**: MRI/MRA of head/neck and echocardiogram to exclude arterial and cardiovascular anomalies (see Fig. 85.12); if abnormal, consult with a neuroradiologist, neurologist, and/or cardiologist as indicated<br>• Cardiac examination, heart rate, and manual blood pressure; also consider an electrocardiogram (ECG); bradycardia (<80 beats per minute), greater than first degree heart block, blood pressure <50/30 mmHg, and decompensated heart failure are considered to be contraindications |
| **Dosing and course** |
| • Initial: usually ~1 mg/kg/day divided into 2 (or 3) doses**<br>• Goal: 2–3 mg/kg/day divided into 2 (or 3) doses**; the target dose for the FDA-approved formulation (Hemangeol™) is as high as 3.4 mg/kg/day, whereas doses ≤1 mg/kg/day may lead to shorter healing times for ulcerated hemangiomas<br>• For a proliferating IH, treatment is typically continued for 6–12 months, depending on the clinical setting and course¶<br>– The dose should be adjusted to account for weight gain and maintain the goal dose/kg, especially during the proliferative phase<br>• Taper over 2–4+ weeks before discontinuing, primarily to assess for rebound growth |
| **Monitoring** |
| • Risks of propranolol include bradycardia, hypotension, hypoglycemia, sleep disturbances, and bronchospasm<br>• Consider a brief inpatient stay (e.g. 1–2 days) with telemetry for initiation of treatment if <5 weeks of age (using corrected age for premature infants) and/or complications such as cardiovascular or cerebrovascular anomalies<br>• Outpatient initiation of therapy<br>– Monitor heart rate and blood pressure for 2 hours after the initial dose or a significant dose increase<br>– Measure heart rate and blood pressure every 4–8 weeks while on a stable dose<br>– Normal ranges for pediatric vital signs are available at: www.emedicinehealth.com/pediatric_vital_signs/article_em.htm<br>• Educate parents about signs of hypoglycemia – *early* (may be masked by β-blockade): sweating, rapid heart rate, shakiness, fussiness; *late*: lethargy, poor feeding, hypothermia, seizures<br>• Administer during or immediately after a feeding; twice daily doses should be ≥9 hours apart<br>– Dose should be lowered or therapy suspended during intercurrent illnesses with decreased oral intake or vomiting |
| **Segmental hemangioma ≥5 cm in diameter on the head or upper body (see Table 85.2).*<br>***The dose is typically increased in increments of 1 mg/kg/day weekly in an outpatient setting or after 1–3 doses in an inpatient setting, until reaching the goal dose. A lower starting dose and slower escalation may be required for patients at higher risk of complications or when treatment is initiated without in-office monitoring (e.g. starting with 0.5 mg/kg/d and increasing by 0.5 mg/kg/d every 3-4 days). The FDA-approved Hemangeol™ 4.28 mg/ml solution has a dosing chart in the package insert; the concentration differs slightly from generic propranolol 20 mg/5 ml (4 mg/ml) solution.*<br>*¶A longer duration of treatment may be required for IHs with prolonged growth or rebound growth after reduction/discontinuation of propranolol.* |

**Table 85.4 Administration of propranolol for infantile hemangiomas (IHs): pretreatment evaluation, dosing, and monitoring.** Propranolol, a nonselective β-blocker, binds to $\beta_2$-adrenergic receptors on hemangioma endothelial cells, with effects including vasoconstriction (leading to softening and dulling of color within 24 hours), decreased expression of pro-angiogenic growth factors, and induction of apoptosis. Practices vary, and the patient's age, hemangioma-related issues, and medical comorbidities also affect management.

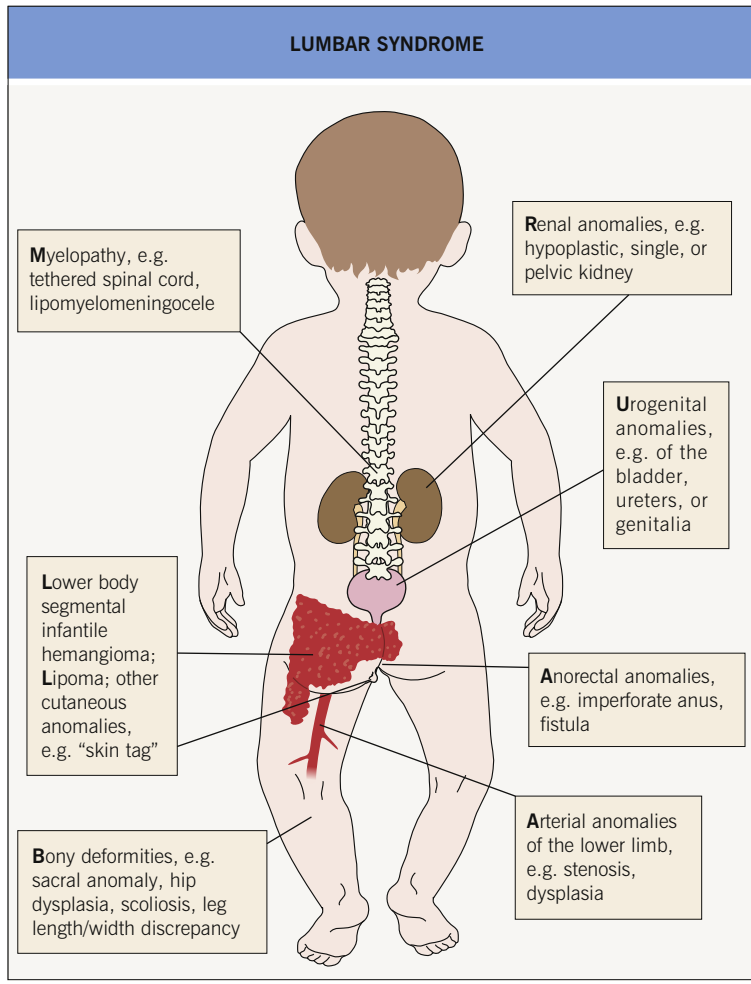


**Fig. 85.13 LUMBAR syndrome.** Major clinical features are illustrated. The segmental hemangioma is often ulcerated.



**Fig. 85.14 Multifocal infantile hemangiomas with extracutaneous hemangiomas.** This infant had many small, superficial skin lesions in a miliary pattern plus hemangiomas in the liver. Historically, this was referred to as "diffuse neonatal hemangiomatosis." *Courtesy, Julie V. Schaffer, MD.*

## Hemangioma Variants

• *Congenital hemangiomas* are fully developed at birth, typically presenting as a warm, pink to blue-violet mass or plaque with overlying coarse telangiectasias, surrounded by a vasoconstricted rim and/or radiating veins; unlike IHs, congenital hemangiomas are GLUT1-negative and often have an underlying somatic mutation in *GNAQ* or *GNA11* that activates G protein α-subunits.

– *Rapidly involuting congenital hemangioma (RICH)* – rapid involution during the first year of life (Fig. 85.15A,B)

– *Partially involuting congenital hemangioma (PICH)* – incomplete involution early in life

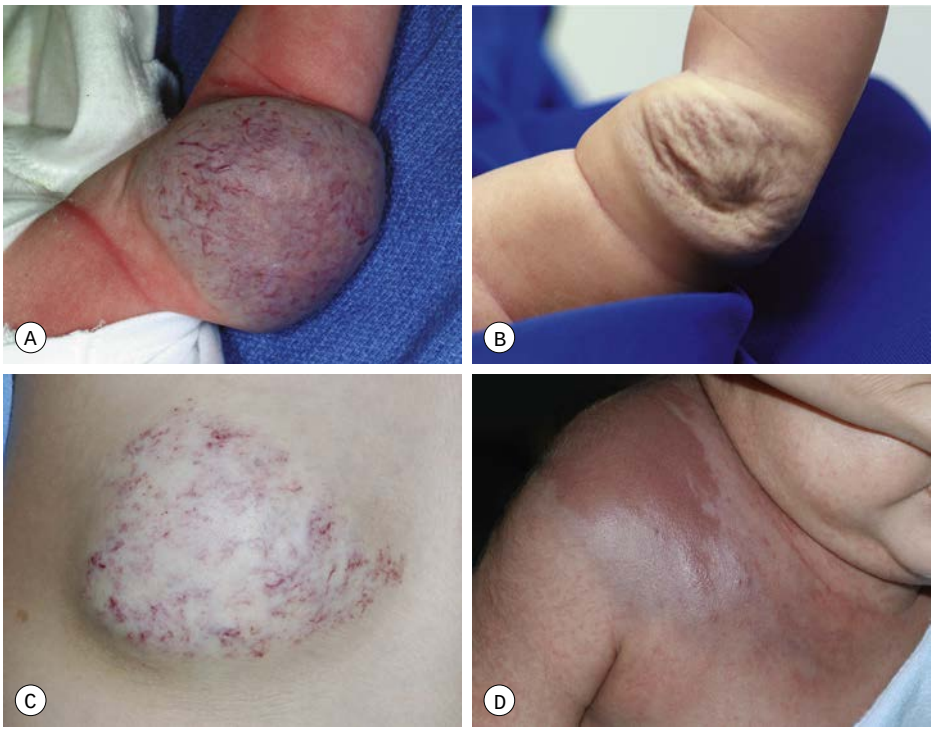


**Fig. 85.15 Congenital hemangiomas and other vascular tumors. A** Rapidly involuting congenital hemangioma (RICH) presenting as a violaceous tumor on the upper extremity with surface telangiectasias in a neonate. **B** Spontaneous involution of the RICH at 5 months of age, with fibrofatty residua. **C** Non-involuting congenital hemangioma (NICH) in a school-aged child. This lesion was fully formed at birth and is still warm and firm to palpation. Note the coarse telangiectasias and pallor. **D** Kaposiform hemangioendothelioma associated with Kasabach–Merritt phenomenon in a 5-week-old boy. Progressive induration and ecchymosis developed rapidly over a 24-hour period. An eczematous eruption is also evident. *A, B, Courtesy, Annette Wagner, MD; C, D, Courtesy, Julie V. Schaffer, MD.*

  - *Non-involuting congenital hemangioma (NICH)* – postnatal growth in proportion to the child, without involution (Fig. 85.15C); tardive expansion occasionally occurs during childhood

## Vascular Malformations

- Categorized based on the predominant type(s) of vascular channels, which are divided into slow- and fast-flow groups:
  - *Slow-flow*: capillary (port-wine stain), venous, microcystic lymphatic ("lymphangioma"), and macrocystic lymphatic ("cystic hygroma")
  - *Fast-flow*: arteriovenous (arterial anomalies + arteriovenous shunting)
- Vascular malformations may contain only one type of vessel or an arteriovenous malformation (*simple*) or ≥2 types of vessels (*combined*; e.g. capillary–lymphatic–venous malformation).
- Although they can affect any organ, vascular malformations are most easily identified in the skin and mucous membranes, where they may extend into deeper structures or be associated with other extracutaneous abnormalities.

### Capillary Malformations (CMs) and Related Conditions

#### NEVUS SIMPLEX (SALMON PATCH)

- Common congenital capillary stain (*not* a true CM) on the mid face (forehead, glabella, nasal tip, and philtrum), eyelids, occiput, and nape ("stork bite") (Fig. 85.16A,B); multiple lesions may be present (*nevus simplex complex*) and can occur in the lumbar area.
- Facial lesions often fade by early childhood.

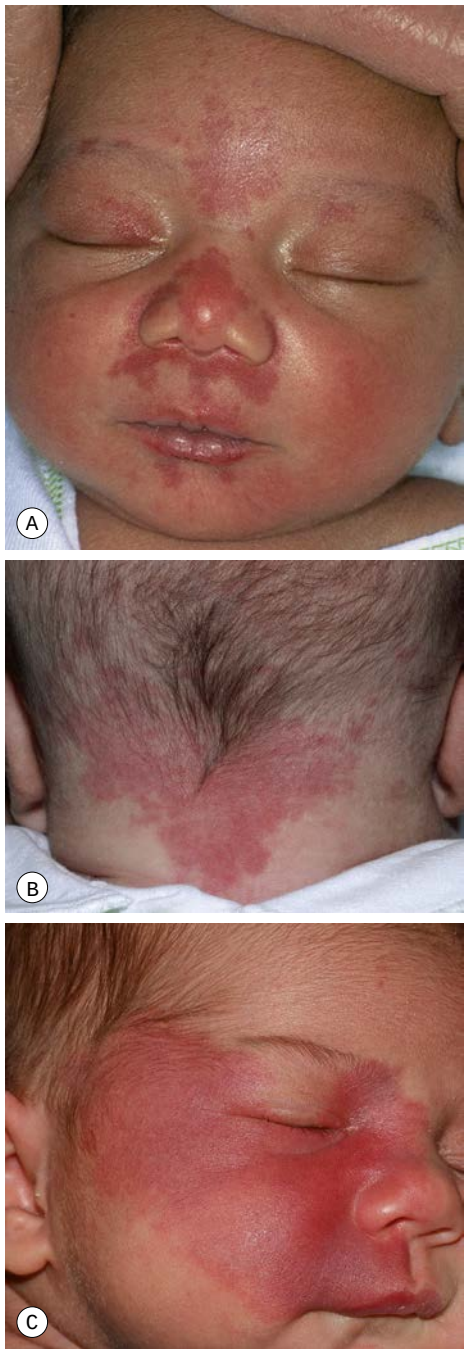


**Fig. 85.16 Nevus simplex versus port-wine stain (PWS). A** Involvement of the central face in a symmetric pattern is common with a nevus simplex (salmon patch); such lesions fade over the first few years of life but are sometimes misdiagnosed as a PWS. **B** Nevus simplex in the nape area ("stork bites") tends to be more persistent. **C** In this young infant with a PWS in the maxillary region, the affected skin is smooth. This lesion will persist. *A, Courtesy, YDRSC; B, C, Courtesy, Julie V. Schaffer, MD.*



**Fig. 85.17 Facial port-wine stains in the maxillary region with hypertrophic changes in an adult.** Note the prominent skin thickening and nodularity. *Courtesy, Pablo Boixeda, MD.*

### PORT-WINE STAIN (PWS)

- Mosaic activating mutations in the *GNAQ* gene, which encodes a G protein α-subunit, underlie both nonsyndromic PWSs and Sturge–Weber syndrome.
- PWSs present at birth as pinkish-red macules and patches, often in a segmental pattern (Fig. 85.16C).
- Over time, may develop a deeper purplish-red color, and affected skin (especially on the face) often thickens and becomes nodular; overgrowth of underlying soft tissues and bones can also occur (Figs 85.17 and 85.18).
- **DDx:** *in infant*: nevus simplex, early or arrested-growth IH; CMTC (especially if on an extremity), stage 1 arteriovenous malformation, *verrucous venocapillary malformation* ("verrucous hemangioma"; congenital red-purple hyperkeratotic plaques, often in a segmental pattern favoring the extremities, with growth proportional to the child).
- **Rx:** pulsed dye laser therapy, preferably initiated during infancy for facial lesions to avoid psychosocial distress and lesional thickening.
- *Sturge–Weber syndrome:* ocular and/or leptomeningeal vascular malformations may accompany a facial PWS involving the "forehead area," which also includes the upper

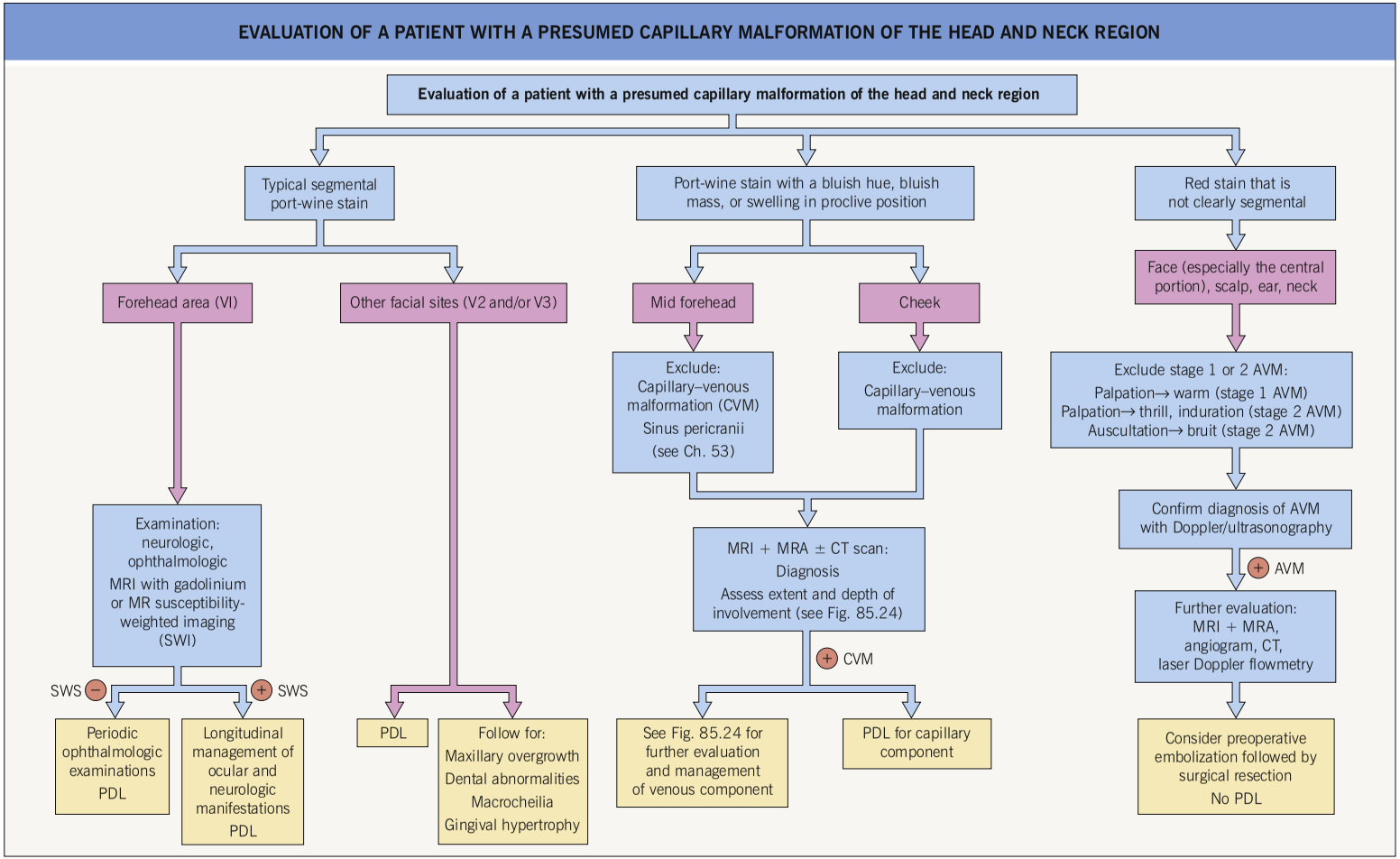


**Fig. 85.18 Evaluation of a patient with a presumed capillary malformation of the head and neck region.** AVM, arteriovenous malformation; CVM, capillary venous malformation; PDL, pulsed dye laser; PET, positron emission tomography; SPECT, single photon emission computed tomography; SWS, Sturge–Weber syndrome.



**Fig. 85.19 Infant at risk for Sturge–Weber syndrome (SWS).** The port-wine stain covers most of the left side of the face, with involvement of the "forehead area" conferring risk of SWS. *Courtesy, Odile Enjolras, MD.*

eyelid and is delineated inferiorly by a line drawn from the outer canthus to the top of the ear; this area encompasses most of the trigeminal V1 and small portions of the V2/V3 dermatomes (Fig. 85.19). Affected individuals can develop glaucoma and neurologic sequelae such as developmental delay and contralateral seizures or hemiparesis. Neuroimaging (e.g. susceptibility-weighted MRI) can reliably exclude leptomeningeal involvement by 1 year of age, and prophylactic aspirin administration may reduce the likelihood of neurologic symptoms in SWS patients.

- *Phakomatosis pigmentovascularis (PPV)*: PWS coexisting with aberrant Mongolian spots (dermal melanocytosis; both caused by mosaic *GNAQ/11* mutations) (Fig. 85.20) or a nevus spilus; a nevus anemicus may also be present.
- *Diffuse capillary malformation with overgrowth*: widespread reticulated CM associated with soft tissue hypertrophy that does not necessarily correlate with the CM location and is not progressive (Fig. 85.21A); may be due to a *GNA11* mutation.
- *Megalencephaly–capillary malformation* (previously *macrocephaly–CMTC*): reticulated PWS and persistent nevus simplex associated with asymmetric overgrowth, macrocephaly, and developmental delay; due to mosaic *PIK3CA* mutations (Fig. 85.21B).



**Fig. 85.20 Phakomatosis pigmentovascularis type 2.** A large port-wine stain and extensive dermal melanocytosis are seen. *Courtesy, Julie V. Schaffer, MD.*

#### CUTIS MARMORATA TELANGIECTATICA CONGENITA (CMTC)

- Red-purple, broad reticulated vascular pattern intermingled with telangiectasias, ± prominent veins and atrophy; most often affects a limb, which may be hypoplastic; occasionally generalized (Fig. 85.22).
- *Adams–Oliver syndrome* features CMTC together with aplasia cutis congenita and limb defects (see Table 53.3).

### Venous Malformations (VMs; Former Misnomer of "Cavernous Hemangioma")

#### CLASSIC VMs

- Soft, compressible bluish nodules that fill with dependency; may be focal, segmental, or widespread, and often extend into underlying muscles and bones (Fig. 85.23).
- Both *multiple cutaneous and mucosal VMs* with autosomal dominant inheritance and sporadic VMs can result from mutations in the *TEK* gene, which encodes an endothelial cell-specific tyrosine kinase, or *PIK3CA*.
- *Blue rubber bleb nevus (Bean) syndrome* also presents with multiple cutaneous and mucosal (e.g. GI) VMs.
- An approach to the evaluation and management of VMs at different sites is presented in Fig. 85.24.

#### GLOMUVENOUS MALFORMATIONS (GVMs; PREVIOUSLY KNOWN AS GLOMANGIOMATOSIS)

- Pink to blue-purple nodules and cobblestoned plaques that resist full compression

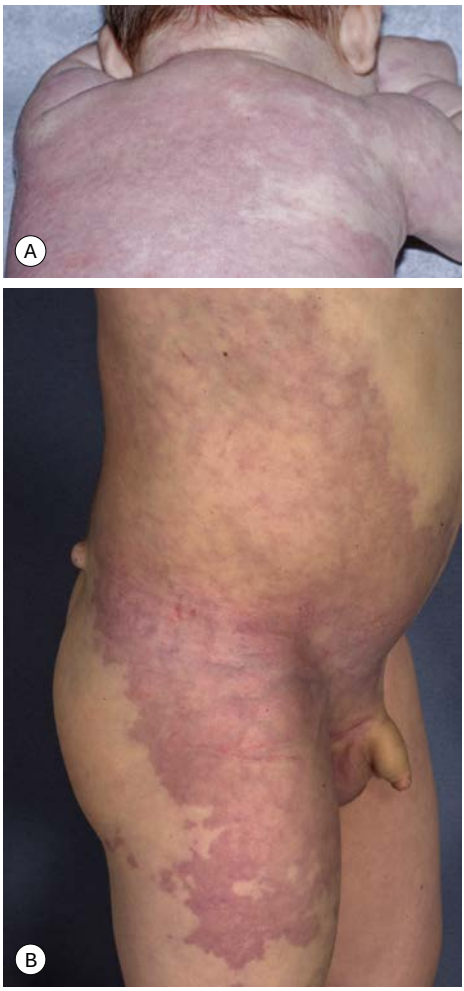


**Fig. 85.21 Reticulated capillary malformations. A** Diffuse capillary malformation with overgrowth. This normocephalic infant has an extensive reticulated capillary malformation involving the trunk, one arm, and both legs. **B** Megalencephaly–capillary malformation syndrome. This boy has hemihypertrophy of the side of the body *opposite* to the PWS. *Courtesy, Julie V. Schaffer, MD.*



**Fig. 85.22 Cutis marmorata telangiectatica congenita (CMTC) with atrophy of the affected limb.** The color of the broad vascular network can be red-purple (as in this infant) to brownish-purple. *Courtesy, YDRSC.*

and are painful upon palpation; may be focal, segmental, or widespread and (unlike classic VMs) are typically limited to the skin and subcutis (Fig. 85.25).

- Autosomal dominant inheritance due to mutations in the glomulin gene (*GLMN*).

#### MAFFUCCI SYNDROME

- Association of VMs with enchondromas, most often of the extremities; skin lesions may also have features of a spindle cell hemangioma.

## Lymphatic Anomalies

- *Lymphatic malformations (LMs)* are due to excessive aberrant lymphatic channels, often due to an underlying mosaic *PIK3CA* mutation, whereas *lymphedema* results from hypoplasia or disruption of the lymphatics.

#### LYMPHATIC MALFORMATIONS

- *Microcystic LM ("lymphangioma circumscriptum")*: clusters of clear or hemorrhagic, vesicle-like papules favoring the proximal limbs and chest; intermittent hemorrhage and leakage of lymph can occur (Fig. 85.26A–D). A subset of superficial LM presents as red-purple, geographic patches with a finely reticulated, net-like pattern of vascular structures.
- *Macrocystic LM ("cystic hygroma")*: ballotable subcutaneous masses representing




**Fig. 85.23 Venous malformations (VMs). A** Distortion of the tongue and lower lip has led to an open bite. **B** The skin and muscles of the entire arm are affected, with soft bluish nodules and obvious swelling in the dependent position. **C** This VM has a segmental distribution on the right trunk and involvement of the ipsilateral arm. *Courtesy, Odile Enjolras, MD.*

larger lymphatic cysts; favor the neck, axilla, and lateral chest wall (Fig. 85.26E).

- Cellulitis-like inflammatory reactions can be triggered by trauma or infection and may result in expansion and worsening over time.
- Cervicofacial lesions often distort underlying bony structures, and oropharyngeal involvement can lead to airway compromise; rare complications include visceral "lymphangiomatosis" and massive osteolysis (*Gorham–Stout [disappearing bone] disease*).
- **DDx:** acquired cutaneous lymphangiectasia (e.g. due to Crohn disease, recurrent cellulitis, or intralymphatic metastases).
- Radiologic evaluation: ultrasonography, MRI with gadolinium (lack enhancement).
- **Rx:** topical or oral sirolimus, sclerotherapy, laser therapy (for microcystic lesions), surgical excision (but recurrences are common).

#### PRIMARY LYMPHEDEMA

- Most often affects the extremities (lower > upper), with occasional genital, cephalic, or generalized involvement; may be associated with pulmonary or GI lymphangiectasia.
- *Congenital lymphedema* is present at birth or develops during infancy; etiologies include *Milroy disease* (mutations in the gene encoding vascular endothelial growth factor receptor 3) and *Turner* and *Noonan syndromes.*
- *Lymphedema praecox* presents around puberty; etiologies include *Meige disease* and *lymphedema–distichiasis syndrome.*
- Secondary lymphedema is discussed in Chapter 86.

### Arteriovenous Malformations (AVMs)

- Fast-flow malformations with potential for serious complications (e.g. amputation, deformity); frequently due to a mosaic mutation

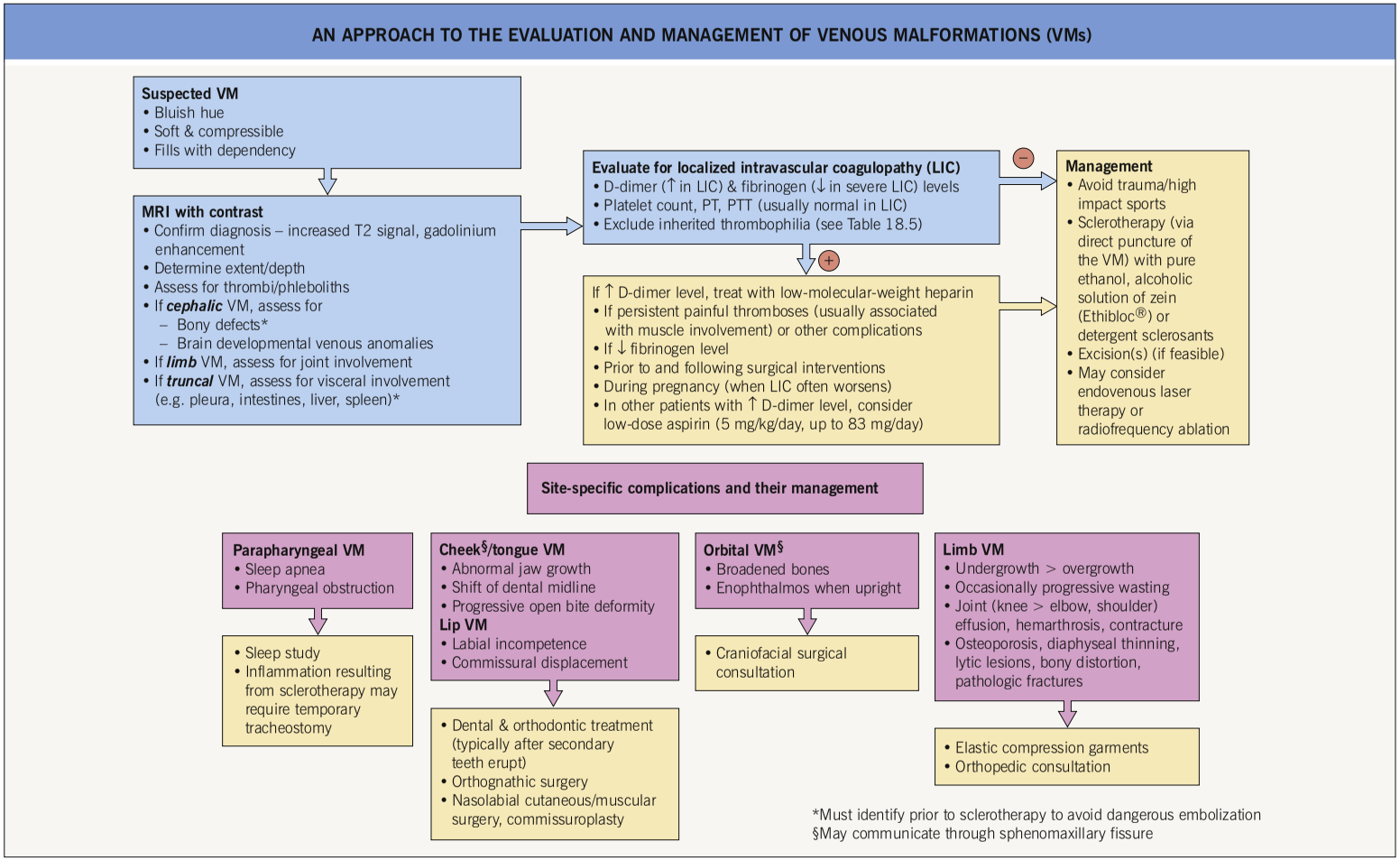


**Fig. 85.24 An approach to the evaluation and management of venous malformations (VMs).**



**Fig. 85.25 Segmental glomuvenous malformation on the abdomen.** Coalescing blue-purple papulonodules. *Courtesy, Paula North, MD.*

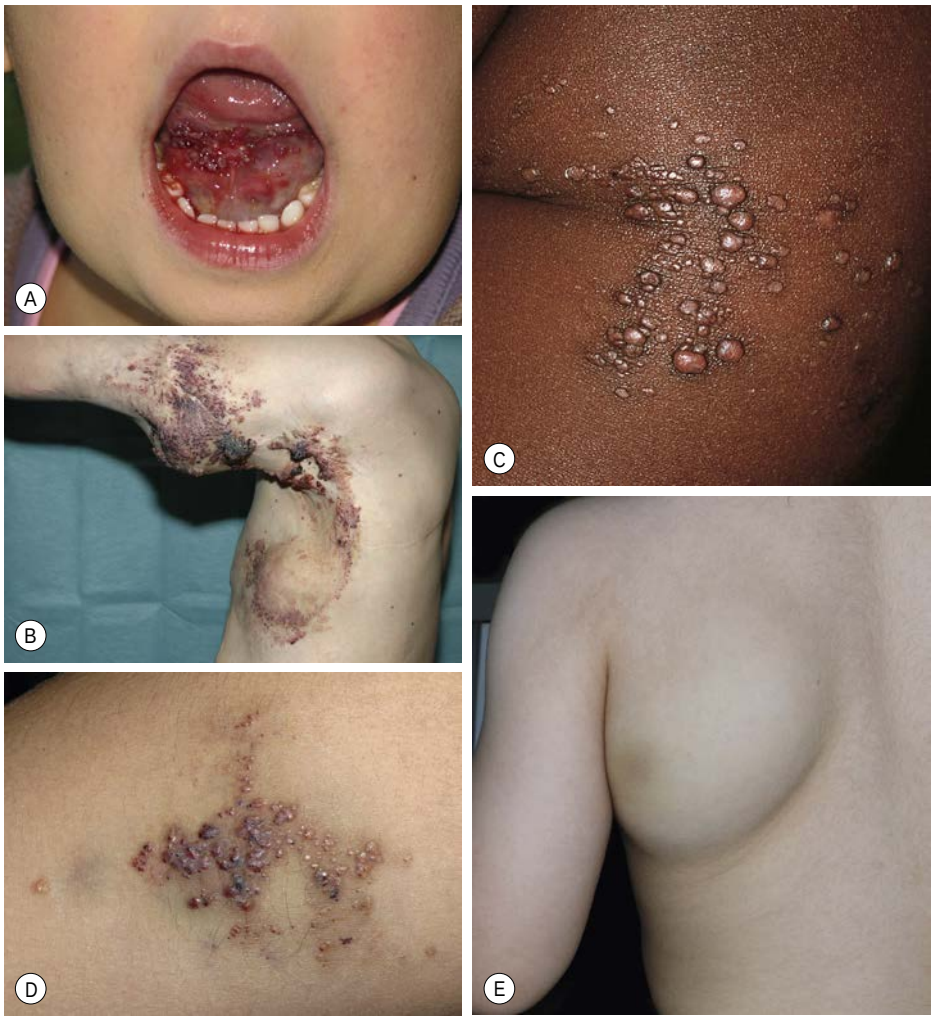


**Fig. 85.26 Lymphatic malformations (LMs). A–D** Microcystic LMs presenting as clusters of clear or hemorrhagic vesicles, with active bleeding from lesions in the mouth **(A)**. The crops of vesicles in **(B)** recurred years after surgical resection (utilizing grafting and linear closure) of a large microcystic LM affecting the skin and deeper structures of the arm and thorax. **E** Macrocystic LM on the lateral trunk. The mass was soft except for a focal firm area of hemorrhage associated with bruise-like discoloration of the overlying skin. *A, B, Courtesy, Odile Enjolras, MD; C, Courtesy, YDRSC; D, E, Courtesy, Julie V. Schaffer, MD.*

affecting the mitogen-activated protein kinase (MAPK) pathway (e.g. *KRAS, MAP2K1*).

- Often involve the cephalic region, especially the central face, with approximately half of lesions evident at birth; may worsen with puberty, pregnancy, trauma, partial excision, or proximal embolization.
- Divided into four stages based on clinical severity:
  - *Stage 1 – dormant*: red, warm and macular (mimicking a PWS) or slightly infiltrated (Fig. 85.27A,B)
  - *Stage 2 – expansion*: warm mass with thrill/throbbing and dilated draining veins
  - *Stage 3 – destruction*: pain, necrosis, and ulceration; ± lytic bone lesions (Fig. 85.27C)
  - *Stage 4 – cardiac decompensation*: high-output cardiac failure
- Radiologic evaluation: ultrasonography, MRI/MRA, arteriography.
- **Rx:** complete excision after judicious preoperative embolization.
- *Acroangiodermatitis* (pseudo-Kaposi sarcoma; see Ch. 86) can occur in association with a lower extremity AVM.
- *Metameric AVMs.*
  - *Cobb syndrome*: cutaneous (may mimic a CM or angiokeratomas) in dermatomal distribution + intraspinal/vertebral
  - *Bonnet–Dechaume–Blanc (Wyburn–Mason) syndrome*: cutaneous facial + orbit/eye and/or brain

## *PIK3CA*-Related Overgrowth Spectrum and Other Syndromes Associated with Combined Vascular Malformations

- *Klippel–Trenaunay syndrome*: CM + VM ± LM due to a mosaic *PIK3CA* mutation, associated with progressive overgrowth of the affected extremity; well-demarcated geographic stains usually have a lymphatic component, which increases the likelihood of massive overgrowth and cellulitis; risk of deep venous thrombosis/pulmonary embolism (Fig. 85.28).
- *Proteus syndrome* (see Table 51.3): mosaic disorder due to *AKT1* mutations; can feature CM, VM, and/or LM.
- *CLOVES syndrome: c*ongenital *l*ipomatous *o*vergrowth, *v*ascular malformations (slow- or




**Fig. 85.27 Arteriovenous malformations (AVMs). A, B** Dormant (stage 1) AVMs mimicking a port-wine stain **(A)** and infantile hemangioma **(B). C** Destructive (stage 3) AVM that has led to cutaneous necrosis. *A, B, Courtesy, Odile Enjolras, MD; C, Courtesy, Juan Carlos Lopez, MD.*



**Fig. 85.28 Klippel–Trenaunay syndrome (KTS).** Dilated incompetent veins and an enlarged lower limb are evident. The sharply demarcated *geographic* borders of this capillary stain and the superimposed purple papulovesicles (representing lymphangiectasias) are clues to the presence of a lymphatic malformation. In contrast, KTS without a lymphatic component often presents with an ill-defined *patchy* capillary stain in a segmental or haphazard distribution. *Courtesy, USCDRSC.*



**Fig. 85.29 Capillary malformation–arteriovenous malformation due to a *RASA1* mutation.** Multiple pink-red macules. A blanched halo is often evident at the periphery of lesions. *Courtesy, Eulalia Baselga, MD.*

fast-flow), *e*pidermal nevi, and *s*keletal anomalies (e.g. scoliosis, splayed feet) due to mosaic *PIK3CA* mutations.

- *PTEN hamartoma tumor syndrome* (see Ch. 52): often intramuscular fast-flow anomalies associated with ectopic fat and dilated draining veins; ± CM and LM components.
- *Cerebral CM and hyperkeratotic cutaneous CM-VM:* autosomal dominant disorder, usually due to *KRIT1* mutations; congenital red-purple plaques and red-brown macules with peripheral telangiectatic puncta.
- *CM-AVM syndrome*: autosomal dominant disorder due to *RASA1* or *EPHB4* mutations; presents with multiple small CMs ± AVM(s) (Fig. 85.29) and sometimes *Parkes–Weber syndrome* (limb overgrowth associated with an AVM).

For further information see Chs 103 and 104 from *Dermatology, Fourth Edition*.

**For additional online figures and tables visit www.expertconsult.com**



**eFig. 85.1 Deep infantile hemangioma.**
*Courtesy, Anthony Mancini, MD.*







**eFig. 85.2 Segmental superficial infantile hemangiomas.** *A, Courtesy, Anita Haggstrom, MD, and Maria Garzon, MD; B, Courtesy, Julie V. Schaffer, MD.*

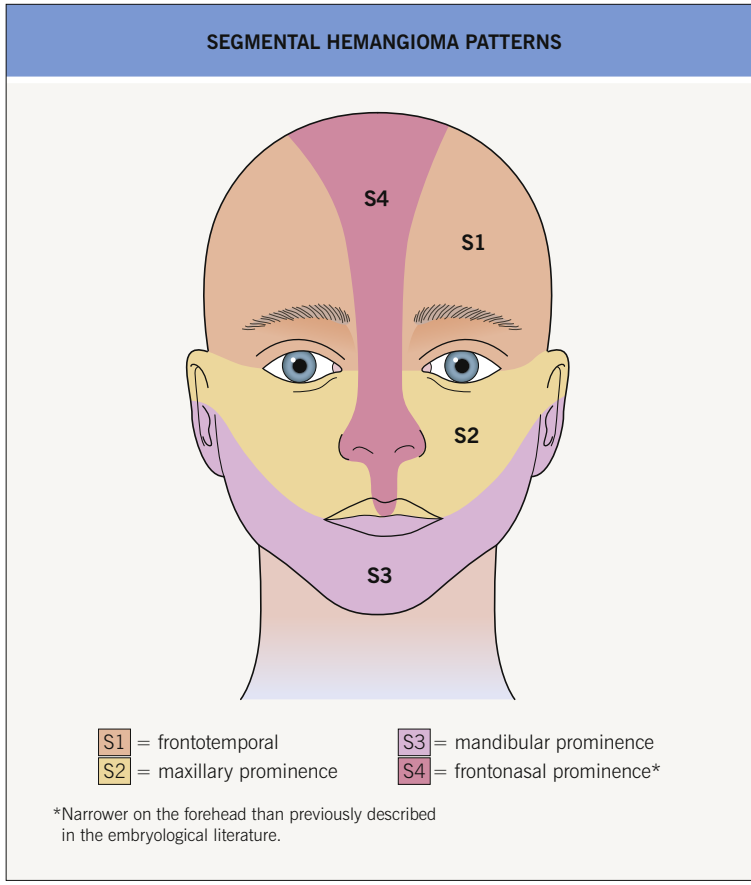


**eFig. 85.3 Segmental hemangioma patterns.** Based upon a prospective study (n = 165) of image analyses of hemangiomas. *Adapted with permission from Haggstrom AN, Lammer EJ, Schneider RA, et al. Patterns of infantile hemangiomas: new clues to hemangioma pathogenesis and embryonic facial development. Pediatrics 2006;117:698–703.*



**eFig. 85.4 "Biker glove" pattern of an acral infantile hemangioma.** Note the characteristic sparing of the distal fingers. *Courtesy, Anita Haggstrom, MD, and Maria Garzon, MD.*

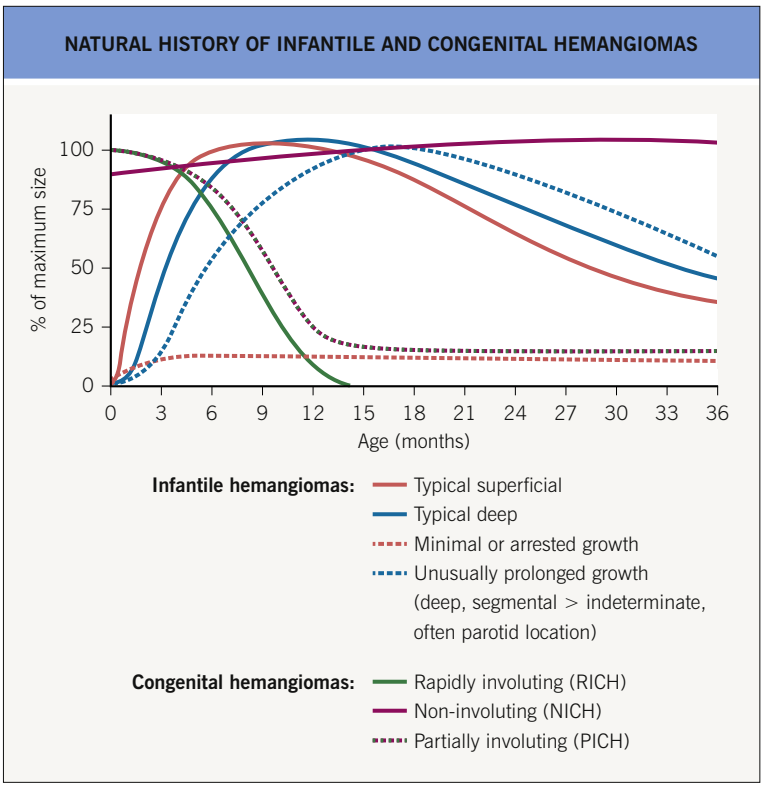


**eFig. 85.5 Natural history of infantile and congenital hemangiomas.**




**eFig. 85.6 Infantile hemangiomas with minimal or arrested growth (IH-MAG). A–D** Focal small bright red papules cover <25% of the surface area. Presence of these papules (which may be subtle or absent; arrow in **D**), reticulated erythema, and characteristic fine to coarse telangiectasias help to distinguish these lesions from capillary–venous malformations. *A, B, Courtesy, Anita Haggstrom, MD, and Maria Garzon, MD; C, D, Courtesy, Julie V. Schaffer, MD.*




**eFig. 85.7 Ulcerated superficial hemangioma treated with topical timolol. A** An ulcerated superficial infantile hemangioma on the neck of a 10-week-old girl. **B** Four weeks after institution of topical timolol 0.5% gel, with one small drop applied twice daily. Note the healing of the ulcer, which occurred within two weeks, as well as the lighter color and decreased thickness of the hemangioma. *Courtesy, Julie V. Schaffer, MD.*

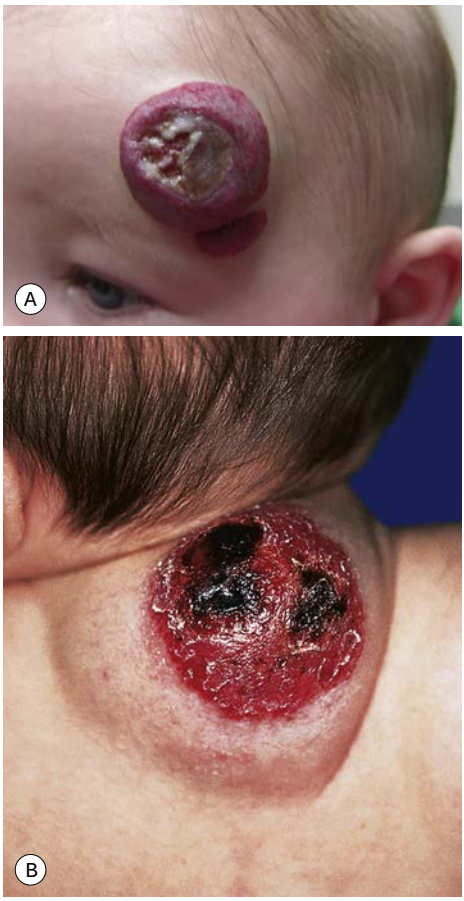


**eFig. 85.8 Ulcerated mixed hemangiomas.**
*A, Courtesy, Anita Haggstrom, MD, and Maria Garzon, MD; B, Courtesy, YDRSC.*



**eFig. 85.9 Multifocal infantile hemangiomas with extracutaneous hemangiomas.** In this child, multiple small, superficial skin lesions were present in a miliary pattern and hemangiomas were present in the liver. Historically, this was referred to as "diffuse neonatal hemangiomatosis." *Courtesy, Ronald P. Rapini, MD.*

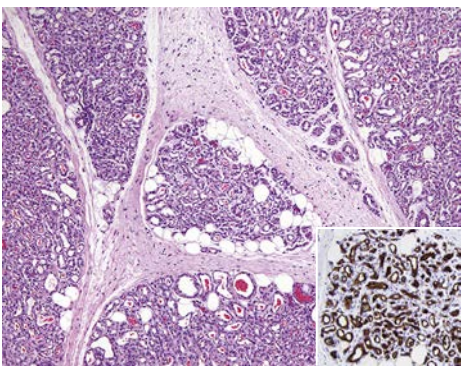

**eFig. 85.10 Histologic features of a proliferating infantile hemangioma.** Collections of endothelial cells forming vascular lumens, separated by fibrotic septae. The inset shows positive GLUT-1 staining of endothelial cells. *Courtesy, Matthew Kuhar, MD.*




**eFig. 85.11 Rapidly involuting congenital hemangioma (RICH). A** Violaceous nodule with coarse telangiectasias and peripheral blanching in a neonate. **B** Spontaneous involution at 5 months of age, with a residual depression. *Courtesy, Julie V. Schaffer, MD.*



**eFig. 85.12 Non-involuting congenital hemangioma (NICH).** Violaceous nodule with coarse telangiectasias and peripheral blanching in a young child. *Courtesy, Julie V. Schaffer, MD.*




**eFig. 85.13 Phakomatosis pigmentovascularis. A** A port-wine stain and nevus anemicus are intermingled on the shoulder of this man, who also had extensive dermal melanocytosis. **B** Port-wine stains and extensive dermal melanocytosis are intermixed. *A, Courtesy, Odile Enjolras, MD; B, Courtesy, YDRSC.*




**eFig. 85.14 Cutis marmorata telangiectatica congenita (CMTC).** Note the hypoplasia of the affected limb (**A**) and associated cutaneous atrophy leading to a depression (**B**). The color of the broad vascular network can be red-purple (**A**) or, as seen in this infant of Caribbean descent, brownish-purple (**B**). *A, Courtesy, Eulalia Baselga, MD; B, Courtesy, Richard Antaya, MD.*



**eFig. 85.15 Blue rubber bleb nevus syndrome.** Small blue venous nodules are superimposed on a larger subcutaneous venous malformations. *Courtesy, Juan Carlos Piez, MD.*



**eFig. 85.16 Plaque-type glomuvenous malformation on the distal lower extremity.** *Courtesy, YDRSC.*

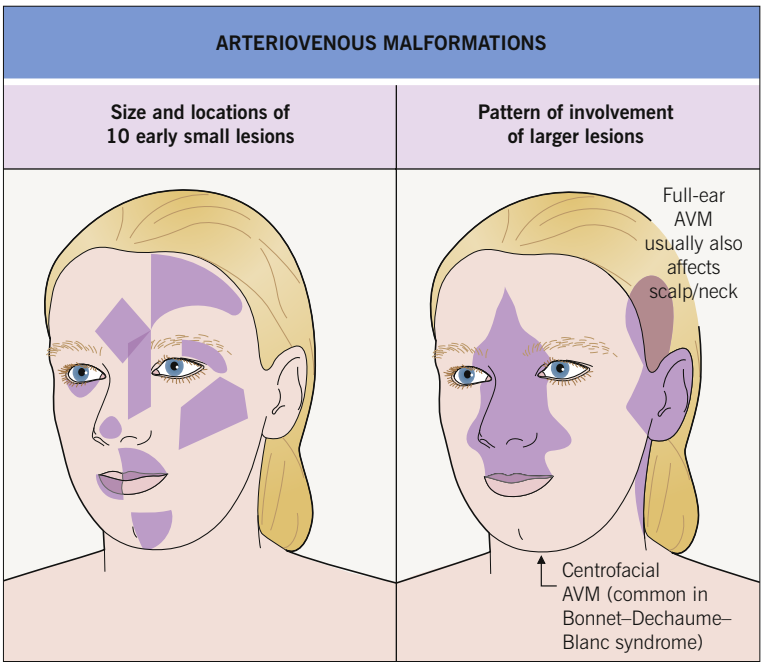


**eFig. 85.17 Arteriovenous malformations – size, locations, and patterns.** *Courtesy, Odile Enjolras, MD.*



**eFig. 85.18 Cobb syndrome.** This stain on the nape has an appearance reminiscent of a salmon patch, but it was warm and superimposed darker red macules progressively appeared. Doppler ultrasonography, MRI, and arteriography confirmed the presence of a metameric arteriovenous malformation of the skin and spine. *Courtesy, Odile Enjolras, MD.*

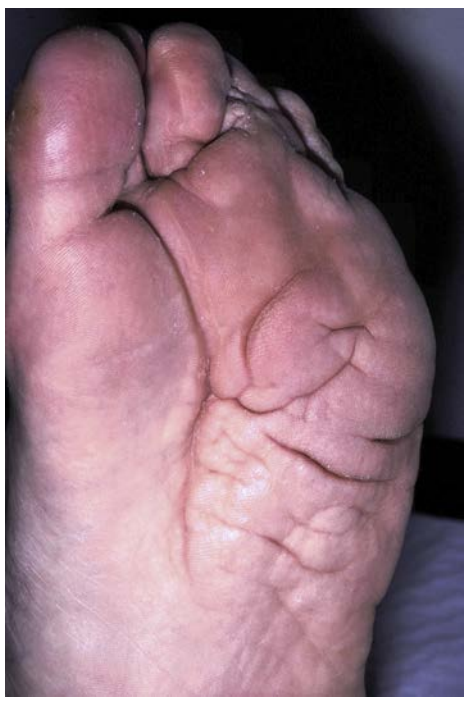

**eFig. 85.19 Plantar cerebriform connective tissue nevus in a man with Proteus syndrome.** *Courtesy, Odile Enjolras, MD.*

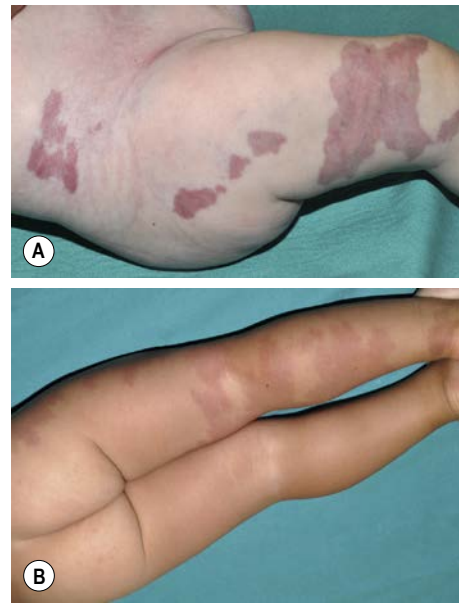


**eFig. 85.20 Klippel–Trenaunay syndrome.** **A** Darker red-purple, well-demarcated geographic capillary stain on the thigh associated with dilated veins and an enlarged lower limb. **B** Light red, blotchy capillary stain associated with enlargement of the lower extremity. *Courtesy, Antonio Torrelo, MD.*




**eFig. 85.21 CLAPO syndrome due to a mosaic *PIK3CA* mutation.** **A** Capillary malformation on the lower lip and chin, with swelling of the neck due to a lymphatic malformation. **B** Microcystic lymphatic malformation on the tongue. *A, Courtesy, Julie V. Schaffer, MD; B, Courtesy, Eulalia Baselga, MD.*







**eFig. 85.22 Capillary malformation–arteriovenous malformation (CM-AVM) due to a *RASA1* mutation.** Multiple pink-red (**A**) to brownish (**B**) macules. A subtle blanched halo is often evident at the periphery of the lesions. *A, Courtesy, Margarita Larralde, MD; B, Courtesy, Eulalia Baselga, MD.*

| BIOLOGIC CLASSIFICATION OF VASCULAR BIRTHMARKS |
|---|
| **Vascular tumors** |
| **Benign**<br>• Infantile hemangioma<br>• Congenital hemangioma (rapidly involuting, non-involuting, partially involuting)<br>• Tufted angioma<br>• Pyogenic granuloma<br>• Spindle cell hemangioma<br>• Others |
| **Locally aggressive or borderline**<br>• Kaposiform hemangioendothelioma<br>• Others, e.g. retiform or composite hemangioendothelioma |
| **Vascular malformations** |
| **Simple**<br>• Capillary malformations (CMs)<br>• Venous malformations (VMs)<br>– Common, glomuvenous, others<br>• Lymphatic malformations (LMs)<br>– Common: macrocystic, microcystic, mixed; others<br>• Arteriovenous malformations, arteriovenous fistula (AVMs, AVFs; high flow) |
| **Combined**<br>• CVM, CLM, LVM, CAVM, CLAVM, others of major named vessels |
| **Associated with other anomalies**<br>• Sturge–Weber syndrome, Klippel–Trenaunay syndrome, others |
| **Provisionally unclassified** |
| • Angiokeratomas<br>• Multifocal lymphangioendotheliomatosis with thrombocytopenia<br>• Kaposiform lymphangiomatosis<br>• Others |

**eTable 85.1 Biologic classification of vascular birthmarks.** Updated based on the 2014 International Society for the Study of Vascular Anomalies (ISSVA) Classification of Vascular Anomalies. Other vascular tumors are discussed in Chapter 94. CAVM, capillary–arteriovenous malformation; CLAVM, capillary–lymphatic–arteriovenous malformation; CLM, capillary–lymphatic malformation; CVM, capillary–venous malformation; LVM, lymphatic–venous malformation

| KEY FEATURES OF INFANTILE AND CONGENITAL HEMANGIOMAS | | |
|---|---|---|
| **Infantile hemangioma** | **Rapidly involuting congenital hemangioma (RICH)** | **Non-involuting congenital hemangioma (NICH)** |
| Usually absent or precursor lesion at birth | Fully developed at birth | Fully developed at birth |
| Rapid postnatal proliferation | Intrauterine proliferation | Intrauterine proliferation then proportionate postnatal growth |
| Slow spontaneous involution | Rapid involution during the first year* | Do not involute spontaneously |
| More common in girls | Equal prevalence or slightly more common in girls | Equal prevalence or slightly more common in girls |
| Lobular endothelial proliferation during proliferative phase; fibrous and fatty tissue during involution | Capillary lobules within fibrotic stroma containing thin-walled vessels, hemosiderin | Lobules of small, thin-walled vessels with large central vessel; dilated, dysplastic veins between lobules; "hobnailed" endothelial cells lining intralobular vessels |
| Positive GLUT1 and Lewis Y antigen | Negative GLUT1 and Lewis Y antigen | Negative GLUT1 and Lewis Y antigen |

**Occasionally associated with thrombocytopenia during the neonatal period.*

**eTable 85.2 Key features of infantile and congenital hemangiomas.** Partially involuting congenital hemangiomas (PICHs) represent an intermediate form that undergoes incomplete involution.

| OVERGROWTH SYNDROMES WITH VASCULAR MALFORMATIONS | | | | | | |
|---|---|---|---|---|---|---|
| | **DCMO** | ***PIK3CA*-related overgrowth spectrum** | | | **Proteus** | **PHTS** |
| | | **M-CM** | **KTS** | **CLOVES** | | |
| **Gene** | ?<br>*GNA11* (in some patients) | *PIK3CA*, mosaic | *PIK3CA**, mosaic | *PIK3CA*, mosaic | *AKT1*, mosaic | *PTEN* germline with somatic second mutation |
| **Asymmetric/segmental overgrowth** | | | | | | |
| **At birth** | + | + | + | + | –/minimal | + |
| **Progressive** | – | – | + | + | +++ | + |
| **Correlates with site(s) of vascular malformation** | – | – | + | + | – | Variable |
| **Digital abnormalities** | 30%: syndactyly, sandal-gap, macrodactyly | Syndactyly > polydactyly, macrodactyly; sandal gap | Occasional macrodactyly, syndactyly (associated with deep venous anomalies) | Broad hands/feet, macrodactyly (especially 3rd toe), sandal gap | Macrodactyly with distorted/deformed digits | – |
| **Macrocephaly** | – | +; (hemi)megalencephaly, dolichocephaly | – | 30% with (hemi) megalencephaly | Dolichocephaly | + |
| **Capillary malformations** | Reticulated ± confluent areas; widespread, block-like | Reticulated; widespread, block-like; persistent nevus simplex | Geographic, well-demarcated, dark (associated with LM) or blotchy light; on extremity ± extension | Geographic, well-demarcated, dark; on trunk overlying lipomatous mass | Well demarcated; often on trunk | Variable |

**eTable 85.3 Overgrowth syndromes with vascular malformations.** *Continued*

| OVERGROWTH SYNDROMES WITH VASCULAR MALFORMATIONS | | | | | | |
|---|---|---|---|---|---|---|
| | **DCMO** | ***PIK3CA*-related overgrowth spectrum** | | | **Proteus** | **PHTS** |
| | | **M-CM** | **KTS** | **CLOVES** | | |
| **Venous anomalies** | Variable prominent veins | Variable prominent veins | VM[§]; often persistent lateral marginal vein, abnormal deep venous system | VM[§] of superficial, deep thoracic, and often major central veins | Variable VM[§] | Variable VM; dilated draining veins associated with high-flow lesions |
| **Lymphatic anomalies** | – | – | Often LM with overlying vesicles, lymphedema | Truncal LM within lipomatous mass; overlying vesicles | Variable LM | Variable LM, lymphedema |
| **Arteriovenous malformations** | – | – | – | Variable spinal/paraspinal AVM | – | Fast-flow "PTEN hamartoma of soft tissue" with intramuscular involvement and ectopic fat |
| **Other cutaneous features** | – | Hyperelastic, soft/doughy skin | – | Lipomatous truncal masses, epidermal nevi, furrowed soles | Cerebriform connective tissue nevi of palms/soles, epidermal nevi, lipomatous overgrowth, regional lipohypoplasia | Lipomatosis, epidermal nevi, pigmented macules of genitalia; later tricholemmomas, acral keratoses, oral papillomas, neuromas, sclerotic fibromas |

**eTable 85.3** *Continued* **Overgrowth syndromes with vascular malformations.** *Continued*

| OVERGROWTH SYNDROMES WITH VASCULAR MALFORMATIONS | | | | | | |
|---|---|---|---|---|---|---|
| | **DCMO** | ***PIK3CA*-related overgrowth spectrum** | | | **Proteus** | **PHTS** |
| | | **M-CM** | **KTS** | **CLOVES** | | |
| **Other extracutaneous features** | – | Polymicrogyria, ventriculomegaly, cerebellar tonsillar ectopia, hypotonia, seizures, developmental delay; frontal bossing, joint hypermobility | – | Variable polymicrogyria, seizures, and other features of M-CM | Lung bullae; hyperostoses, megaspondylodysplasia with scoliosis; long face with ptosis, depressed nasal bridge, anteverted nares, and open mouth at rest | See Table 52.1 |
| **Tumors** | – | Rare Wilms tumor** | – | Rare Wilms tumor** | Parotid monomorphic adenoma, ovarian cystadenoma, testicular tumors, meningioma | Increased risk of thyroid, breast, endometrial, renal, and GI carcinomas |

*PIK3CA *mutations have been found to underlie KTS with a lymphatic component.*
*§Associated with a high risk of venous thrombosis and pulmonary embolism; may have chronic intravascular coagulopathy.*
*** Surveillance with abdominal ultrasound every 3–4 months until 8 years of age is recommended.*

**eTable 85.3** *Continued* **Overgrowth syndromes with vascular malformations.** PTEN hamartoma tumor syndrome (PHTS) includes Cowden and Bannayan–Riley–Ruvalcaba syndromes as well as SOLAMEN syndrome – *s*egmental *o*vergrowth, *l*ipomatosis, *a*rteriovenous *m*alformation, and *e*pidermal *n*evus (see Chs 51 and 52). CLOVES, *c*ongenital *l*ipomatous *o*vergrowth, *v*ascular anomalies, *e*pidermal nevi, *s*coliosis/skeletal abnormalities; DCMO, *d*iffuse *c*apillary *m*alformation with *o*vergrowth; KTS, Klippel–Trenaunay syndrome; LM, lymphatic malformation; M-CM, megalencephaly–capillary malformation; *PIK3CA*, phosphatidylinositol-4,5-biphosphate 3-kinase catalytic subunit α; PTEN, phosphatase and tensin homolog; VM, venous malformation.

| CAUSES OF ACQUIRED CUTANEOUS LYMPHANGIECTASIA |
|---|
| **Inflammatory causes** |
| Crohn disease (favors perineal area)<br>Morphea profunda<br>Systemic sclerosis |
| **Infectious causes** |
| Tuberculosis (e.g. scrofuloderma)<br>Recurrent erysipelas/cellulitis |
| **Neoplastic causes** |
| Intralymphatic metastases (e.g. breast carcinoma, melanoma) |
| **Iatrogenic causes** |
| Surgical resection, lymphadenectomy, and/or radiotherapy for cancer (e.g. of the breast, prostate, bladder, cervix)<br>Amputations<br>Corticosteroid-induced atrophy ± photoaging<br>Penicillamine-induced dermopathy |
| **Other causes** |
| Pregnancy (vulvar)<br>Cirrhotic ascites (abdominal)<br>Porphyrias (e.g. porphyria cutanea tarda, variegate porphyria; centrofacial)<br>Spontaneous development in elderly patients (genital) |

**eTable 85.4 Causes of acquired cutaneous lymphangiectasia.** In the literature, this is sometimes referred to as acquired lymphangioma circumscriptum.

# 86 Ulcers

- An ulcer is defined as a wound with loss of the entire epidermis plus dermal tissue, sometimes extending as deep as the subcutis.
- The most common types of leg ulcers – venous, arterial, and neuropathic – as well as pressure ulcers, lymphedema, and an approach to wound healing are reviewed (see below); additional physical, inflammatory, infectious, metabolic, and neoplastic causes of leg ulcers are outlined in Fig. 86.1.
- Features to consider in the history and physical examination of patients with a leg ulcer are presented in Table 86.1, and routine laboratory testing often includes a CBC, ESR, and blood glucose and serum albumin levels; microbial cultures, evaluation for thrombophilia (previously referred to as hypercoagulability; see Table 18.5), and additional studies depend on the clinical setting.
- Ulcers with atypical features or a lack of response to appropriate therapy should be re-evaluated, with expansion of the DDx and consideration of a skin biopsy (preferably including the ulcer margin and bed) to exclude less common etiologies, such as SCC, vasculitis, and fungal or mycobacterial infections (via tissue culture).

## Venous Ulcers

- Venous hypertension and insufficiency represent the most common causes of chronic leg ulcers.
- Prevalence increases with age, and risk factors include female sex, obesity, pregnancy, prolonged standing, and family history of venous insufficiency; thrombophilia can be a contributing factor, especially in patients with a history of deep vein thrombosis or livedoid vasculopathy (Fig. 86.3; see Ch. 18).
- Ulcers tend to have irregular borders and a yellow fibrinous base, with a predilection for the area above the medial malleolus (Fig. 86.4); the ulcers can become large but are often fairly shallow, with granulation tissue evident upon debridement.
- Surrounding skin has signs of venous hypertension such as yellow-brown discoloration due to hemosiderin deposits, pinpoint petechiae, stasis dermatitis, lipodermatosclerosis, and, occasionally, acroangiodermatitis (Fig. 86.5; see Table 11.1).
- Other findings include varicosities and edema > lymphedema of the lower extremities (Fig. 86.6); swelling and aching of the legs is worsened by dependency (e.g. prolonged standing) and improved by leg elevation and the use of compression therapy; other dependent sites, such as a large pannus, can develop similar clinical changes (Fig. 86.7).
- **DDx:** see Fig. 86.1; coexistent arterial insufficiency (see below) or uncompensated congestive heart failure should be excluded before initiating compression therapy.
- Evaluation and **Rx:** an approach to the patient with a chronic venous ulcer is presented in Fig. 86.8.
- Compression represents a mainstay of therapy.
  - *Graduated compression stockings*: pressures of 30–40 mmHg at the ankle are required for moderate edema and to promote healing of venous ulcers, although lower pressures (20–30 mmHg) can be used for mild edema and as an initial step; stockings should be applied immediately upon arising from bed in the morning, and lifelong use is recommended
  - *Compression bandages*: the *Unna boot*, a zinc oxide-impregnated bandage that is covered by a self-adherent elastic wrap such as Coban™, provides semi-rigid compression and is usually changed weekly; four-layer bandages represent another option for highly exudative wounds

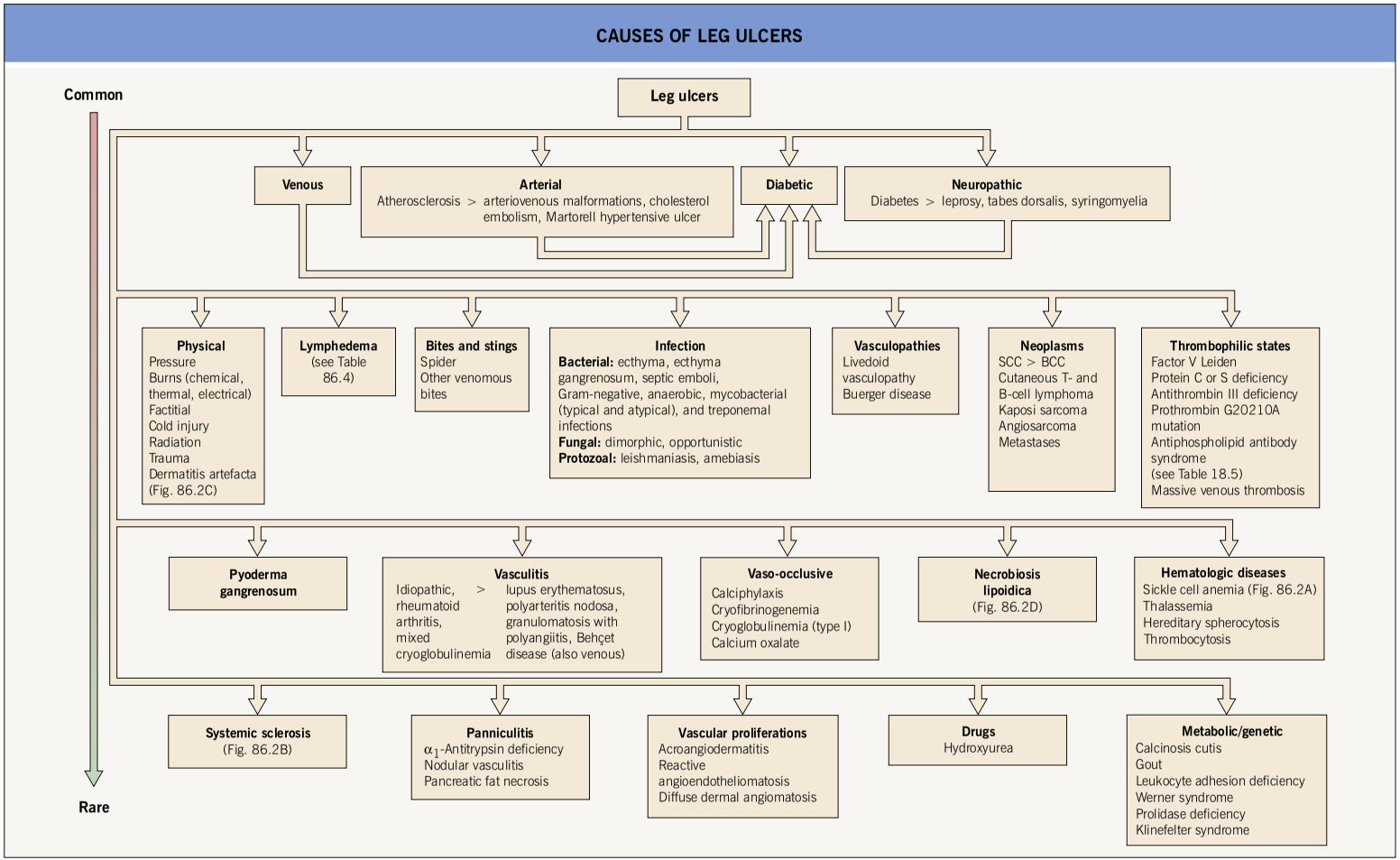


**Fig. 86.1 Causes of leg ulcers.** Patients with Behçet disease can also develop leg ulcers due to vasculitis and/or venous insufficiency related to deep vein thromboses. Erosive pustular dermatosis is another occasional cause of leg ulcers. Hydroxyurea-induced leg ulcers are exceedingly painful, surrounded by atrophic skin, and often located on the malleolus or tibial crest.

| POINTS TO INCLUDE IN THE HISTORY AND PHYSICAL EXAMINATION OF PATIENTS WITH A LEG ULCER | |
|---|---|
| **History** | **Physical examination** |
| • Onset and clinical course of ulcer<br>• Symptoms, including those of vascular disease or neuropathy<br>• Alleviating and exacerbating factors<br>• Past medical history, e.g. diabetes mellitus, atherosclerotic cardiovascular disease, AI-CTD<br>• Family history<br>• Medications, topical and systemic<br>• Personal habits (e.g. smoking, alcohol intake) | General, emphasizing the following:<br>• Ulcer characteristics<br>– Location and size<br>– Morphology, including depth, shape, border, and base<br>– Surrounding skin, e.g. edema, dermatitis, fibrosis, cellulitis, necrosis<br>• Peripheral pulses<br>• Capillary refill time<br>• Evidence of peripheral neuropathy<br>• Deep tendon reflexes |

**Table 86.1 Points to include in the history and physical examination of patients with a leg ulcer.** *Courtesy, Tania Phillips, MD.*

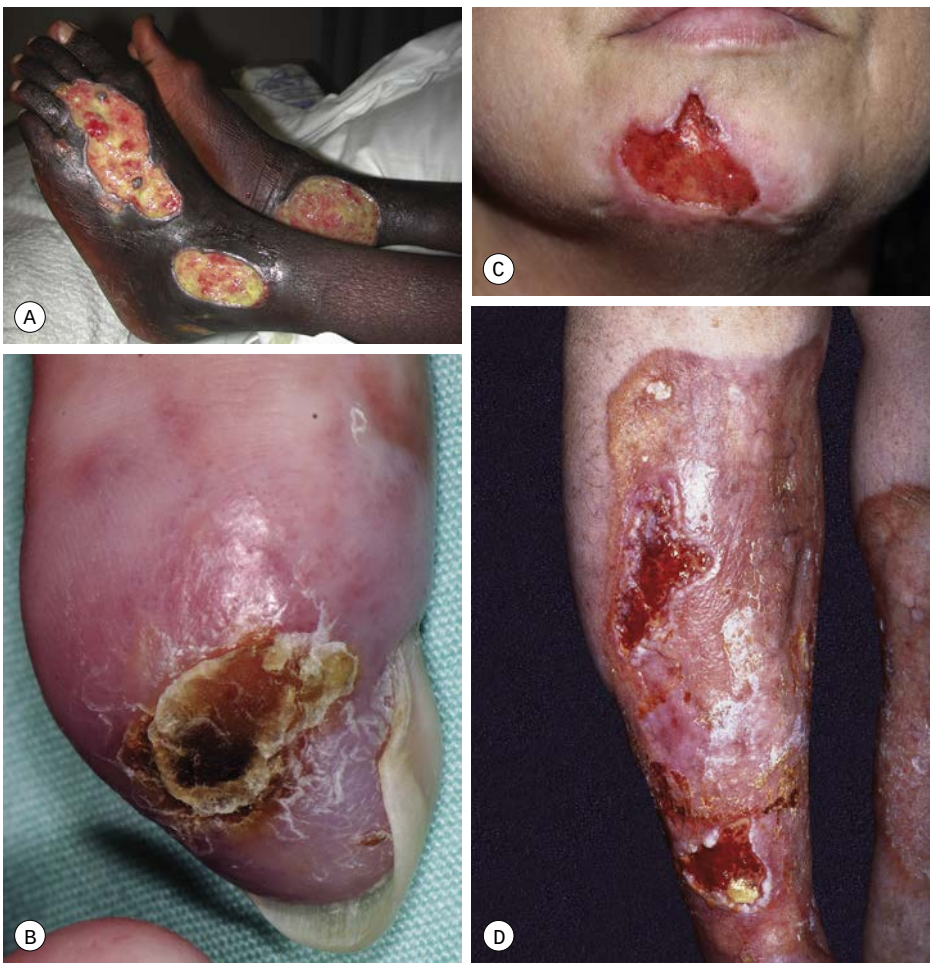


**Fig. 86.2 Diverse causes of ulcers. A** Multiple ulcers in a patient with sickle cell anemia. **B** Ulcer of the fingertip in a patient with systemic sclerosis. **C** Ulcer with a "bizarre" shape and angulated borders due to dermatitis artefacta. **D** Ulcerated necrobiosis lipoidica, which is associated with diabetes mellitus in a subset of affected individuals. *A, B, Courtesy, YDRSC; C, Courtesy, Kalman Watsky, MD; D, Courtesy, Jeffrey Callen, MD.*

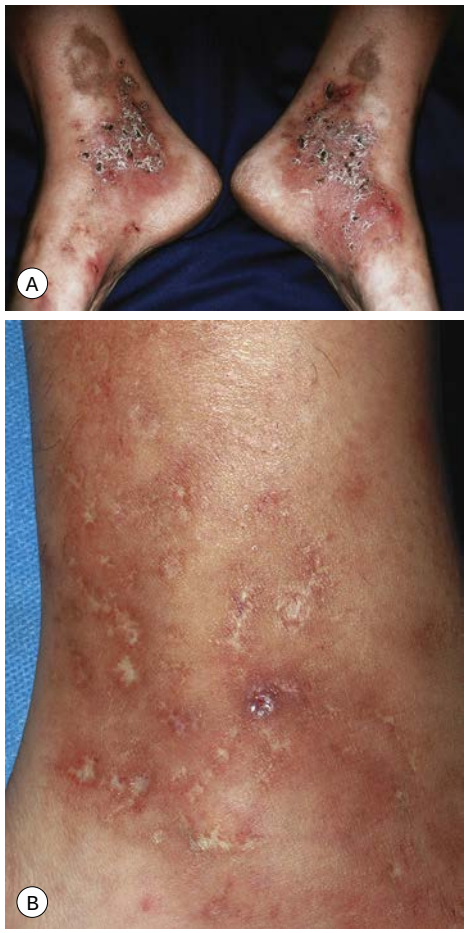


**Fig. 86.3 Livedoid vasculopathy. A** Multiple hemorrhagic crusts and small, very painful ulcers associated with brown discoloration due to hemosiderin deposits. **B** Stellate, porcelain-white atrophic scars with peripheral telangiectatic papules, referred to as atrophie blanche. *A, Courtesy, YDRSC; B, Courtesy, Julie V. Schaffer, MD.*

## Arterial Ulcers

- Peripheral arterial disease (PAD), a manifestation of atherosclerosis, is present in up to 25% of patients with leg ulcers; risk factors include cigarette smoking, diabetes mellitus, dyslipidemia, and hypertension; ulceration is often precipitated by trauma.
- Well-demarcated, round, "punched out" ulcers with a dry necrotic base; occur primarily on the distal lower extremities, favoring the toes and sites of pressure.
- Surrounding skin is typically hairless, shiny, and atrophic (Fig. 86.9).
- Other findings include cool feet, weak or absent peripheral pulses, prolonged capillary refill time (>3–4 seconds), pallor ± pain upon leg elevation (45° for 1 minute), and dependent rubor; patients may report pain induced by ambulation and relieved by rest.
- **DDx:** other causes of ulcers in patients with PAD include cholesterol emboli (Fig. 86.10), diffuse dermal angiomatosis (painful violaceous plaques with central ulceration), and Buerger disease (thrombangiitis obliterans; inflammatory and vaso-occlusive disorder in smokers affecting upper and lower extremities); patients with co-existing diabetes mellitus may have overlapping features (see below).
- Evaluation: the ankle–brachial index (ABI) is used to screen for PAD (Table 86.2); additional assessment may include duplex ultrasonography, CT angiography, and magnetic resonance angiography.
- **Rx:** surgical or endovascular restoration of blood flow; wound care (see below), but with avoidance of sharp debridement.

## Neuropathic (Mal Perforans) and Diabetic Ulcers

- Diabetes mellitus confers a 15–25% lifetime risk of foot ulcers, ~15% of which eventuate in an amputation; diabetic neuropathy is the major cause of these ulcers, although ischemia, venous hypertension, and infection often contribute to pathogenesis.
- *Sensory* neuropathy leads to unrecognized foot trauma, *motor* neuropathy leads to altered biomechanics and structural deformities that increase mechanical stress, and *autonomic* neuropathy leads to both arteriovenous shunting that decreases perfusion and reduced sweating that predisposes to dryness and fissuring.
- Neuropathic ulcers are typically "punched out" with a hyperkeratotic rim, arising in a background of callused skin; they are usually located on pressure points and over bony prominences (e.g. metatarsal heads, heels, great toes) (Fig. 86.11).
- Other findings include decreased sensation due to peripheral neuropathy and sometimes foot deformities (e.g. hammer toes, Charcot foot).
- Evaluation: neurologic examination using nylon monofilament to test sensation ± nerve




**Fig. 86.4 Venous ulcers over the medial malleolus. A** Note the yellowish fibrinous base over most of the ulcer and focal areas of granulation tissue. There is surrounding stasis dermatitis with erythema, crusting, and scaling as well as scarring. **B** Induration due to lipodermatosclerosis, hemosiderin deposition, and atrophie blanche scars are present in the surrounding skin. *A, Courtesy, YDRSC; B, Courtesy, Jean L. Bolognia, MD.*

conduction studies/electromyography and determination of the ABI (see Table 86.2); assessment for infection utilizing laboratory studies (e.g. CBC, ESR/C-reactive protein), wound cultures (tissue from biopsy is higher yield than swabs), and imaging to exclude osteomyelitis (e.g. radiographs [low sensitivity], MRI) as indicated by clinical suspicion.

- **Rx:** wound care with debridement of necrotic material and the hyperkeratotic rim, eradication of infection, and mechanical offloading (e.g. bed rest, wheelchair, crutches, total contact casting, felted foam, orthotic shoes); additional options include hyperbaric oxygen and becaplermin gel (recombinant platelet-derived growth factor [PDGF]); patient instructions are provided in Table 86.3.

## Pressure (Decubitis) Ulcers (Bed Sores)

- Occur as a consequence of prolonged immobility, affecting ~10% of hospitalized patients and ~25% of nursing home residents; other risk factors include sensory deficits, older age, and poor nutrition.
- Soft tissues are compressed between a bony prominence (e.g. sacrum, ischial tuberosity; Figs 86.12 and 86.13) and an external surface; pathogenic factors include continuous pressure, shearing forces/friction, and moisture (e.g. perspiration, urine, feces).
- Classified according to a four-stage system (Fig. 86.14); ulcers do not necessarily progress sequentially through these stages, and extensive deep tissue damage may initially have few superficial manifestations.
- Prevention: frequent position changes together with use of softer surfaces (e.g. containing foam, air, or liquid) and devices (e.g. pillows, foam wedges) to relieve pressure; optimize nutrition.
- **Rx:** relief of pressure and wound care – for example, utilizing an occlusive dressing (see below); stage IV ulcers may require surgical intervention.




**Fig. 86.5 Associated findings in patients with venous hypertension and insufficiency.**
**A** Venulectasias of the instep referred to as corona phlebectasia. **B** Brown discoloration of the foot and ankle due to hemosiderin deposits within dermal macrophages in addition to hyperpigmentation. Note the cutoff at Wallace's line. **C** Lipodermatosclerosis with violet-brown discoloration, tenderness, and induration that typically begins above the medial malleolus. **D** Stasis dermatitis and chronic lipodermatosclerosis with serous crusts and the "inverted champagne bottle" or "bowling pin" configuration. **E** Acroangiodermatitis (pseudo-Kaposi sarcoma). Violaceous plaque in a patient with venous hypertension. Histologically, these lesions can resemble Kaposi sarcoma. *A, B, Courtesy, Jean L. Bolognia, MD; C, Courtesy, Kalman Watsky, MD; D, Courtesy, Ariela Hafner, MD, and Eli Sprecher, MD; E, Courtesy, YDRSC.*

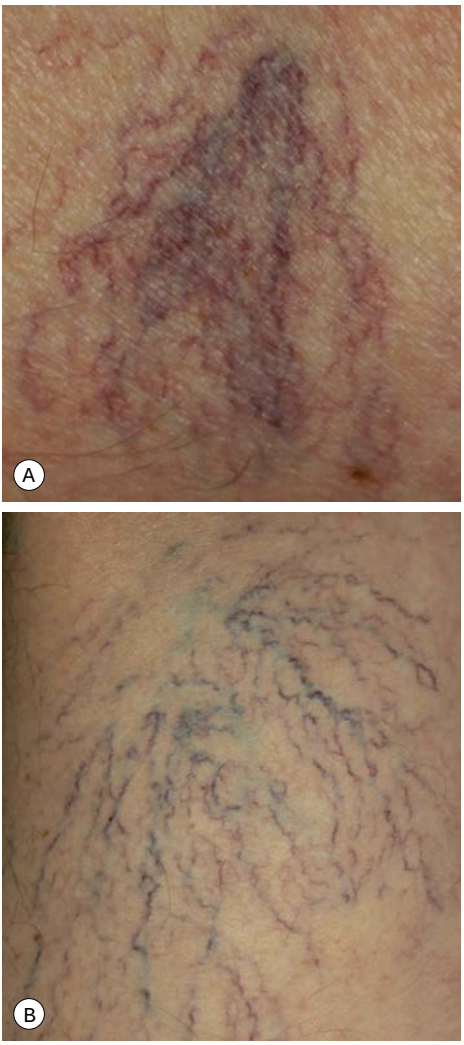





**Fig. 86.6 Venous abnormalities of the lower extremity. A** Venulectasias and a few reticular varicosities at the site of a perforator vein. **B** Reticular varicosities; note the blue-green color. **C** Larger saphenous varicosities may also be evident. *Courtesy, Jean L. Bolognia, MD.*



**Fig. 86.7 Lymphedema, lipodermatosclerosis, and chronic ulceration of the dependent portion of the pannus.** The changes are similar to those that can be seen on the distal lower extremities. *Courtesy, Jean L. Bolognia, MD.*

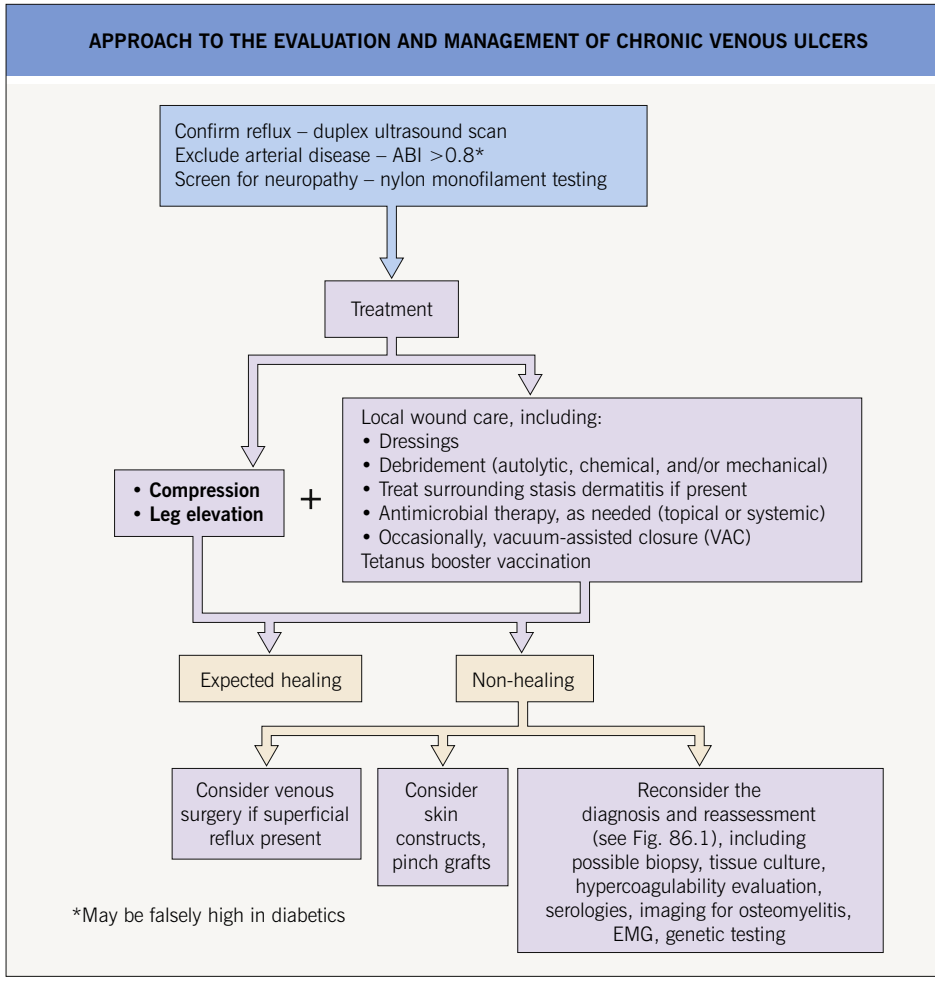


**Fig. 86.8 Approach to the evaluation and management of chronic venous ulcers.** *Courtesy, Tania Phillips, MD.*



**Fig. 86.9 Arterial ulcer.** The punched-out appearance and surrounding smooth shiny skin are common features. *Courtesy, Ariela Hafner, MD, and Eli Sprecher, MD.*



**Fig. 86.10 Cholesterol emboli.** Ischemia of the toes and necrosis with early ulcer formation. *Courtesy, YDRSC.*

**DETERMINATION AND INTERPRETATION OF THE ANKLE–BRACHIAL INDEX (ABI)**

- With the patient in a supine position, the systolic blood pressure is measured in the:
  - Brachial arteries (right and left)
  - Dorsalis pedis and posterior tibial arteries (right and left)
- The ABI is determined by:

$$\frac{\text{the highest of the systolic pressures from the dorsalis pedis or posterior tibial arteries}}{\text{the higher of the brachial artery systolic pressures}}$$

- Interpretation of the ABI:
  0.91–1.30 = normal range
  >1.30 = suggests incompressible tibial arteries due to medial calcification (diabetes mellitus, chronic renal insufficiency)
  <0.9 = indicative of peripheral artery disease (PAD)
  0.41–0.90 = mild to moderate PAD
  0.00–0.40 = severe PAD

**Table 86.2 Determination and interpretation of the ankle–brachial index (ABI).**




**Fig. 86.11 Neuropathic ulcers in patients with diabetes mellitus and peripheral neuropathy.** Common locations are the plantar surface of the heel **(A)** and the great toe **(B)**. Note the thick rim of callus. *A, Courtesy, Ariela Hafner, MD, and Eli Sprecher, MD; B, Courtesy, YDRSC.*

| INSTRUCTIONS FOR THE PATIENT WITH A DIABETIC OR NEUROPATHIC ULCER |
|---|
| **Foot care**<br>• Inspect feet daily for blisters, scratches, and red areas. If your vision is impaired, get someone to do this for you.<br>• Wash your feet daily in warm water. Dry carefully between the toes.<br>• Apply petroleum jelly to dry areas of skin but not between the toes.<br>• Do not remove corns or apply strong chemicals to your feet.<br>• Cut nails straight across.<br>• If you develop any breaks in the skin or blisters, inform your doctor.<br>• See your podiatrist regularly. |
| **Shoe choice and use**<br>• Wear properly fitting shoes. New shoes should be worn for 1–2 hours daily only. Check your feet for red spots afterwards.<br>• Inspect the insides of your shoes before putting them on.<br>• Avoid open-toed sandals and shoes with pointed toes.<br>• Never walk barefoot. |
| **General medical care and safety**<br>• Stop smoking, control blood sugar levels, and lose weight if overweight.<br>• Always test water temperature before bathing.<br>• See your doctor regularly. |

**Table 86.3 Instructions for the patient with a diabetic or neuropathic ulcer.** *Adapted with permission from Levin M, O'Neal ME. The Diabetic Foot. St. Louis: Mosby, 1988.*

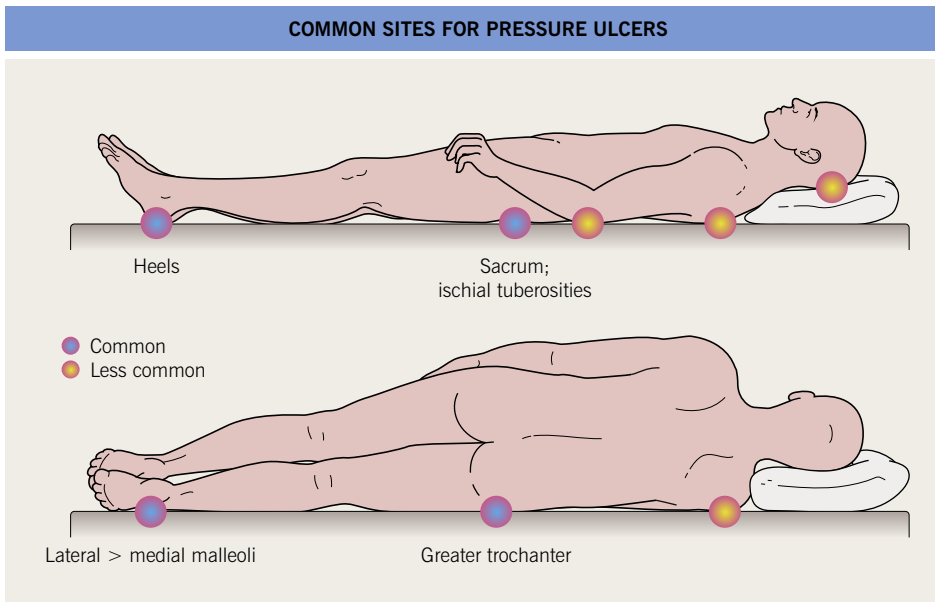


**Fig. 86.12 Common sites for pressure ulcers.**

## Lymphedema

• Lymphedema is the interstitial accumulation of lymphatic fluid due to reduced drainage by lymphatic vessels.

• Divided into *primary* forms due to abnormal lymphatic development (see Ch. 85) and *secondary* forms due to lymphatic damage or obstruction (Table 86.4).

• Usually presents as chronic, painless swelling and heaviness of an extremity (leg > arm), typically beginning distally (e.g. on the dorsal foot) and progressing proximally (Fig. 86.15); initially pitting, but becomes indurated




**Fig. 86.13 Pressure ulcers. A** Stage III ulcer over the sacrum. **B** Black eschar on the heel due to pressure necrosis. *A, Courtesy, Ariela Hafner, MD, and Eli Sprecher, MD; B, Courtesy, YDRSC.*

and non-pitting as fibrosis develops; prone to ulceration and often worsens following secondary infections.

- *Elephantiasis nostras verrucosa* is a complication of severe lymphedema characterized by massive enlargement of the affected area, marked fibrosis, and verrucous epidermal changes with a mossy, cobblestoned appearance (Fig. 86.16).
- **DDx:** edema secondary to venous insufficiency, lipedema (bilateral lower extremity swelling that spares the feet, almost exclusively affecting women; Fig. 86.17), obesity-associated lymphedematous mucinosis.
- **Rx:** difficult; compression (e.g. garments, wrapping), pneumatic pumps and massage to decrease accumulation of lymph; treatment of secondary infections.

## General Approach to Wound Healing

- In a patient with an ulcer, modifiable local and systemic factors that may impair wound healing should be addressed, including deleterious mechanical forces, inadequate perfusion, and poor nutritional or immune status.
- A moist wound environment such as that provided by a semipermeable "occlusive" dressing enhances healing by stimulating collagen synthesis, promoting angiogenesis, encouraging re-epithelialization, and providing autolytic debridement.
- The choice of dressing depends on the wound type and amount of exudate (Tables 86.5 and 86.6), and it may be helpful to protect the skin around the wound with a thin coat of ointment to prevent maceration; the frequency of dressing changes is based on their absorbency as well as the amount of exudate.
- Debridement of non-viable tissue from the wound bed also promotes healing.
  - *Autolytic debridement* utilizing the body's own proteolytic enzymes is provided by moist retentive dressings; it is best suited for non-infected wounds with minimal debris
  - *Mechanical debridement* (e.g. "sharp" with surgical instruments, wet-to-dry [can disrupt viable tissue]) may be helpful for wounds with large amounts of necrotic and/or infected tissue
  - *Enzymatic debridement* utilizes topical proteolytic enzyme preparations such as collagenase and papain-urea
  - *Maggot debridement* can be considered for recalcitrant ulcers with excessive necrotic tissue
- Bacterial colonization occurs in all chronic wounds and must be distinguished from true

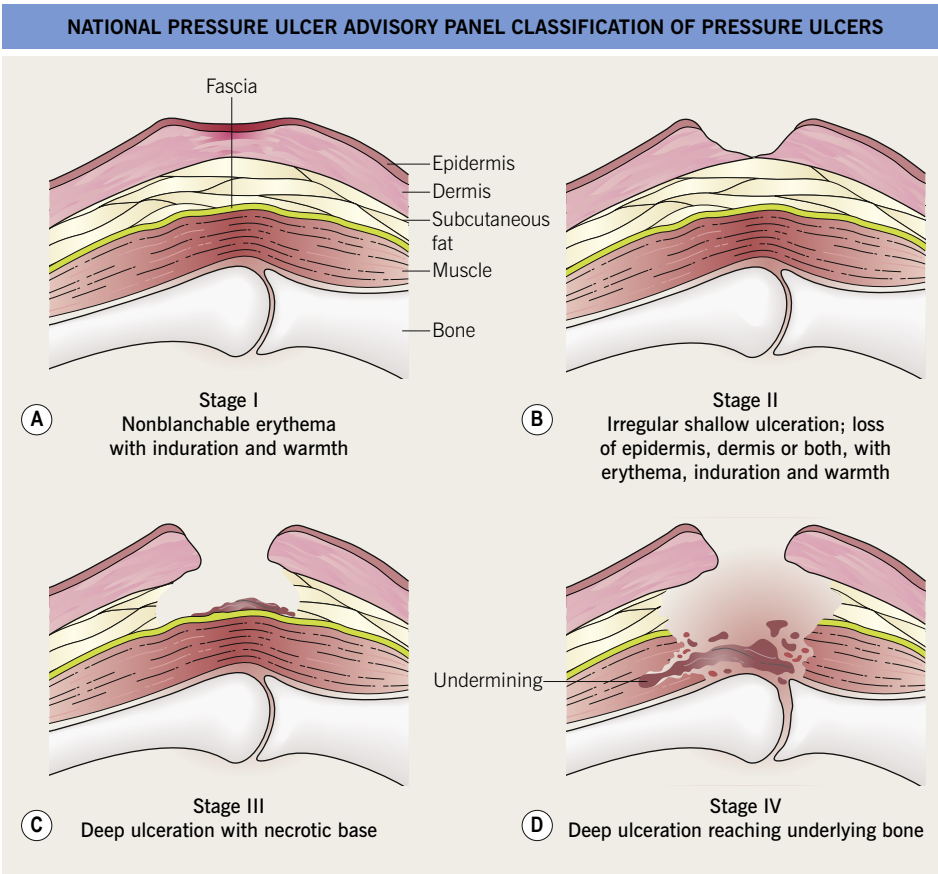


**Fig. 86.14 National Pressure Ulcer Advisory Panel classification of pressure ulcers. A** Stage I: nonblanchable erythema of intact skin. This lesion is the heralding sign of impending skin ulceration. For darker-skinned individuals, other signs may be indicators and include warmth, edema, discoloration of the skin, and induration. **B** Stage II: partial-thickness skin loss involving the epidermis, dermis, or both. This superficial lesion presents as an abrasion, blister, or shallow crater. **C** Stage III: full-thickness skin loss, in which subcutaneous tissue is damaged or necrotic and may extend down into, but not including, the underlying fascia. This deep lesion presents as a crater and sometimes involves adjacent tissue. **D** Stage IV: full-thickness skin loss and extensive tissue necrosis, destruction to muscle, bone, or supporting structures such as a tendon or joint capsule. Undermining or sinus tracts can be present.

soft tissue infection; wounds with clinical evidence of infection (e.g. purulent discharge, surrounding cellulitis) should be cultured and treated with systemic antibiotics (initially broad-spectrum and then adjusted based on sensitivities); topical antimicrobial agents (e.g. dressings containing silver or cadexomer-iodine) can be considered for non-healing wounds with "critical colonization" ($>10^6$ colony-forming units of bacteria per gram of tissue).

- In addition to wound care, treatment of ulcers should be directed at the underlying cause (see above).
- Other adjuncts to wound care may include topical growth factors (e.g. PDGF), topical negative pressure therapy, and tissue-engineered skin equivalents.

For further information see Ch. 105 from *Dermatology, Fourth Edition*.

**For additional online figures and tables visit www.expertconsult.com**

| CAUSES OF SECONDARY LYMPHEDEMA |
|---|
| **Infections** |
| • Recurrent cellulitis and lymphangitis<br>• Parasitic infections (e.g. filariasis) |
| **Cancer-related, including iatrogenic** |
| • Lymph node dissection (e.g. for melanoma or breast cancer) or other surgical excisions (e.g. mastectomy)<br>• Radiation injury<br>• Malignant obstruction (e.g. by lymphoma or Kaposi sarcoma) |
| **Inflammatory** |
| • Acne vulgaris and rosacea (midfacial)<br>• Granulomatous disorders (e.g. anogenital in Crohn disease) |
| **Other** |
| • Obesity<br>• Podoconiosis (exposure to mineral microparticles in volcanic soils) |

**Table 86.4 Causes of secondary lymphedema.**







**Fig. 86.15 Lymphedema. A** Primary lymphedema of the upper extremities due to Milroy disease (see Ch. 85). **B** Lymphedema of the lower extremities secondary to morbid obesity and associated with myxedema. *A, Courtesy, YDRSC; B, Courtesy, Ariela Hafner, MD, and Eli Sprecher, MD.*



**Fig. 86.16 Elephantiasis nostras verrucosa.** The patient had both lymphedema and venous insufficiency. Note the involvement of the foot. *Courtesy, Ariela Hafner, MD, and Eli Sprecher, MD.*



**Fig. 86.17 Lipedema.** This middle-aged woman has bilateral "stovepipe" enlargement of the legs and minimal involvement of the feet. Note the sharp demarcation between normal and abnormal tissue at the ankle, referred to as the "cuff sign." *Courtesy, Jean L. Bolognia, MD.*

| TYPES OF WOUND DRESSINGS | | |
|---|---|---|
| **Dressing type** | **Properties** | **Disadvantages** |
| Gauzes | • Good absorption<br>• Can be impregnated with:<br>– NaCl to become highly absorbent, discourage bacterial overgrowth, and prevent formation of excess granulation tissue<br>– Petrolatum so less drying and adherent, but then less absorbent<br>– Iodine or silver as an antiseptic | • Adhere to wound bed and promote desiccation<br>• Can cause pain and trauma, including disruption of epithelium, upon removal |
| Films | • Thin polyurethane membranes<br>• Maintain a moist environment<br>• Semipermeable (only to vapors, not to liquids)<br>• Transparency enables wound visualization | • Non-absorbent<br>• Can cause maceration of surrounding skin if applied to wounds with heavy exudate |
| Hydrogels | • Maintain a moist environment<br>• Promote autolytic debridement<br>• Non-adhesive<br>• Relieve pain | • Can cause maceration of surrounding skin if applied to wounds with heavy exudate |
| Hydrocolloids | • Adhesive, occlusive dressings that absorb exudates with the formation of hydrophilic gel<br>• Provide a moist environment | • Not suitable for wounds with heavy exudate or infected wounds<br>• May produce a brown, malodorous gel<br>• May lead to maceration of surrounding skin, and removal can be traumatic |
| Alginates | • Fibrous dressings derived from brown seaweed<br>• Highly absorbent and require moisture to function<br>• Ion exchange between calcium in the alginate and sodium in the wound fluid leads to the formation of a moist retentive gel<br>• Hemostatic | • May adhere to dry wounds<br>• May leave fibrous debris in the wound<br>• Can lead to maceration around the wound unless cut to the size of the wound bed |
| Foams (polyurethane) | • Good absorbance capacity<br>• Non-traumatic upon removal<br>• Provide thermal and shear protection | • Not suitable for dry wounds<br>• Maceration around wound possible |
| Collagens | • Collagen matrix that physically entraps MMPs and facilitates growth factor activity | • Nonspecific inhibition of MMPs |

**Table 86.5 Types of wound dressings.** A conventional layered dressing usually has three components: (1) a nonadherent, fluid-permeable material that directly contacts the wound; (2) an absorbent layer (e.g. cotton pad or gauze); and (3) an outer wrap. However, some dressings (e.g. hydrocolloids) that are waterproof and adhere directly do not require secondary layers. MMPs, matrix metalloproteinases. *Courtesy, Ariela Hafner, MD, and Eli Sprecher, MD.*

| DRESSING CHOICES FOR DIFFERENT WOUND TYPES | | | | | | |
|---|---|---|---|---|---|---|
| | **Gauze** | **Film** | **Hydrogel** | **Hydrocolloid** | **Alginate*** | **Foam** |
| Wound exudate: | | | | | | |
| Minimal | | ✓ | ✓ | | | |
| Mild | | | | ✓ | | |
| Moderate | | | | ✓ | ✓ | ✓ |
| Heavy | ✓ | | | | ✓ | ✓ |
| Use as a secondary dressing | ✓ | ✓ | | | | |

**Helpful for undermined or tunneling wounds.*

**Table 86.6 Dressing choices for different wound types.** Collagens may also be useful for recalcitrant chronic wounds that are clean and non-infected.

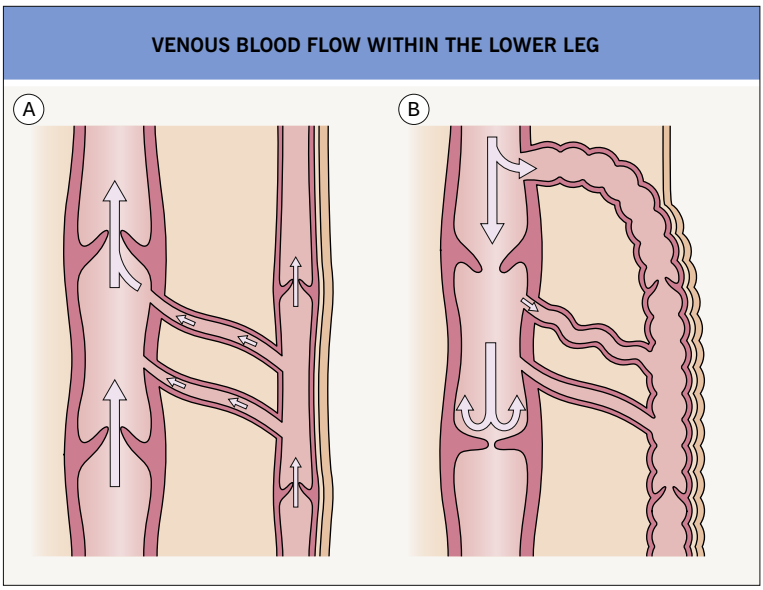


**eFig. 86.1 Venous blood flow within the lower leg. A** Under normal circumstances, blood is pumped against gravity towards the heart by the calf muscles. Blood flows from the superficial veins to the deep venous system via the perforating veins. Bicuspid valves ensure the unidirectionality of the blood flow. **B** When the valves are incompetent and/or hydrostatic pressure is elevated, blood flows back into the superficial venous system, leading to the formation of varicose veins.



**eFig. 86.2 Sacral decubitus ulcer.** *Courtesy, Ronald Rapini, MD.*




**eFig. 86.3 Elephantiasis nostras verrucosa.** **A** The patient had both lymphedema and venous insufficiency. **B** Note the multiple fibrotic papules and nodules. *A, Courtesy, Ariela Hafner, MD, and Eli Sprecher, MD; B, Courtesy, Jean L. Bolognia, MD.*

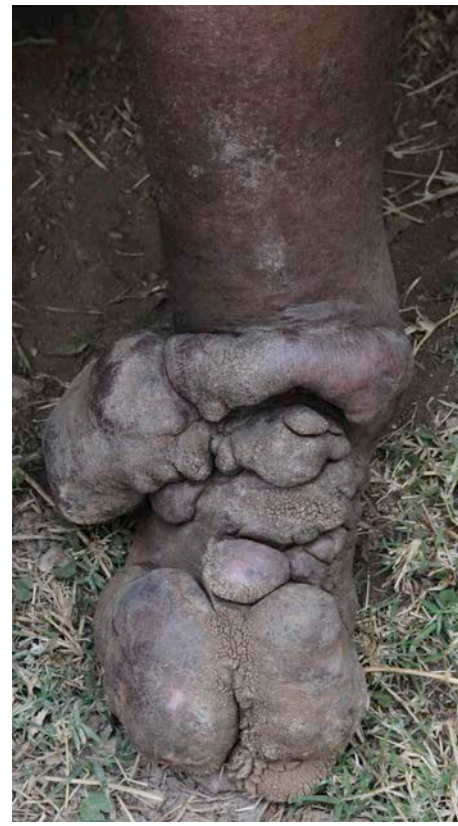

**eFig. 86.4 Elephantiasis nostras verrucose a due to podoconiosis.** This endemic, non-filarial form of elephantiasis is caused by pedal exposure to volcanic soils. *Courtesy, Claire Fuller, MD.*



**eFig. 86.5 Diffuse dermal angiomatosis.** This condition develops most often in pendulous breasts (note the scars from prior breast reduction surgery) and the lower extremities in association with atherosclerosis. *Courtesy, Margo Peters, MD.*

| CUTANEOUS SIGNS OF CHRONIC VENOUS HYPERTENSION |
|---|
| • Edema, often tender |
| • Varicosities |
| • Stasis dermatitis |
| • Petechiae superimposed on a yellow-brown discoloration due to hemosiderin deposits (stasis purpura) |
| • Lipodermatosclerosis, acute and chronic |
| • Stasis ulcerations, in particular above the medial malleolus |
| • Acroangiodermatitis (pseudo-Kaposi sarcoma) |
| • Livedoid vasculopathy (porcelain-white scars surrounded by punctate telangiectasias and painful ulcerations)* |
| **Need to exclude causes of hypercoagulability.* |

**eTable 86.1 Cutaneous signs of chronic venous hypertension.**

# 87 Other Vascular Disorders

This chapter covers a range of vascular disorders from livedo reticularis to common vascular ectasias such as venous lakes and telangiectasias. Additional disorders characterized by a proliferation of blood vessels are covered in Chapters 85 (infantile hemangiomas and vascular malformations) and 94 (vascular neoplasms).

## Livedo Reticularis

- Blue-violet netlike pattern that reflects an increase in deoxygenated blood within the venous plexus of the skin (Fig. 87.1); this increase can be due to a number of causes, including vasospasm of arterioles supplying the skin and sluggish flow due to hypercoagulability or luminal pathology.
- A common physiologic vasospastic response to cold that resolves with rewarming, as well as a sign of a number of systemic diseases, from severe atherosclerosis to SLE (Table 87.1; Fig. 87.2).
- Most commonly observed on the legs but may be more widespread, especially in the setting of systemic diseases. When the pattern is larger and more branching and irregular ("broken up"), as well as more widespread, it is often described as *livedo racemosa* (Fig. 87.3).
- **DDx:** early phase of erythema ab igne; viral exanthems (e.g. erythema infectiosum),

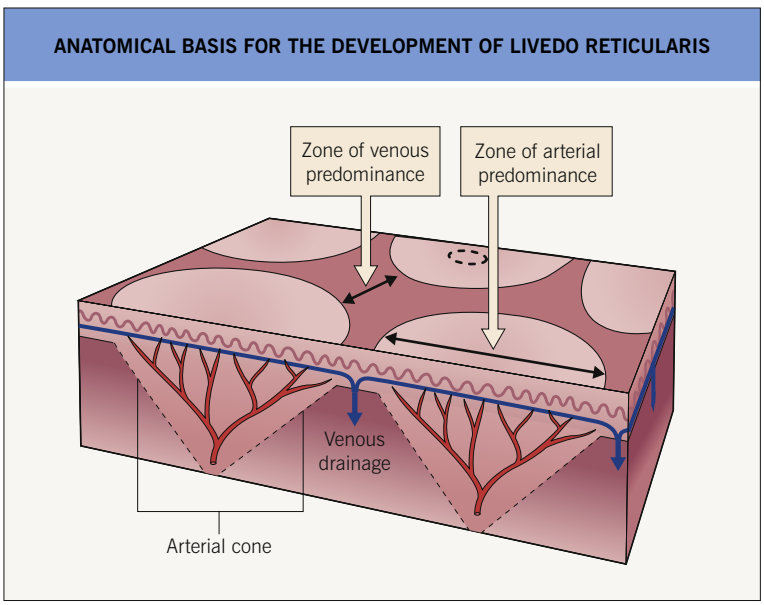


**Fig. 87.1 Anatomic basis for the development of livedo reticularis.** At the edges of arterial cones, the venous plexus is prominent. An increase in deoxygenated blood within this plexus (due to a decrease in blood flow into or through the skin or impeded drainage of blood) leads to livedo reticularis. If disease of the feeding arteriole is suspected, a wedge biopsy of the central paler cone (dashed oval) can be performed.

| CAUSES OF LIVEDO RETICULARIS |
|---|
| **Congenital livedo reticularis** |
| Cutis marmorata telangiectatica congenita |
| **Acquired livedo reticularis** |
| **Vasospasm** |
| • Cutis marmorata/physiologic livedo reticularis (more common in young children)<br>• Primary (idiopathic) livedo reticularis<br>• Autoimmune connective tissue diseases (e.g. SLE)<br>• Raynaud phenomenon/disease |
| **Vessel wall pathology** |
| • Vasculitis (medium-sized arterioles)<br>– Cutaneous polyarteritis nodosa (nearly all patients)<br>– Systemic polyarteritis nodosa<br>– Cryoglobulinemic vasculitis*<br>– Autoimmune connective tissue-associated vasculitis (e.g. rheumatoid arthritis, SLE, Sjögren syndrome)*<br>• Calciphylaxis<br>• Sneddon syndrome<br>• Livedoid vasculopathy (also intraluminal obstruction)<br>• Adenosine deaminase 2 deficiency (can present as Sneddon syndrome or PAN) |
| **Intraluminal pathology** |
| • Increased normal blood components (e.g. thrombocythemia, polycythemia vera)<br>• Abnormal proteins (e.g. cryoglobulinemia, paraproteinemia; see Ch. 18)<br>• Hypercoagulability (e.g. antiphospholipid antibody syndrome, protein C or S deficiency, antithrombin III deficiency, factor V Leiden mutation, DIC; see Table 18.5)<br>• Thrombotic thrombocytopenic purpura<br>• Emboli (e.g. cholesterol, septic)<br>• Hyperoxaluria<br>• Intralymphatic histiocytosis |
| **Other** |
| • Medications (e.g. amantadine, norepinephrine, interferon)<br>• Infections (e.g. hepatitis C [vasculitis], *Mycoplasma* spp. [cold agglutinins], syphilis)<br>• Neoplasms (e.g. pheochromocytomas, multiple myeloma)<br>• Neurologic disorders (e.g. complex regional pain syndrome [reflex sympathetic dystrophy], paralysis)<br>• Moyamoya disease |
| **Can also present with cutaneous small vessel vasculitis.* |

**Table 87.1 Causes of livedo reticularis.** DIC, disseminated intravascular coagulation; PAN, polyarteritis nodosa.

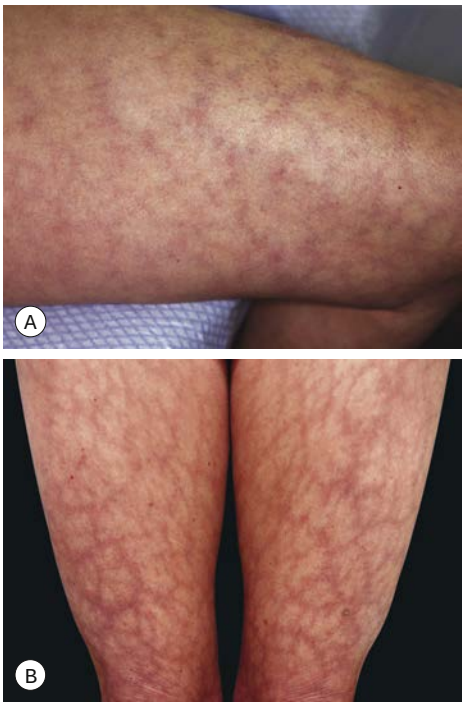


**Fig. 87.2 Livedo reticularis. A** An even, netlike pattern is seen on the thigh in physiologic livedo reticularis; in primary (idiopathic) livedo reticularis, the pattern persists with rewarming. **B** Livedo reticularis in a patient with SLE. *A, Courtesy, Christopher Baker, MD, and Robert Kelly, MD; B, Courtesy, Jeffrey P. Callen, MD.*



**Fig. 87.3 Sneddon syndrome.** The characteristic irregular, broken, branching pattern of livedo racemosa is seen on the back and arms. Pediatric-onset livedo racemosa and stroke with or without polyarteritis nodosa should prompt consideration of adenosine deaminase 2 deficiency. *Courtesy, Christopher Baker, MD, and Robert Kelly, MD.*



**Fig. 87.4 Calciphylaxis in a patient with end-stage chronic renal disease.** There is retiform purpura and a large black eschar overlying cutaneous necrosis. Note the violaceous reticulated pattern on the inner thighs. Because the patient was also receiving warfarin, the differential diagnosis included warfarin necrosis. *Courtesy, Alicia Little, MD.*

retiform purpura and necrosis due to more complete disruption of blood flow (Fig. 87.4; see Ch. 18); underlying etiologies are outlined in Table 87.1.

- **Rx:** can improve with treatment of an underlying systemic disorder; no treatment currently available for the idiopathic form.

## Flushing

- Exaggerated physiologic dilatation of superficial cutaneous blood vessels that can be triggered by a number of factors, including heat, spicy foods, hot drinks, and anxiety; the resultant erythema of the skin is episodic and transient and may be accompanied by sweating.
- Common etiologies are menopause, other causes of estrogen deficiency (e.g. tamoxifen), rosacea, and medications (e.g. nicotinic acid, nitrates); uncommon causes are carcinoid syndrome, mastocytosis, and pheochromocytoma (Table 87.2).
- Sites of involvement, primarily the face > ears, neck, and chest, are both visible and characterized by greater vasculature capacitance; an approach to the evaluation of a patient with flushing is outlined in Table 87.3.
- **Rx:** avoidance of exacerbating factors; addressing any underlying systemic disorder; for physiologic flushing – propranolol, nadolol, or clonidine; for menopausal "hot flashes" – hormone replacement therapy, SSRIs, or clonidine; laser therapy can address telangiectasias that may result from repeated episodes of flushing.

**CAUSES OF FLUSHING**

- Physiologic
- Estrogen deficiency (e.g. menopause, tamoxifen, raloxifene*)
- Rosacea (also triggered by exogenous agents)
- Exogenous agents
  - Alcohol, especially poor metabolizers
  - Drugs (e.g. nicotinic acid, nitrates, PDE5 inhibitors [e.g. sildenafil], prostaglandins, disulfiram**, chlorpropamide**, methylphenidate, calcium channel blockers, calcitonin)
  - Foods (e.g. spoiled scombroid fish)
  - Food additives (e.g. monosodium glutamate, sodium nitrite, sulfites)
- Neurologic disorders
  - Anxiety
  - Autonomic dysfunction
  - Tumors (e.g. hypogonadal pituitary tumors)
  - Migraine
  - Frey syndrome (auriculotemporal syndrome)
- Systemic disease
  - Carcinoid syndrome (also vascular rosacea-like changes, pellagra, facial edema)***
  - Mastocytosis (also red-brown papules, plaques, or nodules)
  - Pheochromocytoma (also macular amyloidosis if MEN 2a)
  - Medullary carcinoma of the thyroid (also macular amyloidosis if MEN 2a)
  - Thyrotoxicosis (also hyperhidrosis)
  - POEMS syndrome
  - Pancreatic tumors (e.g. VIPomas)

**Agonist effects on bone and cholesterol.*
***With alcohol intake.*
****Midgut tumors with liver metastases, type III gastric tumors, and bronchial tumors.*

**Table 87.2 Causes of flushing.** PDE5, phosphodiesterase type 5; POEMS, polyneuropathy, organomegaly, endocrinopathy, M-protein (monoclonal gammopathy), skin changes; VIP, vasoactive intestinal polypeptide.

## Erythromelalgia

- Erythema, warmth, and painful burning sensation of the distal extremities (lower > upper) that is usually episodic but may be constant (Fig. 87.5); relieved by cooling and

**CLINICAL APPROACH TO THE EVALUATION OF FLUSHING**

1. Identify provocative factors
   - Direct questioning (e.g. menopause, perimenopause)
   - Patient diary (food, medications, supplements, activities)
2. Check for associated symptoms
   - Sweating
   - Urticaria
   - Diarrhea
   - Bronchospasm
3. Investigation (not required in all cases)
   Indicated if flushing:
   - Of sudden or recent onset
   - Severe
   - Associated with systemic symptoms

   Investigations to consider:
   - Serum estradiol, FSH, LH (in women)
   - Complete blood count with differential and platelets
   - Thyroid function tests
   - Serum tryptase [M] and/or chromogranin A levels [C]; plasma free metanephrines [P]
   - 24-hour urine collection for:
     - Serotonin metabolites such as 5-hydroxyindole acetic acid (5-HIAA) [C]
     - Fractionated metanephrines [P]
     - Histamine metabolites such as methylimidazole acetic acid (MIAA) [M]
   - CT/MRI scans; somatostatin receptor scintigraphy (using radiolabeled analogue of somatostatin)
4. Elimination
   - Exclude suspected drugs and food additives

**Table 87.3 Clinical approach to the evaluation of flushing.** C, carcinoid; FSH, follicle stimulating hormone; LH, luteinizing hormone; M, mastocytosis; P, pheochromocytoma.

precipitated by warming, with attacks often beginning in the evening.

- Three major forms: (1) associated with thrombocythemia, (2) primary or "idiopathic" that can be familial, and (3) associated with underlying disorders other than thrombocythemia (e.g. myelodysplasia, SLE); in some families, gain-of-function mutations in *SCN9A*, which encodes a subunit of a voltage-gated sodium channel, have been identified and are thought to lead to "overexcitability" of pain-signaling sensory neurons.
- **DDx:** complex regional pain syndrome (reflex sympathetic dystrophy), peripheral neuropathy, autonomic dysfunction, acrodynia, thromboangiitis obliterans, administration of calcium channel blockers.
- **Rx:** cooling techniques, leg elevation, oral analgesics, topical anesthetics, SSRIs, tricyclic antidepressants, gabapentin, carbamazepine, magnesium; for those with thrombocythemia, aspirin; for those with *SCN9A* mutations, sodium channel blocking agents (e.g. mexiletine, flecainide).



**Fig. 87.5 Erythromelalgia.** Red hot hand with painful burning sensation. *Courtesy, Agustin Aloma, MD.*

## Telangiectasias

- Permanently dilated superficial cutaneous blood vessels; fine (diameter 0.1–1 mm), red to blue-violet in color, and usually fade with pressure (Fig. 87.6).
- Although most commonly seen on the face and on the lower extremities in the settings of photodamage and venous hypertension, respectively, telangiectasias are associated with a number of conditions (Table 87.4) and have several variants (see later).
- **Rx:** fine wire diathermy, injection sclerotherapy (legs), laser or intense pulsed light therapy.

### Spider Telangiectasia (Spider Angioma)

- Characterized by a red papule with multiple radiating fine vessels ("legs"); the papular component is the site of the feeding arteriole; usually present as isolated lesions in children but are often multiple when associated with hyperestrogenemia, e.g. in the setting of pregnancy or hepatic cirrhosis in men.







**Fig. 87.6 Telangiectasias. A** Sun-induced linear and branching telangiectasias on the cheek. **B** Prominent telangiectasias on the breast following radiation therapy. Note the overall rectangular configuration. **C** Venulectasias of the leg, which have a larger diameter (1–2 mm). The latter are a reflection of venous hypertension. *A, B, Courtesy, Christopher Baker, MD, and Robert Kelly, MD; C, Courtesy, Jean L. Bolognia, MD.*

| CAUSES OF TELANGIECTASIAS |
|---|
| **Primary** |
| • Spider telangiectasias (also associated with estrogen excess) (Fig. 87.8)<br>• Hereditary benign telangiectasia (Fig. 87.7)<br>• Costal fringe<br>• Angioma serpiginosum (Fig. 87.9)<br>• Unilateral nevoid telangiectasia (Fig. 87.10)<br>• Generalized essential telangiectasia (Fig. 87.11)<br>• Cutaneous collagenous vasculopathy |
| **Secondary to physical changes or damage** |
| • Photodamage (Fig. 87.6A)<br>• Post radiation therapy (Fig. 87.6B)<br>• Traumatic<br>• Venous hypertension (Fig. 87.6C) |
| **Skin disease** |
| • Telangiectatic rosacea (see Ch. 30)<br>• Incipient, minimally progressive, or involuted infantile hemangiomas (see Figs 85.2 and 85.3)<br>• Basal cell carcinoma |
| **Hormonal/metabolic** |
| • Estrogen-related<br>– Liver disease<br>– Pregnancy<br>– Exogenous estrogens<br>• Corticosteroids |

**Table 87.4 Causes of telangiectasias.** *Continued*

| CAUSES OF TELANGIECTASIAS |
|---|
| **Systemic conditions** |
| • Carcinoid syndrome<br>• Mastocytosis (telangiectasia macularis eruptiva perstans) (see Fig. 96.5)<br>• Autoimmune connective tissue diseases<br>– Lupus erythematosus<br>– Dermatomyositis (see Fig. 34.3)<br>– Systemic sclerosis (see Fig. 35.6)<br>• Mycosis fungoides, including poikilodermatous<br>• B-cell lymphomas<br>• Angiolupoid sarcoidosis<br>• GVHD (in the context of poikiloderma)<br>• HIV infection (anterior chest) |
| **Congenital malformations and genodermatoses*** |
| • Cutis marmorata telangiectatica congenita<br>• Hereditary hemorrhagic telangiectasia (Fig. 87.12)<br>• Ataxia–telangiectasia (see Fig. 49.1)<br>• Bloom syndrome (see Ch. 73)<br>• Goltz syndrome (in lines of Blaschko) |
| *Not exhaustive list. |

**Table 87.4** *Continued* **Causes of telangiectasias.**



**Fig. 87.7 Hereditary benign telangiectasia.** Multiple linear and arborizing telangiectasias appear during childhood and favor the sun-exposed areas of the face and upper extremities; the vermilion lips and palate are occasionally affected, but there is no visceral involvement. *Courtesy, Julie V. Schaffer, MD.*

• Usually develop in otherwise healthy women and children, with the most common locations being the face, neck, chest, and hands (Fig. 87.8).

## Generalized Essential Telangiectasia

• Broad areas composed of multiple linear telangiectasias that vary in color from red to purple; involvement is often symmetrical and usually begins on the ankles, primarily of adult women (Fig. 87.11); over time, there is typically proximal spread.

• Although these linear telangiectasias can become quite extensive, the disorder remains a cosmetic one, i.e. there are no associated systemic manifestations.

• **DDx:** cutaneous collagenous vasculopathy (similar clinical appearance but central distribution and perivascular deposits of type IV collagen histologically); initially, telangiectasias due to venous hypertension.

## Hereditary Hemorrhagic Telangiectasia (Osler–Weber–Rendu Disease)

• Autosomal dominant disorder due to mutations in several genes, particularly the two that encode endoglin and ALK-1, both of which are TGF-β receptors expressed in the vascular endothelium.

• The vascular lesions are actually arteriovenous malformations (AVMs) and are found in the skin, mucous membranes, GI tract, CNS, and other visceral organs (e.g. lung, liver); the disorder most often initially presents as recurrent epistaxis due to involvement of the nasal mucosa, with hemorrhage at other sites usually occurring later in life.

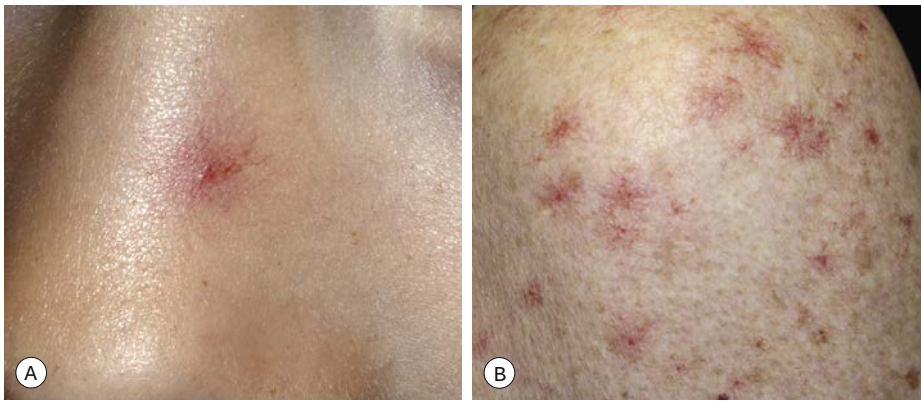


**Fig. 87.8 Spider telangiectasias.** They are characterized by a central arteriole with radiating telangiectatic "legs". **A** Single lesion on the nose of a young child. **B** Multiple lesions on the shoulder of an adult with liver disease. *A, Courtesy, Julie V. Schaffer, MD; B, Courtesy, Jeffrey P. Callen, MD.*



**Fig. 87.9 Angioma serpiginosum.** Clusters of dark red puncta on the arm in a serpiginous pattern. This disorder initially favors a single extremity, usually in a girl, and may be confused with a pigmented purpuric eruption. *Courtesy, YDRSC.*



**Fig. 87.11 Generalized essential telangiectasia.** The site of initial involvement is usually the distal lower extremities. Sheets of asymptomatic blanchable telangiectasias appear bilaterally and over time can become widespread. *Courtesy, Jean L. Bolognia, MD.*



**Fig. 87.10 Unilateral nevoid telangiectasia.** Discrete telangiectasias in a unilateral, segmental distribution pattern. This is a common location. *Courtesy, Robert Hartman, MD.*

- The oral mucosal lesions (tongue, lips) usually appear during adolescence and predate the cutaneous "telangiectasias" (face, hands); there is an increase in the overall number of lesions with time (Fig. 87.12).
- Clinical criteria: (1) spontaneous recurrent epistaxis, (2) characteristic mucocutaneous telangiectasias/AVMs, (3) visceral telangiectasias/AVMs, and (4) HHT in a first-degree relative; definite diagnosis if ≥3 criteria and possible/suspected diagnosis if 1 or 2 criteria (especially in children and young adults).
- Evaluation is outlined in Table 87.5.

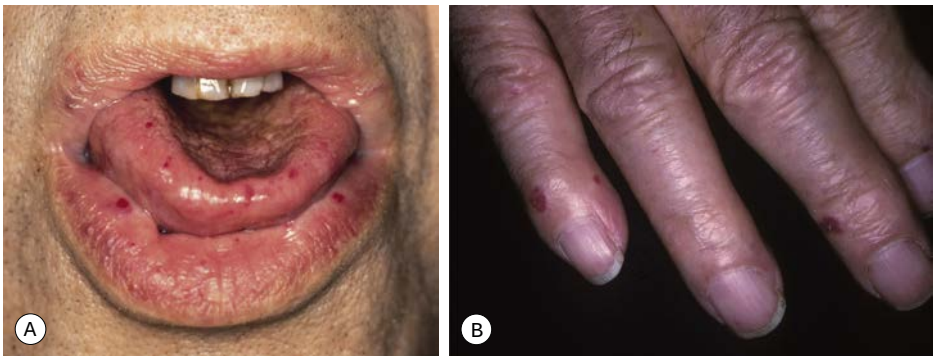


**Fig. 87.12 Hereditary hemorrhagic telangiectasia (Osler–Weber–Rendu disease).** The majority of lesions are papular, but occasionally they resemble the mat telangiectasias observed in systemic sclerosis. **A, B** Common locations include the tongue and lips as well as the fingers, with the former predating the latter. *A, Courtesy, YDRSC; B, Courtesy, Irwin Braverman, MD.*

**STUDIES RECOMMENDED TO SCREEN FOR SYSTEMIC INVOLVEMENT AND ASSIST IN THE DIAGNOSIS OF HEREDITARY HEMORRHAGIC TELANGIECTASIA (HHT)**

| Study and purpose | Frequency | Indication(s) | % of HHT patients |
|---|---|---|---|
| Transthoracic contrast echocardiography (bubble study) to detect **pulmonary** AVMs | If initial screening negative, repeat every 5–10 years as well as prior to and following pregnancies | Suspected or confirmed HHT | 15–50 |
| Brain MRI with and without gadolinium to detect **cerebral** AVMs and other vascular malformations | If initial screening negative, repeat at age 18 years | Suspected or confirmed HHT | ~25 |
| Hemoglobin and hematocrit levels to detect GI bleeding due to **GI** AVMs | Yearly after age 35 years | HHT patients | ~25 |
| Doppler ultrasonography or triphasic spiral CT of liver to detect **hepatic** AVMs | If signs or symptoms of heart failure or hepatobiliary disease | HHT patients | 30–80 |
| | As a clinical criterion (see text) | Suspected or confirmed HHT | |
| Genetic analysis of *ENG* and/or *ACVRL1* (then *SMAD4* or *GDF2* if negative) of index case | Once unless additional genes identified or improved methodology | Also performed in first-degree relatives of HHT patients or suspected HHT | ~75 for *ENG* or *ACVRL*1; 1–3 for *SMAD4* |

**Table 87.5 Studies recommended to screen for systemic involvement and assist in the diagnosis of hereditary hemorrhagic telangiectasia (HHT).**

• **Rx:** laser therapy, diathermy, transcatheter embolotherapy (e.g. for lung AVMs so as to avoid right-to-left shunting and risk of paradoxical embolization), surgical intervention.

## Ataxia–Telangiectasia (see Ch. 49)

• Primary immunodeficiency syndrome inherited in an autosomal recessive manner in which telangiectasias appear on the bulbar conjunctivae during childhood as



**Fig. 87.13 Venous lake on the vermilion lip.** This dark blue papule is soft and, with compression, can be emptied of most of its blood content. *Courtesy, Ronald Rapini, MD.*

well as in the head and neck region (eyelids, malar, ears) and antecubital and popliteal fossae.

## Venous Lake

- A blue, soft papule that is compressible and, with pressure, both its color and elevation are diminished (Fig. 87.13); represents dilation of superficial blood vessels.
- Most common sites are vermilion lip > face, ears.
- **Rx:** electrosurgery, vascular laser therapy.

## Angiokeratomas

- See Chapter 94

## Nevus Anemicus

- Congenital circumscribed area of pale vasoconstriction, often 5–10 cm in diameter and occurs most commonly on the trunk (Fig. 87.14).
- The edges are irregular and disappear via diascopy (pressure), allowing distinction from nevus depigmentosus or vitiligo; application of heat or an ice cube accentuates the border as a result of hyperemia of surrounding uninvolved skin.

## Angiospastic Macules (Bier Spots)

- Pale macules due to relative vasoconstriction within areas of subtle vascular mottling (Fig. 87.15); as with nevus anemicus, the border disappears with diascopy (pressure); dependency leads to accentuation of lesions due to venous congestion.
- Most commonly observed in young healthy adults with lightly pigmented skin; no effective **Rx.**

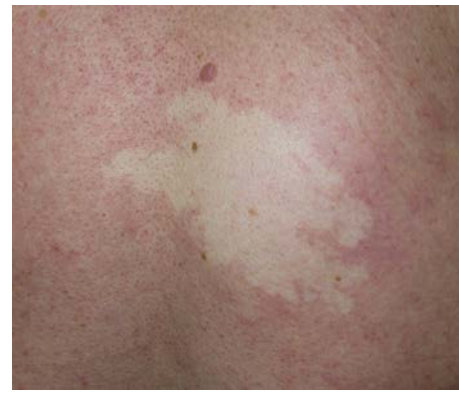

**Fig. 87.14 Nevus anemicus.** Pale area of vasoconstriction with irregular borders on the back. *Courtesy, YDRSC.*



**Fig. 87.15 Angiospastic macules (Bier spots).** Multiple pale macules due to vasoconstriction within a background of erythema on the forearm.

For further information see Ch. 106 from *Dermatology, Fourth Edition*.

**For additional online figures visit www.expertconsult.com**

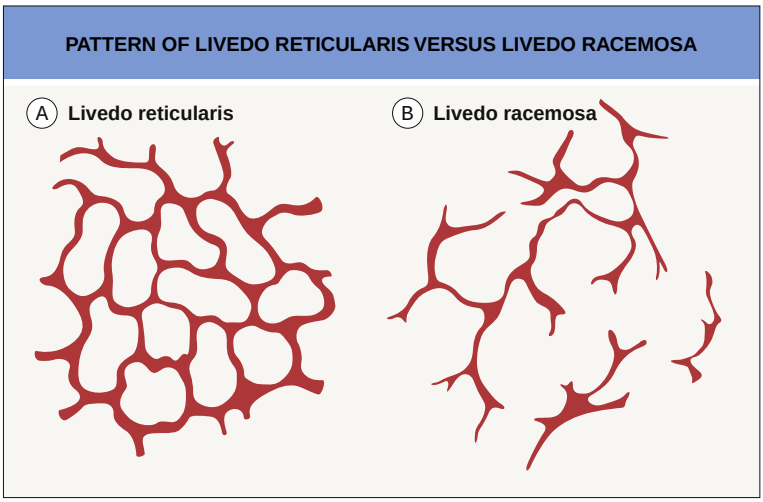


**eFig. 87.1 Pattern of livedo reticularis (A) versus livedo racemosa (B).**



**eFig. 87.2 Primary (idiopathic) livedo reticularis.** An even, netlike pattern that persists with rewarming. *Courtesy, Christopher Baker, MD, and Robert Kelly, MD.*



**eFig. 87.3 Livedo racemosa in a patient with lymphocytic thrombophilic arteritis.** A more irregular, broken, and branching pattern is seen, as compared to livedo reticularis. Some clinicians view this disease as a variant of polyarteritis nodosa. *Courtesy, Christopher Baker, MD, and Robert Kelly, MD.*



**eFig. 87.4 Reticulated purpura and necrosis due to calciphylaxis.** These patients can also have patchy areas of livedo reticularis. *Courtesy, Norbert Sepp, MD.*



**eFig. 87.6 Fine, linear and branching, blue-violet telangiectasias of the leg.** *Courtesy, Jean L. Bolognia, MD.*



**eFig. 87.5 Erythromelalgia.** Red hot painful feet. *Courtesy, Christopher Baker, MD, and Robert Kelly, MD.*



**eFig. 87.7 Hereditary benign telangiectasia.** Fine linear and punctate telangiectasias were present on the cheeks and vermilion lips bilaterally in this child. There is no associated visceral involvement. *Courtesy, Antonio Torrelo, MD.*




**eFig. 87.8 Spider telangiectasias. A** Central red papule representing the feeding arteriole with radiating telangiectatic "legs" on the cheek of a young child. **B** Multiple lesions in a jaundiced patient with liver disease. *A, Courtesy, Phillip Bekhor, MD; B, Courtesy, Ronald Rapini, MD.*



**eFig. 87.9 Cutaneous collagenous vasculopathy.** Multiple violaceous branching telangiectasias on the forearm; the patient also had involvement of the thighs, abdomen, and back. *Courtesy, Lorenzo Cerroni, MD.*



**eFig. 87.10 Hereditary hemorrhagic telangiectasia (Osler–Weber–Rendu disease).** The majority of lesions are papular, but occasionally they resemble the mat telangiectasias observed in systemic sclerosis. The lips are a common location. *Courtesy, Irwin Braverman, MD.*

# Actinic Keratosis, Basal Cell Carcinoma, and Squamous Cell Carcinoma

88

## Introduction

- Keratinocyte carcinoma (KC), also referred to as non-melanoma skin cancer (NMSC), is the most frequently observed malignancy in Caucasians.
- KC typically refers to basal cell carcinoma (BCC) and squamous cell carcinoma (SCC).
- In individuals with fair skin, ~75–80% of KCs are BCCs, and up to 25% are SCCs.
- The two most important risk factors for developing KC are skin phototype (see Appendix) and exposure to UVR (Table 88.1).
- The presence of actinic keratoses (AKs) and/or KCs increases the likelihood of future KCs and cutaneous melanoma, particularly lentigo maligna; such persons require lifelong surveillance via total body skin examination (TBSE).
- Based upon epidemiologic studies, KCs have been associated with an increased risk of internal malignancies; the risk is greatest in persons with numerous KCs and in those with younger age of onset of KCs.

## Actinic Keratoses (AKs)

- Also referred to as solar keratoses, AKs are considered "precancerous" lesions that have the potential to progress into invasive SCC; estimates of progression vary from a rate of 0.075–0.1% per lesion per year to ~10% over 10 years.
- The atypical keratinocytes are confined to the lower portion of the epidermis (Fig. 88.1).
- AKs are one of the most frequently encountered lesions in clinical practice.
- Occur primarily in sites that have received the greatest amount of cumulative sun exposure (e.g. scalp in bald individuals, face, ears, neck, dorsal forearms and hands, shins); seen primarily in middle-aged to older, fair-skinned individuals.
- Classic presentation is a gritty papule with an erythematous base; the associated scale is usually white to yellow in color and feels rough (Fig. 88.2).
- Common clinical variants: pigmented (Fig. 88.2C), hypertrophic (referred to as HAK [Fig. 88.2D, E]), lichenoid, and atrophic (Fig. 88.2B); in actinic cheilitis, there is scaling and roughness of the lower vermilion lip (Fig. 88.2F).
- Dx: usually made by visual inspection and palpation; because of the rough texture, it is sometimes easier to detect lesions via touch.
- AKs have the potential to persist, spontaneously regress, or progress to SCC, but clinically it is difficult to predict which course a given AK will take.
- Clinical clues of progression to invasive SCC and need for biopsy: tenderness, volume (particularly thickness), inflammation, and failure to respond to appropriate therapy.
- **DDx:** SCC *in situ*, BCC, lichen planus-like keratosis (LPLK; see Ch. 89), irritated seborrheic keratosis (SK) or verruca vulgaris, and amelanotic melanoma; for thicker lesions (e.g. HAK), invasive SCC; for lesions on extensor extremities, actinic porokeratosis; occasionally, isolated lesions of psoriasis or seborrheic dermatitis may resemble an AK.
- **Rx:** localized or lesion-targeted treatments are best for an isolated or limited number of lesions; field treatments are best for more numerous or larger lesions (Table 88.2).
- Prevention is possible with broad-spectrum sunscreens and sun avoidance measures; in patients with a history of KCs, use of oral nicotinamide may reduce the development of additional AKs and KCs.

| RISK FACTORS FOR THE DEVELOPMENT OF BASAL CELL CARCINOMAS (BCC) AND SQUAMOUS CELL CARCINOMAS (SCC) | | |
|---|---|---|
| | **SCC** | **BCC** |
| **Environmental exposures** | | |
| UV exposure | + | + |
| Other exposures to UV light (PUVA, tanning beds) | + | + |
| Ionizing radiation | + | + |
| Chemicals, including arsenic, mineral oil, coal tar, soot, mechlorethamine (nitrogen mustard), polychlorinated biphenyls, 4,4′ bipyridyl, psoralen (plus UVA) | + | + |
| Medications (e.g. HCTZ, voriconazole, BRAF inhibitors [especially when used alone], hydroxyurea) | + | (+) |
| Human papillomavirus (HPV) | + | (+) |
| Cigarette smoking | + | |
| **Pigmentary phenotype** | | |
| Fair skin, always burns, never tans | + | + |
| Freckling | + | + |
| Red hair | + | + |
| **Genetic syndromes** | | |
| Xeroderma pigmentosum | **+** | **+** |
| Oculocutaneous albinism | + | + |
| Epidermodysplasia verruciformis | + | (+) |
| Dystrophic epidermolysis bullosa (primarily recessive) | + | |
| Ferguson–Smith syndrome | + | |
| Muir–Torre syndrome | +* | +* |
| Basal cell nevus syndrome | | + |
| Bazex–Dupré–Christol and Rombo syndromes | | + |
| **Predisposing clinical settings** | | |
| Chronic non-healing wounds | **+** | |
| Longstanding discoid lupus erythematosus, lichen planus (erosive), or lichen sclerosus | + | |
| Porokeratosis (especially linear) | + | |
| Nevus sebaceus | + | +† |
| **Immunosuppression** | | |
| Organ transplantation | **+** | **+** |
| Immunosuppressive medications (e.g. azathioprine, cyclosporine, tacrolimus, biologics, prednisone) | **+** | **+** |
| Other (e.g. chronic lymphocytic leukemia treated with fludarabine, AIDS patients with HPV infection, childhood cancer survivors) | + | (+) |

**Both SCCs (keratoacanthoma type) and BCCs typically have sebaceous differentiation.*
*†More often trichoblastomas.*

**Table 88.1 Risk factors for the development of basal cell carcinomas (BCC) and squamous cell carcinomas (SCC).**

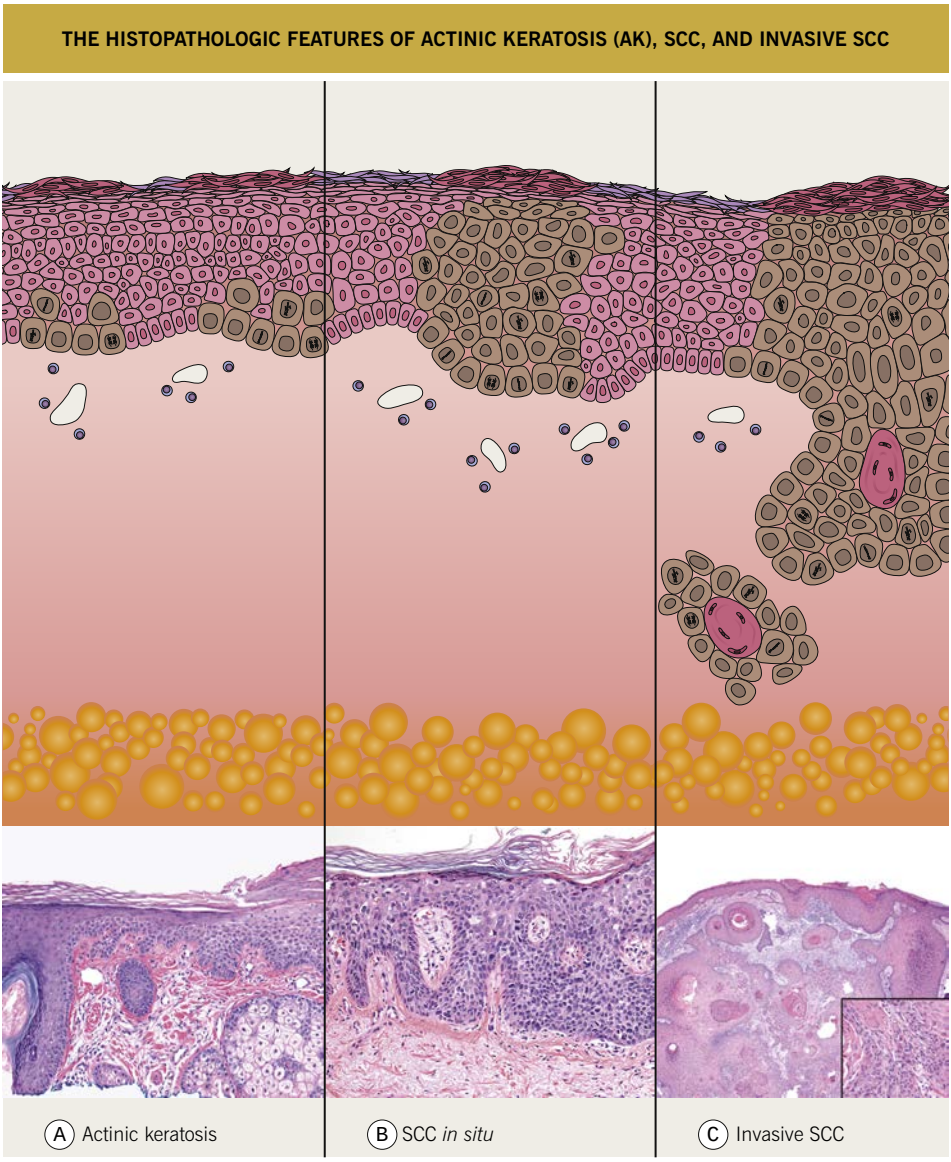


**Fig. 88.1 The histopathologic features of actinic keratosis (AK), SCC *in situ*, and invasive SCC.** **A** An AK consists of a lower epidermal proliferation of cytologically abnormal keratinocytes; the adnexal epithelium is notably spared. **B** In SCC *in situ*, the atypical keratinocytes occupy the entire epidermis and intraepidermal portion of adnexal structures, without invasion into the dermis. **C** Invasive SCC is distinguished by the extension of the malignant keratinocytes into the dermis. If an invasive SCC is clinically suspected, the biopsy specimen should be deep enough to determine the extent of dermal invasion.

## SCC *In Situ* (Bowen Disease)

- May arise *de novo* or from a pre-existing AK; sometimes caused by oncogenic strains of human papillomavirus (HPV, e.g. periungual [see Ch. 66]).
- Keratinocyte atypia is seen throughout the entire epidermis (full-thickness) (see Fig. 88.1) and has the potential to progress to invasive SCC, with an estimated risk of ~3–5% if untreated.
- With the exception of HPV- or arsenic-related SCC *in situ*, the risk factors for and the locations of SCC *in situ* are similar to those for AKs (see above and Table 88.1).




**Fig. 88.2 Actinic keratoses (AKs).** **A** Multiple AKs on the face of an elderly woman with fair complexion, blue eyes, and moderate to severe photodamage; the AKs vary in size from a few millimeters to more than 1 cm. On the left forehead, the red nodule with slight scale-crust represents a well-differentiated SCC. **B** Pink-colored atrophic AK with minimal scale on the forehead. **C** Pigmented AK presenting as a subtle hyperpigmented, reticulated macule on the cheek; there may be associated scale but an absence of erythema. **D** Multiple AKs on the bald scalp, some of which are hypertrophic; the area of hypopigmentation represents a site of previous treatment and due to the field defect, recurrence at the edge is commonly seen. **E** Multiple, large hypertrophic AKs on the shin of an elderly woman; note the thick scale. **F** Actinic cheilitis presenting with erythema and scale of the entire lower vermilion lip; note the erosions and areas of leukoplakia. *A, Courtesy, H. Peter Sawyer, MD; B, Courtesy, Iris Zalaudek, MD; C, F, Courtesy Kalman Watsky, MD; D, Courtesy, Luis Requena, MD; E, Courtesy, Jean L. Bolognia, MD.*

| COMMON TREATMENT OPTIONS FOR ACTINIC KERATOSES (AKS) | |
|---|---|
| **Localized/lesion-targeted treatments*** | |
| **Lesion-targeted treatment** | **Helpful hints** |
| Liquid nitrogen cryosurgery | • No cutting or anesthesia necessary<br>• 10- to 14-day healing period<br>• Risk of hypopigmentation |
| Curettage<br>(> curettage + electrodesiccation) | • Requires local anesthesia<br>• Risk of hypopigmentation and scarring (less so if curettage alone) |
| Shave excision | • Requires local anesthesia<br>• Risk of hypopigmentation and scarring |

| **Topical field treatments**,†** | | |
|---|---|---|
| *Although these are the recommended FDA dosing schedules, if the patient develops significant burning with application or significant erosive erythema, the treatment should be held or discontinued.* | | |
| **Topical agent** | **Dosing** | **Helpful hints** |
| 5-Fluorouracil | • 1.0% or 5.0% cream – apply twice a day for 2–4 weeks<br>• 2.0% and 5.0% solutions – apply twice a day for 2–4 weeks<br>• 0.5% cream – apply at bedtime × 4 weeks<br>• When treating extensor extremities, pretreatment with a topical retinoid for 1–2 weeks may be required<br>• For severe leg involvement, occluded "chemowraps" may be used<br>• 5.0% cream can be combined with topical 0.005% calcipotriene (calcipotriol) ointment twice a day for 4 days | • Warn of photosensitivity, which can be severe<br>• Optimal results occur if treatment continues until there is significant inflammation or mild superficial erosions<br>• Healing usually occurs within 2 weeks of stopping treatment<br>• Solution is best for hair-bearing areas, such as the scalp |
| Imiquimod | • 2.5% or 3.75% cream – apply at bedtime for 2 weeks; take a 2-week break, and then repeat 2-week application cycle<br>• 5% cream – apply twice a week for 16 consecutive weeks<br>• Recommended treatment area is 25 $cm^2$ | • May cause systemic flu-like symptoms<br>• Not recommended if patient has an underlying autoimmune condition<br>• May cause hypopigmentation at the treated site |
| Diclofenac | • 3% gel – apply twice a day for 90 days<br>• A maximum amount of 8 gm daily should not be exceeded | • Do not use if patient is allergic to NSAIDs<br>• Although it may have a less severe cutaneous reaction, compliance is an issue given a longer application period |
| Ingenol mebutate[$] | • 0.015% gel – apply at bedtime for 3 consecutive nights (face and scalp)<br>• 0.05% gel – apply at bedtime for 2 consecutive nights (trunk and extremities) | • Rapid onset of action; typically within 24 hours of application, patient will experience erythema and burning<br>• Healing occurs within 10–14 days<br>• Supposedly does not cause hypopigmentation |

**Table 88.2 Common treatment options for actinic keratoses (AKs).** *Continued*

| COMMON TREATMENT OPTIONS FOR ACTINIC KERATOSES (AKS) | |
|---|---|
| **Procedural field treatments**,†** | |
| **Procedure** | **Helpful hints** |
| Photodynamic therapy (e.g. 5-ALA + blue light) | • Can be painful<br>• Requires 48 hours of no outdoor exposure post-treatment<br>• Relatively quick recovery over 1–2 weeks |
| Chemical peels (e.g. trichloroacetic acid) | • May require local anesthesia<br>• May cause significant irritation and temporary discoloration<br>• Healing typically over 7 days |
| Ablative laser techniques (e.g. ablative fractional lasers, erbium:YAG laser) | • Requires local anesthesia<br>• Depending on the technique, recovery period varies<br>• Hypopigmentation a potential complication |

*Most appropriate for an isolated or limited number of AKs.
**Most appropriate for numerous or larger AK lesions; a recent study favored 5-fluorouracil over other topical therapies.
†In practice, combination or sequential therapy is sometimes used (e.g. liquid nitrogen to several thicker lesions followed by 5-fluorouracil or imiquimod).
$Ingenol mebutate has been withdrawn from the EU, UK, and Canadian markets because of concern over an associated increase in cutaneous malignancy.

**Table 88.2** *Continued* **Common treatment options for actinic keratoses (AKs).** ALA, aminolevulinic acid.

- Clinically presents as an erythematous patch or thin plaque with scale (Fig. 88.3); occasionally, the lesions are pigmented.
- Less common sites (may be related to HPV infection): beard area, periungual (see Figs 88.3C and 58.8) and subungual, anogenital (now referred to as intraepithelial neoplasia, further qualified by anatomic site [see Ch. 60 and Fig. 88.4]); SCC *in situ* in non-sun-exposed sites may also be related to arsenic exposure.
- Dx: biopsy; dermoscopy may assist in diagnosis (Fig. 88.3B).
- **DDx:** AK, invasive SCC, BCC, LPLK, irritated SK, amelanotic melanoma; occasionally may be misdiagnosed as an isolated lesion of psoriasis or nummular eczema, but a clue is its lack of response to appropriate therapy.
- **Rx:** tangential excision with curettage or electrodesiccation and curettage (especially for smaller lesions), excision, Mohs micrographic surgery (e.g. head and neck, acrogenital); imiquimod cream and topical 5% fluorouracil (twice daily for a longer period, e.g. 8 weeks) may be used when a surgical approach would prove difficult to perform because of location or extent.

## Squamous Cell Carcinoma (SCC)

- An invasive mucocutaneous malignancy arising from keratinocytes; may develop *de novo* or from precursor AK or SCC *in situ* (see Fig. 88.1).
- More common in males than females, and incidence increases with age.
- In fair-skinned individuals, the risk factors for and the locations of invasive SCC are similar to those for AKs and SCC *in situ* (see above and Table 88.1).
- In all phototypes, invasive SCC may develop in sites of HPV infection, scars, chronic injury or inflammation, previous radiation therapy, or chemical exposure (e.g. polycyclic aromatic hydrocarbons; see Table 88.1).
- Common clinical presentation is an erythematous, keratotic papule or nodule that arises within a background of sun-damaged skin; tenderness is common; often a history of rapid enlargement (Fig. 88.5) and sometimes a history of antecedent trauma (see Fig. 88.5B).
- Clinical variants: keratoacanthoma (KA) (Fig. 88.6), verrucous carcinoma (Fig. 88.7), mucosal (Fig. 88.8), periungual and subungual.
- Dx: biopsy (should be deep enough to determine extent of dermal invasion); palpate regional lymph node basin.
- **DDx:**
  - *Most common*: AK, HAK, SCC *in situ*, BCC, verruca vulgaris, irritated SK
  - *Less common*: amelanotic melanoma, atypical fibroxanthoma (AFX), Merkel cell carcinoma, adnexal tumors, prurigo nodularis




**Fig. 88.3 Squamous cell carcinomas *in situ*, Bowen disease type. A** Scaly red plaque on the chest with skip areas and background photodamage. **B** Larger broken up pink plaque with scale-crust in the pubic region, a sun protected site. This type of lesion is often misdiagnosed as dermatitis or psoriasis and treated with topical CS; (inset) dermoscopic examination of a pink scaly plaque of SCC *in situ* with tiny dotted vessels in the upper half of the lesion combined with superficial scales. **C** Bright-red, well-demarcated plaque on the proximal nail fold with associated horizontal nail ridging; the possibility of HPV infection needs to be considered. **D** Extensive involvement of the finger, which was misdiagnosed clinically as an inflammatory dermatosis and treated for years with topical CS. *A, C, Courtesy, YDRSC; B, Courtesy, Kalman Watsky, MD; inset, Courtesy, Iris Zalaudek, MD; D, Courtesy, H. Peter Sawyer, MD.*

• A cutaneous SCC staging format has been proposed by the American Joint Commission on Cancer, incorporating the TNM criteria, prognostic factors (tumor thickness, ± perineural invasion, high-risk locations, ± lymph node involvement), histologic grade, and the presence or absence of lymphatic/vascular invasion on histology (Table 88.3).



**Fig. 88.4 Squamous cell carcinoma, *in situ*, of the penis, also known as penile intraepithelial neoplasia (PIN).** Formerly called SCC *in situ*, erythroplasia of Queyrat type. Large eroded erythematous plaque with well-demarcated borders. The lesion began on the shaft of the penis. *Courtesy, YDRSC.*

- Long-term prognosis for adequately treated SCC is excellent.
- Overall, the risk of nodal metastases from invasive SCC has been estimated at 2–4%; ~20% of all skin cancer deaths are due to SCC.
- There are several risk factors for metastasis: lesions on the lips, ear, and mucosae (e.g. tongue, vulva, penis); development within a scar; host immunosuppression; tumor thickness >2 mm; tumor diameter ≥2 cm; poorly differentiated histopathology; development within Bowen disease; perineural invasion.
- Significant cause of morbidity and mortality in solid organ transplant recipients, who are more likely to experience local and regional recurrences, as well as metastases.
- **Rx:** primarily excision, but based on risk factors (Table 88.4), ranges from electrodesiccation and curettage (e.g. smaller, minimally invasive lesion in an elderly patient) to Mohs micrographic surgery (Table 88.5).
- Prophylaxis in high-risk patients: acitretin, low-dose oral capecitabine in solid organ transplant recipients.

## Basal Cell Carcinoma (BCC)

- Most common KC in humans; arises *de novo*, with no known precursor lesion.
- More common in males than females; primarily seen in middle-aged to older adults who are fair-skinned; however, the incidence is rising, especially in young women.
- UVR exposure is the greatest risk factor, but in contrast to AK/SCC, intense episodes of burning are more important than chronic long-term exposure; in addition, BCCs can also arise in relatively non-sun-exposed areas, e.g. retroauricular crease and inner canthus (Fig. 88.9C).
- Usually slow-growing; without adequate treatment, BCCs will gradually increase in size and they may ulcerate and cause local destruction of surrounding tissue; metastases are exceedingly rare (regional lymph nodes > lung).
- Multiple clinical variants and varied presentations exist:
  - *Most common*: nodular (pearly papule with telangiectasias and/or umbilication; Fig. 88.9), superficial (typically an erythematous thin plaque on trunk > extremities; Fig. 88.10), pigmented (Fig. 88.11)
  - *Less common*: morpheaform (scar-like; Fig. 88.12), micronodular, cystic, basosquamous, and fibroepithelial (fibroepithelioma of Pinkus) (Fig. 88.13)
- Dx: biopsy; dermoscopy can assist in diagnosis (see Figs 88.9B and 88.11C).
- **DDx:** *nodular*: intradermal melanocytic nevus, fibrous papule, sebaceous hyperplasia, invasive SCC, amelanotic melanoma; *superficial*: LPLK, AK, SCC *in situ*, isolated lesion of psoriasis, seborrheic dermatitis or nummular eczema, amelanotic melanoma; *morpheaform*: scar, adnexal tumors (e.g. desmoplastic trichoepithelioma, microcystic adnexal carcinoma [see Ch. 91]); *pigmented*: melanocytic nevus, seborrheic keratosis, pigmented SCC *in situ*, nodular melanoma.
- Categorize tumor into histologic subtype and whether or not meets criteria for high-risk BCC (e.g. morpheaform, micronodular, or infiltrative; see Table 88.4) or indications for Mohs micrographic surgery to determine best treatment (see Table 88.5); basosquamous lesions are treated as invasive SCCs (see above).
- Nevoid BCC syndrome (NBCS): rare, autosomal dominant, caused by mutations in human *PTCH* gene; characterized by multiple BCCs, palmoplantar pits, odontogenic keratocysts of jaw, skeletal abnormalities, macrocephaly, and calcification of the falx cerebri; patients may develop medulloblastomas during childhood or ovarian fibromas.

For further information see Chs 107–108 from *Dermatology, Fourth Edition*.




**Fig. 88.5 Squamous cell carcinomas (SCCs). A** A large keratotic nodule on the supraorbital region in an elderly woman; note the coarse wrinkling and solar elastosis of the face. **B** Eroded and keratotic nodule that developed rapidly at the site of trauma on the shin in a patient with severe photodamage; this has also been described as a reactive process, termed "atypical squamous proliferation". **C** Large, fungating nodule on the dorsum of the hand. **D** Multiple eroded superficial SCCs in association with hypertrophic AKs on the cheek and neck of an elderly man. **E** Erosive, slightly vegetating, thick plaque arising within lichen sclerosus of the vulva. **F** Firm, eroded red plaque on the scrotum; histopathologically, the SCC was moderately differentiated. *A, C–F, Courtesy, H. Peter Sawyer, MD; B, Courtesy, Jean L. Bolognia, MD.*

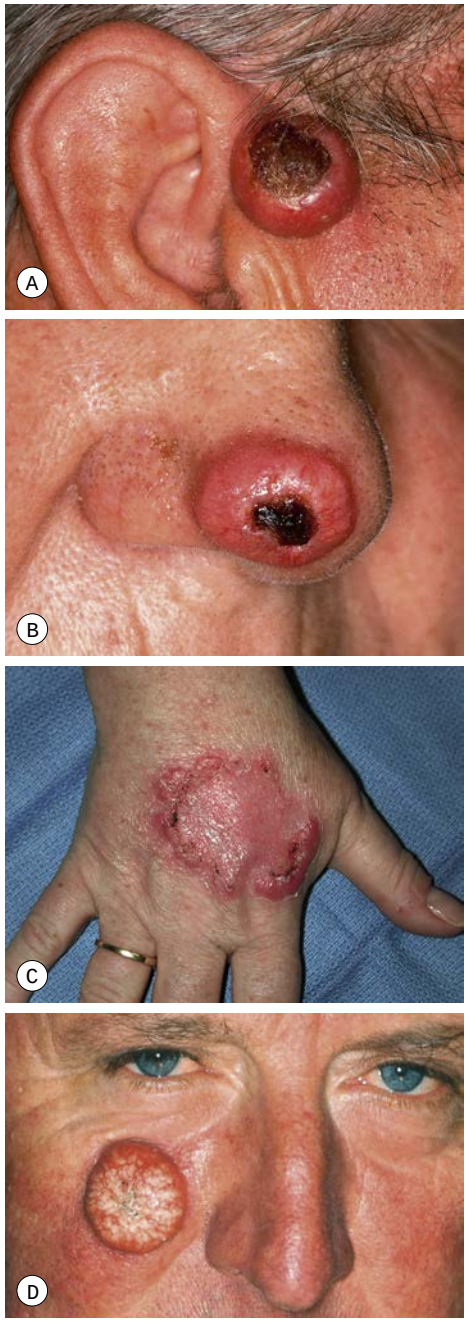


**Fig. 88.6 Clinical spectrum of keratoacanthomas. A, B** Rapidly growing, erythematous crateriform nodules with a rolled border and central keratotic core. **C** Progressive peripheral expansion and central involution with residual atrophy characterize keratoacanthoma centrifugum marginatum. **D** Giant keratoacanthoma with a yellow-red color and a history of rapid growth. *A, D, Courtesy, H. Peter Sawyer, MD; B, C, Courtesy, YDRSC.*




**Fig. 88.7 Verrucous carcinoma. A** Long-standing large nodule on the plantar surface with a rabbit burrow-like appearance; such a tumor is also referred to as an epithelioma cuniculatum. **B** Keratotic and ulcerated plaque on the ventromedial aspect of the great toe. The lesion was originally misdiagnosed as a plantar wart. **C** A classic location in an amputation stump. In general, these well-differentiated SCCs enlarge slowly. *A, C, Courtesy, H. Peter Sawyer, MD; B, Courtesy, YDRSC.*

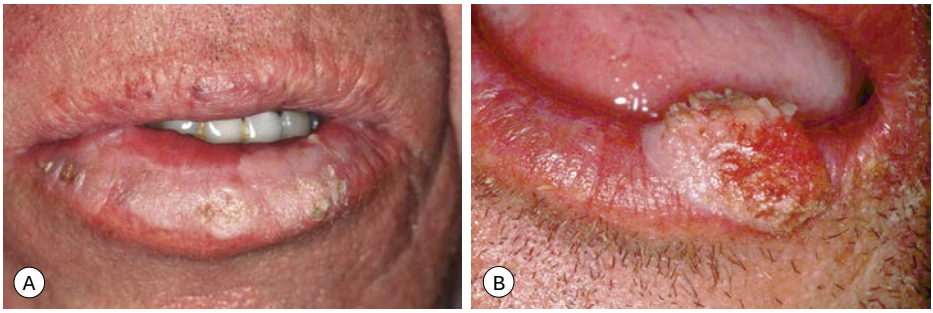


**Fig. 88.8 Squamous cell carcinoma (SCC) of the lower lip. A** Extensive hyperkeratosis and leukoplakia of the lower vermilion lip; histopathologically, the SCC was superficially invasive and well-differentiated. **B** Verrucous and eroded nodule on the lower vermilion lip in a heavy smoker. *Courtesy, H. Peter Sawyer, MD.*

| STAGING OF CUTANEOUS SQUAMOUS CELL CARCINOMA (SCC) OF THE HEAD AND NECK | |
|---|---|
| **T, N, M** | |
| **Primary tumor (T)** | |
| TX | Primary tumor cannot be identified |
| Tis | Carcinoma *in situ* |
| T1 | Tumor <2 cm in greatest dimension |
| T2 | Tumor 2 cm or larger, but smaller than 4 cm in greatest dimension |
| T3 | Tumor 4 cm or larger in maximum dimension or minor bone erosion or perineural invasion or deep invasion* |
| T4 | Tumor with gross cortical bone/marrow invasion (4a); skull base invasion and/or skull base foramen involvement (4b) |
| **Regional lymph nodes (clinical) (cN)** | |
| NX | Regional lymph nodes cannot be assessed |
| N0 | No regional lymph node metastasis |
| N1 | Metastasis in a single ipsilateral lymph node, ≤3 cm in greatest dimension and ENE(–) |
| N2 | Metastasis in a single ipsilateral lymph node, >3 cm but <6 cm in greatest dimension and ENE(–) (2a); or in multiple ipsilateral lymph nodes, none >6 cm in greatest dimension and ENE(–) (2b); or in bilateral or contralateral lymph nodes, none >6 cm in greatest dimension and ENE(–) (2c) |
| N3 | Metastasis in a lymph node, >6 cm in greatest dimension and ENE(–) (3a); or metastasis in any node(s) and ENE(+) (3b) |
| **Distant metastasis (M)** | |
| M0 | No distant metastasis |
| M1 | Distant metastasis |

**Table 88.3 Staging of cutaneous squamous cell carcinoma (SCC) of the head and neck.** *Continued*

| STAGING OF CUTANEOUS SQUAMOUS CELL CARCINOMA (SCC) OF THE HEAD AND NECK | | | |
|---|---|---|---|
| **Stage** | | | |
| | **T** | **N** | **M** |
| 0 | Tis | N0 | M0 |
| I | T1 | N0 | M0 |
| II | T2 | N0 | M0 |
| III | T3 | N0 | M0 |
| | T1 | N1 | M0 |
| | T2 | N1 | M0 |
| | T3 | N1 | M0 |
| IV | T1 | N2 | M0 |
| | T2 | N2 | M0 |
| | T3 | N2 | M0 |
| | T Any | N3 | M0 |
| | T4 | N Any | M0 |
| | T Any | N Any | M1 |

**Deep invasion is defined as invasion beyond the subcutaneous fat or >6 mm (as measured from the granular layer of adjacent normal epidermis to the base of the tumor); perineural invasion for T3 classification is defined as tumor cells within the nerve sheath of a nerve lying deeper than the dermis or measuring 0.1 mm or larger in caliber, or presenting with clinical or radiographic involvement of named nerves without skull base invasion or transgression.*

**Table 88.3** *Continued* **Staging of cutaneous squamous cell carcinoma (SCC) of the head and neck.** The Brigham and Women's Hospital (BWH) T staging system divides T2 into a and b and considers T1 = 0 high-risk factors (HRF), T2a = 1 HRF, T2b = 2–3 HRF, and 3 = ≥4 HRF or bone invasion; the HRF are diameter ≥2 cm, poorly differentiated, perineural invasion ≥0.1 mm, or invasion beyond fat. ENE, extranodal extension. *Adapted from American Joint Committee on Cancer, 2017.*

| CHARACTERISTICS OF HIGH-RISK BCC AND SCC | |
|---|---|
| **Clinical characteristics** | **Histopathologic characteristics** |
| • Area L ≥20 mm<br>Area M ≥10 mm<br>Area H (any size)<br>• Poorly defined borders<br>• Recurrent tumor<br>• Immunosuppressed host<br>• Tumor at site of previous XRT<br>• Tumor at site of chronic inflammatory process or ulceration<br>• Rapidly growing tumor (SCC only)<br>• Neurologic symptoms: pain, paresthesia, paralysis | • Morpheaform (sclerosing), infiltrative, micronodular or basosquamous subtypes (BCC only)<br>• Adenoid, adenosquamous, desmoplastic or metaplastic subtypes (SCC only)<br>• Poorly differentiated (SCC only)<br>• Arising within Bowen disease (SCC only)<br>• Depth ≥2 mm or Clark level IV or V (SCC only)<br>• Perineural involvement (BCC and SCC)<br>• Lymphatic or vascular involvement (SCC) |

**Table 88.4 Characteristics of high-risk basal cell carcinoma (BCC) and squamous cell carcinoma (SCC).** The presence of these high-risk characteristics increases the likelihood of recurrence of BCC and SCC, as well as the possibility of metastasis (primarily SCC). In addition, these high-risk features are used to determine indication for Mohs micrographic surgery. Area L – low-risk anatomic sites: trunk, extremities (excluding hands, feet, nail units, pretibia, ankles). Area M – middle-risk anatomic sites: cheeks, forehead, neck, jawline, scalp, pretibia. Area H – high-risk anatomic sites: central face, eyelids, eyebrows, periorbital skin, nose, lips, chin, mandible, pre- and post-auricular skin/sulci, temple, ear, genitalia, hands, feet, ankles, nipple/areola.

| COMMON TREATMENT OPTIONS FOR BCC AND SCC | |
|---|---|
| **Squamous cell carcinoma** | **Basal cell carcinoma** |
| **Low-risk lesions** | **Low-risk lesions** |
| Surgical:<br>• Tangential excision with curettage<br>• Electrodesiccation and curettage<br>• Standard excision with 4- to 6-mm margins<br>Nonsurgical**:<br>• XRT† for nonsurgical candidates<br>• Topical therapies (e.g. imiquimod, 5-FU) and PDT are typically *not* recommended for treatment of *invasive* SCC; occasionally they are used for treatment of *in situ* SCC when a patient declines or is not a candidate for surgical therapy. | Surgical:<br>• Tangential excision with curettage<br>• Electrodesiccation and curettage<br>• Standard excision with 4-mm margins<br>Nonsurgical (primarily for superficial variant)**:<br>• Topical imiquimod (e.g. 5 days/week × 6 weeks)***<br>• Topical 5% 5-FU (e.g. BID × 3-6 weeks)***<br>• MAL- or ALA-PDT<br>• XRT† for nonsurgical candidates |
| **High-risk* lesions** | **High-risk* lesions** |
| • Mohs micrographic surgery<br>• Standard excision with 10+ mm margins$<br>• XRT† for nonsurgical candidates<br>• Adjuvant XRT (if perineural involvement) | |
| **Inoperable or metastatic#** | **Inoperable or metastatic#** |
| • Immune checkpoint inhibitors (e.g. cemiplimab) | • Hedgehog pathway inhibitors (e.g. vismodegib, sonidegib) |
| **Indications for Mohs micrographic surgery** | |
| • Lesions noted as "high-risk" (see Table 88.4)<br>• Site of positive margin on prior excision<br>• Underlying genetic syndrome (e.g. xeroderma pigmentosum, nevoid BCC syndrome) | |
| **See characteristics of such lesions in Table 88.4.*<br>***The cure rate with topical therapies is lower than with surgical therapies.*<br>****Dosing regimen should be adjusted based upon tolerance of side effects (e.g. crusting, erosive erythema).*<br>†*Excluding genitalia, hands, and feet.*<br>$*May be considered for select high-risk tumors, but the concern is the inability of complete margin assessment.*<br>#*Referral to an oncologist is also necessary.* | |

**Table 88.5 Common treatment options for basal cell carcinoma (BCC) and squamous cell carcinoma (SCC).** 5-FU, 5-fluorouracil; ALA, aminolevulinic acid; MAL, methylaminolevulinate; PDT, photodynamic therapy.

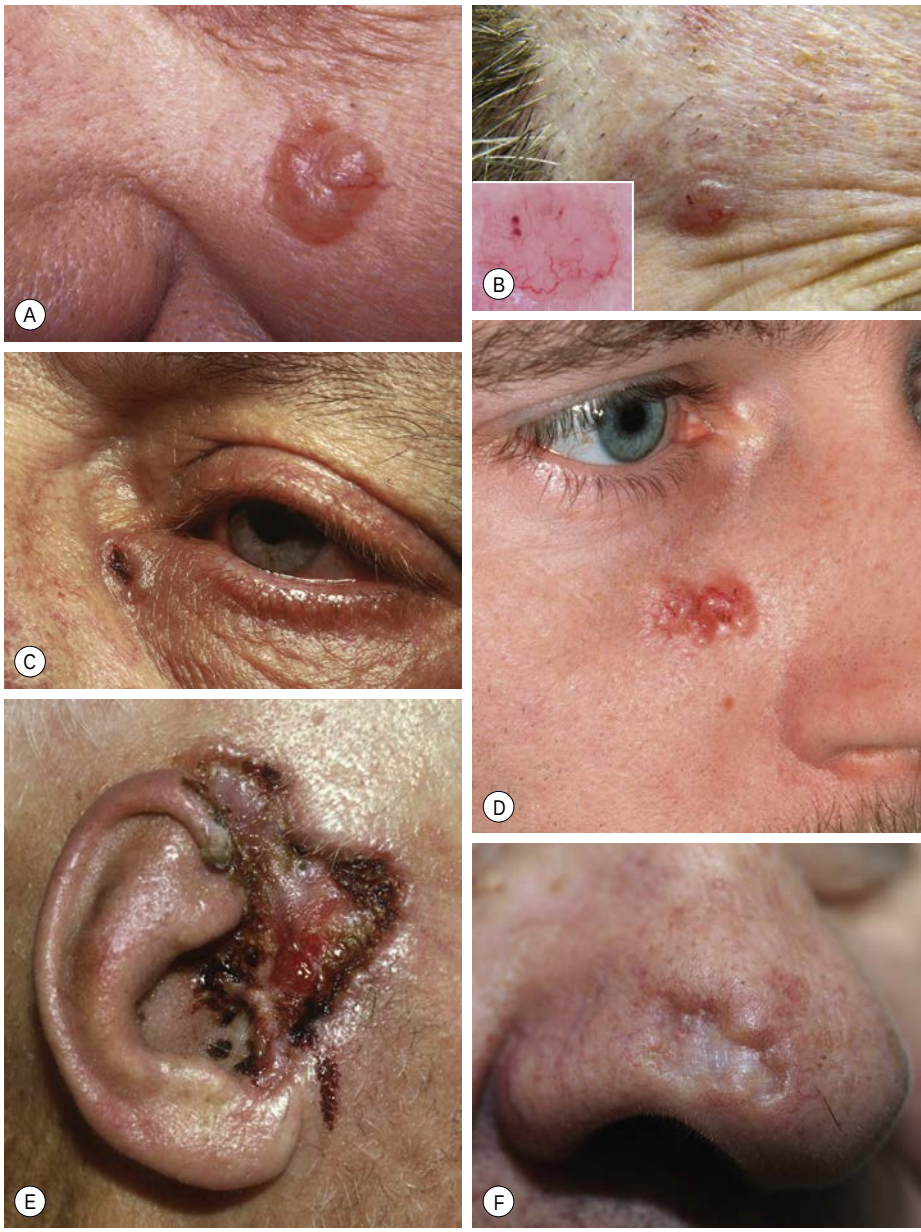


**Fig. 88.9 Clinical spectrum of nodular basal cell carcinoma (BCC). A, B** Translucent papulonodules with prominent telangiectasias on the infraorbital cheek (**A**) and forehead (**B**); on dermoscopy (**B**, inset) the arborizing telangiectasias are in sharp focus. **C** Classic presentation with a pearly rolled border and central hemorrhagic crust. **D** Larger plaque with rolled borders and multiple telangiectasias. **E** Nodulo-ulcerative tumor of the preauricular region with translucent rolled borders, most obvious at "noon." **F** Depressed scar on the nose. *A, Courtesy, Stanley J. Miller, MD; B, D, E, Courtesy, H. Peter Sawyer, MD; C, Courtesy, YDRSC; F, Courtesy, Kalman Watsky, MD.*

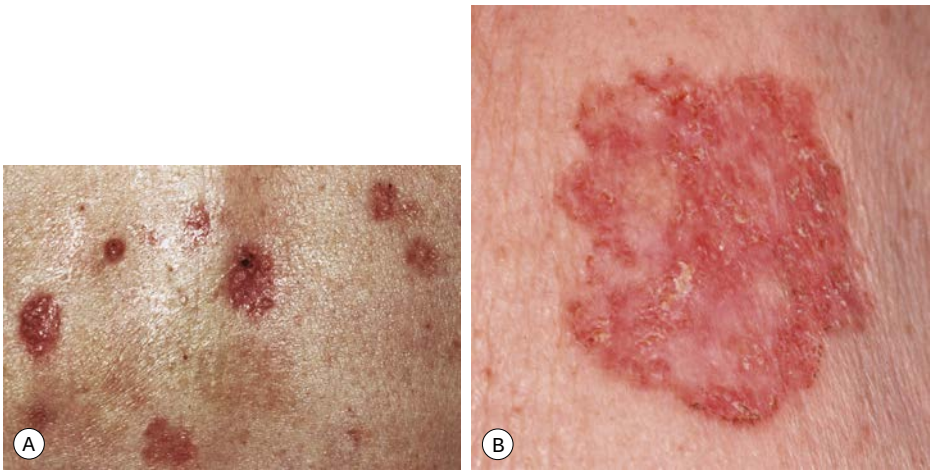


**Fig. 88.10 Superficial basal cell carcinoma (BCC). A** Numerous erythematous patches and thin plaques on the back of a man with a history of arsenic exposure decades previously. **B** A solitary large, thin, dark pink plaque. There are scattered areas of fine scaling and small foci of brown pigment within the rolled border. As a rule, these lesions are neither pruritic nor tender. *Courtesy, H. Peter Sawyer, MD.*




**Fig. 88.11 Pigmented basal cell carcinoma (BCC). A, B** Pigmented nodular BCCs with varying degrees of melanin pigmentation that may clinically resemble cutaneous melanoma. However, the glassy translucency, in concert with characteristic dermoscopic features such as arborizing telangiectasias and multiple blue-gray ovoid globules (**C**), point to the diagnosis of pigmented BCC. *A, Courtesy, Kalman Watsky, MD; B, Courtesy, H. Peter Sawyer, MD; C, Courtesy, Giuseppe Argenziano, MD.*

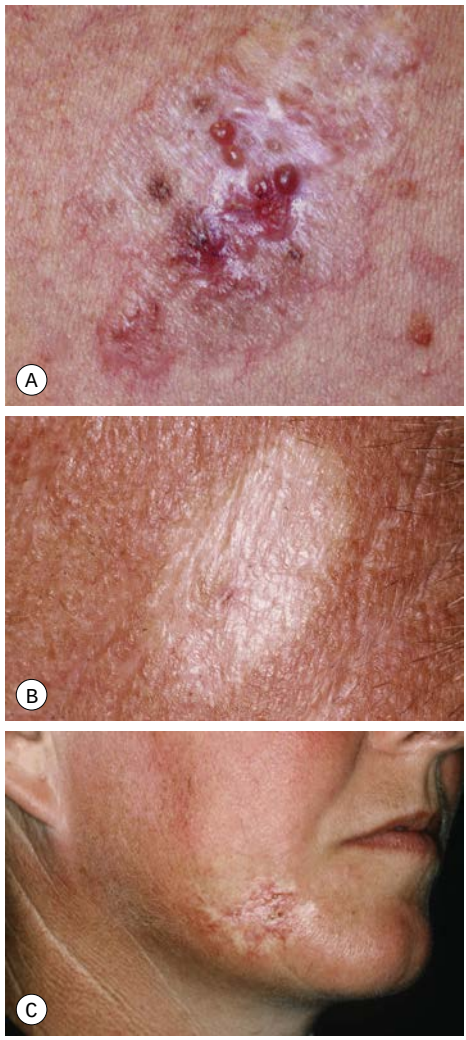


**Fig. 88.12 Morpheaform basal cell carcinoma (BCC). A** Recurrent tumor two years after microscopically controlled surgery; note the scar-like appearance with superimposed glassy pink and brown papules. **B** Oval hypopigmented firm plaque that resembles a scar (e.g. post electrodesiccation and curettage). While there is a light pink color between 6 and 9 o'clock, no translucency or rolled border is present. **C** A classic example with indistinct borders and scar-like appearance. *A, Courtesy, Darrell S. Rigel, MD; B, C Courtesy, H. Peter Sawyer, MD.*

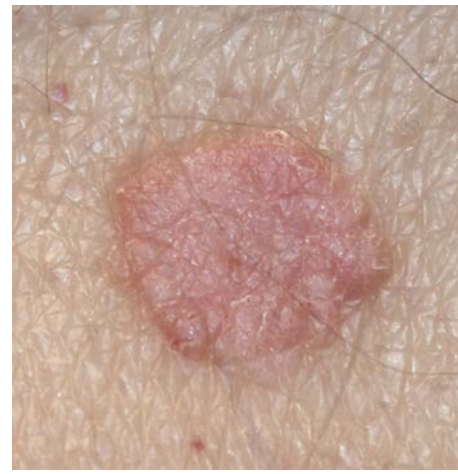

**Fig. 88.13 Fibroepithelial basal cell carcinoma (fibroepithelioma of Pinkus).** A soft, skin-colored to light pink, broad, sessile plaque on the lower back is a classic presentation for a fibroepithelial BCC. *Courtesy, Oscar R. Colegio, MD, PhD.*

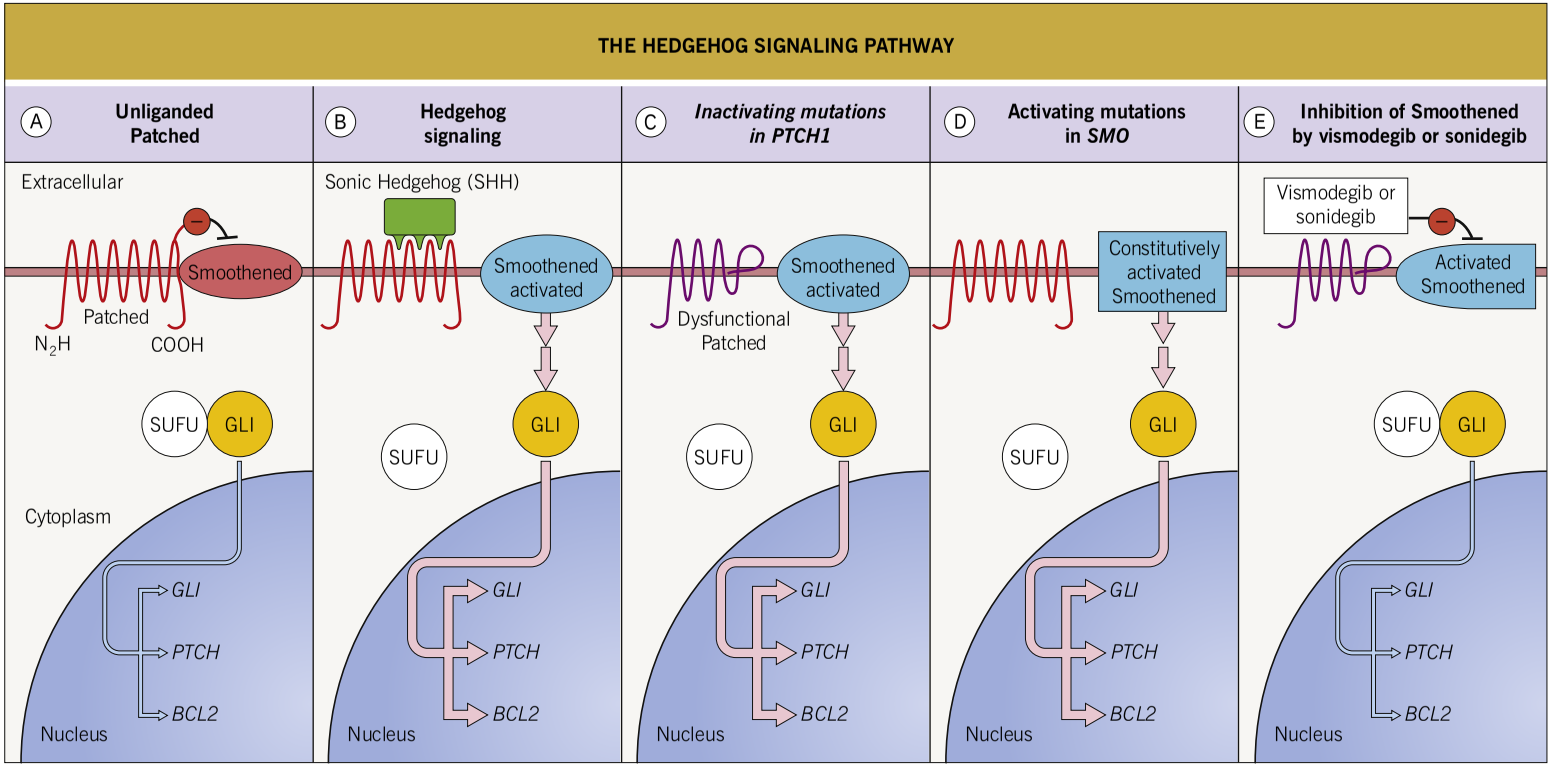


**eFig. 88.1 The hedgehog signaling pathway.** **A** Unbound Patched silences Smoothened (SMO) signaling. **B** As Hedgehog binds to its receptor Patched, the repression of SMO is removed and signals are transduced via GLI to the nucleus. **C** Inactivating mutations in *PTCH* lead to dysfunctional Patched and this simulates Hedgehog binding and results in constitutive activation of GLI and downstream target genes. **D** An activating mutation in *SMO* results in constitutive signaling to GLI and downstream target genes. Such mutations are detected in sporadic BCCs in which *PTCH1* is intact. **E** Vismodegib and sonidegib are inhibitors of SMO that have been used to treat patients with BCNS as well as metastatic or locally advanced BCCs. At least 50% of advanced BCCs develop resistance to vismodegib, commonly via acquiring mutations in *SMO*.

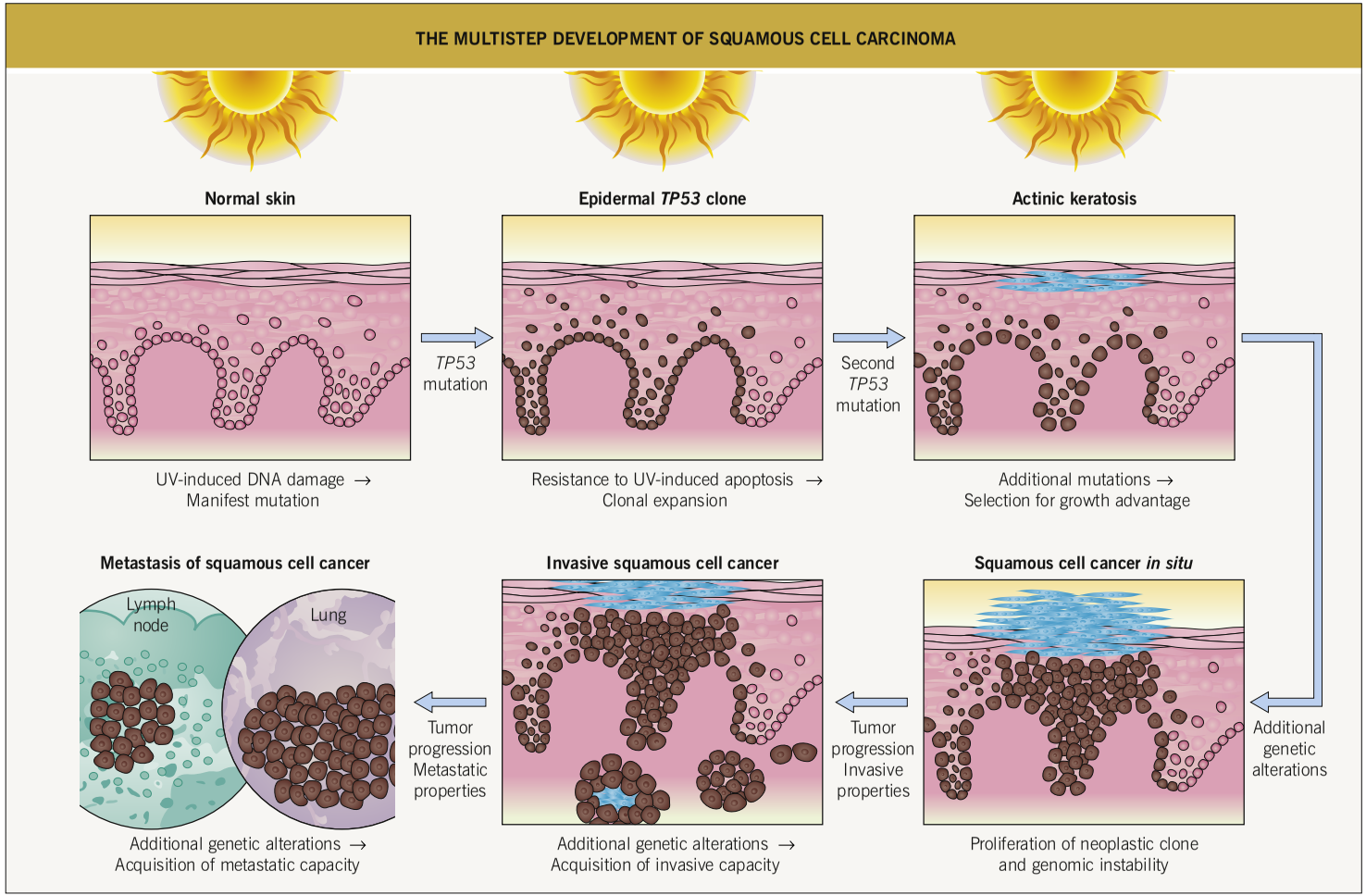


**eFig. 88.2 The multistep development of squamous cell carcinoma (SCC).** UV irradiation of normal skin induces mutations in keratinocytes and facilitates clonal expansion of keratinocytes with a mutated *TP53* gene. Additional mutations (including a second *TP53* mutation) that affect genes controlling proliferation, cell migration and cell death provide for selective growth advantage and cause genomic instability. The final result is metastatic tumor cells, capable of growing in regional lymph nodes and internal organs.










**eFig. 88.3 Actinic keratoses (AKs). A** Multiple hypertrophic AKs on the bald scalp with hypopigmentation at sites of previous treatment. **B** Pigmented AK on the cheek. **C** Actinic cheilitis presenting with erosions, scaling and leukoplakia of the lower vermilion lip. *A, Courtesy, H. Peter Sawyer, MD; B, Courtesy, Kalman Watsky, MD; C, Courtesy, Carl M. Allen, MD.*

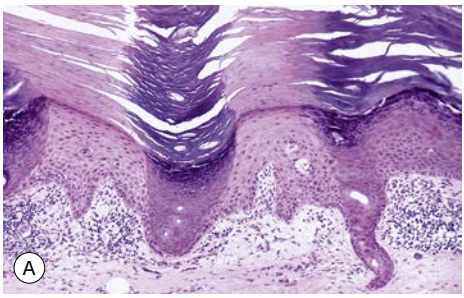


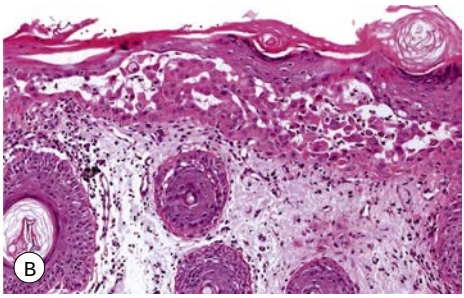


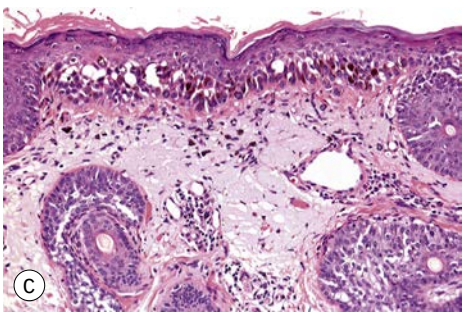


**eFig. 88.4 Histopathology of actinic keratoses (AKs). A** Hyperkeratotic AK with alternating pink and blue colors in the cornified layer; the pink-colored parakeratotic columns within the stratum corneum are located above the atypical keratinocytes in the spinous layer, while the blue-colored columns of orthohyperkeratosis are above the acrosyringia. Atypical epidermal keratinocytes also display a pinkish color that contrasts with the color of the basophilic normal keratinocytes of the acrosyringia. **B** Acantholytic variant with clefts within the stratum spinosum. **C** Pigmented AK with increased melanin pigmentation within the basal layer. Note the solar elastosis in the dermis. *Courtesy, Lorenzo Cerroni, MD.*




**eFig. 88.5 Squamous cell carcinomas *in situ,* Bowen disease type. A** Pink plaque with white scale and a hemorrhagic crust arising within photodamaged skin. **B** Dermoscopic findings of tiny dotted vessels in the upper half of the lesion combined with superficial scales. **C** Pigmented Bowen disease lesion, which may be clinically misdiagnosed as cutaneous melanoma. The pink depressed area is a biopsy site. *A, C, Courtesy, Kalman Watsky, MD; B, Courtesy, Iris Zalaudek, MD.*

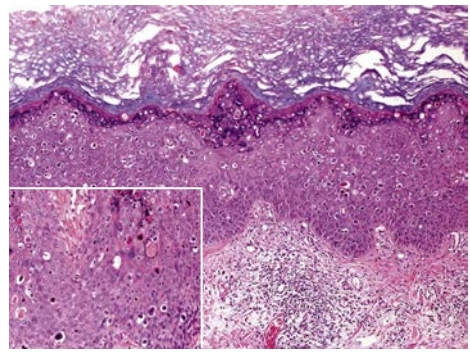

**eFig. 88.6 Histopathology of squamous cell carcinoma *in situ*, Bowen disease-type.** Irregular epidermal hyperplasia with atypical pleomorphic keratinocytes throughout the entire epidermal thickness. Note several necrotic keratinocytes (inset). *Courtesy, Lorenzo Cerroni, MD.*

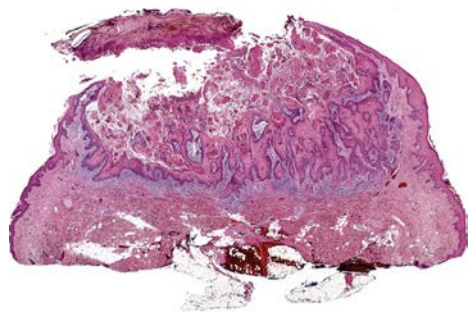

**eFig. 88.7 Histopathology of keratoacanthoma.** Scanning magnification of a stereotypical keratoacanthoma with a keratin-filled crater encompassed by epithelial lips. *Courtesy, Lorenzo Cerroni, MD.*

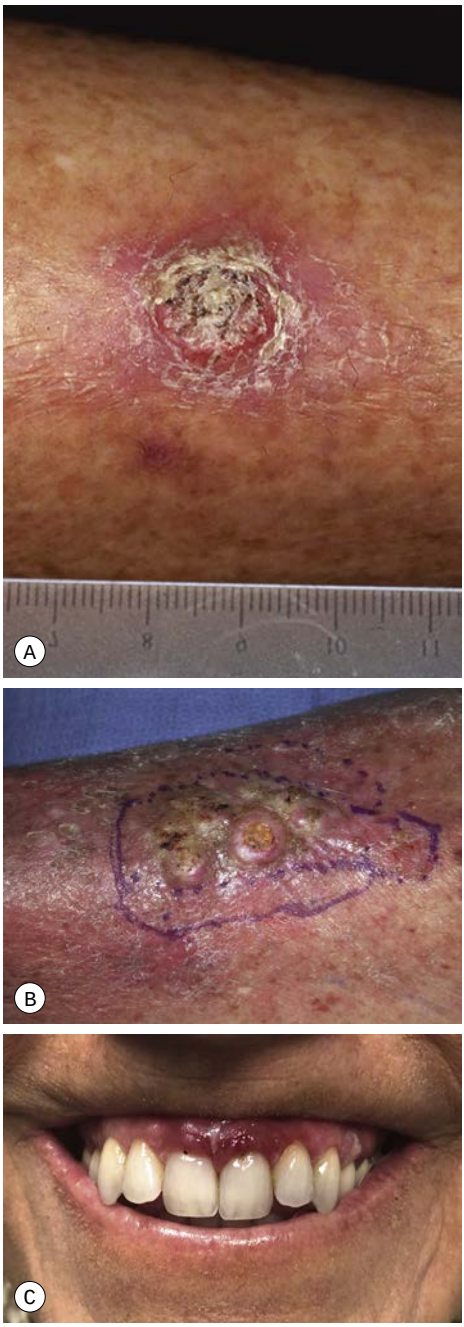


**eFig. 88.8 Squamous cell carcinomas (SCCs).** **A** Eroded and keratotic nodule that developed rapidly at the site of trauma on the shin in a patient with severe photodamage; this has also been described as a reactive process, termed "atypical squamous proliferation'. **B** Recurrent SCC in a patient who had received a solid organ transplant. **C** Gingival SCC presenting as an erythematous eroded plaque, initially misdiagnosed and treated as oral candidiasis. *A, C, Courtesy, Karynne O. Duncan, MD; B, Courtesy, John Carucci, MD.*

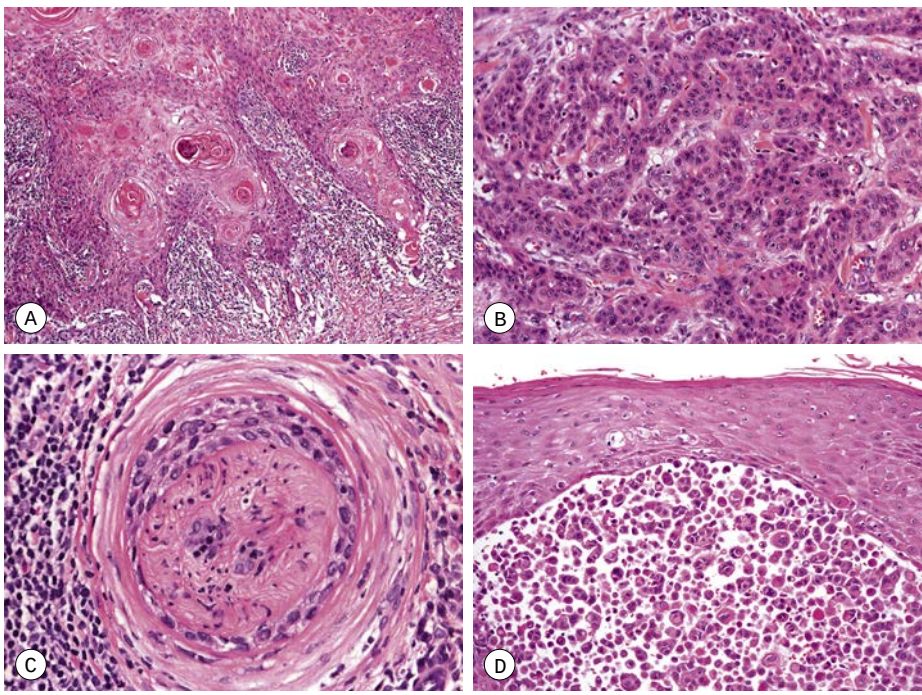


**eFig. 88.9 Squamous cell carcinoma (SCC): range of histopathologic findings.** **A** Well-differentiated SCC with numerous horn pearls (eosinophilic keratinization). **B** Poorly differentiated SCC with strands and cords of epithelial cells with prominent nuclear atypia and no signs of keratinization. **C** Perineural growth and neurotropism of a poorly differentiated SCC. **D** Acantholytic SCC characterized by epithelial aggregations composed of atypical keratinocytes with acantholysis. *Courtesy, Lorenzo Cerroni, MD.*




**eFig. 88.10 Basal cell nevus syndrome.** **A** Numerous small and several large nodular BCCs on the face. **B** Three superficial BCCs and one nodular BCC on the chest of a younger man. **C** Frontal bossing and hypertelorism, with multiple scars from previous excisions of BCCs. **D** Multiple palmar pits. *A–C, Courtesy, H. Peter Sawyer, MD; D, Courtesy, Jeffrey P. Callen, MD.*

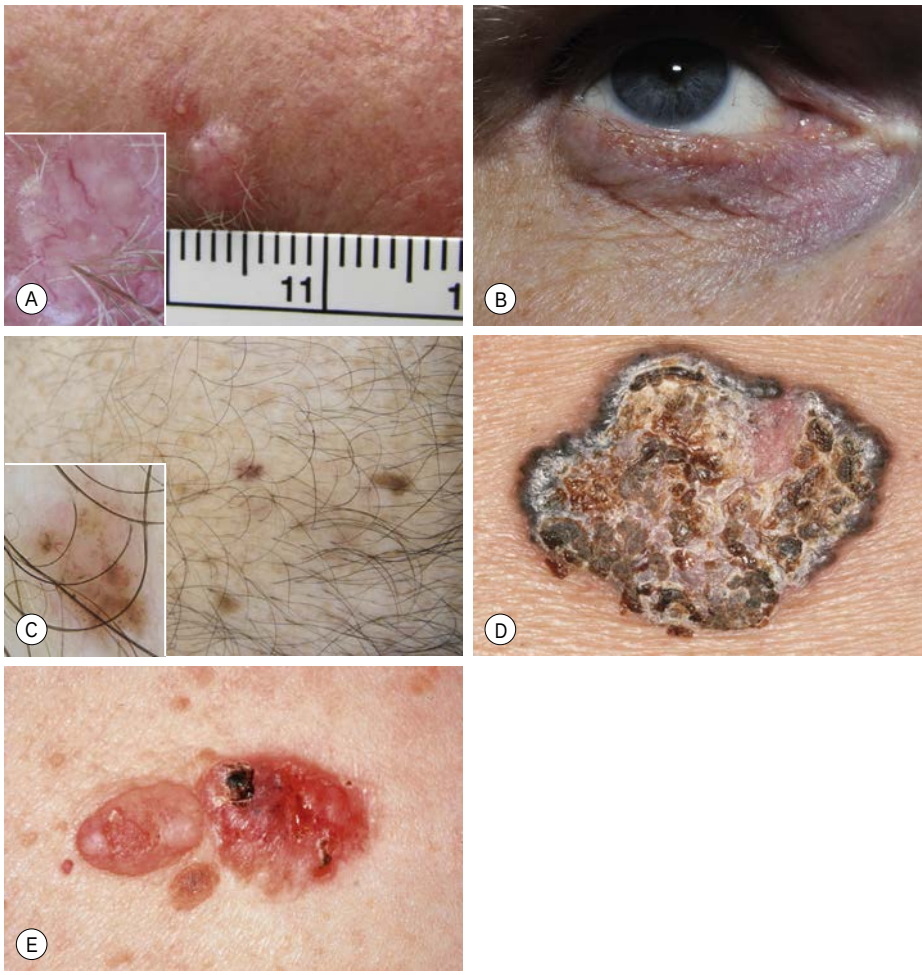


**eFig. 88.11 Basal cell carcinomas (BCCs) – clinical variants. A, B** *Nodular* BCCs. Pink papule above the eyebrow (**A**). Dermoscopy (inset) shows telangiectatic vessels, erythema, and cystic spaces. Subtle papules of BCC of the eyelid margin (**B**). **C, D** *Pigmented* BCCs. Pigmented "nevoid" BCCs of the abdomen in a patient with basal cell nevus syndrome (**C**); there are pigment globules, maple leaf structures, and one arborizing telangiectasia as well as a pink background color (inset). In addition to the admixture of scale and hemorrhagic crusts centrally, there is a translucent and black rolled border superiorly (**D**). **E** *Fibroepithelial* BCC (fibroepithelioma of Pinkus). This soft, skin-colored to light pink, broad, sessile nodule on the lower back representing a fibroepithelial BCC is adjacent to a classic nodular BCC. *A, C–E, Courtesy, H. Peter Sawyer, MD; B, Courtesy, Kalman Watsky, MD.*

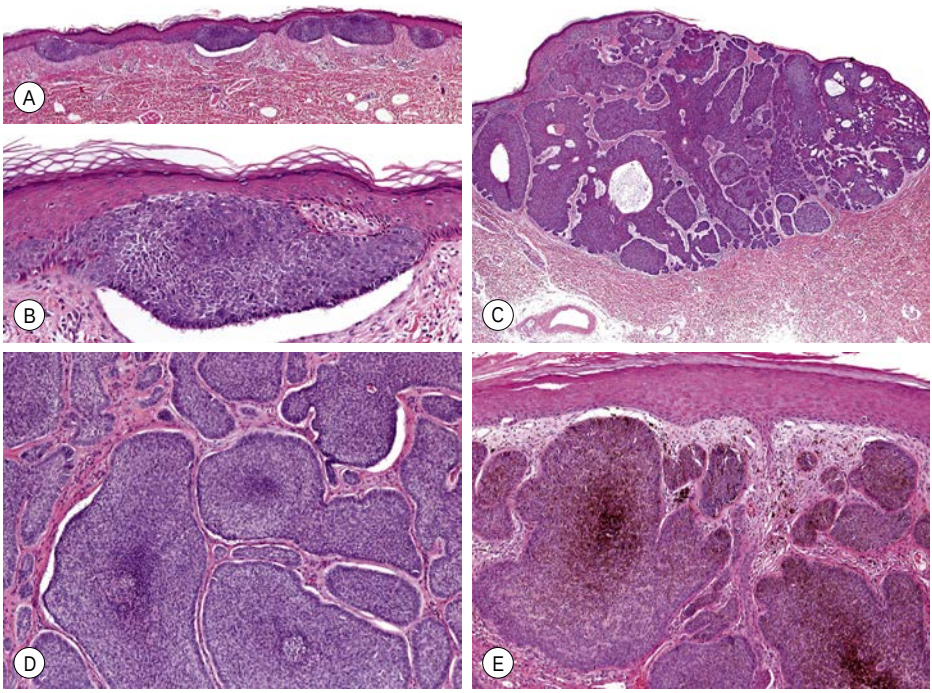


**eFig. 88.12 Basal cell carcinoma (BCC) – range of histopathologic findings.** **A** *Superficial* type with a few basaloid buds and stromal retraction spaces. **B** A single basaloid aggregation with all the morphologic findings (e.g. peripheral palisading of nuclei, retraction between the tumor and surrounding stroma) characteristic of a *superficial* BCC. **C** *Nodular* BCC with large, partly confluent aggregations of basaloid cells as well as a few cystic spaces. **D** Nodular aggregations of basaloid cells with peripheral palisading and retraction spaces commonly seen in conventional *nodular* BCCs. **E** *Pigmented* BCC with nodular aggregations of basaloid cells that contain brown melanin pigment. *Courtesy, Lorenzo Cerroni, MD.*

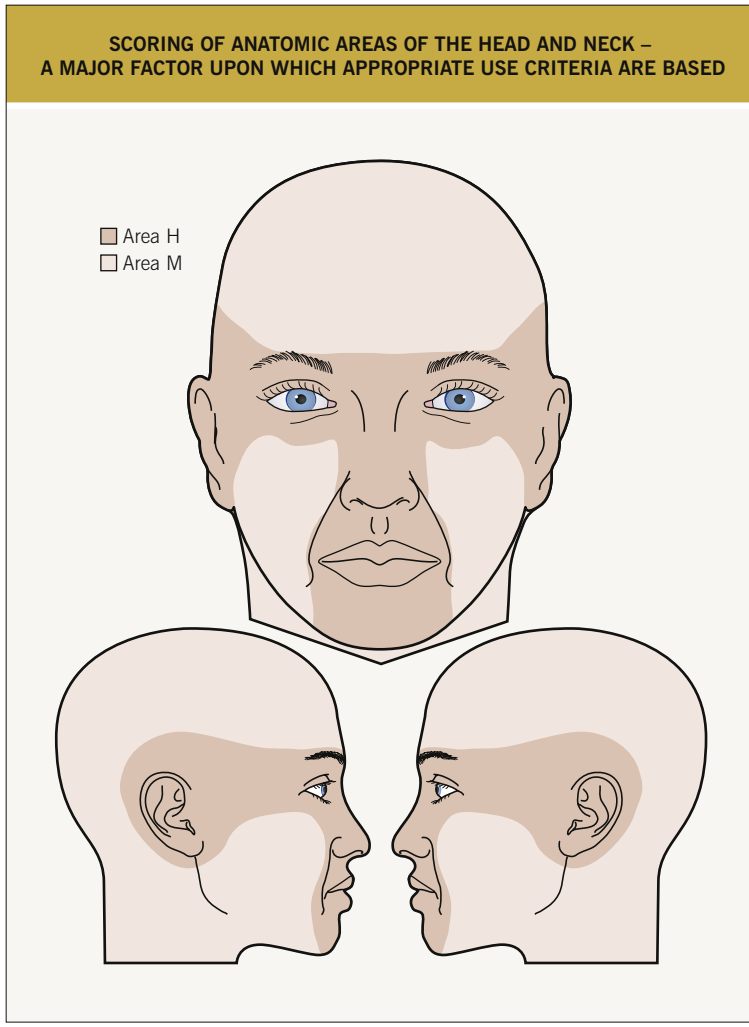


**eFig. 88.13 Scoring of anatomic area of the head and neck – a major factor upon which appropriate use criteria are based.** Area H represents the anatomic sites with the highest risk for recurrence and the greatest need for tissue sparing, followed by Area M. The majority of the trunk and extremities is labelled as Area L (lowest need for tissue sparing and risk of recurrence), with the hand, foot, ankle, nail unit, nipple/areola, and anogenital region representing additional Area H sites and the shins an Area M site.

| DIAGNOSTIC CRITERIA FOR BASAL CELL NEVUS SYNDROME (BCNS) |
|---|
| **Major criteria** |
| 1. More than two BCCs or one BCC before the age of 20 years<br>2. Odontogenic keratocysts of the jaw (proven by histology)<br>3. Three or more palmar or plantar pits<br>4. Bilamellar calcification of the falx cerebri<br>5. Bifid, fused or markedly splayed ribs<br>6. First-degree relative with BCNS |
| **Minor criteria** |
| 1. Macrocephaly (determined after adjustment for height)<br>2. Congenital malformations: cleft lip or palate; frontal bossing; "coarse face"; moderate or severe hypertelorism<br>3. Other skeletal abnormalities: Sprengel deformity*; marked pectus deformity; marked syndactyly of the digits<br>4. Radiographic abnormalities: bridging of the sella turcica; vertebral anomalies such as hemivertebrae and fusion or elongation of the vertebral bodies; modeling defects of the hands and feet; flame-shaped lucencies of the hands or feet<br>5. Bilateral ovarian fibromas<br>6. Medulloblastoma |
| **Unilateral elevation of smaller-sized scapula.* |

**eTable 88.1 Diagnostic criteria for basal cell nevus syndrome (BCNS).** The diagnosis of BCNS requires *two major* or *one major and two minor* criteria. *Adapted from Kimonis VE, Goldstein AM, Pastakia B, et al. Clinical manifestations in 105 persons with nevoid basal cell carcinoma syndrome. Am J Med Genet 1997;69:299–308.*

| BASAL CELL CARCINOMA (BCC), SQUAMOUS CELL CARCINOMA (SCC), AND KERATOACANTHOMA (KA) – CLINICAL DIFFERENTIAL DIAGNOSES | | | |
|---|---|---|---|
| | **BCC** | **SCC** | **KA** |
| **Benign and malignant neoplasms and reactive disorders with pseudoepitheliomatous hyperplasia** | | | |
| Seborrheic keratosis, including inflamed or irritated | | √ | |
| Lichen planus-like keratosis | √ | √ | |
| Verruca vulgaris, especially periungual | | √ | √ |
| Amelanotic melanoma* | √ | √ | |
| Merkel cell carcinoma | √ | √ | |
| Atypical fibroxanthoma | | √ | |
| Prurigo nodularis | | √ | √ |
| Hypertrophic lichen planus | | √ | |
| Hypertrophic lupus erythematosus | | √ | √ |
| **Additional entities** | | | |
| Cysts, especially inflamed or proliferating variant | | √ | |
| Adnexal carcinomas | √ | √ | |
| Lymphoma cutis, especially ALCL mimicking SCC | | √ | |
| KA-like lesions in cutaneous ALCL and in LyP | | √ | √ |
| DFSP, cutaneous leiomyosarcoma | | √ | |
| Cutaneous metastases from visceral carcinomas | √ | √ | √ |
| Mammary and extramammary Paget disease | √ | √ | |
| Epithelioid sarcoma | | √ | |
| Verrucous melanoma | | √ | √ |
| Molluscum contagiosum | | | √ |
| **Pigmented variants of BCC and SCC can also be confused with melanoma.* | | | |

**eTable 88.2 Basal cell carcinoma (BCC), squamous cell carcinoma (SCC), and keratoacanthoma (KA) – clinical differential diagnoses.** ALCL, anaplastic large cell lymphoma; DFSP, dermatofibrosarcoma protuberans; LyP, lymphomatoid papulosis.

| SIDE EFFECTS OF VISMODEGIB AND SONIDEGIB | |
|---|---|
| **Common** | |
| • Dysguesia* (>40% of patients) | • Nausea, reduced appetite, and weight loss |
| • Muscle spasms | • Diarrhea |
| • Alopecia | • Fatigue |
| **Less common** | |
| • SCCs, including phenotypic switch of BCC to SCC | • Keratoacanthomas |
| • Cough | • Amenorrhea |
| • Congestive heart failure | • Hyponatremia |
| • Pneumonia | • Arthralgia |
| • Thromboembolism | • Pruritus |
| *Due to altered cell turnover of adult tongue epithelium. | |

**eTable 88.3 Side effects of vismodegib and sonidegib.** Both medications can lead to birth defects or fetal death. *Adapted from Kimonis VE, Goldstein AM, Pastakia B, et al. Clinical manifestations in 105 persons with nevoid basal cell carcinoma syndrome. Am J Med Genet 1997;69:299–308.*

# Benign Epithelial Tumors and Proliferations

# 89

The entities in this chapter can be further classified according to the algorithm in Fig. 89.1.

## COMMON

### Seborrheic Keratosis

- Begin to appear during the 4th decade of life and then gradually increase in number.
- Macular, papular, or verrucous; colors vary from white to black but most commonly brown.
- Typically has a "stuck-on" appearance with a smooth to verrucous surface (Fig. 89.2).
- Spares the palms, soles, and mucosal surfaces.
- May resemble a melanoma clinically but has no pigment network (by dermoscopy) and has horn pseudocysts.
- Sudden appearance of multiple lesions may be associated with internal malignancy (*sign of Leser–Trélat)* or erythroderma; the former may also be associated with skin tags, irritated seborrheic keratoses, tripe palms, and acanthosis nigricans.
- Histopathology: a spectrum of different architectures, most commonly acanthotic, papillomatous and hyperkeratotic, or irritated (Fig. 89.3).
- Variants:
  - **Dermatosis papulosa nigra** (Fig. 89.4): common in dark-skinned individuals; 1- to 5-mm hyperpigmented papules on the face
  - **Stucco keratosis** (Fig. 89.5): 1- to 4-mm gray-white papules on the lower extremities (especially dorsal feet and ankles) of older adults

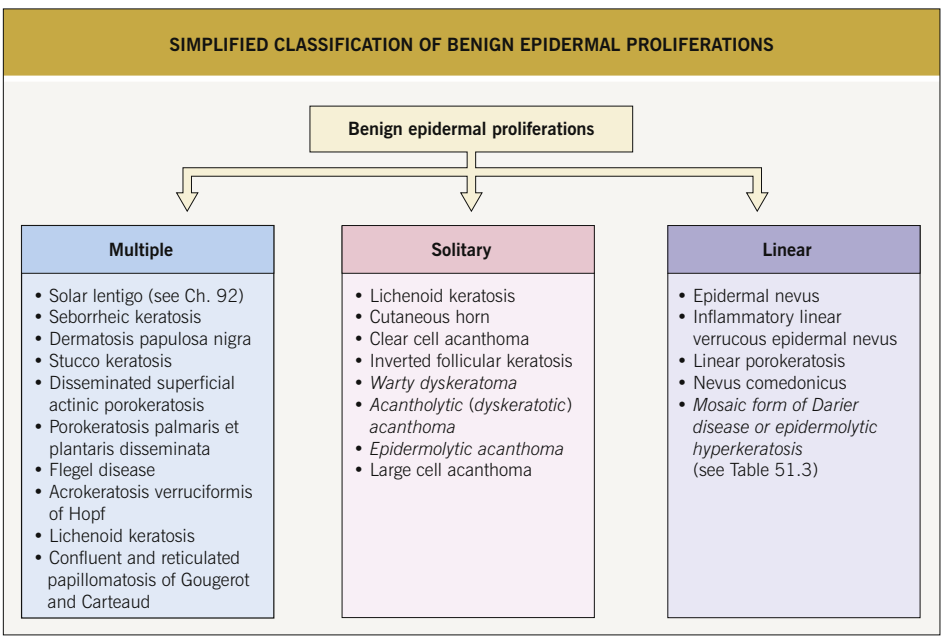


**Fig. 89.1 Simplified classification of benign epidermal proliferations.** Although the term solitary lichenoid keratosis is sometimes used, patients may develop multiple lesions, especially those with skin phototypes I or II and significant actinic damage. Entities in *italics* are not covered. *Courtesy, Luis Requena, MD.*

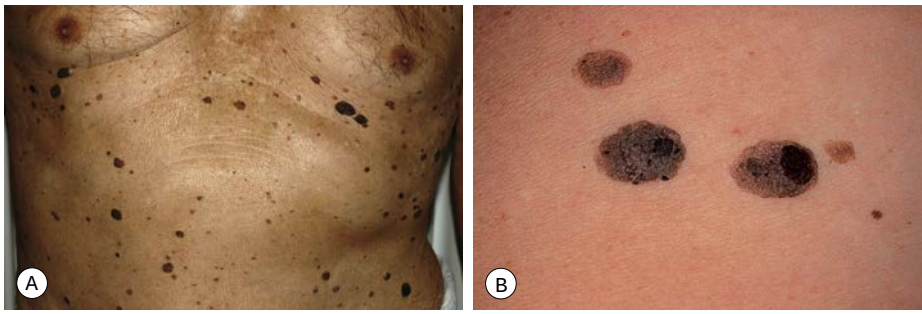

**Fig. 89.2 Seborrheic keratoses. A** Multiple seborrheic keratoses of the anterior trunk that vary in size and color. **B** Sharply demarcated pigmented papules and plaques with a papillomatous surface and horn pseudocysts. Note the "stuck-on" appearance. *B, Courtesy, YDRSC.*

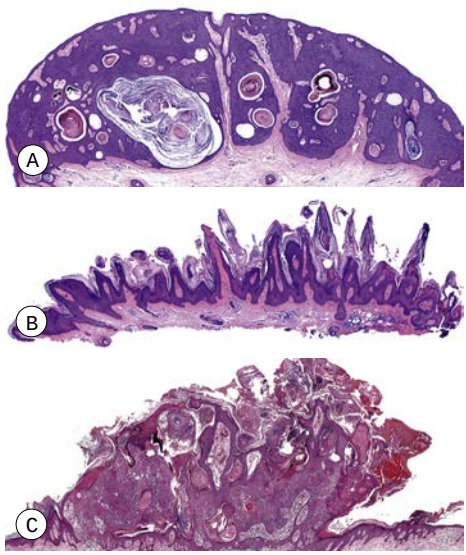

**Fig. 89.3 Seborrheic keratoses – spectrum of histologic subtypes. A** Acanthotic type with lobular hyperplasia with prominent horn cysts. **B** Papillomatous or hyperkeratotic type with church spires of papillomatosis and hyperkeratosis. **C** Irritated seborrheic keratosis. Exophytic lesion with papillomatosis, hyperkeratosis, hemorrhagic crust, and dermal inflammation. *A, B, Courtesy, Luis Requena, MD; C, Courtesy, Lorenzo Cerroni, MD.*



**Fig. 89.4 Dermatosis papulosa nigra.** Multiple hyperpigmented papules with typical location on the cheeks. *Courtesy, Luis Requena, MD.*



**Fig. 89.5 Stucco keratoses.** Multiple gray-white keratotic papules, primarily on the ankle and dorsal foot.

– **Inverted follicular keratosis**: endophytic variant of seborrheic keratosis; tan to pink papule, typically on the face of adults

## Cutaneous Horn

• Clinical term for marked hyperkeratosis arising from a papule or nodule (Fig. 89.6).

• The base of the lesion most commonly represents an actinic keratosis or wart, but of the entities in this chapter, a seborrheic keratosis is most common; sometimes the base is a squamous cell carcinoma.



ALGrawany







**Fig. 89.6 Cutaneous horn. A** This cutaneous horn arose from an actinic keratosis. **B** Striking column of hyperkeratosis with hyperplasia of the underlying epidermis. *A, Courtesy, YDRSC; B, Courtesy, Luis Requena, MD.*

## Solitary Lichenoid Keratosis/Lichen Planus-Like Keratosis

- Pink to pink-brown papule or plaque (Fig. 89.7); arises in chronically sun-damaged skin, most commonly on the chest, arms, and shins.

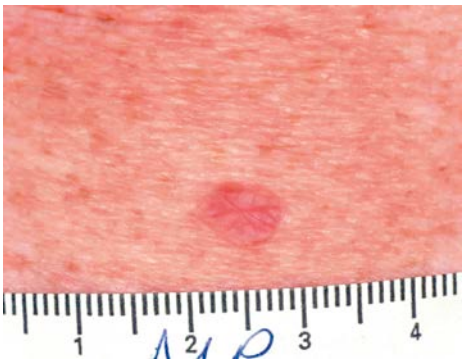

**Fig. 89.7 Lichenoid keratosis.** Pink, flat-topped papule in a fair-skinned individual. *Courtesy, Jean L. Bolognia, MD.*

- Occasionally multiple.
- Clinically mimics basal cell carcinoma or Bowen disease.

## Porokeratosis

- Several different types (Table 89.1; Fig. 89.8).
- All have a distinctive thread-like border of scale that corresponds histopathologically to the cornoid lamella (column of parakeratosis histologically).
- The most common form, disseminated superficial actinic porokeratosis (DSAP), is sometimes misdiagnosed as multiple actinic keratoses.

## Confluent and Reticulated Papillomatosis (of Gougerot and Carteaud)

- Onset during puberty.
- Scaly to verrucous hyperpigmented plaques.
- Centrally confluent and reticulated at periphery (Fig. 89.9).
- Favors neck, central chest, submammary regions.
- **Rx:** oral tetracyclines (e.g. minocycline).

# LESS COMMON

## Clear Cell Acanthoma

- Red, shiny papule or plaque, sometimes with a peripheral collarette of scale (Fig. 89.10).
- Favors the leg.
- Histopathology: acanthosis of characteristically well-demarcated pale or clear keratinocytes with overlying parakeratosis.

| CLINICAL VARIANTS OF POROKERATOSIS | |
|---|---|
| **Type** | **Clinical features** |
| Porokeratosis of Mibelli | Plaque that arises during infancy or childhood, usually on a distal extremity; usually several cm in diameter |
| Disseminated superficial actinic porokeratosis | Pink to brown papules and plaques with peripheral scale; arise in sun-exposed sites, especially the forearms and shins; usually measure from a few mm to 1.5 cm; in some patients, autosomal dominant inheritance |
| Large-sized lesions | Usually in immunocompromised patients, especially solid organ transplant recipients; in sun-exposed areas |
| Linear porokeratosis | Streaks along the lines of Blaschko; arise during infancy or childhood<br>Risk of development of squamous cell carcinoma |
| Punctate porokeratosis | Palmoplantar papules that measure 1 to 2 mm in diameter; arise during adolescence or adulthood |
| Porokeratosis palmaris et plantaris et disseminata | Palmoplantar papules in addition to involvement of the trunk, extremities, and even mucous membranes; onset during childhood or adolescence |
| Porokeratosis ptychotropica | Red to brown papules or plaques in the intergluteal cleft and on the buttocks; there may be coalescence of lesions centrally with scattered papules peripherally |

**Table 89.1 Clinical variants of porokeratosis.** There have been scattered case reports of eruptive disseminated porokeratosis in which numerous, inflamed keratoses were thought to be a sign of associated malignancy.

### Large Cell Acanthoma

- Variably colored papule or plaque in sun-exposed sites in older individuals (Fig. 89.11).
- A variant of actinic keratosis and seborrheic keratosis.
- Histopathology: orthokeratosis overlying a thin epidermis composed of enlarged keratinocytes.

### Flegel Disease (Hyperkeratosis Lenticularis Perstans)

- Rare; may have an autosomal dominant inheritance.
- Onset usually during adulthood.
- Lentil-like keratotic papules on the distal lower extremities (Fig. 89.12).

### Acrokeratosis Verruciformis

- Autosomal dominant disorder; sometimes associated with Darier disease.
- Multiple, skin-colored, flat-wart-like papules on dorsal aspect of hands and feet (see Fig. 48.10).
- Benign neoplasm of keratinocytes showing papillomatosis with overlying hyperkeratosis in "church spires".
- May have *ATP2A2* gene mutation.

## LINEAR

### Epidermal Nevus (See Ch. 51)

- Hyperpigmented (rarely hypopigmented) papules and plaques (Fig. 89.13) along lines of Blaschko.
- Verrucous, keratotic, velvety or barely elevated.
- May have a sebaceous or other adnexal component (i.e. nevus sebaceus), especially if on the scalp or face.
- Can be caused by mosaicism for mutations in *FGFR3* (fibroblast growth factor receptor-3), *PIK3CA*, *HRAS* (also in nevus sebaceus), keratin 1 or 10 (if histologic finding of epidermolytic hyperkeratosis), and other genes.
- May be associated with extracutaneous manifestations (see Ch. 51).

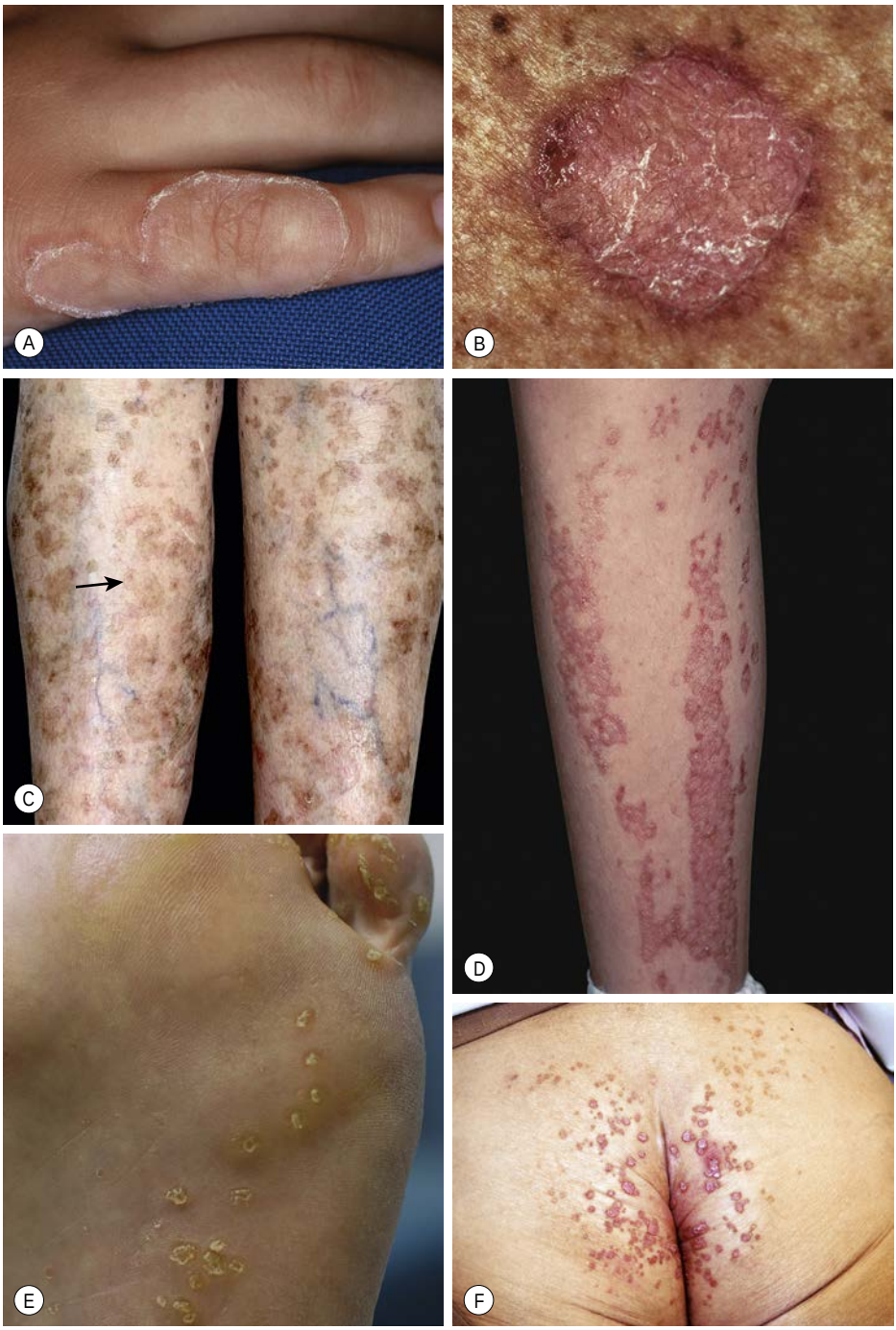


**Fig. 89.8 Porokeratoses.** **A** Porokeratosis of Mibelli on the hand of a child. **B** Actinic porokeratosis in a renal transplant patient with significant solar damage. Note the narrow, elevated rim. **C** Multiple lesions of disseminated superficial actinic porokeratosis (DSAP). Note the hyperpigmented, peripheral keratotic edge (black arrow) which is where the biopsy should be obtained in order to see the cornoid lamellae; lesions can range in color from light brown to pink. **D** Several streaks of linear porokeratosis on the lower extremity. **E** Multiple keratotic papules on the plantar surface due to punctate porokeratosis. **F** Porokeratosis ptychotropica with pink to brown papules localized to the intergluteal cleft and buttocks. *A, Courtesy, YDRSC; B, D, Courtesy, Jean L. Bolognia, MD; C, Courtesy, Karynne O. Duncan, MD; E, Courtesy, Kalman Watsky, MD; F, Courtesy, César Cosme Álvarez Cuesta, MD.*



**Fig. 89.9 Confluent and reticulated papillomatosis (CARP).** Multiple hyperpigmented papules that are confluent centrally and assume a reticulated pattern laterally. *Courtesy, Julie V. Schaffer, MD.*



**Fig. 89.10 Clear cell acanthoma.** Well-demarcated, dark, red, shiny papule with a wafer-like collarette of scale. *Courtesy, Karynne O. Duncan, MD.*



**Fig. 89.11 Large cell acanthoma.** Well-demarcated, thin, pink-brown plaque. *Courtesy, Luis Requena, MD.*



**Fig. 89.12 Flegel disease.** Multiple symmetric hyperpigmented keratotic papules are present on the shins. *Courtesy, Luis Requena, MD.*



**Fig. 89.13 Epidermal nevus.** Obvious papillomatosis in a single thin linear plaque; this is the most common clinical presentation. *Courtesy, Julie V. Schaffer, MD.*

## Inflammatory Linear Verrucous Epidermal Nevus

- Linear, pruritic, psoriasiform (erythematous with scale) plaques, usually on an extremity (see Fig. 51.2C).
- 75% appear before age 5 years.
- **DDx:** primarily linear psoriasis (see Ch. 6).

## Nevus Comedonicus

- Linear plaques composed of grouped comedones; may develop inflammatory acneiform lesions (see Fig. 51.3G).
- 50% present at birth; otherwise, generally appear before age 10 years.
- May be due to mosaicism for a mutation in *FGFR2*.

For further information see Ch. 109 from *Dermatology, Fourth Edition*.



**For additional online figures visit www.expertconsult.com**



**eFig. 89.1 Porokeratosis – clinical variants.** Multiple lesions of disseminated superficial actinic porokeratosis (DSAP) with obvious peripheral keratotic rims; lesions can range in color from light brown to pink. *Courtesy, Jean L. Bolognia, MD.*



**eFig. 89.2 Solitary epidermolytic acanthoma.** Keratotic papulonodule on the chest.




**eFig. 89.3 Epidermal nevi. A** Larger sized verrucous hyperpigmented plaque. **B** Multiple verrucous hyperpigmented plaques that clearly follow the lines of Blaschko. Note the midline demarcation. *A, Courtesy, Kalman Watsky, MD; B, Courtesy, Kathryn Schwarzenberger, MD.*



**eFig. 89.4 Inflammatory linear verrucous epidermal nevus (ILVEN).** Linear erythematous scaly plaques on the medial aspect of the right thigh. Some of the lesions have a psoriasiform appearance.



**eFig. 89.6 Confluent and reticulated papillomatosis (CARP).** Multiple thin hyperpigmented papules of the chest and neck that have become confluent centrally and assume a reticulated pattern peripherally. *Courtesy, Lorenzo Cerroni, MD.*

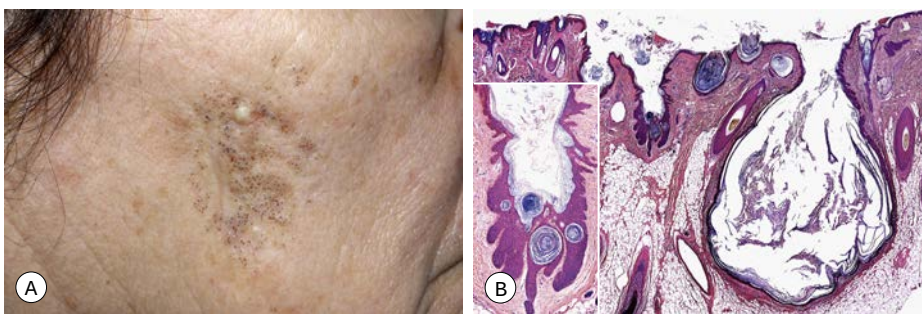


**eFig. 89.5 Nevus comedonicus. A** Numerous comedones within a circumscribed area on the right cheek. **B** Dilated infundibula filled with orthokeratotic keratin. Occasionally, the wall of the comedo will display epithelial hyperplasia (inset). *A, Courtesy, Lorenzo Cerroni, MD.*



**eFig. 89.7 Large lesion of porokeratosis on an extremity in an immunocompetent individual.** Distally, a double-edged border of scale is appreciable.

# Cysts 90

## Introduction

- Variably sized papules or nodules.
- Cysts can be divided into true cysts with an epithelial lining (histologically and sometimes visible clinically) and false cysts without such a lining.
- Appreciation of the actual size of the cyst often requires palpation.
- Different types of cysts often have characteristic anatomic locations and histologic features.
- Treatment of true cysts (if symptomatic) is primarily surgical.
- Congenital cysts (e.g. dermoid, branchial cleft, omphalomesenteric duct) are covered in Ch. 53.

## True Cysts – Common

### Epidermoid Cyst (Epidermoid Inclusion Cyst [EIC], "Sebaceous Cyst", Epidermal Cyst)

- Most commonly on the face and the upper trunk; skin-colored to yellow-white unless inflamed; size varies from a few millimeters to several centimeters.
- A visible comedonal-like opening or pore (resembles a blackhead) may be seen on the surface of the papule or nodule (Fig. 90.1A).
- A soft cheese-like, sometimes malodorous, material composed primarily of keratin can usually be expressed from the opening.
- Cyst contents may rupture into the dermis, eliciting an acute and chronic inflammatory reaction, leading to significant redness and pain; this inflammation is often confused with a bacterial infection (Fig. 90.1B).
- Most commonly sporadic; multiple lesions rarely associated with Gardner syndrome or Gorlin syndrome. Facial cysts may also develop in patients receiving targeted oncologic drugs, e.g. selective BRAF inhibitors.
- **DDx:** see Fig. 95.18.
- **Rx:** *inflamed* lesions: if fluctuant, can be incised and drained ± packed with gauze (a wick); if non-fluctuant, can be injected with intralesional CS; *non-inflamed* ("cold") lesions can be excised surgically but may result in a significant scar.

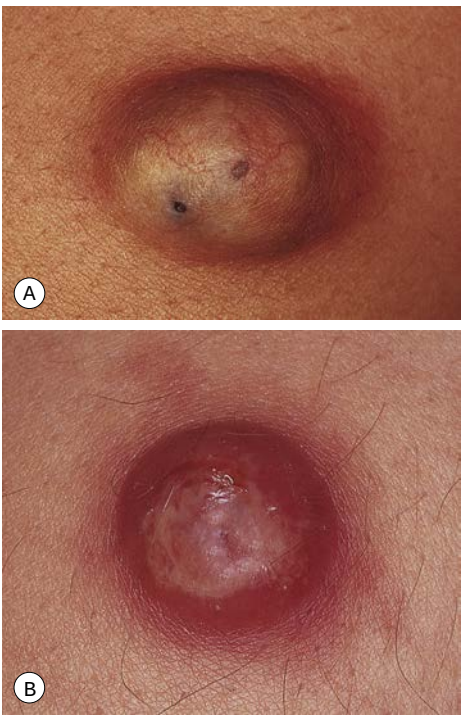


**Fig. 90.1 Epidermoid inclusion cysts.** **A** Typical clinical appearance of an epidermoid inclusion cyst with a yellowish hue. Two pores are present in this example. **B** Painful inflammatory reactions to cyst rupture are a frequent cause for presentation to a physician. Culture will often prove these lesions to be sterile, even if draining pus. Antibiotic treatment can be helpful due to their anti-inflammatory effects. *A, Courtesy, YDRSC; B, Courtesy, Mary S. Stone, MD.*



**Fig. 90.2 Milia.** Tiny (1–2 mm), white, dome-shaped papules on the face. *Courtesy, YDRSC.*

| CONDITIONS ASSOCIATED WITH MULTIPLE MILIA |
|---|
| • Trauma, e.g. burn |
| • Bullous diseases |
| – Metabolic (e.g. porphyria cutanea tarda) |
| – Autoimmune (e.g. epidermolysis bullosa acquisita >> bullous pemphigoid) |
| – Inherited (e.g. epidermolysis bullosa) |
| – Exposures (e.g. poison ivy) |
| • Other genodermatoses (e.g. Bazex–Dupré–Christol syndrome) |
| • Follicular mycosis fungoides |

**Table 90.1 Conditions associated with multiple milia.**

## Milium (Milia – Plural)

• A small, superficial (1–2 mm) epidermoid cyst that is white in color and is sometimes confused with a whitehead (Fig. 90.2); occasionally they are grouped.
• Occurs most frequently on the central face, especially the periorbital region; seen in both children and adults.
• Commonly observed on the face in newborns; in this setting, they often resolve spontaneously.
• The majority of patients with multiple facial milia have no underlying condition; however, there may be a secondary cause (Table 90.1).
• **DDx:** whitehead (closed comedone), syringoma.
• **Rx:** because a milium lies beneath intact epidermis, the lesion must be punctured with a needle or sharp blade (e.g. #11) in order to express the keratin contents.



**Fig. 90.3 Pilar cyst.** A non-inflamed pilar cyst is skin-colored, mobile, and has a smooth surface. *Courtesy, Mary S. Stone, MD.*

## Pilar Cyst (Tricholemmal Cyst, Wen)

• Most common location is the scalp; sometimes there is associated overlying alopecia (Fig. 90.3).
• Solitary or multiple relatively firm nodules.
• May be inherited (autosomal dominant).
• Surgical removal is easier than for an EIC because less dissection from surrounding normal tissue is required; a small incision with lateral pressure may be all that is necessary.

## Pilonidal Cyst (Pilonidal Sinus, Pilonidal Disease)

• Most common location is the upper gluteal cleft in association with a sinus tract ± fragments of hairs (Fig. 90.4).
• May have a history of draining malodorous material.
• More common in men.
• May be associated with acne conglobata, hidradenitis suppurativa, and dissecting cellulitis (follicular occlusion tetrad).



**Fig. 90.4 Pilonidal sinus and abscess formation at the superior portion of the intergluteal cleft.** *Courtesy, Kalman Watsky, MD.*



**Fig. 90.5 Eruptive vellus hair cysts.** Pigmented small papules on the thigh of a young woman. *Courtesy, Mary S. Stone, MD.*

## True Cysts – Less Common

### Vellus Hair Cyst

- 1- to 3-mm, skin-colored to brown-blue papule(s), commonly on the trunk (Fig. 90.5).
- Occasionally inflamed.
- When multiple, may be inherited (autosomal dominant); can occasionally be associated with pachyonychia congenita 6b/17 > 6a/16.
- Bedside diagnostic test: nick the cyst and examine expressed contents for vellus hairs.
- **DDx:** acne, steatocystomas (may have overlap).

### Steatocystoma

- 2- to 10-mm, skin-colored to pigmented papule or nodule, usually multiple and grouped (steatocystoma multiplex); commonly develop on the trunk or in the axillae and groin (Fig. 90.6). May be solitary (steatocystoma simplex).
- Can drain oily fluid.
- Multiple lesions may be inherited as an isolated finding (autosomal dominant, *KRT17* mutation) or represent a clinical feature of pachyonychia congenita 6b/17 > 6a/16.

### Hidrocystoma

#### APOCRINE

- Often a solitary, translucent to bluish papule on the eyelid margin (Fig. 90.7).
- Histology: the lining resembles that of an apocrine gland (decapitation secretion).
- **Rx:** if bothersome or symptomatic, excision by an experienced surgeon.

#### ECCRINE

- Multiple or solitary bluish, translucent papule(s) on the face (Fig. 90.8).
- Can become more prominent with sweating.
- Bedside diagnostic test: nicking the surface results in drainage of clear liquid.

## "False" Cysts (No True Epithelial Lining)

### Mucocele

- Compressible mucosal-colored to bluish papule or nodule, most commonly seen on the lower, inner mucosal lip (Fig. 90.9).
- Secondary to disruption of the minor salivary ducts.
- May resolve spontaneously.
- **Rx:** if persistent, excision or other destructive procedure, intralesional CS.

### Digital Mucous Cyst (Digital Myxoid Cyst)

- Skin-colored to translucent papule or nodule most commonly on digits, in particular the dorsal, distal finger near the distal interphalangeal joint (Fig. 90.10).
- There may be a connection to the joint space.
- Occurs in the setting of osteoarthritis.
- Longitudinal nail deformity, usually a depression, may be present when the lesion compresses the nail matrix.
- Puncture can result in drainage of a gelatinous material.
- **Rx:** observation, intralesional CS, excision, repeated incision and drainage.

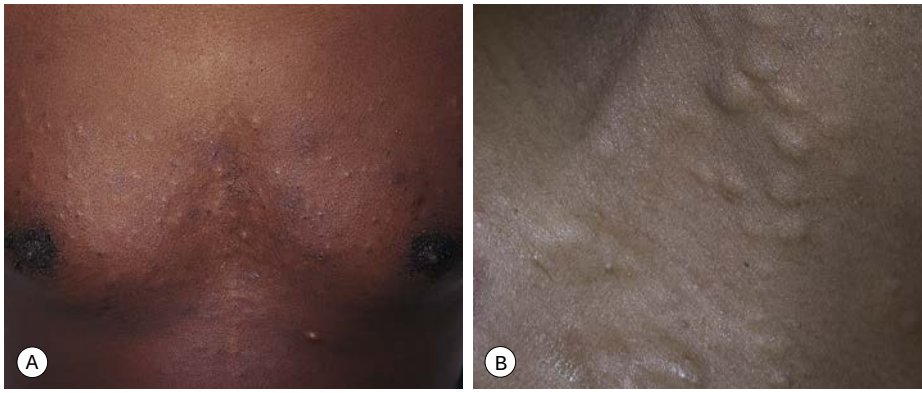


**Fig. 90.6 Steatocystoma multiplex. A, B** Numerous cystic papules on the trunk and multiple cystic nodules on the neck. *A, Courtesy, Mary S. Stone, MD; B, Courtesy, YDRSC.*



**Fig. 90.7 Apocrine hidrocystoma.** A single, slightly bluish, translucent papule on the lower eyelid near the lateral canthus. *Courtesy, Mary S. Stone, MD.*



**Fig. 90.8 Eccrine hidrocystomas.** Numerous, tiny translucent or bluish papules on the lower eyelid.

## Ganglion Cyst (Synovial Cyst)

- Soft, cystic nodule up to 4 cm in diameter, most commonly on the wrist > ankle (Fig. 90.11).
- **Rx:** may spontaneously resolve but recurrence common; treatment modalities include compression, aspiration and intralesional CS, excision.

## Pseudocyst of the Auricle

- Painless swelling, generally unilateral, of the scaphoid fossa of the ear (Fig. 90.12).
- More common in men than in women.
- **Rx:** aspiration ± intralesional CS, incision and drainage; any treatment should be followed by pressure dressings.



**Fig. 90.9 Mucocele.** A bluish translucent papule on the lower mucosal lip. *Courtesy, Mary S. Stone, MD.*

For further information see Ch. 110 from *Dermatology, Fourth Edition*.

**For additional online figures visit www.expertconsult.com**



**Fig. 90.10 Digital mucous cyst.** A translucent papule on the dorsal distal phalanx of the finger causing a depression in the nail plate. *Courtesy, Mary S. Stone, MD.*

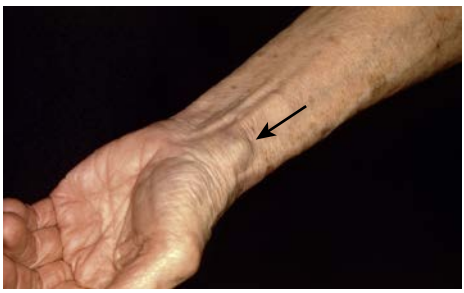

**Fig. 90.11 Ganglion (cyst).** A skin-colored, compressible, subcutaneous nodule is present on the wrist (arrow), the most common location. *Courtesy, Jean L. Bolognia, MD.*



**Fig. 90.12 Pseudocyst of the auricle.** Erythematous firm nodule on the ear. *Courtesy, YDRSC.*

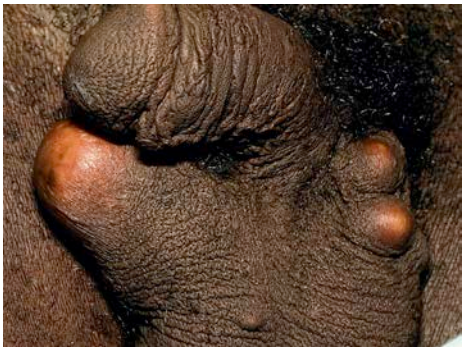

**eFig. 90.1 Multiple scrotal cysts.** They may be associated with dystrophic calcification. *Courtesy, Joyce Rico, MD.*

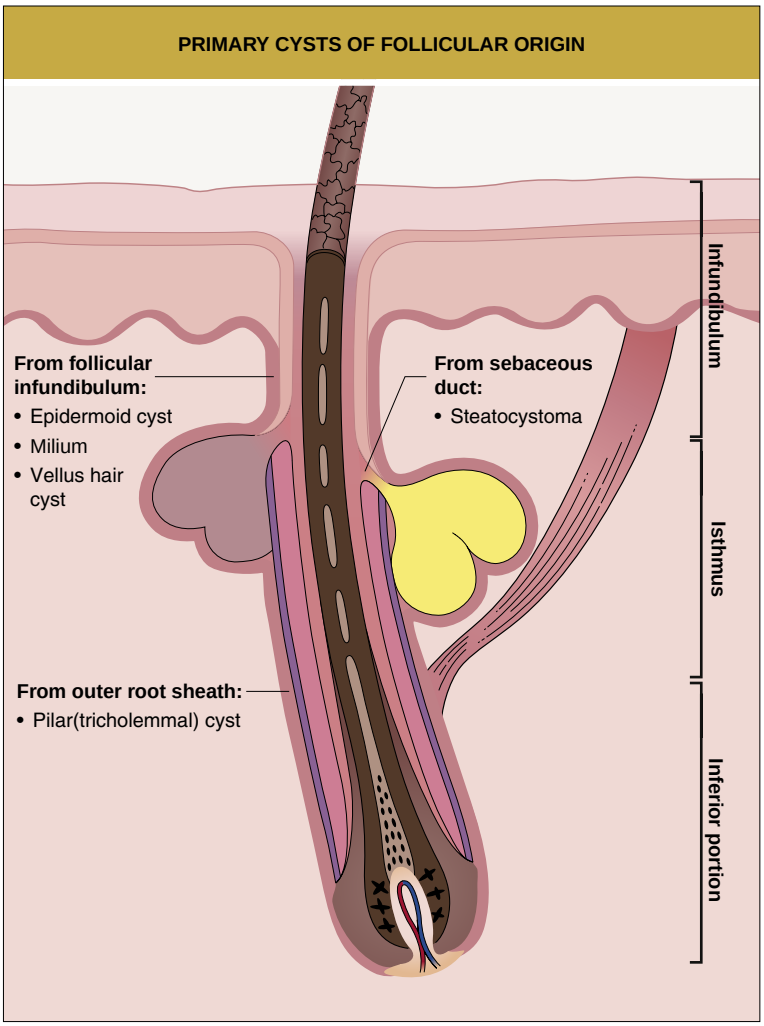


**eFig. 90.2 Primary cysts of follicular origin.** Anatomic origin of cysts derived from the pilosebaceous unit. *Adapted from Requena L, Sanchez Yus E. Follicular hybrid cysts. An expanded spectrum. Am J Dermatopathol 1991;13:228–33.*



**eFig. 90.3 Eccrine hidrocystomas.** Numerous, tiny, translucent or bluish papules on the cheek. *Courtesy, YDRSC.*

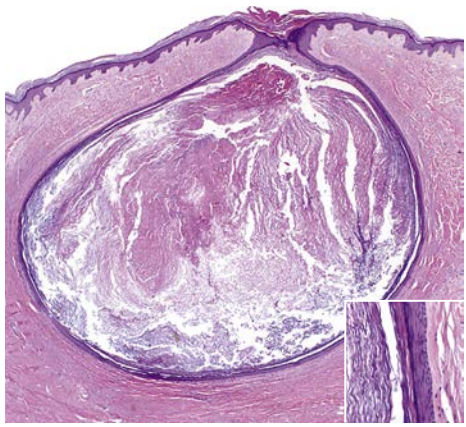

**eFig. 90.4 Histology of an epidermoid cyst.** Laminated keratin within an epithelial-lined cyst in the dermis. The cyst wall shows epidermal keratinization including a granular layer (inset).

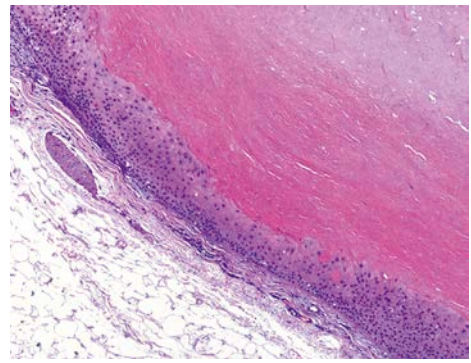

**eFig. 90.5 Histology of a tricholemmal cyst.** The cyst wall shows swollen keratinocytes with abrupt keratinization without formation of a granular layer. Compact, eosinophilic keratin fills the cyst. *Courtesy, Luis Requena, MD.*

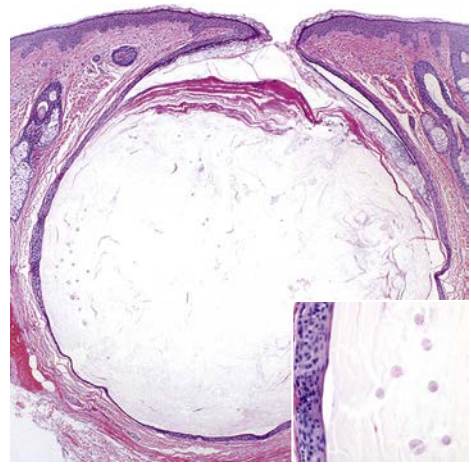

**eFig. 90.6 Histology of a vellus hair cyst.** A cyst shows epidermoid keratinization of its wall as well as laminated keratin and several vellus hairs within its cavity (inset).

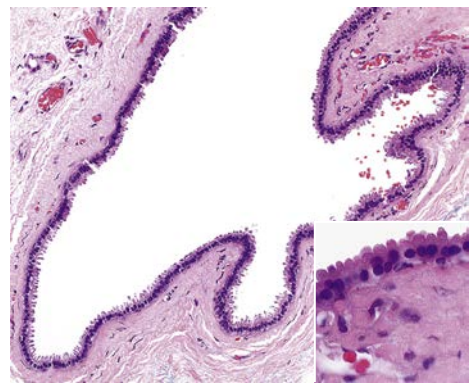

**eFig. 90.7 Histology of an apocrine hidrocystoma.** A unilocular cyst whose wall shows typical apocrine decapitation secretion (inset).

# 91 Adnexal Neoplasms

• Adnexal neoplasms are tumors, more commonly benign, that show features of cutaneous adnexal structures (Fig. 91.1), e.g. hair (Table 91.1), sebaceous glands (Table 91.2), apocrine glands and eccrine glands (Table 91.3).

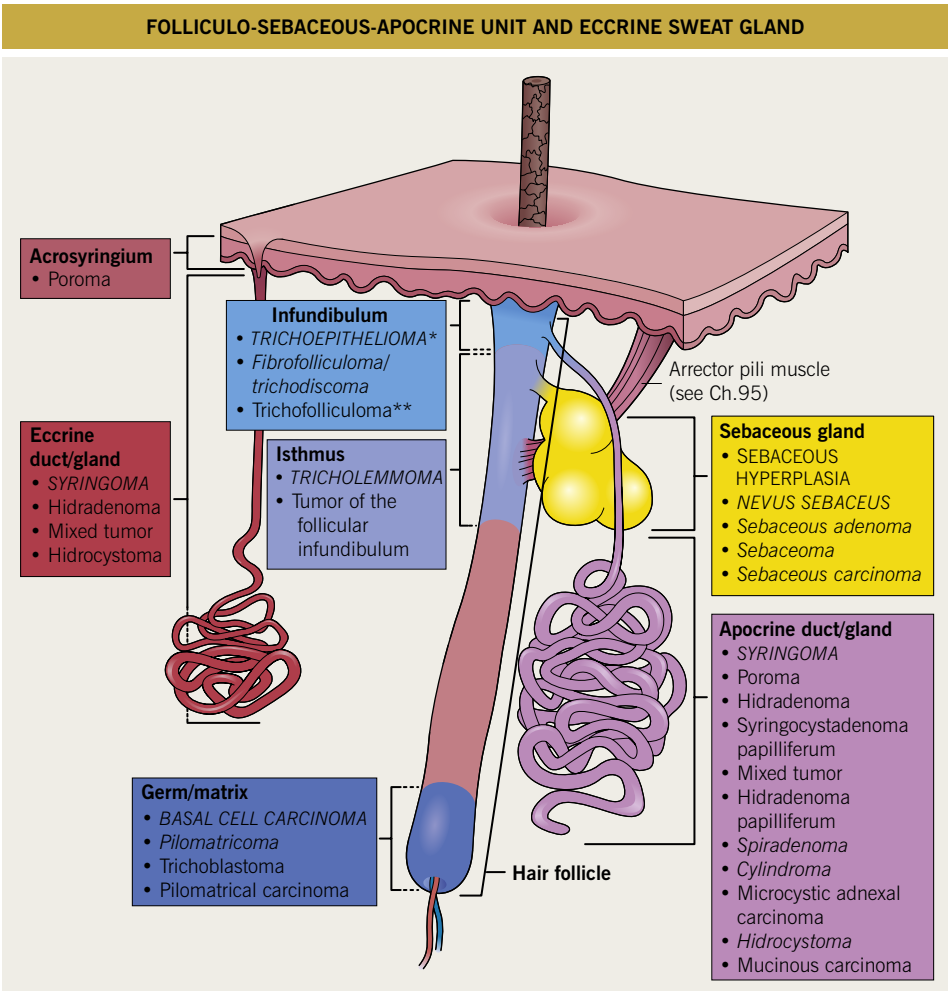


**Fig. 91.1 Folliculo-sebaceous-apocrine unit and eccrine sweat gland.** Adnexal tumors showing differentiation toward the hair follicle, sebaceous gland, apocrine gland, and eccrine gland are listed in correspondingly colored boxes. Important entities are in capital letters; entities associated with syndromes are in italics (see Tables 91.1–91.3). *Can show germinal differentiation; **differentiation toward entire follicle.

| BENIGN AND MALIGNANT TUMORS WITH FOLLICULAR DIFFERENTIATION | | | | |
|---|---|---|---|---|
| | **Morphology** | **Common site(s)** | **Distinctive characteristic(s)** | **Association(s)*** |
| **Benign** | | | | |
| Pilomatricoma | Firm to hard (calcified) papule, nodule, or dermal plaque | Head > upper trunk (Fig. 91.2) | Common in children; may have a characteristic "shelf-like" feel, possibly due to calcification; sometimes has associated anetoderma | Tumor has *CTNNB1* mutation (encodes β-catenin)<br>Occasionally associated with myotonic dystrophy, Gardner syndrome (when cystic; *APC* mutation), Rubinstein–Taybi syndrome |
| Tricholemmoma | Skin-colored papule > nodule | Central face, especially nose or upper lip | May be wart-like (verrucous) | Cowden disease (PTEN hamartoma tumor syndrome) (*PTEN* mutation) (Fig. 91.16) |
| Desmoplastic trichoepithelioma | Skin-colored to erythematous plaque | Cheek or upper lip | Annular; more common in women | |
| Trichofolliculoma | Papule or nodule | Face > scalp > upper trunk | Occasionally has a tuft of white, wispy hairs protruding from center (Fig. 91.3) | |
| Fibrofolliculoma/ trichodiscoma | Subtle skin-colored to hypopigmented papule | Face, ears (Fig. 91.4), neck > scalp > upper trunk | | Birt–Hogg–Dubé syndrome (*BHD* mutation) (Fig. 91.16) |
| Tumor of the follicular infundibulum | Hypopigmented, subtle macule or papule or plaque | Face (Fig. 91.5) | Sometimes atrophic | Rarely, Cowden disease (PTEN hamartoma tumor syndrome) (Fig. 91.16) |
| Trichoepithelioma | Pink-red to skin-colored papule or nodule | Face (especially medial cheeks, nose) > upper trunk (Fig. 91.6) | | Brooke–Spiegler syndrome (*CYLD* mutation), multiple familial trichoepitheliomas |
| Trichoblastoma | Nodule | | | Most common tumor to develop in nevus sebaceus |
| Proliferating pilar tumor | Skin-colored to pink-red nodule | 90% of cases on scalp | | |
| **Malignant†** | | | | |
| Basal cell carcinoma | See Ch. 88 | | | |

**Patients generally have multiple tumors when associated with a syndrome.*
*†Rare tumors include pilomatrical carcinoma and trichilemmal carcinoma.*

**Table 91.1 Benign and malignant tumors with follicular differentiation.** Cysts (e.g. epidermoid and pilar) are discussed in Chapter 90. *BHD* encodes folliculin, a tumor suppressor; *CYLD* encodes a deubiquinating enzyme; *APC* encodes a protein that regulates cell adhesion/migration.

| BENIGN AND MALIGNANT TUMORS WITH SEBACEOUS DIFFERENTIATION | | | | |
|---|---|---|---|---|
| | **Morphology** | **Site(s)** | **Distinctive characteristic(s)** | **Association(s)** |
| **Benign** | | | | |
| Nevus sebaceus (see Ch. 51) | Yellow-orange, hairless linear plaque (Fig. 91.7) | Scalp > face/neck | Along lines of Blaschko, minimally raised and waxy during childhood, becoming thicker and verrucous at puberty; can develop secondary tumors, most commonly trichoblastoma | Mosaic *HRAS* > *KRAS* mutation; more extensive lesions may be associated with Schimmelpenning syndrome (see Ch. 51) |
| Sebaceous hyperplasia | Yellowish papule (Fig. 91.8) | Face (rarely other sites) | Sometimes telangiectatic, with central dell | |
| Sebaceous adenoma | Papule or nodule | Head and neck > upper trunk | | Muir–Torre syndrome (especially in patients <50 years of age; *MSH2* or *MLH1* >> *MSH6* mutation) (Fig. 91.16)* |
| Sebaceoma | Deep nodule or "cyst" | Face (especially nose) > upper trunk | | Muir–Torre syndrome (Fig. 91.16) |
| **Malignant** | | | | |
| Sebaceous carcinoma | Occasionally yellowish nodule or plaque, sometimes ulcerated or crusted | Eyelid or other sites | Early lesions may resemble blepharitis or ocular rosacea | Muir–Torre syndrome (Fig. 91.16) |

**MSH2, MLH1, and MSH6 encode mismatch repair proteins.*

**Table 91.2 Benign and malignant tumors with sebaceous differentiation.**

| BENIGN AND MALIGNANT TUMORS WITH APOCRINE/ECCRINE (GLANDULAR) DIFFERENTIATION | | | | |
|---|---|---|---|---|
| | **Morphology** | **Site(s)** | **Distinctive characteristic(s)** | **Associated syndrome(s)*** |
| **Benign** | | | | |
| Syringoma | 2–4 mm firm, skin-colored to yellow or pink papule | Most commonly eyelids > vulva > disseminated on trunk and upper extremities (Fig. 91.9) | More discrete than xanthelasma | Down syndrome, rarely metabolic syndrome (diabetes) with clear cell syringomas (Fig. 91.16) |
| Mixed tumor | Nodule | Head and neck (Fig. 91.10) | | |
| Poroma | Red-blue papule, plaque, or nodule | Head and neck or palmoplantar | May have a vascular appearance (Fig. 91.11) | |
| Hidradenoma | Dermal or subcutaneous nodule (Fig. 91.12) | | | |
| Syringocystadenoma papilliferum | Papule or plaque, often crusted | Scalp (Fig. 91.13) | May arise within nevus sebaceous (see Fig. 91.7B) | |
| Hidradenoma papilliferum | Smooth dermal or subcutaneous nodule | Vulva | | |
| Spiradenoma | Dermal or subcutaneous papule or nodule, may have bluish hue | | Sometimes painful | Brooke–Spiegler syndrome (Fig. 91.16) |
| Cylindroma | Pink, single or multiple papule(s) or nodule(s) | Head and neck, especially scalp (Fig. 91.14) | May become confluent/extensive on head ("turban" tumor) | Cylindromatosis, Brooke–Spiegler syndrome (Fig. 91.16) |
| **Malignant†** | | | | |
| Microcystic adnexal carcinoma | Nodule or plaque | Face (Fig. 91.15) | Young or middle-aged adults, female > male; more aggressive than basal cell carcinoma | |

**Patients generally have multiple tumors when associated with a syndrome.*
*†Other rare tumors include porocarcinoma and adenoid cystic carcinoma.*

**Table 91.3 Benign and malignant tumors with apocrine/eccrine (glandular) differentiation.** Cysts (e.g. hidrocystoma) are discussed in Chapter 90.



**Fig. 91.2 Pilomatricoma.** A nodule on the cheek of a child. *Courtesy, YDRSC.*



**Fig. 91.5 Tumor of the follicular infundibulum.** Multiple hypopigmented thin papules on the cheek. *Courtesy, YDRSC.*



**Fig. 91.3 Trichofolliculoma.** Wispy vellus hairs emerge from a skin-colored papule with a dilated central pore. *Courtesy, YDRSC.*

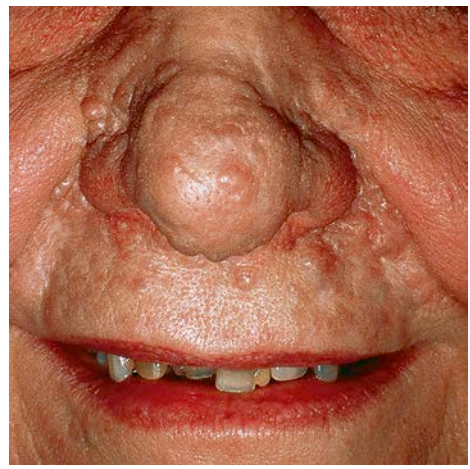

**Fig. 91.6 Multiple familial trichoepitheliomas.** Numerous skin-colored papules and nodules on the mid-face. *Courtesy, YDRSC.*

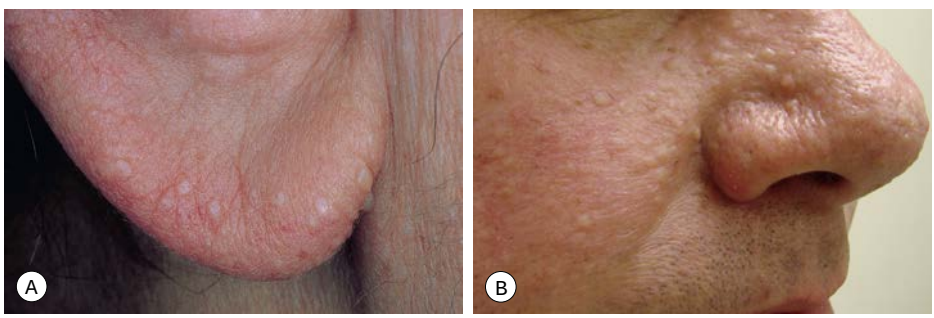


**Fig. 91.4 Fibrofolliculomas in association with Birt–Hogg–Dubé syndrome. A** Several skin-colored papules are present on the ear. **B** Multiple smooth papules of the cheek that are skin-colored to relatively hypopigmented; they lack the telangiectasias of the background skin. *A, Courtesy, YDRSC; B, Courtesy, Barry Goldberg, MD.*

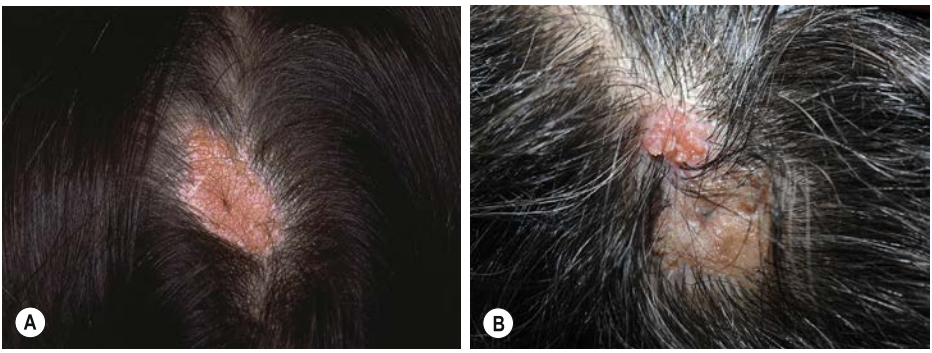


**Fig. 91.7 Nevus sebaceus. A** An oval yellow-pink verrucous plaque on the scalp. Note the alopecia. **B** Syringocystadenoma papilliferum arising within a nevus sebaceous. Yellow-brown verrucous plaque in which an eroded, pink, lobulated papulonodule developed. *A, Courtesy, YDRSC; B, Courtesy, Kalman Watsky, MD.*




**Fig. 91.8 Sebaceous hyperplasia. A** Skin-colored to yellowish papules with a central dell. **B** Numerous lesions of sebaceous hyperplasia in a solid organ transplant recipient receiving long-term cyclosporine. *A, Courtesy, YDRSC; B, Courtesy, Oscar Colegio, MD, PhD.*

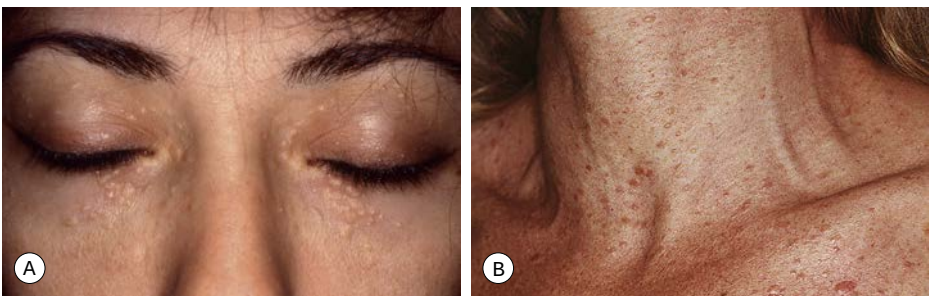


**Fig. 91.9 Syringomas. A** Aggregated skin-colored papules on the eyelids. **B** Multiple skin-colored to pink, smooth papules on the neck and upper chest. The lesions favor the ventral surface of the trunk, a distribution pattern referred to as *"en demicuirasse"*. *A, Courtesy, YDRSC; B, Courtesy, Jean L. Bolognia, MD.*



**Fig. 91.10 Mixed tumor (chondroid syringoma).** Nodule on the chin. *Courtesy, Ronald P. Rapini, MD.*



**Fig. 91.11 Poroma.** A solitary eroded red plaque on the plantar surface. The differential diagnosis often includes amelanotic melanoma and pyogenic granuloma. *Courtesy, YDRSC.*



**Fig. 91.12 Hidradenoma.** A solitary violaceous nodule on the abdomen with serous drainage. *Courtesy, USCDRSC.*



**Fig. 91.13 Syringocystadenoma papilliferum.** Grouped papules and nodules. The possibility of an associated nevus sebaceus needs to be considered. *Courtesy, YDRSC.*



**Fig. 91.14 Cylindroma.** Whereas numerous tumors aggregated on the scalp are called turban tumors, solitary lesions usually present as smooth erythematous nodules. *Courtesy, YDRSC.*



**Fig. 91.15 Microcystic adnexal carcinoma.** This tumor presents as a slowly expanding, firm plaque. *Courtesy, YDRSC.*

## APPROACH TO MULTIPLE FACIAL PAPULES

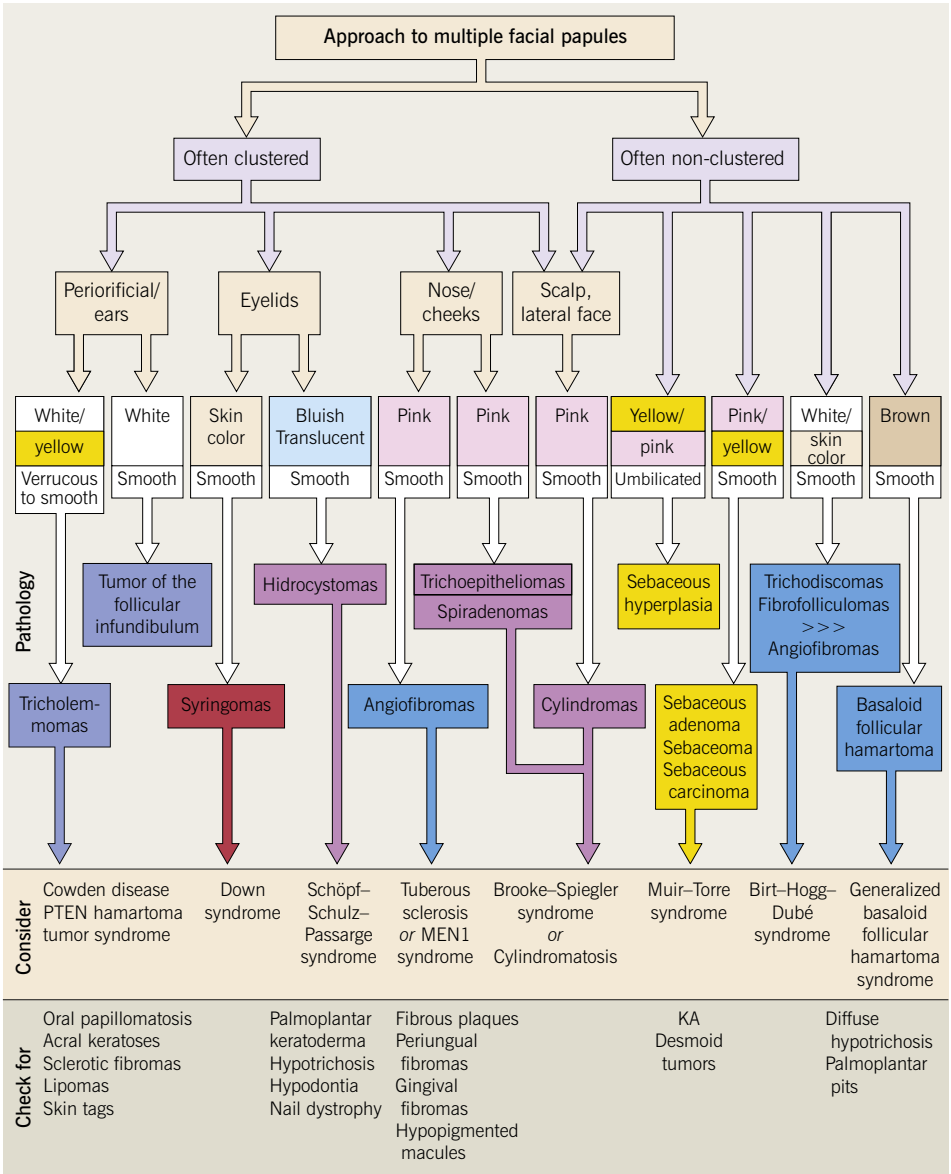


**Fig. 91.16 Approach to multiple facial papules.** As a general rule, multiple lesions are suggestive of a syndrome, but exceptions are syringoma and tumor of the follicular infundibulum (rarely syndromic). Other causes of multiple facial papules include BCCs (acquired and inherited in nevoid basal cell carcinoma syndrome), miliary osteomas, milia, verrucae, and acne. KA, keratoacanthoma

For further information see Ch. 111 from *Dermatology, Fourth Edition*.

**For additional online figures visit www.expertconsult.com**

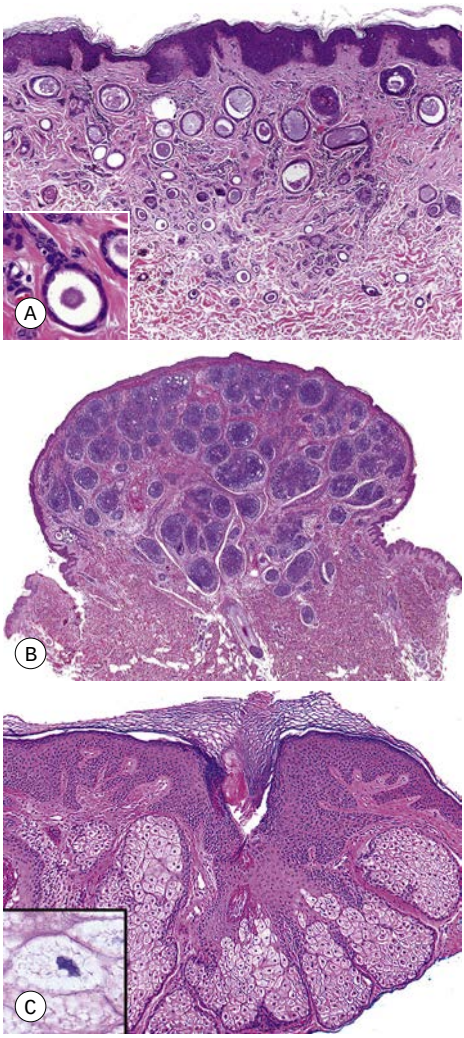


**eFig. 91.1 Histopathologic findings in three different adnexal tumors with differentiation toward adnexal structures (eccrine gland, hair follicle, sebaceous gland).** In the syringoma in **A**, duct-like lumens with tails of epithelium ("tadpoles", inset) have resemblance to the normal eccrine gland. In the trichoepithelioma in **B**, blue islands of epithelium resemble the lower portion of the hair follicle; the stroma is sclerotic. In sebaceous hyperplasia (**C**), an increased number of sebaceous glands composed of mature sebocytes (inset) are centered around the upper portion of a hair follicle.



**eFig. 91.2 Porocarcinoma.** Rapid growth and erosion or ulceration accompany this malignant adnexal tumor. *Courtesy, YDRSC.*



**eFig. 91.3 Porokeratotic eccrine ostial and dermal duct nevus.** Markedly hyperkeratotic spines arise from dilated eccrine ostia, corresponding to the histologic findings of cornoid lamellae. Note the linearity of several of the lesions. *Courtesy, Julie V. Schaffer, MD.*




**eFig. 91.4 Porokeratotic eccrine ostial and dermal duct nevus. A** Linear keratotic plaques on the palm. **B** Markedly keratotic spines arise from dilated eccrine ostia, corresponding to the histologic findings of cornoid lamellae. *B, Courtesy, YDRSC.*

# 92 Benign Melanocytics Neoplasms

## Benign Pigmented Cutaneous Lesions Other Than Melanocytic Nevi

- This group of lesions can further be divided into: (1) predominantly epidermal lesions (Table 92.1; Figs 92.1–92.5); and (2) dermal melanocytoses (Table 92.2; Figs 92.6 and 92.7).
- In the predominantly epidermal lesions, the tan to brown color can result from a variety of mechanisms – e.g. increased melanocyte activity (melanogenesis), increased melanin content in keratinocytes, and a mild increase in the number of melanocytes.
- In dermal melanocytoses, the skin is blue to blue-gray in color (ceruloderma) due to the presence of melanin-producing melanocytes in the mid to lower dermis and the resultant Tyndall phenomenon (the preferential scattering of shorter wavelengths of light by the dermal melanin).



**Fig. 92.1 Labial lentigines in a patient with Laugier–Hunziker syndrome.** Multiple hyperpigmented macules on the lower lip (labial melanotic macules) and a few on the tongue; Peutz–Jeghers syndrome can have a similar clinical appearance. *Courtesy, YDRSC.*



**Fig. 92.2 Anogenital lentiginosis (anogenital melanotic macules).** Biopsy of the clinically most atypical lesion (at 7 o'clock) showed no cellular atypia. Over a period of 10 years, several of the macules faded. *Courtesy, Jean L. Bolognia, MD.*



**Fig. 92.3 Solar lentigines.** Multiple, round to irregularly shaped, brown macules on the dorsal aspect of the hands in an older woman. *Courtesy, Luis Requena, MD.*

| BENIGN PIGMENTED LESIONS OTHER THAN MELANOCYTIC NEVI (PREDOMINANTLY EPIDERMAL LESIONS) | |
|---|---|
| **Lesion** | **Major clinical features** |
| **Ephelid** (freckle) | • Onset in childhood (UVR-induced) and tends to fade with age and in the absence of sun exposure (e.g. winter months)<br>• Small, well-circumscribed, usually multiple, tan to brown macules on sun-exposed areas in fair-skinned individuals |
| **Lentigo simplex and mucosal melanotic lesions** | • Onset usually in childhood; not related to sun exposure<br>• Small, sharply circumscribed, brown to black macule that can occur at any site, including mucosae; typically a few lesions<br>• Multiple or generalized lentigines may be an isolated phenomenon or a marker of an underlying disorder (Table 92.3) |
| • **Oral melanotic macules** (Fig. 92.1) | • Onset in adulthood<br>• Typically, an isolated to a few, brown to brown-black macule(s) on the vermilion portion of the lower lip (labial melanotic macules); occasionally on the gingiva, buccal mucosa, tongue, or palate (Fig. 92.1)<br>• Multiple lesions (lentiginosis) may be a marker of Peutz–Jeghers or Laugier–Hunziker syndromes |
| • **Anogenital lentiginosis** (anogenital melanotic macules) (Fig. 92.2) | • Onset typically in adulthood; females > males<br>• One or more brown to black macules, sometimes with irregular or jagged borders, mottled pigmentation, and occasionally of large size (>1 cm)<br>• In *females* favors the labia minora > labia majora, vaginal introitus, perineum; in *males* favors the glans penis and penile shaft<br>• Multiple lesions are a feature of lichen sclerosis, Laugier–Hunziker syndrome, and Bannayan–Riley–Ruvalcaba syndrome (see Table 52.1) |
| • **Conjunctival melanosis** (conjunctival melanotic macules) | • Conjunctival brown to black pigmented macules, streaks, or patches<br>• While congenital form is typically benign, primary acquired ocular melanosis is considered a precursor lesion of conjunctival melanoma |
| **Solar lentigo** (lentigo senilis, "liver spot") (Fig. 92.3) | • Onset in adulthood (UVR-induced); persists throughout life and may darken with sun exposure, but does not fade<br>• Typically, multiple tan to dark brown macules, often with irregular borders, ranging from a few millimeters to >1 cm in diameter<br>• Distribution limited to sun-exposed sites, favoring those areas of greatest cumulative exposure (e.g. face, dorsal hands and forearms, upper trunk)<br>• Clinical variants: ink spot lentigo, PUVA lentigo, tanning bed lentigo, sunburn lentigo<br>• If present or widespread in young children, consider: xeroderma pigmentosum, type 2 oculocutaneous albinism (lesions are unusually large and jagged) |
| **Café-au-lait macule** (CALM) (Fig. 92.4) | • Onset at birth or in early childhood; not UVR-induced, but may first become noticeable following sun exposure<br>• Uniformly colored, tan to brown macule or patch, varying in size from a few millimeters to >15 cm; grows proportionately with the child<br>• Usually isolated but occasionally multiple; single CALM seen in ~25–35% of children; <1% of children have ≥3 CALMs<br>• Multiple CALMs may be associated with a variety of disorders (see Table 50.3) |

**Table 92.1 Benign pigmented lesions other than melanocytic nevi (predominantly epidermal lesions).** *Continued*

| BENIGN PIGMENTED LESIONS OTHER THAN MELANOCYTIC NEVI (PREDOMINANTLY EPIDERMAL LESIONS) | |
|---|---|
| **Lesion** | **Major clinical features** |
| **Becker melanosis (nevus)** (Fig. 92.5; see Fig. 57.3 and Table 57.1) | • May be present at birth, but the majority appear around puberty; male:female ratio ~5:1; stimulated by androgens<br>• Classically, unilateral, tan to brown patch or thin plaque on the shoulder and/or upper trunk, but can occur elsewhere; margins typically irregular and break up into "islands" at the periphery; hypertrichosis in ~50%<br>• Associated smooth muscle hamartoma often present and is clinically apparent by the presence of perifollicular papules that are accentuated with rubbing<br>• Infrequently associated with ipsilateral developmental anomalies (e.g. supernumerary nipples, breast hypoplasia, hypoplasia of the pectoralis major muscle, bony abnormalities) |

**Table 92.1** *Continued* **Benign pigmented lesions other than melanocytic nevi (predominantly epidermal lesions).**



**Fig. 92.4 Café-au-lait macule (CALM).** Large tan patch in a geographic pattern on the lateral trunk. The patient did not have McCune–Albright syndrome (see Ch. 50). *Courtesy, YDRSC.*

## Acquired Melanocytic Nevi (Moles)

- Benign proliferations of a type of melanocyte called a "nevus cell".
- Nevus cells differ from "ordinary" melanocytes, which typically reside as single units in the basal layer of the epidermis, in that they: (1) usually cluster as nests in the lower epidermis and/or dermis; and (2) do not have dendritic processes (except when found in a blue nevus).
- Both "ordinary" melanocytes and nevus cells can produce melanin.
- Acquired melanocytic nevi can be categorized as **common** (banal) or **atypical** (dysplastic), and they are further named based on the histopathologic location of the collections of nevus cells (Fig. 92.8):
  - ***Junctional*** *melanocytic nevus*: dermal–epidermal junction
  - ***Compound*** *melanocytic nevus:* dermal–epidermal junction plus dermis
  - ***Intradermal*** *melanocytic nevus:* dermis
- Variants include halo, blue, Spitz, and "special site" nevi (Figs 92.9A–F and 92.10).
- Risk factors for developing acquired melanocytic nevi: (1) a family history of numerous nevi; (2) a greater degree of sun exposure during childhood, especially intermittent and intense; and (3) lightly pigmented skin (individuals with phototype II have the greatest number of nevi).
- The vast majority of acquired melanocytic nevi remain as benign neoplasms throughout one's life and do not require treatment.
- Having numerous melanocytic nevi (>50–100) or multiple atypical nevi are phenotypic markers for an entire skin surface at risk for developing cutaneous melanoma; such persons should have lifelong surveillance with periodic total body skin examinations (beginning around puberty) and counseling regarding home self-skin examinations and sun protective measures.
- Cutaneous melanoma may arise within a pre-existing nevus, but more than half of cutaneous melanomas arise *de novo* – i.e. in previously normal-appearing skin.




**Fig. 92.5 Becker melanosis (nevus). A** Unilateral, block-like configuration with hyperpigmentation and hypertrichosis; the patient had an underlying smooth muscle hamartoma. **B** Large patch of hyperpigmentation on the leg, which is medium brown in color. Such lesions may be misdiagnosed as café-au-lait macules or congenital melanocytic nevi, especially when they do not occur on the upper trunk. *A, Courtesy, Edward Cowen, MD; B, Courtesy, Jean L. Bolognia, MD.*

**THE SPECTRUM AND CLINICAL FEATURES OF DERMAL MELANOCYTOSES**

| Lesion | Major clinical features |
|---|---|
| **Congenital dermal melanocytosis** (Mongolian spots) (Fig. 92.6) | • Typically apparent at birth or within the first few weeks of life<br>• Regresses in >95% of patients by age 18 years; more likely to persist in extensive or extra-sacral variants; most common in Asians and Blacks<br>• Presents as a single or multiple, uniform, blue-gray patch(es) with indefinite borders; favors the lumbosacral area and buttocks > back; varies in size from a few centimeters to >20 cm<br>• CALM and melanocytic nevi that reside within these areas often have a "halo" that lacks dermal melanocytes (Fig. 92.6)<br>• **DDx:** ecchymosis, child abuse, patch blue nevus, venous malformation<br>• Extensive lesions may be associated with a port-wine stain (phakomatosis pigmentovascularis; see Ch. 85), developmental abnormalities (e.g. cleft lip), or inborn errors of metabolism (e.g. Hurler syndrome) |
| **Nevus of Ota**[*,**] (oculodermal melanocytosis, nevus fuscocaeruleus ophthalmomaxillaris) (Fig. 92.7) | • Bimodal age of onset, with the majority (50–60%) present at birth or in infancy (before 1 year of age), and the remainder (40–50%) appearing at or around puberty; lifelong persistence<br>• More common in Asians and Blacks; females > males<br>• Involves those areas innervated by the first and second divisions of the trigeminal nerve, including the skin, conjunctiva, sclera, tympanic membrane, and/or oral and nasal mucosa; 10% of cases are bilateral<br>• Lesions are characterized by speckled or mottled, grayish-brown to blue-black patches; may extend in size over time but usually stable by adulthood<br>• Occasionally associated with neurocutaneous melanosis, glaucoma, ipsilateral sensorineural hearing loss, ocular melanoma (yearly ophthalmologic exams recommended) |

**Table 92.2 The spectrum and clinical features of dermal melanocytoses.** *Continued*

| THE SPECTRUM AND CLINICAL FEATURES OF DERMAL MELANOCYTOSES | |
|---|---|
| **Lesion** | **Major clinical features** |
| **Nevus of Ito*** (nevus fuscocaeruleus acromiodeltoideus) | • Favored populations and clinical appearance are similar to nevus of Ota (see above)<br>• Involves areas of skin innervated by the posterior supraclavicular and lateral brachiocutaneous nerves, namely the supraclavicular, scapular, or deltoid regions; typically unilateral |
| **Nevus of Ota-like macules**** (acquired dermal melanocytosis, acquired bilateral nevus of Ota-like macules, Hori's nevus) | • Most often seen in middle-aged Asian females<br>• Multiple grayish-brown macules arising in a symmetric, bilateral distribution on the malar cheeks and forehead and sometimes the eyelids, temple, and nose; does not involve mucosa<br>• Important to distinguish from melasma, as laser therapy improves nevus of Ota-like macules |

**DDx for nevus of Ota or Ito: patch or plaque blue nevus, ecchymosis, venous malformation; for nevus of Ito: extra-sacral Mongolian spot.*
***Rx (if desired): pulsed Q-switched lasers (e.g. Q-switched ruby, alexandrite, or Nd:YAG lasers) beneficial but often requires multiple sessions.*

**Table 92.2** *Continued* **The spectrum and clinical features of dermal melanocytoses.** CALM, café-au-lait macule.



**Fig. 92.6 Dermal melanocytosis (Mongolian spots) in a child with neurofibromatosis 1.** Surrounding each café-au-lait macule, there is an absence of the characteristic blue discoloration. *Courtesy, YDRSC.*



**Fig. 92.7 Nevus of Ota (oculodermal melanocytosis).** Unilateral blue-gray discoloration of the face, which is either mottled or confluent. There is also involvement of the sclera. *Courtesy, YDRSC.*

• Most patients with numerous nevi and atypical nevi will have a prominent morphologic type of nevus ("signature nevus"); by recognizing signature nevi, the "ugly duckling" can be identified and closely examined.
• Persons with more darkly pigmented skin will typically have darker colored nevi.

| DISORDERS ASSOCIATED WITH MULTIPLE LENTIGINES | |
|---|---|
| **Disorder, inheritance, gene mutation** | **Comments** |
| **Generalized** | |
| LEOPARD syndrome (now referred to as Noonan syndrome with multiple lentigines)<br>AD<br>*PTPN11* > *RAF1* > *BRAF* | • *L*entigines present in infancy/early childhood<br>• Café-noir macules<br>• *E*CG changes (conduction defects, hypertrophic cardiomyopathy), *o*cular hypertelorism, *p*ulmonary stenosis, *a*bnormal genitalia, growth *r*etardation and *d*eafness |
| Generalized lentigines<br>AD | • Café-au-lait macules |
| Carney complex (NAME/LAMB syndrome)<br>AD<br>*PRKAR1A* | • Lentigines, mucocutaneous myxomas, blue nevi (including epithelioid)<br>• Psammomatous melanotic schwannomas<br>• Atrial myxoma<br>• Myxoid mammary fibroadenomas<br>• Pigmented nodular adrenocortical disease; testicular (calcifying Sertoli cell), thyroid, and pituitary tumors |
| Arterial dissection plus lentiginosis | • Cutaneous lentigines with onset in childhood<br>• Dissection of aortic, internal carotid, and vertebral arteries |
| **Localized** | |
| ***Head and neck (including oral mucosa)* ± *acral*** | |
| Peutz–Jeghers syndrome<br>AD<br>*STK11* | • Lentigines favor perioral region†, oral mucosa‡, and hands; longitudinal melanonychia<br>• Multiple hamartomatous GI polyps<br>• Pancreatic carcinoma; ovarian (adenoma malignum)/testicular tumors |
| Laugier–Hunziker syndrome | • Similar distribution of lentigines as in Peutz–Jeghers, including lips, oral mucosa, and digits<br>• Longitudinal melanonychia and genital melanosis |
| Hyperkeratosis–hyperpigmentation (Cantú) syndrome<br>AD | • Punctate palmoplantar keratoderma<br>• Multiple small (1 mm) macules on the face, forearms, hands/feet |
| Cowden disease<br>AD<br>*PTEN* (See Ch. 52 and Table 52.1) | • Periorificial and acral pigmented macules |

**Table 92.3 Disorders associated with multiple lentigines.** *Continued*

Downloaded for Novin lib (novinlibrary@yahoo.com) at United Arab Emirates University from ClinicalKey.com by
March 26, 2022. For personal use only. No other uses without permission. Copyright ©2022. Elsevier Inc. All rig

| DISORDERS ASSOCIATED WITH MULTIPLE LENTIGINES | |
|---|---|
| **Disorder, inheritance, gene mutation** | **Comments** |
| Centrofacial lentiginosis (neurodysraphic)<br>AD | • Lentigines in a butterfly distribution on the nose, cheeks > forehead, eyelids, upper lip<br>• Onset in infancy; increase in number in childhood<br>• Possibly associated with neuropsychiatric illness and osseous anomalies |
| Inherited patterned lentiginosis<br>AD | • Blacks with more lightly pigmented skin<br>• Pigmented macules appear in early childhood<br>• Present on central face and lips > buttocks, elbows, hands/feet<br>• Rare oral mucosal involvement |
| Cronkhite–Canada syndrome | • Typically affects older men<br>• Lentigines of buccal mucosa, face, hands/feet<br>• Alopecia (diffuse, non-scarring), nail dystrophy, intestinal polyposis, diarrhea, malabsorption |
| ***Genital*** | |
| Bannayan–Riley–Ruvalcaba syndrome<br>AD<br>*PTEN* (see Table 52.1) | • Penile > vulvar pigmented macules |
| ***"Photodistribution"*** | |
| Xeroderma pigmentosum<br>AR<br>Mutations in genes encoding DNA repair proteins | • Lentigines favor, but are not limited to, chronically sun-exposed sites<br>• Multiple skin cancers |
| ***Segmental*** | |
| Partial unilateral lentiginosis | • Multiple lentigines in a segmental distribution<br>• Café-au-lait macules in same distribution |

*†May fade.*
*‡Persists.*

**Table 92.3** *Continued* **Disorders associated with multiple lentigines.** AD, autosomal dominant; AR, autosomal recessive; LAMB, lentigines/atrial myxoma/mucocutaneous myxoma/blue nevi syndrome; LEOPARD, lentigines/ECG abnormalities/ocular hypertelorism/pulmonary stenosis/abnormalities of genitalia/retardation of growth/deafness syndrome; NAME, nevi/atrial myxoma/myxoid neurofibroma/ephelides syndrome. *Adapted from Bolognia JL. Disorders of hypopigmentation and hyperpigmentation. In Harper J, Oranje A, Prose N (eds.), Textbook of Pediatric Dermatology, 2nd edn. Oxford: Blackwell, 2006;997–1040.*

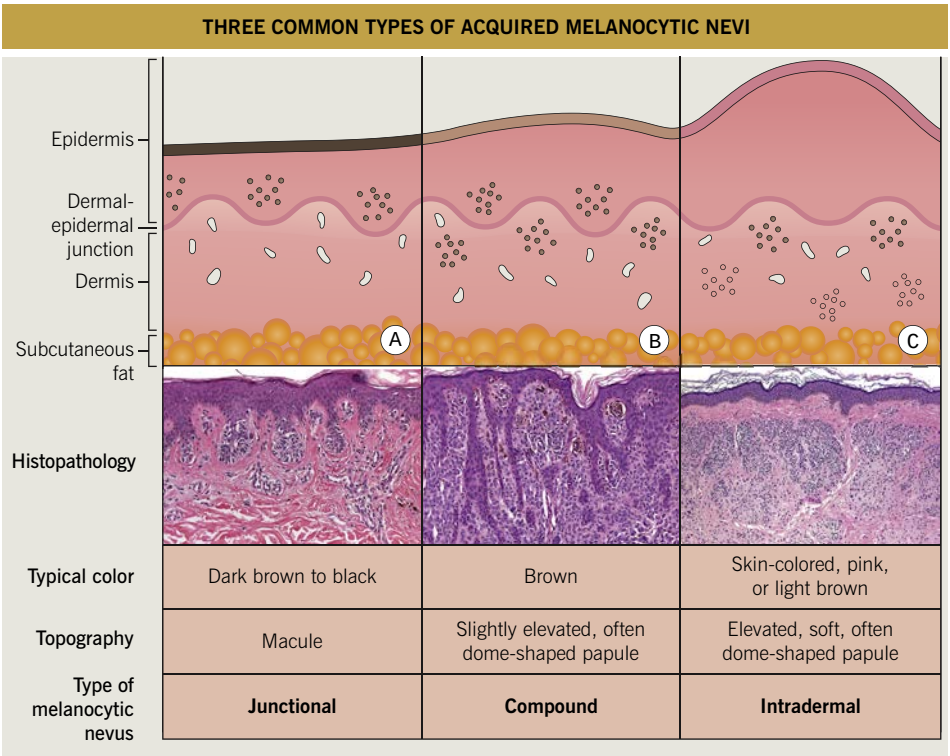


**Fig. 92.8 Three common types of acquired melanocytic nevi. (A)** Junctional, **(B)** compound, and **(C)** intradermal. The latter may also be pedunculated or papillomatous (see Ch. 1).

- **Rx:** it is not necessary to remove clinically atypical nevi prophylactically in order to confirm the presence of histopathological atypia; biopsies of nevi are indicated primarily when a severely atypical nevus or cutaneous melanoma is in the **DDx** (Table 92.4); if banal nevi become irritated (e.g. by clothing or jewelry), shave removal can be done.
- When cutaneous melanoma is in the **DDx**, complete removal of the nevus is recommended as well as submission to a dermatopathologist; removal can be accomplished by several methods (see Fig. 1.6); providing additional information (e.g. eccentric hyperpigmented area) is also helpful.

## Common (Banal) Acquired Melanocytic Nevi

- Benign lesions with varied clinical appearance, but typically ≤6 mm in diameter, symmetric, well-circumscribed, evenly pigmented, and round or oval in shape; perifollicular hypopigmentation or stippled pigmentation is often present upon closer inspection.
- Distribution favors intermittently sun-exposed areas of the trunk and extremities and, less frequently, acral sites (palms, soles, nail matrix); in patients who eventually develop many nevi, the scalp may be one of the first sites of involvement.
- Classically appear after the first 6 months of life, increase in number during childhood and adolescence, peak by the third decade, and then slowly regress with age.
- As nevi "age" over time, they often become more elevated, softer, and less pigmented.

## Atypical (Dysplastic or Clark) Acquired Melanocytic Nevi

- Benign lesions that share, to a lesser extent, many clinical features of cutaneous melanoma (e.g. asymmetry, border irregularity, color variegation, and diameter >6 mm) but usually they "age" in a manner similar

| POTENTIAL INDICATIONS FOR BIOPSY OF MELANOCYTIC NEVI |
|---|
| • **Patient concern for cutaneous melanoma** (e.g. new nevus, changing nevus, anxiety-provoking nevus)<br>• **Symptoms** (e.g. pruritus, pain, bleeding)<br>• **Physician concern for cutaneous melanoma**<br>– Marked *a*symmetry (e.g. irregular *b*orders, variegated *c*olor) – i.e. the ABCDEs of cutaneous melanoma*<br>– Areas of regression (often seen as white or blue-gray areas)<br>– Development of areas of pink or red color that are not easily explained by a benign etiology (e.g. acne or trauma)<br>– Surrounding cloak of erythema ("little red riding hood sign")<br>– History or photographic evidence of worrisome change in size, color, configuration<br>– "Ugly duckling" nevus (i.e. a nevus with a different phenotype than most of the other nevi in a given patient)<br>• **Acral nevus –** marked asymmetry, mottled pigmentation, parallel ridge pattern on dermoscopy<br>• **Nail matrix-derived nevus –** single band that is dark or has an irregular color, width ≥4 mm, progressive darkening with time, or extension of pigmentation beyond the nail fold<br>• **Halo nevus –** the central nevus is markedly atypical or has worrisome features<br>• **Cellular blue nevus –** has undergone change (e.g. a new papule or nodule)<br>• **Spitz nevus with clinically atypical features** – see text<br>• **Congenital melanocytic nevus –** new papulonodule whose color can vary from red to black, new area of induration or ulceration |
| **D and E represent large diameter and evolution.* |

**Table 92.4 Potential indications for biopsy of melanocytic nevi.** Patients with numerous nevi can continue to develop new nevi, and banal nevi can increase in size over time**.**

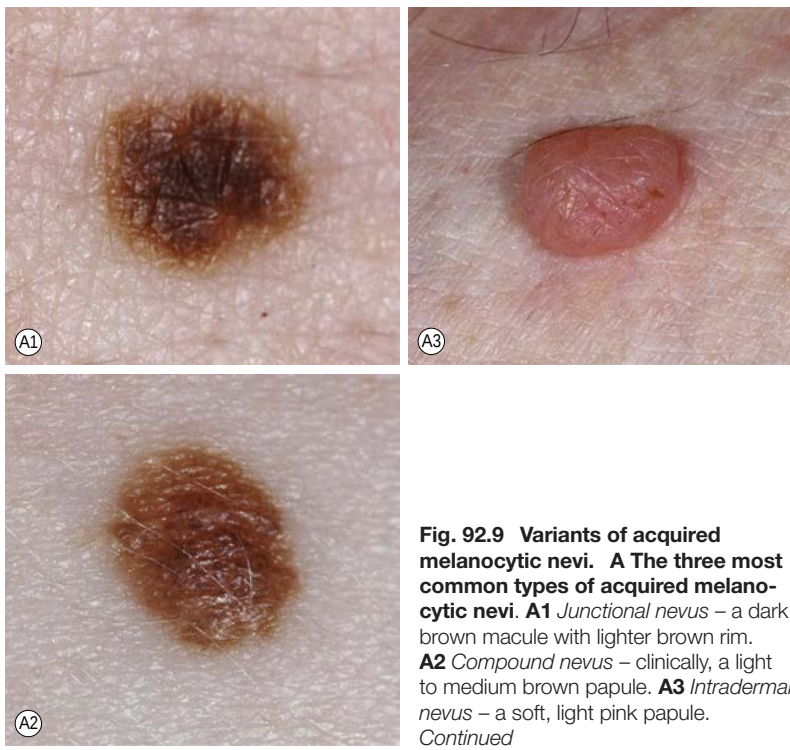


**Fig. 92.9 Variants of acquired melanocytic nevi. A The three most common types of acquired melanocytic nevi**. **A1** *Junctional nevus* – a dark brown macule with lighter brown rim. **A2** *Compound nevus* – clinically, a light to medium brown papule. **A3** *Intradermal nevus* – a soft, light pink papule. *Continued*

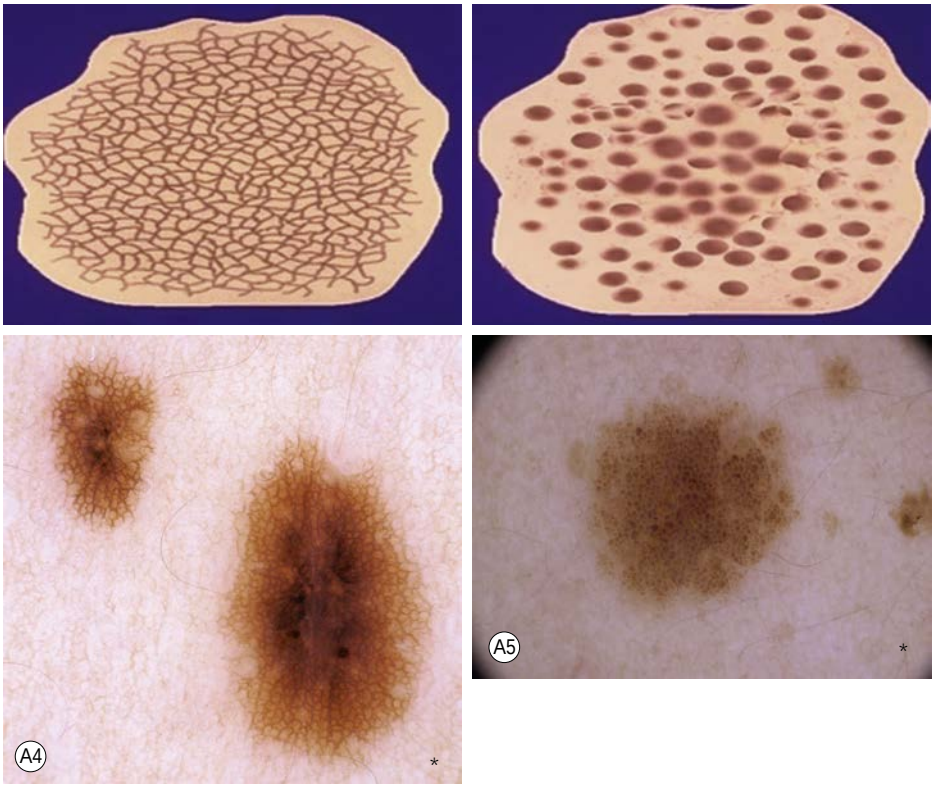


**Fig. 92.9** *Continued* **A4** A reticular pattern on dermoscopy* is commonly seen in typical acquired nevi. **A5** The globular pattern is another common dermoscopic* finding in acquired melanocytic nevi.

to banal nevi and only a tiny proportion may develop melanoma within them.

- Histopathologically, architectural disorder is seen and cytologic atypia may be present; sometimes the latter is categorized as mild, moderate, or severe.
- The major risk factor for developing atypical nevi is genetic predisposition.
- The "*atypical mole syndrome*" has been variably described in the literature, ranging from individuals with atypical nevi but no personal or family history of melanoma to the *f*amilial *a*typical *m*ultiple *m*ole and *m*elanoma syndrome (FAMMM syndrome), in which an individual with numerous nevi (>50), multiple atypical nevi, and ≥1 first- or second-degree relative with cutaneous melanoma has a very high risk of developing melanoma (see Ch. 93).
- Atypical nevi often appear around puberty and are thought to develop throughout life.
- Although the majority of atypical nevi are located in intermittently sun-exposed sites (e.g. trunk and extremities [lower > upper in females]), often they can be seen on the breasts and buttocks.
- *Clinically*, atypical nevi are recognized by various features – e.g. varied colors (pink, brown, tan), a "fried-egg" appearance with a papular component and a macular rim, a larger size than banal nevi, and borders that are ill-defined, "fuzzy," and sometimes notched or irregular (see Fig. 92.9B).
- Adjuncts to monitoring these patients include baseline and follow-up nevus and total body photography; dermoscopy; patient/partner education on skin self-examination and




**Fig. 92.9** *Continued* **B Clinically atypical melanocytic nevi. B1** In addition to multiple atypical nevi, patients can have numerous banal nevi. **B2** There is asymmetry as well as several shades of brown, simulating the clinical features seen in cutaneous melanoma. **B3** Although this "fried egg" nevus is at least 7 mm in size, it is symmetric and does not need to be excised.

signs of melanoma; and possibly alternating examinations between two dermatologists.

- Nevi with mild cytologic atypia histopathologically and most with moderate cytologic atypia do not require re-excision, especially when the biopsy attempted to remove the entire nevus; it is generally recommended, however, that severely atypical nevi be completely excised or re-excised with conservative margins (e.g. 3–5 mm).

## Blue Nevi

- Benign lesions due to a proliferation of dendritic melanocytes within the dermis; blue in color because of the Tyndall effect (see above).
- Sites of predilection are those areas in which active dermal melanocytes are still present at the time of birth (e.g. head, neck, dorsal hands and feet, sacral region).
- Most blue nevi have a somatic activating mutation in *GNAQ* (more often than *GNA11*), both of which encode Q-class G-protein α subunits.
- The ***common blue nevus*** typically presents as a solitary, blue to blue-black, dome-shaped papule, usually <1 cm in diameter and most often occurring on the dorsal hands or feet (see Fig. 92.9C); frequently arises in adolescence; no malignant potential.

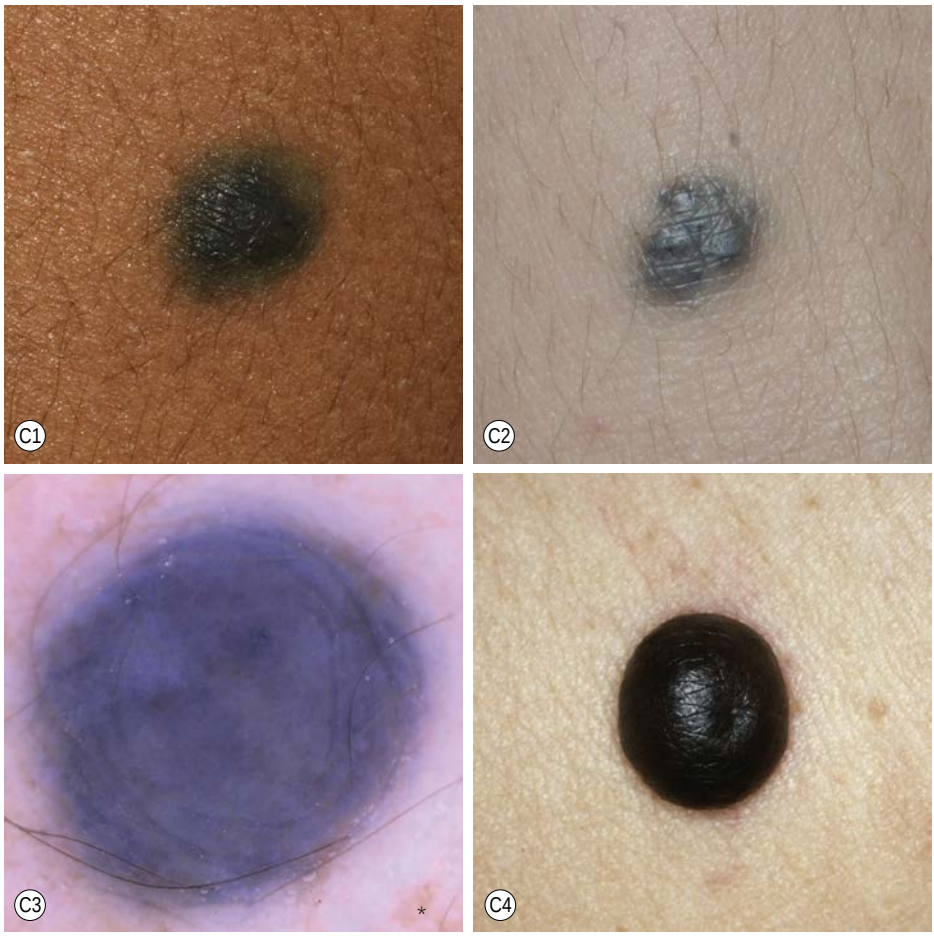


**Fig. 92.9** *Continued* **C Blue nevi**. **C1–C3** *Common blue nevus* – clinically a dark blue-black papule in a patient with more darkly pigmented skin (**C1**). Blue papule with an irregular, micropapular surface (**C2**). Dermoscopically* – blue homogeneous color (**C3**). **C4** *Cellular blue nevus* – a black nodule is seen.

- The ***cellular blue nevus*** tends to be larger in size (i.e. more plaque-like), and it can be congenital or acquired (see Fig. 92.9C4); favors the head, sacral region, and buttocks; melanoma (malignant blue nevus) can develop within cellular blue nevi (see Ch. 93); if location (e.g. scalp) or patient awareness prevents satisfactory observation, then complete excision can be performed.
- The ***combined blue nevus*** typically presents as a blue to gray-brown macule or papule with a subtle brown rim; it usually represents a combination of a blue nevus with a banal nevus, but in theory can be a combination of any two types of nevi.
- **DDx:** traumatic tattoo (e.g. carbon from a pencil), which typically can be distinguished by history, or a venous lake (compressible) > melanoma metastasis, primary cutaneous melanoma.
- **Rx:** none for common blue nevi and as noted above for cellular blue nevi; lesions with a history of recent growth or change should be biopsied.
- Multiple blue nevi (normal in Asians) may signify an underlying syndrome, e.g. Carney complex (see Table 92.3).

## Spitz Nevus (Spindle and Epithelioid Cell Nevus)

- Benign proliferation of epithelioid and/or spindled melanocytes.

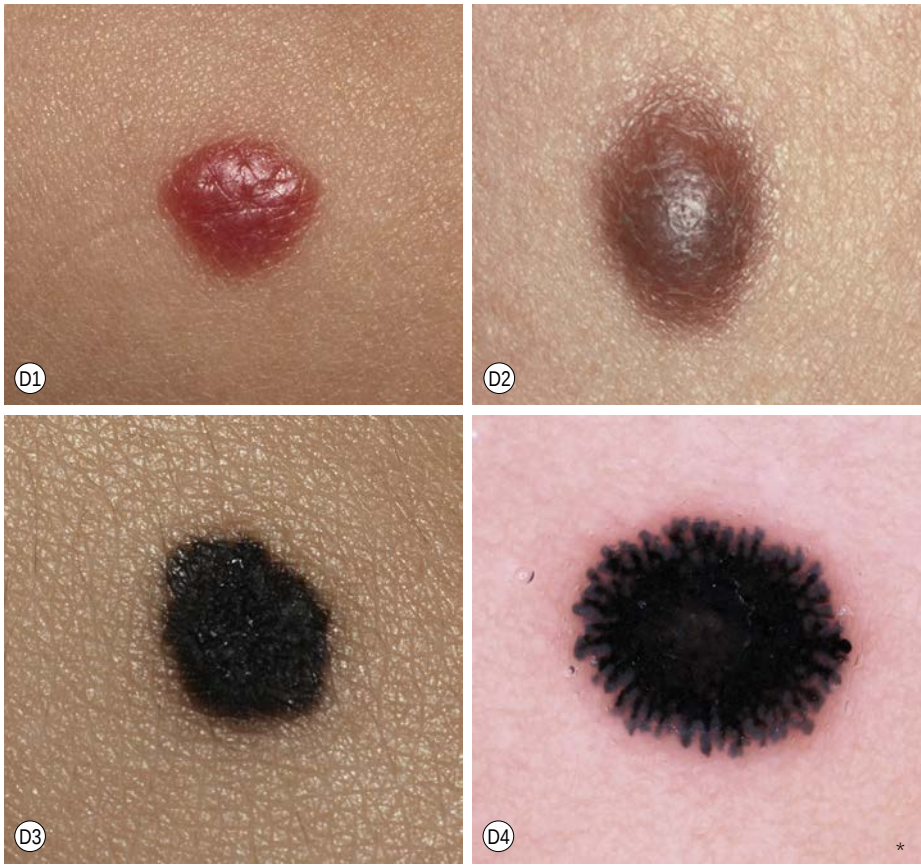


**Fig. 92.9** *Continued* **D Spitz nevi. D1** Red, symmetric, dome-shaped papule on the thigh of a child. **D2** Medium-brown, symmetric, dome-shaped papule with a thinner rim in an adolescent. **D3** Darkly pigmented Spitz nevus in a child with a flatter surface. **D4** *Reed nevus*, typified dermoscopically* by the classic starburst pattern (irregular streaks at the periphery of a heavily pigmented and symmetric small macule).

- Majority appear during childhood or young adulthood and most commonly occur on the face and lower extremities.
- Classically, a Spitz nevus is symmetric, well-circumscribed, <1 cm in diameter, uniformly pink, tan, red, or red-brown, smooth, and dome-shaped (see Fig. 92.9D); occasionally, lesions are verrucous or darkly pigmented.
- ***Pigmented spindle cell nevus of Reed*** is a variant that typically presents in young women as a very dark brown to black minimally elevated papule, most often on the thigh; characteristic "starburst pattern" on dermoscopy (see Fig. 92.9D4).
- **DDx:** *clinical:* pyogenic granuloma, juvenile xanthogranuloma, molluscum contagiosum, verruca vulgaris, intradermal melanocytic nevus (in adults), cutaneous melanoma, dermatofibroma, solitary mastocytoma; *histopathologic:* when atypical features, cutaneous melanoma.
- The **DDx** also includes "BAP-omas," which in general are amelanotic (pink) and occur in patients with germline *BAP1* mutations (see Ch. 93).
- Molecular techniques (e.g. FISH or CGH analysis, *BRAF* V600E and *H-RAS* mutational status) are sometimes used to differentiate atypical Spitz nevi from melanoma.
- Spitz nevi have a tendency to involute over time, and monitoring is an option for a presumed Spitz nevus that develops during childhood and has classic clinical and dermoscopic features.

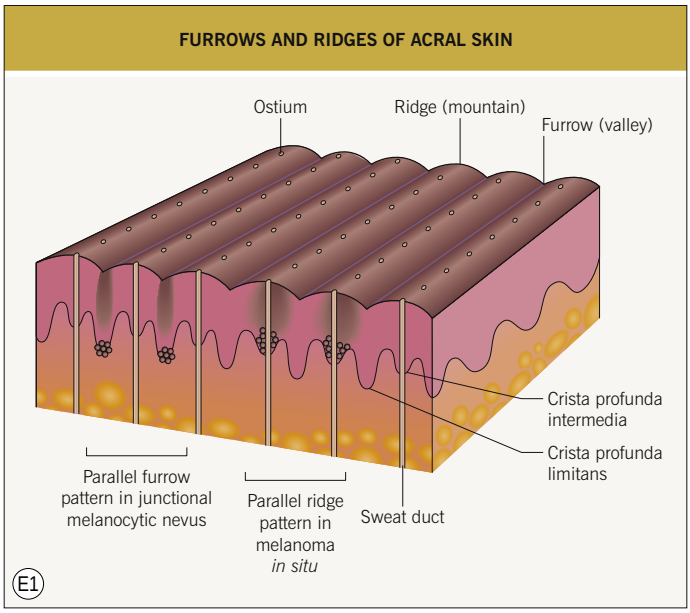


**Fig. 92.9** *Continued* **E Nevi of "special sites" (e.g. scalp, acral, genital, milk-line). E1** *Acral melanocytic nevus* – furrows and ridges of acral skin. **E2** The parallel furrow pattern is evident with a small focus of the lattice pattern. The ostia of the eccrine ducts within the epidermal ridges can also be seen, especially at the site of blue ink.

- Any presumed Spitz nevus with *clinically* atypical features (e.g. size >1 cm, ulceration, asymmetry) should be biopsied.
- Any Spitz nevus with unusual features *histopathologically* should be completely excised.

## Nevi of Special Sites

- Nevi in certain anatomic locations (e.g. scalp) may exhibit *atypical clinical* features, whereas those in several specific sites (e.g. acral, genital, auricular, milk line, flexural, and scalp nevi) may have *atypical histopathologic* features that simulate cutaneous melanoma (see Fig. 92.9E).
- Recognition of this phenomenon prevents overdiagnosis of cutaneous melanoma.

## Other "Specially Named" Nevi

- ***Meyerson or eczematous nevus***: a melanocytic nevus with an eczematous halo; eczematous reaction typically resolves spontaneously or with the application of a topical CS.
- ***Eclipse nevus***: benign melanocytic nevus most often found on the scalp of children; presents as a tan, occasionally pink, central macule or papule with a brown, often stellate rim (see Fig. 92.9F1); ages into an intradermal nevus; when present on the scalp, may be a marker for developing numerous nevi elsewhere over time.
- ***Cockade nevus***: a benign melanocytic nevus with a target configuration, namely a central pigmented papule surrounded by a concentric tan rim, which is then surrounded by another pigmented annulus (see Fig. 92.9F2); occurs in patients with eclipse nevi.
- ***Recurrent nevus***: the reappearance of pigment within the scar of a previously biopsied or excised nevus (see Fig. 92.9F4); if symmetric, re-evaluation of the original histopathology and observation is generally all that is required; if asymmetric or continues to enlarge after its initial appearance, then biopsy is prudent.
- ***Agminated nevus***: a clustering of melanocytic nevi within normal-appearing skin.













**Fig. 92.9** *Continued* **F Other "specially named" nevi. F1** *Eclipse nevus,* characterized by a tan center and brown rim, is commonly found on the scalp of children who go on to develop numerous melanocytic nevi. The associated dermoscopic patterns are those seen in benign melanocytic nevi. **F2** *Cockade or target nevus*, characterized by a central lightly pigmented papule surrounded by a tan annulus then a brown ring. **F3** One variant of *combined melanocytic nevus* – dark brown to black papule within an otherwise uniformly pigmented light brown nevus. The differential diagnosis includes the possibility of a melanoma developing in a nevus. **F4** *Recurrent melanocytic nevus*. Irregular dark brown pigmentation within the center of a circular scar; the pigmentation reflects the proliferation of melanocytes within the epidermis. Note that there is no extension of the recurrence beyond the scar itself, one of the signs that favors observation rather than repeat biopsy. *A1–A3, Courtesy, Raymond L. Barnhill, MD; A4, Courtesy, AAD Dermoscopy Group and Iris Zalaudek, MD & Giuseppe Argenziano, MD; A5, Courtesy, AAD Dermoscopy Group and Iris Zalaudek, MD & Giuseppe Argenziano, MD; B1, B2, Courtesy, Raymond L. Barnhill, MD; B3, C5, E2, F4, Courtesy, Jean L. Bolognia, MD; C1, C2, D1, D3, F1, Courtesy, Julie V. Schaffer, MD; C3, D4, Courtesy, Iris Zalaudek, MD & Giuseppe Argenziano, MD; C4, D2, F3, Courtesy, Lorenzo Cerroni, MD; E1, Courtesy, Jean L. Bolognia, MD and Julie V. Schaffer, MD; F2, Courtesy, Jean L. Bolognia, MD.*

### Halo Nevus

- A melanocytic nevus that is surrounded by a round or oval, usually symmetric, halo of complete depigmentation (i.e. white color).
- The central nevus is most often a common acquired melanocytic nevus, but it can also be other nevus subtypes.
- The halo of depigmentation is believed to represent a T-cell-mediated immune response against nevus antigens, analogous to vitiligo (see Ch. 54).
- Halo nevi are seen in up to 5% of Caucasian children aged 6–15 years; they are more common in patients with an increased number of nevi and a personal or family history of vitiligo.
- The most common location is the back; multiple halo nevi are seen in ~50% of cases.
- There are four clinical stages in the life of a halo nevus, and the evolution usually occurs over years to decades (Fig. 92.10).
- The central nevus should be assessed for suspicious or clinically atypical features; if none are present, then no treatment is necessary (vast majority of lesions); if present, then biopsy of just the central nevus should be performed.
- A new onset of multiple halo nevi is unusual in middle-aged and older adults; this clinical scenario should raise the possibility of the halo nevi representing an autoimmune reaction against a cutaneous or ocular melanoma.
- **DDx:** other pigmented lesions that can have halos (e.g. solar lentigo, seborrheic keratosis), halo primary cutaneous melanoma, halo melanoma metastasis.

## Congenital Melanocytic Nevus (CMN)

- Classically defined as a melanocytic nevus present at birth; may be subtle at birth and not readily apparent for a few months.
- Melanocytic nevi that become apparent after 3 months of age, but before 2 years of age, have been termed "tardive CMN," "congenital nevus-like nevi," or "early onset nevi."
- CMN are due to a proliferation of melanocytes that arise during embryogenesis; melanocytes extend deep into the dermis and subcutaneous tissues and often follow follicular and neurovascular structures; in classic large/giant CMN, the most commonly observed mutations are in *NRAS*.
- Incidence of small CMN is estimated at 1–2%, with large CMN having an incidence of ~1 in 20,000 individuals.
- CMN are classified into four groups, based on their **final adult size**:
  - ***Small CMN***: <1.5 cm (Fig. 92.11A)
  - ***Medium CMN***: 1.5–20 cm (Fig. 92.11B–E)
  - ***Large CMN***: >20–40 cm (in a neonate, large CMN are ≥9 cm on the head or ≥6 cm on the body)
  - ***Giant CMN***: >40 cm (Fig. 92.11F)
- ***Small*** or ***medium-sized CMN*** are usually solitary, can occur anywhere on the body, range in color from tan to black, and may have increased terminal hair growth (hypertrichosis).
- ***Giant CMN*** are sometimes referred to as "bathing suit" or "garment" nevi because of their distribution pattern; multiple smaller, widely disseminated "satellite" nevi are also commonly associated with these giant CMN.
- CMN grow proportionately with the child and over time can change from initially flat, evenly pigmented patches to elevated, mottled, pebbly or verrucous plaques; scalp CMN may lighten in color and gradually regress; papules or nodules can develop within the CMN, but signs of rapid growth, induration, or ulceration should raise suspicion for the development of melanoma and prompt a biopsy.
- CMN are a known risk factor for melanoma and neurocutaneous melanosis (NCM), with the absolute risk being associated with the severity of the cutaneous phenotype.
- The risk of developing melanoma within a small or medium-sized CMN is thought to be <1% over a lifetime; the risk for giant CMN is ~5%, with greater risk being a function of nevus size and number of satellite lesions; in giant CMN, the majority of melanomas develop in childhood (~50% in the first 5 years of life).
- Cutaneous melanomas can arise within the dermis or subcutaneous tissues of a CMN, making clinical diagnosis difficult.

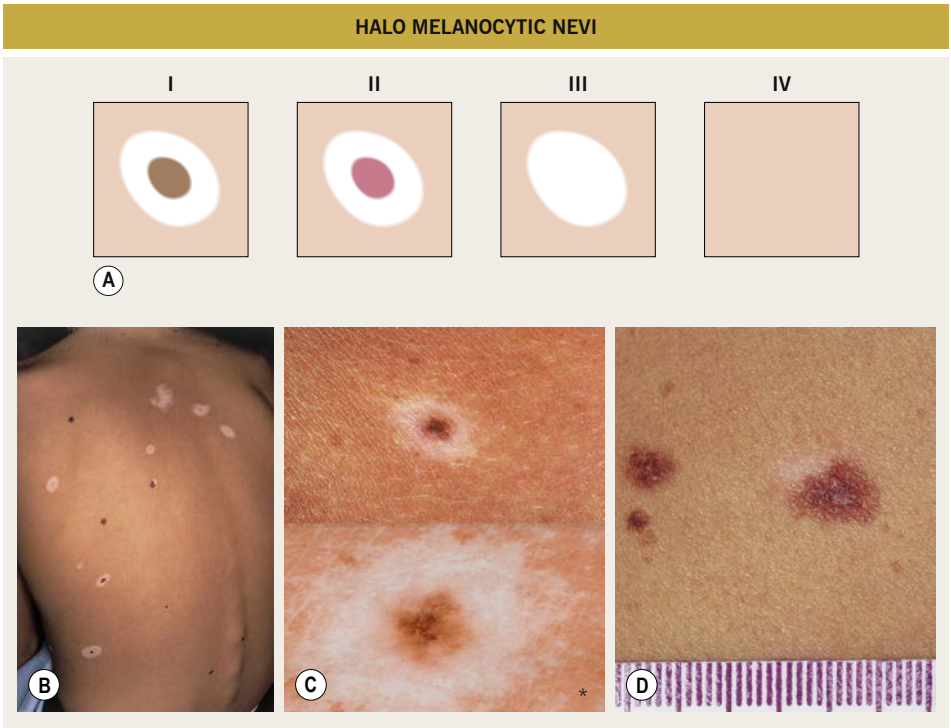


**Fig. 92.10 Halo melanocytic nevi. A** Four potential clinical stages in the life of a halo nevus. *Stage I*: central pigmented melanocytic nevus with a halo of depigmentation; *Stage II*: central nevus is pink with a halo of depigmentation; *Stage III*: no central nevus, just a depigmented macule; *Stage IV*: repigmentation (partial or complete). **B** Multiple halo nevi (seen here in all four of the various stages) are seen most commonly in children and young adults with numerous nevi. **C** Close-up of a halo nevus with a depigmented macular halo surrounding a central dark brown papule. Dermoscopically*, a symmetric white structureless area surrounding the remaining network of the nevus. **D** Asymmetric halos can also be seen, as in this photo surrounding a benign compound melanocytic nevus. *B, Courtesy, YDRSC; C, Courtesy, Harold Rabinovitz, MD; D, Courtesy, Jean L. Bolognia, MD.*

- Patients with a giant CMN in a posterior axial location that is associated with multiple satellite nevi (≥20) have the greatest risk of developing melanoma; although the melanoma can develop within the CMN itself (not the satellite lesions), the CNS, or the retroperitoneum, the primary site may remain unknown.
- In **neurocutaneous melanosis (NCM)**, also referred to as leptomeningeal melanocytosis, there is a proliferation of melanocytes in the CNS (as well as the skin); individuals with multiple (≥3, but usually 10–20+), disseminated medium-sized CMN are at greatest risk of NCM, followed by those with a giant CMN in a posterior axial location with multiple satellites.
- NCM-associated signs – e.g. hydrocephalus, seizures, developmental delay, increased intracranial pressure, cranial nerve palsies, sensorimotor defects, and hypotonia – tend to manifest by 2–3 years of age.
- An approach to the management of CMN is presented in Table 92.5 and Fig. 92.12.

## Nevus Spilus (Speckled Lentiginous Nevus [SLN])

- A subtype of congenital melanocytic nevus with a prevalence of ~2% in the general population.

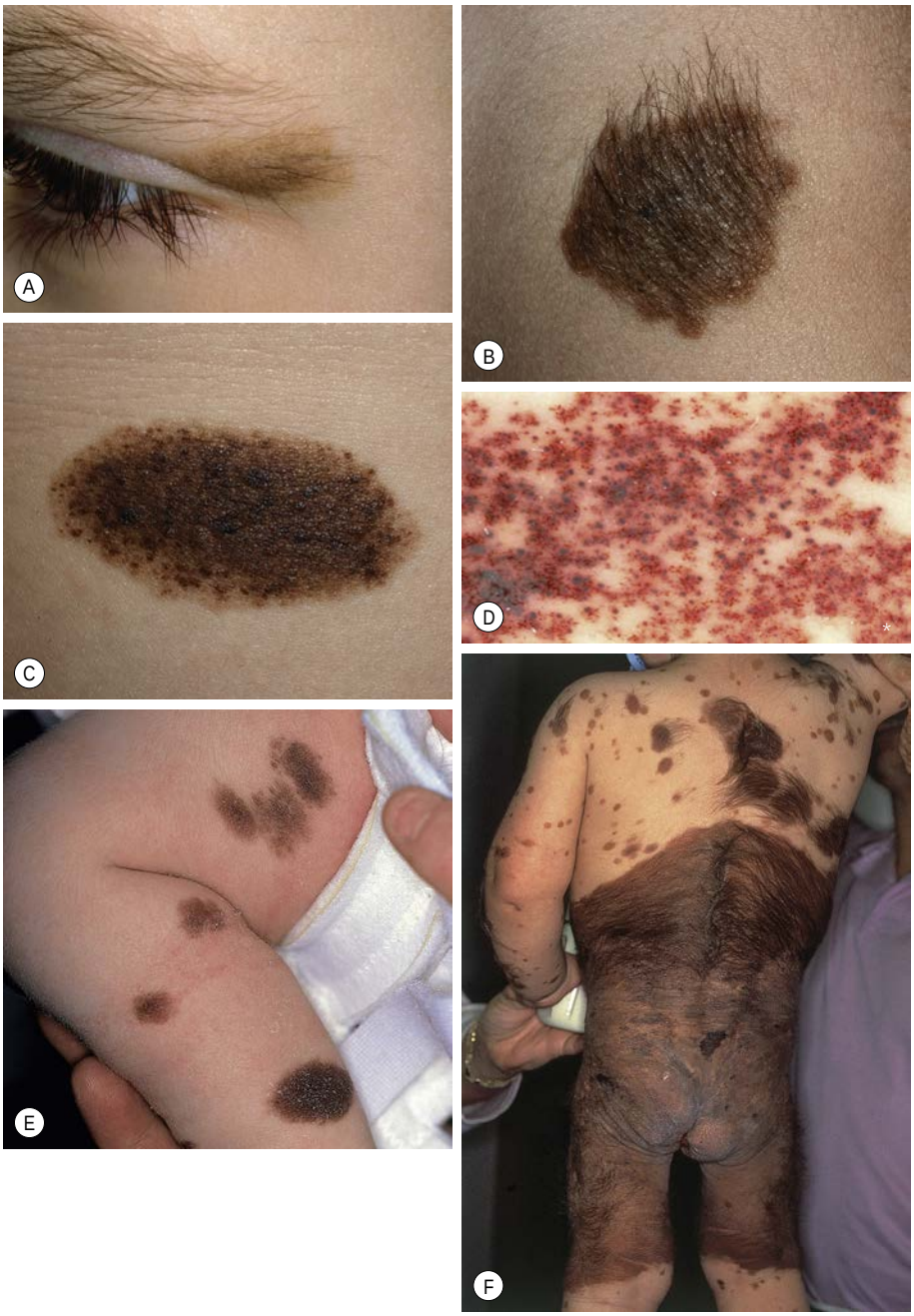


**Fig. 92.11 Congenital melanocytic nevi (CMN).** **A** Small CMN. Note the hypertrichosis and slight heterogeneity in pigmentation, reflecting its hamartomatous nature. **B, C** Medium-sized CMN, also with hypertrichosis and slight heterogeneity in pigmentation (**B**). Note the pebbly appearance on clinical examination (**C**) and the globular pattern with hyphae-like structures on dermoscopy* (**D**). **E** Multiple medium-sized CMN. This patient had 25–30 such lesions. This presentation can be associated with neurocutaneous melanosis (NCM). **F** Giant CMN, also called a "bathing suit" nevus. It is situated in a posterior axial location with numerous satellite nevi, some of which have hypertrichosis. This patient died of intractable ascites due to the migration of benign melanocytes from the brain to the peritoneal cavity via his VP shunt. In the perianal region, the nevus was softer and somewhat "boggy" due to neurotization. *A, Courtesy, Lorenzo Cerroni, MD; B, C, Courtesy, Julie V. Schaffer, MD; D, Courtesy, Raymond L. Barnhill, MD, and Harold S. Rabinovitz, MD; E, F, Courtesy, Jean L. Bolognia, MD.*

| APPROACH TO THE PATIENT WITH A SMALL OR MEDIUM-SIZED CONGENITAL MELANOCYTIC NEVUS (CMN) | |
|---|---|
| **Longitudinal evaluation*** | **Excision** |
| • No worrisome features | • Worrisome clinical or histopathologic features |
| • Observation is easy because of:<br>– Location<br>– Color<br>– Smooth surface and uniform texture | • Observation is difficult because of:<br>– Location (e.g. scalp)<br>– Color (e.g. black)<br>– Irregular or multinodular surface<br>– Dense hypertrichosis |
| • Parents/patient are:<br>– Motivated and knowledgeable<br>– Not anxious regarding the small chance (<1%) of melanoma<br>– Not concerned regarding cosmetic appearance | • Parents/patient are:<br>– Reluctant to observe<br>– Anxious regarding small chance (<1%) of melanoma<br>– Concerned regarding cosmetic appearance |
| *Includes baseline photography, measurements, and periodic skin examinations. | |

**Table 92.5 Approach to the patient with a small or medium-sized congenital melanocytic nevus (CMN).**

• Often presents at or around birth as a tan patch; over time numerous macules and papules develop within the tan patch, ranging from lentigines to junctional, compound and intradermal nevi to Spitz and blue nevi (Fig. 92.13).

• The risk of developing melanoma within the nevus spilus is thought to be similar to classic congenital melanocytic nevi of the same size range, but may be related to the type of nevi that develop within it.

• **DDx:** agminated nevus (see above); partial unilateral lentiginosis.

• Nevus spilus should be followed with periodic examinations, photography, and biopsies as clinically indicated.

For further information see Ch. 112 from *Dermatology, Fourth Edition*.

**For additional online figures and tables visit www.expertconsult.com**

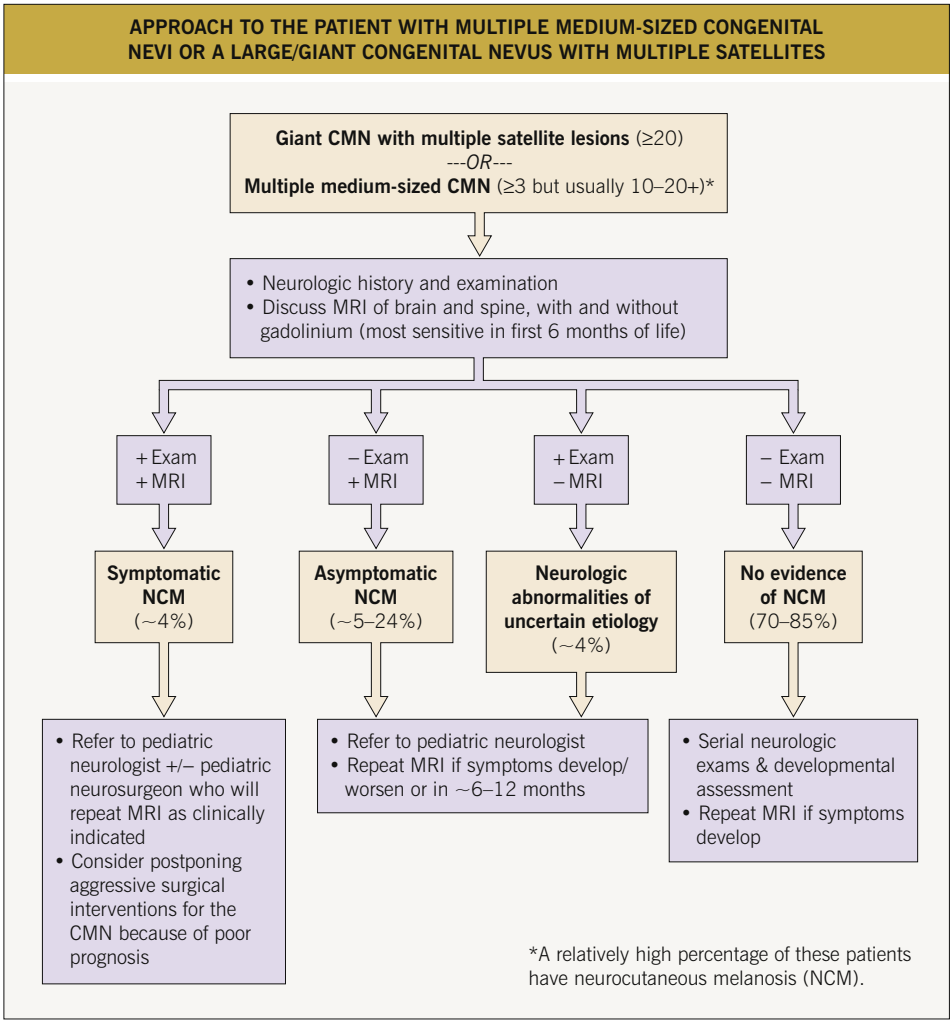


**Fig. 92.12 Approach to the patient with multiple medium-sized congenital nevi or a large/giant congenital nevus with multiple satellites.** CMN, congenital melanocytic nevus.

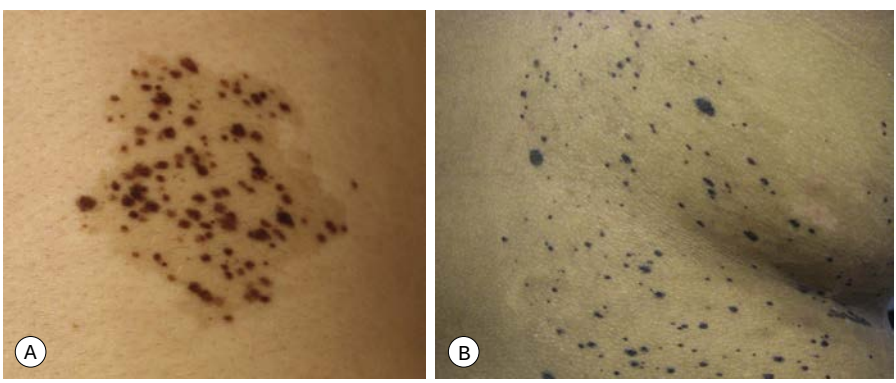


**Fig. 92.13 Nevus spilus (speckled lentiginous nevus). A** Multiple medium to dark brown macules and papules superimposed upon a tan patch. **B** Larger lesion of the lateral trunk with dark brown to black nevi of varying sizes; sometimes the tan background is subtle and not initially recognized. *Courtesy, Jean L. Bolognia, MD.*



**eFig. 92.1 Acral lentigines in a patient with Laugier–Hunziker syndrome.** Numerous lentigines on the palms. *Courtesy, Drs Tello Flores and Sanchez Felix.*

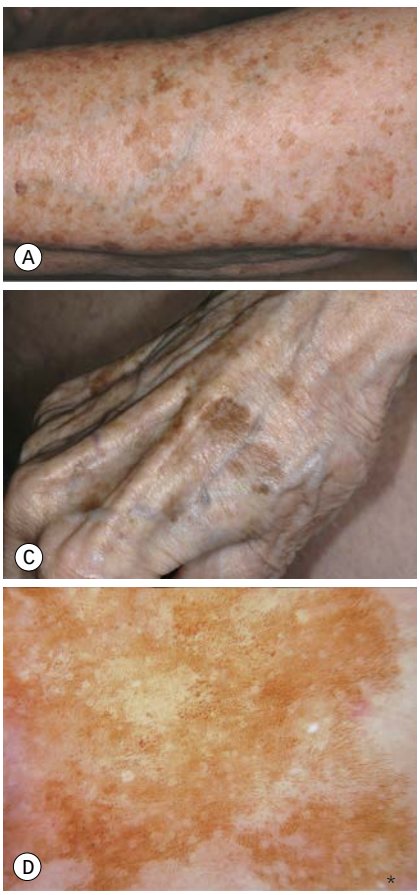


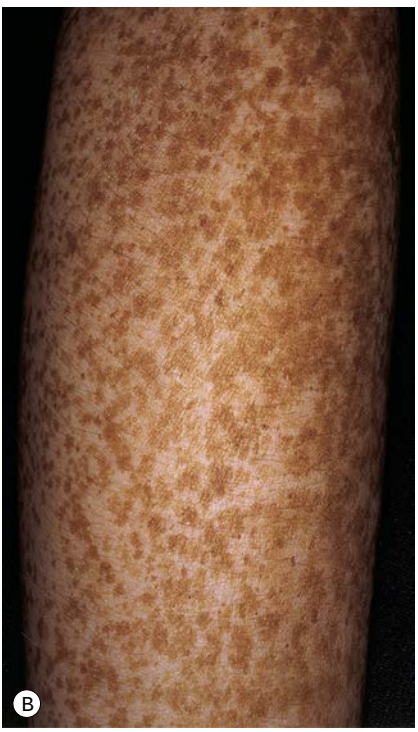


**eFig. 92.2 Solar lentigines. A, B** Numerous light brown macules, some of which have an irregular border, on chronically sun-exposed skin. **C** Sharply demarcated, uniform, tan macules on sun-exposed skin. **D** Dermoscopically*, moth-eaten borders, fingerprinting, and a reticular pattern with thin lines, short and interrupted. *A, Courtesy, Raymond Barnhill, MD; B, Courtesy, Jean L. Bolognia, MD; C, D, Courtesy, Harold Rabinovitz, MD.*



**eFig. 92.3 Café-au-lait macules (CALMs).** Typical CALM with well-defined and regular margins in a patient with neurofibromatosis 1. *Courtesy, Julie V. Schaffer, MD.*



**eFig. 92.5 Becker melanosis (nevus).** Unilateral hyperpigmented patch of the upper chest with confluence centrally and an irregular broken-up border. Acneiform lesions were limited to the lesion in this prepubescent boy. *Courtesy, Julie V. Schaffer, MD.*

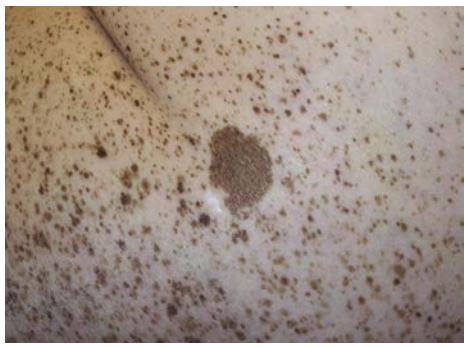

**eFig. 92.4 Café-noir lesion in a patient with Carney complex.** When compared to uninvolved skin, café-noir lesions are a darker shade than CALMs. *Courtesy, Jean L. Bolognia, MD.*

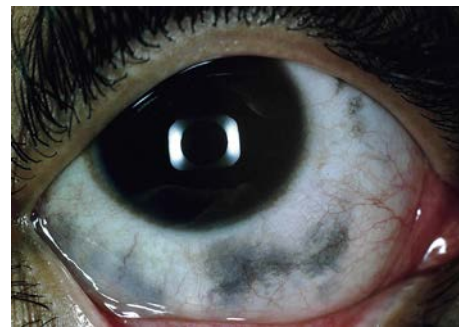

**eFig. 92.6 Nevus of Ota – ocular involvement.** Blue discoloration of the sclera. *Courtesy, Jean L. Bolognia, MD.*




**eFig. 92.7 Blue nevus – clinical features.** **A, B** *Common blue nevi* – well-circumscribed, blue-black flat papules. *A, Courtesy, Iris Zalaudek, MD and Giuseppe Argenziano, MD; B, Courtesy, Julie V. Schaffer, MD.*

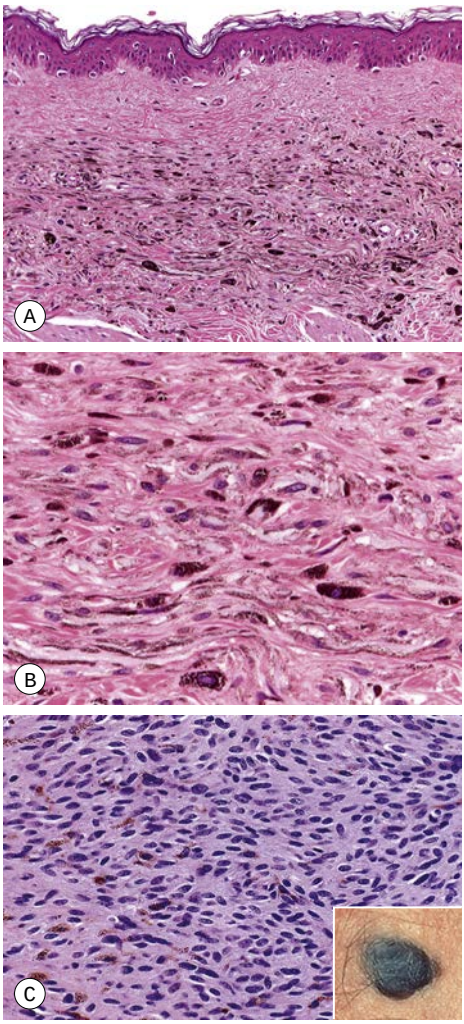


**eFig. 92.8 Blue nevus – histopathologic features.** **A, B** *Common blue nevus* with heavily pigmented, spindle-shaped melanocytes as well as melanophages within the dermis; the melanocytes are denser than in the dermal melanocytosis or nevus of Ota. **C** *Cellular blue nevus*. Plump spindled melanocytes devoid of melanin pigment and arranged within bundles are present within the dermis. Scattered melanin-containing melanophages are also present. A firm blue plaque is a common presentation (inset). *Courtesy, Lorenzo Cerroni, MD; Inset, Courtesy, Jean L. Bolognia, MD.*

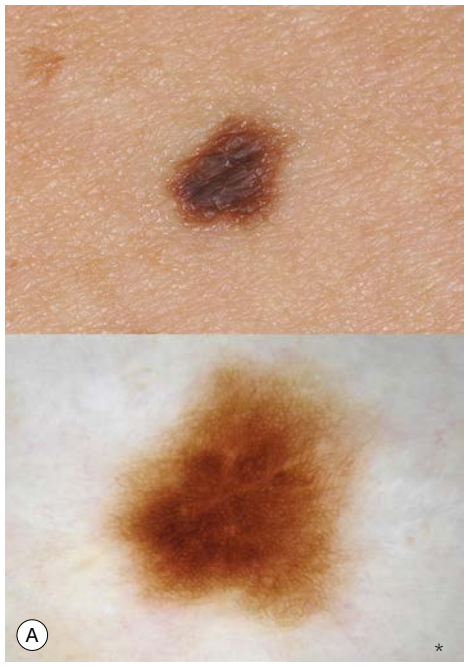





**eFig. 92.9 Common acquired melanocytic nevi. A** *Junctional nevus* – clinically, a brown macule with central hyperpigmentation. Dermoscopically*, a uniform pigment network. **B** *Intradermal nevus* – clinically, a light tan, soft, raised papule. Dermoscopically*, focal globular-like structures, whitish structureless areas, and fine comma vessels. *Courtesy, Harold Rabinovitz, MD.*




**eFig. 92.10 Melanocytic nevus of acral skin.** A brown macule on the sole of the foot. Dermoscopically*, a lattice-like pattern. *Courtesy, Harold Rabinovitz, MD.*



**eFig. 92.11 Longitudinal melanonychia due to a benign melanocytic nevus of the nail matrix.** Note the pseudo-Hutchinson sign. *Courtesy, Julie V. Schaffer, MD.*

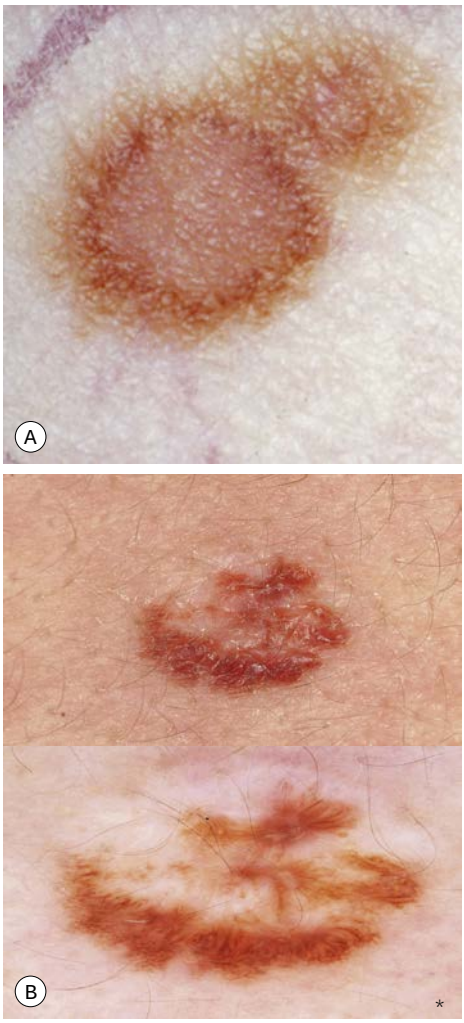


**eFig. 92.12 Other "specially named" nevi.** **A** Eclipse nevus – a tan center and thinner brown rim; note the stellate appearance of the brown rim. **B** Recurrent melanocytic nevus. A brown papule with areas of scarring. Dermoscopically*, asymmetric pigmentation within the confines of the scar. *A, Courtesy, Jean L. Bolognia, MD; B, Courtesy, Harold Rabinovitz, MD.*

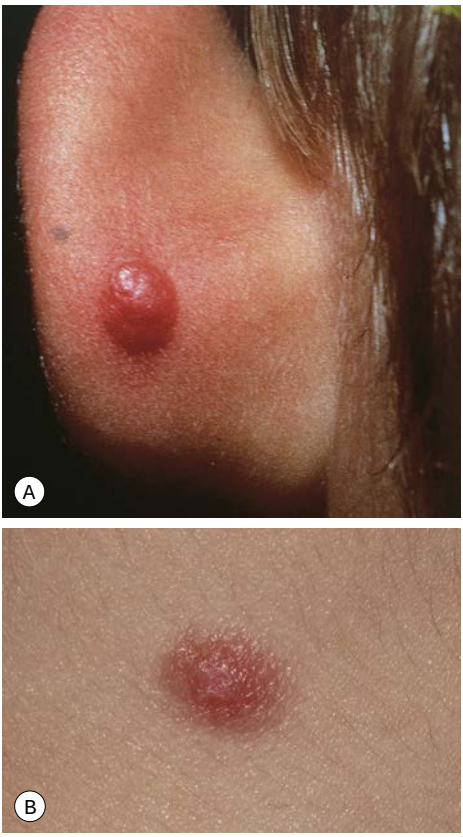


**eFig. 92.13 Spitz nevi – clinical features.** **A** Red dome-shaped papule on the ear of a child. **B** Pink symmetric papule in a child. *A, Courtesy, Ronald P. Rapini, MD; B, Courtesy, Julie V. Schaffer, MD.*



**eFig. 92.14 Agminated Spitz nevi.** The grouped papules have arisen on normally pigmented skin. *Courtesy, Raymond L. Barnhill, MD.*

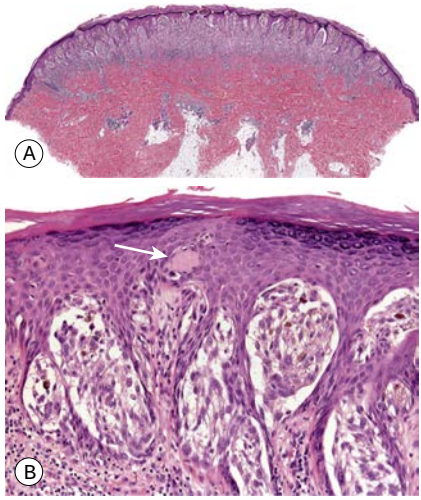


**eFig. 92.15 Spitz nevus – histopathologic features. A** Dome-shaped with sharply demarcated and symmetric proliferation of spindled and epithelioid melanocytes at the dermal–epidermal junction and within the papillary dermis; there is also regular epidermal hyperplasia. **B** Nests of cohesive spindled and epithelioid melanocytes with clefts between the nests and the hyperplastic epidermis. Note a "Kamino body" (arrow). *Courtesy, Lorenzo Cerroni, MD.*

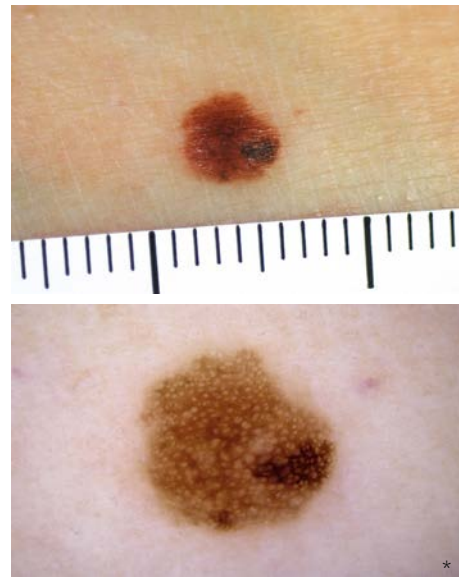


**eFig. 92.16 Clinically atypical melanocytic nevus.** The dermoscopy* pattern is reticular-disorganized and can be seen with uncertain lesions. *Courtesy, Harold Rabinovitz, MD.*

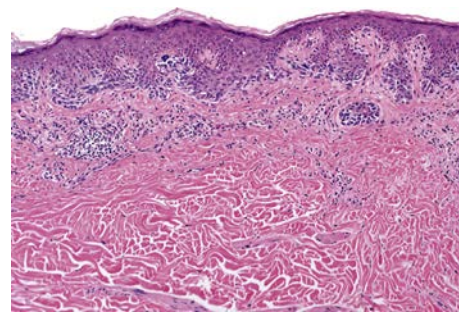

**eFig. 92.17 Atypical melanocytic nevus – histopathologic features.** Note confluent nests of melanocytes at the dermal–epidermal junction and scattered solitary melanocytes in the lower portion of the epidermis. *Courtesy, Lorenzo Cerroni, MD.*

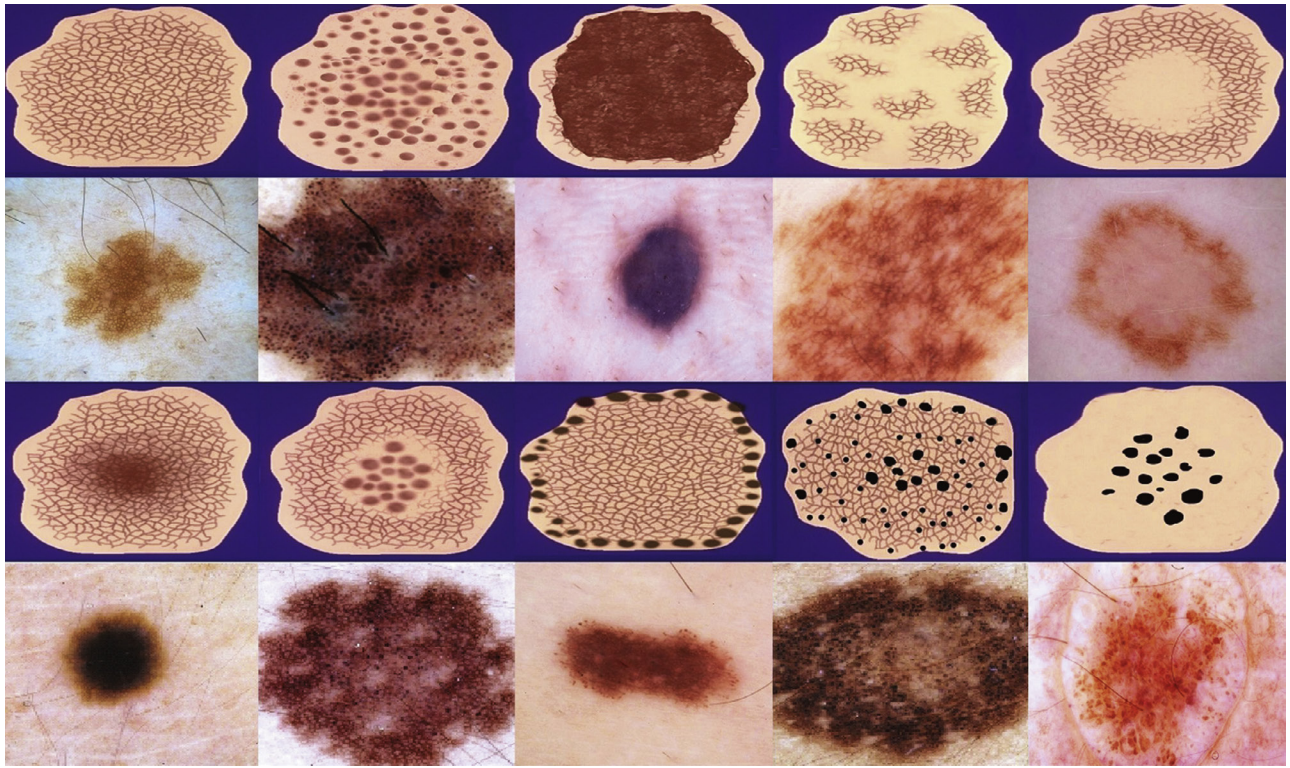

**eFig. 92.18 Atypical melanocytic nevi with dermoscopic patterns commonly seen in benign melanocytic nevi.** *Courtesy, the AAD Dermoscopy Group.*



Downloaded for Novin lib (novinlibrary@yahoo.com) at United Arab Emirates University from ClinicalKey.com by March 26, 2022. For personal use only. No other uses without permission. Copyright ©2022. Elsevier Inc. All rig

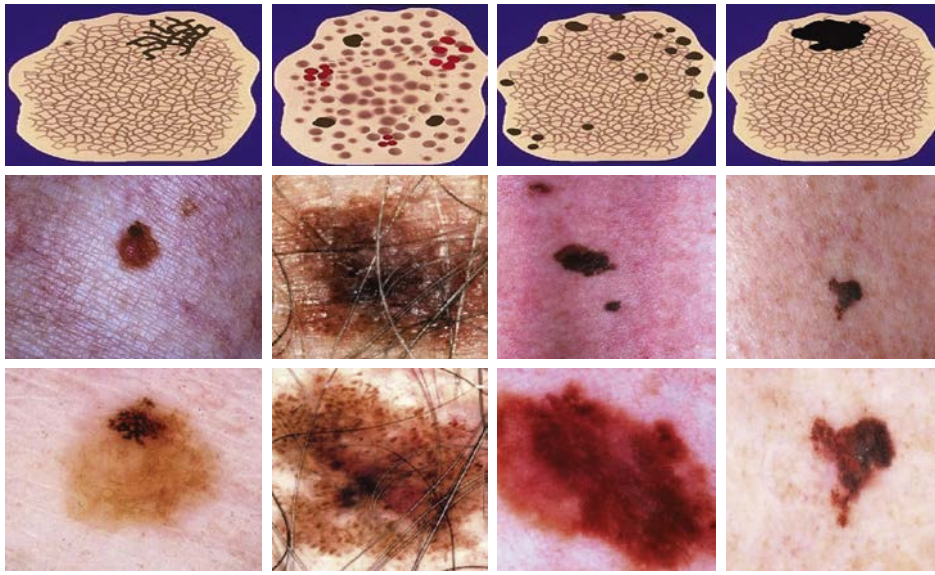

**eFig. 92.19 Atypical melanocytic nevi with dermoscopic patterns often associated with melanoma.** From top to bottom, schematic, normal illumination, and dermoscopy. *Courtesy, the AAD Dermoscopy Group.*

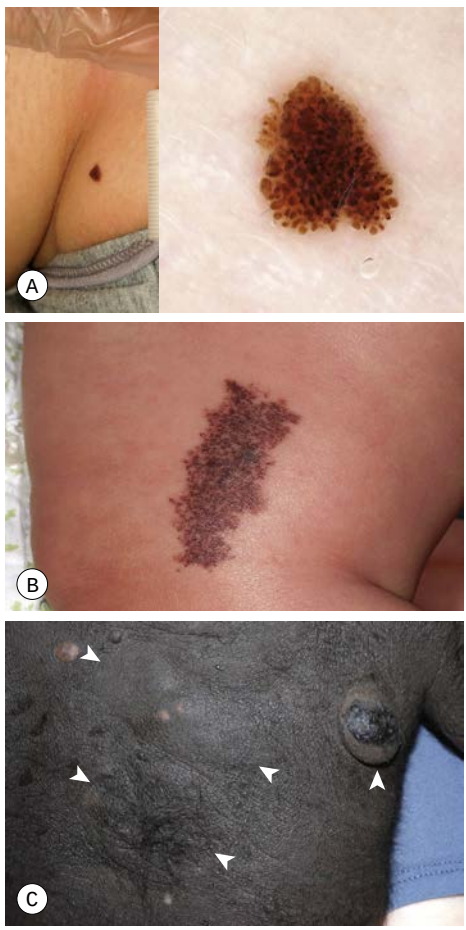


**eFig. 92.20 Congenital melanocytic nevi (CMN). A** Small congenital nevus with a globular pattern. **B** Medium-sized CMN. Note the pebbly appearance on clinical examination. **C** Several areas of "neurotization" within a giant CMN. The edges of the boggy plaques or nodules are demarcated by arrowheads. This phenomenon should not be confused with how cells of acquired nevi can display a neuroid differentiation within conventional intradermal nevi, sometimes characterized by Schwann cell-like features. *A, Courtesy, Iris Zalaudek, MD and Giuseppe Argenziano, MD; B, Courtesy, Raymond L. Barnhill, MD, and Harold S. Rabinovitz, MD; C, Courtesy, Julie V. Schaffer, MD.*

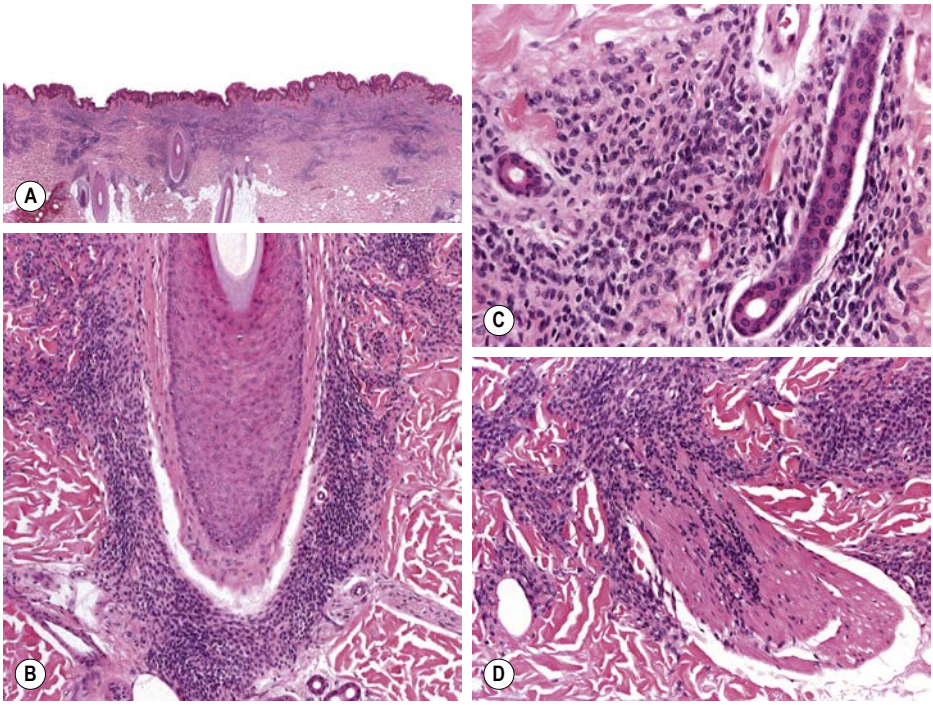


**eFig. 92.21 Congenital melanocytic nevus – histopathologic features. A** Scanning view with complexes of nevus cells extending into the deep reticular dermis and down adnexal structures. Melanocytes surround a half follicle (**B**), extend along eccrine ducts (**C**), and surround and infiltrate an arrector pili muscle (**D**). *Courtesy, Lorenzo Cerroni, MD.*




**eFig. 92.22 Nevus spilus (speckled lentiginous nevus). A** Multiple brown macules and papules superimposed upon a tan patch. **B** The "speckles" can be larger and resemble small and medium-sized congenital nevi. The larger lesions were present at birth while the smaller nevi have appeared over time. *A, Courtesy, Raymond L. Barnhill, MD and Harold S. Rabinovitz, MD; B, Courtesy, Jean L. Bolognia, MD.*

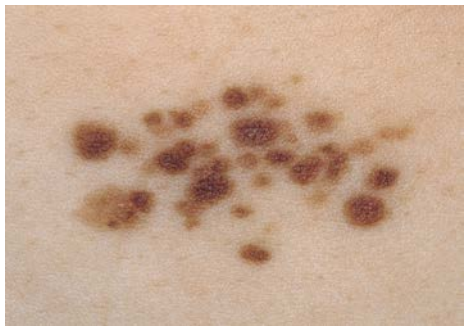

**eFig. 92.23 Agminated melanocytic nevi.** Grouped brown macules and papules in the absence of background hyperpigmentation, thus distinguishing it from a nevus spilus (speckled lentiginous nevus). *Courtesy, Jean L. Bolognia, MD*

**COMPARATIVE CLINICAL FEATURES OF EPHELIDES AND SOLAR LENTIGINES**

| | Ephelides (freckles) | Solar lentigines |
|---|---|---|
| **Epidemiology** | | |
| Age of appearance | Early childhood | By 20–30 years (I, II) |
| Skin color | Light pigmentation | Light to dark pigmentation |
| Hair color | Often red or blond hair | Any type |
| Skin phototype | More common in I, II | More common in I and II, but also in III and IV |
| **History** | | |
| Precipitating factors | Bursts of high-intensity sun exposure activate latent predetermined melanocytes, leading to permanent freckles | Repeated sun exposure over time alters melanocytes within a circumscribed area to overproduce melanin |
| Duration of lesions | Fade without sun exposure | Persist for life |
| Relation to season | Much darker in summer, fade in winter and over time with aging | May darken in summer but do not fade in winter |
| Heredity | Probably AD; also AR when related to *MC1R* variants | No data |
| **Physical examination** | | |
| Type of lesion | Macule | Macule |
| Size | 1–5 mm | 5–15 mm or larger |
| Color | Light or medium brown | Medium or dark brown |
| Shape | Oval to irregular | Oval to irregular |
| Border | Smooth to jagged | Smooth to jagged |
| Distribution | Favor the face, extensor forearms, and back; rare on the dorsal aspect of the hands | Sites of chronic sun exposure, especially the face, arms (including dorsal aspect of the hands), and upper trunk |
| **Dermoscopic features** | | |
| | Uniform pigmentation and a moth-eaten edge | Diffuse light brown structureless areas, sharply demarcated and/or moth-eaten borders, fingerprinting, and a reticular pattern with thin lines that are occasionally short and interrupted |

**eTable 92.1 Comparative clinical features of ephelides and solar lentigines.** I, II, III, IV = skin phototypes (see Appendix); AD, autosomal dominant; AR, autosomal recessive; MC1R, melanocortin-1 receptor.

| GENETIC SYNDROMES ASSOCIATED WITH NUMEROUS ACQUIRED MELANOCYTIC NEVI |
|---|
| Familial atypical mole and melanoma syndrome* |
| BAP1 cancer syndrome – atypical epithelioid nevi/tumors, uveal melanomas, mesothelioma |
| Carney complex (NAME/LAMB syndromes) |
| Turner syndrome – webbed neck, congenital lymphedema (partial or complete loss of X chromosome in females) |
| Noonan syndrome (mutations in multiple genes including *PTPN11*, *RAF1*, *KRAS*, *SOS1*) > other RASopathies (e.g. LEOPARD [Noonan with multiple lentigines] syndrome, cardiofaciocutaneous syndrome, Costello syndrome) |
| Ectrodactyly, ectodermal dysplasia, and cleft lip/palate syndrome (EEC syndrome; *TP63* mutations) |
| Goeminne syndrome – torticollis, keloids, cryptorchidism, and renal dysplasia |
| Kuskokwim syndrome – congenital joint contractures, skeletal deformities (*FKBP10* mutations) |
| Mulvihill Smith syndrome – progeroid short stature with pigmented nevi |
| Trichorhinophalangeal syndrome type II (Langer–Giedion syndrome) |
| Tricho-odonto-onychial dysplasia |
| **OMIM designation is "Susceptibility to cutaneous melanoma".* |

**eTable 92.2 Genetic syndromes associated with numerous acquired melanocytic nevi.**

| TRIGGERS FOR THE DEVELOPMENT AND/OR GROWTH OF MELANOCYTIC NEVI |
|---|
| **Exposure to ultraviolet light** |
| Sun exposure leading to multiple or severe sunburns*<br>Intermittent intense sun exposure (e.g. on sunny holidays)<br>Chronic moderate sun exposure (e.g. residence at lower latitudes)<br>Neonatal phototherapy |
| **Blistering processes (other than severe sunburns)** |
| Toxic epidermal necrolysis/Stevens–Johnson syndrome*<br>Epidermolysis bullosa – junctional (particularly generalized atrophic benign) > recessive dystrophic > recessive simplex*<br>Bullae secondary to sulfur mustard (mustard gas) exposure* |
| **Scarring processes** |
| Genital lichen sclerosus† |
| **Systemic immunosuppression** |
| Chemotherapy, particularly for childhood hematologic malignancies*,†,‡<br>Allogeneic bone marrow transplantation‡<br>Solid organ transplantation, particularly renal and with the use of azathioprine*,‡<br>HIV infection/AIDS*<br>Chronic myelogenous leukemia*<br>TNF inhibitor therapy*,‡<br>Cyclosporine, azathioprine* |
| **Increased hormone levels** |
| Pregnancy*,§<br>Growth hormone (increased size, not number, of nevi)<br>Addison disease*<br>Thyroid hormone*<br>α-Melanocyte stimulating hormone analogue (afamelanotide)* |

**eTable 92.3 Triggers for the development and/or growth of melanocytic nevi.** *Continued*

| TRIGGERS FOR THE DEVELOPMENT AND/OR GROWTH OF MELANOCYTIC NEVI |
|---|
| **Other** |
| Sorafenib, vemurafenib, sunitinib, encorafenib, radotinib, regorafenib, nilotinib* |
| Atopic dermatitis in children (conflicting results in different studies) |
| Postoperative fever* |
| Seizures or electroencephalographic abnormalities* |
| **Eruptive nevi have been reported.* |
| *†An increased number of atypical nevi may also be seen.* |
| *‡Nevi have a predilection for the palms and soles.* |
| *§Relative immunosuppression may also play a role; an increase in the size or number of nevi has not been clearly demonstrated for pregnant women in general. Melanoma may grow at an accelerated pace during pregnancy.* |

**eTable 92.3** *Continued* **Triggers for the development and/or growth of melanocytic nevi.**
*Adapted from Schaffer JV, Bolognia JL. The biology of melanocytic nevi. In: Nordlund JJ, Boissy RE, Hearing VJ, et al. (eds). The Pigmentary System: Physiology and Pathophysiology, 2nd edn. Oxford: Blackwell Publishing, 2006:1092–125.*

| ACRAL NEVI – COMMON DERMOSCOPIC PATTERNS | |
|---|---|
| **Pattern** | **Dermoscopy features** |
| Parallel furrow (most common) | Parallel rows of linear pigmentation along furrows/valleys (sulci of the surface skin markings) |
| Lattice-like | Parallel furrows plus lines of pigmentation crossing the parallel lines |
| Fibrillar | Densely packed, fine parallel lines of pigmentation, often set in a direction that crosses the skin markings |

**eTable 92.4 Acral nevi – common dermoscopic patterns.**

| COMPARISON OF SPITZ NEVUS AND MELANOMA | | |
|---|---|---|
| **Parameter** | **Spitz nevus** | **Melanoma** |
| Age | Young age, especially prepubertal, favors a benign process | Exceedingly rare in pre-pubertal children; outnumber Spitz nevi in patients >30 years of age |
| Anatomic site | May occur anywhere, but favor the lower extremities and particularly in children the head and neck region | Most often on the trunk (back) in men and distal lower extremities in women; favor intermittently sun-exposed skin, but may occur anywhere |
| Size | Often <5–6 mm, usually <10 mm | Often >6 mm, but early lesions may be smaller; large size favors melanoma |
| Symmetry | Usually symmetric | Increasing asymmetry favors melanoma |
| Architecture | Dome-shaped, plaque-like, wedge-shaped in dermis, plexiform | Heterogeneous and complex (with exceptions) |
| Circumscription | Usually well demarcated with peripheral junctional nests | Often poorly demarcated ending in single-cell patterns |
| Epidermal features | Regular hyperplasia; intraepidermal eosinophilic globules common, numerous, and large-sized | Irregular epidermal pattern; intraepidermal eosinophilic globules uncommon, few in number, and small-sized |
| Maturation | Overall reduction in cellular density with depth; orderly dispersion and regular spacing of nests and cells among collagen bundles with depth; nests become progressively smaller, finally resulting in single melanocytes at the base of lesion; cells and nuclei also diminish in size with depth; maturation may be absent in a subset of Spitz nevi | Little or no maturation; confluence of melanocytes is not lost with depth; irregular spacing and disorderly arrangements of cells |
| Pagetoid spread | Less frequent than in melanoma; orderly; often confined to the epidermis over the central part of the lesion; nested patterns may be more frequent than single cells | Common; disorderly; the melanoma cells often reach the granular layer; higher cellular density |
| Zonation | Uniformity of cytologic features across horizontal strata of lesion | Heterogeneity of features |
| Mitotic figures in dermal component | Limited in number, superficial, usually not atypical | Greater in number, deeply located, atypical |
| Cytologic features | Abundant ground-glass or opaque cytoplasm; polyangular, rhomboidal; occasional dendrites | Variable amount of cytoplasm; often granular or “dusty” and abundant in epithelioid cells; scant cytoplasm in spindled cells |
| Nuclear features | Enlarged nuclei; uniform dispersed chromatin pattern; nucleoli may be prominent but usually uniform; reniform, multilobulated, multinucleate and giant bizarre forms occur | Pleomorphism; often high nuclear to cytoplasmic ratios; hyperchromatism; prominent variable nucleoli commonly multiple; thickened nuclear membranes |

**eTable 92.5 Comparison of Spitz nevus and melanoma.**

| MELANOCYTIC NEVUS PHENOTYPES | | |
|---|---|---|
| | **Common pattern** | **Atypical pattern** |
| Number | None to few (<25) nevi | Many (>50) nevi |
| Size | <5 mm | Variable: small to large, often several >5 mm |
| Color | Uniform, homogeneous color | Some to many melanocytic nevi with irregular or haphazard color, erythema within the nevus |
| Borders | Well circumscribed | Irregular or ill-defined borders |

**eTable 92.6 Melanocytic nevus phenotypes.**

| MANAGEMENT OF CHILDREN WITH GIANT CONGENITAL MELANOCYTIC NEVI |
|---|
| **Surgical excision versus long-term clinical examination** |
| Consider surgical excision of the nevus (staged and/or with tissue expanders), typically in children at least 6 months of age in order to avoid the period of highest general anesthesia risk<br>If not excised or partial excision, lifelong examination of the nevus (including palpation) every 6 to 12 months plus baseline photography<br>Histologic examination of enlarging firm papulonodules and new areas of induration or ulceration* |
| **MRI of head and spine for the detection of neurocutaneous melanosis† (NCM) and other CNS abnormalities‡** |
| Risk factors for NCM<br>• multiple satellite lesions (≥20)§<br>• giant/"garment" nevus (>40 cm projected adult size)<br>• posterior axial location (in some but not all studies)<br>If no risk factors and no neurologic symptoms, MRI not necessary<br>If at least one risk factor but asymptomatic, MRI should be considered prior to 4–6 months of age for highest sensitivity<br>In asymptomatic patients with intermediate risk (e.g. <10–20 satellites, 20–40 cm nevus as an adult), MRI can be considered on a case-by-case basis<br>Patients with symptomatic NCM should have MRI performed |
| **Ulceration at birth or during the first week of life in areas prone to trauma may be due to immaturity of the skin but should heal over a few weeks.*<br>*†Also referred to as neurocutaneous melanocytosis.*<br>*‡Need to check renal function given association with genitourinary malformations.*<br>*§Highest risk of NCM in those with multiple satellite nevi but no giant congenital nevus.* |

**eTable 92.7 Management of children with giant congenital melanocytic nevi (GCMN).**

# 93 Cutaneous Melanoma

- A malignant tumor of melanocytes, most commonly arising from cutaneous melanocytes; can also develop from melanocytes residing elsewhere – e.g. in the uveal tract, retinal pigment epithelium, gastrointestinal mucosa, or leptomeninges.
- Some cutaneous melanomas (CMs) arise *de novo*, whereas others arise within precursor lesions (e.g. melanocytic nevi; see Ch. 92).
- Tremendous advances have been made in understanding the molecular pathways and mutations from which many CMs originate, resulting in identification of genetic markers, tools for aiding in the histopathologic diagnosis, and targeted treatments for CM (Figs 93.1 and 93.2; see Table 93.14).

## Epidemiology

- There has been a marked increase in the incidence of CM, especially thinner lesions, during the past 40–50 years, with a modest increase in mortality, primarily in older men (Fig. 93.3).
- Death occurs at a younger age than for most other cancers.
- Risk factors are divided into three major groups: genetic, environmental, and phenotypic (Table 93.1).

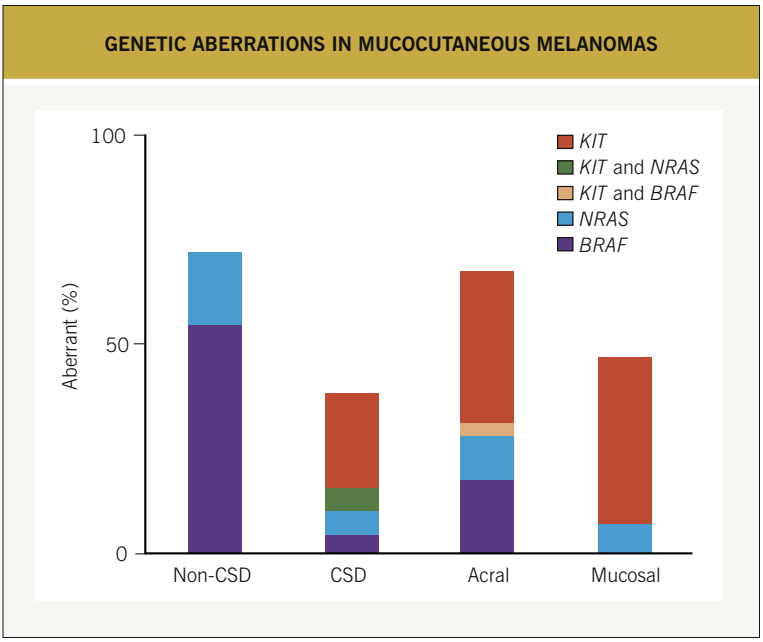


**Fig. 93.1 Genetic aberrations in mucocutaneous melanomas.** Of melanomas with somatic mutations in *BRAF*, at least 80% lead to substitution of glutamic acid (E) for Valine (V) at codon 600, i.e. V600E. CSD, skin with chronic sun-induced damage such as marked solar elastosis; non-CSD, skin without chronic sun-induced damage. *From Curtin JA, Busam K, Pinkel D, Bastian BC. J Clin Oncol 2006;24:4340–6.*

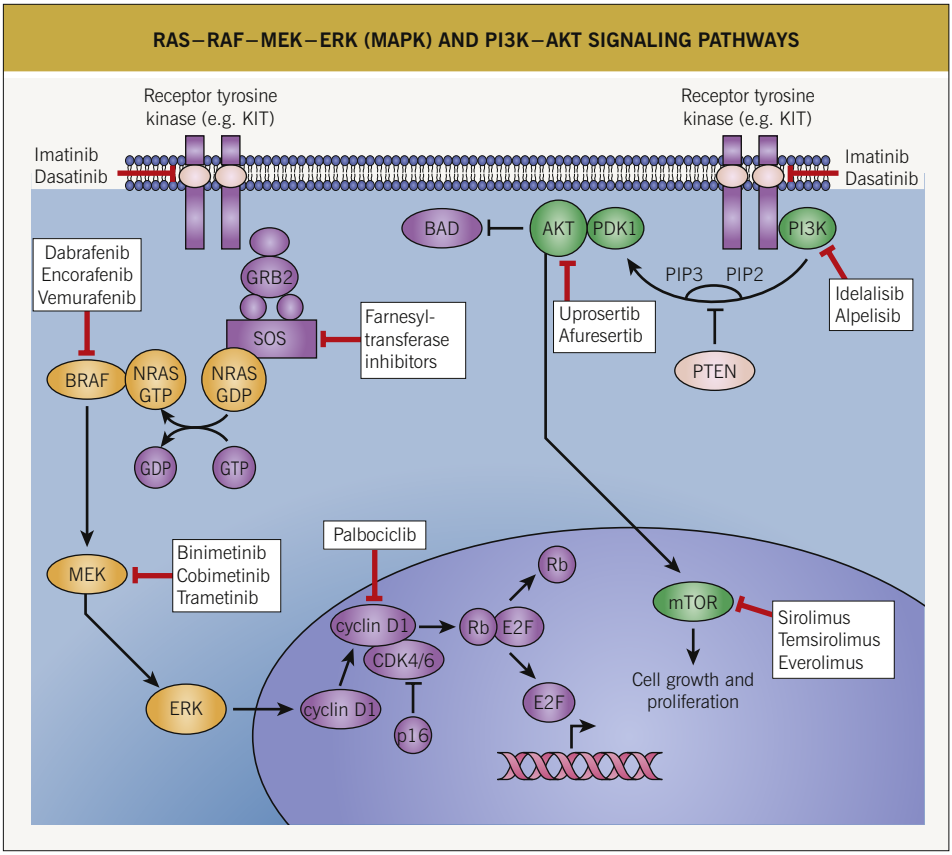


**Fig. 93.2 RAS–RAF–MEK–ERK (MAPK) and PI3K–AKT signaling pathways.** The *m*itogen-*a*ctivated *p*rotein *k*inase (MAPK) pathway (orange color), also referred to as the MAP kinase pathway, is physiologically activated by growth factor binding to receptor tyrosine kinases. The stimulus is relayed to the nucleus via the GTPase activity of NRAS and the kinase activity of BRAF, MEK, and ERK. Within the nucleus, this results in increased transcription of genes involved in cell growth, proliferation and migration. The central role of this pathway in melanocytic neoplasia is highlighted by the fact that either *NRAS* or *BRAF* is mutated in ~80% of all cutaneous melanomas and melanocytic nevi. The PI3K–AKT pathway is another important regulator of cell survival, growth, and apoptosis (green color). A key inhibitor of this pathway is PTEN, and inactivation of the gene that encodes PTEN via mutations, deletions, or promoter methylation also occurs in cutaneous melanomas. As a result, there is increased activity of the PI3K–AKT signaling pathway. Examples of farnesyltransferase inhibitors are tipifamib and ionafamib. BAD, BCL-2 associated agonist of cell death; CDK, cyclin-dependent kinase; E2F, transcription factor that controls transcription of cyclins; ERK, extracellular signal-regulated kinase; GDP, guanosine-5′-diphosphate; GRB2, growth factor receptor-bound protein 2, an adaptor protein that contains one Src homology 2 (SH2) domain and two SH3 domains; GTP, guanosine-5′-triphosphate; MEK, MAPK kinase; mTOR, mammalian target of rapamycin (aka sirolimus); p16, protein product of *CDKN2A*; PDK1, phosphoinositide-dependent kinase-1; PI3K, phosphoinositide 3-kinase; PIP2, phosphatidylinositol 4,5-bisphosphate; PIP3, phosphatidylinositol 3,4,5-triphosphate; PTEN, phosphatase and tensin homolog; Rb, retinoblastoma protein; SOS, son of sevenless.

- Approximately 10% of melanomas are familial, and germline mutations have been detected in several melanoma-dominant genes (e.g. *CDKN2A, CDK4*) as well as genes responsible for a more general predisposition to malignancies ("mixed cancer syndromes" such as Lynch and Li–Fraumeni; Tables 93.2 and 93.3).
- Primary prevention: sun protective measures, avoidance of tanning beds.

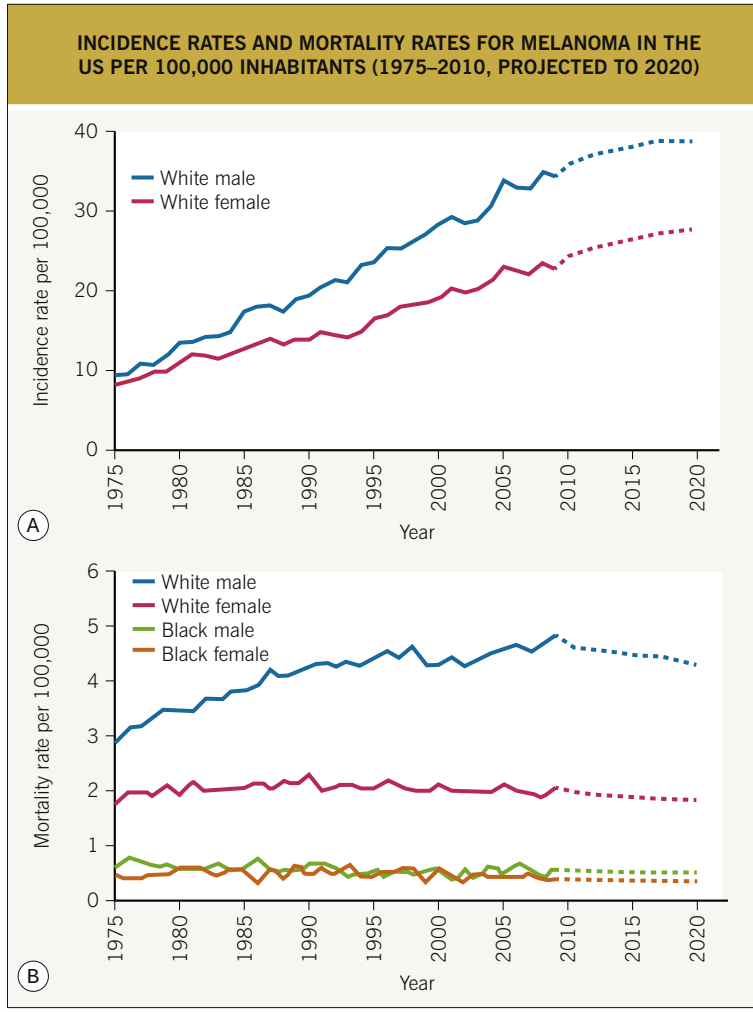


**Fig. 93.3 Incidence rates and mortality rates for melanoma in the US per 100,000 inhabitants (1975–2010, projected to 2020). A,B** While the incidence has increased significantly in white men and women over the past four decades, there has been a modest increase in mortality in white men. *Data from* www.cdc.gov/cancer/dcpc/research/articles/cancer_2020_incidence.htm.

• Secondary prevention: early detection, screening of higher-risk individuals.

## Clinical

• The clinical presentation of CM varies greatly; although the **ABCDE**s (**A**symmetry, **B**order irregularity, **C**olor variegation, **D**iameter >6 mm, **E**volution) are often used in public awareness campaigns to help promote the clinical recognition of CM, they have their shortcomings; to rectify this, the **EFG** rule (**E**levated, **F**irm, **G**rowing) has been added for nodular and amelanotic CMs.

• As banal nevi age, they also become more elevated, but in contrast to nodular CMs, they are soft to palpation.

• In CM *in situ* (MIS), the malignancy is confined to the epidermis and/or the hair follicle epithelium (Fig. 93.4); all types of CM (except for nodular melanoma) can have an *in situ* phase; *lentigo maligna* (Fig. 93.5) is a type of MIS that arises within chronically sun-damaged skin and can remain *in situ* for years to decades.

| RISK FACTORS FOR THE DEVELOPMENT OF CUTANEOUS MELANOMA |
|---|
| **Genetic factors** |
| • Family history of cutaneous melanoma (see Table 93.2)<br>• Family history of "mixed cancer syndrome" (see Table 93.2)<br>• Lightly pigmented skin<br>• Tendency to burn, inability to tan<br>• Red hair color<br>• DNA repair defects (e.g. xeroderma pigmentosum) |
| **Environmental factors** |
| • Intense intermittent sun exposure<br>• Chronic sun exposure<br>• Residence in equatorial latitudes<br>• PUVA (possible)<br>• Tanning bed use, especially under the age of 35 years<br>• Iatrogenic or acquired immunosuppression |
| **Phenotypic expressions of gene/environment interactions** |
| • Melanocytic nevi and solar lentigines:<br>– Increased total number of acquired melanocytic nevi (MN)<br>>100 MN, relative risk ~8- to 10-fold increased<br>– Atypical melanocytic nevi (AMN)<br>>5 AMN, relative risk ~4- to 6-fold increased<br>• Multiple solar lentigines (SL):<br>– Multiple SL, relative risk ~3- to 4-fold increased<br>– Relative risks (RR) are multiplicative: e.g. a person with >100 MN + >5 AMN + multiple SL has a relative risk ~10 × 5 × 3 = 150-fold<br>• Personal history of cutaneous melanoma |

**Table 93.1 Risk factors for the development of cutaneous melanoma.**

| FAMILIAL MELANOMA – DOMINANT AND SUBORDINATE SYNDROMES | | |
|---|---|---|
| **Susceptibility gene** | **Syndrome** | **Characteristic features (in addition to cutaneous melanoma)** |
| **Melanoma dominant syndromes – multiple & early-onset melanomas + strong family history of melanoma** | | |
| *CDKN2A/p16** | Familial atypical multiple mole–melanoma syndrome (FAMMM)<br>Melanoma–astrocytoma syndrome (MAS) | • Numerous nevi (>50), atypical nevi**, ≥1 first- or second-degree relative with melanoma<br>• Increased risk for pancreatic cancer<br>• CNS tumors (e.g. astrocytoma) |
| *CDK4* | Rare cases of FAMMM syndrome | • Similar presentation as patients with *CDKN2A* mutations |
| *BAP1* | BAP1 tumor syndrome | • Multiple "BAP-omas" – atypical melanocytic proliferations which appear clinically benign (e.g. dome-shaped, often pink papules) with histopathologically spitzoid features<br>• Uveal melanoma<br>• Mesothelioma, renal cell carcinoma, other internal malignancies |
| *MITF* (E318K) variant | MITF-related melanoma and renal cell carcinoma predisposition syndrome | • Often high atypical nevus count<br>• Early-onset melanoma<br>• Renal cell carcinoma, pancreatic carcinoma |

**Table 93.2 Familial melanoma – dominant and subordinate syndromes.** *Continued*

| FAMILIAL MELANOMA – DOMINANT AND SUBORDINATE SYNDROMES | | |
|---|---|---|
| **Susceptibility gene** | **Syndrome** | **Characteristic features (in addition to cutaneous melanoma)** |
| Shelterin complex genes (e.g. *POT1*, *ACD*, *TERF2IP*) | | • Early-onset and multiple primary melanomas<br>• Many different internal malignancies (e.g. breast, prostate, lung) |
| *TERT* | | • Numerous atypical nevi (possible)<br>• Hematologic malignancies and multiple types of internal malignancies |
| **Melanoma subordinate syndromes – in the context of a "mixed cancer syndrome"** | | |
| *BRCA1* and *BRCA2* | Hereditary breast and ovarian carcinoma syndrome (HBOC) | • Breast, ovarian, pancreatic, prostate cancers |
| *TP53* | Li–Fraumeni syndrome | • Childhood (e.g. sarcomas, leukemias, CNS) and multiple primary lifetime cancers (e.g. breast, others) |
| *PTEN* | Cowden syndrome/PTEN hamartoma tumor syndrome (see Table 52.1) | • Tricholemmomas, papillomatous papules, mucosal lesions, palmar–plantar keratosis<br>• Breast, thyroid, endometrial, and colorectal carcinomas |
| *RB* | Hereditary retinoblastoma | • Early onset, often bilateral, ocular retinoblastoma<br>• Pineoblastoma, osteosarcoma, soft tissue sarcomas |
| *MLH1, MSH2, MSH6, PMS2, EPCAM* | Lynch syndrome | • Colorectal, endometrial, stomach, breast and other cancers |
| **Other possible hereditary factors** | | |
| *MC1R* | | • Red hair, freckling, fair skin<br>• Childhood/adolescent melanomas |

*The major high-penetrance susceptibility gene locus associated with familial melanoma; MAS may be more linked to the functional loss of the *CDKN2A* gene product $p14^{ARF}$.
**Not all patients/families with *CDKN2A* mutation have numerous/atypical nevi.

**Table 93.2** *Continued* **Familial melanoma – dominant and subordinate syndromes.** About 45% of familial melanomas are due to an inherited mutation in a highly penetrant predisposition gene.

- There are four **major subtypes** of primary invasive CM, based on clinicopathologic features:
  - *Superficial spreading melanoma* (SSM; ~60% of melanomas) (Fig. 93.6)
  - *Nodular melanoma* (NM; ~20%) (Fig. 93.7)
  - *Lentigo maligna melanoma* (LMM; ~9%) (Fig. 93.8)
  - *Acral lentiginous melanoma* (ALM; ~4%) (Fig. 93.9)
- **Less common variants of CM:**
  - *Amelanotic melanoma*: color ranges from pink to red and any type of CM may be amelanotic (Fig. 93.10); children can develop amelanotic nodular CM, and the lesion may resemble a pyogenic granuloma or wart
  - *Nail matrix melanoma*: see Table 58.3 and Fig. 93.11

| SUGGESTED CRITERIA FOR REFERRAL TO A GENETICS COUNSELOR FOR A SUSPECTED FAMILIAL MELANOMA SYNDROME |
|---|
| **Suspected melanoma dominant syndrome*** |
| • Family history, defined as ≥3 affected members on 1 side of the family, of invasive melanoma or pancreatic cancer or CNS tumor (e.g. astrocytoma) or renal cell carcinoma |
| • ≥3 primary invasive melanomas, including 1 early-onset melanoma (≤45 years of age) |
| • ≥2 *BAP1*-mutated atypical melanocytic proliferations ("BAP-omas") |
| • ≥1 *BAP1*-mutated atypical melanocytic proliferations ("BAP-omas") + a family history of mesothelioma, meningioma, renal cell carcinoma, and/or uveal melanoma |
| **Suspected melanoma subordinate syndrome**** |
| • Personal history of melanoma + personal/family history of other malignancies that suggest a mixed cancer syndrome (e.g. breast, ovarian, prostate, pancreatic, colon; see Table 93.2) |
| **Familial cancer syndrome in which melanoma is the predominant cancer type, although other cancers may also be observed (see Table 93.2).*<br>***Familial cancer syndrome in which there is a lower risk of melanoma than that of other malignancies seen in the syndrome (see Table 93.2).* |

**Table 93.3 Suggested criteria for referral to a genetics counselor for a suspected familial melanoma syndrome.** Melanoma predisposition genes can be associated with other malignancies and other cancer predisposition genes can increase the risk of melanoma. A discussion regarding genetic counseling should be held with melanoma patients who have any of the proposed criteria in this table. HBOC, hereditary breast and ovarian cancer.

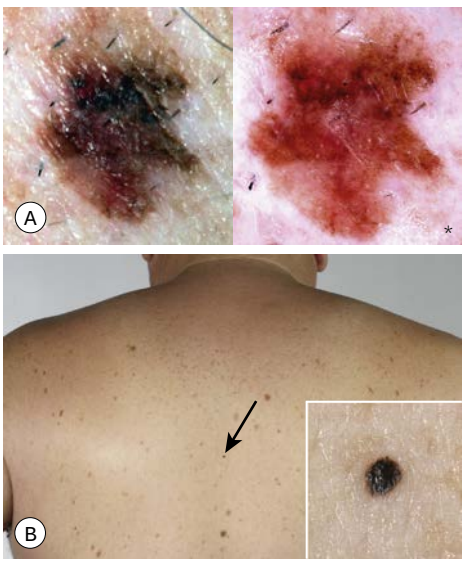


**Fig. 93.4 Melanoma *in situ*. A** Clinically, note the asymmetry, border irregularity, color variation, and erythema ("little red riding hood" sign); by dermoscopy*, findings include a broadened network, dots, and some globules. **B** This melanoma *in situ* measured less than 3 mm in diameter. Small melanomas can be easily overlooked, especially if they are less heavily pigmented. This lesion was the "ugly duckling" of all of this patient's nevi. Dermoscopy assists in making an earlier diagnosis. *Courtesy, Claus Garbe, MD.*

  - *Mucosal melanoma*: mouth (e.g. palate, gingiva), anus > nasopharynx, larynx, vagina; ~35% are amelanotic
  - *Desmoplastic* and *neurotropic melanomas*: skin-colored or pink > brown to black, firm nodule, usually in sun-exposed sites; may arise *de novo* or within a lentigo maligna; a deeper biopsy is necessary for diagnosis; local recurrence is a common problem
  - *Ocular melanoma:* divided into conjunctival or uveal melanomas, with a majority of the latter harboring *GNA11* or *GNAQ* mutations; partial or total loss of chromosome 3 portends a poor prognosis (*BAP1* is on its short arm)
- Childhood CM is rare; prepubertal patients tend to have amelanotic (pink or red), thicker lesions that can be difficult to distinguish from atypical Spitz nevi histopathologically.
- Controlling for Breslow depth of invasion (in sites where the Breslow depth can be measured), all CMs have the same prognosis, including pregnancy-associated CM; however, some types of CM tend to have a deeper Breslow depth at presentation due to delayed diagnosis (e.g. amelanotic, ALM).

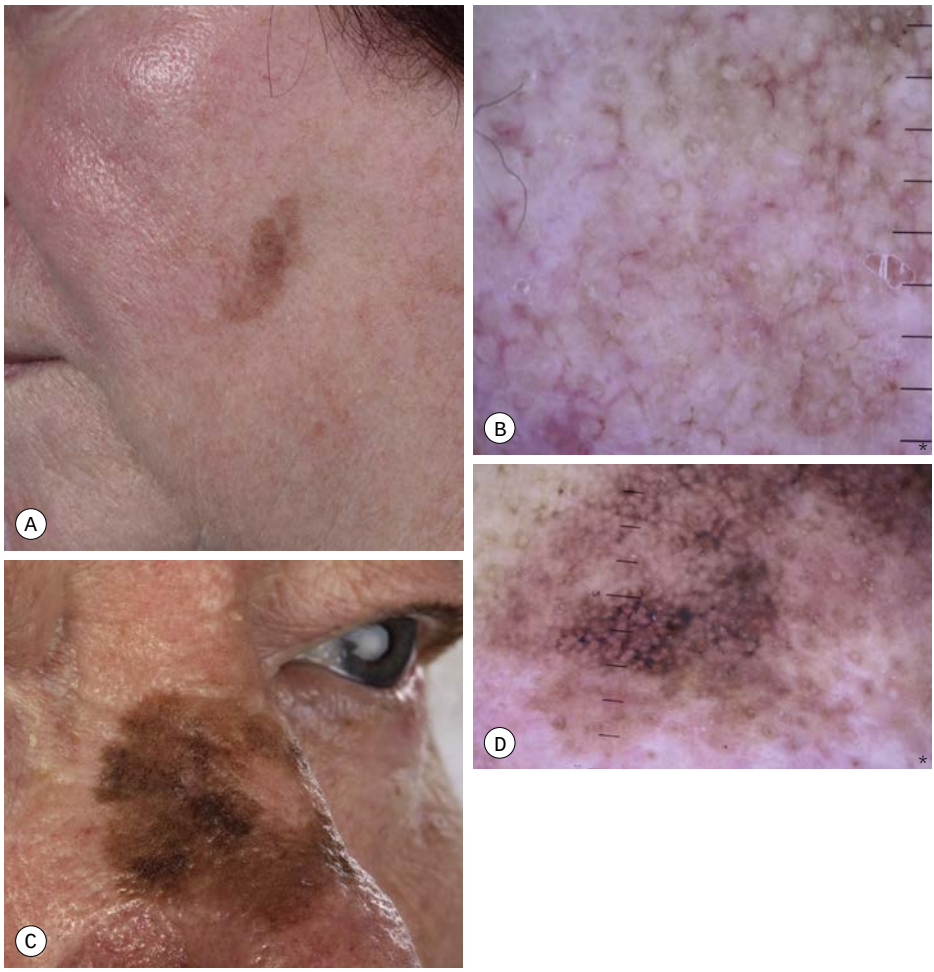


**Fig. 93.5 Lentigo maligna (LM). A, C** An early LM presenting as a light brown patch with subtle asymmetric pigmentation (**A**) is compared to a more advanced lesion with readily apparent variation in pigmentation (**C**). **B, D** By dermoscopy*, follicular openings surrounded by annular pigmentation are seen, referred to as a "circle in a circle". Findings are more subtle in **B** and a few rhomboidal structures are seen in **D**. *Courtesy, Claus Garbe, MD and Jürgen Bauer, MD.*

## Diagnosis

- Early detection is key to improved survival; diagnosis is based upon clinical suspicion (e.g. visual inspection, dermoscopy), followed by histopathologic confirmation.
- The biopsy should attempt to remove the entire lesion, including a depth adequate to determine an accurate Breslow depth (Fig. 93.12); if limited by large size, representative samples should be obtained; histopathologic evaluation is then performed by a dermatopathologist.
- When doing a total body skin examination (TBSE), signs such as the "ugly duckling sign" (a pigmented lesion that stands out as atypical within the context of surrounding nevi; see Fig. 93.4B and Ch. 92) and the "little red riding hood sign" can prove useful (see Fig. 93.4A).
- In addition to dermoscopy, photography can aid in diagnosis; for the former, the first step is to determine if the lesion is melanocytic (Table 93.4) and then assess for worrisome features (Tables 93.5 and 93.6).

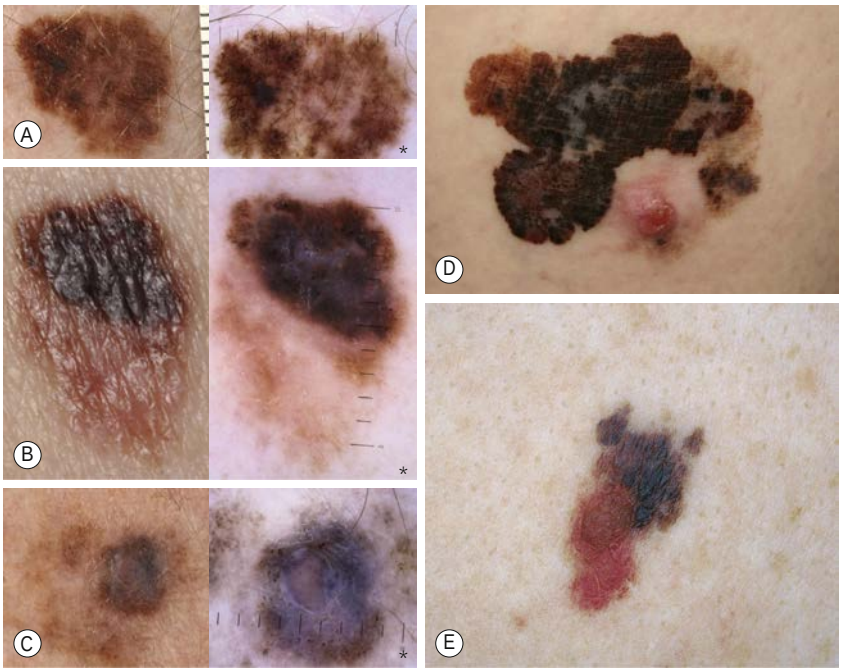


**Fig. 93.6 Superficial spreading melanomas. A–C** Clinically, all of these lesions demonstrate asymmetry due to variation in color and irregularity in outline. Breslow depths for **A–C** were <0.5 mm, 0.58 mm, and 1.60 mm, respectively. By dermoscopy*, there is asymmetry, atypical pigment networks, irregular blotches, and multiple colors; in **B** and **C** a blue-white veil is present. **D** In this more advanced lesion, note the asymmetry, irregular borders, variation in colors, scar-like regression zones, and an inferior pink papule, indicating vertical growth phase. **E** Superficial spreading melanoma arising within a compound melanocytic nevus. Note the irregular outline and variable pigmentation. *A–C, Courtesy, Claus Garbe, MD and Jürgen Bauer, MD; D, Courtesy, Claus Garbe, MD; E, Courtesy, YDRSC.*

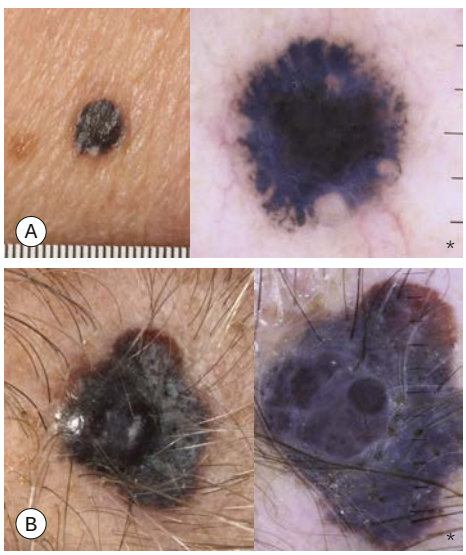


**Fig. 93.7 Nodular melanomas. A** Clinically, a darkly pigmented papule measuring ~3 mm in diameter with a Breslow depth of 0.95 mm; by dermoscopy*, a blue color, atypical pigment network, and streaks are seen. **B** Darkly pigmented plaque on the scalp with an eccentric nodule and a Breslow depth of 2.75 mm; by dermoscopy*, multiple colors including blue-gray are seen. *Courtesy, Claus Garbe, MD and Jürgen Bauer, MD.*



**Fig. 93.8 Lentigo maligna melanoma (LMM).** **A** Asymmetric pigmented lesion on the earlobe, with irregular borders and significant variation in pigmentation; the Breslow depth was 0.45 mm. **B** Larger triangular brown patch in which there are multiple dark brown, black, and blue-gray papules and plaques; Breslow depth was 1.1 mm. *A, Courtesy, Claus Garbe, MD and Jürgen Bauer, MD; B, Courtesy, Kalman Watsky, MD.*



**Fig. 93.9 Acral lentiginous melanoma.** Irregularly pigmented lesion on the plantar surface of the foot. These tumors may become amelanotic and are then easily overlooked or misdiagnosed as verrucae or other benign lesions, often resulting in a significantly delayed diagnosis. Dermoscopic findings include irregular diffuse pigmentation and a parallel ridge pattern. *Courtesy, Claus Garbe, MD.*



**Fig. 93.10 Amelanotic melanoma.** **A** Skin-colored to light pink nodule on the right scapula of a female patient; Breslow depth was 4 mm. **B** By dermoscopy*, some pigmented globules allow one to identify the tumor as a melanocytic lesion. Dotted, point and linear-irregular vessels are suggestive of melanoma. *Courtesy, Claus Garbe, MD.*

- Not all cutaneous melanomas present with typical features and in early lesions, clinical findings can be subtle; therefore, concern by a patient for one particular lesion needs to be factored into the evaluation.
- **DDx:** outlined in Table 93.7.

## Prognosis and Staging

- Of the histopathologic features of a primary invasive CM, the Breslow depth (measured in millimeters) is the strongest predictor of survival (see Fig. 93.12); the presence or absence of lymph node involvement is an even stronger predictor of survival.
- The American Joint Committee on Cancer's (AJCC) TNM classification and staging system for CM are outlined in Tables 93.8 and 93.9.

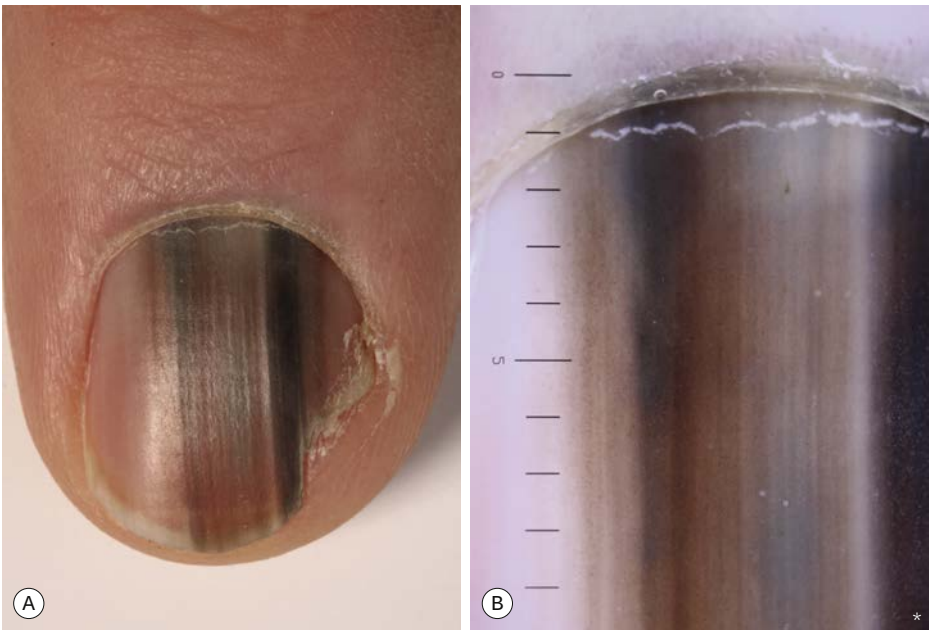


**Fig. 93.11 Melanoma of the nail matrix. A, B** The longitudinal pigmentation of the nail plate is non-homogeneous, both clinically (**A**) and dermoscopically* (**B**); the Breslow depth was 0.7 mm. *Courtesy, Claus Garbe, MD and Jürgen Bauer, MD.*

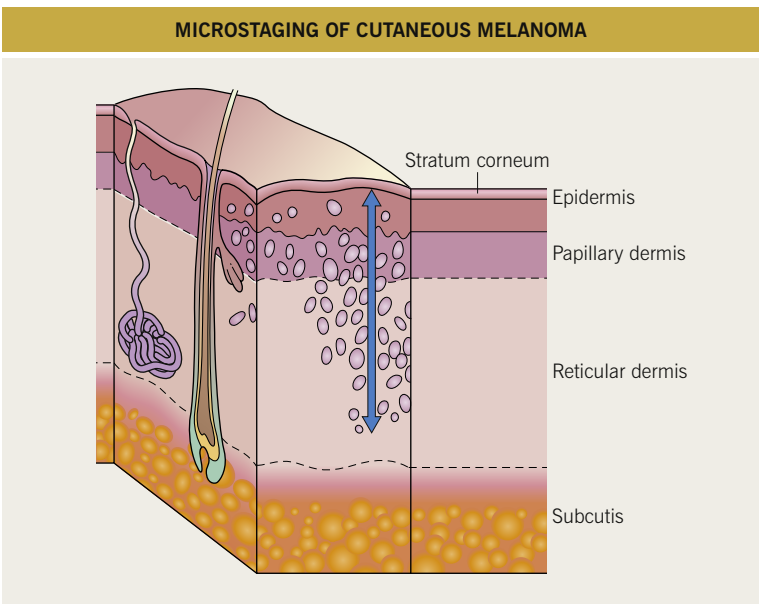


**Fig. 93.12 Microstaging of cutaneous melanoma: Breslow tumor thickness (blue vertical arrow).** Breslow method: measure in millimeters from the top of the granular layer of the epidermis (or the base of an ulcer) to the deepest part of the tumor.

| DERMOSCOPIC PATTERN ANALYSIS: FIRST-STEP ALGORITHM FOR DIFFERENTIATION BETWEEN MELANOCYTIC AND NON-MELANOCYTIC LESIONS | | |
|---|---|---|
| **Dermoscopic criterion** | **Definition** | **Diagnostic significance** |
| Pigment network – pseudo-network† | Network of brownish interconnected lines over a background of tan diffuse pigmentation. In facial skin, a peculiar pigment network, also called a pseudo-network, is typified by round, equally sized network holes corresponding to the pre-existing follicular ostia. | Melanocytic lesion |
| Aggregated globules | Numerous, variously sized, more or less clustered, round to oval structures with various shades of brown and gray-black. They should be differentiated from multiple blue-gray globules. | Melanocytic lesion |
| Streaks | These have been previously described separately as pseudopods and radial streaming, but are now combined into the one term. They are bulbous and often kinked or finger-like projections seen at the edge of a lesion. They may arise from network structures but more commonly do not. They range in color from tan to black. | Melanocytic lesion |
| Homogeneous blue pigmentation‡ | Structureless blue pigmentation in the absence of pigment network or other distinctive local features | Melanocytic lesion |
| Parallel pattern | Seen in melanocytic lesions of palms/soles and mucosal areas. On palms/soles, the pigmentation may follow the sulci or the cristae (i.e. furrows or ridges) of the dermatoglyphics. Rarely arranged at right angles to these structures. | Melanocytic lesion |
| Multiple milia-like cysts | Numerous, variously sized, white or yellowish, roundish structures | Seborrheic keratosis |
| Comedo-like openings | Brown-yellowish to brown-black, round to oval, sharply circumscribed keratotic plugs in the ostia of hair follicles. When irregularly shaped, comedo-like openings are also called irregular crypts. | Seborrheic keratosis |
| Light brown fingerprint-like structures | Light brown, delicate, network-like structures with the pattern of a fingerprint | Seborrheic keratosis |
| Cerebriform pattern | Dark brown furrows between ridges typifying a brainlike appearance | Seborrheic keratosis |
| Arborizing vessels | Tree-like branching telangiectasias | Basal cell carcinoma* |
| Leaf-like structures | Brown to gray/blue discrete bulbous structures forming leaflike patterns. They are discrete pigmented nests (islands) never arising from a pigment network and usually not arising from adjacent confluent pigmented areas. | Basal cell carcinoma* |
| Large blue-gray ovoid nests | Well-circumscribed, confluent or near confluent, pigmented, ovoid or elongated areas, larger than globules, and not intimately connected to a pigmented tumor body | Basal cell carcinoma* |
| Multiple blue-gray globules | Multiple globules (not dots) that should be differentiated from multiple blue-gray dots (melanophages) | Basal cell carcinoma* |

**Table 93.4 Dermoscopic pattern analysis: first-step algorithm for differentiation between melanocytic and non-melanocytic lesions.** *Continued*

| DERMOSCOPIC PATTERN ANALYSIS: FIRST-STEP ALGORITHM FOR DIFFERENTIATION BETWEEN MELANOCYTIC AND NON-MELANOCYTIC LESIONS | | |
|---|---|---|
| **Dermoscopic criterion** | **Definition** | **Diagnostic significance** |
| Spoke-wheel areas | Well-circumscribed radial projections, usually tan in color but sometimes blue or gray, meeting at an often darker (dark brown, black or blue) central axis | Basal cell carcinoma* |
| Ulceration§ | Absence of the epidermis, often associated with congealed blood, not due to a well-described recent history of trauma | Basal cell carcinoma* |
| Red-blue lacunae | More or less sharply demarcated, roundish or oval areas with a reddish, red-bluish, or dark red to black coloration | Vascular lesion |
| Red-bluish to reddish-black homogeneous areas | Structureless homogeneous areas of red-bluish to red-black coloration | Vascular lesion |
| None of the listed criteria | Absence of the above-mentioned criteria | Melanocytic lesion |

**To diagnose a basal cell carcinoma, the negative feature of pigment network must be absent and one or more of the positive features listed here must be present.*
*†Exception 1: Pigment network or pseudo-network is also present in solar lentigo and rarely in seborrheic keratosis and pigmented actinic keratosis. A delicate, annular pigment network is also commonly seen in dermatofibroma and accessory nipple (clue for diagnosis of dermatofibroma and accessory nipple: central white patch).*
*‡Exception 2: Homogeneous blue pigmentation (dermoscopic hallmark of blue nevus) is also seen (uncommonly) in some hemangiomas and basal cell carcinomas and (commonly) in intradermal melanoma metastases.*
*§Exception 3: Ulceration is also seen less commonly in invasive melanoma.*

**Table 93.4** *Continued* **Dermoscopic pattern analysis: first-step algorithm for differentiation between melanocytic and non-melanocytic lesions.** *Adapted from Argenziano G, Soyer HP, Chimenti S, et al. Dermoscopy of pigmented skin lesions: Results of a consensus meeting via the Internet. J Am Acad Dermatol 2003;48:679–93.*

| DERMOSCOPIC PATTERN ANALYSIS: SECOND-STEP ALGORITHM FOR DIFFERENTIATION BETWEEN MELANOCYTIC NEVI AND MELANOMA | | |
|---|---|---|
| **Dermoscopic criterion** | **Definition** | **Diagnostic significance** |
| **Global features** | | |
| Reticular pattern | Pigment network covering most parts of the lesion | Melanocytic nevus |
| Globular pattern | Numerous, variously sized, round to oval structures with various shades of brown and gray-black | Melanocytic nevus |
| Cobblestone pattern | Large, closely aggregated, somehow angulated globule-like structures resembling a cobblestone | Dermal nevus |
| Homogeneous pattern | Diffuse, brown, gray-blue to gray-black pigmentation in the absence of other distinctive local features | Melanocytic (blue) nevus |
| Starburst pattern | Pigmented streaks in a radial arrangement at the edge of the lesion | Spitz/Reed nevus |

**Table 93.5 Dermoscopic pattern analysis: second-step algorithm for differentiation between melanocytic nevi and melanoma.** *Continued*



ALGrawany

| DERMOSCOPIC PATTERN ANALYSIS: SECOND-STEP ALGORITHM FOR DIFFERENTIATION BETWEEN MELANOCYTIC NEVI AND MELANOMA | | |
|---|---|---|
| **Dermoscopic criterion** | **Definition** | **Diagnostic significance** |
| Parallel pattern | Pigmentation on palms/soles that follows the sulci or the cristae (furrows or ridges), rarely arranged at right angles to these structures | Acral nevus/ melanoma (see below) |
| Multicomponent pattern | Combination of three or more of the above patterns | Melanoma |
| Nonspecific pattern | Pigmented lesion lacking above patterns | Possible melanoma |
| **Local features** | | |
| Pigment network | Typical pigment network: light to dark brown network with small, uniformly spaced network holes and thin network lines distributed more or less regularly throughout the lesion and usually thinning out at the periphery | Benign melanocytic lesion |
| | Atypical pigment network: black, brown, or gray network with irregular holes and thick lines | Melanoma |
| Dots/globules | Black, brown, round to oval, variously sized structures regularly or irregularly distributed within the lesion | If regular, benign melanocytic lesion<br>If irregular, melanoma |
| Streaks | These have been previously described separately as pseudopods and radial streaming. Streaks are bulbous and often kinked or finger-like projections seen at the edge of a lesion. They may arise from network structures but more commonly do not. They range in color from tan to black. | If regular, benign melanocytic lesion (Spitz/Reed nevus)<br>If irregular, melanoma |
| Blue-whitish veil | Irregular, structureless area of confluent blue pigmentation with an overlying white "ground-glass" film. The pigmentation cannot occupy the entire lesion and usually corresponds to a clinically elevated part of the lesion. | Melanoma |
| Regression structures | White scarlike depigmentation and/or blue pepper-like granules usually corresponding to a clinically flat part of the lesion | Melanoma |
| Hypopigmentation | Areas with less pigmentation than the overall pigmentation of the lesion | Nonspecific |
| Blotches | Black, brown, and/or gray structureless areas with symmetrical or asymmetrical distribution within the lesion | If symmetrical, benign melanocytic lesion<br>If asymmetrical, melanoma |

**Table 93.5 Dermoscopic pattern analysis: second-step algorithm for differentiation between melanocytic nevi and melanoma.** *Continued*

| DERMOSCOPIC PATTERN ANALYSIS: SECOND-STEP ALGORITHM FOR DIFFERENTIATION BETWEEN MELANOCYTIC NEVI AND MELANOMA | | |
|---|---|---|
| **Dermoscopic criterion** | **Definition** | **Diagnostic significance** |
| **Site-related features** | | |
| Face | Typical pseudo-network (round, equally sized network holes corresponding to the pre-existing follicular ostia) | Benign melanocytic lesion |
| | Annular–granular structures (multiple blue-gray dots surrounding the follicular ostia with an annular–granular appearance) | Melanoma |
| | Gray pseudo-network (gray pigmentation surrounding the follicular ostia, formed by the confluence of annular–granular structures) | Melanoma |
| | Rhomboidal structures (gray-brown pigmentation surrounding the follicular ostia with a rhomboidal appearance) | Melanoma |
| | Asymmetric pigmented follicles (eccentric annular pigmentation around follicular ostia) | Melanoma |
| Palms/soles | Parallel-furrow pattern (pigmentation following the sulci) | Acral nevus |
| | Lattice-like pattern (pigmentation following and crossing the furrows) | Acral nevus |
| | Fibrillar pattern (numerous, finely pigmented filaments perpendicular to the furrows and ridges) | Acral nevus |
| | Parallel-ridge pattern (pigmentation aligned along the cristae) | Melanoma |

**Table 93.5** *Continued* **Dermoscopic pattern analysis: second-step algorithm for differentiation between melanocytic nevi and melanoma.** *Adapted from Argenziano G, Soyer HP, Chimenti S, et al. Dermoscopy of pigmented skin lesions: Results of a consensus meeting via the Internet. J Am Acad Dermatol 2003;48:679–93.*

| DEFINITIONS OF DERMOSCOPIC CRITERIA FOR THE 3-POINT CHECKLIST | |
|---|---|
| **Criterion** | **Definition** |
| Asymmetry | Asymmetrical distribution of colors and dermoscopic structures |
| Atypical network* | More than one type of network (in terms of color and thickness of the meshes) irregularly distributed within the lesion |
| Blue-white structures† | Presence of any type of blue and/or white color |

**Usually found in early melanoma.*
*†Usually found in both melanoma and pigmented basal cell carcinoma.*

**Table 93.6 Definitions of dermoscopic criteria for the 3-point checklist.** The presence of more than one criterion suggests a suspicious lesion. *Adapted from Argenziano G, Puig S, Zalaudek I, et al. Dermoscopy improves accuracy of primary care physicians to triage lesions suggestive of skin cancer. J Clin Oncol. 2006;24:1877–82.*

| DIFFERENTIAL DIAGNOSIS OF CUTANEOUS MELANOMA | |
|---|---|
| **General** | **Location-based** |
| **If pigmented**<br>• Atypical (dysplastic) nevus<br>• Other nevi (e.g. black [hypermelanotic], blue, genital, acral, Spitz, recurrent)<br>• Seborrheic keratosis<br>• Pigmented BCC<br>• Pigmented Bowen disease<br>• Thrombosed hemangioma<br>• Dermatofibroma<br><br>**If amelanotic (pink, red)**<br>• Pyogenic granuloma (nodular)<br>• BCC; SCC, *in situ* or invasive<br>• Merkel cell carcinoma<br>• Pink intradermal nevus<br>• Spitz nevus<br>• Dermatofibroma<br>• Wart<br>• Lichen planus-like keratosis (LPLK)<br>• Isolated patch of psoriasis or eczema | **Lentigo maligna melanoma**<br>• Pigmented actinic keratosis<br>• Solar lentigo<br>• Macular seborrheic keratosis<br><br>**Nail matrix melanoma**<br>• Longitudinal melanonychia (see Table 58.2)<br>• Drug-induced nail pigmentation (see Table 58.4)<br>• SCC, *in situ* or invasive<br>• Subungual hematoma<br>• Wart<br><br>**Mucosal melanoma**<br>• Melanosis of mucosal regions<br>• Venous lake (vermilion lip)<br>• Amalgam tattoo<br>• Angiokeratoma (genital)<br>• SCC, *in situ* or invasive<br><br>**Acral lentiginous melanoma**<br>• Black heel or palm (see Fig. 74.9)<br>• Plantar wart<br>• Tinea nigra<br>• Plantar callosity<br>• Trophic ulcers |

**Table 93.7 Differential diagnosis of cutaneous melanoma.**

| AJCC MELANOMA TNM CLASSIFICATION – 2017 | | |
|---|---|---|
| **T category** | **Thickness** | **Ulceration status** |
| Tis (melanoma *in situ*) | NA | NA |
| T1 | <0.8 mm | a. – |
| | <0.8 mm<br>0.8–1.0 mm | b. +<br>b. +/– |
| T2 | >1.0–2.0 mm | a. – |
| | | b. + |
| T3 | >2.0–4.0 mm | a. – |
| | | b. + |
| T4 | >4.0 mm | a. – |
| | | b. + |

| N category | Number of tumor-involved regional lymph nodes | Presence of in-transit, satellite, and/or micro-satellite metastases* |
|---|---|---|
| N0 | No regional metastases detected | No |
| N1 | One tumor-involved node –*or*– in-transit, satellite, and/or microsatellite metastases with no tumor-involved nodes | |
| N1a | One clinically occult (i.e. detected by SLN biopsy) | No |

**Table 93.8 AJCC melanoma TNM classification – 2017.** *Continued.*

| AJCC MELANOMA TNM CLASSIFICATION – 2017 | | |
|---|---|---|
| **N category** | **Number of tumor-involved regional lymph nodes** | **Presence of in-transit, satellite, and/or micro-satellite metastases*** |
| N1b | One clinically detected | No |
| N1c | No regional lymph node disease | Yes |
| N2 | Two or three tumor-involved nodes –*or*– in-transit, satellite, and/or microsatellite metastases with one tumor-involved node | |
| N2a | Two or three clinically occult | No |
| N2b | Two or three, at least one of which was clinically detected | No |
| N2c | One clinically occult or clinically detected | Yes |
| N3 | Four or more tumor-involved nodes –*or*– in-transit, satellite, and/or microsatellite metastases with two or more tumor-involved nodes –*or*– any number of matted nodes without or with in-transit, satellite, and/or microsatellite metastases | |
| N3a | Four or more clinically occult | No |
| N3b | Four or more, at least one of which was clinically detected, or presence of any number of matted nodes | No |
| N3c | Two or more clinically occult or clinically detected and/or presence of any number of matted nodes | Yes |

| **M category** | **Anatomic site** | **LDH level** |
|---|---|---|
| M0 | No evidence of distant metastasis | NA |
| M1a | Distant metastasis to skin, soft tissue including muscle, and/or non-regional lymph node | Not recorded or unspecified |
| | | (0) Not elevated |
| | | (1) Elevated |
| M1b | Distant metastasis to lung with or without M1a sites of disease | Not recorded or unspecified |
| | | (0) Not elevated |
| | | (1) Elevated |
| M1c | Distant metastasis to non-CNS visceral sites with or without M1a or M1b sites of disease | Not recorded or unspecified |
| | | (0) Not elevated |
| | | (1) Elevated |
| M1d | Distant metastasis to CNS with or without M1a, M1b or M1c sites of disease | Not recorded or unspecified |
| | | (0) Not elevated |
| | | (1) Elevated |

**In-transit metastases are >2 cm from the primary tumor but not beyond the regional lymph nodes, while satellite lesions are within 2 cm of the primary. Satellite lesions can be detected clinically or microscopically; the latter are referred to as microsatellite metastases.*

**Table 93.8** *Continued* **AJCC melanoma TNM classification – 2017.** Histologic evaluation of lymph nodes must include at least one immunohistochemical marker (e.g. HMB45, MART-1/Melan-A). NA, not applicable; SLN, sentinel lymph node. *Adapted from: AJCC Cancer Staging Manual. American Joint Committee on Cancer, 8th edn. Springer, 2017:563–85.*

| AJCC STAGE GROUPINGS FOR CUTANEOUS MELANOMA – 2017 | | | | | | | |
|---|---|---|---|---|---|---|---|
| | Survival (%)* | Clinical staging† | | | Pathologic staging‡ | | |
| | | T | N | M | T | N | M |
| 0 | | Tis | N0 | M0 | Tis | N0 | M0 |
| IA | 97 | T1a | N0 | M0 | T1a | N0 | M0 |
| | | | | | T1b | | |
| IB | 93 | T1b | N0 | M0 | T2a | N0 | M0 |
| | | T2a | | | | | |
| IIA | 82 | T2b | N0 | M0 | T2b | N0 | M0 |
| | 79 | T3a | | | T3a | | |
| IIB | 68 | T3b | N0 | M0 | T3b | N0 | M0 |
| | 71 | T4a | | | T4a | | |
| IIC | 53 | T4b | N0 | M0 | T4b | N0 | M0 |
| III§ | | Any T, Tis | ≥N1 | M0 | | | |
| IIIB | | | | | T0 | N1b, N1c | M0 |
| IIIC | | | | | T0 | N2b, N2c, N3b or N3c | M0 |
| IIIA | 78 | | | | T1a/b–T2a | N1a or N2a | M0 |
| IIIB | 59 | | | | T1a/b–T2a | N1b/c or N2b | M0 |
| | | | | | T2b/T3a | N1a–N2b | |
| IIIC | 40 | | | | T1a–T3a | N2c or N3a/b/c | M0 |
| | | | | | T3b/T4a | Any N ≥ N1 | |
| | | | | | T4b | N1a–N2c | |
| IIID | | | | | T4b | N3a/b/c | M0 |
| IV | 9–27¶ | Any T | Any N | M1 | Any T, Tis | Any N | M1 |

**Approximate 5-year survival (%), adapted from Balch et al. 2009 AJCC melanoma staging and classification. J Clin Oncol. 2009;27:6199–206; based upon 2009 AJCC melanoma TNM classification and prior to advent of targeted therapy and immunotherapy.*
*†Clinical staging includes microstaging of the primary melanoma and clinical/radiologic evaluation for metastases. By convention, it should be used after complete excision of the primary melanoma with clinical assessment for regional and distant metastases.*
*‡Pathologic staging includes microstaging of the primary melanoma and pathologic information about the regional lymph nodes after partial or complete lymphadenectomy. Pathologic stage 0 or stage IA patients are the exception.*
*§There are no stage III subgroups for clinical staging.*
*¶Higher survival rate associated with normal serum LDH levels and lower rate with elevated LDH levels.*

**Table 93.9 AJCC stage groupings for cutaneous melanoma – 2017.** *Adapted from Balch CM, Gershenwald JE, Soong SJ, et al. Final version of 2009 AJCC melanoma staging and classification. J Clin Oncol 2009;27:6199–6206. Reprinted with permission from the American Society of Clinical Oncology.*

- As with other cancers, prognosis is dependent on the stage at the time of diagnosis (Fig. 93.13); other independent prognostic factors for survival have also been identified (Table 93.10).
- Molecular testing of the primary CM (e.g. gene expression profiling) for prognostication is still considered investigational.

## Management

- Once the histopathologic diagnosis of CM is confirmed and prior to re-excision (Table 93.11), evaluation should include a thorough history, TBSE, palpation of the surrounding skin and lymph node basins, and

**COMPARISON OF SURVIVAL CURVES IN FOUR STAGES OF MELANOMA**

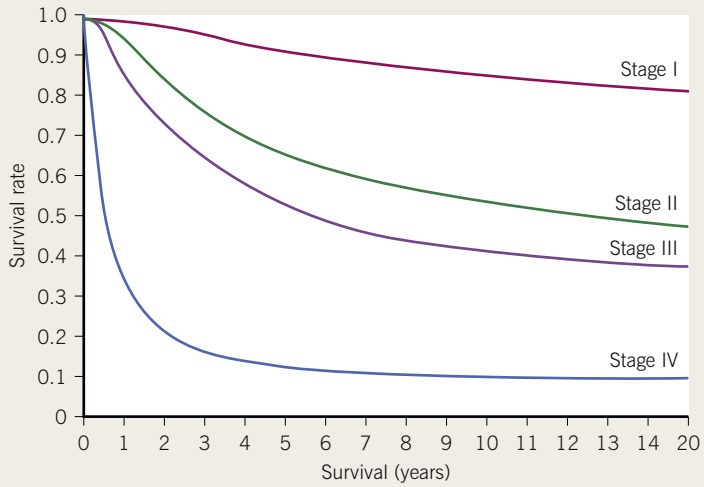


**Fig. 93.13 Comparison of survival curves in four stages of melanoma.** *Redrawn from Balch CM. Melanoma of the skin. In Edge SB, Byrd DR, Compton CC, et al., eds. AJCC Cancer Staging Manual, 7th edn. New York: Springer, 2009.*

**MELANOMA – MAJOR INDEPENDENT PROGNOSTIC FACTORS FOR SURVIVAL IN MULTIVARIATE ANALYSES**

| Prognostic factor | Commentary |
|---|---|
| Tumor thickness | ≤1 mm, low risk; >1 mm, higher risk |
| Ulceration | Worse prognosis with ulceration |
| Mitotic rate | Worse prognosis with ≥1 mitoses/mm$^2$ |
| Age | Worse prognosis with older age |
| Sex | Men have poorer prognosis (only for localized disease) |
| Anatomic site | Trunk, head, and neck associated with poorer prognosis than extremities |
| Number of involved lymph nodes | Cutoff points: 1, 2–3, 4 or more lymph nodes (see Table 93.8) |
| Regional lymph node tumor burden | Clinically detectable (palpable) nodal metastases with poorer prognosis than clinically occult (non-palpable) nodal metastases |
| Site of distant metastases | Visceral metastases associated with poorer prognosis than non-visceral metastases (skin, subcutaneous, distant lymph nodes) |

**Table 93.10 Melanoma – major independent prognostic factors for survival in multivariate analyses.**

determination of whether or not a sentinel lymph node biopsy (SLNB) should be considered (Table 93.12).

- **Sentinel lymph node biopsy (SLNB):**
  - SLNB is useful as a staging and prognostic tool, but to date its usefulness as a therapeutic modality has not been established
  - SLN status is also an important determinant for consideration of adjuvant therapy (e.g. immune checkpoint inhibitors) for patients with stage III disease
  - Typically, SLNB is performed at the time of re-excision
  - If the SLNB is positive for *micro*-metastases, complete lymph node

| SURGICAL TREATMENT OF PRIMARY CUTANEOUS MELANOMA | | |
|---|---|---|
| **Tumor thickness** | **Excision margins* (cm)** | **Comments** |
| *In situ* | 0.5 | Lentigo maligna of the face may be excised with 1-cm margins (especially when lesions are >1.5–2 cm in diameter) or treated by Mohs micrographic surgery or radiotherapy; postoperative topical imiquimod is often used |
| ≤1 mm | 1.0 | Mohs micrographic surgery may be employed in acral and facial melanomas |
| 1.01–2 mm | 1.0–2.0 | |
| >2 mm | 2.0 | |

**Measurement of the excision margins should begin at the outermost edge of the biopsy site or the clinical lesion, whichever is furthest out.*

**Table 93.11 Surgical treatment of primary cutaneous melanoma.** Evidence from available randomized trials is insufficient to address the optimal margins for the excision of primary cutaneous melanoma, but multiple expert international committees have produced fairly consistent guidelines, as summarized here. Of note, further investigative efforts will likely alter the standards of care over time. *Adapted from Sladden MJ, et al. Surgical excision margins for primary cutaneous melanoma. Cochrane Database Syst Rev 2009;(4):CD004855.*

| CRITERIA FOR CONSIDERATION OF SENTINEL LYMPH NODE BIOPSY (SLNB) |
|---|
| **Discuss SLNB** |
| • Stage T1a: <0.8 mm without ulceration but with any adverse features* |
| • Stage T1b: <0.8 mm with ulceration |
| • Stage T1b: 0.8–1.0 mm with or without ulceration |
| **Discuss and offer SLNB** |
| • Stage >T2a: >1.0 mm |
| **Young age (<40 years), presence of lymphovascular invasion, positive deep biopsy margin (especially if diffuse), high mitotic rate.* |

**Table 93.12 Criteria for consideration of sentinel lymph node biopsy (SLNB).** The patient should also be informed of the FDA-approved therapies for stage III disease.

dissection used to be the standard procedure, but nowadays clinical surveillance (including ultrasound of the regional basin) is often chosen instead

– *Disadvantages*: can cause lymphedema; expensive; usually requires general anesthesia

• Regional nodal ultrasound surveillance may also be used to monitor the regional lymph node basin in patients who are eligible for SLNB but elect not to undergo the procedure.

• Imaging studies for identification of metastases include: ultrasound of lymph node basins; CT scan of the chest, abdomen, and pelvis or PET scan in high-risk patients; and if symptoms, cranial MRI; serum LDH is measured serially in stage IV patients, as it influences prognosis (see Table 93.8).

• Additional **Rx**, in particular immunotherapy and targeted therapies, is outlined in Tables 93.13 and 93.14.

• A melanoma patient worksheet can help organize all of this information for both the patient and the clinician (see Appendix).

## Follow-Up

• Primary objectives include identification of potentially curable local recurrences (~4% of patients; Fig. 93.14) or regional metastases (e.g. in transit, lymph node; Fig. 93.15) and to identify second primary CMs (up to 10% of patients).

| GENERAL GUIDELINES FOR TREATMENT OF CUTANEOUS MELANOMA (CM) BASED ON STAGE AT DIAGNOSIS, IN ADDITION TO RE-EXCISION OF THE PRIMARY CM | |
|---|---|
| **Stage** | **Recommended treatment** |
| **Stage 0 (melanoma *in situ*)** | |
| • Tis | • Re-excision (see Table 93.11) |
| **Stages I and II** | |
| • T1a <0.8 mm (no ulceration and no other adverse features*) | • Re-excision (see Table 93.11) |
| • T1a <0.8 mm (no ulceration but (+) adverse features*)<br>• T1b <0.8 mm (+) ulceration or 0.8–1.0 mm +/– ulceration | • Re-excision (see Table 93.11)<br>• Discussion of SLNB** |
| • ≥T2a (>1.0 mm +/– ulceration) | • Re-excision (see Table 93.11)<br>• Discussion and offering of SLNB** |
| **Stage III** | |
| • Lymph node metastases, including clinically occult disease noted by SLNB | • Offer adjuvant therapy (see Table 93.14)<br>• Consider clinical trial enrollment |
| • In-transit or satellite metastases† | *Depending on number of lesions, local, regional or systemic therapy is chosen or may be combined:*<br>• *Systemic therapy* (see Table 93.14)<br>• *Local therapy*:<br>– Complete surgical excision to clear margins if possible<br>– T-VEC¶, BCG, interferon alpha, or IL-2 injection in tumor<br>– Topical imiquimod cream<br>– Consider radiotherapy if can't be removed by surgery<br>• *Regional therapy:*<br>– Isolated limb infusion/perfusion with melphalan |
| **Stage IV** | |
| • Skin or subcutaneous metastases | • Depends upon size and number of lesions (see above, in-transit metastases) |
| • Solid organ metastases | • Systemic therapy (see Table 93.14) +/– surgery or radiotherapy (including stereotactic) |

**Adverse features include young age (<40 years), presence of lymphovascular invasion, positive deep biopsy margin (especially if diffuse), high mitotic rate.*
***SLNB should be performed before or at the time of re-excision.*
*†The distinction between in-transit and satellite metastases is not clinically necessary as both are considered manifestations of intralymphatic disease and are grouped together in the new AJCC staging system.*
*¶An oncolytic virus therapy that uses a genetically modified herpes virus to infect and kill cancer cells.*

**Table 93.13 General guidelines for treatment of cutaneous melanoma (CM) based on stage at diagnosis, in addition to re-excision of the primary CM.** BCG, Bacillus Calmette–Guérin; SLNB, sentinel lymph node biopsy; T-VEC, talimogene laherparepvec.

• Visits should include: (1) review of systems that focuses on signs or symptoms of metastases to soft tissue, liver, lung, GI tract, and CNS; (2) TBSE; (3) examination and palpation of the melanoma scar/excision site and surrounding area for local recurrences or in-transit metastases; (4) lymph node examination; and (5) laboratory and radiologic tests as indicated by signs and symptoms.

• Follow-up intervals during the first 3–5 years after diagnosis vary from 3 to 6 months, depending on stage, in addition to the number of primary melanomas, melanocytic nevi, and atypical nevi as well as family history of melanoma; lifelong follow-up is recommended.

• Patients should be counseled to adhere to sun protective measures; perform skin self-examinations at home; stay up-to-date on

| TARGETED THERAPIES AND CHECKPOINT INHIBITORS | | |
|---|---|---|
| **Targeting the MAPK pathway (see Fig. 93.2)** | | **FDA approved as of June 2021** |
| BRAF inhibitors (selective*,**) | Dab*raf*enib*** | √ |
| | Enco*raf*enib | √ |
| | Vemu*raf*enib | √ |
| MEK inhibitors** | Bini*met*inib | √ |
| | Cobi*met*inib | √ |
| | Tra*met*inib*** | √ |
| **Immune checkpoint inhibitors** | | |
| Anti-CTLA-4 antibody | Ipilimumab*** | √ |
| | Tremelimumab | |
| Anti-PD-1 antibody | Nivolumab*** | √ |
| | Pembrolizumab*** | √ |
| | Pidilizumab | |
| | Cemiplimab | Approved for advanced cutaneous SCC and BCC |
| Anti-PD-L1 antibodies | Atezolizumab | √ |
| | Avelumab | Approved for metastatic Merkel cell carcinoma and urothelial carcinoma |
| | Durvalumab | Approved for bladder cancer (PD-L1-positive) and extensive-stage small cell lung cancer |

**Target melanomas that have specific amino acid substitutions at position 600 in BRAF, most commonly V600E and less often V600D or V600K.*
***For melanomas with activating BRAF mutations, the combination of a selected BRAF inhibitor with a MEK inhibitor is recommended to minimize the development of drug resistance and cutaneous toxic effects (see Table 17.9), most notably eruptive SCCs and KAs.*
****Dabrafenib + trametinib, ipilimumab, nivolumab, and pembrolizumab have been approved for **adjuvant therapy** of melanoma; peginterferon alpha 2b is also approved but is rarely used.*

**Table 93.14 Major systemic treatments for metastatic melanoma – targeted therapies and checkpoint inhibitors.** MAPK, mitogen-activated protein kinase.

their other health maintenance and recommended cancer screenings; and take an oral vitamin D supplement if needed.

- Family members can be screened by a dermatologist, who can then determine frequency of subsequent screenings.
- Genetic counseling/testing for germline mutations should be considered in patients suspected of having a familial melanoma syndrome (see Tables 93.2 and 93.3).

For further information see Ch. 113 from *Dermatology, Fourth Edition*.

**For additional online figures and tables visit www.expertconsult.com**

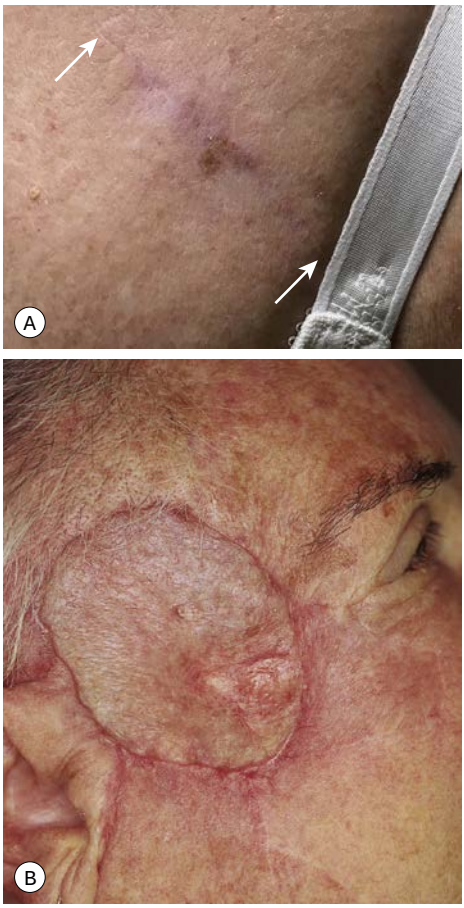


**Fig. 93.14 Local recurrences of cutaneous melanoma. A** Recurrent melanoma *in situ* occurring midway along the excision scar (demarcated by arrows) on the right upper back in a female with Lynch syndrome (*PMS2* mutation). **B** Amelanotic nodular recurrence of a desmoplastic melanoma within the skin graft. *A, Courtesy, Karynne O Duncan, MD; B, Courtesy, Jean L. Bolognia, MD.*



**Fig. 93.15 In-transit metastases of melanoma.** Multiple pink, brown and black papulonodules (see arrowheads) developed along the lymphatic drainage route following resection of a recurrent melanoma (3.2 mm Breslow depth) on the left medial foot one year prior. This patient subsequently received intralesional talimogene laherparepvec injection treatment. *Courtesy, Karynne O. Duncan, MD.*

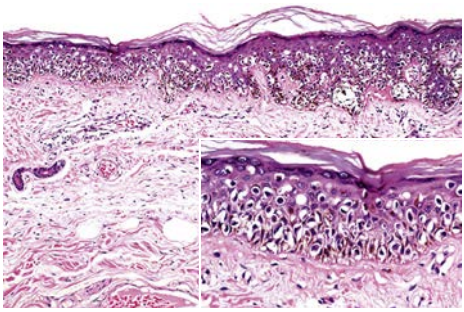

**eFig. 93.1 Histopathologic features of a melanoma *in situ*.** Increased number of melanocytes with atypical nuclei not only in the basal layer, but also at all levels of the epidermis. Note the predominance of single cells over nests. *Courtesy, Lorenzo Cerroni, MD.*

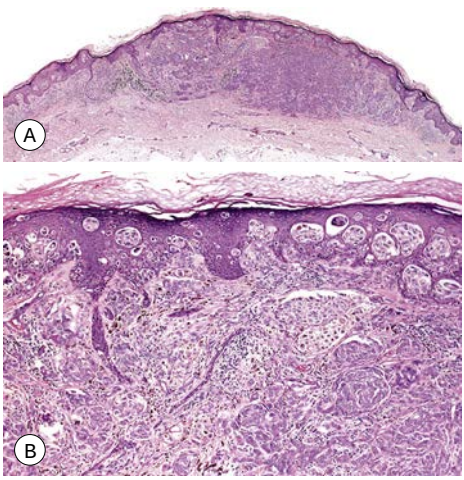


**eFig. 93.2 Histopathologic features of a typical cutaneous melanoma. A** Asymmetric melanocytic tumor with asymmetry in both distribution of melanocytic complexes and pigment. **B** Pagetoid melanocytes organized as solitary units and nests varying in size and shape are present throughout the entire epidermis. Neoplastic melanocytes extend into the dermis. There is absence of maturation at deeper levels of the dermis. *Courtesy, Lorenzo Cerroni, MD.*

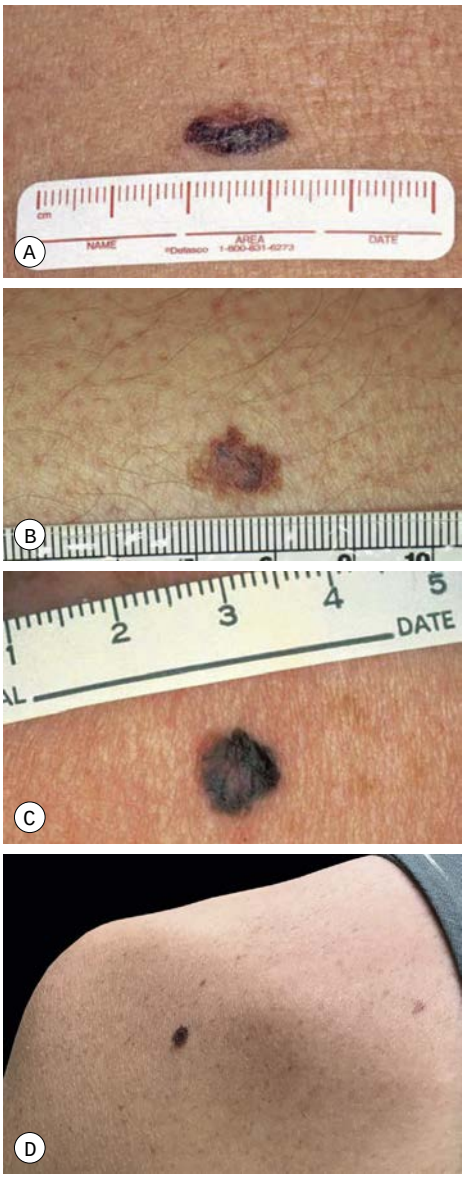


**eFig. 93.3 Superficial spreading melanomas. A–C** All of these early lesions demonstrate asymmetry due to variation in color and irregularity in outline. In addition, there is pink discoloration in **(C)**. **A, B** were less than 0.5 mm in thickness and **(C)** was 0.8 mm. **D** This early lesion (0.5 mm in thickness) is uniform in color and relatively symmetric in shape. The patient presented with concern over the new appearance and growth of this lesion, thus prompting its biopsy. *A, Courtesy, Kalman Watsky, MD; B, C, Courtesy, Jean L. Bolognia, MD; D, Courtesy, Karynne O. Duncan, MD.*

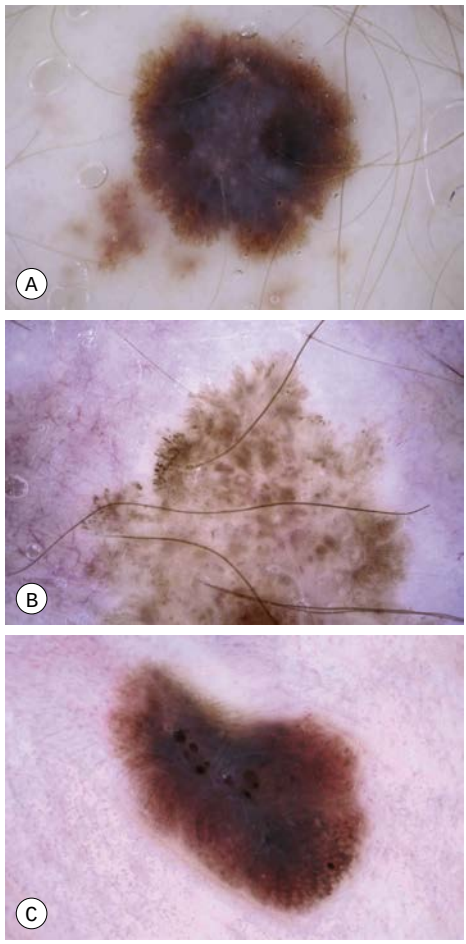


**eFig. 93.4 Dermoscopic appearance of superficial spreading melanomas. A** Striking asymmetry and streaks at the periphery. The latter have also been called radial streaming and pseudopods. **B** Streaks and blue-whitish veil. **C** Streaks, blue-whitish veil, and irregular blotches. *Courtesy, Claus Garbe, MD and Jürgen Bauer, MD.*



**eFig. 93.5 Nodular melanoma.** Rapidly growing black nodule that was >15 mm in diameter on the back of a male patient. *Courtesy, Claus Garbe, MD.*

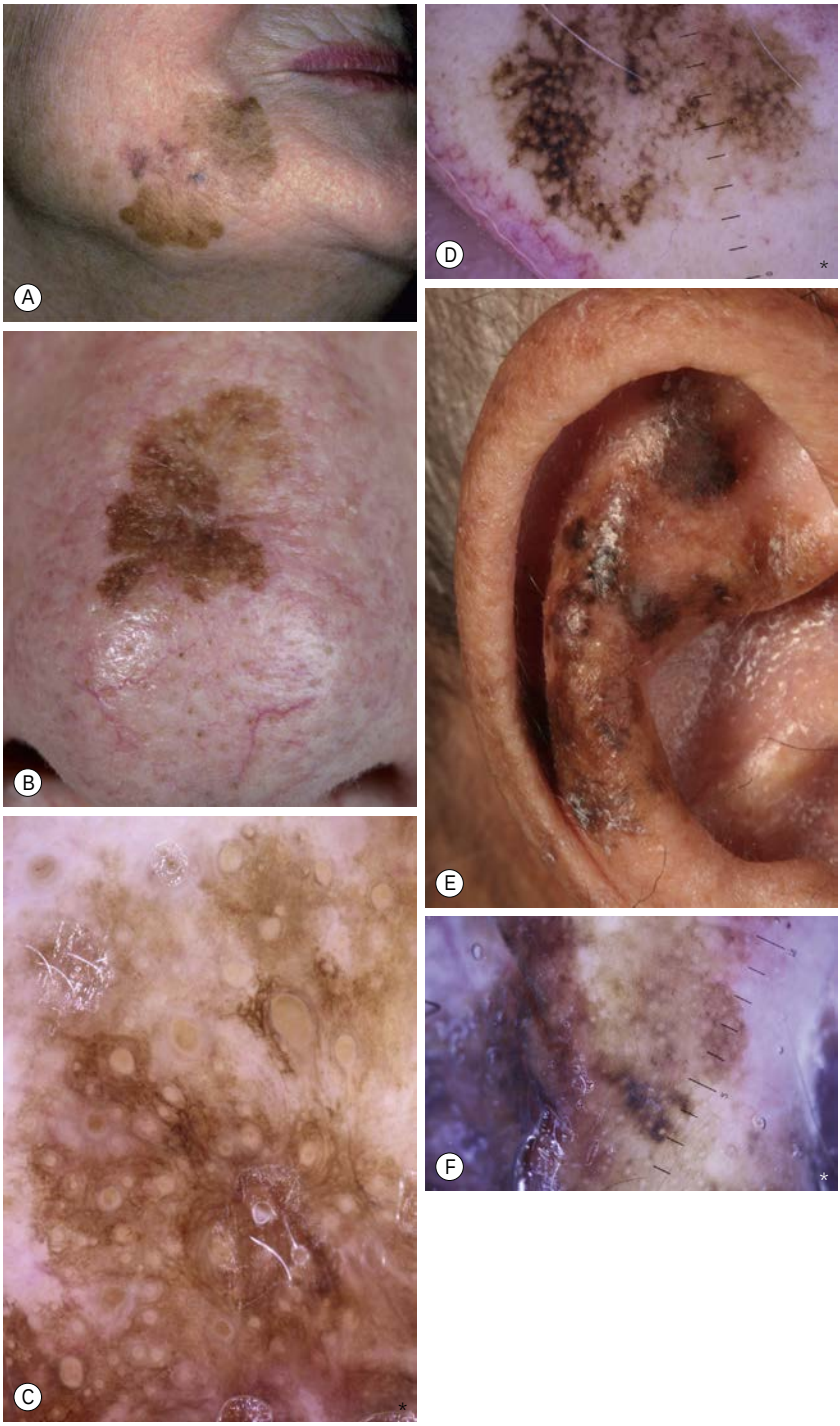


**eFig. 93.6 Lentigo maligna (LM) and lentigo maligna melanoma (LMM).** **A** Large-sized brown patch with some variation in color representing lentigo maligna. **B** LMM on the dorsal nose, with irregular borders, light to dark brown color, and marked asymmetry. **C** Dermoscopy* of this lesion demonstrating annular structures corresponding to follicular openings surrounded by melanoma cells ("circle in a circle"). **D** Dermoscopy* of another LMM (Breslow depth of 0.45 mm), demonstrating asymmetric pigmentation of the follicular openings and annular granular structures. **E, F** A more advanced LMM on the ear (**E**) (Breslow depth of 0.86 mm), with corresponding dermoscopy* (**F**). *A, Courtesy, YDRSC; B, C, Courtesy, Claus Garbe, MD; D–F Courtesy, Claus Garbe, MD and Jürgen Bauer, MD.*



**eFig. 93.7 Acral lentiginous melanoma (ALM).** Multi-colored, ulcerated and bleeding plaque on the plantar foot. This patient also has tinea pedis, as noted by the tiny erythematous-brown vesicles. *Courtesy, Kalman Watsky, MD.*

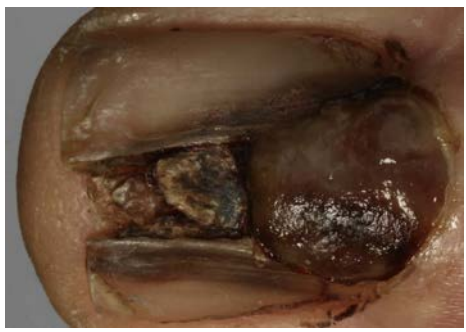

**eFig. 93.8 Melanoma of the nail matrix.** Ulcerated tumor destroying the nail plate. The longitudinal pigmentation of the nail plate adjacent to the nodular portion is a clue to the diagnosis of melanoma. *Courtesy, Claus Garbe, MD.*

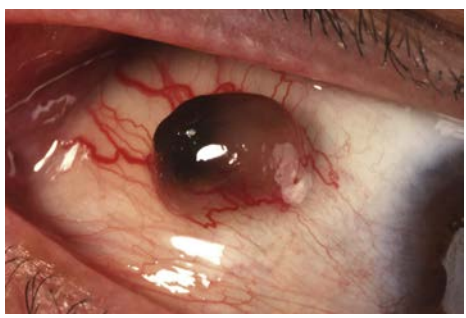

**eFig. 93.9 Conjunctival melanoma.** *Courtesy, Claus Garbe, MD and Jürgen Bauer, MD.*



**eFig. 93.10 Amelanotic melanoma.** Pink scaly plaque on the superior helix of the left ear. The patient presented with a 4-day history of a pruritic eruption on the ear. Biopsy revealed a superficial spreading melanoma invasive to a depth of 0.6 mm. *Courtesy, Karynne O. Duncan, MD.*



**eFig. 93.11 Melanoma in association with a cellular blue nevus (malignant blue nevus).** Satellite metastases are also present. *Courtesy, Helmut Kerl, MD.*



**eFig. 93.12 Cutaneous melanoma with regression.** An asymmetric, irregularly pigmented melanocytic lesion. The central depigmented zone is due to tumor regression and, histopathologically, fibrosis can be seen. *Courtesy, Claus Garbe, MD.*

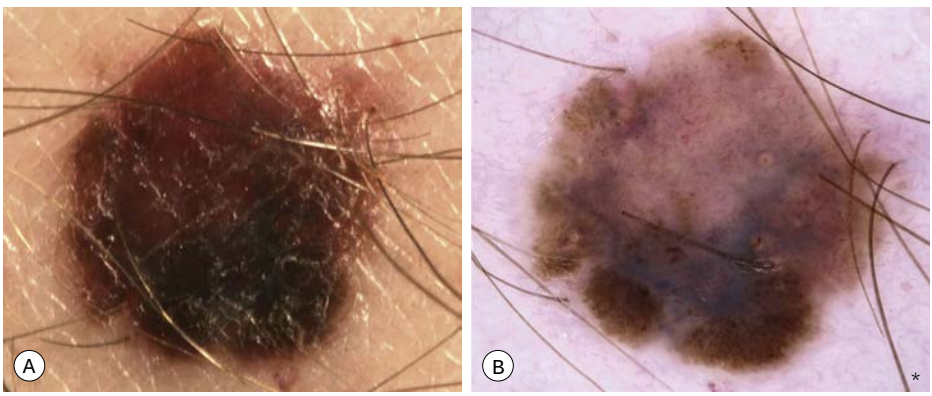


**eFig. 93.13 Illustration of dermoscopy.** This pair of images illustrates the clinical appearance (**A**), and the same lesion viewed with dermoscopy* (**B**). Greater detail can be appreciated at 10- to 20-fold magnification. This lesion is an early invasive melanoma with sharp demarcation, asymmetry, and a central blue-whitish veil. *Courtesy, Claus Garbe, MD and Jürgen Bauer, MD.*

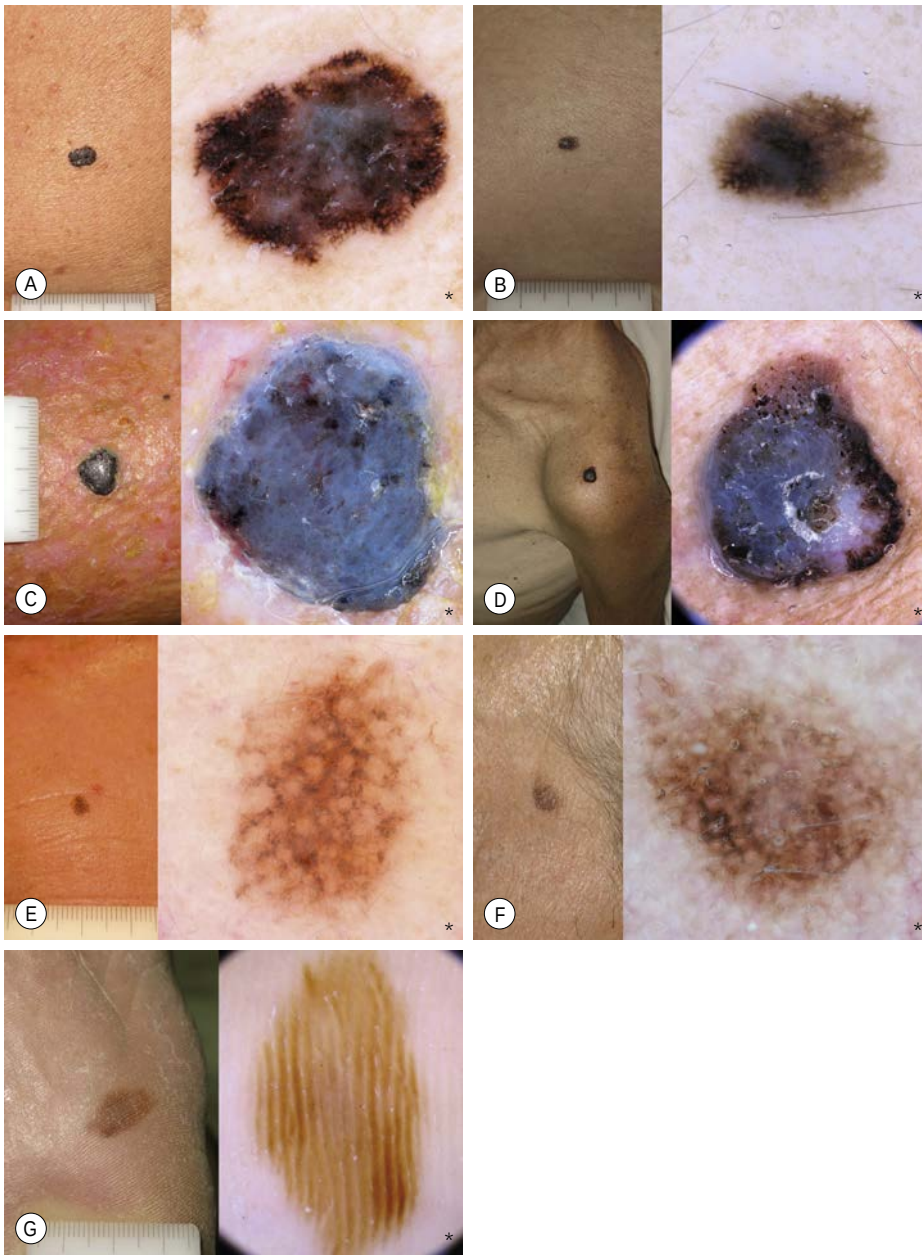


**eFig. 93.14 Dermoscopy of the most common types of cutaneous melanoma. A, B** Small *superficial spreading melanomas* typified dermoscopically* by asymmetry of color and structure, atypical network, blue-white structures, and irregular streaks at the periphery (**B**). **C, D** Large thick *nodular melanomas* with predominant blue-white veil. Dermoscopically*, the combination of blue color with irregular black to brown dots, globules, and blotches is highly specific for the diagnosis of thick melanoma. **E, F** Small *facial melanomas in situ* (lentigo maligna) typified by gray granules around the hair follicles (**E**) and gray color and rhomboidal structures (**F**) by dermoscopy*. **G** *Acral melanoma in situ* typified by the characteristic parallel-ridge pattern*. *Courtesy, Giuseppe Argenziano, MD, and Iris Zalaudek, MD.*

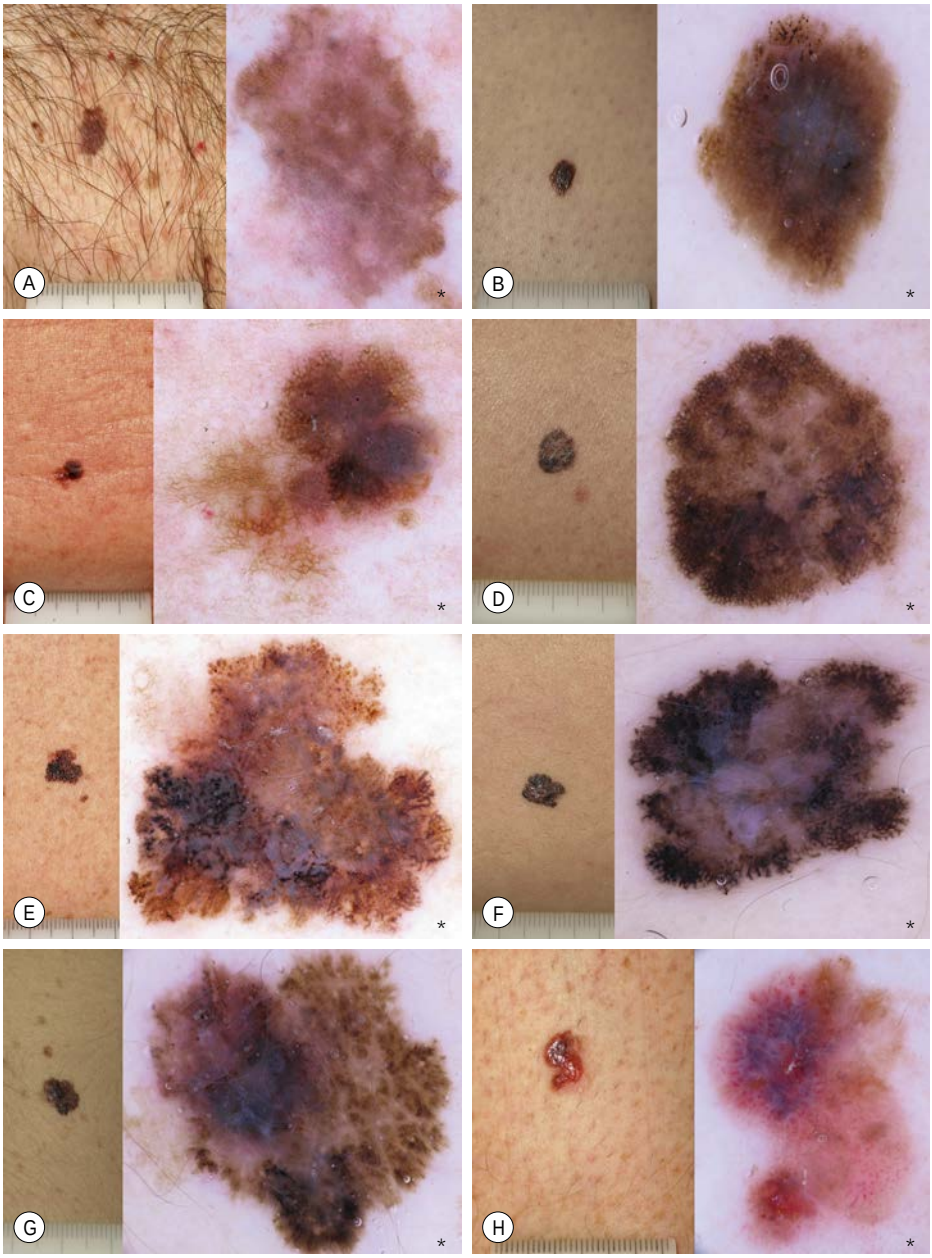


**eFig. 93.15 Dermoscopic examples of superficial melanomas of increasing tumor thickness. A, B** *Melanomas in situ* typified dermoscopically* by asymmetry of color and structure, atypical network, and blue-white structures intermingled with dotted vessels (**A**) and irregular black dots and globules (at the upper portion of the lesion in **B**). **C, D** Melanomas 0.5 mm in depth typified predominantly by an atypical pigment network and blue-white structures (**C**) and regression structures (**D**). **E, F** Melanomas 0.8 mm (**E**) and 0.75 mm (**F**) in depth typified by multiple melanoma-specific criteria including asymmetry of color and structure, irregular dots and globules, blue-white structures, and peripheral irregular streaks. **G** Melanoma 0.9 mm thick. Clinically, a palpable area is visible, corresponding dermoscopically to the presence of a blue-white veil, a sign of increased tumor thickness. Irregular dots and globules (at the upper side), irregular streaks at the periphery, and uneven brown to black pigmented areas (blotches) are also observed. **H** Melanoma 1.3 mm in depth typified predominantly by blue-white veil and atypical vascular pattern, both signs of increased tumor thickness. Remnants of an atypical pigment network and irregular brown globules are also observed. *Courtesy, Giuseppe Argenziano, MD, and Iris Zalaudek, MD.*

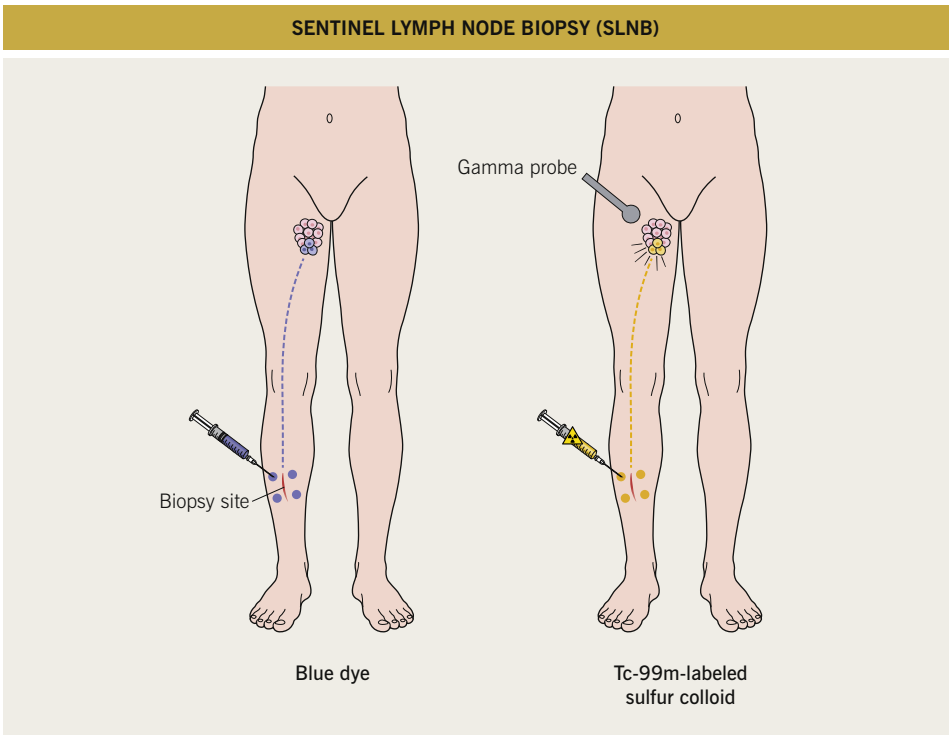


**eFig. 93.16 Sentinel lymph node biopsy (SLNB).** Identification of the sentinel node(s) using the injection of blue dye, technetium-99m-labeled sulfur colloid, or both. Re-excision is performed after the injections. *Redrawn from Olhoffer IH and Bolognia JL. What's new in the treatment of cutaneous melanoma. Semin Cutan Med Surg 1998;17(2):96–107.*

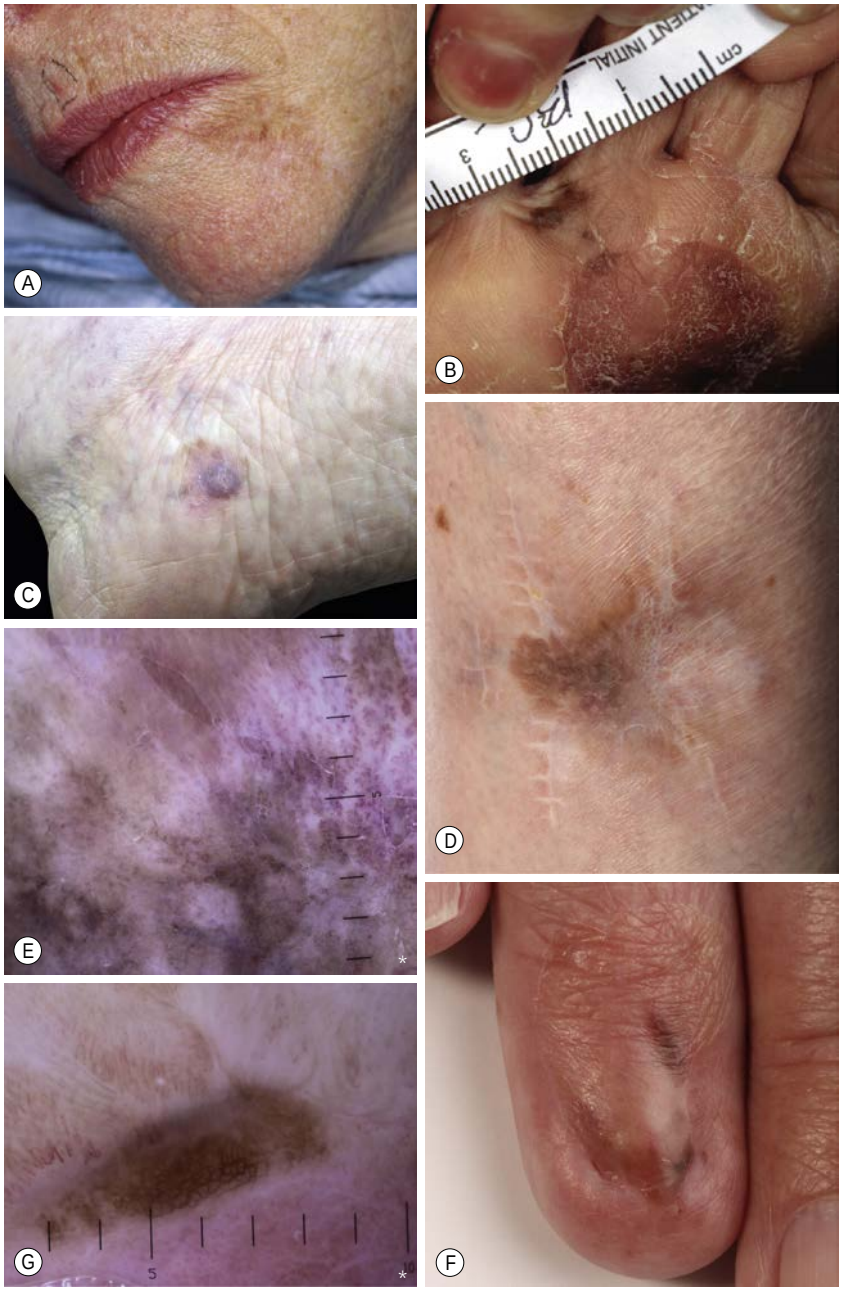


**eFig. 93.17 Local recurrences of cutaneous melanoma.** **A** Recurrent lentigo maligna along upper lateral margin of the excision on the chin; inked lesion on central upper lip is an actinic keratosis. **B** Recurrent, *in situ* acral lentiginous melanoma at the 10 o'clock position on the split-thickness skin graft. **C** Recurrent melanoma (invasive to a depth of 3.2 mm) on the left medial foot; the original excision had been performed 16 years prior to this presentation. **D** Recurrent lentigo maligna on the lower leg; note the depressed scar due to repeated excisions. **E** By dermoscopy*, an asymmetric pattern with multiple colors, ranging from light brown to dark blue-gray. **F** Recurrent acral lentiginous melanoma of the nail unit. The lentiginous types of melanoma have a propensity to recur. **G** By dermoscopy*, an asymmetric pattern with an atypical network inferiorly and multiple colors including blue-gray and gray-white. *A, B, Courtesy, Jean L. Bolognia, MD; C, Courtesy, Karynne O. Duncan, MD; D–G, Courtesy, Claus Garbe, MD and Jürgen Bauer, MD.*

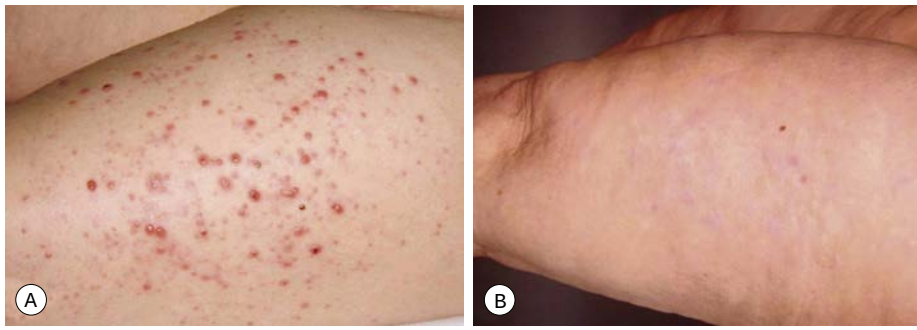


**eFig. 93.18 In-transit metastases of melanoma. A** Multiple pink papulonodules along the lymphatics were treated with intralesional low-dose IL-2 for 6 weeks. **B** Complete remission after 1 year, which persisted during the follow-up period of 7 years. *Courtesy, Clause Garbe, MD.*

| DIFFERENT TYPES OF PRIMARY CUTANEOUS MELANOMA | | | |
|---|---|---|---|
| **Clinicohistopathologic subtype** | **Abbreviation** | **Percentage** | **Median age** |
| Superficial spreading melanoma | SSM | 57.4% | 51 years |
| Nodular melanoma | NM | 21.4% | 56 years |
| Lentigo maligna melanoma | LMM | 8.8% | 68 years |
| Acral lentiginous melanoma | ALM | 4% | 63 years |
| Unclassifiable melanoma | UCM | 3.5% | 54 years |
| Others | | 5% | 54 years |

**eTable 93.1 Different types of primary cutaneous melanoma.** Data from the German Central Malignant Melanoma Registry (n=30,015).

| NON-MELANOCYTIC CLINICAL SIMULATORS OF MELANOMA |
|---|
| **Simulating superficial spreading melanoma** |
| • Seborrheic keratosis<br>• Thrombosed hemangioma, angiokeratoma<br>• Pigmented basal cell carcinoma<br>• Pigmented actinic keratosis<br>• Extramammary Paget disease<br>• Bowen disease including pigmented variant |
| **Simulating nodular melanoma** |
| • Seborrheic keratosis<br>• Pyogenic granuloma<br>• Dermatofibroma<br>• Thrombosed hemangioma, angiokeratoma<br>• Pigmented basal cell carcinoma<br>• Pigmented poroma and pigmented porocarcinoma<br>• Pigmented pilomatricoma<br>• Pigmented dermatofibrosarcoma protuberans (Bednar tumor) |

**eTable 93.2 Non-melanocytic clinical simulators of melanoma.** *Continued*

| NON-MELANOCYTIC CLINICAL SIMULATORS OF MELANOMA |
|---|
| **Simulating lentigo maligna melanoma** |
| • Macular seborrheic keratosis<br>• Solar keratosis, including the pigmented variant<br>• Pigmented basal cell carcinoma |
| **Simulating acral lentiginous melanoma of the palms and soles** |
| • Black heel (hemorrhage in stratum corneum caused by trauma)<br>• Plantar warts<br>• Trophic ulcers<br>• Plantar callosity<br>• Tinea nigra |
| **Simulating subungual acral lentiginous melanoma** |
| • Subungual hematoma<br>• Bowen disease<br>• Verruca<br>• Paronychia<br>• Drug-induced nail pigmentation |
| **Simulating amelanotic melanoma** |
| • Superficial basal cell carcinoma<br>• Bowen disease<br>• Benign lichenoid keratosis<br>• Pyogenic granuloma |

**eTable 93.2** *Continued* **Non-melanocytic clinical simulators of melanoma.**

| DERMOSCOPIC CRITERIA AND THEIR CORRESPONDING HISTOPATHOLOGIC FEATURES | | | |
|---|---|---|---|
| **Criterion** | **Morphologic definition** | **Associated histopathologic changes** | **Diagnosis** |
| Pigment network | Network of brownish lines over a diffuse tan background | Pigmented rete ridges | Melanocytic lesion |
| Typical network | Brown-colored, regularly meshed and narrowly spaced network | Regular and elongated rete ridges | Benign melanocytic lesion |
| Atypical network | Black, brown or gray network with irregular meshes and thick lines | Irregular and broadened rete ridges | Melanoma |
| Dots/ globules | Black, brown and/or gray, round to oval, variably sized structures regularly or irregularly distributed within the lesion | Pigment aggregates within the stratum corneum, epidermis, dermal–epidermal junction or papillary dermis | If regular: benign melanocytic lesion; if irregular: melanoma |
| Streaks | Irregular, linear structures not clearly combined with pigment network lines at the margins | Confluent junctional nests of melanocytes | Melanoma |
| Blue-white veil | Irregular, confluent, gray-blue to whitish-blue diffuse pigmentation | Acanthotic epidermis with focal hypergranulosis above sheets of heavily pigmented melanocytes in the dermis | Melanoma |

**eTable 93.3 Dermoscopic criteria and their corresponding histopathologic features.** *Continued*

| DERMOSCOPIC CRITERIA AND THEIR CORRESPONDING HISTOPATHOLOGIC FEATURES | | | |
|---|---|---|---|
| **Criterion** | **Morphologic definition** | **Associated histopathologic changes** | **Diagnosis** |
| Blotches | Black-, brown- and/or gray-colored areas with regular or irregular shape/distribution | Hyperpigmentation throughout the epidermis and/or upper dermis | If regular: benign melanocytic lesion; if irregular: melanoma |
| Regression structures | White (scar-like) areas, blue (pepper-like) areas or combinations of both | Thickened papillary dermis with fibrosis and/or variable amounts of melanophages | Melanoma |
| Milia-like cysts | White-yellowish, roundish dots | Intraepidermal horn globules, also called horn pseudocysts | Seborrheic keratosis (occasionally observed in papillomatous melanocytic nevi) |
| Comedo-like openings | Brown-yellowish, round to oval or even irregularly shaped, sharply circumscribed structures | Keratin plugs situated within dilated follicular openings | Seborrheic keratosis |
| Leaf-like areas | Brown-gray to gray-black patches revealing a leaf-like configuration | Pigmented, solid aggregations of basaloid cells in the papillary dermis | Basal cell carcinoma |
| Red-blue lacunas | Sharply demarcated, roundish to oval areas with a reddish, red-bluish, or red-black color | Dilated vascular spaces situated in the upper dermis | Vascular lesion |
| Vascular structures | Comma-like vessels | | Benign melanocytic lesion |
| | Arborizing vessels | | Basal cell carcinoma |
| | Hairpin vessels | | Seborrheic keratosis |
| | Dotted or irregular vessels | | Melanoma |

**eTable 93.3** *Continued* **Dermoscopic criteria and their corresponding histopathologic features.**
*With permission from Argenziano & Soyer; Lancet Oncol 2001;2:443–9.*

| CUTANEOUS MELANOMA – COMPONENTS OF THE HISTOPATHOLOGIC REPORT |
|---|
| **Mandatory** |
| Diagnosis of malignant melanoma<br>Tumor thickness (Breslow depth)<br>Ulceration (if present)<br>Margins |
| **Desirable** |
| Histopathologic subtype of melanoma<br>Regression, tumor-infiltrating lymphocytes, presence of plasma cells<br>Vascular invasion<br>Microscopic satellites<br>Associated nevus<br>Mitotic rate |

**eTable 93.4 Cutaneous melanoma – components of the histopathologic report.**

| DIFFERENTIAL DIAGNOSIS OF MELANOMA – MOLECULAR DIAGNOSTICS THAT CAN BE UTILIZED | | | |
|---|---|---|---|
| **Test** | **Detects** | **Advantages** | **Disadvantages** |
| Comparative genomic hybridization (CGH) | Chromosomal gains and losses (DNA copy number changes) | Genome-wide screening for chromosomal gains and losses without prior knowledge of the genomic aberrations | • No detection of mutations (single nucleotide changes), small gains or deletions, balanced translocations, and polyploidy<br>• A low percentage of neoplastic cells in the specimen leads to false negative results |
| Fluorescent *in situ* hybridization (FISH) | Deletions, amplifications, translocations | Each cell nucleus is evaluated individually so that even tumors with a low percentage of neoplastic cells can be analyzed without the risk of false negative results | • No detection of mutations or small copy number aberrations<br>• Analyzes only a limited number of chromosomal loci (usually 4–6)<br>• Prior knowledge of the genomic aberrations necessary to build the probe<br>• Poor interobserver reproducibility |
| Gene expression profiling (GEP) | Gene expression levels of selected genes, usually 20 to 30 | • May predict the risk of metastasis for cutaneous melanomas*<br>• May distinguish benign melanocytic nevi from cutaneous melanomas | • Evaluates gene expression levels, but gives no information regarding the underlying genomic aberrations<br>• In selected, unequivocal benign or malignant lesions, the sensitivity and specificity appears to be ~80–90%, but the diagnostic value for ambiguous lesions remains undetermined |

**Currently used to predict metastatic risk in uveal melanomas.*

**eTable 93.5 Differential diagnosis of melanoma – molecular diagnostics that can be utilized.** These tests have been used to assist in the diagnosis of ambiguous and/or controversial melanocytic tumors as well as for prognostication (mainly GEP in the case of melanoma). *Courtesy, Claus Garbe, MD and Jürgen Bauer, MD.*

| SYMPTOMS AND DIAGNOSTIC TESTS FOR METASTATIC MELANOMA | | |
|---|---|---|
| **Metastatic site (TNM)** | **Symptoms** | **Diagnostic tests*** |
| Skin, soft tissue metastasis (TxNxM1a), in-transit metastasis (TxN1–3cM0) | Papules or nodules that vary in color from skin-toned to pink-red to blue, brown or black; secondary ulceration or bleeding | Histopathologic examination |
| Brain metastasis (TxNxM1d) | Headache, nausea, seizures, focal weakness, visual disturbance, paresthesias | MRI, CT or PET-CT |
| Lung metastasis (TxNxM1b) | Chest pain, dyspnea, cough, hemoptysis | Chest radiograph, CT or PET-CT |
| Gastrointestinal or liver metastasis (TxNxM1c) | • GI: abdominal pain, signs of anemia (e.g. fatigue, chest pain), vomiting, constipation, melena | • CBC, CT or PET-CT; colonoscopy |
| | • Liver: abdominal pain, jaundice | • Liver function tests, LDH; CT, PET-CT or MRI |
| Bone metastasis (TxNxM1c) | Pain, spontaneous fractures | Bone scan or PET-CT |

**Always include a thorough medical history and physical examination as well as complete blood count (CBC) and blood chemistry including lactate dehydrogenase (LDH). Special procedures such as detection of soluble melanoma markers (e.g. S100, melanoma inhibitory activity [MIA] protein) are performed at selected melanoma referral centers, especially in Europe.*

**eTable 93.6 Symptoms and diagnostic tests for metastatic melanoma.** PET, positron emission tomography.

# 94 Vascular Neoplasms and Reactive Proliferations

Lesions of vascular origin are broadly, and somewhat imperfectly, classified as neoplasms (tumors), malformations, reactive proliferations, or telangiectasias. The growth of a neoplasm is largely autonomous (i.e. not reactive). Malformations, in general, are not actively proliferating (see Ch. 85). Reactive proliferations represent endothelial cell proliferation that is in response to some factor (e.g. fibrin, hypoxia, trauma). Telangiectasias represent pre-existing capillaries that are persistently dilated but lack a proliferative component (see Ch. 87).

## Neoplasms/Tumors

### Infantile Hemangioma and Congenital Hemangioma

- See Chapter 85.

### Cherry Angioma

- Bright red, 1- to 6-mm papule, commonly on the trunk or upper extremities (Fig. 94.1); appears during adulthood; early, tiny lesions can be macular.
- Dermoscopy: red to red-blue lacunas (well-demarcated round to oval, red to red-blue structures).

### Glomus Tumor

- Solitary, painful papule or nodule on the extremities, or in the nail bed (beneath the nail plate) in young adults (Fig. 94.2).
- A glomus cell is a perivascular contractile cell that influences vessel diameter as a means of controlling temperature.

### Tufted Angioma

- Pink to dark red patches and plaques with superimposed papules (Fig. 94.3) that slowly enlarge and occasionally regress.
- Commonly found on the neck and trunk.
- Congenital or acquired during childhood or young adulthood.
- On a spectrum with kaposiform hemangioendothelioma.
- Early-onset lesions can be associated with Kasabach–Merritt phenomenon (consumptive coagulopathy with decreased platelets) – see below.

### Kaposiform Hemangioendothelioma

- Ill-defined, pink to violaceous plaques or nodules (Fig. 94.4); sometimes deeply seated; any site.
- May be congenital and generally appears by 2 years of age.
- Locally aggressive, persistent.

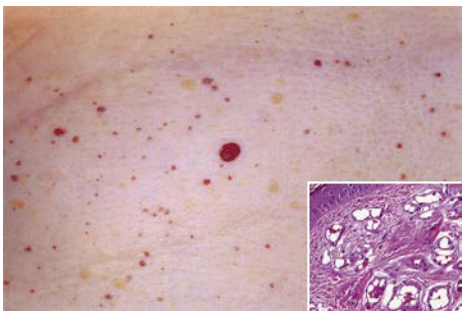

**Fig. 94.1 Cherry angiomas.** Multiple, slightly compressible red papules. Histologically, congested capillaries and postcapillary venules expand the papillary dermis (inset). *Courtesy, Jean L. Bolognia, MD.*



**Fig. 94.2 Glomus tumor.** The lesion presented with pain and ill-defined subungual erythema. *Courtesy, Ronald P. Rapini, MD.*



**Fig. 94.3 Tufted angioma.** Mottled red patches and superimposed papules are typical clinical features. *Courtesy, YDRSC.*



**Fig. 94.5 Classic Kaposi sarcoma.** Red macules and patches on the plantar surface of the foot, with violaceous plaques on the ankle. *Courtesy, Paula North, MD.*



**Fig. 94.4 Kaposiform hemangioendothelioma complicated by Kasabach–Merritt phenomenon.** A large red-purple mass on the upper flank of an infant. *Courtesy, YDRSC.*

- Associated with Kasabach–Merritt phenomenon (KMP).
  - Life-threatening thrombocytopenic coagulopathy associated with a vascular tumor, usually a kaposiform hemangioendothelioma or tufted angioma in an infant (*not* an infantile hemangioma)
  - Presents with a rapidly enlarging, indurated, ecchymotic mass associated with marked thrombocytopenia and a consumptive coagulopathy (see Fig. 94.4)
  - **Rx:** difficult; sirolimus (rapamycin) or vincristine plus prednisone

## Kaposi Sarcoma

- Multifocal systemic disease; extramucocutaneous sites include gastrointestinal tract, lymph nodes, and lungs.
- Four main variants: (1) older men from the Mediterranean basin or of Ashkenazi Jewish descent with lesions on the lower extremities (Fig. 94.5); (2) African endemic; (3) iatrogenic/immunocompromised; and (4) AIDS-related epidemic (Fig. 94.6).
- Pink to dark violet patches and plaques; with time, can become nodular.
- May have mucosal involvement, e.g. oral.
- Associated with human herpes virus-(HHV-) 8 infection.
- Histopathology varies from a subtle increase in slit-like vessels to nodular proliferations of spindle cells; HHV-8 can be detected in endothelial cells by immunohistochemistry.
- **Rx:** observation, surgical excision, cryotherapy, laser removal, radiotherapy, topical alitretinoin, intralesional or systemic vinblastine, taxanes, liposomal anthracyclines, pomalidomide, reduction of immunosuppression.

## Angiosarcoma

- Most commonly begins as a bruise-like patch in the head and neck region of older adults with color varying from pink to dark purple (likened to the color of an eggplant); also associated with lymphedema (Fig. 94.7) or previously irradiated skin (Fig. 94.8).
- With time nodules and ulceration can develop.
- 15% survival at 5 years.
- **Rx:** wide excision ± radiotherapy; consider systemic therapy with taxanes, tyrosine kinase inhibitors (e.g. sorafenib, pazopanib), or bevacizumab for larger lesions.

# Malformations (see Ch. 85)

## Glomuvenous Malformation (Previously Referred to as Glomangioma)

- See Chapter 85.



**Fig. 94.6 Kaposi sarcoma in a patient with AIDS.** Violet-red papules or nodules are often oval to lance-ovate and are usually more widely distributed than in classic KS. *Courtesy, Paula North, MD.*



**Fig. 94.7 Angiosarcoma.** Erythematous and purple hemorrhagic plaques as well as grouped vesicles with clear or hemorrhagic fluid (reminiscent of microcystic lymphatic malformation) are present. There is also induration and a pink hue to the left side of the face in addition to evidence of previous excisions and radiotherapy. *Courtesy, Lorenzo Cerroni, MD.*

### Targetoid Hemosiderotic Lymphatic Malformation (Previously Referred to as Hobnail "Hemangioma"/Targetoid Hemosiderotic Hemangioma)

- Uncommon red-purple papule on the trunk or extremities of children or young adults; papule may have a surrounding pale area and outer ecchymotic ring, thus creating a target lesion (Fig. 94.9).

## Reactive Proliferations

- Some consider pyogenic granuloma, angiolymphoid hyperplasia with eosinophilia (epithelioid hemangioma), and glomeruloid hemangioma to be tumors.

### Pyogenic Granuloma

- Rapidly growing, friable, red papulonodule that is sometimes pedunculated; often ulcerates and bleeds; common in children and young adults.
- Gingival and fingers > lips > face > tongue (Fig. 94.10).
- May arise on the gingiva of pregnant women (granuloma gravidarum).
- Multiple tumors (especially periungual) may be seen in association with medications (e.g. oral retinoids, antiretroviral protease inhibitors, EGFR inhibitors).
- **DDx:** need to distinguish from amelanotic melanoma and Spitz nevus.
- **Rx:** shave excision or saucerization followed by electrosurgery of the base under local anesthesia.



**Fig. 94.8 Post-radiation angiosarcoma.** Red-violet patches and plaques on the breast. The clinicopathologic differential diagnosis is primarily post-radiation atypical vascular lesions of the skin, an entity that may represent a precursor of post-radiation angiosarcoma. Development of thicker, more indurated plaques and the presence of cellular atypia, multilayering of the vessels, and positivity for c-MYC favor angiosarcoma. *Courtesy, Paula North, MD.*



**Fig. 94.9 Targetoid hemosiderotic lymphatic malformation (hobnail "hemangioma" [targetoid hemosiderotic hemangioma]).** Note the target-like appearance. *Courtesy, Ronald P. Rapini, MD.*

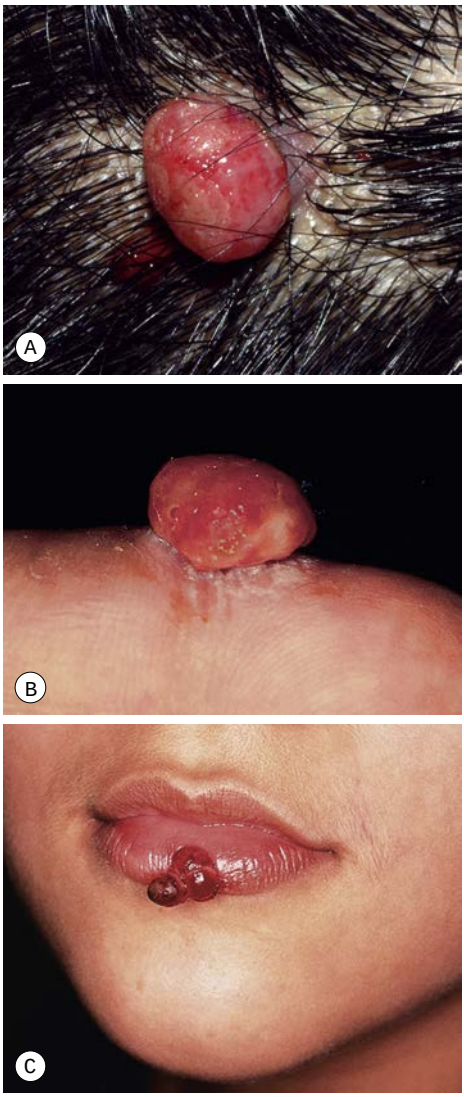


**Fig. 94.10 Pyogenic granuloma. A** Eroded pink-red papulonodule with a narrow base on the scalp. **B** Pedunculated papule on the finger. **C** Grouped red papules on the lip. The latter two are both common sites. By dermoscopy, red homogeneous areas are intersected by white lines. *A, Courtesy, Julie V. Schaffer, MD; B, C, Courtesy, Paula North, MD.*

## Angiolymphoid Hyperplasia with Eosinophilia (Epithelioid Hemangioma)

- Pink to red-brown nodules or plaques, often multiple and grouped.
- Favors the head and neck region, especially around ears (Fig. 94.11).
- May be painful, pruritic, or rarely pulsatile.
- Occasionally, peripheral eosinophilia.

## Glomeruloid Hemangioma

- Firm red papules or nodules on the trunk and proximal extremities.
- Associated with POEMS (polyneuropathy, organomegaly, endocrinopathy, monoclonal gammopathy, and skin findings) syndrome.



**Fig. 94.11 Angiolymphoid hyperplasia with eosinophilia (epithelioid hemangioma).** Multiple pink papulonodules are often seen on the scalp. *Courtesy, USCDRSC.*

### Reactive Angioendotheliomatosis

- Rare, self-limited.
- Erythematous nodules or plaques, often with petechiae or purpura.
- Associated with cryoglobulinemia (type I) or systemic disorders (e.g. renal failure).
- The form due to severe atherosclerosis leads to ulceration.

### Diffuse Dermal Angiomatosis

- Some consider this a variant of reactive angioendotheliomatosis.
- This term has been used to describe an ulcerated lesion in the setting of severe atherosclerosis or vascular compromise; these ulcers usually occur on the lower extremities and resolve with revascularization; less often occurs on the breast or pannus.

## Telangiectasias

- See Chapter 87.

## Angiokeratomas

- Dark red to purple papules that represent vascular ectasias; the affected blood vessels are often located in the most superficial portion of the dermis.
- Most commonly occur as multiple lesions on the scrotum or vulva (Fig. 94.12) or as an isolated lesion on the lower extremity (Fig. 94.13).
- Occasionally, angiokeratomas are grouped (circumscriptum and Mibelli forms) or rarely more widely distributed (diffusum form), especially within the girdle area; the latter form is a cutaneous manifestation of several lysosomal storage disorders (e.g. Fabry disease) (see Ch. 52).



**Fig. 94.12 Scrotal angiokeratomas.** These lesions typically arise along superficial vessels. *Courtesy, Christopher Baker, MD, and Robert Kelly, MD.*

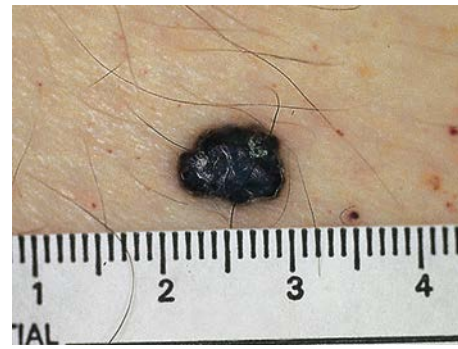


**Fig. 94.13 Solitary angiokeratoma.** Because of their dark color, these lesions may resemble cutaneous melanoma. Dermoscopy will readily distinguish between these two entities. *Courtesy, Jean L. Bolognia, MD.*

For further information see Ch. 114 from *Dermatology, Fourth Edition*.

**For additional online figures visit www.expertconsult.com**

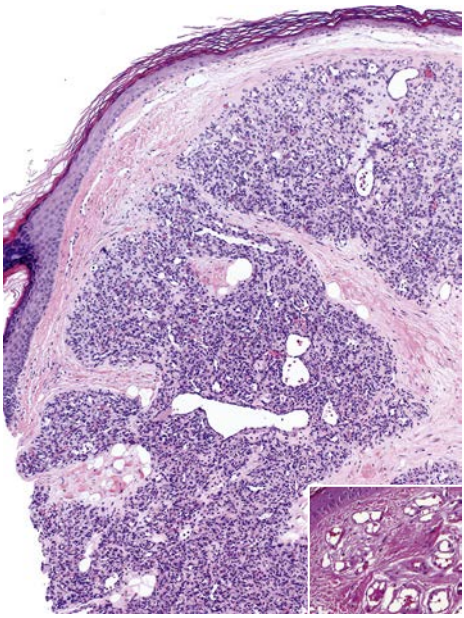

**eFig. 94.1 Histology of pyogenic granuloma (lobulary capillary hemangioma).** Exophytic nodule characterized by lobules of capillaries delineated by fibrous bands (hence the synonym lobular capillary hemangioma). The lesions are often clutched by an epithelial collarette and are commonly ulcerated. The inset shows the proliferation of small capillaries. *Courtesy, Lorenzo Cerroni, MD.*



**eFig. 94.2 Tufted angioma.** Pink-red to violet plaque in an infant that is broken up into smaller papules. *Courtesy, Julie V. Schaffer, MD.*

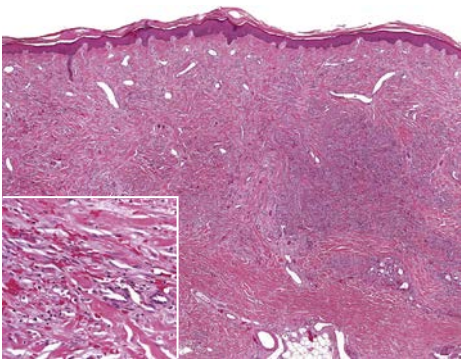

**eFig. 94.3 Histology of Kaposi sarcoma – plaque stage.** In the reticular dermis, there is a spindle cell vascular proliferation characterized by slit-like vascular spaces with extravasated erythrocytes (inset). *Courtesy, Lorenzo Cerroni, MD.*



**eFig. 94.4 Glomuvenous malformation ("glomangioma").** Large cluster of blue papulonodules becoming confluent centrally. *Courtesy, YDRSC.*

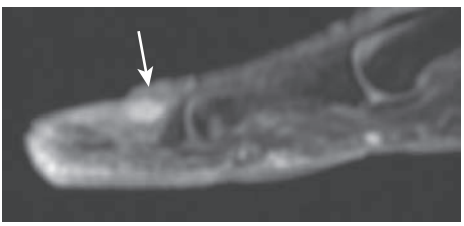

**eFig. 94.5 MRI of a glomus tumor located in the proximal portion of the nail bed and matrix.** While there was a low-signal lesion noted in T1-weighted images of the left index finger, the lesion was very bright in T2-weighted images with diffuse homogeneous enhancement with gadolinium (arrow). *Courtesy, Kalman Watsky, MD.*



**eFig. 94.6 Kaposiform hemangioendothelioma associated with Kasabach–Merritt phenomenon in a 5-week-old boy.** Progressive induration and ecchymosis developed rapidly over a 24-hour period. An eczematous eruption is also evident. *Courtesy, Julie V. Schaffer, MD.*

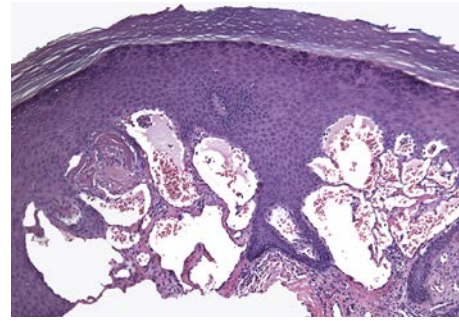

**eFig. 94.7 Angiokeratoma.** The white spaces within the dermis represent dilated blood vessels which contain erythrocytes and are lined by endothelial cells. Note how the vessels abut the undersurface of the epidermis. *Courtesy, Christine J. Ko, MD.*

# Common Soft Tissue Tumors/ Proliferations

# 95

## Neural/Neuroendocrine

### Neurofibroma

- Skin-colored to pink, soft papulonodule, often on the trunk (see Fig. 50.2).
- Compressible (the tumor often herniates inward upon palpation – this is referred to as the "button-hole" sign); it is sometimes pedunculated.
- Usually solitary in most individuals.
- When multiple, need to distinguish linear form (segmental; mosaic) from a generalized distribution pattern (neurofibromatosis type 1) (see Ch. 50).
- Histopathology: wavy, delicate spindle cells with tapered nuclei in a pink stroma.
- Plexiform type has been likened to a "bag of worms" (Fig. 95.1); it is generally on the trunk and proximal extremities, highly associated with neurofibromatosis type 1, and prone to malignant degeneration (2–13%).

### Schwannoma/Neurilemmoma

- Solitary, pink-yellow, soft, smooth papulonodule; generally seen in adults.
- Often on the extremities or head (Fig. 95.2).
- Asymptomatic (rarely painful).
- Histopathology: encapsulated tumor with foci of wavy, spindled nuclei in palisades and foci of myxoid change.

### Granular Cell Tumor

- Often in adults; skin-colored to brown-red, firm papulonodule; sometimes ulcerated or verrucous.
- 30% on the tongue.
- Multiple tumors in 10% of patients.
- Histopathology: polygonal cells with oval nuclei and characteristic granular cytoplasm.

### Traumatic Neuroma

- Skin-colored papulonodule(s) at a site of prior trauma.
- Often painful or "sensitive" (Fig. 95.3).
- Histopathology: haphazardly distributed fascicles of spindle cells with tapered nuclei.

### Merkel Cell Carcinoma

- In older adults; solitary, rapidly growing, pink to red to violaceous nodule (Fig. 95.4).
- Commonly on the head and neck.
- Pathogenesis involves clonal integration of Merkel cell polyoma virus DNA into the host genome in ~80%; UVR-signature mutations in the remainder.
- Aggressive behavior: distant metastases in 40%; 70% survival at 5 years if primary lesion is <2 cm in diameter; 18% survival at 5 years if distant metastatic disease.



**Fig. 95.1 Plexiform neurofibroma in a child with neurofibromatosis.** Bag-like mass with overlying patches of hyperpigmentation. *Courtesy, Zsolt B. Argenyi, MD.*



**Fig. 95.2 Solitary schwannoma.** Skin-colored nodule on the plantar surface of the great toe. *Courtesy, Julie V. Schaffer, MD.*



**Fig. 95.3 Traumatic neuroma.** A painful, firm papule that appeared after a deep puncture injury. *Courtesy, Zsolt B. Argenyi, MD.*



**Fig. 95.4 Merkel cell carcinoma (primary cutaneous neuroendocrine carcinoma).** Eroded erythematous nodule arising within sun-damaged skin of the cheek. *Courtesy, Lorenzo Cerroni, MD.*



**Fig. 95.5 Multiple skin tags in the axilla.** The lesions are skin-colored, soft, and pedunculated. *Courtesy, YDRSC.*

• Histopathology: islands or trabeculae of blue cells that on high-power magnification have chromatin that appears speckled like "salt and pepper"; characteristically cytokeratin 20 (CK20)-positive and thyroid transcription factor-1 (TTF1)-negative.

• **Rx:** consider baseline Merkel cell polyomavirus serology for prognostic significance and to track disease; optimally includes wide excision, accompanied by sentinel lymph node biopsy (SLNB); adjuvant radiation treatment recommended for most patients (exceptions: primary ≤1 cm, SLNB negative, no immunosuppression). For metastatic disease, consider a checkpoint inhibitor (e.g. pembrolizumab) or chemotherapy (e.g. etoposide and carboplatin).

## Fibrous/Fibrohistiocytic

### Skin Tag (Acrochordon, Fibroepithelial Polyp, Soft Fibroma)

• Common; skin-colored to pink or occasionally hyperpigmented, pedunculated papule.

• Sites of predilection: neck, axilla, groin (Fig. 95.5).

• Can become irritated or infarcted.



**Fig. 95.6 Fibrous papule of the nose.** A smooth, dome-shaped, skin-colored papule. *Courtesy, NYUDSC.*



**Fig. 95.7 Pearly penile papules.** Multiple small white papules along the corona of the glans penis. Note the multilayered distribution. *Courtesy, Kalman Watsky, MD.*

## Angiofibroma (Fibrous Papule)

- Solitary, skin-colored to pink, shiny papule; commonly on the nose (Fig. 95.6).
- When multiple, need to consider genodermatoses (e.g. tuberous sclerosis, multiple endocrine neoplasia type I).
- Histopathology: stellate spindle cells in a hyalinized stroma with dilated vessels.
- **DDx:** BCC, intradermal melanocytic nevus, adnexal tumors.

## Pearly Penile Papules

- Multiple, small, white to light pink papules along the corona of the glans penis, often with a multilayered distribution (Fig. 95.7).
- **Rx:** reassurance.

## Dermatofibroma

- 6- to 10-mm pink (especially in fair-skinned individuals), tan, or brown papule (Fig. 95.8; see Fig. 1.16D); firm; dimples inward with lateral pressure.
- Often on the lower extremities; women > men.
- Common; multiple lesions can be seen in normal individuals but also are associated with lupus erythematosus and immunosuppression (e.g. HIV infection).
- Histopathology: epidermal hyperplasia (sometimes with basaloid induction that resembles BCC) above a spindle cell proliferation that entraps collagen.
- Dermoscopic features are shown in Fig. 1.16D.



**Fig. 95.8 Dermatofibroma.** Hyperpigmented firm papule on the lower extremity. *Courtesy, Jean L. Bolognia, MD.*



**Fig. 95.9 Acral fibrokeratoma.** A light pink exophytic papule arising from the dorsal surface of the finger. *Courtesy, NYUDSC.*

## Acral Fibrokeratoma

- 4- to 10-mm solitary, skin-colored to pink, cone-shaped, keratotic papule with a collarette of elevated skin (Fig. 95.9).

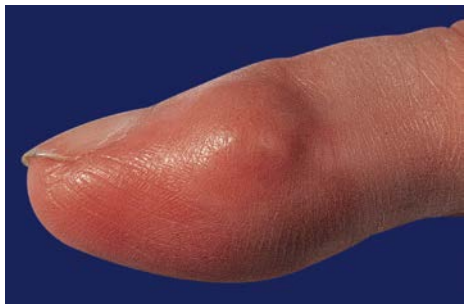

**Fig. 95.10 Giant cell tumor of tendon sheath.** A skin-colored nodule on the lateral aspect of the index finger. *Courtesy, NYUDSC.*

- Located on the fingers and sometimes the palms.

### Sclerotic Fibroma

- 2- to 9-mm dome-shaped, pearly papule or nodule in adults.
- Slight predilection for the head and neck.
- Can be seen in patients with Cowden disease.

### Giant Cell Tumor of Tendon Sheath

- Firm nodule (1–2 cm), generally on the fingers or toes (Fig. 95.10).
- 30% of tumors recur locally.

### Nodular Fasciitis

- Benign, reactive process in young adults.
- Rapidly growing subcutaneous nodule (1–5 cm in diameter).
- Commonly on the distal upper extremity.
- Sometimes associated with trauma.
- Histopathology: subcutaneous nodule of elongated spindle cells in a myxoid matrix.

### Connective Tissue Nevus

- Skin-colored to yellow-tan (more yellow when composed predominantly of elastic tissue), firm papulonodules or plaques; solitary or multiple (often grouped) (Fig. 95.11).
- Present at birth or arise during childhood.
- May be associated with genodermatoses (e.g. tuberous sclerosis, Buschke–Ollendorf syndrome, Proteus syndrome).
- Histopathology: increased collagen (sometimes subtle) and/or elastic tissue; diagnosis may require special stains for elastic fibers and collagen.



**Fig. 95.11 Connective tissue nevus.** Coalescence of multiple tan papules and plaques on the lower back. The lesion was firm to palpation and histologically had increased collagen. *Courtesy, YDRSC.*



**Fig. 95.12 Infantile digital fibroma.** Firm skin-colored nodule on the dorsolateral aspect of the second toe in a young child. *Courtesy, YDRSC.*



**Fig. 95.13 Knuckle pads.** Note the localization to the skin overlying the knuckles. *Courtesy, Ronald P. Rapini, MD.*

### Infantile Digital Fibroma

- Firm, skin-colored to pink papulonodule on the fingers or toes (tends to spare the thumb and great toe) (Fig. 95.12).



**Fig. 95.14 Pachydermodactyly.** A form of digital fibromatosis characterized by soft tissue swelling of the lateral aspects of the fingers, usually in the area of the proximal interphalangeal joints of the second to fourth fingers. *Courtesy, Julie V. Schaffer, MD.*



**Fig. 95.15 Clustered piloleiomyomas on the back.** The trunk is a common location for multiple piloleiomyomas. Patients with this clinical presentation need to be evaluated for the possibility of hereditary leiomyomatosis and renal cell cancer (Reed syndrome). *Courtesy, Julie V. Schaffer, MD.*

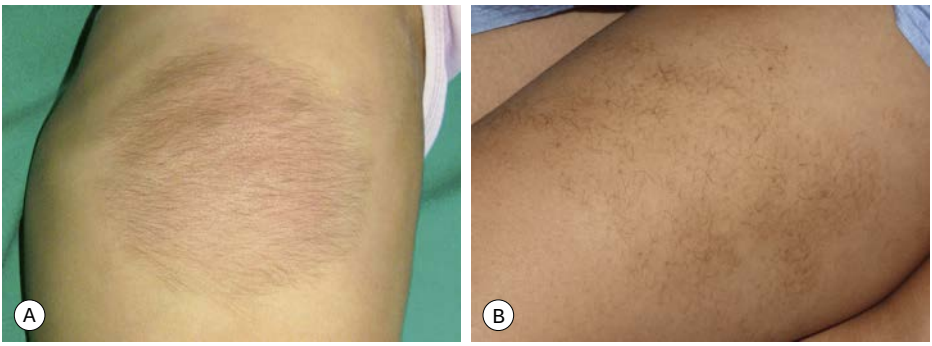


**Fig. 95.16 Smooth muscle hamartoma. A** A hyperpigmented plaque with hypertrichosis that can be misdiagnosed clinically as a congenital melanocytic nevus or less often a neurofibroma. **B** Sometimes the hamartoma has a broken-up appearance and there is overlap with Becker melanosis (nevus) both clinically and histologically. *A, Courtesy, Antonio Torello, MD; B, Courtesy, Julie V. Schaffer, MD.*

- Solitary or multiple; generally present before 1 year of age.
- Tend to spontaneously regress within a few years but may recur.

## Infantile Myofibromatosis

- One or more skin-colored to pink to violet, firm to rubbery dermal/subcutaneous nodules.
- Most commonly on the head and neck or trunk.
- Rare; lesions present at birth or appear during the first 2 years of life.
- Can have cutaneous lesions alone or systemic involvement (bone, gastrointestinal, kidneys, lungs, heart).
- Tumors tend to self-regress.
- Histopathology: biphasic pattern of spindle cells in nodular arrangements with vessels at the periphery.

## Fibromatoses

- Most subtypes are superficial: (1) palmar (Dupuytren disease); (2) plantar (Ledderhose disease); (3) penile (Peyronie disease); (4) knuckle pads (holoderma) (Fig. 95.13); and (5) pachydermodactyly (Fig. 95.14).




**Fig. 95.17 Lipomatoses. A** Familial multiple lipomatosis. Several discrete lipomas are present on the forearm. **B** Benign symmetric lipomatosis (Madelung disease). Large symmetric fatty deposits in the supraclavicular region, lateral chest, and abdomen. *A, Courtesy, YDRSC; B, Courtesy, Steven Kaddu, MD.*

- One deep form: extra-abdominal desmoid tumor.
- Slowly growing nodules or plaques or cord-like tumors.
- Palmar fibromatosis can result in flexion contractures, especially of the 4th and/or 5th finger (see Ch. 81).
- Penile fibromatosis can result in pain and erectile dysfunction.

## Muscle/Adipose

### Leiomyoma

- Solitary or multiple red-brown papules or nodules, often grouped (Fig. 95.15).
- Sometimes painful.
- Generally on the trunk.
- When multiple, consider association with uterine leiomyomas and papillary renal cell carcinoma (Reed syndrome: autosomal dominant familial cancer syndrome with mutation in fumarate hydratase).
- Histopathology: fascicles of spindle cells with cigar-shaped nuclei that have perinuclear vacuoles.

### Smooth Muscle Hamartoma

- Congenital or acquired, skin-colored to hyperpigmented plaque on the trunk > proximal extremities (Fig. 95.16).
- Follicular prominence and hypertrichosis may be present.
- May be confused with a congenital melanocytic nevus.
- Is on a clinicopathologic spectrum with Becker nevus.

### Lipoma

- Common tumor of mature fat; soft, mobile subcutaneous nodule.
- Generally on the trunk and extremities, but any site possible.
- Occasionally painful.
- Multiple lesions may be associated with a lipomatosis (e.g. familial type; Fig. 95.17) or a genodermatosis (e.g. Gardner syndrome, Proteus syndrome).
- **DDx:** see Fig. 95.18.

### Angiolipoma

- Soft, mobile, subcutaneous nodule; often on the forearm in young adults.
- Often painful.

### Nevus Lipomatosus

- Grouped, soft, yellow to skin-colored papulonodules on the hips and/or upper thighs (Fig. 95.19).
- Develops during infancy to the first two decades of life.

## Soft Tissue Sarcomas (Table 95.1)

- Rare in comparison to benign soft tissue tumors.
- Generally presents as a nonspecific, deep-seated nodule.
- May occasionally primarily involve the dermis.



**Most common**

- Lipoma*
  - Mobile, oval-shaped, lobulated
  - Soft to firm but not hard
  - Sometimes tender
  - Angiolipomas more frequently tender
- Epidermoid inclusion or pilar cyst*
  - Spherical
  - May have a surface pore
  - Often a history of "cheesy" drainage
  - Location aids in diagnosis, e.g. scalp (pilar cyst)

**Less common**

- Lymph node, inside or outside lymph node basin
- Soft tissue tumor (e.g. neurofibroma, schwannoma, angioleiomyoma, nodular fasciitis)
- Metastasis*, lymphoma or leukemia cutis
- Location aids in diagnosis
  - Elbow/extensor surfaces of joints - rheumatoid nodule
  - Palm/sole - fibromatosis
  - Wrist/ankle - ganglion cyst
  - Major body fold - burnt-out cyst due to hidradenitis suppurativa

**Unusual**

- Soft tissue sarcoma*
- Deposition (e.g. myxoma, calcinosis cutis)
- Adnexal tumor (e.g. pilomatricoma)
- Onchocercoma§

*Ultrasound examination can often distinguish the solid cellularity of a sarcoma or a metastasis from the fat of a lipoma and the cystic architecture of an epidermal inclusion cyst.

§Tropical regions of Latin America and Africa.

**Fig. 95.18 Approach to a "lump under the skin" in adults.** Incisional biopsy is preferred for the histopathologic evaluation of subcutaneous nodules while a punch biopsy suffices for dermal lesions. For bedside diagnosis of an epidermal inclusion cyst: after local anesthesia and superficial incision with a #11 blade, keratin is expressed.




**Fig. 95.19 Nevus lipomatosus superficialis.** **A** This hamartoma is characterized by grouped, soft, pedunculated, skin-colored tumors. **B** Histopathologically, irregular aggregates of mature fat cells ectopically located in the dermis are the characteristic feature. *Courtesy, Steven Kaddu, MD.*



**Fig. 95.20 Dermatofibrosarcoma protuberans.** A broad, pink-brown, multinodular, firm plaque on the back. Histopathologically, bland spindle cells are arranged in storiform ("cartwheel") patterns. *Courtesy, NYUDSC.*

| SELECTED SOFT TISSUE SARCOMAS |
|---|
| Angiosarcoma (can arise in setting of lymphedema and on the scalp of elderly patients) (see Ch. 94) |
| Atypical fibroxanthoma (Fig. 95.21) |
| Dermatofibrosarcoma protuberans (often multinodular; see Fig. 95.20) |
| Pleomorphic undifferentiated sarcoma (previously referred to as malignant fibrous histiocytoma*) |
| Malignant peripheral nerve sheath tumor |
| Epithelioid sarcoma |
| Fibrosarcoma |
| Leiomyosarcoma |
| Liposarcoma |
| **Some pathologists consider atypical fibroxanthoma (AFX) to be a superficial variant of malignant fibrous histiocytoma (MFH); dermatologists see AFXs more commonly than MFHs.* |

**Table 95.1 Selected soft tissue sarcomas.**



**Fig. 95.21 Atypical fibroxanthoma.** A red, dome-shaped nodule on the nose of an elderly man. *Courtesy, Lorenzo Cerroni, MD.*

- Dermatofibrosarcoma protuberans (DFSP) is characteristically multinodular (Fig. 95.20).
- Most DFSPs have a translocation t(17;22) that fuses the collagen I and platelet-derived growth factor genes; expression of this fusion gene results in high levels of platelet-derived growth factor that stimulates proliferation of fibroblasts.

For further information see Chs 115, 116, and 117 from *Dermatology, Fourth Edition*.

**For additional online figures and tables visit www.expertconsult.com**

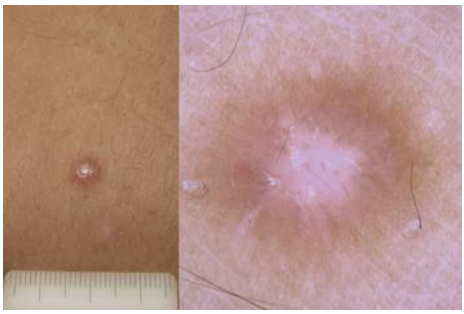

**eFig. 95.1 Dermoscopy of a dermatofibroma with characteristic central white patch and peripheral delicate pseudo-network.** *Courtesy, Giuseppe Argenziano, MD, and Iris Zalaudek, MD.*



**eFig. 95.2 Merkel cell carcinoma (primary neuroendocrine carcinoma).** A rapidly growing, violaceous nodule on the toe. *Courtesy, YDRSC.*



**eFig. 95.3 Infantile myofibromatosis.** Multiple firm violaceous papulonodules on the scalp. Gain-of-function mutations in *PDGFRB* have been described in multifocal cases. *Courtesy, YDRSC.*



**eFig. 95.4 Clustered piloleiomyomas on the back.** The trunk is a common location for multiple piloleiomyomas. Patients with this clinical presentation need to be evaluated for the possibility of Reed syndrome. *Courtesy, YDRSC.*



**eFig. 95.5 Nevus lipomatosus superficialis.** This hamartoma is characterized by grouped, soft, pedunculated, skin-colored tumors; a partial resection had been performed. *With permission from Kopf AW and Bart RS. J Dermatol Surg Oncol 1983;9:279–81.*

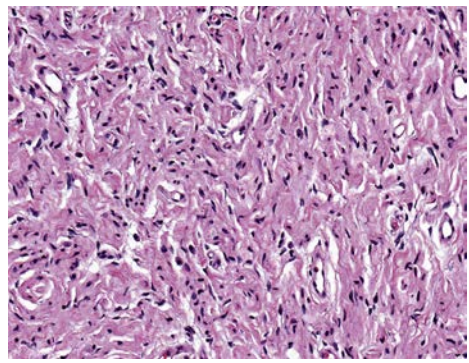

**eFig. 95.6 Neurofibroma.** The tumor contains a diffuse proliferation of spindle cells with slender, ovoid nuclei in a fibrillary matrix. Note several mast cells. *Courtesy, Lorenzo Cerroni, MD.*

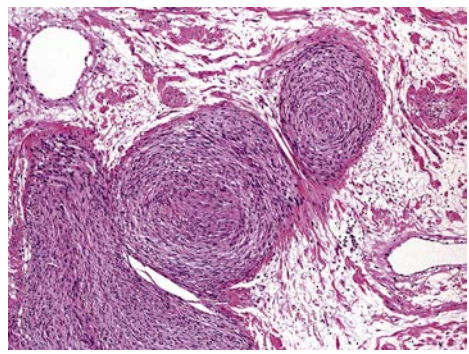

**eFig. 95.7 Plexiform neurofibroma.** Irregularly expanded, twisted nerve fascicles arranged in lobular structures. *Courtesy, Lorenzo Cerroni, MD.*

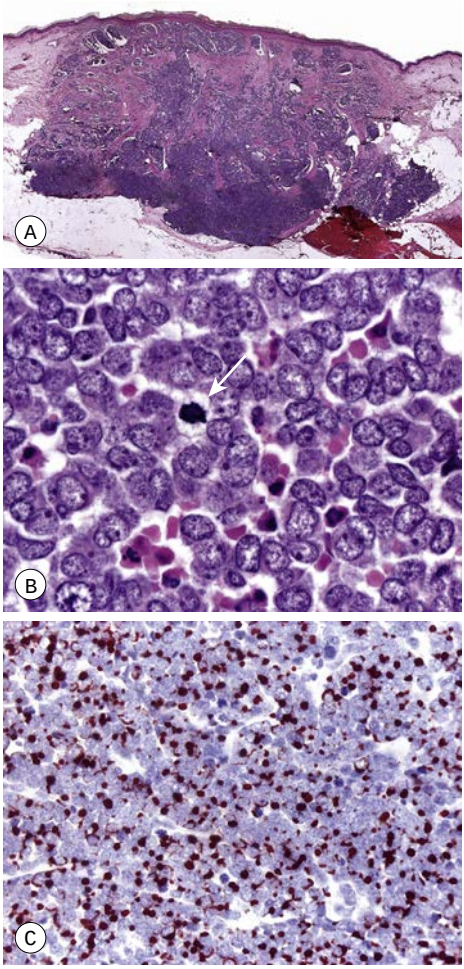


**eFig. 95.8 Primary neuroendocrine carcinoma of the skin (Merkel cell carcinoma).** **A** Nodular infiltrate of basaloid cells with focally small "trabecular" structures within the entire dermis and superficial subcutis. **B** Small, round to ovoid basaloid cells with vesicular nuclei and small nucleoli; note several necrotic (apoptotic) cells and a mitotic figure (arrow). **C** Immunohistochemical stain for cytokeratin 20 demonstrates a characteristic perinuclear dot pattern. *Courtesy, Lorenzo Cerroni, MD.*

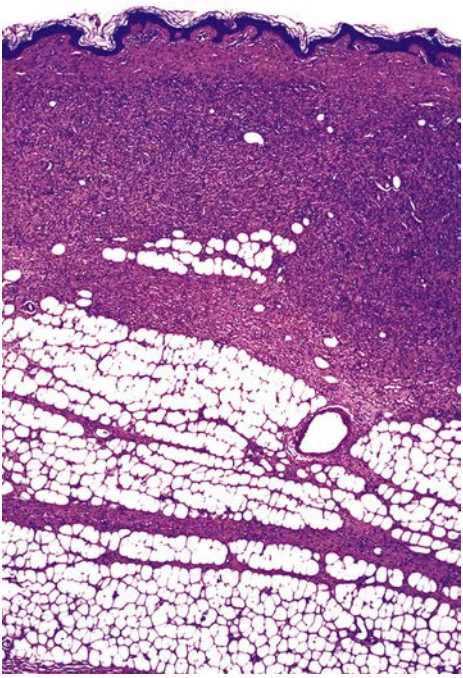

**eFig. 95.9 Dermatofibrosarcoma protuberans, plaque stage.** Characteristic multilayered pattern of infiltration into the subcutaneous tissue.

| CLINICAL FEATURES OF HEREDITARY LEIOMYOMATOSIS AND RENAL CELL CANCER (REED SYNDROME) | |
|---|---|
| **Genetic aspects** | Autosomal dominant<br>Mutations in the gene on chromosome 1q42.3-43 that encodes fumarate hydratase, an enzyme in the mitochondrial Krebs cycle |
| **Clinical features** | Cutaneous leiomyomas: appear during the second to fourth decade and multiple painful, grouped, skin-colored to red-brown papules during the second to fourth decades<br>Uterine leiomyomas: >90% of affected women; menorrhagia and pelvic pressure or pain<br>Renal cell cancer: 10–16% of patients with syndrome; most commonly type 2 papillary renal cell carcinomas that are often early-onset and aggressive (metastases in >50% of patients) |
| **Screening of individuals with multiple cutaneous leiomyomas** | Abdominal and pelvic ultrasound (or CT scan)<br>Complete history and physical examination, including pelvic examination in women<br>Immunohistochemistry of cutaneous leiomyomas: (1) negative staining for fumarate hydratase (in one series, 83% sensitivity and 75% specificity was found*); and (2) intracellular accumulation of S-(2-succino)-cysteine<br>Genetic testing for heterozygous pathogenic variant in the fumarate hydratase gene (*FH*; 70–90% detected by sequence analysis)<br>If pathogenic *FH* variant not detected, can measure fumarate hydratase activity (will be ≤60%) |
| **Patients with confirmed syndrome** | Complete history and physical examination yearly, including pelvic examination in women<br>Yearly abdominal MRI (if baseline or follow-up scan normal)<br>If renal lesion detected, then CT scan and renal ultrasound performed; PET-CT scan be done<br>Complete physical examination (including pelvic examination in women) of first-degree family members and other family members as indicated; abdominal and pelvic ultrasound as indicated |
| Established diagnosis: heterozygous pathogenic variant in *FH* + multiple cutaneous leiomyomas (at least 1 confirmed histologically) *-or-* single cutaneous leiomyoma + family history of syndrome *-or-* ≥1 tubulo-papillary, collecting-duct, or papillary type 2 renal tumor +/– family history | |

**See Llamas-Velasco M, Requena L, Kutzner H, et al. Fumarate hydratase immunohistochemical staining may help to identify patients with multiple cutaneous and uterine leiomyomatosis (MCUL) and hereditary leiomyomatosis and renal cell cancer (HLRCC) syndrome. J Cutan Pathol 2014;41:859–65.*

**eTable 95.1 Clinical features of hereditary leiomyomatosis and renal cell cancer (Reed syndrome).** PET, positron emission tomography.

# Mastocytosis 96

- Spectrum of disorders caused by proliferation and accumulation of mast cells in the skin and/or other tissues (Table 96.1).
- *Childhood-onset mastocytosis*, defined as presenting prior to puberty, develops before 6 months of age in ~70% of patients; it has a benign course and often remits spontaneously by adolescence (Fig. 96.1).
- *Adult-onset mastocytosis* most often develops in the third or fourth decade of life; it typically persists and may have systemic involvement (see Fig. 96.1).
- The majority of pediatric and adult mastocytosis patients have a *somatic* activating mutation (most frequently involving codon 816) in the gene encoding the KIT tyrosine kinase receptor expressed on mast cells; familial mastocytosis occasionally occurs.

## Clinical Features of Cutaneous Mastocytosis

- Patients frequently experience pruritus and may have episodic urtication (redness and swelling) of mastocytosis lesions.

| WHO CLASSIFICATION OF MASTOCYTOSIS |
|---|
| **Cutaneous mastocytosis (CM)** |
| Maculopapular CM/"urticaria pigmentosa" |
| Diffuse CM |
| Mastocytoma (≤3 lesions) |
| **Systemic mastocytosis (SM)** |
| Indolent SM* |
| Smoldering SM* |
| SM with associated hematologic neoplasm** |
| Aggressive SM |
| Mast cell leukemia |
| **Mast cell sarcoma (e.g. larynx, colon, brain)** |

**Forms of SM most likely to have cutaneous involvement.*
***The associated disorder may be myeloproliferative (including the form of hypereosinophilic syndrome characterized by FIP1L1/PDGFRA fusion gene; see Ch. 25), myelodysplastic, or lymphoproliferative.*

**Table 96.1 WHO classification of mastocytosis.**

- Lesions in infants and preschool-aged children can blister due to release of proteases from densely packed mast cells.
- Firmly rubbing or stroking cutaneous lesions of mastocytosis often causes urtication (Darier sign) (Fig. 96.2); this is generally more pronounced in children.
- In approximately half of patients, hiving develops after stroking clinically uninvolved skin (dermatographism).
- Several clinical patterns of cutaneous mastocytosis are recognized, but overlap between these groups can occur.

### Mastocytomas (≤3 Lesions)

- Typically present at birth or appear during infancy.
- One to several papules, nodules, or plaques with a yellow-tan to red-brown color and leathery (peau d'orange) texture (Fig. 96.3).
- Can occur anywhere on the skin surface, including acral sites.
- Smaller mastocytomas frequently go unrecognized and are likely underrepresented in series of pediatric mastocytosis patients.
- **DDx:** melanocytic nevus (e.g. congenital, Spitz), café-au-lait macule, juvenile xanthogranuloma, arthropod bite, pseudolymphoma, bullous impetigo.

### Maculopapular Cutaneous Mastocytosis, Including "Urticaria Pigmentosa"

- Multiple (often numerous) pink-tan to red-brown macules, papules, and/or plaques (Fig. 96.4).
- Two major variants:
  - *monomorphic small* lesions ("urticaria pigmentosa") that can occur in adults or children and tend to persist

Downloaded for Novin lib (novinlibrary@yahoo.com) at United Arab Emirates University from ClinicalKey.com by Elsevier on March 26, 2022. For personal use only. No other uses without permission. Copyright ©2022. Elsevier Inc. All rights reserved.

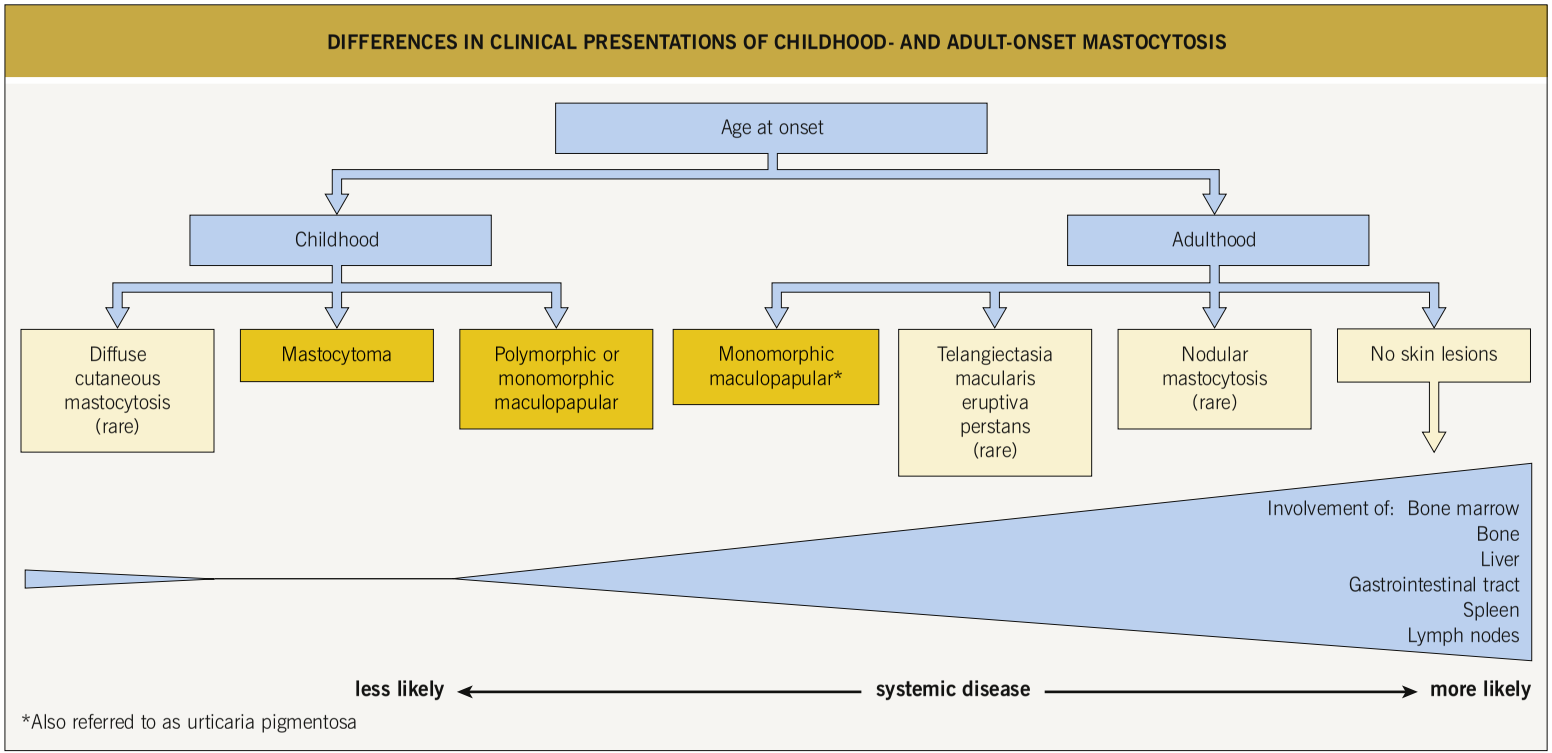


**Fig. 96.1 Differences in clinical presentations of childhood- and adult-onset mastocytosis.** The darker boxes represent the most common forms. *Courtesy, Michael Tharp, MD.*




**Fig. 96.2 Darier sign in mastocytosis.** An infant with extensive cutaneous involvement (**A**) and an adult with macular and papular lesions (**B**). *A, Courtesy, Julie V. Schaffer, MD; B, Courtesy, Thomas Horn, MD.*




**Fig. 96.3 Mastocytomas in infants. A** Tan plaque with a leathery surface. **B** Swelling and a subtle rim of erythema due to urtication of a yellowish nodule on the wrist. *A, Courtesy, Antonio Torrelo, MD; B, Courtesy, Julie V. Schaffer MD.*

  - *polymorphic larger* lesions (some >1 cm) that most often develop in infancy and typically resolve by adolescence

- Favors the trunk and proximal extremities, usually sparing the central face, palms, and soles.
- A subtle leathery texture is usually evident in larger lesions, and hyperpigmentation is less prominent in patients with lightly colored skin.
- Telangiectasias may be seen, especially in adults; ***t****elangiectasia* ***m****acularis* ***e****ruptiva* ***p****erstans* (TMEP) is a rare adult variant that presents with telangiectatic macules and patches without significant hyperpigmentation (Fig. 96.5), often with a minimal Darier sign.
- **DDx:** lentigines, melanocytic nevi; for TMEP, photodamage, poikiloderma, multiple spider telangiectasias, and other telangiectatic conditions (see Ch. 87).

## Diffuse Cutaneous Mastocytosis

- Occurs primarily in infants, with rare reports in adults.
- Generalized, doughy thickening of the skin with a leathery texture, sometimes with deep creases.
- Flushing, blistering, and erosions are common (Fig. 96.6), but spontaneous resolution usually occurs.
- **DDx:** epidermolysis bullosa, autoimmune bullous dermatoses.

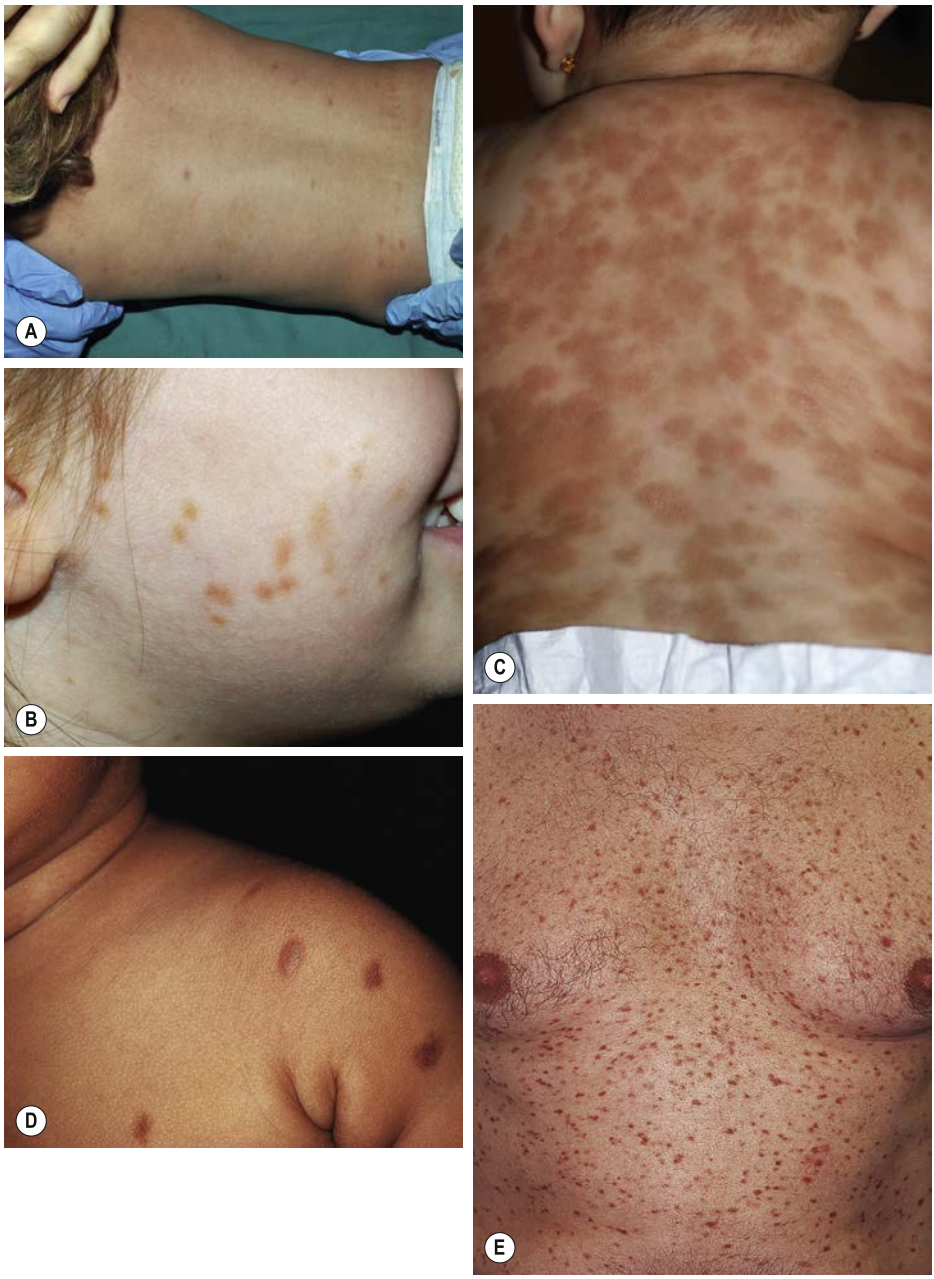


**Fig. 96.4 Maculopapular cutaneous mastocytosis ("urticaria pigmentosa").** Children present with variable numbers and sizes of papules, which may be scattered (**A**) or clustered (**B**), as well as polymorphic lesions including plaques (**C**) or papulonodules (**D**). The degree of associated hyperpigmentation also varies. **E** Adults typically present with small, red-brown macules and papules. *A, Courtesy, Antonio Torrelo, MD; B, C, Courtesy Julie V. Schaffer, MD; D, E, Courtesy, Michael Tharp, MD.*

## Systemic Manifestations of Mastocytosis

- In patients with a higher mast cell burden (e.g. extensive cutaneous disease, a large mastocytoma, extracutaneous involvement), release of mast cell mediators such as histamine can lead to systemic symptoms, which range from flushing to abdominal pain and diarrhea to lightheadedness and syncope (Fig. 96.7).



**Fig. 96.5 Telangiectasia macularis eruptiva perstans.** Multiple lesions composed of telangiectasias are present. *Courtesy, YDRSC.*



**Fig. 96.6 Diffuse cutaneous mastocytosis in an infant.** Diffusely infiltrated skin with multiple erosions and a leathery texture. *Courtesy, YDRSC.*

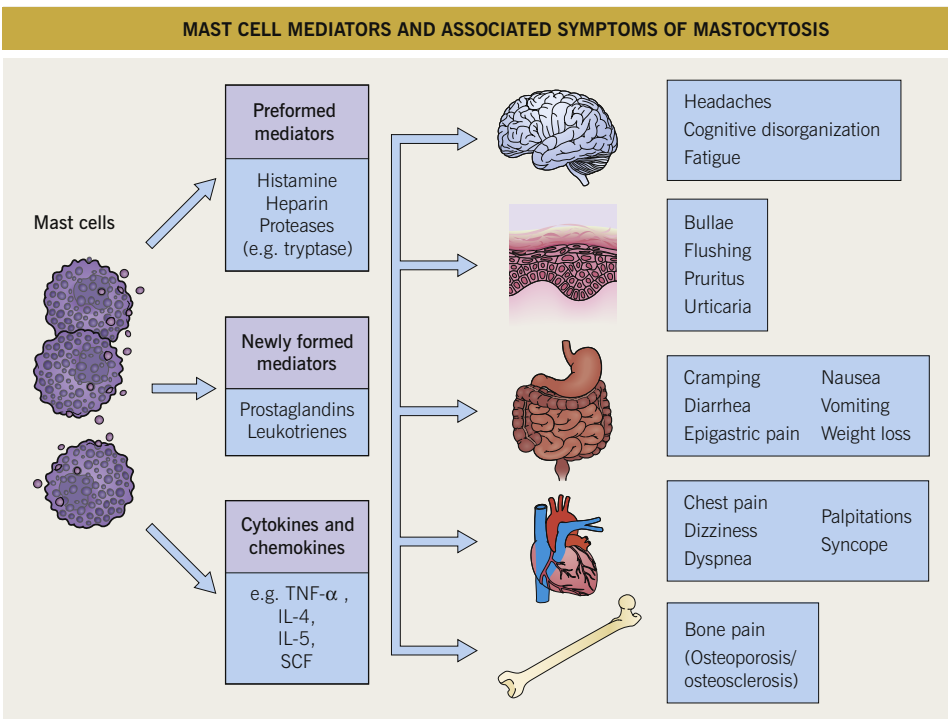


**Fig. 96.7 Mast cell mediators and associated symptoms of mastocytosis.** SCF, stem cell factor (binds to KIT receptor).

| WHO CRITERIA FOR THE DIAGNOSIS OF SYSTEMIC MASTOCYTOSIS |
|---|
| ***Requires either the major criterion plus one minor criterion or three minor criteria*** |
| **Major criterion** |
| • Multifocal dense infiltrates of mast cells (aggregates of ≥15 mast cells) in bone marrow or extracutaneous tissues |
| **Minor criteria** |
| • >25% of mast cells in bone marrow samples or extracutaneous tissues are spindle-shaped or otherwise atypical<br>• Extracutaneous mast cells (CD117+) express CD2, CD25, or both (often bone marrow; determined via flow cytometry)<br>• Presence of c-*KIT* codon 816 mutation in blood, bone marrow, or extracutaneous tissues<br>• Serum total tryptase level is persistently >20 ng/ml (unless there is an associated clonal myeloid disorder, in which case this parameter is not valid) |

**Table 96.2 WHO criteria for the diagnosis of systemic mastocytosis.**

- Systemic disease is extremely rare in childhood mastocytosis.
- Although the bone marrow is frequently involved in adult patients with cutaneous mastocytosis, hematologic sequelae are uncommon (see Table 96.1).
- Criteria for the diagnosis of systemic mastocytosis are presented in Table 96.2.
- Patients with systemic mastocytosis (primarily adults) occasionally develop osteoporosis, osteosclerosis, hepatosplenomegaly, lymphadenopathy, and infiltration of the GI tract.

## Evaluation and Treatment

- An approach to the evaluation of a patient with cutaneous mastocytosis is presented in Fig. 96.8.
- Treatment of cutaneous and indolent systemic mastocytosis is directed at alleviating symptoms, if present.
- Triggers of mast cell degranulation (Table 96.3) should be avoided when possible.
- **Rx:** low-sedating $H_1$ antihistamine(s), often in higher than standard doses (e.g. up to 40 mg daily of cetirizine in adults); addition of a sedating $H_1$ antihistamine at night, an $H_2$ antagonist (especially if upper GI symptoms), or cromolyn sodium (topical or oral) may be beneficial.
- An Epipen® or Epipen Jr® for emergency use can be given to patients with a high mast cell burden.
- Topical therapy with a potent CS or calcineurin inhibitor, narrowband UVB phototherapy, or omalizumab may be helpful in patients with refractory symptoms.
- Aggressive systemic disease can be treated with agents such as midostaurin (a multikinase/KIT inhibitor), imatinib (for some KIT mutations), or cladribine.

For further information see Ch. 118 from *Dermatology, Fourth Edition*.

**For additional online figures visit www.expertconsult.com**

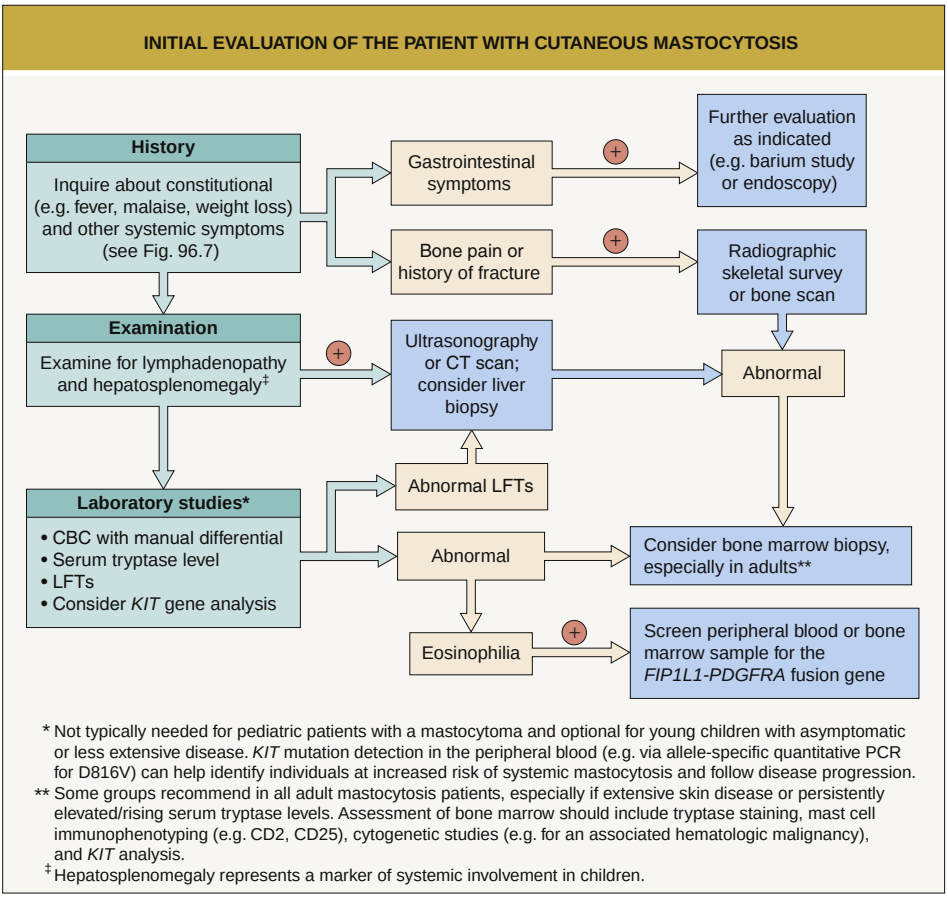


**Fig. 96.8 Initial evaluation of the patient with cutaneous mastocytosis.** A proposed scheme for the diagnosis of mastocytosis in the skin requires the major criterion of typical skin lesions associated with the Darier sign plus one minor criterion, either an increased number of mast cells histologically or an activating *KIT* mutation in lesional skin. Patients with systemic mastocytosis should be assessed for osteoporosis with a DEXA scan.

| POTENTIAL STIMULANTS OF MAST CELL DEGRANULATION |
|---|
| **Physical** |
| • Friction<br>• Exercise<br>• Heat (e.g. hot bath) or cold (e.g. swimming) |
| **Dietary** |
| • Hot beverages<br>• Spicy foods<br>• Alcohol |
| **Medications** |
| • Aspirin<br>• Nonsteroidal anti-inflammatory drugs<br>• Narcotics (e.g. morphine, codeine)<br>• Anticholinergics (e.g. scopolamine)<br>• Dextromethorphan (a cough suppressant)<br>• Polymyxin B sulfate<br>• Some systemic anesthetics (e.g. lidocaine*, etomidate, thiopental, isoflurane)<br>• Iodine-based radiographic dyes<br>• Dextran (in some IV solutions) |
| **Allergic** |
| • Allergens causing an immediate-type hypersensitivity reaction in that patient |
| **Local injections are safe.* |

**Table 96.3 Potential stimulants of mast cell degranulation.**

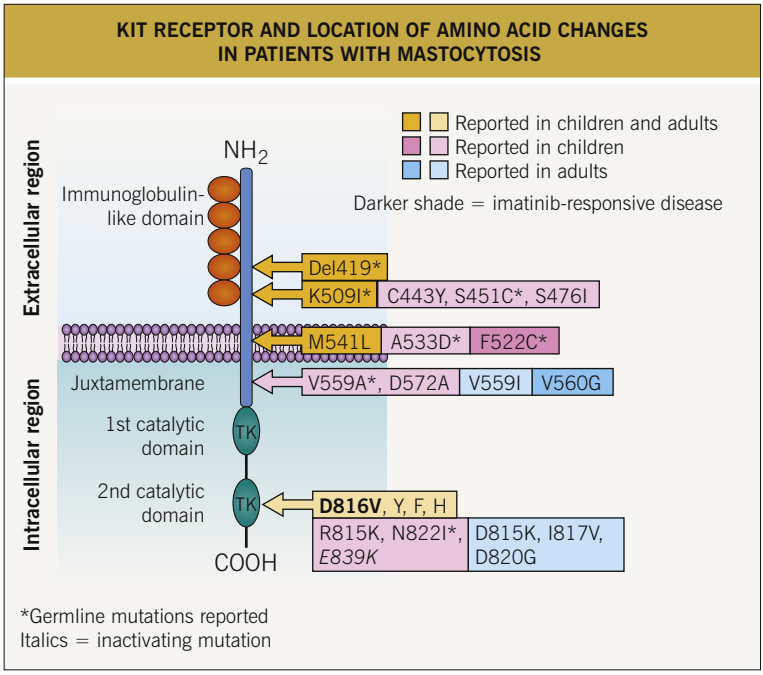


**eFig. 96.1 KIT receptor and location of amino acid changes (due to *KIT* mutations) in pediatric and adult patients with mastocytosis.** For example, D816V means that because of a mutation in codon 816, valine (V) has replaced aspartic acid (D). The plasma membrane-bound KIT receptor is composed of three distinct regions: (1) the extracellular region (five immunoglobulin-like repeats [orange]); (2) the transmembrane region; and (3) the intracellular region (two tyrosine kinase domains [green]). The most common site for activating mutations is exon 17, which contains codon 816. The result is constitutive ligand-independent activation of the receptor. In adults with advanced forms of systemic mastocytosis, somatic mutations have been identified in both *KIT* and other genes such as *TET2*, *ASXL1*, and *JAK2*. TK, tyrosine kinase domain (one binds ATP and the other has phosphotransferase activity).




**eFig. 96.2 Maculopapular cutaneous mastocytosis ("urticaria pigmentosa") in children.** **A–E** Variable numbers of tan to brown macules, papules, and plaques are evident. *A, Courtesy, Michael Tharp, MD; B, C, E, Courtesy, Antonio Torrelo, MD; D, Courtesy, Julie V. Schaffer, MD.*




**eFig. 96.3 Adult maculopapular cutaneous mastocytosis.** Multiple small (**A**) and (**B**) larger, confluent red-brown papules and plaques. *Courtesy, Michael Tharp, MD, and Bryan Sofen, MD.*

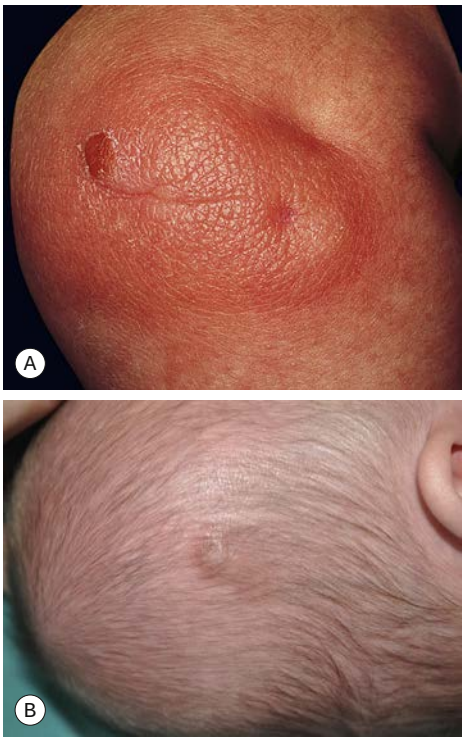


**eFig. 96.4 Mastocytomas in infants. A** Note the leathery appearance of the skin and erosions. **B** Subtle tan papule on the scalp. *A, Courtesy, Michael Tharp, MD, and Bryan Sofen, MD; B, Courtesy, Antonio Torrelo, MD*




**eFig. 96.5 Bullous mastocytosis.** **A** Tense bullae on the wrist and flaccid bullae on the dorsal hands as well as pink plaques on the trunk in a 1-month-old infant. **B** Large bulla overlying a mastocytoma on the lower back of a 4-month-old infant. **C** Blister superimposed on a plaque. *A, Courtesy, Deborah Goddard, MD, Amy Gilliam, MD, and Ilona Frieden, MD; B, Courtesy, Julie V. Schaffer, MD; C, Courtesy, YDRSC.*




**eFig. 96.6 Diffuse cutaneous mastocytosis with blistering and erosions.** The leathery skin texture may be subtle (**A**) or striking (**B**).
*A, Courtesy, Antonio Torrelo, MD; B, Courtesy, YDRSC.*

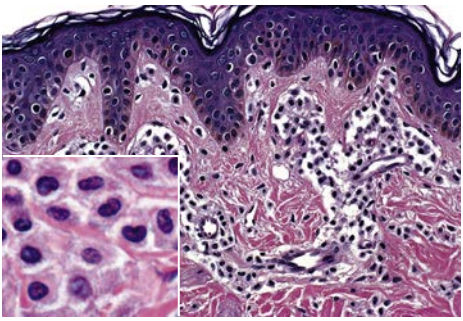

**eFig. 96.7 Cutaneous mastocytosis – histologic features.** Mast cells within the dermis have a rounded or cuboidal appearance. Granules are seen within the amphophilic cytoplasm (inset). *Courtesy, Lorenzo Cerroni, MD.*

# 97 B-Cell Lymphomas of the Skin

## General

- Cutaneous lymphomas can involve the skin as either the exclusive site of involvement (*primary cutaneous lymphoma*) or as the result of cutaneous involvement in association with a systemic (usually nodal) lymphoma (*secondary cutaneous lymphoma*).
- Primary cutaneous lymphomas are defined as lymphomas presenting in the skin with no evidence of extracutaneous disease at the time of diagnosis.
- Primary cutaneous lymphomas differ significantly from their nodal counterparts in terms of their natural history and thus require a specialized approach to their evaluation and treatment.
- Primary cutaneous lymphomas can originate from B cells (PCBCL), T cells (CTCL), or natural killer (NK) cells.
- Unlike most extranodal lymphomas, T-cell rather than B-cell lymphomas are more prevalent in the skin.

## PCBCL

- Primary cutaneous B-cell lymphomas are derived from B lymphocytes in different stages of differentiation.
- B-cell lineage is identified by the presence of CD20 and CD79a and the absence of CD3 markers.
- PCBCLs constitute approximately 20–25% of all primary cutaneous lymphomas, but there may be regional variation in incidence and specific types of CBCLs.
- Usually affects older adults of both sexes.
- Pathogenesis is unknown, but in certain areas of the world, *Borrelia* species are thought to play a role; marked immune suppression/dysregulation is also a risk factor.
- Precise classification can be achieved only after a complete synthesis of clinical, histopathologic, immunophenotypic, and molecular features.
- Once the diagnosis of a B-cell lymphoma in the skin has been made, complete staging (Table 97.1) is recommended to distinguish between primary and secondary cutaneous lymphoma.
- The World Health Organization–European Organization for Research and Treatment of Cancer (WHO–EORTC) classification provides the basis for a consistent classification of patients and divides PCBCL into three major types (Table 97.2).
- Primary cutaneous marginal zone B-cell lymphoma (PCMZL) and primary cutaneous follicle center lymphoma (PCFCL) are indolent lymphomas with 5-year survival rates of ≥95% (Table 97.3).
- Primary cutaneous diffuse large B-cell lymphoma, leg type (PCDLBCL, LT) has intermediate clinical behavior, worse 5-year survival estimates, and requires more aggressive treatment (see Table 97.3).
- An approach to the patient with a suspected diagnosis of cutaneous B-cell lymphoma is shown in Fig. 97.1.

## Plasma Cell Dyscrasias, Including Multiple Myeloma

- Plasma cell dyscrasias include monoclonal gammopathy of undetermined significance (MGUS), smoldering/asymptomatic myeloma and active/symptomatic myeloma, as well as light and heavy chain deposition diseases and primary systemic amyloidosis (AL).
- While proliferations of plasma cells in the skin are unusual, cutaneous disorders associated with or thought to be related to a monoclonal gammopathy are more common (Table 97.4).

| RECOMMENDED STAGING INVESTIGATIONS FOR PATIENTS WITH A CONFIRMED DIAGNOSIS OF B-CELL LYMPHOMA INVOLVING THE SKIN |
|---|
| **History and physical examination** |
| • Presence/absence of "B" symptoms, including fever, night sweats, weight loss, malaise<br>• Complete lymph node examination<br>• Palpation of abdomen for hepatosplenomegaly<br>• Examination of oral cavity<br>• History of organ transplantation and/or other immune suppression (e.g. HIV, iatrogenic, congenital) |
| **Laboratory studies** |
| • Complete blood count with differential and platelet count<br>• Comprehensive serum chemistries including LDH<br>• Flow cytometry of peripheral blood mononuclear cells* |
| **Imaging studies** |
| • Ultrasound of abdomen and superficial lymph nodes<br>• Whole-body PET/CT scan or whole-body CT scan* |
| **Additional studies as clinically indicated** |
| • Bone marrow biopsy**<br>• Excisional biopsy of enlarged lymph nodes or other suspicious lesions<br>• PCR analysis for *Borrelia* spp. DNA in patients from endemic areas (Europe) or travelers to endemic areas |
| **Not required in primary cutaneous marginal zone B-cell lymphoma.*<br>***While recommended for follicle center lymphoma and all types of large B-cell lymphoma, in the US bone marrow biopsy has been replaced by PET scan, as the latter is a more sensitive test.* |

**Table 97.1 Recommended staging investigations for patients with a confirmed diagnosis of B-cell lymphoma involving the skin.** PET, positron emission tomography.

| CLASSIFICATION OF B-CELL LYMPHOMAS WITH PRIMARY CUTANEOUS MANIFESTATIONS |
|---|
| • Primary cutaneous marginal zone B-cell lymphoma (PCMZL)*<br>• Primary cutaneous follicle center lymphoma (PCFCL)**<br>• Primary cutaneous diffuse large B-cell lymphoma, leg type (PCDLBCL, LT)**<br>• Intravascular large B-cell lymphoma |
| **Includes cases previously designated as primary cutaneous immunocytoma and primary cutaneous plasmacytoma.*<br>***In rare cases that cannot be classified as either PCDLBCL, LT or PCFCL, a diagnosis of primary cutaneous DLBCL-NOS (not otherwise specified) should be made.* |

**Table 97.2 WHO–EORTC 2018 classification of B-cell lymphomas with primary cutaneous manifestations.** In addition, there is one provisional diagnosis of EBV-positive mucocutaneous ulcer (EBVMCU).

For further information see Ch. 119 from *Dermatology, Fourth Edition*.

**For additional online figures visit www.expertconsult.com**

| THE PRIMARY CUTANEOUS B-CELL LYMPHOMAS (PCBCLs): CLINICAL AND DIAGNOSTIC FEATURES AND RECOMMENDED TREATMENT OPTIONS | | | | | | |
|---|---|---|---|---|---|---|
| **Primary cutaneous B-cell lymphoma subtype** | **Preferred location** | **Clinical features** | **Other distinguishing features** | **DDx** | **Rx** | **Outcome** |
| **Indolent behavior** | | | | | | |
| Primary cutaneous marginal zone B-cell lymphoma (PCMZL) | • Extremities: upper > lower<br>• Trunk<br>• Occasionally generalized | • Multifocal, pink-violet to red-brown, asymptomatic papules, plaques and nodules (Fig. 97.2)<br>• Rare ulceration; may resolve with anetoderma<br>• Can occur in areas of acrodermatitis chronica atrophicans (Fig. 97.2C) | • Bcl-2 (+), Bcl-6 (–), CD10 (–)<br>• Monoclonal rearrangement of *IGH* genes<br>• Intracytoplasmic monotypic expression of Ig light chains (Fig. 97.3)<br>• May be linked to infection with *Borrelia* species in endemic areas (e.g. Europe) | • Distinguish between the various PCBCLs<br>• Benign reactive processes (e.g. lymphocytic infiltrate of Jessner, cutaneous lymphoid hyperplasia)<br>• Leukemia cutis (e.g. cutaneous CLL)<br>• Secondary involvement from a systemic lymphoma<br>• Solid organ metastases | **Solitary or few lesions (trunk, occasionally more generalized)**<br>• Watchful waiting<br>• XRT<br>• Surgical excision<br>• Surgical excision plus postoperative XRT<br>• Intralesional rituximab<br>• Intralesional CS<br>**Multiple lesions at different body sites or diffuse PCFCL with disseminated lesions or if located on legs**<br>• Intralesional CS<br>• Intralesional rituximab<br>• Subcutaneous or intralesional interferon α-2a<br>• Systemic rituximab<br>• Systemic chemotherapy plus rituximab | • 5-year survival ≥95%<br>• Skin relapse common<br>• Occasionally spontaneous resolution<br>• Progression to systemic involvement is rare |
| Primary cutaneous follicle center lymphoma (PCFCL) | • Scalp, forehead, trunk (especially back), rarely legs (~5%) | • Solitary or grouped, asymptomatic, pink to plum-colored papules, plaques, or tumors (Fig. 97.4)<br>• May have peripheral patch of erythema (*Crosti lymphoma*)<br>• Ulceration uncommon<br>• Occasionally miliary, acneiform-like small papules | • Bcl-6 (+), MUM1 (–)<br>• Usually Bcl-2 (–), t(14;18) (–) ; if either (+) suspect systemic involvement<br>• (–) monoclonal Ig gene rearrangement<br>• (+) monotypic surface Ig expression | | | |

**Table 97.3 The primary cutaneous B-cell lymphomas (PCBCLs): clinical and diagnostic features and recommended treatment options.** *Continued*

| THE PRIMARY CUTANEOUS B-CELL LYMPHOMAS (PCBCLs): CLINICAL AND DIAGNOSTIC FEATURES AND RECOMMENDED TREATMENT OPTIONS | | | | | | |
|---|---|---|---|---|---|---|
| **Primary cutaneous B-cell lymphoma subtype** | **Preferred location** | **Clinical features** | **Other distinguishing features** | **DDx** | **Rx** | **Outcome** |
| **Intermediate to aggressive behavior** | | | | | | |
| Primary cutaneous diffuse large B-cell lymphoma, leg type (PCDLBCL, LT) | • Distal leg<br>• Unilateral > bilateral<br>• May occur elsewhere (10–15%) | • Solitary or clustered, red to red-brown nodules<br>• Often see small red papules adjacent to larger nodules (Fig. 97.5)<br>• Ulceration may occur | • Bcl-2 (+), MUM1 (+), MYC (+)<br>• Usually Bcl-6 (+)<br>• CD10 (–)<br>• ± monoclonal rearrangement of *IGH* genes<br>• (+) monotypic surface and/or intracytoplasmic Ig expression | • Secondary cutaneous involvement from systemic lymphoma<br>• Cutaneous infiltrates from AML<br>• Solid organ metastases | • Systemic rituximab<br>• Systemic chemotherapy plus rituximab<br>• Consider local XRT for small solitary lesions | • 5-year survival ~50%<br>• Extracutaneous involvement in ~50%<br>• Multiple lesions on leg = poor prognosis |
| **Other** | | | | | | |
| Intravascular large B-cell lymphoma | • Indurated, red to violaceous patches and plaques; favors trunk and thighs<br>• Neoplastic CD20(+) cells are located within the lumina of blood vessels that are CD31(+) and CD34(+)<br>• ~25% present with skin-limited disease at the time of diagnosis, predominantly in women; much better prognosis than in patients with systemic disease (e.g. CNS, lungs) | | | | | |
| **Provisional** | | | | | | |
| EBV-positive mucocutaneous ulcer (EBVMCU) | • Solitary, sharply demarcated ulcerating lesion involving the skin, oropharyngeal mucosa or GI tract in patients with age-related or iatrogenic immunosuppression<br>• Typically self-limited, indolent course; reduction or cessation of immunosuppressive therapy may result in complete remission | | | | | |

**Table 97.3** *Continued* **The primary cutaneous B-cell lymphomas (PCBCLs): clinical and diagnostic features and recommended treatment options.**
AML, acute myelogenous leukemia; CLL, chronic lymphocytic leukemia; Ig, immunoglobulin.

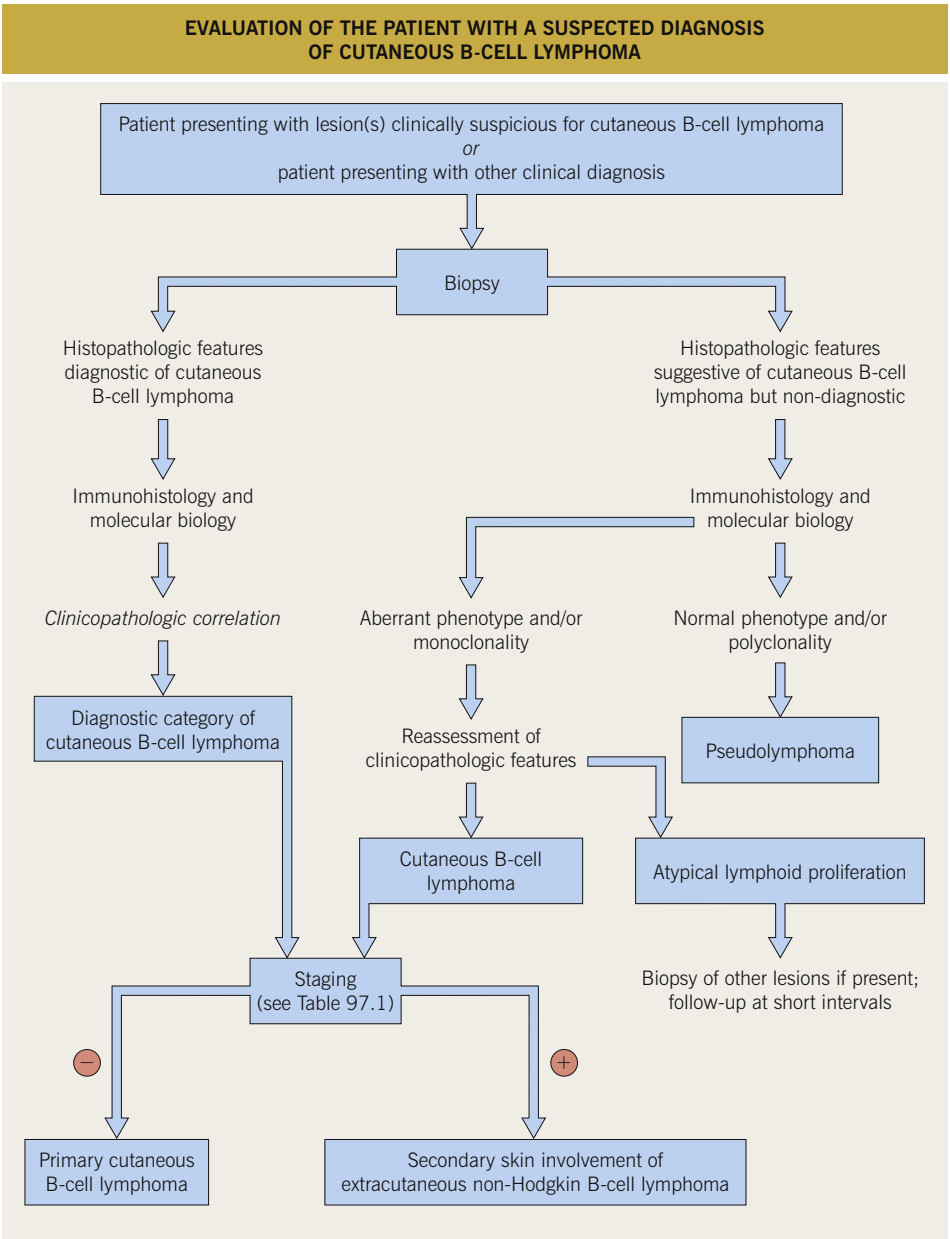


**Fig. 97.1 Evaluation of the patient with a suspected diagnosis of cutaneous B-cell lymphoma.** Algorithm outlining approach to the patient. *Courtesy, Lorenzo Cerroni, MD.*




**Fig. 97.2 Primary cutaneous marginal zone B-cell lymphoma.** **A** Two well-circumscribed, erythematous nodules on the shoulder. **B** Two thick, pink-violet plaques on the foot, one of which has a flat surface. Molecular analysis revealed *Borrelia* DNA within the infiltrate. **C** Dome-shaped erythematous nodule with smooth surface. The surrounding area shows features of acrodermatitis chronica atrophicans. In the past, the tumors pictured in **B** and **C**, which demonstrated prominent lymphoplasmacytic differentiation histopathologically, were classified as cutaneous immunocytomas. *Courtesy, Lorenzo Cerroni, MD.*

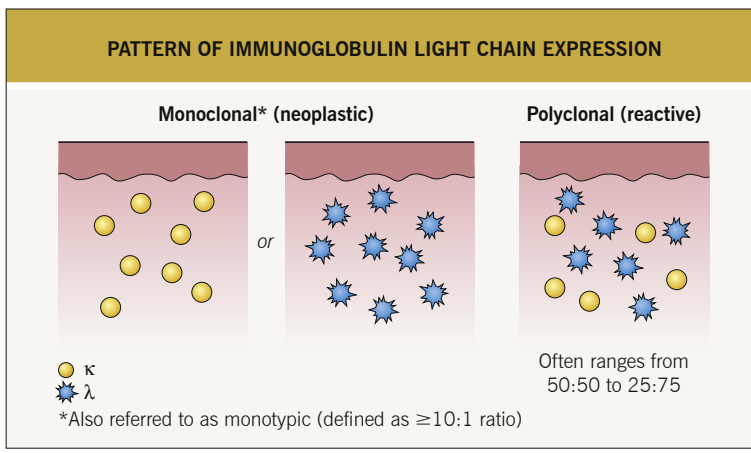


**Fig. 97.3 Pattern of immunoglobulin light chain expression.** Detection of monoclonal expression of immunoglobulin light chains (κ or λ) is a key diagnostic feature for primary cutaneous marginal zone B-cell lymphoma. Monoclonality is defined as a ≥10:1 ratio.




**Fig. 97.4 Primary cutaneous follicle center lymphoma. A** Prominent pink-violet nodule on the lateral forehead with a few telangiectasias. The nodule is surrounded by papules and large infiltrated plaques. **B** Large nodule on the upper back. Note the surrounding erythematous papules, patches, and plaques (Crosti lymphoma). *Courtesy, Lorenzo Cerroni, MD.*




**Fig. 97.5 Primary cutaneous diffuse large B-cell lymphoma, leg type. A** Multiple coalescing red-brown papulonodules and plaques on the lower leg. **B** Multiple red-brown papulonodules and tumors on the lower leg. *Courtesy, Lorenzo Cerroni, MD.*

| CUTANEOUS CONDITIONS ASSOCIATED WITH MONOCONAL GAMMOPATHY |
|---|
| **Proliferation of lymphoplasmacytic cells in the skin** |
| • Extramedullary cutaneous plasmacytoma* |
| • Cutaneous Waldenström macroglobulinemia** |
| **Deposition of the monoclonal protein in the skin, by definition** |
| • Primary systemic amyloidosis (light chains) |
| • Cryoglobulinemic occlusive vasculopathy (type I cryoglobulins†) |
| • Hyperkeratotic spicules (follicular > nonfollicular) |
| • Crystal-storing histiocytosis |
| • Crystalglobulinemia |
| • IgM storage papules (cutaneous macroglobulinosis)** |
| • Subepidermal bullous dermatosis associated with IgM gammopathy** |
| **Deposition of the monoclonal protein in the skin frequently observed** |
| • Plasma cell dyscrasia-associated acquired cutis laxa, acral or generalized (amyloid and/or IgG) |
| • Plasma cell dyscrasia-associated reactive angioendotheliomatosis (type I cryoglobulins or amyloid) |
| **Almost always associated with monoclonal gammopathy** |
| • Scleromyxedema |
| • POEMS syndrome‡ |
| • AESOP syndrome – *a*denopathy and *e*xtensive *s*kin patch *o*verlying a *p*lasmacytoma; may coexist with POEMS syndrome‡ |
| • Schnitzler syndrome** |
| • Necrobiotic xanthogranuloma |
| **Frequently associated with monoclonal gammopathy** |
| • Normolipemic plane xanthoma |
| • Scleredema (type 2) |
| • Angioedema secondary to acquired C1 esterase inhibitor deficiency |
| • Clarkson syndrome (idiopathic systemic capillary leak syndrome) |
| **Significant association with monoclonal gammopathy (at least 15% of cases)** |
| • Erythema elevatum diutinum |
| • Subcorneal pustular dermatosis (SPD) and SPD-type IgA pemphigus |
| • Pyoderma gangrenosum |
| **Occasionally associated with monoclonal gammopathy** |
| • Sweet syndrome |
| • Cutaneous small vessel vasculitis†, including adult IgA vasculitis with monoclonal IgA gammopathy |
| • Xanthoma disseminatum |
| • Epidermolysis bullosa acquisita |
| • Paraneoplastic pemphigus |
| **In the current WHO–EORTC classification (see Table 97.2), primary cutaneous plasmacytoma is classified as primary cutaneous marginal zone B-cell lymphoma.* |
| ***IgM monoclonal gammopathy is present by definition; in Schnitzler syndrome, IgG gammopathy has occasionally been observed; Waldenström macroglobulinemia is due to a lymphoplasmacytic lymphoma.* |
| *†Cryoglobulinemic vasculitis can occur secondary to type II cryoglobulins.* |
| *‡Polyneuropathy (P), organomegaly (O), endocrinopathy (E), M-protein (M), skin changes (S) (see Ch. 45); diagnosis requires monoclonal plasmaproliferative disorder & neuropathy + one other major criterion (sclerotic bone lesions, Castleman disease, increased serum VEGF levels) and one minor criterion (extravascular volume overload, papilledema, O, E, S, thrombocytosis/polycythemia).* |

**Table 97.4 Cutaneous conditions associated with a monoclonal gammopathy.**




**eFig. 97.1 Primary cutaneous follicle center lymphoma. A** Large ulcerated tumors on the scalp surrounded by infiltrated erythematous nodules and plaques. **B** Large ulcerated tumor on the back. Note surrounding erythematous papules, patches, and plaques (Crosti lymphoma). *A, B, Courtesy, Lorenzo Cerroni, MD.*



**eFig. 97.2 Primary cutaneous diffuse large B-cell lymphoma, leg type.** Multiple red-brown papulonodules and tumors on the lower leg. *Courtesy, Lorenzo Cerroni, MD.*

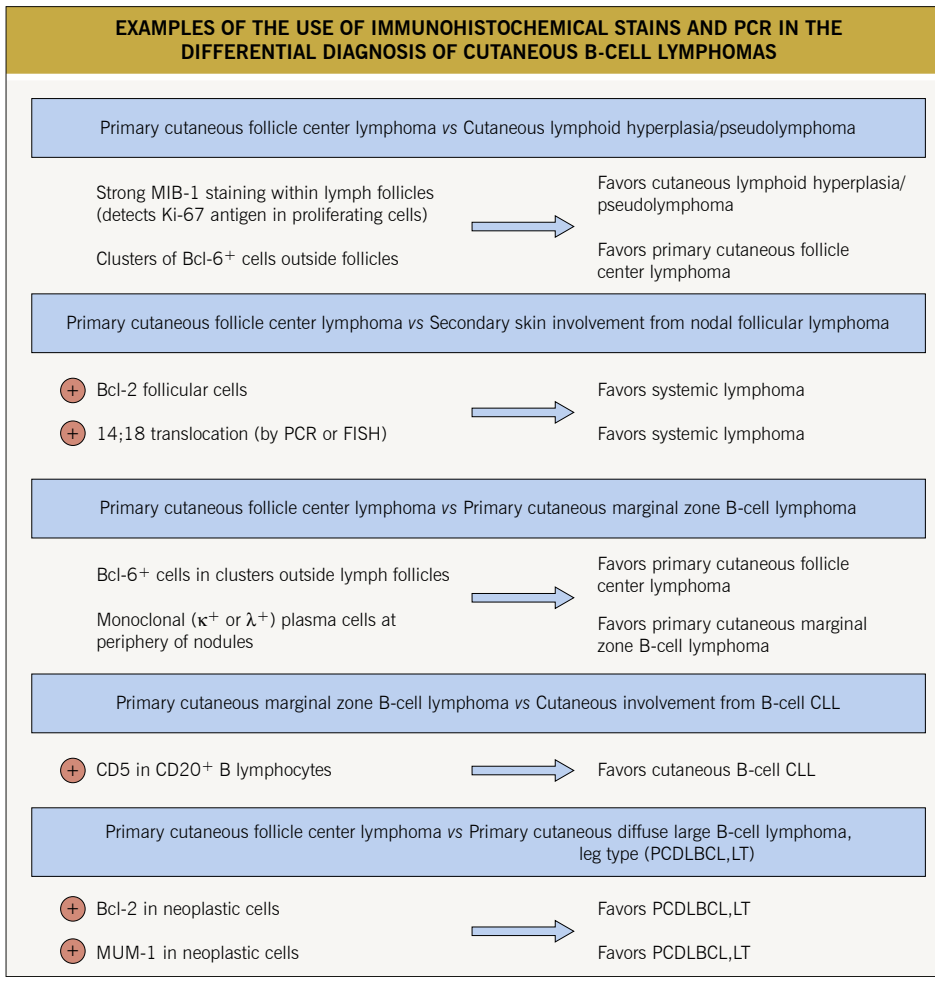


**eFig. 97.3 Examples of the use of immunohistochemical stains and PCR in the differential diagnosis of cutaneous B-cell lymphomas.** This represents a simplification and is intended to assist dermatologists in their interpretation of pathology reports. $CD20^+/CD5^+$ infiltrates are also seen in secondary skin involvement from mantle cell lymphoma, but in contrast to CLL, mantle cell lymphoma is also positive for cyclin D1 and negative for CD23. CLL, chronic lymphocytic leukemia; FISH, fluorescent *in situ* hybridization.

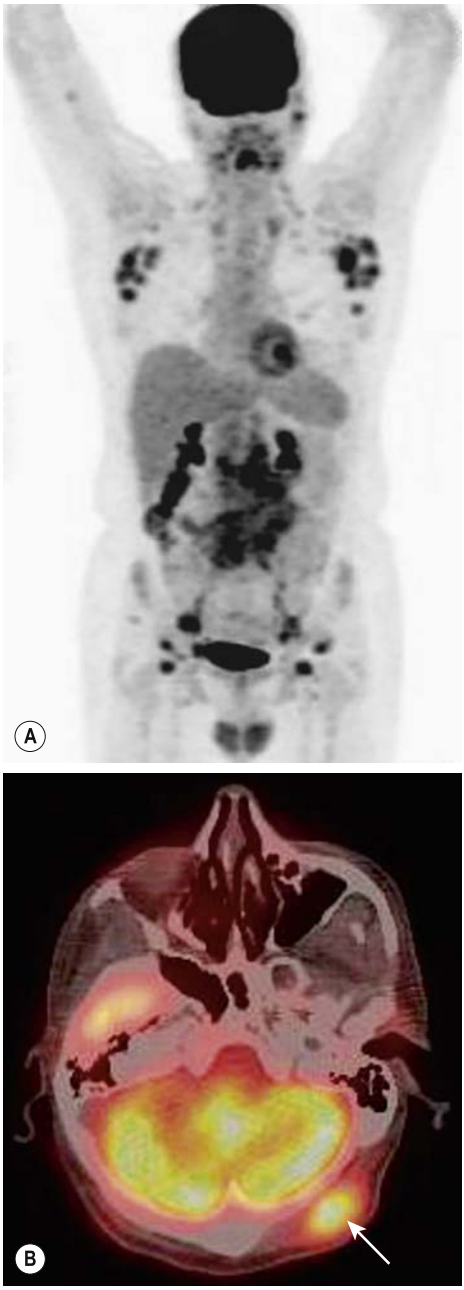


**eFig. 97.4 Evaluation of the patient with a suspected diagnosis of cutaneous B-cell lymphoma. A, B** Positron emission tomography (PET) scans in a 66-year-old patient with stage IV non-Hodgkin B-cell lymphoma. He had a 1-year history of a cutaneous nodule of the scalp that was originally diagnosed as an epidermoid inclusion cyst. Biopsy of the nodule showed a diffuse large B-cell lymphoma ($CD10^+$, $CD20^+$, variably $Bcl\text{-}2^+$, $MUM\text{-}1^-$) and a PET-CT scan was performed for staging. There is evidence of widespread disease involving multiple lymph node basins in the dedicated (MIP) image (**A**) as well as a scalp lesion in a PET-CT fusion image (**B**; arrow). *Courtesy, Dennis Cooper, MD.*

# Cutaneous T-Cell Lymphoma

98

- *Primary* cutaneous lymphomas present in the skin without evidence of extracutaneous disease at the time of diagnosis.
- *Secondary* cutaneous lymphomas are skin manifestations of systemic (nodal) lymphomas and will not be discussed (see oncology texts).
- Primary **c**utaneous **l**ymphomas may be of **T-c**ell origin (75–80%) or **B-c**ell origin (20–25%) and are termed **CTCL** and **CBCL**, respectively.
- The term CTCL will be used herein to describe the heterogeneous group of primary cutaneous lymphomas composed of neoplastic T cells or natural killer (NK) cells (Tables 98.1–98.3).
- As different types of CTCLs, CBCLs, and even secondary cutaneous lymphomas may present with similar clinical and histopathological features, it is imperative to combine clinical and staging data with histopathologic, immunophenotypic, and genetic data before making a definitive diagnosis (classification).
- Immunophenotyping, as determined from immunohistochemical studies done on skin biopsy specimens, can help distinguish between a T-cell vs an NK-cell vs a B-cell lymphoma and can aid in subtyping.
- T-cell receptor (TCR) gene rearrangement analysis is useful in detecting the presence or absence of a clonal T-cell population in skin biopsy specimens.
- The presence of a clonal T-cell population cannot be used as an absolute criterion of malignancy, as several benign conditions may also demonstrate clonality (e.g. pityriasis lichenoides et varioliformis acuta, lichen planus, pigmented purpuric dermatosis, lichen sclerosus, and some pseudolymphomas).
- An approach to the evaluation of a patient with suspected CTCL is presented in Fig. 98.1.
- Once a diagnosis of CTCL has been made, the type of CTCL should then be determined.
- Of the various CTCLs (see Tables 98.1–98.3), approximately 65% are mycosis fungoides (MF), MF variants, or Sézary syndrome (SS); 25% are within the spectrum of $CD30^+$ lymphoproliferative disorders (Fig. 98.2); and the remainder (10%) are composed of other rare entities.
- In general, the aggressive-behaving CTCLs (see Tables 98.1 and 98.3) require more extensive staging (Table 98.4), referral to a hematologist–oncologist, and systemic chemotherapy or targeted immunotherapy (e.g. rituximab, brentuximab).

## Mycosis Fungoides (MF)

- The most common subtype of CTCL, representing about 50% of all *primary* cutaneous lymphomas.
- The term MF should be restricted to the classic "Alibert–Bazin" type, characterized by the typical evolution of patches, plaques, and tumors (Fig. 98.3).
- Other clinical variants with similar behavior include hypo- and hyperpigmented MF (Fig. 98.3C) and bullous MF.
- Three rare clinical variants of MF with distinctive clinicopathologic features are considered separately, namely folliculotropic MF (Fig. 98.4), pagetoid reticulosis (Fig. 98.5), and granulomatous slack skin (Fig. 98.6).
- Classic MF is an uncommon disease; more prevalent in males (> females), older adults, and African-Americans; pathogenesis is unknown.
- Clinical presentation depends on stage at diagnosis (Tables 98.5 and 98.6), but classically patients progress from persistent patch/plaque stage to tumor stage over years to decades (see Fig. 98.3).

| 2018 WHO–EORTC CLASSIFICATION FOR CUTANEOUS T-CELL LYMPHOMAS | | |
|---|---|---|
| **2018 WHO–EORTC classification** | **Frequency (%)*** | **5-year DSS (%)*** |
| **Indolent clinical behavior** | | |
| Mycosis fungoides (MF) | 39 | 88 |
| Mycosis fungoides variants | | |
| • Folliculotropic MF | 5 | 75 |
| • Pagetoid reticulosis | <1 | 100 |
| • Granulomatous slack skin | <1w | 100 |
| Primary cutaneous CD30-positive lymphoproliferative disorders | | |
| • Lymphomatoid papulosis (LyP) | 12 | 99 |
| • Primary cutaneous anaplastic large cell lymphoma (C-ALCL) | 8 | 95 |
| Subcutaneous panniculitis-like T-cell lymphoma (SPTCL) | 1 | 87 |
| Primary cutaneous CD4-positive small/medium T-cell lymphoproliferative disorder (provisional) | 6 | 100 |
| Primary cutaneous acral CD8-positive T-cell lymphoma (provisional) | <1 | 100 |
| **Aggressive clinical behavior** | | |
| Sézary syndrome (SS) | 2 | 36 |
| Adult T-cell leukemia/ lymphoma (ATLL) | <1 | NDA |
| Extranodal NK/T-cell lymphoma, nasal type | <1 | 16 |
| Primary cutaneous aggressive epidermotropic CD8-positive T-cell lymphoma (provisional) | <1 | 31 |
| Primary cutaneous gamma/delta T-cell lymphoma (PCGD-TCL) | <1 | 11 |
| Chronic active EBV infection | <1 | NDA |
| Primary cutaneous peripheral T-cell lymphoma (PTCL), NOS | 2 | 15 |

**Based on data included in Dutch and Austrian cutaneous lymphoma registries between 2002 and 2017.*

**Table 98.1 2018 WHO–EORTC classification for cutaneous T-cell lymphomas.** DSS, disease specific survival; NDA, no data available; NOS, not otherwise specified. *From Willemze R, Cerroni L, Berti E, et al. The 2018 update of the WHO-EORTC classification for primary cutaneous lymphomas. Blood. April 2019; 133(16):1703–14.*

- Most patients have years of nonspecific eczematous or psoriasiform skin lesions and nondiagnostic biopsies before a definitive diagnosis of MF is made.
- There can be gradual progression or relapse at a similar stage of disease; advancement to a higher stage usually transpires after years and multiple treatment failures.
- Extracutaneous disease is extremely rare in patch/plaque stage, uncommon with generalized plaques, and most likely with extensive tumors or erythroderma.
- Extracutaneous involvement almost always initially involves regional lymph nodes draining the areas of greatest skin involvement; visceral involvement can develop subsequently; bone marrow involvement is rare.
- Histopathologic examination of persistently enlarged lymph nodes can help distinguish between dermatopathic (reactive) lymphadenopathy and involvement with MF.
- Treatment is dependent on the stage at diagnosis, the host's immune status, and the general condition of the patient (Table 98.7).

| CUTANEOUS T-CELL LYMPHOMAS WITH INDOLENT CLINICAL BEHAVIOR | | |
|---|---|---|
| **Clinical & diagnostic features** | **DDx** | **Treatment recommendations** |
| **Mycosis fungoides** | | |
| • Variable progression from patch to plaque to tumor stage over years–decades (see Fig. 98.3)<br>• **Patch stage:** variably sized red, finely scaling lesions with atrophy and poikiloderma; predilection for sun-protected sites<br>• **Plaque stage:** infiltrated red-brown scaling plaques; often annular, polycyclic or horseshoe-shaped<br>• **Tumor stage:** often have combination of patches, plaques, and tumors; many with ulceration<br>• $CD3^+$, $CD4^+$, $CD45RO^+$, $CD8^-$<br>• Occasionally $CD4^-$, $CD8^+$; rarely $CD4^-$, $CD8^-$ | • **Benign dermatoses:**<br>– Eczema<br>– Psoriasis<br>– Superficial fungal infections<br>– Drug reactions<br>• **Benign conditions with histopathologic features suggestive of MF:**<br>– Lymphomatoid contact dermatitis<br>– Lymphomatoid drug reactions<br>– Actinic reticuloid<br>• **Other types of epidermotropic CTCL** | • See Table 98.7 |
| **Mycosis fungoides variants** | | |
| *Folliculotropic MF* | | |
| • Grouped follicular papules, acneiform lesions, indurated plaques (see Fig. 98.4)<br>• Favors head and neck<br>• Pruritus, alopecia, mucinorrhea<br>• Pruritus often severe<br>• $CD3^+$, $CD4^+$, $CD8^-$; occasionally $CD30^+$ | • Acne vulgaris<br>• Chloracne<br>• Alopecia mucinosa<br>• Seborrheic dermatitis<br>• Atopic dermatitis | • Two subgroups:<br>1. Indolent clinical behavior treated similarly to early-stage MF (see Table 98.7)<br>2. More aggressive form requiring combination therapy (see Table 98.7) |
| *Pagetoid reticulosis* | | |
| • Slowly progressive, solitary or localized psoriasiform or hyperkeratotic patch or plaque<br>• Favors extremities (see Fig. 98.5)<br>• Histologically purely intraepidermal proliferation<br>• $CD3^+$, $CD4^+$, $CD8^-$ *-OR-* $CD3^+$, $CD4^-$, $CD8^+$; $CD30^+$ in many cases | • Isolated patch of psoriasis or eczema<br>• Other types of CTCL | • XRT or surgical excision |

**Table 98.2 Cutaneous T-cell lymphomas (CTCL) with *indolent* clinical behavior: clinical and diagnostic features as well as treatment recommendations.**
*Continued*

| CUTANEOUS T-CELL LYMPHOMAS WITH INDOLENT CLINICAL BEHAVIOR | | |
|---|---|---|
| ***Granulomatous slack skin*** | | |
| • Circumscribed areas of pendulous, atrophic, lax skin (see Fig. 98.6)<br>• Favors axillae and groin<br>• $CD3^+$, $CD4^+$, $CD8^-$ | • Acquired generalized cutis laxa<br>• Pseudoxanthoma elasticum | • XRT is an option |
| **Primary cutaneous $CD30^+$ lymphoproliferative disorders** | | |
| ***Lymphomatoid papulosis (LyP)*** | | |
| • Red-brown papules and nodules that can develop central hemorrhage, necrosis, and crusting (Fig. 98.8)<br>• Spontaneously disappear over 3–8 weeks<br>• Different stages of evolution coexist<br>• May last months to >40 years<br>• ~20% preceded by/followed by/associated with another cutaneous lymphoma (e.g. MF, C-ALCL, Hodgkin lymphoma)<br>• Type B may be $CD30^-$ | • Pityriasis lichenoides et varioliformis acuta (PLEVA)<br>• Pityriasis lichenoides chronica (PLC)<br>• Folliculitis<br>• If clustered, Majocchi granuloma<br>• Arthropod bites | • Low-dose oral methotrexate (e.g. 5–20 mg/week) is the most effective treatment<br>• Long-term follow-up, given risk of systemic lymphoma |
| ***Primary cutaneous anaplastic large cell lymphoma (C-ALCL)*** | | |
| • Solitary or localized nodules or tumors, often with ulceration (Fig. 98.9)<br>• Occasionally will spontaneously regress<br>• $CD30^+$, $CD4^+$ >> $CD8^+$, $ALK^-$, $EMA^-$, $CD15^-$, TIA-$1^+$ | • $CD30^+$ large cell lymphoma secondary to MF transformation<br>• HIV-associated or post-transplant lymphoma<br>• Skin manifestations of systemic ALCL | • Solitary lesions may resolve spontaneously<br>• XRT or surgical excision if limited number of lesions<br>• Brentuximab vedotin, low-dose methotrexate, retinoids, IFN-alpha; systemic chemotherapy when extensive |
| **Subcutaneous panniculitis-like T-cell lymphoma (SPTCL)** | | |
| • Subcutaneous nodules and plaques<br>• Extremities > trunk (Fig. 98.10)<br>• ± Fever, fatigue, weight loss<br>• $CD3^+$, $CD4^-$, $CD8^+$, $CD56^-$, $\beta F1^+$ (TCR $\alpha/\beta^+$) | • Other types of panniculitis (see Ch. 83) | • XRT for solitary lesions<br>• More conservative immunosuppressive regimens (e.g. prednisone, cyclosporine) as well as combination chemotherapy |

**Table 98.2** *Continued* **Cutaneous T-cell lymphomas (CTCL) with *indolent* clinical behavior: clinical and diagnostic features as well as treatment recommendations.** *Continued*

| CUTANEOUS T-CELL LYMPHOMAS WITH INDOLENT CLINICAL BEHAVIOR | | |
|---|---|---|
| **Primary cutaneous CD4⁺ small/medium T-cell lymphoproliferative disorder (provisional)** | | |
| • Most often a solitary plaque or tumor on face, neck, upper trunk<br>• CD3⁺, CD4⁺, CD8⁻, βF1⁺ (TCR α/β⁺), CD30⁻, CD56⁻; CD279/PD-1⁺, BCL66⁺, CXCL13⁺ | • Other types of CTCL | • If lesions do not resolve spontaneously after biopsy, then treat with intralesional CS, surgical excision, or rarely XRT |
| **Primary cutaneous acral CD8⁺ T-cell lymphoma (provisional)** | | |
| • Solitary, slowly progressive papule or nodule, typically located on the ear or less commonly other acral sites (e.g. nose, foot)<br>• CD3⁺, CD4⁻, CD8⁺, CD30⁻,TIA-1⁺ | • Other types of CTCL | • Surgical excision or XRT |

**Table 98.2** *Continued* **Cutaneous T-cell lymphomas (CTCL) with *indolent* clinical behavior: clinical and diagnostic features as well as treatment recommendations.** HTLV-1, human T-lymphotrophic virus 1; IFN, interferon; NDA, no data available; TCR, T-cell receptor; TSEB, total skin electron beam irradiation.

| CUTANEOUS T-CELL LYMPHOMAS WITH AGGRESSIVE CLINICAL BEHAVIOR | | |
|---|---|---|
| **Clinical and diagnostic features** | **DDx** | **Treatment recommendations** |
| **Sézary syndrome** | | |
| • Exfoliative erythroderma (see Fig. 98.7), lymphadenopathy, and circulating clonal malignant T cells<br>• Intense pruritus with lichenification<br>• Alopecia, palmoplantar keratoderma<br>• $CD3^+$, $CD4^+$, $CD8^-$, $CD7^-$, $CD26^-$ | • Other erythrodermic syndromes (see Ch. 8)<br>• Actinic reticuloid | • See Table 98.7 |
| **Adult T-cell leukemia/lymphoma (ATLL)** | | |
| • Associated with HTLV-1 infection<br>• More common in SW Japan, Caribbean islands<br>• **Smoldering variant**: resembles MF<br>• **Acute presentation**: leukemia, lymphadenopathy, hypercalcemia, skin lesions<br>• $CD3^+$, $CD4^+$, $CD8^-$, $CD25^+$ | **Smoldering variant**<br>• MF<br>**Acute variant**<br>• Other lymphomas, leukemias | **Smoldering variant**<br>• Skin-directed therapies as in MF (see Table 98.7)<br>**Acute variant**<br>• Systemic chemotherapy; occasionally zidovudine + IFN-alpha |
| **Extranodal NK/T-cell lymphoma, nasal type** | | |
| • Almost always associated with EBV<br>• **Nasal type**: mid-facial destructive tumor (Fig. 98.11)<br>• **Skin only**: ulcerated plaques or tumors on trunk/extremities<br>• $CD2^+$, CD3 epsilon$^+$, TIA-$1^+$, EBER-$1^+$, $CD56^+$, $CD4^-$, $CD8^{-/+}$ | **Nasal type**<br>• Mucormycosis<br>• Leishmaniasis<br>**Skin only**<br>• Other cutaneous lymphomas | • XRT for localized disease<br>• More advanced disease often resistant to chemotherapy |
| **Primary cutaneous aggressive epidermotropic $CD8^+$ T-cell lymphoma (provisional)** | | |
| • Eruptive papulonodules with ulceration (Fig. 98.12) *-OR-*<br>• Keratotic patches and plaques<br>• $CD3^+$, $CD4^-$, $CD8^+$, TIA-$1^+$, $AF1^+$ (TCR $\alpha/\beta^+$) | • Other $CD8^+$ CTCLs (e.g. pagetoid reticulosis, MF, LyP, C-ALCL) | • Systemic chemotherapy |
| **Primary cutaneous gamma/delta T-cell lymphoma (PCGD-TCL)** | | |
| • Disseminated plaques and/or ulceronecrotic nodules or tumors<br>• Hemophagocytic syndrome common<br>• $CD4^-$, $CD8^-$, TCR $\gamma/\delta^+$, $TF1^-$ (TCR $\alpha/\beta^-$), TIA-$1^+$, $CD56^+$, $CD3^+$ | • Other panniculitides (see Ch. 83) | • Aggressive, often rapidly fatal disease that is resistant to multi-agent chemotherapy |

**Table 98.3 Cutaneous T-cell lymphomas (CTCL) with *aggressive* clinical behavior: clinical and diagnostic features as well as treatment recommendations.**
*Continued*

| CUTANEOUS T-CELL LYMPHOMAS WITH AGGRESSIVE CLINICAL BEHAVIOR | | |
|---|---|---|
| **Chronic active EBV infection** | | |
| • Two entities with a risk of progression to systemic EBV (+) T-cell or NK-cell lymphoma; favors Asian and native Latin American children:<br>1. **Hydroa vacciniforme-like lymphoproliferative disorders (HV-like LPD)**<br>– Similar presentation to HV (see Ch. 73; Fig. 73.9) but may have more extensive involvement, e.g. facial swelling and ulcerated nodules<br>2. **Hypersensitivity reactions to mosquito bites (HMB)**<br>– Ulceronecrotic lesions at sites of bites<br>• Both may have systemic symptoms such as fever, lymphadenopathy, hepatosplenomegaly | • Other photosensitizing disorders (e.g. hydroa vacciniforme (see Fig. 73.8), porphyrias, cutaneous lupus)<br>• Other lymphomas | • Treatment of cutaneous disease similar to HV (see Ch. 73)<br>• Referral to hematology is recommended |
| **Primary cutaneous peripheral T-cell lymphoma (PTCL), NOS** | | |
| • Diagnosis of exclusion; refers to CTCLs that do not fit into any of the other subtypes<br>• Generalized > solitary or localized nodules and tumors (Fig. 98.13)<br>• $CD4^+$, $CD30^-$, $CD56^-$ | • Other cutaneous lymphomas | • Systemic chemotherapy, but prognosis is poor |

**Table 98.3** *Continued* **Cutaneous T-cell lymphomas (CTCL) with *aggressive* clinical behavior: clinical and diagnostic features as well as treatment recommendations.** IFN, interferon; NOS, not otherwise specified.

## AN APPROACH TO THE PATIENT WITH A SUSPECTED CUTANEOUS T-CELL LYMPHOMA (CTCL)

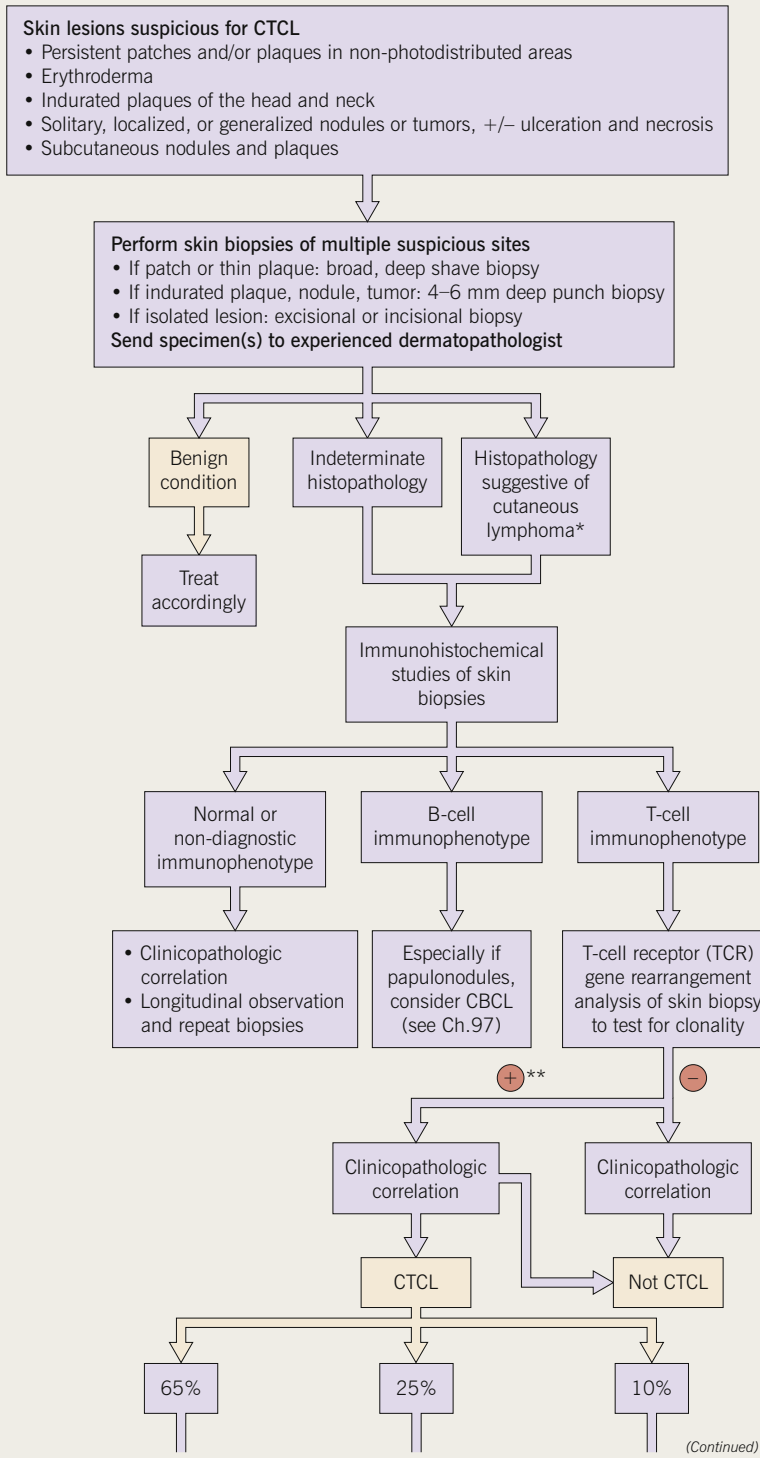


**Fig. 98.1 An approach to the patient with a suspected cutaneous T-cell lymphoma (CTCL).** *Continued*

**AN APPROACH TO THE PATIENT WITH A SUSPECTED CUTANEOUS T-CELL LYMPHOMA (CTCL)**

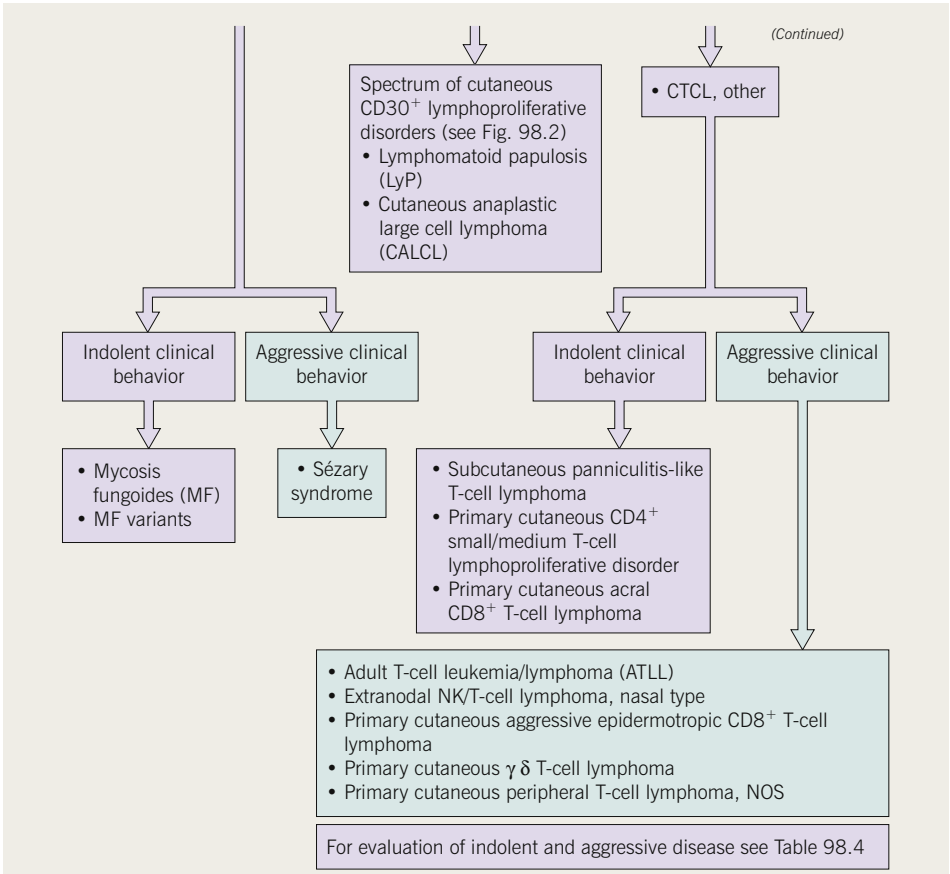


*If classic clinical and histopathological findings for MF, immunohistochemical and TCR/clonality studies may not be necessary
**The presence of a clonal T-cell population cannot be used as an absolute criterion of malignancy, as several benign conditions may also demonstrate clonality (e.g. pityriasis lichenoides et varioliformis acuta, lichen planus, pigmented purpuric dermatosis)

**Fig. 98.1** *Continued* **An approach to the patient with a suspected cutaneous T-cell lymphoma (CTCL).** CBCL, cutaneous B-cell lymphoma; NOS, not otherwise specified.

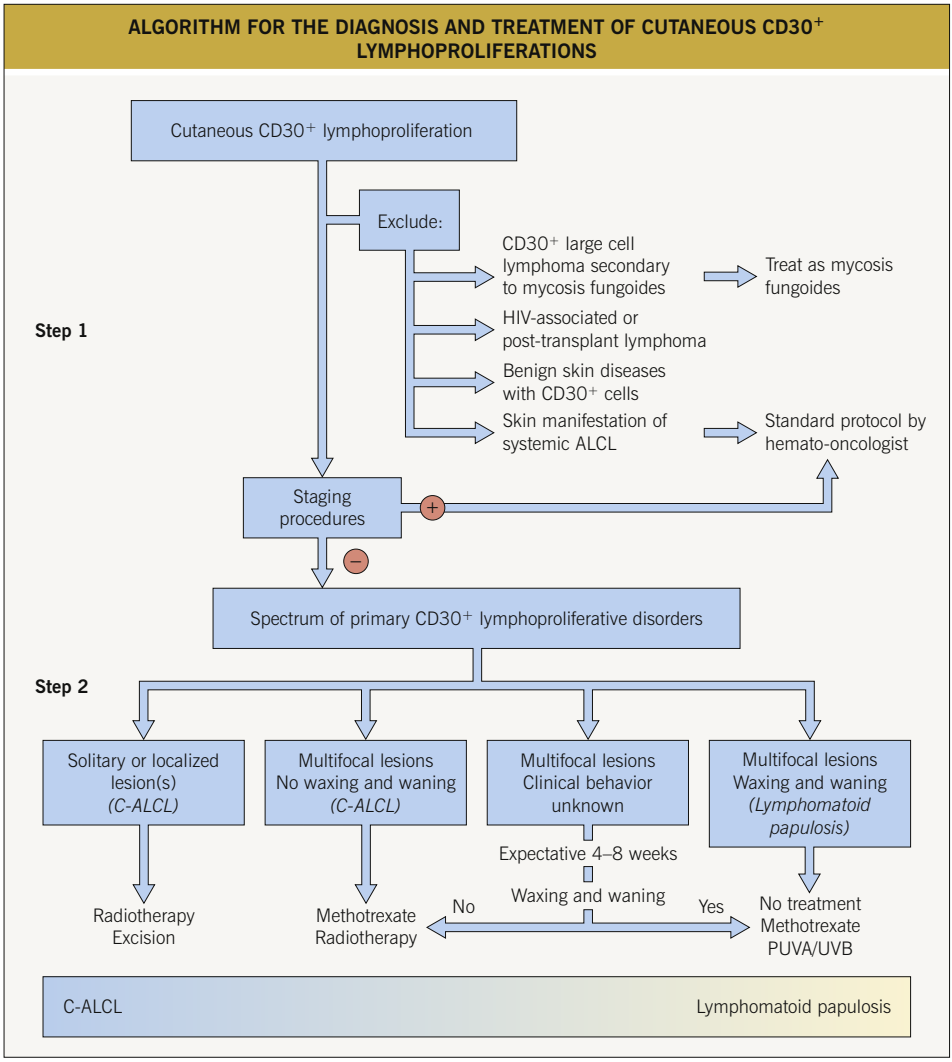


**Fig. 98.2 Algorithm for the diagnosis and treatment of primary cutaneous CD30+ lymphoproliferative disorders.** Cases previously designated as regressing atypical histiocytosis, as well as rare cases of primary cutaneous Hodgkin lymphoma with an indolent clinical course, also belong to this spectrum. Of note, there are reports of ALCL developing in patients with breast implants. C-ALCL, cutaneous anaplastic large cell lymphoma. *From Bekkenk M, Geelen FAMJ, van Voorst Vader PC, et al. Primary and secondary cutaneous CD30-positive lymphoproliferative disorders: long term follow-up data of 219 patients and guidelines for diagnosis and treatment. A report from the Dutch Cutaneous Lymphoma Group. Blood. 2000;95:3653–61.*

| RECOMMENDED STAGING EVALUATION FOR INDOLENT- AND AGGRESSIVE-BEHAVIOR CUTANEOUS T-CELL LYMPHOMAS (CTCL) |
|---|
| **Indolent-behavior CTCL** |
| • Physical examination, including lymph nodes and palpation for hepatosplenomegaly<br>• Laboratory studies: CBC with differential, platelets, chemistry panel, calcium, LDH<br>• Biopsy of persistently enlarged lymph node(s) |
| **Aggressive-behavior CTCL** |
| *In addition to that performed for indolent, also include:* |
| • CT vs CT/PET scan<br>• Referral to hematology–oncology |
| **Special tests, if clinically indicated** |
| • Detection of peripheral blood involvement (flow cytometry, TCR gene rearrangement, Sézary cell buffy coat preparation)<br>• HTLV-1 serology, Southern blot analysis, or PCR in at-risk populations |

**Table 98.4 Recommended staging evaluation for indolent- and aggressive-behavior cutaneous T-cell lymphomas (CTCL).** TCR, T-cell receptor; PET, positron emission tomography.

- Available therapies are effective in controlling disease but usually do not prolong life.
- Three main treatment categories are available: (1) skin-directed therapies (SDT); (2) systemic biologic therapies; and (3) systemic chemotherapies; combination therapy is also utilized (Table 98.7).
- Prognosis depends on stage, the type and extent of skin lesions, and the presence of extracutaneous disease (see Tables 98.5 and 98.6).
- The disease-related 10-year survival rate is approximately 95% for stage IA, 80% for stage IB, 40% for stage IIB, but only 20% for stage IV.
- An aggressive course is seen in patients with effaced lymph nodes, visceral involvement, or transformation into a large T-cell lymphoma.
- Death is usually due to systemic involvement or profound immunosuppression with resultant opportunistic infection.

## Sézary Syndrome (SS)

- A leukemic, more aggressive variant of CTCL that is thought to arise from a distinct functional T-cell subset.
- Defined historically by the triad of: (1) erythroderma; (2) generalized lymphadenopathy; and (3) the presence of clonally related neoplastic T cells (Sézary cells) in the skin, lymph nodes, and peripheral blood (Fig. 98.7).
- Diagnosis is aided by the presence of one of the following: (1) absolute Sézary cell count of ≥1000 cells/mm$^3$; (2) CD4:CD8 ratio ≥10 and/or an abnormal immunophenotype, including the loss of CD7 (>40%) or CD26 (>30%) by flow cytometry; and (3) evidence of T-cell clonality in the blood.
- SS is distinguished from patients who begin as classic MF who then become erythrodermic (erythrodermic MF).
- Prognosis is generally poor, and most patients die from opportunistic infections due to immunosuppression.
- Systemic treatment is required, with skin-directed therapies sometimes being used as adjuvant therapy (see Table 98.7).

For further information see Ch. 120 from *Dermatology, Fourth Edition*.

**For additional online figures and tables visit www.expertconsult.com**




**Fig. 98.3 Mycosis fungoides (MF).** **A** Limited patch/plaque stage disease (*stage 1A*). Patches on the buttocks, involving less than 10% of the skin surface. **B** Generalized patch/plaque disease (*stage 1B*). Extensive patches and plaques with scale involving more than 10% of the skin surface. **C** Hypopigmented MF (*stage 1B*) with generalized hypopigmented lesions as well as pink to pink-brown plaques. **D** *Tumor stage.* Multiple skin tumors in combination with typical patches and plaques. *A, C, D, Courtesy, Rein Willemze, MD; B, Courtesy Lorenzo Cerroni, MD.*



**Fig. 98.4 Folliculotropic mycosis fungoides.** Infiltrated erythematous plaques and acneiform lesions on the forehead and eyebrows with concurrent hair loss. The infiltration, thickening, and accentuation of the skin folds is referred to as a "leonine facies." *Courtesy, Rein Willemze, MD.*



**Fig. 98.5 Pagetoid reticulosis.** Solitary plaque on the left upper leg. *Courtesy, Rein Willemze, MD.*



**Fig. 98.6 Granulomatous slack skin.** Pendulous fold of atrophic lax skin in the right inguinal area. *Courtesy, Rein Willemze, MD.*



**Fig. 98.7 Sézary syndrome.** Diffuse erythroderma is present. *Courtesy, Rein Willemze, MD.*

| TNMB CLASSIFICATION OF MYCOSIS FUNGOIDES AND SÉZARY SYNDROME | |
|---|---|
| **T (skin)** | |
| $T_1$ | Limited patch/plaque (involving <10% of total skin surface) |
| $T_2$ | Generalized patch/plaque (involving ≥10% of total skin surface) |
| $T_3$ | Tumor(s) |
| $T_4$ | Erythroderma |
| **N (lymph node)** | |
| $N_0$ | No enlarged lymph nodes |
| $N_1$ | Enlarged lymph nodes, histologically uninvolved |
| $N_2$ | Enlarged lymph nodes, histologically involved (nodal architecture uneffaced) |
| $N_3$ | Enlarged lymph nodes, histologically involved (nodal architecture [partially] effaced) |
| **M (viscera)** | |
| $M_0$ | No visceral involvement |
| $M_1$ | Visceral involvement |
| **B (blood)** | |
| $B_0$ | No circulating atypical (Sézary) cells (or <5% of lymphocytes) |
| $B_1$ | Low blood tumor burden (≥5% of lymphocytes are Sézary cells, but not $B_2$) |
| $B_2$ | High blood tumor burden (≥1000/mcl Sézary cells + positive clone) |

**Table 98.5 TNMB classification of mycosis fungoides and Sézary syndrome.**

| CLINICAL STAGING SYSTEM FOR MYCOSIS FUNGOIDES AND SÉZARY SYNDROME | | | | |
|---|---|---|---|---|
| **Clinical stage** | | | | |
| IA | $T_1$ | $N_0$ | $M_0$ | $B_{0–1}$ |
| IB | $T_2$ | $N_0$ | $M_0$ | $B_{0–1}$ |
| IIA | $T_{1–2}$ | $N_{1–2}$ | $M_0$ | $B_{0–1}$ |
| IIB | $T_3$ | $N_{0–1}$ | $M_0$ | $B_{0–1}$ |
| IIIA | $T_4$ | $N_{0–2}$ | $M_0$ | $B_0$ |
| IIIB | $T_4$ | $N_{0–2}$ | $M_0$ | $B_1$ |
| $IVA_1$ | $T_{1–4}$ | $N_{0–2}$ | $M_0$ | $B_2$ |
| $IVA_2$ | $T_{1–4}$ | $N_3$ | $M_0$ | $B_{0–2}$ |
| IVB | $T_{1–4}$ | $N_{0–3}$ | $M_1$ | $B_{0–2}$ |

**Table 98.6 Clinical staging system for mycosis fungoides and Sézary syndrome.** The shaded boxes highlight the required features for the three subdivisions of stage IV disease. By definition, patients with Sézary syndrome are stage IVA or IVB because of blood involvement.

| TREATMENT OF MYCOSIS FUNGOIDES AND SÉZARY SYNDROME |
|---|
| **Premycotic phase** |
| • Topical or intralesional CS; narrowband UVB§<br>• If former not effective, PUVA§ |
| **Stage IA–IIA (patches/plaques)** |
| • PUVA§; HN2<br>• Narrowband UVB§ (if only patches)<br>• Topical CS or topical retinoids^ (if only limited patches/thin plaques as second-line therapy)<br>• XRT (if single lesion)<br>• TSEB (if generalized thick plaques) |
| **Stage IIB (skin tumors)** |
| • PUVA or HN2 + XRT (if only a few tumors)<br>• TSEB (followed by skin-directed therapies)<br>• Relapse: PUVA + IFN-α; PUVA + retinoids (acitretin; oral bexarotene*); second-line therapy: denileukin diftitox*,¶; HDACi (vorinostat, romidepsin)*<br>• Add XRT (if persistent tumors); consider second course of TSEB (10–20 Gy) |
| **Stage III (erythroderma)** |
| • ECP; if not effective, add oral bexarotene, IFN-α, low-dose MTX<br>• Low-dose chlorambucil and prednisone; low-dose methotrexate<br>• Add skin-directed therapies (PUVA; HN2; XRT), if necessary<br>• Second-line therapy: oral bexarotene*; denileukin diftitox*,¶; HDACi*; low-dose alemtuzumab; mogamulizumab-kpkc |
| **Stage IV (nodal, visceral involvement)** |
| • Multi-agent chemotherapy (e.g. CHOP)<br>• Biological response modifiers (denileukin diftitox¶; IFN-α; oral retinoids)<br>• Add skin-directed therapies (PUVA; HN2), if necessary<br>• Allogeneic hematopoietic stem cell transplantation (utilizing non-myeloablative reduced-intensity conditioning regimens), in selected cases |
| *§Address UV-shielded areas (e.g. upper inner thighs) via positioning.*<br>*^Bexarotene 1% gel, tazarotene 0.1% gel, altretinoin 0.1% gel.*<br>**Efficacy compared to traditional treatments yet to be determined.*<br>*¶At the time of writing, not commercially available.* |

**Table 98.7 Treatment of mycosis fungoides (MF) and Sézary syndrome (SS).** Topical bis-chloronitrosourea (BCNU; carmustine) is rarely used nowadays. Based upon one case series, topical resiquimod may be effective for Stage IA/IIA disease. SS requires systemic treatment with occasional use of skin-directed therapies as adjuvant treatment (see options listed for treatment of stage III and IV disease). Anti-PD-1 antibodies have been used to treat SS in the setting of PD-1 positivity. CHOP, cyclophosphamide, hydroxydaunomycin (doxorubicin), Oncovin® (vincristine) and prednisone; ECP, extracorporeal photopheresis; HDACi, histone deacetylase inhibitors; HN2, topical mechlorethamine (nitrogen mustard); IFN, interferon; TSEB, total skin electron beam.



**Fig. 98.8 Lymphomatoid papulosis (LyP).** Clinical presentation with papulonecrotic skin lesions at different stages of evolution. *Courtesy, Rein Willemze, MD.*



**Fig. 98.10 Subcutaneous panniculitis-like T-cell lymphoma (SPTCL).** Pink nodular skin lesions (arrowhead) as well as an area of lipoatrophy (arrow) at the site of a resolved nodule. *Courtesy, Rein Willemze, MD.*



**Fig. 98.12 Primary cutaneous aggressive epidermotropic CD8⁺ T-cell lymphoma.** Generalized skin tumors with central ulceration. *Courtesy, Rein Willemze, MD.*



**Fig. 98.9 Primary cutaneous anaplastic large cell lymphoma (C-ALCL).** Characteristic clinical presentation with a solitary ulcerating tumor. *Courtesy, Rein Willemze, MD.*



**Fig. 98.11 Extranodal NK/T-cell lymphoma, nasal type.** An extensive ulceronecrotic nasal mass, previously referred to as lethal midline granuloma. *Courtesy, Rein Willemze, MD.*



**Fig. 98.13 Primary cutaneous peripheral T-cell lymphoma, not otherwise specified.** Rapidly growing nodules and tumors. Note: The skin lesions in the left upper corner do not represent patches but, rather, deep plaques present for 2 weeks. *Courtesy, Rein Willemze, MD.*




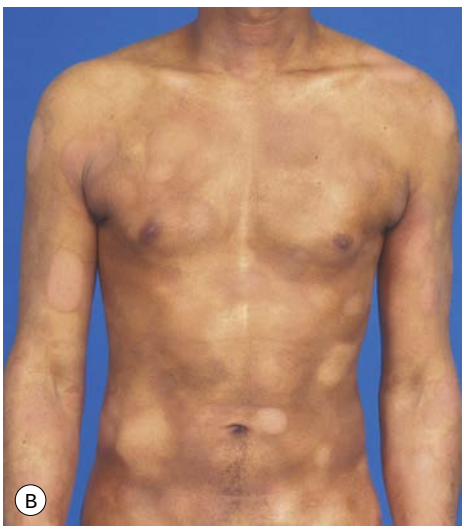


**eFig. 98.1 Mycosis fungoides (stage 1B).** **A** Generalized patch/plaque disease. Extensive patches and plaques involving more than 10% of the skin surface. **B** Generalized hypopigmented lesions as well as pink-colored plaques. *Courtesy, Rein Willemze, MD.*



**eFig. 98.2 Folliculotropic mycosis fungoides.** Acneiform lesions and cysts in the face. *Courtesy, Rein Willemze, MD.*

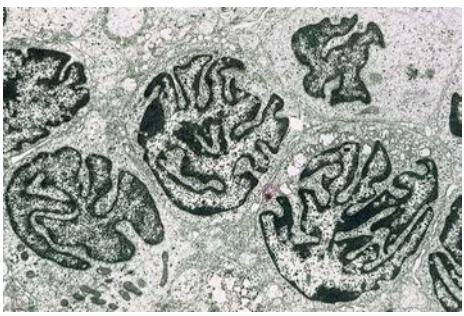

**eFig. 98.3 Sézary syndrome.** Electron photomicrograph of a skin biopsy showing characteristic Sézary cells. *Courtesy, Rein Willemze, MD.*

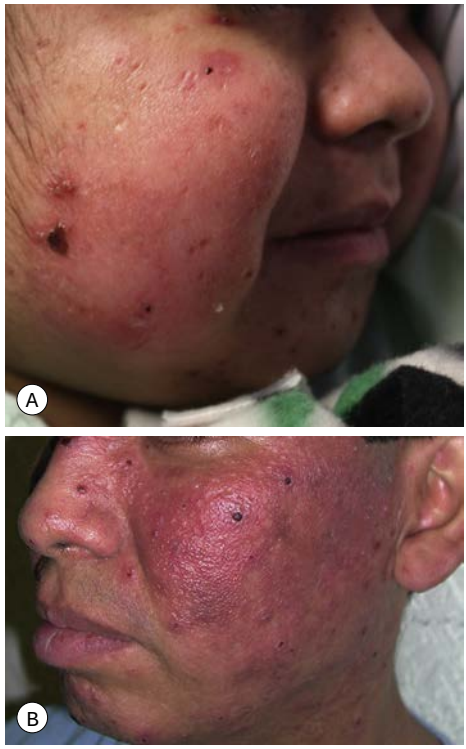


**eFig. 98.4 EBV-associated hydroa vacciniforme-like lymphoproliferative disorder (HV-like LPD). A** This Hispanic child had >50,000 copies of EBV DNA/100,000 WBCs as well as EBV RNA within skin lesions by *in situ* hybridization; he subsequently died of lymphoma. Note the facial edema, erythema, papulovesicles, hemorrhagic crusts, and varioliform scars. **B** Extensive involvement of the face by erythematous edematous plaques with hemorrhagic crusts at sites of vesiculation.
*A, Courtesy, Richard Antaya, MD; B, Courtesy, Henry W. Lim, MD and Cheryl F. Rosen, MD.*

| APPROACH TO INITIATING ORAL BEXAROTENE THERAPY FOR CUTANEOUS T-CELL LYMPHOMA | | | |
|---|---|---|---|
| | **Bexarotene administration** | **Monitoring** | **Management of side effects** |
| **Prior to treatment** | | Baseline CBC, basic metabolic panel, hepatic panel, TSH, free T4, fasting lipid panel, CK<br>Determine if patient takes medications that inhibit or induce CYP3A4 | Dietary and lifestyle modifications to minimize risk of hyperlipidemia<br>If pre-existing laboratory abnormalities, administer:<br>• Levothyroxine to achieve normal free T4 levels<br>• A fibrate (e.g. fenofibrate)* to achieve triglyceride level <200 mg/dl and HDL level >50 mg/dl<br>• A statin** to achieve LDL level <160 mg/dl |
| **Day –7** | | | Start fibrate (e.g. fenofibrate 145–200 mg daily)* |
| **Day 0** | Start bexarotene 150 mg/m$^2$ daily | | Start levothyroxine 0.05 mg daily |
| **Days 7 to 28** | | Free T4¶ & fasting lipid panel every 1–2 weeks | Adjust levothyroxine and fibrate doses and/or add statin** as required to keep laboratory values in target ranges above |
| **Day 28§** | Increase to bexarotene 300 mg/m$^2$ daily | | |
| **Day 29 onward** | Adjust bexarotene dose as needed depending on disease response | Free T4¶ & fasting lipid panel<br>• Every 1–2 weeks until in target range and after subsequent dose changes<br>• Otherwise every 1–2 months<br>CBC every 1–2 months | As above; a triglyceride level <400 mg/dl may be a more realistic target for some patients |

**Reduce dose for patients with decreased creatinine clearance; because gemfibrozil raises bexarotene levels, these medications should **not** be administered concomitantly.*
***Niacin represents another option for patients with combined hyperlipidemia; patients receiving a fibrate and statin concomitantly may be at increased risk of rhabdomyolysis.*
*¶Monitor free T4 as indicator of hypothyroidism; bexarotene lowers TSH levels (central hypothyroidism).*
*§May increase dose as early as day 14 or, if more time is required to normalize lipid and free T4 levels, after day 28.*

**eTable 98.1 Approach to initiating oral bexarotene therapy for cutaneous T-cell lymphoma.** CK, creatine kinase; HDL, high-density lipoprotein; LDL, low-density lipoprotein; T4, thyroxine.

# Other Lymphoproliferative and Myeloproliferative Diseases

# 99

## Benign Lymphocytic Infiltrates

### Lymphocytic Infiltrate of Jessner

- A benign skin-limited disorder that overlaps with other entities, including dermal lupus erythematosus, cutaneous lymphoid hyperplasia, and polymorphic light eruption (PMLE).
- Males = females; onset typically during middle age; very rare in children.
- Most commonly appears on the head, neck, and upper back as one or several asymptomatic, erythematous papules, plaques (often annular) > nodules (Fig. 99.1); no secondary or surface changes (such as scale or crust).
- May last several weeks to months and will typically resolve spontaneously over months to years without sequelae.
- No systemic manifestations.
- **DDx:** see Fig. 99.2.
- **Rx:** watch-and-wait approach is often acceptable; if Rx desired, consider topical (class I) or intralesional CS; less often hydroxychloroquine is used.

### Cutaneous Lymphoid Hyperplasia (CLH); also known as "Pseudolymphoma" or "Lymphocytoma Cutis"

- A benign, reactive lymphocytic proliferation that is thought to represent an exaggerated local immunologic reaction to a trigger that is usually unidentified.
- Inciting agents that have been reported include arthropod bites, tattoos, vaccinations, medications (e.g. antihistamines, antidepressants, angiotensin II receptor blockers), and in Europe, *Borrelia burgdorferi* infection.
- Presents most often on the head, neck, and upper extremities as one or several firm, erythematous to violaceous papules, plaques, or nodules (Fig. 99.3); usually no surface changes.
- Often spontaneously resolves without scarring.
- **DDx** (see Fig. 99.2): lymphocytic infiltrate of Jessner, lymphoma cutis, leukemia cutis, solid organ metastases, and occasionally adnexal tumors.
- **Rx:** topical (class I) or intralesional CS; excision or XRT; antibiotics if *Borrelia* infection.

### Extramedullary Hematopoiesis

- Most commonly seen in neonates secondary to underlying bone marrow dysfunction; rarely in adults secondary to myelofibrosis, other myeloproliferative disorders or after splenectomy.
- Most often associated with TORCH (*t*oxoplasmosis, *o*ther [e.g. parvovirus B19], *r*ubella, *c*ytomegalovirus) infections in neonates.
- Clinically presents with erythematous to violaceous papules and nodules > plaques, ulcers, or nasal polyps (Fig. 99.4).
- When widely disseminated (typically in neonates) it leads to the classic "blueberry muffin baby" presentation (Table 99.1).
- Diagnosis is made by histopathology (dermal infiltrates of immature erythrocytes, leukocytes, and megakaryocytes).
- **DDx:** see Table 99.1 for neonates, leukemia cutis in adults.
- **Rx:** treat underlying bone marrow dysfunction; spontaneous resolution typically occurs in cases related to viral infections.

## Malignant Hematopoietic Infiltrates

### Leukemia Cutis

- Cutaneous lesions associated with both acute and chronic leukemias may be either (1) *nonspecific* reactive skin lesions (Table 99.2);

or (2) *specific* infiltrates, called "leukemia cutis."

- Leukemia cutis typically presents as erythematous to violaceous firm papules or nodules (Fig. 99.5); less often purpura, ulcers, and rarely bullae; lesions may be hemorrhagic due to thrombocytopenia.
- Favors head, neck, trunk, and sites of scars or trauma.
- Less common presentations of leukemia cutis: chloromas, gingival hyperplasia.
- In most patients with acute leukemia, cutaneous lesions (if present) appear at the time of diagnosis or recurrence.
- Occasionally, leukemia cutis antedates the appearance of leukemia in the peripheral smear ("aleukemic leukemia cutis"); rarely predates apparent bone marrow involvement by months.
- **DDx:** lengthy list because of the protean clinical presentations of leukemia cutis, but may include lymphoma cutis, infectious emboli, vasculitis, drug eruptions, Sweet syndrome and other neutrophilic disorders, extramedullary hematopoiesis.
- **Rx:** treat the underlying leukemia.



**Fig. 99.1 Lymphocytic infiltrate of Jessner.** Annular erythematous plaque with central clearing on the face. *Courtesy, YDRSC.*

**DIFFERENTIAL DIAGNOSIS OF A PERSISTENT RED FACIAL PLAQUE**

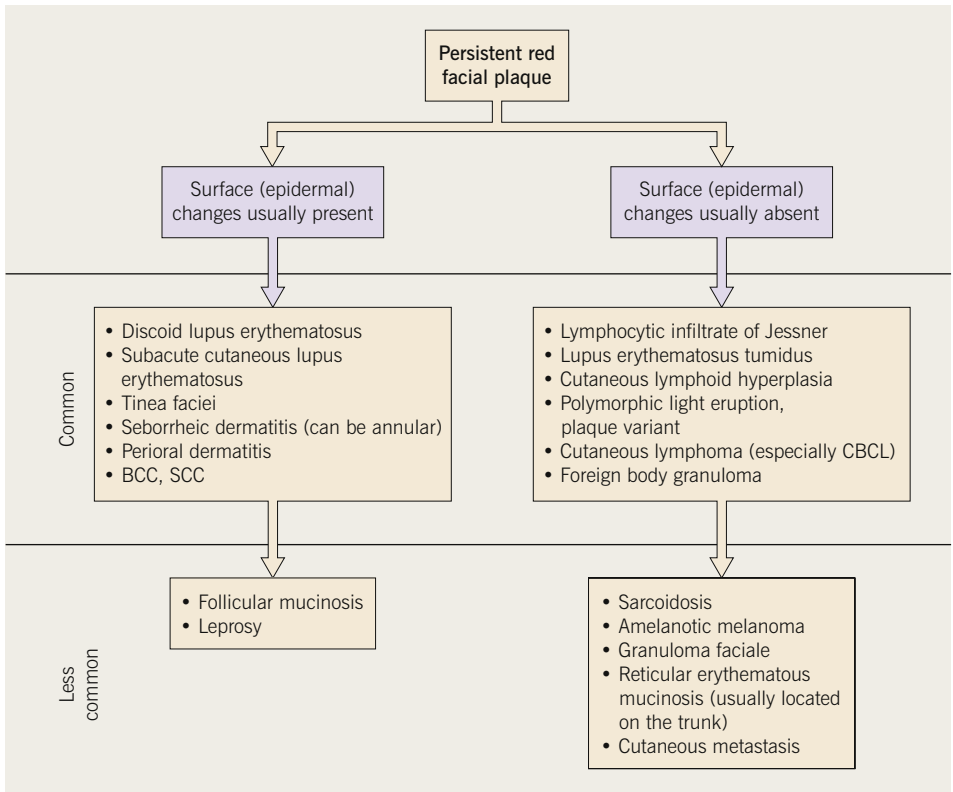


**Fig. 99.2 Differential diagnosis of a persistent red facial plaque.** CBCL, cutaneous B-cell lymphoma.

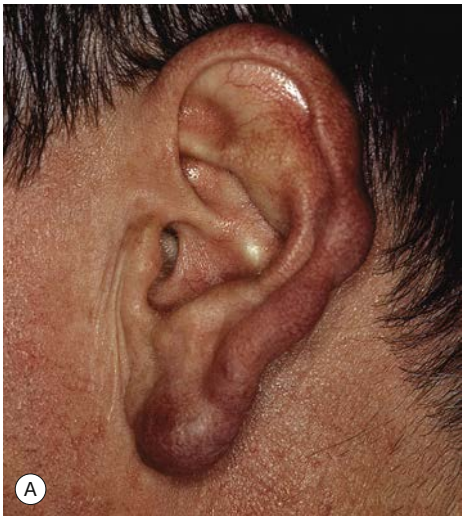





**Fig. 99.3 Cutaneous lymphoid hyperplasia (pseudolymphoma of the skin; lymphocytoma cutis). A** Violet papulonodules on the helix and lobe of the ear (unknown etiology). **B** Multiple red-brown to violet papules at the sites of *Hirudo medicinalis* (medicinal leech) application. *A, Courtesy, YDRSC; B, Courtesy, Cesare Massone, MD.*

## Cutaneous Hodgkin Lymphoma (Cutaneous Hodgkin Disease; HD)

- **Primary** or isolated cutaneous HD is very unusual; typically presents as one or several ulcerated nodules and usually follows a more indolent course, with prognosis similar to those patients with early stage HD.
- **Secondary** cutaneous HD, occurring in patients with advanced systemic disease, constitutes the vast majority of cutaneous HD cases and as expected carries a worse prognosis.



**Fig. 99.4 Extramedullary hematopoiesis.** "Blueberry muffin baby" secondary to congenital rubella. *Courtesy, Eugene Mirrer, MD.*

**DIFFERENTIAL DIAGNOSIS OF "BLUEBERRY MUFFIN BABY"**

Disseminated extramedullary hematopoiesis
- Prenatal infections
- TORCH
  - Congenital rubella
  - Cytomegalovirus
  - Toxoplasmosis
- Coxsackievirus
- Parvovirus
- Severe and chronic prenatal anemias
- Severe hemolytic anemias
  - Congenital spherocytosis
  - Rhesus hemolytic disease
  - ABO incompatibility
- Twin–twin transfusion
- Chronic fetomaternal hemorrhage
- Severe internal bleeding (e.g. intracranial)
- Myelodysplasia, congenital leukemia

Congenital leukemia cutis
Neonatal neuroblastoma
Congenital Langerhans cell histiocytosis
Congenital alveolar rhabdomyosarcoma
Hemangiomatosis, other vascular lesions (e.g. multifocal lymphangioendotheliomatosis, glomuvenous malformations)

**Table 99.1 Differential diagnosis of "blueberry muffin baby."** TORCH, *t*oxoplasmosis, *o*ther agents, *r*ubella, *c*ytomegalovirus and *h*erpes simplex virus.

- **Secondary** cutaneous HD usually presents with the rapid appearance of multiple, disseminated papulonodules and plaques, often on the trunk (Fig. 99.6), along with locations distal to affected lymph nodes.

| "INFLAMMATORY" DISORDERS ASSOCIATED WITH ACUTE AND CHRONIC LEUKEMIAS | |
|---|---|
| **Disorder** | **Associated leukemias** |
| **Neutrophilic dermatoses** | |
| Sweet syndrome | AML > CML, hairy cell leukemia, CNL > ALL, CLL |
| Pyoderma gangrenosum* | AML, CML, hairy cell leukemia > ALL, CLL |
| Neutrophilic eccrine hidradenitis | AML >> ALL, CML, CLL |
| **Reactive erythemas** | |
| Exaggerated arthropod reactions (eosinophilic dermatosis associated with hematologic disorders) | CLL > other hematologic disorders, chronic active EBV infection (see Table 98.3) |
| Erythroderma | CLL† |
| **Vasculitis** | |
| Polyarteritis nodosa | Hairy cell leukemia >> CMML |
| Vasculitis (small vessel/leukocytoclastic) | Hairy cell leukemia, CLL > AMML, ALL |
| Erythema elevatum diutinum | Hairy cell leukemia, CLL |
| **Panniculitis** | |
| Erythema nodosum** | AML, CML, CMML |
| Other panniculitides‡ | Hairy cell leukemia, AML, CMML |
| **Other** | |
| Paraneoplastic pemphigus | CLL |

**Especially bullous.*
*†Many probably represent Sézary syndrome.*
***Isolated case reports; may occur concomitantly with Sweet syndrome.*
*‡Including subcutaneous Sweet syndrome.*

**Table 99.2 "Inflammatory" disorders associated with acute and chronic leukemias.** ALL, acute lymphoblastic leukemia; AML, acute myelogenous leukemia; AMML, acute myelomonocytic leukemia; CLL, chronic lymphocytic leukemia; CML, chronic myelogenous leukemia; CMML, chronic myelomonocytic leukemia; CNL, chronic neutrophilic leukemia.

## Angioimmunoblastic T-Cell Lymphoma (AITCL)

- A peripheral T-cell lymphoma whose cells of origin are follicular T helper cells.
- Unique in that it characteristically presents *acutely* and at an advanced stage with fever, weight loss, sweats, lymphadenopathy, hepatosplenomegaly, and a diffuse, pruritic morbilliform eruption mimicking an acute viral infection or drug eruption.
- Other findings include polyclonal gammopathy, autoantibodies, hemolytic anemia, thrombocytopenia and eosinophilia.
- The morbilliform eruption and lymphadenopathy typically wax and wane, making suspicion and diagnosis of this malignancy even more elusive.
- The usual course is aggressive with a poor prognosis (median survival is <3 years); up to 30% may have longer-term survival.
- **DDx:** reactive lymphadenopathy due to a viral infection; drug eruptions, including DRESS; infectious mononucleosis, or other systemic inflammatory diseases.
- **Rx:** Systemic chemotherapy and allogeneic stem cell transplantation have been used but response and prognosis are poor.

## Lymphomatoid Granulomatosis (LYG)

- A rare, EBV-associated, angiocentric/destructive lymphoproliferative disorder that primarily affects the lungs, skin, and nervous system (less often the kidneys and gastrointestinal tract).
- Although previously classified as a reactive process, in most patients it represents a form of large B-cell lymphoma.
- LYG can be divided into grades 1, 2, or 3 depending on the proportion of CD20(+) large lymphoid cells.



**Fig. 99.5 Leukemia cutis.** Numerous red-brown papules and plaques on the back of a patient with acute myelogenous leukemia. *Courtesy, Cesare Massone, MD.*



**Fig. 99.6 Cutaneous Hodgkin lymphoma.** Pink to red-brown papulonodules within a thin erythematous plaque; note the larger tumor on the hip. *Courtesy, Lorenzo Cerroni, MD.*



**Fig. 99.7 Lymphomatoid granulomatosis.** Ulcerated violaceous plaque in the popliteal fossa. *Courtesy, Jean L. Bolognia, MD.*

- Most often seen in adults; males > females; can occur in the setting of immune dysfunction (e.g. renal transplantation, HIV infection, Wiskott–Aldrich syndrome).
- Frequently presents with cough, dyspnea, chest pain, fever, weight loss, malaise, arthralgia, and myalgia; cavitary pulmonary nodules on chest radiograph.
- Nodular or ulcerative cutaneous lesions in 25–50% (Fig. 99.7); rarely an exanthematous eruption develops.
- Typically follows an aggressive, fatal course with a 5-year mortality rate of 60–90%.
- **DDx:** other cutaneous lymphomas, infections (e.g. tuberculosis), pyoderma gangrenosum, medium vessel vasculitis, granulomatosis with polyangiitis, sarcoidosis.
- **Rx:** rituximab, multidrug chemotherapy, or perhaps interferon-α in earlier stage disease.

For further information see Ch. 121 from *Dermatology, Fourth Edition*.

**For additional online figures and tables visit www.expertconsult.com**



**eFig. 99.1 Lymphocytic infiltrate of Jessner.** Pink arciform plaques on the mid back. On palpation, the lesions feel infiltrated. *Courtesy, Cesare Massone, MD.*

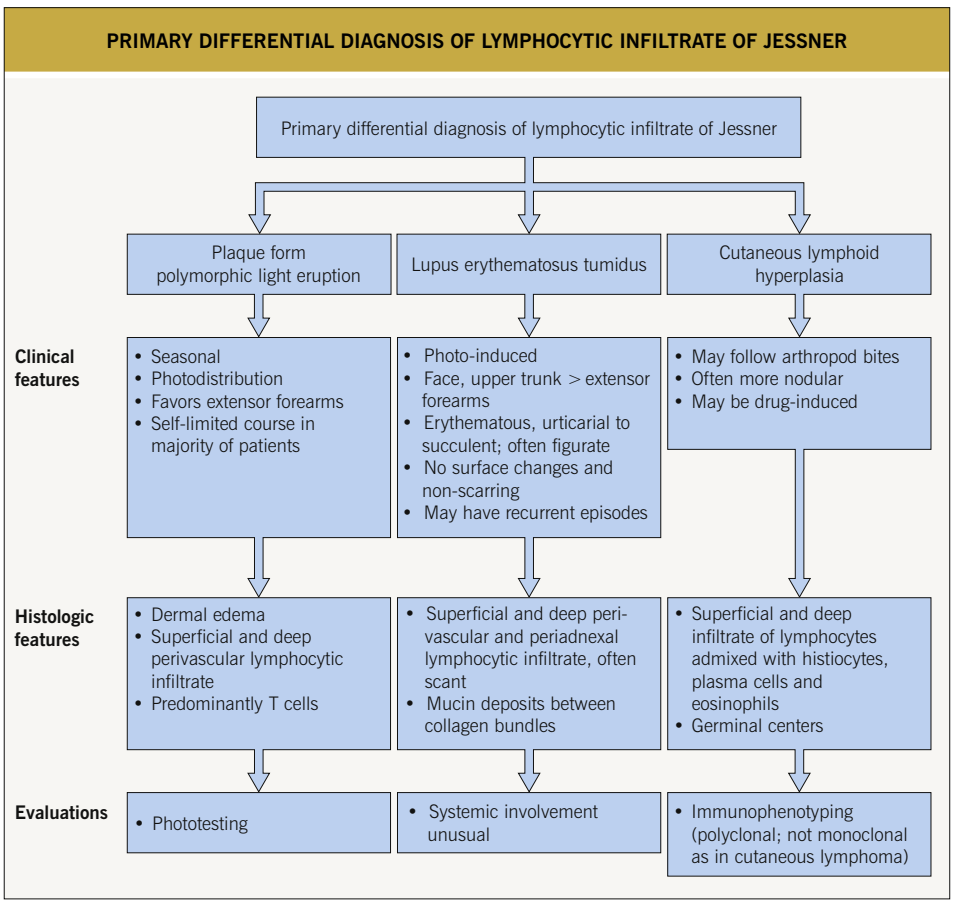


**eFig. 99.2 Primary differential diagnosis of lymphocytic infiltrate of Jessner.** Reticular erythematous mucinosis (REM) can also be considered in the differential diagnosis; histopathologically, abundant dermal mucin is observed. Some authors consider lymphocytic infiltrate of Jessner, LE tumidus, and REM to be similar entities along a clinical spectrum. The differential diagnosis also includes lymphoma cutis.




**eFig. 99.3 Cutaneous lymphoid hyperplasia (pseudolymphoma of the skin; lymphocytoma cutis). A** Pink nodule on and adjacent to the areola in an Austrian woman with *Borrelia burgdorferi*-associated lymphocytoma cutis. **B** Multiple red-brown to violet papules at the sites of *Hirudo medicinalis* (medicinal leech) application. *A, Courtesy, Cesare Massone, MD; B, Courtesy, Josef Smolle, MD.*



**eFig. 99.4 Miliarial-type perifollicular cutaneous lymphoid hyperplasia (pseudolymphoma).** An unusual variant of cutaneous lymphoid hyperplasia presenting as numerous violaceous, translucent perifollicular papules on the head and nek. The clinical differential diagnosis includes papular rosacea, acneiform eruptions, *Demodex* folliculitis, papular sarcoidosis, lupus miliaris disseminatus faciei, and miliary primary cutaneous follicle center lymphoma. *Courtesy, Karynne O. Duncan, MD.*

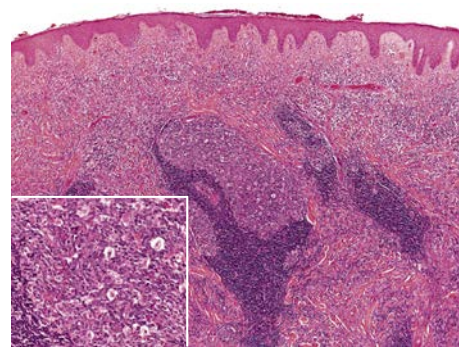

**eFig. 99.5 Cutaneous lymphoid hyperplasia (pseudolymphoma) – histopathologic features.** Lymphoid cells are seen throughout the dermis in a nodular and diffuse pattern. There is germinal center formation and tingible-body macrophages are present within the germinal centers (inset). The patient had *Borrelia burgdorferi*-associated lymphocytoma cutis. *Courtesy, Lorenzo Cerroni, MD.*



**eFig. 99.6 Extramedullary hematopoiesis.** "Blueberry muffin baby" secondary to congenital rubella. *Courtesy, James Graham, MD.*



**eFig. 99.7 Leukemia cutis – clinical features.** Multiple red-brown papules and plaques in a patient with hairy cell leukemia. *Courtesy, YDRSC.*

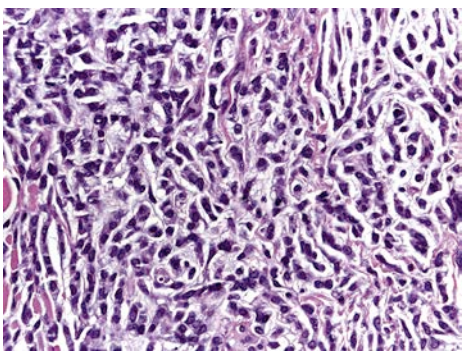

**eFig. 99.8 Leukemia cutis – histopathologic features.** An infiltrate of atypical monocytoid cells characterized by nuclear pleomorphism and relatively abundant cytoplasm is seen in a patient with acute myelogenous leukemia presenting with numerous red-brown papules and plaques on the torso. *Courtesy, Lorenzo Cerroni, MD.*



**eFig. 99.9 Cutaneous Hodgkin lymphoma.** A large pink plaque with central clearing is noted on the lower abdomen. *Courtesy, USCDRSC.*

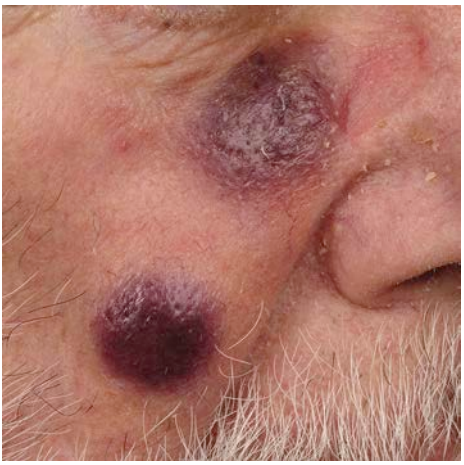

**eFig. 99.10 Blastic plasmacytoid dendritic cell neoplasm (BPDCN).** A rare, aggressive hematologic malignancy caused by transformed plasmacytoid dendritic cells that overexpress interleukin-3 receptor subunit alpha (IL3RA or CD123). It typically presents in older men with diverse clinical features, but cutaneous lesions are present in almost all cases. Two firm violaceous nodules on the cheek are seen in this patient with BPDCN. Prognosis and response to conventional multidrug chemotherapy regimens are poor. Recent clinical studies with tagraxofusp, a CD123-directed cytotoxin consisting of recombinant human interleukin-3 fused to a truncated diphtheria toxin, have shown promise in treating BPDCN. *Courtesy, Lorenzo Cerroni, MD.*

| ENTITIES THAT CAN MIMIC LYMPHOMA CUTIS (PSEUDOLYMPHOMAS) | | |
|---|---|---|
| **More common** | **Uncommon** | **Rare** |
| Persistent arthropod bites, scabies<br>*Borrelia* infections, in particular lymphocytoma cutis and acrodermatitis chronica atrophicans (Europe)<br>CD30+ reactive lymphoid infiltrates in the context of cutaneous infections (e.g. herpes simplex, herpes zoster, molluscum contagiosum)<br>Drug eruptions (lichenoid, lymphomatoid)<br>Lichenoid (lymphomatoid) keratosis<br>Pseudolymphomatous infiltrates in lupus erythematosus | Lichen sclerosus on genital skin<br>Lymphomatoid contact dermatitis<br>Pigmented purpura, lichenoid variant<br>Pityriasis lichenoides et varioliformis acuta (PLEVA), especially ulceronecrotic<br>Pseudolymphomatous atopic dermatitis<br>Pseudolymphomatous folliculitis<br>Pseudolymphomatous reactions to tattoo pigments<br>Syphilis, primary and secondary | Actinic reticuloid<br>APACHE (acral pseudolymphomatous angiokeratoma of children)<br>Cutaneous IgG4-related disease*<br>Cutaneous plasmacytosis<br>Hydroa vacciniforme<br>Intralymphatic histiocytosis<br>Kikuchi–Fujimoto disease<br>Lobular panniculitis in children with congenital immunodeficiencies<br>Pseudolymphomatous reactions to vaccinations<br>Vitiligo (inflammatory stage) |

**Increased IgG4-positive plasma calls and sclerotic stroma; can also see granuloma faciale-like lesions.*

**eTable 99.1 Entities that can mimic lymphoma cutis (pseudolymphomas).**

| CHARACTERISTICS OF DIFFERENT TYPES OF LEUKEMIA CUTIS | | | | |
|---|---|---|---|---|
| **Subtype of leukemia** | **ALL** | **CLL** | **AML** | **CML** |
| **Characteristic age** | Predominantly <6 years of age | Late 7th decade or older | Variable, most commonly 7th decade | Variable, most commonly after 50 years of age |
| **Presenting anatomic site** | Predominantly head and neck | Generalized; may appear at sites of infection (e.g. herpes zoster) or neoplasms (e.g. SCC) | Generalized | Variable |
| **Clinical course** | Aggressive | Indolent | Aggressive | Intermediate* |
| **Subtype of leukemia/ immunophenotype** | • Predominantly B-cell ALL ($TdT^+/CD5^+/CD19^+/CD20^+/CD10^+$)<br>• Rarely T-cell ALL ($TdT^+/CD1a^+/CD2^+/CD3c^+/CD5^+/CD7^+$) | • B-cell type ($CD5^+/CD20^+/CD43^+$) | • Most commonly, AMML (M4) & AMoL (M5)<br>• $CD13^+/CD33^+/CD68^+$/ myeloperoxidase-positive | • Most commonly, CMML<br>• Cutaneous involvement associated with blast transformation |
| **Incidence of cutaneous involvement** | Rare | Relatively common† | • Uncommon<br>• May be presenting sign | Rare |
| **Time of presentation** | Late | Late | Early | Late |
| **Clinical appearance** | • Large, nonulcerated tumors<br>• Nonspecific papulonodules | • Nonspecific papulonodules | • Nonspecific papulonodules | • Nonspecific papulonodules |

**When acceleration or blast transformation occurs, becomes aggressive.*
*†Often an incidental finding in biopsy specimens of primary cutaneous neoplasms (e.g. SCC) and inflammatory disorders.*

**eTable 99.2 Characteristics of different types of leukemia cutis.** Most patients with CML who develop vitiligo-like changes are receiving imatinib. ALL, acute lymphoblastic leukemia; AML, acute myelogenous leukemia; AMML, acute myelomonocytic leukemia; AMoL, acute monocytic leukemia; CLL, chronic lymphocytic leukemia; CML, chronic myelogenous leukemia; CMML, chronic myelomonocytic leukemia; TdT, terminal deoxytransferase.

| MEDICATIONS ASSOCIATED WITH CUTANEOUS LYMPHOID HYPERPLASIA (PSEUDOLYMPHOMA) | |
|---|---|
| **Antiarrhythmics** | *Mexiletine*, procainamide |
| **Antibiotics** | *Trimethoprim–sulfamethoxazole, cefixime,* cefuroxime, *nitrofurantoin,* clarithromycin, *vancomycin, rifampin, levofloxacin* |
| **Anticonvulsants** | *Carbamazepine, phenobarbital, phenytoin, ethosuximide, lamotrigine, valproic acid*, ethotoin, *gabapentin* |
| **Antidepressants** | *Amytriptyline*, desipramine, fluoxetine, clomipramine, lithium, *sertraline* |
| **Antihistamines** | Cimetidine, ranitidine, nizatidine, doxepin |
| **Antihypertensives** (including diuretics) | *Atenolol*, *captopril*, lisinopril, *diltiazem*, amlodipine, furosemide, amiloride, losartan, valsartan, clonidine patch, metoprolol |
| **Antipsychotics** | Chlorpromazine, perphenazine, thioridazine |
| **Chemotherapeutic agents** | *Imatinib*, fluorouracil, gemcitabine, oxaliplatin, tamoxifen, leucovorin |
| **Lipid-lowering agents** | Gemfibrozil, lovastatin |
| **Nonsteroidal anti-inflammatory drugs (NSAIDs)** | *Aspirin*, *ibuprofen*, *naproxen*, diclofenac, indomethacin, ketoprofen, sulindac, diflunisal, oxaprozin, nabumetone |
| **Rheumatologic agents** | *Allopurinol*, *dapsone*, *sulfasalazine,* TNF inhibitors, methotrexate, gold, D-penicillamine, tocilizumab |
| **Sedatives** | Benzodiazepines |
| **Steroid hormones** | Estrogen, progesterone |
| **Stimulants** | Methylphenidate |
| **Vaccines** | Hepatitis A, hepatitis B, varicella–zoster |
| **Miscellaneous** | Cyclosporine, interferon-alpha, aldesleukin (interleukin-2), glatiramer acetate, bromocriptine, black cohosh |

**eTable 99.3 Medications associated with cutaneous lymphoid hyperplasia (pseudolymphoma).** For patients with the drug reaction with eosinophilia and systemic symptoms (DRESS)/drug-induced hypersensitivity syndrome (DIHS) who have atypical lymphocytes in the blood and skin, the term pseudolymphoma is sometimes applied; however, although this is a separate entity (see Ch. 17), there is overlap. The drugs in *italics* have also been reported to cause DRESS/DIHS. *Courtesy, Harry L. Winfield, MD.*

# 100 Cutaneous Metastases

- Relatively rare with the exception of breast cancer and melanoma metastases.
- May be the presenting sign of a malignancy.
- Often associated with a poor prognosis.
- Overall, breast carcinoma most commonly metastasizes to the skin and prostate carcinoma least commonly (Table 100.1).
- Most common skin metastases: women – breast carcinoma, melanoma; men – melanoma, squamous cell carcinoma of the head and neck and lung, and colon carcinoma (Table 100.2).
- In general, nonspecific morphology: firm, mobile, painless papulonodule(s), often skin-colored to pink or red-brown and occasionally ulcerated (Figs 100.1 and 100.2).
- Other clinical morphologies may be characteristic of a particular primary malignancy (Table 100.3).
- Melanoma metastases vary from pink to blue to black and they may develop along the lymphatic drainage between the primary site and regional lymph nodes (referred to as in-transit metastases; AJCC Stage III) or at distant sites (AJCC Stage IV) (Fig. 100.2).
- Location of cutaneous metastases is generally near the primary tumor, especially when secondary to intralymphatic spread (e.g. squamous cell carcinoma of the head and neck, breast carcinoma).

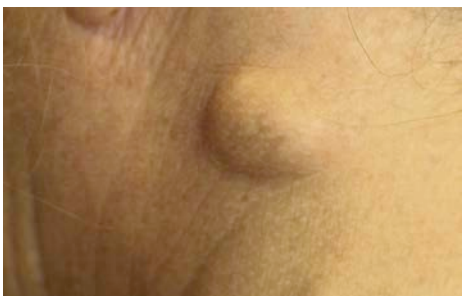

**Fig. 100.1 Cutaneous metastasis of small cell lung carcinoma on the neck.** This skin-colored nodule can resemble an epidermoid cyst or lipoma clinically but on palpation will be much firmer. *Courtesy, Ian Odell, MD.*

| PERCENTAGES OF PATIENTS WITH METASTATIC CANCER WHO HAD CUTANEOUS METASTASES | | |
|---|---|---|
| **Primary malignancy** | **Patients with metastatic disease (*n* = 4020)** | **Patients with cutaneous metastases (*n* = 420; 10%)** |
| Melanoma | 172 | 77 (45%) |
| Breast | 707 | 212 (30%) |
| Squamous cell carcinoma of the head and neck (e.g. laryngeal, oral) | 221 | 29 (13%) |
| Colon/rectum | 413 | 18 (4.5%) |
| Lung | 802 | 21 (2.5%) |
| Prostate | 207 | 0 |

**Table 100.1 Percentages of patients with metastatic cancer who had cutaneous metastases.** *Adapted from Lookingbill DP, Spangler N, Helm KF. Cutaneous metastases in patients with metastatic carcinoma: A retrospective study of 4020 patients.* J Am Acad Dermatol *1993;29(2 Pt 1):228–36.*

| RANKING OF UNDERLYING PRIMARY MALIGNANCIES IN PATIENTS WITH CUTANEOUS METASTASES – MEN VERSUS WOMEN | | | |
|---|---|---|---|
| **Primary malignancy** | **Men with cutaneous metastases (*n* = 127)** | **Primary malignancy** | **Women with cutaneous metastases (*n* = 300)** |
| Melanoma | 41 (32%) | Breast | 212 (70%) |
| Squamous cell carcinoma of the head and neck | 21 (16.5%) | Melanoma | 36 (12%) |
| Lung | 15 (12%) | | |
| Colon/rectum | 14 (11%) | | |

**Table 100.2 Ranking of underlying primary malignancies in patients with cutaneous metastases – men versus women.** *Adapted from Lookingbill DP, Spangler N, Helm KF. Cutaneous metastases in patients with metastatic carcinoma: A retrospective study of 4020 patients.* J Am Acad Dermatol *1993;29(2 Pt 1):228–36.*




**Fig. 100.2 Cutaneous metastases. A** Pink nodule on the scalp with associated alopecia due to a metastasis from lung carcinoma (alopecia neoplastica). **B** Red-purple eroded nodule due to a metastasis from renal cell carcinoma; such lesions may be confused with vascular tumors. **C** Multiple small dark purple to black papules on the left neck and chest due to metastatic melanoma. **D** Pink papules and plaques on the chest due to metastases from adenocarcinoma of the colon. The patient was referred for treatment of dermatitis. *A, Courtesy, Lorenzo Cerroni, MD; B, Courtesy, Edward Cowen, MD; C, Courtesy, Christopher Bunick, MD; D, Courtesy, Kalman Watsky, MD.*

| CLINICAL PRESENTATIONS OF CUTANEOUS METASTASES AND HISTOLOGIC CORRELATES | | | |
|---|---|---|---|
| **Type** | **Clinical description** | **Histology** | **Associated primary malignancy** |
| Dermal or subcutaneous nodules | Small miliary lesions to large tumors; single or multiple | Tumor cells infiltrating among collagen bundles or replacing dermis; grenz zone often present | Most common presentation; any type |
| Inflammatory carcinoma (carcinoma erysipeloides) | Erythematous patch with spreading border; resembles erysipelas | Tumor cells within dilated lymphatic vessels | Breast >> lung, ovary, prostate, GI, others |
| *En cuirasse* | Morpheaform or sclerodermoid, depending on extent; indurated with *peau d'orange* appearance | Fibrosis with infiltrating tumor cells | Breast >> lung, GI, kidney, others |
| Carcinoma telangiectoides | Red-violet papules | Tumor cells within superficial blood vessels and RBC sludging | Breast |
| Paget disease* | Patches extending from the nipple and areola that resemble dermatitis | Large, atypical epithelial cells with abundant pale cytoplasm arranged in solitary units and small nests within all layers of the epidermis | Breast |
| Alopecia neoplastica | Nodules or plaques on the scalp in association with alopecia | Cords of tumor cells between collagen bundles | Breast > lung, renal, others |
| Pyogenic granuloma-like | Rapidly growing nodule resembling a vascular tumor (particularly a pyogenic granuloma) | Neoplastic cells in cords and lobules admixed with prominent hemorrhage and "pseudovascular" spaces | Renal clear cell carcinoma, hepatocellular carcinoma > others |

**Lesions of extramammary Paget disease share similar histopathologic features with those of Paget disease of the breast, but they usually represent (>75% of patients) primary cutaneous adenocarcinomas (see Table 60.6); an underlying visceral malignancy is most likely when there is perianal involvement.*

**Table 100.3 Clinical presentations of cutaneous metastases and histologic correlates.** An individual patient can have an admixture of the various types. Occasionally, cutaneous metastases have a zosteriform distribution pattern and clinically they can resemble dermatoses, including eczema, vasculitis, and erythema annulare centrifugum. Obviously, they can also mimic epidermoid or pilar cysts as well as cutaneous tumors, including non-melanoma skin cancers, lipomas, granular cell tumors, or angiosarcoma.



A L G r a w a n y

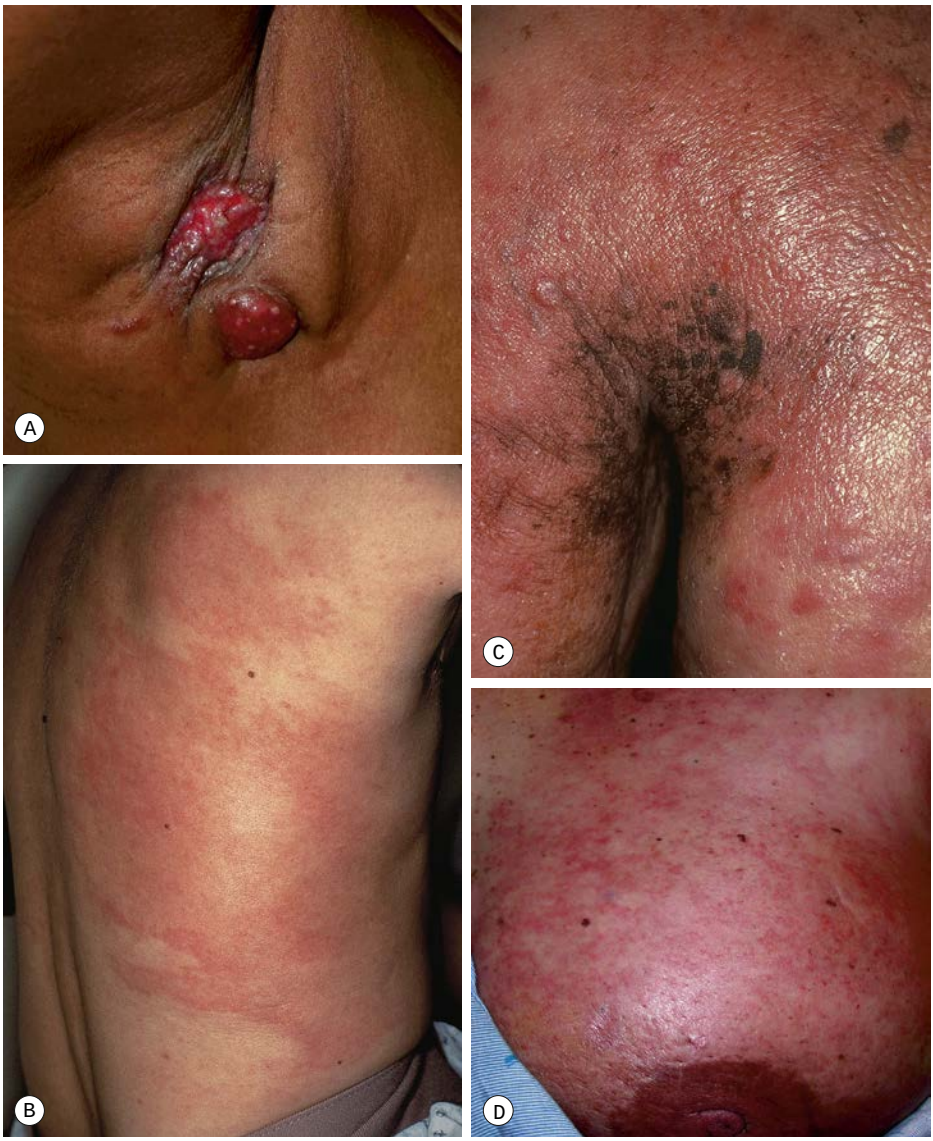


**Fig. 100.3 Various presentations of cutaneous metastases of breast carcinoma.** **A** Eroded erythematous nodules in the axilla. **B** Inflammatory form (carcinoma erysipeloides) with patches of erythema that may initially be misdiagnosed as infectious cellulitis. **C** Primarily *en cuirasse* form with obvious induration and *peau d'orange* appearance in addition to papulonodules. **D** Mixed pattern – reticulated erythema of carcinoma erysipeloides as well as *peau d'orange* appearance near the areola. *A, D, Courtesy, Matthew B. Zook, MD, and Stuart R. Lessin, MD; B, C, Courtesy, YDRSC.*



**Fig. 100.4 Alopecia neoplastica secondary to metastatic breast carcinoma.** Erythematous, indurated plaques of scarring alopecia on the scalp. *Courtesy, Joslyn S. Kirby, MD.*

## Metastatic Breast Carcinoma

- May have distinctive clinical morphologies (Fig. 100.3): (1) *carcinoma erysipeloides* – well-demarcated elevated erythema that resembles erysipelas or cellulitis; (2) *carcinoma telangiectoides* – telangiectasias and red papules; and (3) *carcinoma en cuirasse* – begins on the chest as induration with a *peau d'orange* appearance reminiscent of scleredema.



**Fig. 100.5 Cutaneous metastasis of colon carcinoma.** A Sister Mary Joseph nodule presenting as a pink plaque with scale-crust. *Courtesy, Matthew B. Zook, MD, and Stuart R. Lessin, MD.*

## Alopecia Neoplastica

- Scarring alopecia of the scalp (Fig. 100.4).
- Associated with breast, lung, gastric, and renal carcinomas.

## Sister Mary Joseph Nodule

- Pink to red-brown papule, umbilical or periumbilical (Fig. 100.5).
- Originally described in association with gastric carcinoma.
- May be associated with any abdominal malignancy.

For further information see Ch. 122 from *Dermatology, Fourth Edition*.

**For additional online figures visit www.expertconsult.com**



**eFig. 100.1 Metastases of adenocarcinoma of the lung.** Ulcerated erythematous nodules on the anterior trunk. *Courtesy, YDRSC.*



**eFig. 100.2 Localized melanoma metastases.** Discrete black papules are present within and at the periphery of the skin graft placed at the excision site. *Courtesy, Ronald P. Rapini, MD.*



**eFig. 100.3 Cutaneous metastases of renal cell carcinoma.** Pink plaques in a zosteriform pattern on the flank. *Courtesy, Stuart Lessin, MD.*

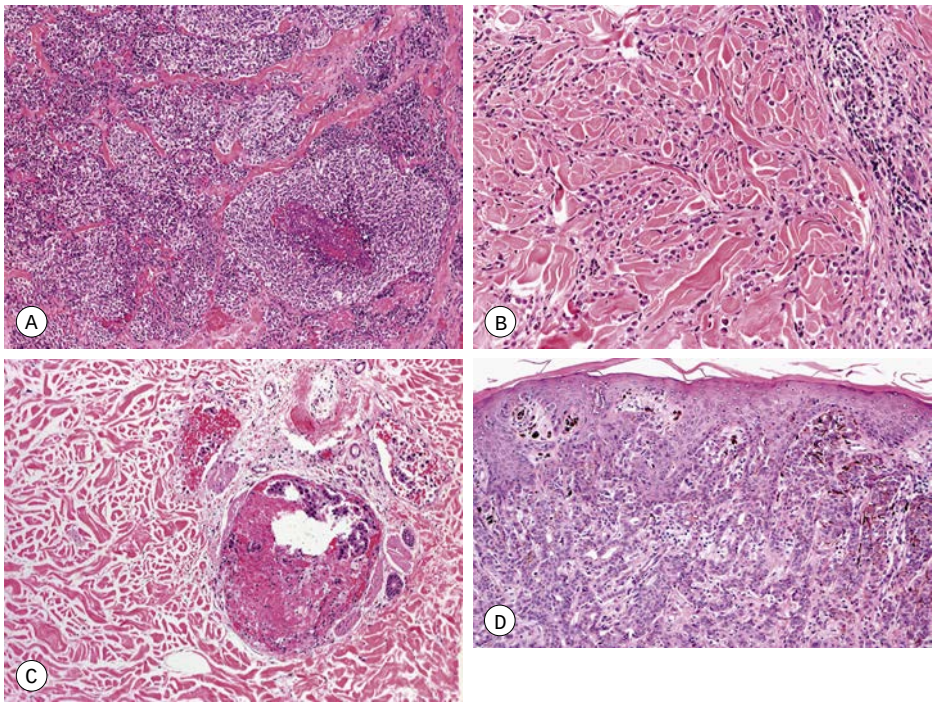


**eFig. 100.4 Major patterns of cutaneous metastases.** **A** Nodular pattern with focal, prominent necrosis in a cutaneous metastasis of small cell lung carcinoma. **B** Diffuse pattern with a linear arrangement of atypical cells in a metastasis of breast carcinoma. **C** Intralymphatic pattern in a metastatic breast carcinoma; tumor cells are confined to dilated lymphatic vessels. **D** Epidermotropic pattern in a metastasis of breast carcinoma; tumor cells are in both the dermis and the epidermis. The presence of focal pigmentation and melanocyte hyperplasia could lead to the misdiagnosis of a melanocytic tumor. *Courtesy, Lorenzo Cerroni, MD.*

# Appendix

| FITZPATRICK SCALE OF SKIN PHOTOTYPES | | |
|---|---|---|
| **Skin phototype** | **Skin color** | **Response to UV irradiation** |
| I | White | Always burns, does not tan |
| II | White | Burns easily, tans with difficulty |
| III | Beige | Mild burns, tans gradually |
| IV | Brown | Rarely burns, tans easily |
| V | Dark brown | Very rarely burns, tans very easily |
| VI | Black | Never burns, gets darker |

## DETERMINATION OF THE SUN PROTECTION FACTOR (SPF)

- 10 human subjects
- Skin type I or II
- Irradiation: light source which mimics solar spectrum
- Procedure: determine minimal erythema dose (MED) in sunscreen-protected* and unprotected skin

$$\text{SPF} = \frac{\text{MED protected}}{\text{MED unprotected}}$$

- To test substantivity – after application and before MED testing:
  Water resistant (40): 2 × 20-min water immersions (whirlpool bath)†
  Water resistant (80): 4 × 20-min water immersions (whirlpool bath)†

**Sunscreen product applied at 2 mg/cm$^2$.*
*†Air drying in between immersions.*

| RELATIONSHIP OF THE SUN PROTECTION FACTOR (SPF) TO BLOCKAGE OF ERYTHEMAL RADIATION | |
|---|---|
| **SPF** | **Blockage of erythemal radiation (%)** |
| 10 | 90 |
| 15 | 92.5 |
| 20 | 95 |
| 40 | 97.5 |

## FDA PROPOSED RULE ON SUNSCREENS (2019) – ULTRAVIOLET B (UVB) AND ULTRAVIOLET A (UVA) PROTECTION AND LABELING REQUIREMENTS

**Ultraviolet B (UVB) protection**

- Raise the maximum proposed labeled SPF from 50+ to 60+
- Allow marketing on sunscreen products formulated up to an SPF of 80

**Ultraviolet A (UVA) protection**

- Require any sunscreen with SPF 15 or higher to be BROAD SPECTRUM
- Requirement for all BROAD SPECTRUM sunscreens with an SPF ≥ 15: as the SPF increases, so too does the magnitude of protection against UVA
- Require that BROAD SPECTRUM sunscreens provide adequate protection against UVA
  - UV absorbance critical wavelength of ≥ 370 nm (90% of the area under the curve [AUC])
  - UVA1/UV ratio of ≥ 0.7

*Continued*

| FDA PROPOSED RULE ON SUNSCREENS (2019) – ULTRAVIOLET B (UVB) AND ULTRAVIOLET A (UVA) PROTECTION AND LABELING REQUIREMENTS—cont'd |
|---|
| **Substantivity*** |
| • WATER RESISTANT (40 minutes) or WATER RESISTANT (80 minutes)<br>• The following designations are prohibited: "WATERPROOF", "SUNBLOCK", "ALL DAY PROTECTION", or "SWEAT PROOF" |
| **Additional labeling** |
| • Include an alphabetical listing of active ingredients on the front of the packaging<br>• If the SPF of the sunscreen is <15, then it must have the following Skin Cancer/Skin Aging Alert: "Spending time in the sun increases your risk of skin cancer and early skin aging. This product has been shown only to help prevent sunburn, not skin cancer or early skin aging"<br>• Require font and placement changes to ensure the terms SPF, BROAD SPECTRUM, and WATER RESISTANT are obvious on the label<br>• Optional: If a sunscreen has an SPF ≥15 *and* is BROAD SPECTRUM, then can state that the product can help to reduce the risk of skin cancer and the risk of early skin aging, when used regularly and as directed in combination with other sun protection measures |
| **These changes were proposed and implemented in the 2011 FDA final rule for "Labeling and Effectiveness Testing: Sunscreen Drug Products for Over-the-Counter Human Use"* |

Active ingredient safety and dosage forms are addressed in next table. SPF, sunscreen protection factor. *Adapted from Department of Health and Human Services/Food and Drug Administration. Sunscreen drug products for over-the-counter human use. Federal Register 2019;84:6204-75.*

| FDA PROPOSED RULE (2019) FOR GRASE STATUS OF SUNSCREEN ACTIVE INGREDIENTS AND DOSAGE FORMS | | | |
|---|---|---|---|
| | **GRASE** | **Not GRASE** | **Insufficient data to support positive GRASE determination** |
| **Active sunscreen ingredients** | Zinc oxide<br>Titanium dioxide | Para-aminobenzoic acid*<br>Trolamine salicylate* | Avobenzone, cinoxate, dioxybenzone, ensulizole, homosalate, meradimate, octinoxate, octisalate, octocrylene, oxybenzone, padimate O, sulisobenzone |
| **Dosage forms^** | Lotions, creams, ointments, oils, gels, butters, pastes, sticks, sprays^^ | Sunscreen-insect repellant combinations** | Powders |

**Not currently marketed in the US.*
*^Wipes, towelettes, body washes, shampoos and other dosage forms are categorized as "new drugs" because the FDA has not yet received enough information about their efficacy and safety.*
*^^Sprays are approved as GRASE subject to testing, including particle size restrictions to avoid inhalation toxicity; flammability testing; and related safety labeling requirements.*
***Data suggest that combining some sunscreen active ingredients with some insecticides may increase absorption of one or both components. CDC recommends that if applying both a sunscreen and an insect repellant, apply the sunscreen first and then the insect repellant.*

Each of the 16 approved active ingredients was assigned to one of three categories: (1) GRASE (generally recognized as safe and effective); (2) not GRASE; or (3) insufficient data to support positive GRASE determination. For the third group, the FDA requires additional information to determine whether or not sunscreens with these ingredients and dosage forms are GRASE. Of note, it does not mean that the FDA has concluded that these ingredients and dosage forms are unsafe. *Adapted from Department of Health and Human Services/Food and Drug Administration. Sunscreen drug products for over-the-counter human use. Federal Register 2019;84:6204-75.*

| COMMONLY USED INSECT REPELLENTS | |
|---|---|
| **Conventional repellents in EPA classification** | |
| DEET (N,N-diethyl-3-methylbenzamide)* | Effective against a wide range of arthropods |
| | Long history of use |
| Picaridin (KBR 3023) | Good evidence for mosquitoes |
| | Fewer studies support repellent effect against ticks |
| **Biopesticide repellents in EPA classification** | |
| IR3535 (3-[N-butyl-N-acetyl]-aminopropionic acid, ethyl ester) | Good evidence for mosquitoes in some, but not all, studies |
| | Fewer studies support repellent effect against ticks |
| p-Menthane-3,8-diol† | Good evidence for mosquitoes |
| | Fewer studies support repellent effect against ticks |
| Botanicals (e.g. soybean oil, citronella, neem oil, fennel oil, geraniol) | Have consumer appeal as "natural" repellents |
| | Best published evidence is for neem oil |
| | Lack of evidence does not necessarily equate to lack of efficacy, but available evidence to date suggests they are inferior to the synthetic repellents listed above |

**There is a plateau of efficacy at 30% with long-acting products, and higher concentrations should generally be avoided. Because sunscreens require frequent reapplication and DEET does not, combination products with these ingredients are not recommended.*
*†The active ingredient of oil of lemon eucalyptus; use on children less than 3 years of age is not recommended.*

Agents are listed in order of decreasing evidence of efficacy. Sunscreen, if also used, should be applied first. Treatment of clothing and other fabrics with permethrin can also be helpful, especially to repel ticks and chiggers (see Ch. 72). EPA, Environmental Protection Agency.

| POTENCY RANKING OF SOME COMMONLY USED TOPICAL GLUCOCORTICOSTEROIDS |
|---|
| **Class 1 (superpotent)** |
| • Clobetasol propionate gel, ointment, cream, lotion, foam, spray and shampoo 0.05%<br>• Betamethasone dipropionate gel* and ointment* 0.05%<br>• Diflorasone diacetate ointment* 0.05%<br>• Fluocinonide cream 0.1%<br>• Flurandrenolide tape 4 mcg/cm$^2$<br>• Halobetasol propionate ointment and cream 0.05% and lotion 0.01% |
| **Class 2 (high potency)** |
| • Amcinonide ointment 0.1%<br>• Betamethasone dipropionate cream*, lotion*, gel and ointment 0.05%<br>• Clobetasol propionate solution ("scalp application") 0.05%<br>• Desoximetasone ointment and cream 0.25% and gel 0.05%<br>• Diflorasone diacetate ointment and cream* 0.05%<br>• Fluocinonide gel, ointment, cream and solution 0.05%<br>• Halcinonide ointment, cream and solution 0.1%<br>• Mometasone furoate ointment 0.1%<br>• Triamcinolone acetonide ointment 0.5% |
| **Class 3 (high potency)** |
| • Amcinonide cream and lotion 0.1%<br>• Betamethasone dipropionate cream, lotion, and spray 0.05%<br>• Betamethasone valerate ointment 0.1%<br>• Diflorasone diacetate cream 0.05%<br>• Fluticasone propionate ointment 0.005%<br>• Triamcinolone acetonide ointment 0.1% and cream 0.5% |

*Continued*

| POTENCY RANKING OF SOME COMMONLY USED TOPICAL GLUCOCORTICOSTEROIDS—cont'd |
|---|
| **Class 4 (medium potency)** |
| • Betamethasone valerate foam 0.12%<br>• Desoximetasone cream 0.05%<br>• Fluocinolone acetonide ointment 0.025%<br>• Flurandrenolide ointment 0.05%<br>• Hydrocortisone valerate ointment 0.2%<br>• Mometasone furoate cream and lotion 0.1%<br>• Triamcinolone acetonide ointment (Kenalog®) and cream 0.1% or spray 0.2% |
| **Class 5 (medium potency)** |
| • Betamethasone dipropionate lotion 0.05%<br>• Betamethasone valerate cream and lotion 0.1%<br>• Clocortolone pivalate cream 0.1%<br>• Fluocinolone acetonide cream 0.025% or oil and shampoo 0.01%<br>• Fluticasone propionate cream and lotion 0.05%<br>• Flurandrenolide cream and lotion 0.05%<br>• Hydrocortisone butyrate ointment, cream and lotion 0.1%<br>• Hydrocortisone probutate cream 0.1%<br>• Hydrocortisone valerate cream 0.2%<br>• Prednicarbate ointment and cream 0.1%<br>• Triamcinolone acetonide ointment 0.025% and lotion 0.1% |
| **Class 6 (low potency)** |
| • Alclometasone dipropionate ointment and cream 0.05%<br>• Triamcinolone acetonide cream 0.1% (Aristocort®)<br>• Betamethasone valerate lotion 0.1%<br>• Desonide gel, ointment, cream, lotion and foam 0.05%<br>• Fluocinolone acetonide cream and solution 0.01%<br>• Triamcinolone acetonide cream and lotion 0.025% |
| **Class 7 (low potency)** |
| • Topicals with hydrocortisone, dexamethasone and prednisolone |
| **Optimized vehicle.* |

| INSTRUCTIONS FOR OPEN WET DRESSINGS |
|---|
| 1. Use a single thickness of thin white cotton material such as a pillowcase, handkerchief, or bed sheet. Do not use a towel or washcloth. |
| 2. Place the material in either (depending upon what is recommended):<br>• Warm tap water<br>• Domeboro® solution (one packet per 16 oz of water stored in the refrigerator, then brought to room temperature). |
| 3. Squeeze out excess water, do not wring dry. |
| 4. Unravel material and cover red, itchy areas with the wet dressing – **apply as only one (1) layer.** Do not apply additional materials such as a blanket. |
| 5. Allow the wet dressing to remain on the skin for 10–15 minutes. |
| 6. Remove the wet dressing and allow skin to air dry. When the skin is dry, apply the topical corticosteroid prescribed. |
| 7. You may feel chilled if you have covered large areas of your body. If you are treating the entire body then place dressings to one side of the body at a time. |
| Open wet dressings allow cooling by continuous evaporation of water. They are used to decrease redness, itching, burning and weeping of skin lesions. They will help to make you more comfortable. Apply two to three times per day. |

| CORTICOSTEROID CLASSES |
|---|
| **Group 1: non-methylated, most often non-halogenated molecules (formerly A, D2, and budesonide)** |
| Budesonide* |
| Cortisone acetate |
| Fludrocortisone acetate |
| *Hydrocortisone*^ |
| Hydrocortisone aceponate |
| Hydrocortisone acetate^ |
| *Hydrocortisone-17-butyrate* |
| Hydrocortisone-21-butyrate |
| Methylprednisolone aceponate |
| Methylprednisolone acetate |
| Prednisolone |
| Prednisone |
| *Tixocortol pivalate* |
| Triamcinolone |
| **Group 2: halogenated molecules with a $C_{16}/C_{17}$ cis ketal/diol structure (formerly B)** |
| Amcinonide |
| Desonide |
| Fluocinolone acetonide |
| Fluocinonide |
| Halcinonide |
| *Triamcinolone acetonide* |
| **Group 3: halogenated and $C_{16}$-methylated molecules (formerly C, D1)** |
| Aclometasone dipropionate |
| Betamethasone |
| Betamethasone-17-valerate |
| Betamethasone dipropionate |
| Betamethasone-disodium phosphate |
| *Clobetasone butyrate* |
| Clobetasol propionate |
| Desoximetasone |
| Dexamethasone |
| Dexamethasone-disodium phosphate |
| Fluocortolone |
| Fluticasone propionate |
| Mometasone furoate |

**Budesonide R-isomer may cross-react with acetonides in Group 2.*
*^Available without a prescription in the U.S.*

Most allergic reactions are due to corticosteroids in Group 1. Suggested patch test screening agents are in *italics* for when allergic contact dermatitis to topical CS is suspected; all but hydrocortisone are in the American Contact Dermatitis Society screening series.

| SPECIAL CONSIDERATIONS FOR CORTICOSTEROID AND ANTIHISTAMINE USE DURING PREGNANCY | |
|---|---|
| **Corticosteroids** | |
| Topical | • Overuse of high-potency products can lead to systemic absorption, and halogenated corticosteroids do cross the placenta; they may also add to the already considerable risk of striae<br>• Corticosteroids that have enhanced cutaneous metabolism (e.g. mometasone furoate, prednicarbate, and methylprednisolone aceponate) can also be considered |

*Continued*

| SPECIAL CONSIDERATIONS FOR CORTICOSTEROID AND ANTIHISTAMINE USE DURING PREGNANCY—cont'd | |
|---|---|
| **Corticosteroids** | |
| Systemic | • Prednisolone is the systemic corticosteroid of choice for dermatologic indications because it is largely inactivated in the placenta (mother:fetus = 10:1)<br>• During the first trimester, particularly between weeks 8 and 11, there is a possible (debated) slightly increased risk of cleft lip/cleft palate, especially if high doses prescribed and for >10 days; during this same period, a longer duration of therapy appears safe if dosages are <10–15 mg daily<br>• If use is long term and extends late into gestation, fetal growth should be monitored and the risk of adrenal insufficiency in the newborn should be addressed |
| **Antihistamines** | |
| Systemic | • During the first trimester, the classic sedating agents (e.g. chlorpheniramine, clemastine, dimethindene) are preferred<br>• During the second and third trimesters, if a non-sedating agent is requested, loratadine and cetirizine are considered safe |

*Courtesy, Christina M. Ambros-Rudolph, MD.*

| DOSING OF SYSTEMIC DRUGS MOST COMMONLY USED IN DERMATOLOGY | |
|---|---|
| **Corticosteroids** | |
| **Duration** | ***Examples of three scenarios*** |
| • Short-term | *Acute allergic contact dermatitis (e.g. poison oak), severe*<br>Prednisone 60 mg each AM × 5–7 days, 40 mg × 5–7 days, 20 mg × 5–7 days<br>In children, begin with ~1 mg/kg of prednisolone and taper in a similar fashion over 15–21 days |
| • Medium-term (requires monitoring for osteopenia) | *DRESS*<br>Prednisone 1 mg/kg each AM then taper over ~3–4 months, following peripheral eosinophil count and any other abnormal laboratory value or systemic involvement (as well as cutaneous examination) |
| • Long-term (requires monitoring for osteopenia) | *Bullous pemphigoid, moderate-to-severe disease*<br>Prednisone 0.5–1 mg/kg each AM then taper over ~7–9 months, e.g. when 1 mg/kg/day, taper by 5 mg every 10 days then when reach 30 mg daily go to alternate day and decrease by 2.5 mg every 14 days until reach 5 mg every other day |
| **Retinoids** | |
| Acitretin | 10–50 mg/day, depending upon disorder |
| Isotretinoin | *Acne*<br>0.5–1 mg/kg/day^, often reaching a cumulative dose of 120–150 mg/kg |
| **Antimalarials** | |
| Chloroquine | Adult: 125–250 mg/day, up to 2.3 mg/kg actual body weight/day<br>Children: <2.3 mg/kg actual body weight/day |
| Hydroxychloroquine | Adult: 200 mg daily–twice daily, up to 5 mg/kg actual body weight/day (whichever is lower)<br>Children: ≤5 mg/kg actual body weight/day up to a maximum of 400 mg/day |

*Continued*

| DOSING OF SYSTEMIC DRUGS MOST COMMONLY USED IN DERMATOLOGY—cont'd | |
|---|---|
| **Immunosuppressives** | |
| Azathioprine | Empiric dosing after checking thiopurine methyltransferase (TPMT) level*:<br>0.5 mg/kg/day (TPMT level 5–13.7 U)<br>1.5 mg/kg/day (TPMT level 13.7–19 U)<br>2.5 mg/kg/day (TPMT level > 19 U) |
| Cyclosporine emulsion | For psoriasis, <6–12 months continual use: 2.5–5 mg/kg/day; taper at 3 months by 1 mg/kg/day every 2 weeks as tolerated |
| Methotrexate | 5–25 mg (for children, 0.2–0.7 mg/kg) once weekly, depending upon disease and severity |
| Mycophenolate mofetil | 1500–3000 mg (for children, 30–50 mg/kg) daily, divided into 2 doses |
| Rituximab | 375 mg/m$^2$ weekly for 3–4 weeks – *or* –<br>1 g on days 0 and 14 repeated in 4 or more months as directed by anti-desmoglein antibody levels |
| **Other** | |
| Apremilast | 30 mg twice daily if no renal impairment; upward titration from 10 mg/day recommended |
| Colchicine | 0.5 or 0.6 mg two to three times daily |
| Dapsone | 50–200 mg/day (for children, 1–2 mg/kg/day) |
| IVIg | Dosage, duration, and schedule vary by disease, e.g. total 2 g/kg per monthly cycle over 2–5 days in dermatomyositis |
| Spironolactone | For acne vulgaris or hidradenitis suppurativa: 50–200 mg/day<br>For hirsutism or female pattern hair loss: 100–200 mg/day<br>• Usually given in divided doses, twice daily<br>• Often used in combination with OCPs<br>• Clinical response may take up to 3 months |
| Thalidomide | 25–100 mg/day, can be tapered to every other day, depending on disease |

*^Typically begin with ≤0.5 mg/kg the first month, with lower initial doses and slower escalation for patients with more severe inflammatory acne (especially teenage boys).*
**Contraindicated if TPMT level <5 U.*

Monitoring recommendations are available online. OCP, oral contraceptive pill.

| USE OF POTASSIUM IODIDE (KI) |
|---|
| **Saturated solution of potassium iodide (SSKI)** |
| • 1000 mg/ml<br>• Droppers are supplied with calibrations for:<br>1. 0.3 ml (300 mg)*<br>2. 0.6 ml (600 mg)<br>• In adults and older children, common dose = 300 mg TID PO with starting dose = 150–300 mg TID<br>• In infants and young children, common dose = 150 mg TID PO<br>• SSKI should be diluted in water or juice to try to minimize the bitter aftertaste<br>• Crystallization may occur with cold temperatures, but rewarming and shaking dissolves the crystals; discard if solution turns yellow-brown |
| **Side effects of SSKI** |
| • Acute – nausea, bitter eructation, excessive salivation, urticaria, angioedema, cutaneous small vessel vasculitis<br>• Chronic – enlargement of salivary and lacrimal glands, acneiform eruption, iododerma, hypothyroidism, hyperkalemia, occasionally hyperthyroidism |
| **0.3 ml = 10 drops from the calibrated dropper supplied with SSKI.* |

| BIOLOGIC AGENTS | | | |
|---|---|---|---|
| | **Medication** | **Available as** | **Dosing** |
| TNF inhibitors | Adalimumab | 10–80 mg prefilled syringes<br>40 mg autoinjector | Psoriasis: 80 mg SC loading dose, then 40 mg SC at day 8, then 40 mg every other week<br>Hidradenitis suppurativa (age ≥12 y and ≥60 kg):<br>160 mg SC loading dose, then 80 mg on day 15, then 40 mg weekly starting day 29 |
| | Certolizumab | 200 mg prefilled syringe | Psoriasis: 400 mg SC at weeks 0, 2, 4; then 200–400 mg every other week |
| | Golimumab | 50 mg prefilled syringe/ autoinjector | Psoriatic arthritis: 50 mg SC monthly |
| | Etanercept | 25–50 mg prefilled syringes<br>50 mg autoinjectors<br>25 mg multiple use vials | Adult: 25–50 mg BIW × 3 months, then 50 mg weekly<br>Children (age ≥4 y): 0.8 mg/kg weekly (maximum 50 mg) |
| | Infliximab | | 3–10 (most commonly 5) mg/kg slow IV infusion at 0, 2, 6, 8 weeks, then every 8 weeks |
| IL-12/23 inhibitors | Guselkumab | 100 mg prefilled syringe | 100 mg SC at weeks 0, 4, 8 and every 8 weeks |
| | Risankizumab | 75 mg prefilled syringe | 150 mg SC at weeks 0 and 4 and every 3 months |
| | Tildrakizumab | 100 mg prefilled syringe | 100 mg SC at weeks 0, 4, and every 12 weeks |
| | Ustekinumab | 45 mg and 90 mg prefilled syringes<br>45 mg single dose vial<br>IV solution | Psoriasis (age ≥12 y):<br>90 mg (if >100 kg), 45 mg (if 60–100 kg), or 0.75 mg/kg (if <60 kg) SC at weeks 0 and 4, then every 12 weeks |
| IL-17 inhibitors | Brodalumab | 210 mg prefilled syringe | 210 mg SC every other week |
| | Ixekizumab | 80 mg prefilled syringe/autoinjector | 160 mg SC loading dose then 80 mg every other week × 12 weeks, then 80 mg monthly |
| | Secukinumab | 150 mg prefilled syringe/autoinjector | 300 mg SC weekly × 5 weeks, then every 4 weeks |
| Dupilumab | | Adults and adolescents (age ≥12 y and ≥60 kg): 600 mg SC at week 0 then 300 mg every other week<br>Adolescents <60 kg: 400 mg SC at week 0 then 200 mg every other week | |

| RECOMMENDED LABORATORY EVALUATION FOR PATIENTS RECEIVING TARGETED IMMUNOMODULATORS FOR PSORIASIS | |
|---|---|
| **Prior to treatment** | **During treatment** |
| Tuberculin skin test*/interferon-γ release assay** and/or (e.g. if immunosuppression or history of tuberculosis) chest X-ray<br>CBC, CMP<br>Hepatitis B and C virus serologic profiles<br>Consider HIV testing | Annual tuberculin skin test*/interferon-γ release assay** and/or chest X-ray<br>CBC or CMP every 3–12 months (or as clinically indicated) |

*≥5 mm of induration should be considered as positive.
**e.g. QuantiFERON® TB Gold or T-SPOT®.TB.

A complete medical history and physical examination should also be performed, with particular attention to history/risk/symptoms/signs of tuberculosis, other chronic infections, malignancy, neurologic disorders and cardiac disease (especially congestive heart failure in patients receiving TNF-α inhibitors). CMP, comprehensive metabolic panel (includes liver function tests).

| SLICC CLASSIFICATION CRITERIA FOR SYSTEMIC LUPUS ERYTHEMATOSUS (2012) | |
|---|---|
| **Clinical criteria** | **Immunologic criteria** |
| • Acute^ or subacute cutaneous lupus<br>• Chronic cutaneous lupus^^<br>• Oral or nasal ulcers<br>• Non-scarring alopecia<br>• Arthritis (synovitis involving ≥2 joints)<br>• Serositis (e.g. pleural or pericardial)<br>• Renal (proteinuria ≥500 mg/24 hours *OR* RBC casts)<br>• Neurologic (e.g. seizures, psychosis, mononeuritis multiplex, myelitis)<br>• Hemolytic anemia<br>• Leukopenia (<4000/mm$^3$) *OR* lymphopenia (<1000/mm$^3$)<br>• Thrombocytopenia (<100,000/mm$^3$) | • ANA (above lab reference range)<br>• Anti-ds-DNA (above lab reference range)<br>• Anti-Sm positivity<br>• Antiphospholipid antibody positivity (e.g. positive lupus anticoagulant, false-positive rapid plasma reagin, medium- or high-titer anti-cardiolipin antibody level, or positive anti-$\beta_2$-glycoprotein I antibody)<br>• Low complement (C3, C4, CH50)<br>• Direct Coombs test (in the absence of hemolytic anemia) |
| • Criteria for the classification of SLE include: ≥**4** criteria (at least 1 clinical and 1 immunologic criteria) *OR* biopsy-proven lupus nephritis with either positive ANA or anti-ds-DNA | |

*^Includes malar rash (but not discoid lesions), bullous lupus, toxic epidermal necrolysis variant of SLE, maculopapular lupus rash, photosensitive lupus rash (in the absence of dermatomyositis).*
*^^Discoid lesions (localized or generalized), hypertrophic lupus, lupus panniculitis, mucosal lupus, LE tumidus, chilblain lupus, discoid lupus/lichen planus overlap.*

These revised criteria are intended to be more clinically relevant and to incorporate new immunologic information. They have not been tested for the purposes of SLE diagnosis. SLICC, Systemic Lupus International Collaborating Clinics. *Adapted from Petri M et al. Arthritis Rheum 2012;64:2677.*

**For online cutaneous melanoma patient worksheet visit www.expertconsult.com**

# CUTANEOUS MELANOMA PATIENT WORKSHEET

## AJCC MELANOMA TNM CLASSIFICATION – 2017

| T category | Thickness | Ulceration status |
|---|---|---|
| Tis (melanoma in situ) | NA | NA |
| T1 | <0.8 mm | a. – |
| | <0.8 mm<br>0.8–1.0 mm | b. +<br>b. +/– |
| T2 | >1.0–2.0 mm | a. – |
| | | b. + |
| T3 | >2.0–4.0 mm | a. – |
| | | b. + |
| T4 | >4.0 mm | a. – |
| | | b. + |

| N category | Number of tumor-involved regional lymph nodes | Presence of in-transit, satellite, and/or microsatellite metastases |
|---|---|---|
| N0 | No regional metastases detected | No |
| N1 | One tumor-involved node – or – in-transit, satellite, and/or microsatellite metastases with no tumor-involved nodes | |
| N1a | One clinically occult (i.e. detected by SLN biopsy) | No |
| N1b | One clinically detected | No |
| N1c | No regional lymph node disease | Yes |
| N2 | Two or three tumor-involved nodes – or – in-transit, satellite, and/or microsatellite metastases with one tumor-involved node | |
| N2a | Two or three clinically occult | No |
| N2b | Two or three, at least one of which was clinically detected | No |
| N2c | One clinically occult or clinically detected | Yes |
| N3 | Four or more tumor-involved nodes – or – in-transit, satellite, and/or microsatellite metastases with two or more tumor-involved nodes – or – any number of matted nodes without or with in-transit, satellite, and/or microsatellite metastases | |
| N3a | Four or more clinically occult | No |
| N3b | Four or more, at least one of which was clinically detected, or presence of any number of matted nodes | No |
| N3c | Two or more clinically occult or clinically detected and/or presence of any number of matted nodes | Yes |

| M category | Anatomic site | LDH level |
|---|---|---|
| M0 | No evidence of distant metastasis | NA |
| M1a | Distant metastasis to skin, soft tissue including muscle, and/or non-regional lymph node | Not recorded or unspecified<br>(0) Not elevated<br>(1) Elevated |
| M1b | Distant metastasis to lung with or without M1a sites of disease | Not recorded or unspecified<br>(0) Not elevated<br>(1) Elevated |
| M1c | Distant metastasis to non-CNS visceral sites with or without M1a or M1b sites of disease | Not recorded or unspecified<br>(0) Not elevated<br>(1) Elevated |
| M1d | Distant metastasis to CNS with or without M1a, M1b or M1c sites of disease | Not recorded or unspecified<br>(0) Not elevated<br>(1) Elevated |

## AJCC STAGE GROUPINGS FOR CUTANEOUS MELANOMA – 2017

| | Survival (% at 5 years) | Clinical staging | | | Pathologic staging | | |
|---|---|---|---|---|---|---|---|
| | | T | N | M | T | N | M |
| 0 | | Tis | N0 | M0 | Tis | N0 | M0 |
| IA | 97 | T1a | N0 | M0 | T1a | N0 | M0 |
| | | | | | T1b | | |
| IB | 93 | T1b | N0 | M0 | T2a | N0 | M0 |
| | | T2a | | | | | |
| IIA | 82 | T2b | N0 | M0 | T2b | N0 | M0 |
| | 79 | T3a | | | T3a | | |
| IIB | 68 | T3b | N0 | M0 | T3b | N0 | M0 |
| | 71 | T4a | | | T4a | | |
| IIC | 53 | T4b | N0 | M0 | T4b | N0 | M0 |
| III | | Any T, Tis | ≥N1 | M0 | | | |
| IIIB | | | | | T0 | N1b, N1c | M0 |
| IIIC | | | | | T0 | N2b, N2c, N3b or N3c | M0 |
| IIIA | 78 | | | | T1a/b–T2a | N1a or N2a | M0 |
| IIIB | 59 | | | | T1a/b–T2a | N1b/c or N2b | M0 |
| | | | | | T2b/T3a | N1a–N2b | |
| IIIC | 40 | | | | T1a–T3a | N2c or N3a/b/c | M0 |
| | | | | | T3b/T4a | Any N ≥ N1 | |
| | | | | | T4b | N1a–N2c | |
| IIID | | | | | T4b | N3a/b/c | M0 |
| IV | 9–27* | Any T | Any N | M1 | Any T, Tis | Any N | M1 |

*Based upon 2009 AJCC melanoma TNM classification and prior to advent of targeted therapy and immunotherapy.*

## CRITERIA FOR CONSIDERATION OF SENTINEL LYMPH NODE BIOPSY (SLNB)

**Discuss SLNB**
- Stage T1a: <0.8 mm without ulceration but with any adverse features*
- Stage T1b: <0.8 mm with ulceration
  0.8–1.0 mm with or without ulceration

**Discuss and offer SLNB**
- Stage >T2a: >1.0 mm

**Young age (<40 years), presence of lymphovascular invasion, positive deep biopsy margin (especially if diffuse), high mitotic rate.*

Patient name: .....

Date of initial biopsy: .....

Location of lesion: .....

Histologic diagnosis: .....

- Breslow depth: .....
- Ulceration: ..... + ..... or ..... –
- Mitoses/mm$^2$: .....
- Margins: .....
- Other: .....

TNM classification: .....

Stage (clinical): .....

Stage (pathologic): .....

## COMPARISON OF SURVIVAL CURVES IN FOUR STAGES OF MELANOMA

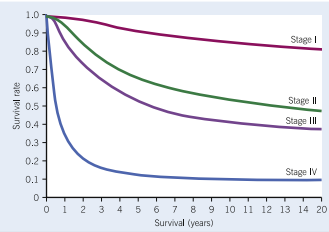


## SURGICAL TREATMENT OF PRIMARY CUTANEOUS MELANOMA

| Tumor thickness | Excision margins (cm) | Comments |
|---|---|---|
| In situ | 0.5 | Lentigo maligna of the face may be excised with 1cm margins (especially when lesions are >1.5–2 cm in diameter) or treated by Mohs micrographic surgery or radiotherapy; postoperative topical imiquimod is often used |
| ≤1 mm<br>1.01–2 mm<br>>2 mm | 1.0<br>1.0–2.0<br>2.0 | Mohs micrographic surgery may be necessary in acral and facial melanomas |

**Treatment plan:**

- ☐ Re-excision with ..... cm margins
- ☐ Referral for SLNB and re-excision
- ☐ Referral to oncologist
- ☐ CBC, LFTs, LDH
- ☐ CT chest, abdomen, pelvis
- ☐ CXR
- ☐ PET/CT
- ☐ Ultrasound: .....
- ☐ MRI: .....
- ☐ Other: .....